

# AMR Seminar #64

## Case – 1

**Contributed by:** N. Volkan Adsay

**Clinical history:** 47 year old female with a history of rheumatoid arthritis for eight years and systemic lupus erythematosus for 10 years, presented with colonic inertia and gallstones. She was hospitalized with a chief complaint of chronic constipation and abdominal pain, which has gone on for approximately 12 years. Ancillary studies demonstrated delayed gastric emptying, decreased rectal tone and dysfunction of anal sphincters. She underwent subtotal colectomy with ileorectal side-to-end anastomosis and cholecystectomy. Gross examination of the colectomy specimen revealed markedly thin colonic wall without any segmental dilatation and the mucosa was unremarkable.



# AMR Seminar #64

## Case – 2

**Contributed by:** Carlos Bacchi

(Case originally from: Dr. Luciana Gurgel T. Henriques, Recife, Brazil)

**Clinical history:** This is a 19-year-old female with a right cervical lymphadenopathy.

**Pathological findings:** This is a lymph node with intense capsular fibrosis forming cellular nodules delimited by thick fibrous bands. In those nodules, most of the neoplastic cells were represented by mononuclear cells, with moderate to abundant eosinophilic cytoplasm. The nuclei showed some variations, i.e., round, oval- or kidney-shaped, with more or less coarse chromatin and small- to medium-sized nucleoli. There were also numerous binucleated neoplastic cells with prominent nucleoli reminiscent of Reed-Sternberg cells. In fact, at medium power those cells had remarkable similarities with lacunar cells of Hodgkin lymphoma, nodular sclerosis. In areas, sinus involvement was present by neoplastic cells. The background of the cellular nodules was formed by lymphocytes, plasma cells and eosinophils. Mummified cells were sometimes observed. In part of the lymph node, residual germinal centers with thick fibrous bands around them were also seen.

**Immunohistochemistry study:** Immunostaining showed the following results: CD30-pos., ALK-pos. (cytoplasmic staining pattern only; see image at AMR website), granzyme B-pos., CD45RB-focally positive, CD20-neg., CD3-neg., CD15-neg., PAX-5-neg., CD2-neg., LMP1-neg. and EBER/ISH-neg.


**Final diagnosis:** ALK-positive anaplastic large cell lymphoma mimicking nodular sclerosis Hodgkin lymphoma with null phenotype.

**Comments:** This case can be easily misdiagnosed as Hodgkin lymphoma on morphological grounds alone. In fact, even with immunohistochemistry if the ALK antibody is not included in the panel, pathologist can interpret a case like this as CD30+/CD15- nodular sclerosis, Hodgkin lymphoma. In particular, the presence of lacunar-like cells and mummified cells in association with thick bands of fibrosis are all morphological characteristics that can lead to the wrong diagnosis of Hodgkin lymphoma instead of ALK+ALCL. It has been described that most of these cases are correctly classified after immunohistochemistry only. In this case, the morphological finding that called our attention for the possibility of ALK+ALCL was the presence of subcapsular sinus involvement besides some of the cytological aspects of the tumor cells (kidney-shaped nuclei).

Most of the ALK+ALCL Nodular Sclerosis Hodgkin lymphoma-like described show ALK staining with cytoplasmic, nuclear and nucleolar pattern, which suggests an association with the t(2;5)(p23;q35) and the NPM-ALK protein. In our case, the pattern of ALK immunostaining was granular cytoplasmic only, which can be associated with other types of translocation including a different ALK partner than *NPM*. We did not perform genetic analysis in the present case. The study of EBV in our case, both by immunohistochemistry (LMP1) and ISH (EBER), was negative for EBV. This indicates, as already described in the literature that, in contrast to HL, ALCL is not an EBV-associated disease.

Harald Stein first described ALK+ALCL in 1982. It is a peripheral T-cell lymphoma (PTCL) consisting usually of large neoplastic cells with abundant cytoplasm and pleomorphic, often horseshoe-shaped, nuclei, with a translocation involving the *ALK* gene, and expression of ALK protein, as well as of CD30. ALCL with similar morphologic and phenotypic features, but lacking the *ALK* rearrangement and the ALK protein, are considered as a separate category (ALK-negative ALCL). ALK+ ALCL must be distinguished from primary cutaneous ALCL, which is usually ALK- and other subtypes of T- or B-cell lymphoma with anaplastic features and/or CD30 expression. Of note, ALK+ ALCL with a B-cell phenotype is considered a subtype of diffuse large B-cell lymphoma. ALK+ALCL usually expresses one or more T-cell antigens (CD3, CD2), but some cases like the cases presented here, may have "null" phenotype.

George Delson's group described in 2006, 10 cases of ALK+ALCL mimicking nodular sclerosis Hodgkin's lymphoma. He stated that although rare, Hodgkin-like ALCL may mimic NSHL, and it is advisable to include EMA in the first line panel and to ask for ALK staining in EMA-positive, CD15-negative lesions with morphologic features suggestive of NSHL.



**References:**

1. Vassallo J, Lamant L, Brugieres L. ALK-positive anaplastic large cell lymphoma mimicking nodular sclerosis Hodgkin's lymphoma: report of 10 cases. *Am J Surg Pathol*; 30 (2):223–229, 2010.
2. Ferreri AJM, Govi S, Pileri SA, Savage KJ. Anaplastic large cell lymphoma, ALK-positive. *Crit Rev Oncol/Hematol* 83:293-302, 2012.



# AMR Seminar #64

## Case – 3

**Contributed by:** David Ben-Dor

**Short Summary:** Enlarged left inguinal lymph node from a 42 year old man.

**Case Description:** The patient is a surgeon on the medical staff of my hospital (whose specialty is not related to the issues which will be raised in this discussion) and is known to me personally. He felt a mass in the groin which ultrasound examination confirmed to be a lymph node. The lesion was excised by the head of the general surgery department. No other information was made available even when I discussed the case with the patient.

**Gross and Microscopic Description:** The specimen measured about 3 cm and was composed of friable grayish-tan tissue. On histology there are sheets of enlarged cells with round nuclei and prominent nucleoli. There are relatively thin fibrous partitions in the lesion containing small lymphoid cell infiltrates as well as aggregates of epithelioid histiocytes.

**Diagnostic Evaluation:** My first reflexive evaluation was lymphoma. I did an initial battery of basic immunostains including LCA, CD20, CD3, and CD43 to get started and was surprised when they all turned out to be negative. Though I didn't do any cytokeratins or S100, I still wouldn't allow myself to be dissuaded from my initial instinct, explaining away the initial results with the assumption that it could still be an anaplastic lymphoma (I didn't do CD30 and don't have ALK, though it would be hard to ignore the CD43 negativity), maybe a T cell lymphoma (I don't have all the required CD's), or some sort of unusual histiocytic lesion. In short obviously more evaluation was needed.

**Further Developments:** Based on my initial opinion of lymphoma, which I expressed with great confidence, the patient had already made an appointment to consult with a hematologist at the Hadassah hospital in Jerusalem. I explained to him the situation that more investigation is necessary and that why shouldn't it be done there, where the facilities are more developed? He agreed to take the block with him.

**Postscript:** I didn't have any further contact with the patient for a few weeks. Eventually I asked around in his department and was given the surprising news that "it was something in the testicle-seminoma". After overcoming my shock, I found out that the patient had an undescended testicle and had undergone orchiopexy on the right side many years previously. He didn't share this information with me and maybe didn't think it was relevant. I'm also not sure if the surgeon was aware or if he bothered to examine the testicles. The hematopathologist at Hadassah- for the record Dr Gail Amir- was clever enough to think of the possibility and prove it with the appropriate immunohistochemical stains. Subsequent clinical evaluation found a right testicular lesion. He then underwent orchiectomy which showed a 2.5 cm mass (the modest size explaining why it was clinically inapparent). No retroperitoneal dissection was performed.

**Final Diagnosis:** Seminoma (cKIT, sall4 positive) developing in a cryptorchid testis s/p orchiopexy and presenting as a contralateral inguinal lymph node metastasis.

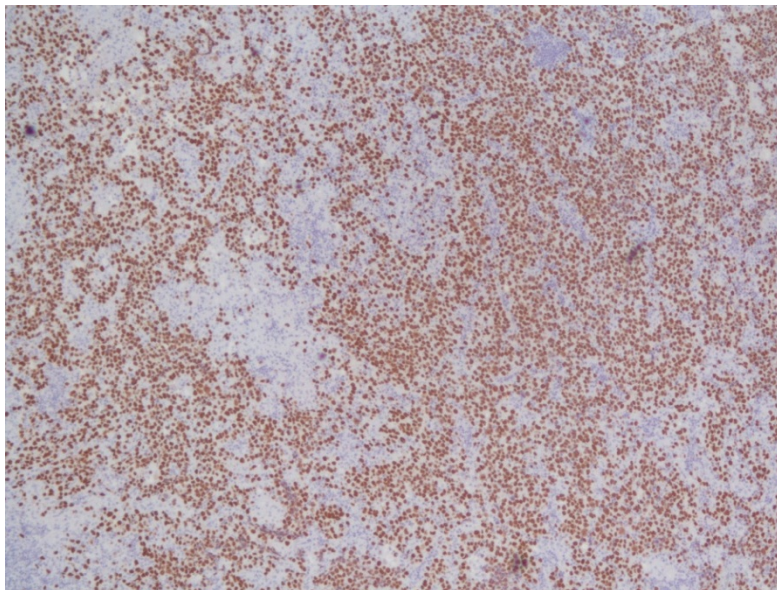
**Discussion:** Using journalistic parlance, the occurrence of seminoma in a previously undescended testicle is akin to "dog bites man"- not unusual. However the appearance of seminoma in an inguinal lymph node is very unusual- "man bites dog". Normal lymphatic drainage of the testis is to the para-aortic retroperitoneal lymph nodes and is established during embryological development. Thus any lymph node metastases from a testicular tumor are expected to be found there. However if in specific circumstances the normal lymphatic communications are disrupted by surgical interventions involving the testis, or the scrotal or inguinal regions, including, as in this case, previous orchiopexy, aberrant connections from the testis to the inguinal lymph nodes, which normally drain the skin of the penis, lower abdomen, perineum, and scrotum, are established. Thus the presentation of seminoma in this patient is explained by the previous surgery.

There are few articles in the literature discussing this phenomenon, most of them anecdotal (see Ismail et al, J Med Case Rep. 2010;4:378-381; Bantis et al Hell J Nucl Med 2012; 15(2) 150-152); Klein et al (J Urol. 1984;131(3):497-500) described 22 cases most of whom had a history of cryptorchidism and orchiopexy, or other surgical interventions including hernia repair, and hydrocele drainage. The most inclusive and recent study was published by Daugaard et al (BJU Int'l 2006 97(4): 274-276). Of 695 patients with stage I germ cell tumors of the testis 14 had inguinal metastases discovered in the course of follow up. 4 of the metastases were documented histologically to be in lymph nodes, while the others were claimed to "show more diffuse involvement of the tissue in the inguinal region". Only one patient had previous orchiectomy, this one with bilateral testicular cancer, the involved inguinal lesion being found during follow up for the second more recent tumor and ipsilateral to it. In all the other patients (including the four with documented lymph node metastases) there was no history of surgical intervention prior to development of the tumor to explain the unusual route of spread. One possibility suggested by some authors could be spread via the sperm cord (personally I'm not sure of the anatomic logic behind this). Involvement of inguinal nodes can also be seen in cases of testicular tumors with local advanced spread to scrotal wall, or any other site draining to the inguinal nodes, or when there is bulky involvement of the retroperitoneum, resulting from backflow secondary to obstruction of the normal lymphatic outflow routes.

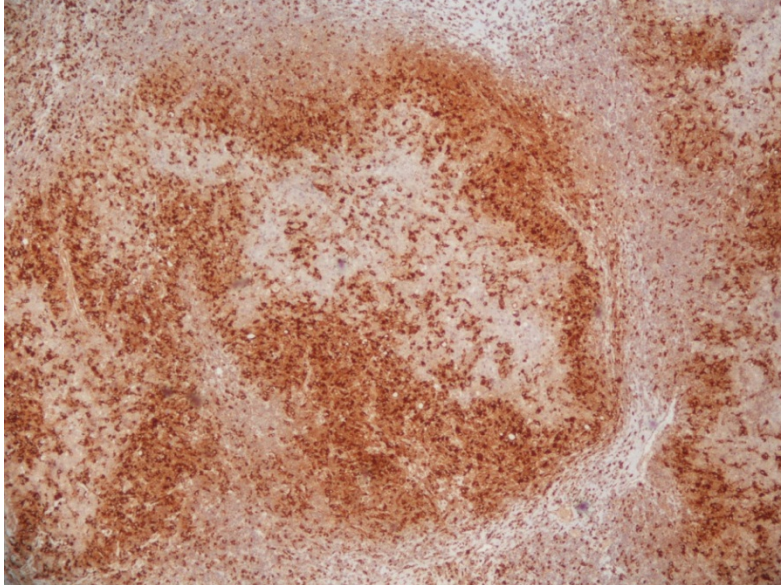
This is another example of difficulties caused by the presentation of a common tumor in an unexpected location. Prof. Rosai compares this to not recognizing a friend if you run into him, say, in Istanbul (assuming that neither you or the friend live or frequently visit that city). This happened to me in a case that I previously shared with this group, of a rectal GIST showing up in a prostate TRUS biopsy. I also had a case of a sizeable intra-abdominal mass composed of large malignant cells similar to this case which I also on first glance thought was lymphoma. Fortunately one of the slides I took included the epididymis which clarified the situation.

I sent this case to John Chan as an "unknown" after I knew the diagnosis. He made the following points in his reply: First, lymphoma cell nuclei are usually irregular and not round as in this case. Second, while granulomas can be found in lymphomas, they are small or discrete aggregates, while in seminoma, they form "irregular patches tightly intermingled with the tumor cells". In any case the presence of granulomas in a large cell malignancy should suggest the possibility of seminoma and prevent one from overlooking it.

It was only when I was about to complete this write-up that I read the pathology reports carefully and realized the discrepancy in laterality. I went back to the patient to make sure and he confirmed that the inguinal node was on the left side and the cryptorchid testis on the right. This can happen when the inguinal lymph node involvement is secondary to retroperitoneal obstruction, which was not the case here. Apparently the newly formed anastomotic lymphatic channels created following repair can hook up any which way they want to. Such a case was reported by Nishimoto et al (Urology1993;41 (3): 275-277) from Hiroshima Japan and my impression is that this is a unique case report. In any case Daugaard did not specify any discrepancy regarding the side of the involved lymph node for any of their cases.



Tumor cells show positive nuclear staining for SALL4



Aggregates of epithelioid histiocytes are positive for CD68





# AMR Seminar #64

## Case – 4

**Contributed by:** Gerald Berry

**Clinical history:** This nine-week old infant boy born at 38 weeks following an uneventful pregnancy presented to a local ER with a fever. His prenatal care included five ultrasounds that were reported to be normal. His early postnatal history was also uneventful and he was thriving. A chest x-ray showed a mass in the right hemithorax. He was hospitalized, given antibiotics and then a more extensive work-up was undertaken. CT and MRI showed a right middle lobe lesion. He required a right pneumonectomy as the hilar mass encroached on the upper lobe and appeared to involve both the middle and lower lobes. He did well postoperatively and radiologic evaluation of the abdomen, pelvis and brain was normal.

**Pathologic findings:** The lung was sectioned in a sagittal plane revealing a 3.5 cm circumscribed, unencapsulated white-tan hilar mass that enveloped the major bronchi without invasion of airway or vascular structures. Microscopically, the expansive neoplasm was composed of oval-to-spindled cells with hyperchromatic nuclei. The lesion surrounded the major hilar structures and was sharply delineated. Division figures were rare and cystic alterations were infrequent. Abnormal mitotic figures were not found. Immunohistochemical staining was negative for cytokeratin, desmin, CD34 and myogenin. FISH studies were negative for ALK rearrangements.

**Diagnosis:** Congenital peribronchial myofibroblastic tumor (CPMT)

**Comment:** I thought I would add to the pediatric collection of lung tumors (I presented two cases of pleuropulmonary blastoma – PPB Types 1 & 3 – in AMR Seminar #62). CPMT is a rare fibroblastic/myofibroblastic proliferation with <25 cases reported. It has been reported under a variety of names: bronchopulmonary fibrosarcoma, bronchopulmonary leiomyosarcoma, congenital mesenchymal malformation and hamartoma. First reported by McGinnis et al in 1993 CPMT is cured by complete surgical removal. The major diagnostic consideration is PPB. According to Dr. Ashley Hill, the distinction is based in large part on age. PPB at this age is purely cystic with a mild expansion of septa with a uniform population of primitive mesenchymal cells. Type II PPB can develop out of Type I PPB with multi-patterned sarcomatous transformation but at an average age of three years.

**Follow-up:** This child is now nine-months old and is thriving. Chest CT shows post-surgical changes with resultant shifting of thoracic contents.

### References:

McGinnis M, Jacobs G, el-Naggar A, Redline RW. Congenital peribronchial myofibroblastic tumor (so-called "congenital leiomyosarcoma"). A distinct neonatal lung lesion associated with noimmune hydrops fetalis. *Mod Pathol.* 1993 Jul;6(4):487-92.

Dishop MK, Kuruvilla S. Primary and metastatic lung tumors in the pediatric population: a review and 25-year experience at a large Children's hospital. *Arch Pathol Lab Med* 2008; 132:1079-1103.

Kim Y, Park H-Y, Cho J, et al. Congenital peribronchial myofibroblastic tumor: a case study and literature review. *Korean J Pathol* 2013; 47:172-176.



# AMR Seminar #64

## Case – 5

**Contributed by:** Thomas Colby

**Clinical History:** A 69-year-old man presented at age 67 with pain in the right hip and a radiologic lesion consistent with chondrosarcoma was noted. Biopsies showed grade 2/3 chondrosarcoma and some months later he underwent partial resection of the right femur at which time an 8 x 7 x 6 cm diameter chondrosarcoma was identified. Extensive histologic evaluation showed typical features of grade 2 chondrosarcoma. At that time imaging of the lung was negative. Eight months later, during re-staging, innumerable small (< 1.0 cm) pulmonary nodules concerning for metastases were noted. He ultimately came to wedge resection of the lung (the specimen submitted for review).

The patient also had a history of a spinal tumor in 2004 which was said to be “benign.” This was obtained and showed typical features of Schwannoma with appropriate immunostaining.

**Histology and Immunostaining:** Multiple lung nodules were resected and examined at frozen section. We weren't sure what was going on but with some confidence said we saw no evidence of chondrosarcoma. We wondered about metastatic malignant granular cell tumor. Among approximately ten nodules resected, all showed the same morphology as the slide submitted. There are multiple nodules of granular-appearing cells (but not quite right for granular cell tumor) with slight spindling, some nesting, and relatively prominent vascularity. Some of these are in a perivascular distribution consistent with lymphangitic spread.

We did not know what was going on and at that point decided we needed to review the spinal tumor which proved to be a Schwannoma. The material in the lung was negative for the following: pankeratin, SMA, S-100, CD68, SOX 10, myogenin, desmin, HMB-45, MART-1, MiTF, synaptophysin, GFAP, CD34, and CD31. No organisms were identified on GMS and fungal stains. Ki-67 showed positivity in 10-20% of the tumor cells.

**Denouement:** We then decided that we should educate ourselves and looked into the literature and found that chondrosarcoma may be associated with granular cells (see ref. below). In re-reviewing the prior resection specimen, a single microscopic focus of granular cell change was identified among multiple slides of the tumor. We finally decided that our confidence at frozen section (that this “could not be a chondrosarcoma”) was eroding and that we were dealing with an unusual example of metastatic chondrosarcoma with exclusively granular cell component.

Has anybody seen this before?

**Diagnosis:** Metastatic chondrosarcoma with exclusively granular cell features.

**Reference:** Cremonini A, et al. Well-differentiated chondrosarcoma of the humerus with prominent granular cell component: a hitherto unreported occurrence. *Int J Surg Pathol* 2006;14:147-54.



# AMR Seminar #64

## Case – 6

**Contributed by:** Goran Elmberger

**Clinical history:** A 66 year old previously healthy male noted increased flatulence and increased frequency of defecation. No pain or weight loss. One year previously had rectal bleeding with surgical treatment of varicose haemorrhoidal plexus. Rectal biopsy revealed adenoma and neuroendocrine carcinoma. MR with extramural tumor T3N1M0. PET positive. Preoperative radiation treatment with 5 Gy x 5 with tumor shrinking. Abdominoperineal resection of rectum with total mesorectal excision technique (TME).

**Gross findings:** A 20 mm sized partly polypoid tumor was detected 3 cm from anus.

**Microscopical findings:** At low power an adenoma with high-grade atypia is seen next to a small infiltrative adenocarcinoma NST, Immediately next to these tumor components a dominating large cell neuroendocrine carcinoma was seen. The neuroendocrine carcinoma infiltrates the inner half of lamina muscularis propria. Intravascular growth detected. Lymph node metastases detected in one lymph node (1/11). Radical excision. Tumor regression grade 0/1 (Dvorak). ypT2N1M0R0; ENETS; Stage III

**Special studies:** LCNEC stained immunohistochemically with CK5-/+, CK18+, Synaptophysin+, SV2+ and cdx2+. CK7, CK20, TTF1, CD56, CD57, Chromogranin A and NFP were all negative. Ki-67 50 %. p53+, p21-. Adenoma and adenocarcinoma revealed CK5-, CK7-, CK18+, CK20+, CEA+, cdx2+, Synaptophysin-, Chromogranin A-, CD56-, CD57- SV2-, TTF1-. p53+, p21-. p53 stain was intensely positive in adenoma, adenocarcinoma and NEC. Mutation analysis of TP53 gene proved the same mutation in adenoma, invasive adenocarcinoma LGNEC and in later occurring intestinal metastasis.

**Diagnosis:** Mixed adenoneuroendocrine carcinoma of the rectum (MANEC) with components of adenoma, adenocarcinoma & high grade neuroendocrine carcinoma, large cell type - a unique composite tumor with a common clonal TP53 mutation.

**Follow-up:** Received post-operative adjuvant chemotherapy. After 6 months a metastasis was resected in the intestine. Later developed liver metastases. DOD after 12 months.

**Discussion:** The concurrence of NEC admixed with adenocarcinoma and/or an epithelial neoplastic precursor lesion within the gastrointestinal tract is an unusual phenomenon that has been reported in the oesophagus, stomach, small intestine, gall bladder, appendix, colon and rectum. Morphologically, such lesions are usually classified into two subgroups: composite-type tumors, in which both components appear to be mixed haphazardly, and collision-type tumors, which are considered as double tumors with a "side by side" or "one upon another" pattern. According to such morphological classification, two hypotheses have arisen regarding the mechanism for the association of adenocarcinoma and NEC carcinoma. One is that both are derived from a common multipotential epithelial stem cell, the NEC carcinoma component resulting from differentiation from the adenocarcinoma to the NEC phenotype during tumor progression. The second hypothesis is that adenocarcinoma and NEC carcinoma arise from a multipotential epithelial stem cell and a primitive NEC, respectively, and that they exist next to each other coincidentally. To test which hypothesis is correct, it is essential to use both immunohistochemical and genetic studies. Collision tumors are thus believed to result from 2 separate but adjacent neoplasms (biclinal malignant), whereas composite tumors are thought to arise through a multidirectional differentiation of a single neoplasm.

Most bona fide MANECs of the large bowel consist of components of adenocarcinoma or squamous cell carcinoma (anal canal) mixed with high-grade NEC, which can be of either large or small cell type. Many high-grade NECs have minor exocrine components, and an origin in association with an adenomatous polyp is frequent.

**Differential diagnosis of mixed adeno-neuroendocrine tumors:**

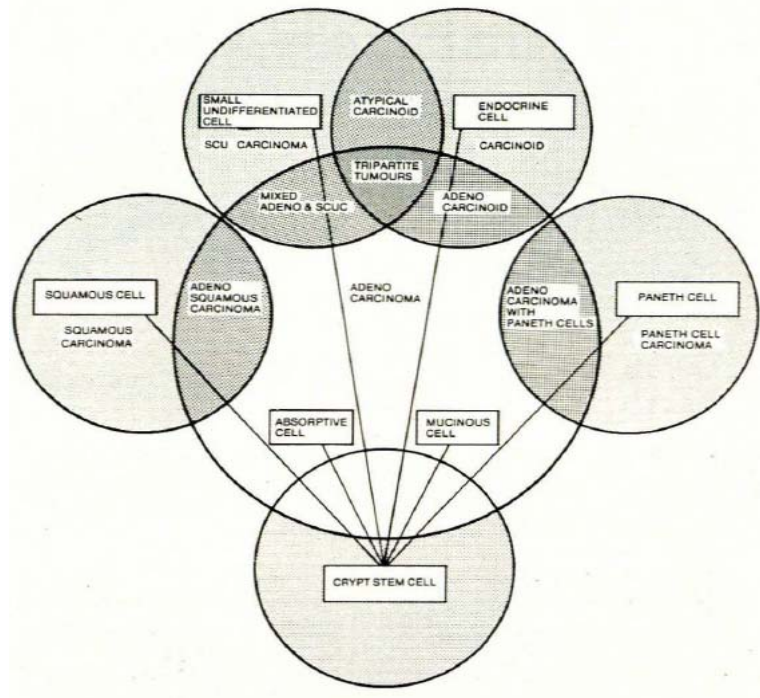
- Composite tumor when the two cell types are intermingled and clonally related
- True collision tumor with 2 elements in a side-by-side pattern with unrelated clones
- Amphicrine tumor when the neuroendocrine and exocrine features are present within the same cells
- Colorectal adenocarcinomas with neuroendocrine differentiation as detected by IHC are found in up to 41%.
- Metastases to primary CRC –metastasis to carcinoma phenomenon

**Staging of NEC and MANEC’s**

- TNM classification not settled
- European Neuroendocrine Tumor Society (ENETS) 2006
- SEER 2008
- AJCC 2010

**Evolution of MANEC classification**

According to Lewin (1987) 3 subtypes of “mixed” tumors could be recognized when more than 30% of the tumor bulk consisted of cells with NE differentiation.



**Fig. 5. A diagrammatic concept of multilinear differentiation within carcinomas arising from neoplastic stem cells.**

## **Molecular pathology**

Sometimes the different types of mixed tumors can be resolved by performing correlative immunohistochemical and molecular studies. Some potential markers that could be used for this purpose are:

- TP53 mutations
- MSI
- Beta-catenin
- KRAS/BRAF

## **Prognostic and predictive factors**

NECs of the large bowel are highly aggressive tumors with a 2 –year survival of 25 % and a 5-year survival of 13 %. At presentation 70 % of the patients already have metastases. However, MANECs are so rare that generalizations about their behaviour are not possible.



# AMR Seminar #64

## Case – 7

Contributed by: Giovanni Falconieri

**Clinical History:** The patient is a 75 year-old lady with past history of breast cancer (proven to be a low grade, encapsulated papillary carcinoma) with negative sentinel lymph node, recently evaluated for a growing, unilateral thyroid mass. FNA was just reported as consistent with follicular neoplasm. Hemithyroidectomy was carried out. Follow up was uneventful

The specimen is nearly replaced by a grey-white mass, 4.8 x 3.9 x 3.5 cm. Histologically, the tumor features a dominant follicular proliferation featuring small nests, often peripherally delimited by a delicate fibrous rim. Some artifactual peripheral clefting is present, suggesting pseudopapillary or convincing papillary architecture. In addition, there is smooth transition to a spindle cell proliferation featuring paucity of follicular structures: in this area the tumor is composed of fascicles of relatively monotonous, short and elongated fibroblast-like elements, admixed with scattered lymphocytes and plasma cells. Residual neoplastic follicles are focally recognized at the interface, suggesting that the 2 components are haphazardly blending. Mitoses may be noticed. In contrast to the follicular nests, these small spindle cells are negative for all epithelial markers, including thyroglobulin, TTF1, keratin cocktails. Instead, they are at least focally positive for CD34, CD99 and actins.

I found this case challenging. Basically, I thought that 2 lesions were present, i.e. a papillary carcinoma of thyroid with follicular architecture, and a malignant spindle cell proliferation. Yet I could not rule out a dedifferentiation occurring within a PTC.

I sent the case for an opinion to professor Sobrinho-Simoes for diagnostic confirmation and further evaluation at his end. He pursued molecular testing on paraffin tissue and concluded that *“no BRAF or N-RAS mutations were noticed in the hot spots of these genes in both PTC areas and spindle cell areas of the tumor. These findings were not helpful in the establishment of a clonal relationship between both PTC and spindle cell components. As we found strong and diffuse positivity for CD99 (MIC-2) together with focal CD34 expression in the spindle cell component favoring the possibility of a malignant solitary fibrous tumor of the thyroid associated to a follicular variant of PTC.”*

I and Manuel decided to circulate representative slides of this lesion and see whether any of the Club Members has ever come across something similar, or has better/alternative diagnostic opinions. I hope that the circulating sections (which have been obtained from 3 separate blocks) reflect the quality of this complex proliferation.



# AMR Seminar #64

## Case – 8

**Contributed by: Franco Fedeli**

(Case Originally From: Dr. Fabrizio Liberati (Rieti))

**Clinical History:** A 67 year old man presented with epigastric pain and digestive disorders. Gastroscopic examination showed no alterations, but colonoscopy highlighted a transverse colon substenosis ab estrinseco. Later, a CT scan revealed a mass at the junction of the body-tail of the pancreas, which was surgically removed. After surgery, the patient was treated with chemotherapy and radiotherapy, and he had a disease-free survival of two years; in the end, he developed recurrence and died.

**Macroscopic Findings:** A mass, 6,1x5,8 cm, with multilobated appearance, necrotic-hemorrhagic areas and firm, infiltrating peripancreatic fat and transverse colon, was found at the body-tail of the pancreas.

**Microscopic Findings:** Histologically, the tumor exhibited three different patterns: acinar formations, solid sheet, and squamoid corpuscles. Acinar and solid areas were cytologically similar and merged imperceptibly; cytoplasm had amphophilic appearance and nuclei presented moderate pleomorphism and increased nucleus-to-cytoplasm ratio with huge nucleoli. Mitotic rate was 3 per 10 high power fields (HPF) and foci of necrosis were present. Squamoid corpuscles were located in the center of the epithelial lobules and ranged from clusters of a few cells to larger areas; they were ill-defined and showed larger nuclei and more eosinophilic cytoplasm than solid and acinar areas. Ductal differentiation was inconspicuous.

**Immunohistochemical Findings:** Tumor cells were positive for trypsin and chymotrypsin; neuroendocrine differentiation was not seen.

**Diagnosis:** Pancreatoblastoma.

**Comments:** Pancreatoblastoma is a very uncommon neoplasm in adults. According to Klimstra et al. [1], several lines of evidence have demonstrated differentiation in the direction of all three major cell types of the adult pancreas: acinar, endocrine, and ductal. Acinar differentiation is the most consistently present and immunohistochemical staining for trypsin, chymotrypsin, or lipase was used to detect it. In addition, focal positivity for endocrine markers (chromogranin or synaptophysin) demonstrates the presence of an endocrine component, which usually is much less prominent than the acinar one. Finally, ductal differentiation can be demonstrated by mucin production or positivity for CEA, Ca19.9 and DUPAN-2. Therefore, the multidirectional differentiation is consistent with the "blastemal" nature of this tumor, even though the most primitive-appearing regions of pancreatoblastoma express more terminal differentiation than the classic blastematos elements in other blastomas. Moreover, in some instances the cellularity of the stroma was as if it suggested a neoplastic nature; however, there is a tendency for pancreatoblastoma in adults to contain less stroma. An interesting recent paper from Honda et al. [2] highlighted the presence of aberrant RASSF1A methylation and CTNNB1 mutation in a pancreatoblastoma, as in hepatoblastoma, and these biomarkers might be used to predict a poor outcome when a greater number of cases are examined.

### References:

- [1]: Klimstra DS, Wenig BM, Adair CF, Heffess CS. Pancreatoblastoma. A clinicopathologic study and review of the literature. *Am J Surg Pathol.* 1995 Dec;19(12):1371-89.
- [2]: Honda S, Okada T, Miyagi H, Minato M, Suzuki H, Taketomi A. Spontaneous rupture of an advanced pancreatoblastoma: aberrant RASSF1A methylation and CTNNB1 mutation as molecular genetic markers. *J Pediatr Surg.* 2013 Apr;48(4):e29-32. doi: 10.1016/j.jpedsurg.2013.02.038.



# AMR Seminar #64

## Case - 9

**Contributed by:** Jeronimo Forteza Vila

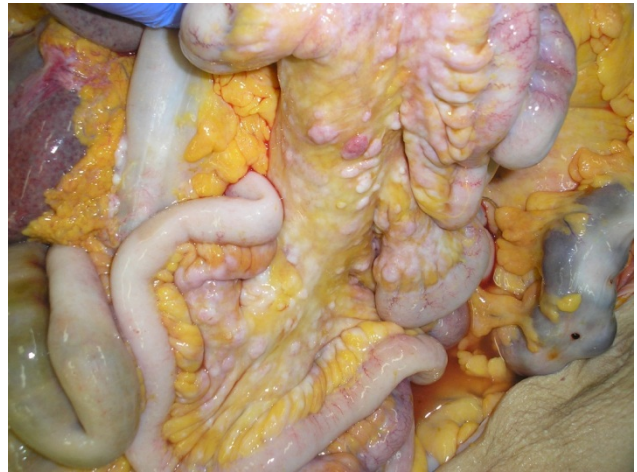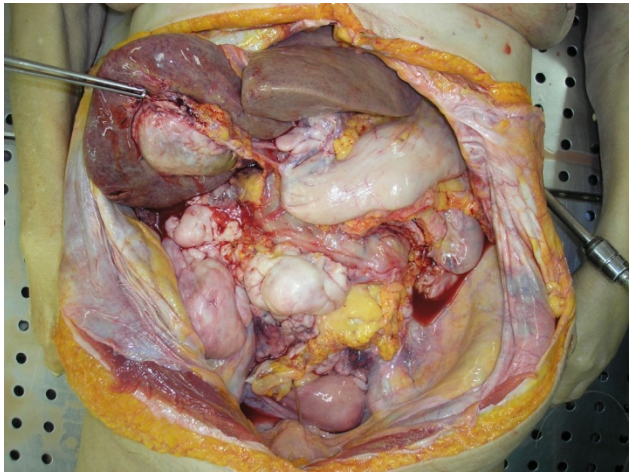
**Clinical history:** Female aged 66 with myelofibrosis and large splenomegaly. Several years after diagnosis, she presents with tumor involvement of left side of the abdomen with severe anemia and malaise. The patient dies and post-mortem examination is carried out.

**Hystologic diagnosis:** Malignant extramedullary myeloid tumor or myelosarcoma.

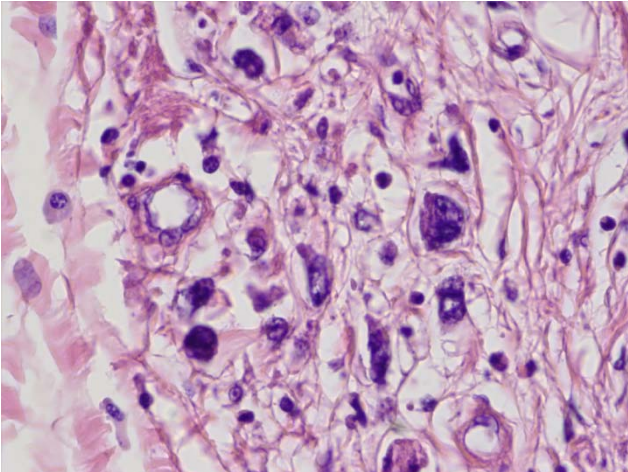
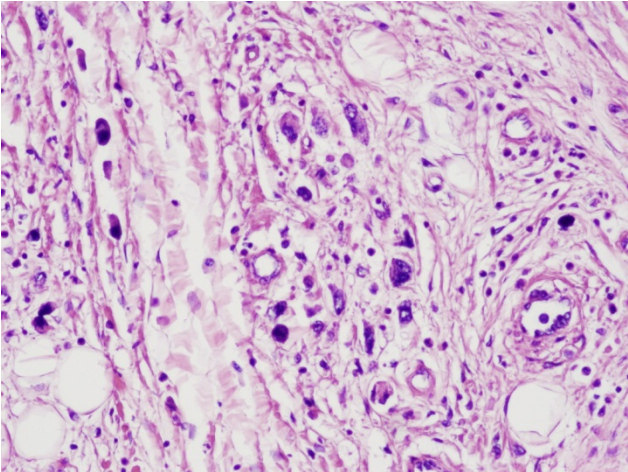
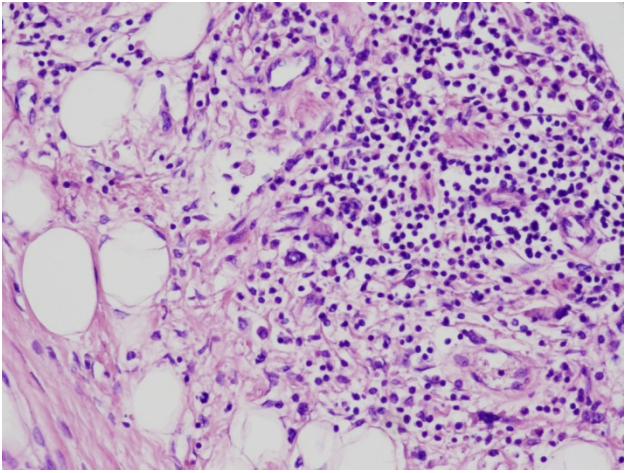
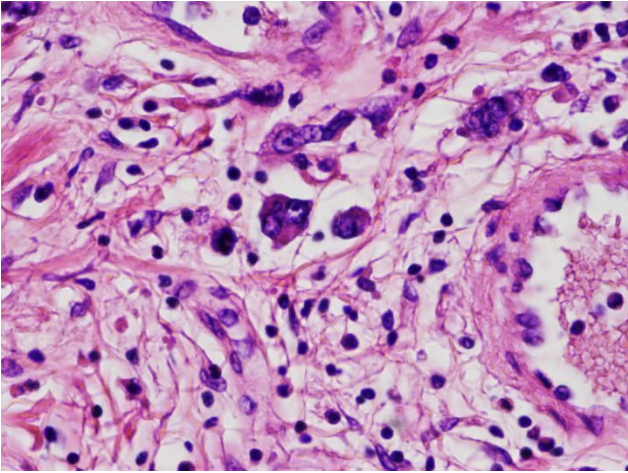
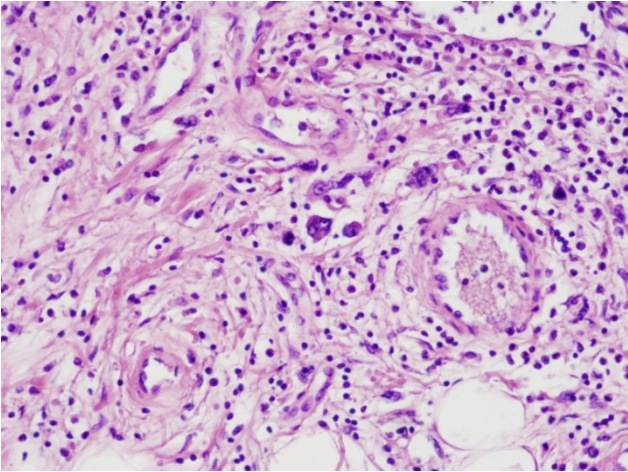
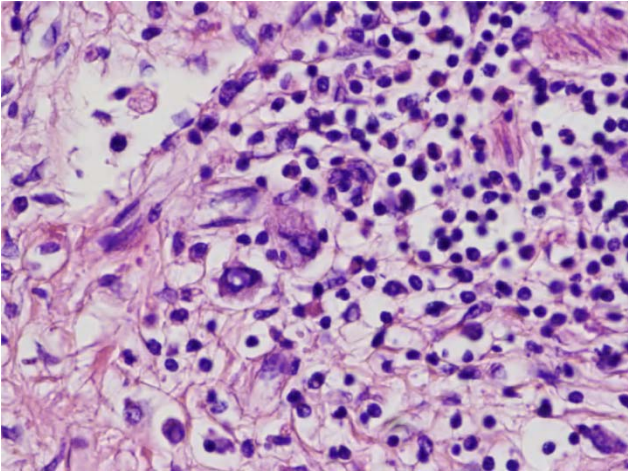
**Discussion:** The immunohistochemical study showed Factor VIII was positive in megakaryocytic cells and myeloperoxidase was positive in the surrounding cells. The FISH study showed RUNX1- RUNX1T1 t(8;21) (q21.3;q22) translocation and the BCR/ABL t(9;22) (q34;q11.2) translocation were negative.

**Comment:** This is a myelosarcoma in association with myelofibrosis that shows a macroscopic appearance mimicking "peritoneal carcinomatosis".

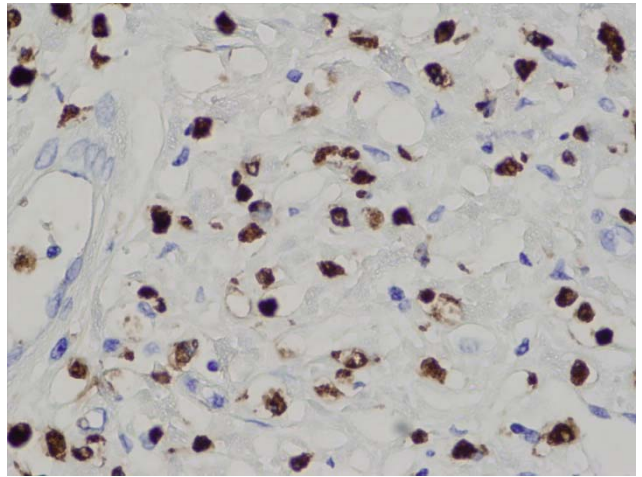
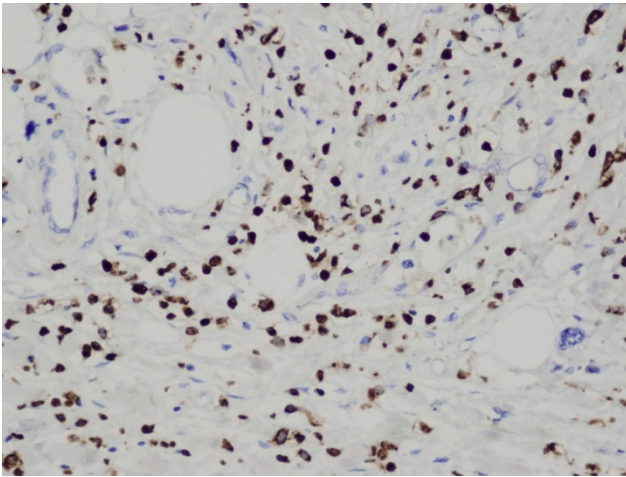
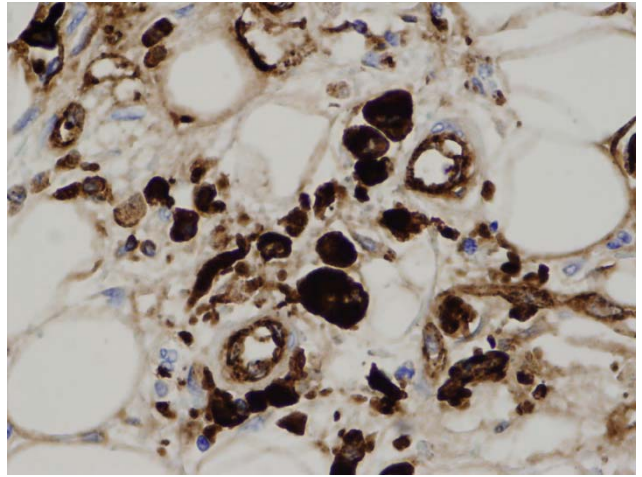
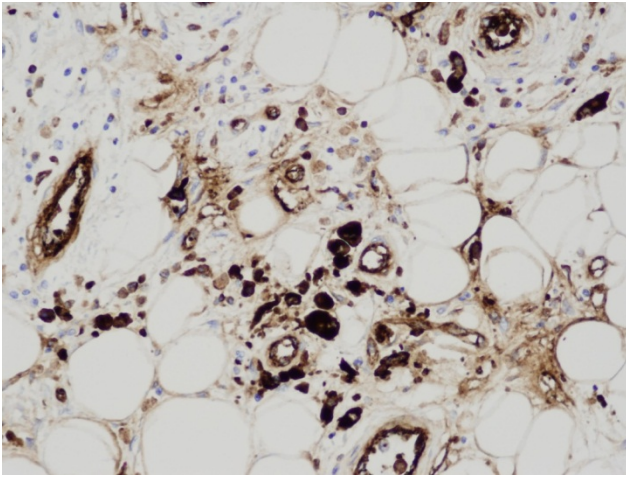
### MACRO



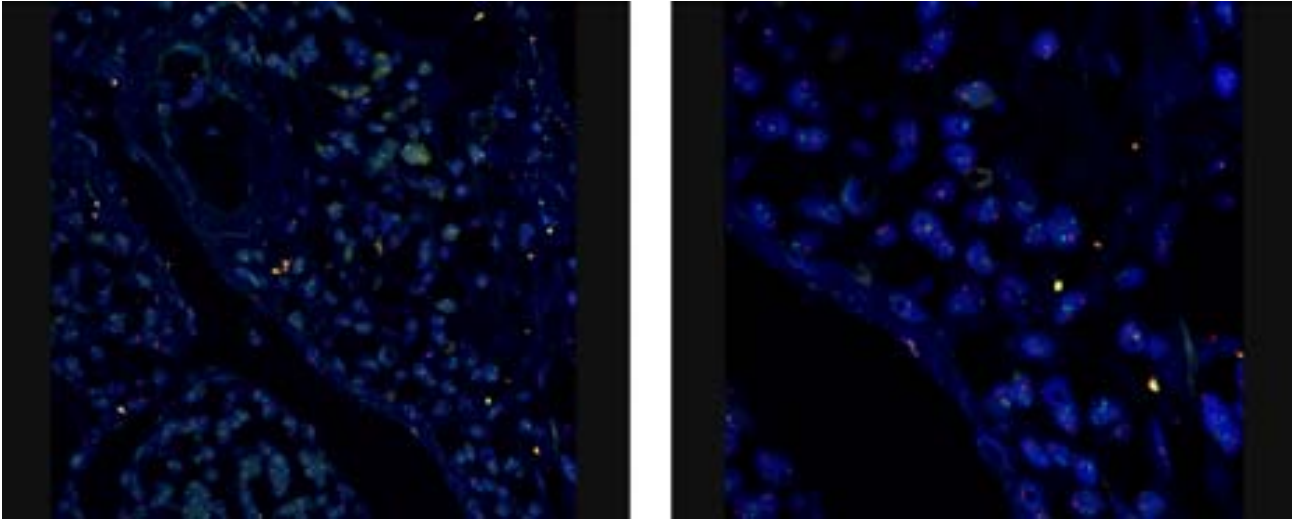
H&E



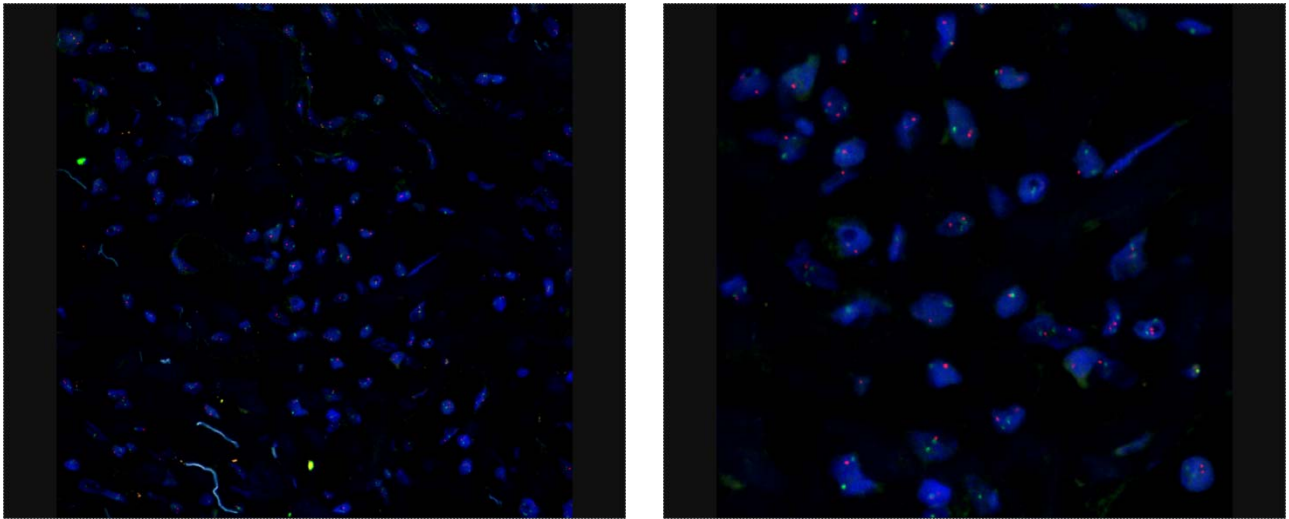
## FACTOR VIII



**FISH – Traslocacion BCR/ABL t(9;22) (q34;q11.2)**



**FISH – Traslocacion RUNX1-RUNX1T1 – t(8;21) (q21.3;q22)**





# AMR Seminar #64

## Case – 10

**Contributed by:** Masaharu Fukunaga (117-11-7-11-4)

**History:** A 77-year-old male presented with a left inguinal mass measuring 4cm. He noticed it a month ago. An excision was performed. The mass was located in the subfascia of the left Sartorius muscle and it looked like a lymph node or hematoma. The patient is well without evidence of disease at 18 months after surgery. The patient had a colectomy for colon cancer operated 4 years ago. He has had an uneventful clinical course.

**Macroscopic features:** An encapsulated yellowish brown solid mass measuring 4.0x3.0x2.5cm. Focal hemorrhage was seen.

**Immunohistochemical studies:** Endothelial cells were positive for CD31, CD34, factor 8 and WT-1 but negative for D2-40. Perivascular cells were diffusely positive for vimentin. HHF35, KP1 and WT-1 were focally positive. They were negative for desmin, alpha-smooth muscle actin, CD34 and S100.

**Diagnosis:** Reactive atypical fibrovascular proliferation (reactive angioendotheliomatosis?).

**Comments:** The case is histologically summarized as follows; an ill-defined lesion, a pseudolobular (multinodular) proliferation, vascular proliferation with fibrin deposits and a sinus-like arrangement, a perivascular atypical stromal (myofibroblast-like) cell proliferation (fasciitis-like), erythrocytic evacuation, active mitotic activity including atypical features, minimal inflammatory infiltrates and the presence of subsiding or granulation-like areas. Judging from the variable features, I think it is a reactive process rather than a neoplasm. May I call this case reactive angioendotheliomatosis? I would appreciate very much if I could hear from you about this unusual lesion.

**References:**

McMenamin ME, Fletcher CDM. Reactive angioendotheliomatosis: a study of 15 cases demonstrating a wide clinicopathologic spectrum. Am J Surg Pathol 2002;26:685-697.

# AMR Seminar #64

## Case – 11

**Contributed by: Thomas Krausz, M.D.**

**Clinical history:** 57-year-old male with history of asbestos exposure in the 1960s-70s presents with recurrent left sided pleural effusion. Cytology of pleural fluid showed malignant epithelioid cells. Subsequently he underwent a VATS with pleural biopsy and talc pleurodesis. Histology combined with immunohistochemistry with appropriate markers showed a predominantly epithelioid malignant mesothelioma with < 10% sarcomatoid component. Even though the sarcomatoid component was <10% on the biopsy, the pathologist suggested that based on literature data it is likely that a future resection specimen would contain larger amount of sarcomatoid component, therefore the tumor should be regarded as a biphasic mesothelioma. The patient received 4 cycles of cisplatin/pemetrexed chemotherapy a month before left pneumonectomy with pleurectomy and pericardial resection performed. The submitted histologic section is from the pleurectomy specimen.

### **Summary of the pathological findings:**

- Malignant mesothelioma, biphasic type (submitted slide is mainly epithelioid)
- 60% epithelioid, 40% sarcomatoid
- Tumor involved both parietal and visceral pleura, including fissure
- Tumor invaded into but not through diaphragm, lung parenchyma, mediastinal fat and pericardium
- Status post talc pleurodesis
- 10 lymph nodes, negative for malignancy
- Lung parenchyma without diagnostic abnormality
- 

**Diagnosis:** Biphasic malignant mesothelioma with peculiar, probably therapy-induced, hyalinizing micronodules

**Comment:** The main reason for submitting this case is the striking hyalinizing micronodules within the tumor which were not present in the pre-therapy VATS biopsy. I suspect that this peculiar histologic feature is the consequence of therapy, whether talc or cytotoxic drugs or both; of course I am not sure. On polarization, the talc crystals are not present within the hyalinizing nodules but in the foreign body granulomas. In some areas they are adjacent to the nodules but overall do not seem to be intimately related. I am wondering whether members have seen this feature before and how did they interpret it.

On a practical level, I feel that this hyalinization biologically is different than the de novo desmoplasia one sees in association with sarcomatoid/desmoplastic mesothelioma. On an observational level, in the nodules one can see that the epithelioid tumor cells become more spindly towards the center but, rightly or wrongly, I would interpret this as atrophy rather than real sarcomatoid transformation. Because of the striking rounded nodules I was considering whether they represent vascular invasion or are centered on blood vessels. I could not prove either of them with appropriate IHC stains. Interestingly the hyaline material is only focally and weakly refractile in polarized light in contrast to what would be seen in thick collagen or even in desmoplastic mesothelioma. Only very little basement membrane material was identified by laminin and collagen IV. I'm also reasonably sure that this material is not osteoid, nor is it amyloid.

There is scant literature on therapy induced histologic changes in mesothelioma; however, I could not find any description of this feature (Attanoos RL and Gibbs AR. The pathology associated with therapeutic procedures in malignant mesothelioma. *Histopathology*, 2004;45:393-397).



# AMR Seminar #64

## Case – 12

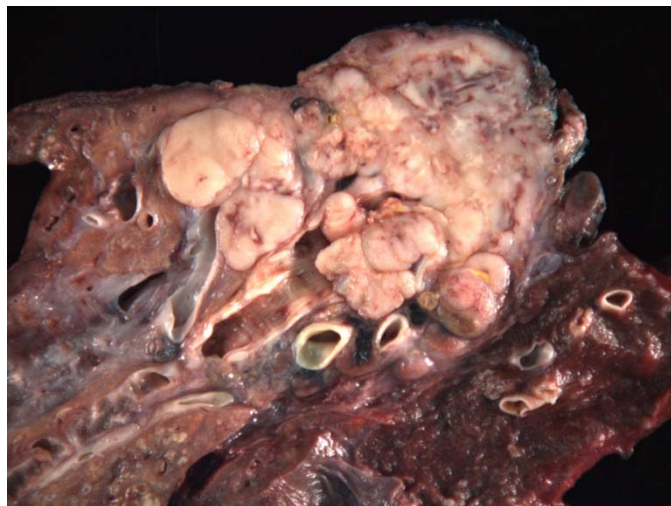
**Contributed by:** Alberto Marchevsky

**Clinical history:** 69 year old man with no history of malignancy presented with cough and other respiratory symptoms. Chest imaging studies showed a large mass involving the right mainstem bronchus. Work-up for metastatic disease was negative. He underwent a right pneumonectomy.

**Pathology findings:** large tumor measuring 8.0 cm in diameter involving the lobar bronchus and the middle and lower lobe bronchi. Five of 32 peribronchial lymph nodes showed metastatic tumor. Subcarinal lymph node was negative for tumor. Tumor cell showed cytoplasmic immunoreactivity for S100 and HBM-45 and nuclear immunoreactivity for Microphthalmia transcription factor. Immunostains for keratin AE1/AE3 and CAM 5.2 were negative. Molecular test for BRAF V600E point mutation was negative.

**Diagnosis:** Malignant melanoma of the lung; presumed lung primary in the absence of previous history of malignant melanoma and negative work-up for extrapulmonary lesions.

**Comments:** the lesion shows characteristic morphological and immunophenotypic features for a malignant melanoma. The problem is whether to consider this a primary lung lesion or not. Primary melanomas of the lung have been previously described in approximately 30 instances. It is often difficult to exclude the possibility of a prior skin, ocular or mucosal lesions that has been missed or has undergone local regression. Seitelman et al reported a patient successfully treated with surgery and reviewed the literature in 2011. They mention as criteria for a primary melanoma of the lung the presence of “dropping off” or “nesting” of melanoma cells beneath the bronchial epithelium, a feature that in my opinion is difficult to distinguish from the presence of any tumor attached to the bronchial epithelium and the absence of evidence for cutaneous, mucosal or ocular detectable lesions at the time of diagnosis.



**References:**

- Allen MS Jr, Drash EC. Primary melanoma of the lung. *Cancer* 1968;21:154.
- Dountsis A, Zisis C, Karagianni E, Dahabreh J. Primary malignant melanoma of the lung: A case report. *World J Oncol* 2003;1: 26.
- Seitelman E, Donenfeld P, Kay K, Takabe K, Andaz S, Fox S. Successful treatment of primary pulmonary melanoma. *J Thorac Dis* 2011, 3:207.



# AMR Seminar #64

## Case – 13

**Contributed by:** Thomas Mentzel

**Clinical History:** A 57-year-old female patient developed an elevated, nodular dermal lesion on her left heel. The referring pathologist asked for inclusion body fibromatosis.

**Pathological Findings:** A skin specimen with a hyperplastic, polypoid elevated epidermis is seen, and in the dermis a hypocellular, lobular, mesenchymal lesion is present. The lesion is composed of uniform, spindled fibroblasts set in a collagenous stroma with cleft-like spaces. In the periphery some spindled cells stained positively for alpha-smooth muscle actin and EMA, no expression of S-100, CD34, and desmin was noted. Numerous neutrophils arranged around vessels but also diffusely in the stroma are present, and are highlighted with MPO stainings

**Diagnosis:** Tumour-like erythema elevatum et diutinum.

**Comments:** The first clue for the correct diagnosis was found in a phone call with the clinician, that revealed that the patient had multiple dermal lesions on both feet and a history of blisters. Given that and the morphological features it is obvious that we are not dealing with a mesenchymal neoplasm but with a tumour-like stage of an inflammatory disorder. Erythema elevatum et diutinum is best regarded as a localised form of vasculitis with leucocytoclasia, may occur in any age group and is seen most frequently on the backs of the hands and feet, wrists, elbows, knees, ankles and toes. Interestingly, a number of associated disorders (i.e. cryoglobulinemia, gammopathy, multiple myeloma, leukaemia, polycythaemia rubra vera) have been recorded in erythema elevatum et diutinum. Early lesions show features of a leucocytoclastic vasculitis with fibrin deposition and a dense inflammatory infiltrate, whereas older lesions are characterized by the presence of granulation tissue, fibrous scarring and tumour-like fibroblastic proliferation. It is still unclear if erythema elevatum et diutinum and granuloma faciale are related disorders or distinct clinicopathological entities. Granuloma faciale may occur also in extrafacial location and is characterised as well as a progressive disease with different stages. However, eosinophils predominate in granuloma faciale and associated systemic disorders do not occur. Eosinophilic angiocentric fibrosis, a rare fibro-inflammatory disorder affecting the nasal cavity, and the glottic and subglottic region may represent the mucosal variant of granuloma faciale. Whereas cases of granuloma faciale shared features with IgG4-associated sclerosing diseases this was not the case with examples of erythema elevatum et diutinum.

### References:

Cesinaro AM, Lonardi S, Facchetti F. Granuloma faciale. A cutaneous lesion sharing features with IgG4-associated sclerosing diseases. *Am J Surg Pathol* 2013; 37: 66-73

Nigar E, Dhillon R, Carr E, Matin RN. Eosinophilic angiocentric fibrosis and extrafacial granuloma faciale. *Histopathology*. 2007; 51: 729-731

Ortonne N, Wechsler J, Bagot M, Grosshans E, Cribier B. Granuloma faciale: a clinicopathologic study of 66 patients. *J Am Acad Dermatol*. 2005; 53:1002-1009

Marcoval J, Moreno A, Peyr J. Granuloma faciale: a clinicopathological study of 11 cases. *J Am Acad Dermatol*. 2004; 51: 269-273

Inanir I, Alvur Y. Granuloma faciale with extrafacial lesions. *Br J Dermatol*. 2001; 145: 360-362

Cecchi R, Paoli S, Giomi A. Granuloma faciale with extrafacial lesions. *Eur J Dermatol*. 2002; 12: 438

Roustan G, Sánchez Yus E, Salas C, Simón A. Granuloma faciale with extrafacial lesions. *Dermatology*. 1999; 198: 79-82





# AMR Seminar #64

## Case – 14

**Contributed by: Elizabeth Montgomery (S13-34070)**

**Clinical History:** A 63 year old man with widely metastatic prostate carcinoma underwent cholecystectomy at the time of a colon resection for ischemic colitis. His gallbladder appeared grossly unremarkable and he had no signs and symptoms of cholecystitis or cholelithiasis. This case was sent in consultation as the initial pathologist was concerned about the epithelial changes.

**Diagnosis:** Taxane effect.

**Comment:** The histologic features are those associated with agents causing mitotic arrest, including colchicine and taxane medication. When we called the oncologist we learned that the patient had received docetaxel (taxotere) 3 days prior to the operation such that the changes are presumably an EFFECT rather than evidence of toxicity. There is mitotic arrest in the proliferative compartment of the gallbladder mucosa, manifest as ring mitoses and prominent apoptosis. The changes are histologically essentially the same for both colchicine TOXICITY and taxane EFFECT (or toxicity) so one must always find the clinical correlation since if the findings are colchicine-related the medication must be withdrawn. The findings are sometimes interpreted as columnar epithelial dysplasia if the mature surface of the epithelium is not noted and attention is paid to the dramatic changes in the proliferative compartment. Of interest is a patient is taking therapeutic doses of colchicine and has a neoplasm or polyp biopsied, the epithelial changes can be very unusual.

### References:

Daniels JA, Gibson MK, Xu L, Sun S, Canto MI, Heath E, Wang J, Brock M, Montgomery E. Gastrointestinal tract epithelial changes associated with taxanes: marker of drug toxicity versus effect. *Am J Surg Pathol.* 2008 Mar;32(3):473-7.

Iacobuzio-Donahue CA, Lee EL, Abraham SC, Yardley JH, Wu TT. Colchicine toxicity: distinct morphologic findings in gastrointestinal biopsies. *Am J Surg Pathol.* 2001 Aug;25(8):1067-73.

Torbenson M, Montgomery EA, Iacobuzio-Donahue C, Yardley JH, Wu TT, Abraham SC. Colchicine effect in a colonic hyperplastic polyp. A lesion mimicking serrated adenoma. *Arch Pathol Lab Med.* 2002 May;126(5):615-7.



# AMR Seminar #64

## Case – 15

**Contributed by:** Santiago Ramon y Cajal

**Clinical History:** Man of 33 years with a tumor in a rib of 8x8x3.7 cm.

**Pathological findings:** It presents an irregular cut surface with areas of chondroid appearance, whitish fibrous areas and others of hemorrhagic appearance.

At microcopy, the tumor is heterogeneous, with various components including tumor cells with an epithelioid appearance, broad cytoplasm, sometimes clear and vesicular nucleus with prominent nucleoli. In areas, suggests atypical low-grade chondrosarcoma and chondrosarcoma. Also there are areas with fibrocartilage tissue and bone formation and presence of amorphous eosinophilic suggestive of osteoid. Moreover, presents hemorrhagic areas in the center of the lesion, suggestive of secondary aneurysmal bone cyst. Immunohistochemically, the tumor cells are positive for S-100 protein, cytoplasmic p16 and negative for p53, CD99 and cytokeratin. The Ki67 proliferative index is 1%.

**Diagnosis:** Clear cell chondrosarcoma.

**Comments:** Clear cell chondrosarcoma is a rare chondroid neoplasm, representing about 2% of all chondrosarcomas. They are of low-grade malignancy with tendency to local recurrence and rarely metastasize. The main differential diagnosis is with chondroblastic osteosarcoma. The presence of clear cells, the low proliferative index and negativity for p53 would support the diagnosis of clear cell chondrosarcoma.



# AMR Seminar #64

## Case – 16

**Contributed by:** Brian Rubin

**Clinical History:** 43 year old woman with menorrhagia.

**Macroscopic features:** 161 gram uterus without adnexa. The serosa had adhesions and there was a 1.0 cm endometrial polyp but the specimen was otherwise unremarkable. The myometrium was described as 2.5 cm in greatest dimension and coarsely trabeculated.

**Histological and immunohistochemical features:** Distributed diffusely throughout the myometrium and even up into the deep endometrium in every single section examined histologically are irregularly shaped nodules of epithelioid cells arranged in nested and pseudoglandular architectural patterns. The stroma surrounding these groups of cells is slightly edematous. The tumor cells are monotonous with finely stippled to vesicular chromatin and single inconspicuous nucleoli. There is an absence of cytological pleomorphism and there is no mitotic activity or necrosis. The groups of tumor cells do not appear to be within blood or lymphatic vessels but the distribution suggests vascular spread diffusely throughout the myometrium. The intervening myometrium and the endometrium are unremarkable. By immunohistochemistry, the tumor cells are uniformly and strongly positive for smooth muscle actin, desmin, ER and PR, focally positive for H-caldesmon, and negative for cytokeratin AE1/AE3.

**Diagnosis:** Multiple plexiform tumorlets of the uterus.

**Comments:** This case is unique in my experience. I never saw anything like it before but I found mention of similar cases in a few papers and text books. Multiple plexiform tumorlets are thought to be benign variants of epithelioid leiomyomas of the uterus. Apparently, this was first described by Kaminski and Tavassoli<sup>1</sup> in a series of plexiform tumorlets with four of fifteen of their cases having multiple tumorlets as compared to single tumorlets. Their cases appear to be similar to the case I submitted to this slide club. The behavior of these lesions appears to be benign. It seems to me that the main differential diagnosis based on histology would be with metastatic carcinoma (e.g. breast carcinoma) although I'm sure there are unusual uterine tumors that also overlap. Obviously, immunohistochemistry is helpful in distinguishing multiple plexiform tumorlets from metastatic carcinoma.

**Reference:** Kaminski PF, Tavassoli FA. Plexiform tumorlet: a clinical and pathologic study of 15 cases with ultrastructural observations. *Int J Gynecol Pathol* 1984;3:124-134.



# AMR Seminar #64

## Case – 17

**Contributed by: Dominic Spagnolo, Western Australia**

(Accession Q13B4337P). Case received in consultation courtesy of my colleague Dr B Latham.

**Case history:** 44 year old male who had a parapharyngeal lymph node excised in 2010 and reported elsewhere. This was originally felt to be suspicious for non-Hodgkin lymphoma (?marginal zone), but no B-clonality was demonstrated by flow cytometry or on immunoglobulin gene rearrangement studies. A proliferation of spindle cells was noted within the node, at the time thought to be myofibroblastic in nature. The patient was followed with serial CT scans. Over the last 6 months an enlarging lymph node has developed in the same right parapharyngeal region, and was resected.

**Pathologic findings:** The findings are identical in the 2010 and 2013 specimens. Sections from the 2010 biopsy have been circulated from 2 different blocks. There is a follicular dendritic cell sarcoma which has arisen in a background of hyaline-vascular Castleman disease (the latter features better seen in other blocks), and also containing multifocal collections of immature thymic T cells (lymphoblasts). There is definitely no ectopic thymic tissue present to account for this coincidental infiltrate of immature T cells (complete lack of keratin positivity in many blocks of tissue).

The FDC sarcoma has a distinctly nodular and B-cell rich architecture in many areas (perhaps leading to the original consideration for a lymphoma with a nodular pattern), even more pronounced in the recent recurrence. The process is often centered on residual lymphoid follicles having markedly expanded mantle zones some of which contain residual atretic, or focally, more hyperplastic germinal centers. From these nodules, growth becomes more confluent and the spindle cells infiltrate the internodular regions in broad sweeping fascicles and perifollicular swirls. In some of the preserved atretic follicles may be found dysplastic FDCs. That the process is folliculocentric (?in-situ) at least in part is confirmed on double immunostains which show clearly that the nodular areas are composed of IgM+ IgD+ TCL1+ mantle zone B-lymphocytes, with or without central, variably atretic germinal centers containing BCL6+ lymphocytes. The FDC cells are strongly and diffusely CD21/CD35-positive (image 1), express vimentin strongly and podoplanin more weakly. They are EBER and HHV-8 negative.

The 2013 recurrence (not submitted) shows an even more obvious nodular, or folliculocentric growth, though everywhere may be found frankly internodular invasion by the sarcoma.

There are no overtly high grade histological features. For the most part the spindly cells are bland or show only mild nuclear pleomorphism, though there are microscopic foci showing greater pleomorphism, including in the recurrence. But mitotic activity is very low in both biopsies, even in the areas showing greater pleomorphism (typically <1 mitosis/hpf) and there is no coagulative necrosis. The proliferation index is very variable, ranging from <5% to about 40% focally.

That hyaline vascular CD underpins this FDC sarcoma is better seen in other blocks. Features include the presence of residual atretic follicles showing FDC predominance, with or without dysplastic nuclear features, marked expansion of mantle zones, "twinning" of germinal centers within the confines of a single expanded mantle zone, and interfollicular sclerosis. The classical "lollipop" follicles of CD are few. Additionally, prominent multifocal aggregates, and also more dispersed, plasmacytoid dendritic cells (CD303+, CD2AP+) are present, which is very typical in CD (images 2,3).

The last interesting finding is the presence of immature T-lymphoblasts seen as geographic clusters typically nestled between nodules and fascicles of the FDC cells, but also in places loosely peppered among the FDCs. These cells have quite dense nuclear chromatin and hence stand out from the other stromal T cells which are present. They lack atypia and are not particularly mitotically active though their proliferation rate is brisk based on MIB-1 staining (see digital image), and there is a subtle starry-sky background. These cells have the immunophenotype of immature thymic T cells (TdT+, CD1a+, CD2+, CD3+, CD4+, CD8+, CD5+, CD7+) (images 4,5). Molecular studies performed on this node failed to show any evidence of monoclonal TCR beta or TCR gamma gene rearrangements. Similarly, only polyclonal rearrangements of the IgH and kappa genes have been found. Interestingly, increased numbers of dispersed TdT+ cells are also present in some smaller nodes which accompanied the 2010 specimen, though these lack the FDC sarcoma.

**DIAGNOSIS:** Follicular dendritic cell sarcoma, recurrent, arising in hyaline-vascular Castleman disease and containing an infiltrate of immature thymic T cells.



**DISCUSSION:** This is an extraordinary case of a FDC sarcoma, now recurrent, arising in the context of hyaline-vascular CD and containing immature thymic T cells. The latter have been described in this setting before, though uncommonly they may occur in pure FDC sarcoma, and have also been described in lymph nodes in the head and neck area. In a recent study by Ohgami et al (ref. 2) TdT+ve T-lymphoblastic populations were found with high frequency in cases of Castleman disease, in CD associated with FDC tumors and also in angioimmunoblastic T-cell lymphoma (much more frequently than in peripheral T-cell lymphoma nos, and other T/B lymphomas). Why they occur is not known, and theories include altered cytokine homeostasis, immune dysregulation, or release of immature thymocytes and homing to peripheral organs for reasons unknown. In no case has there been evidence that they arise in ectopic thymic tissue. Clearly there is always the concern that they represent a coincidental T-lymphoblastic lymphoma, but the cells lack atypia, they are usually multifocal in distribution rather than forming mass lesions, they have not required treatment and in no case has lymphoma developed on follow-up. The absence of T-cell monoclonality is a reassuring finding. There have even been isolated reports of indolent T-lymphoblastic lymphoma in the past, which may very well represent the same phenomenon.

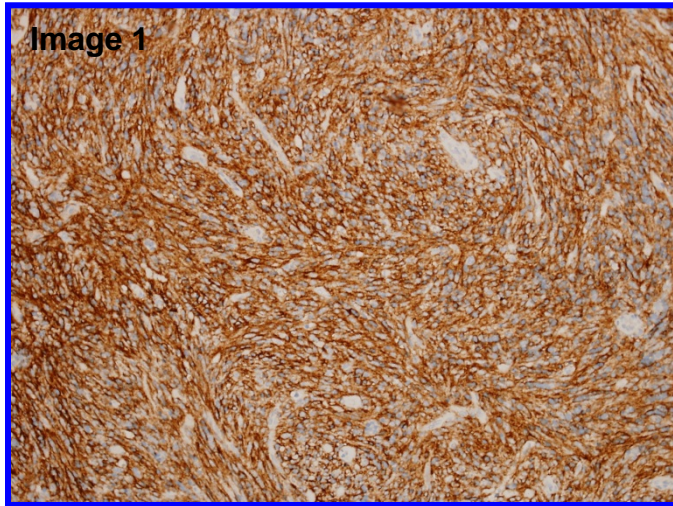
While the FDC sarcoma has, at least focally, a distinctly folliculocentric and B-cell-rich pattern, cytologically it is different from the cases reported recently by Lorenzi et al (see reference, below). Prior to seeing this case, I had received another similar case with striking multifocal "organoid" FDC proliferation (not sarcoma) occurring in hyaline-vascular Castleman disease in a patient with a history strongly suggestive of a familial predisposition to CD (Leslie C et al, below).

FDC sarcomas are typically low grade sarcomas, but they have a high local recurrence rate (40 - 50%) with a protracted clinical course. Metastases may develop in up to a quarter, typically after local recurrences. Factors that may indicate a more aggressive behavior include high grade cytological features, high mitotic index, size >6 cms and coagulative necrosis – these features are essentially absent in this case submitted, including in the recurrence.

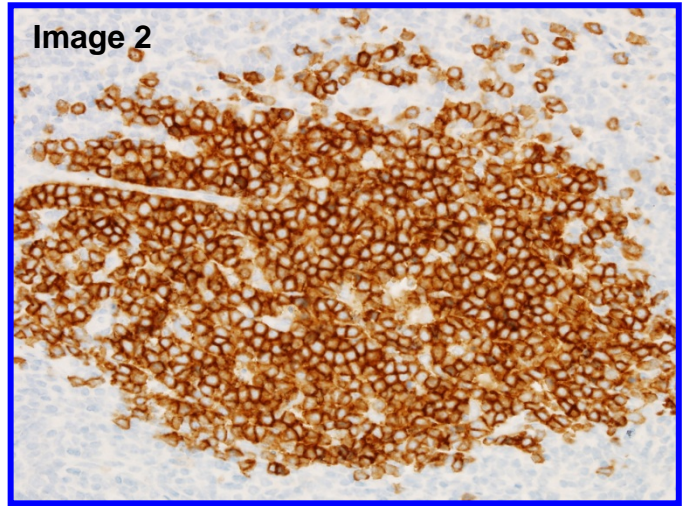
#### **References:**

1. Folliculocentric B-cell-rich follicular dendritic cell sarcoma: a hitherto unreported morphological variant mimicking lymphoproliferative disorders. *Hum Pathol* 2012; 43:209-215. Lorenzi L, et al.
2. TdT+ T-lymphoblastic populations are increased in Castleman disease, in Castleman disease in association with follicular dendritic cell tumors, and in angioimmunoblastic T-cell lymphoma. *Am J Surg Pathol* 2012; 36:1619-1628. Ohgami RS, et al.
3. Follicular dendritic cell sarcoma with immature T-cell proliferation. *Hum Pathol* 2010; 41:129-133. Kim WY, et al.
4. A follicular dendritic cell sarcoma of the mediastinum with immature T cells and association with myasthenia gravis. *Am J Surg Pathol* 2010; 34:742-745. Hartert M, et al.
5. Development of follicular dendritic cell sarcoma in hyaline-vascular Castleman's disease of the nasopharynx: tracing its evolution by sequential biopsies. *Histopathol* 2001; 38:510-518. Chan ACL, et al.
6. B-cell-rich nodular variant of follicular dendritic cell (FDC) sarcoma: a neoplasm with intriguing histologic features. *Mod Pathol* 1999; 12(1):134A. Chan JKC, et al.
7. T-lymphoblastic proliferation and florid multifocal follicular dendritic cell proliferation occurring hyaline-vascular Castleman disease in a patient with a possible familial predisposition. Leslie C, et al.

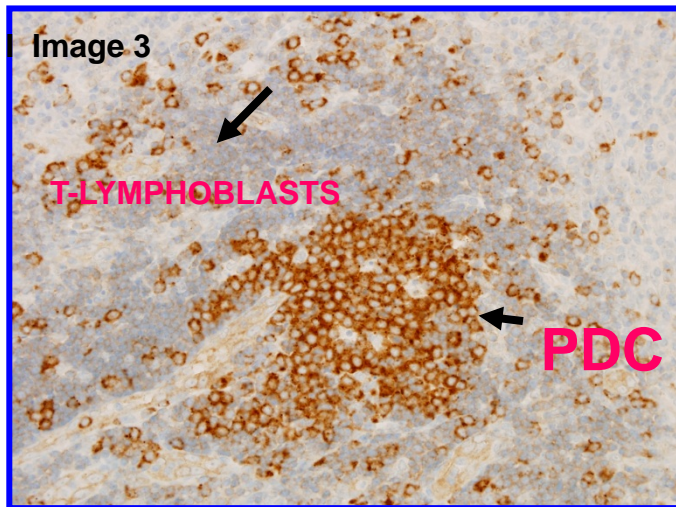
## CD21/CD35



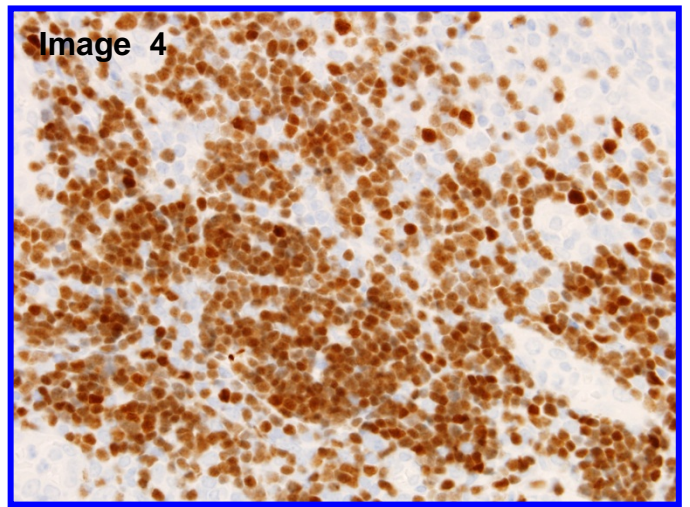
## CD303



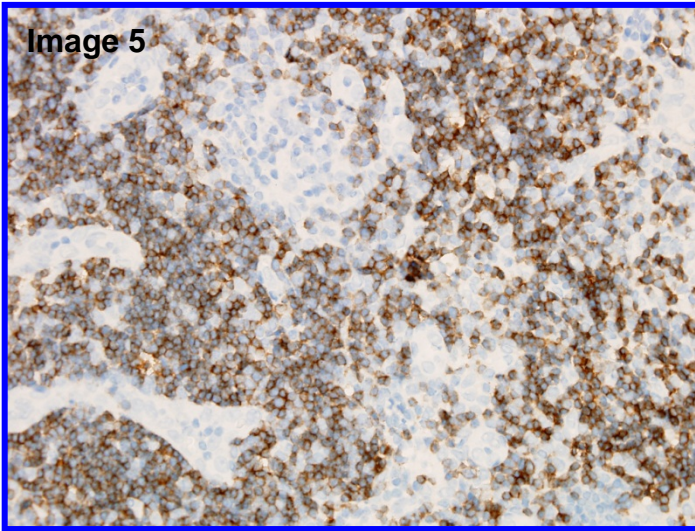
## CD2AP



## TDT



# CD1a





# AMR Seminar #64

## Case – 18

**Contributed by:** Paul Wakley, Jr.

**Clinical history:** A 63 y/o man presented with back pain, constipation, and 40 lb. weight loss over 4 months. A 19-cm. mass was found in his mesentery, and a 2<sup>nd</sup> mass in the pelvic retroperitoneum. No imaging was available. A subtotal resection performed at an outside hospital was interpreted as anaplastic neoplasm with renal cell carcinoma, metastatic non-renal clear cell carcinoma, and clear cell variant of mesothelioma listed as the main diagnostic possibilities. After 2 cycles of chemotherapy the patient was admitted to our hospital for re-resection of the mass and possible IORT.

**Pathology:** The specimen consisted of a 171 gram piece of yellow lobulated fatty tissue measuring 14.0 x 6.5 x 4.0 cm. Positive immunostaining results: cytokeratin AE1/3, 5-10% cells; CK 5/6, 25-30%; calretinin, 25-30%; CD10, 70-80%; and CK 7, < 5% of cells.

**Diagnosis:** Pleomorphic liposarcoma, epithelioid variant.

**Comment:** Nothing fancy here. The entire neoplasm looked pretty much like your slide – this was not merely focal epithelioid change. I realize an example of this neoplasm was presented by Dr. Folpe in seminar #34, however I thought it was just such a picturesque example of the entity that was initially recognized by Markku and Dr. Enzinger that club members would not mind seeing another case. I showed this case as an unknown at an evening seminar some years ago, and none of the panelists made the correct diagnosis. Adrenal carcinoma seemed to be the most popular diagnosis made by the panel, and you can understand why. To make this diagnosis according to Gebhard et al., and I quote “Actually, the main problem is to think of this diagnostic possibility and then to go hunting for lipoblasts.”

**Selected References:**

- 1.) Miettinen M, Enzinger FM. Epithelioid variant of pleomorphic liposarcoma: a study of 12 cases of a distinctive variant of high-grade liposarcoma. *Mod Pathol* 1999; 12:722-28.
- 2.) Fukunaga M, Nomura K. Epithelioid variant of pleomorphic liposarcoma: report of a case. *Path Res Pract* 2004; 200:545-49.
- 3.) Gebhard S, Coindre J-M, Michels J-J, et al. *Am J Surg Pathol* 2002;26:601-16.