

Hearing Loss in Minor Head Injury

Lingamdenne Paul Emerson
*Christian Medical College, Vellore
India*

1. Introduction

Hearing loss is a common problem encountered in ENT practice. Recognition of hearing loss as a problem by the patient usually occurs when speech frequencies are affected or when there is a sudden hearing loss. Hearing loss following head trauma or head injury is a major medical problem in adults (Bergemalm P-O&Borg.E. 2001) as well as children (Hough JVD &Stuart WD, 1968). The loss may go unnoticed when the speech frequencies are not affected. Sensorineural hearing loss at high frequencies is a frequent finding associated with head injuries (H.Alexander Arts). Hearing impairment can be due to central or peripheral causes, middle ear or cochlea being the most common site of peripheral injury. The most pronounced injury is fracture of temporal bone (Dahiya.R &Keller JD, 1999). In both clinical and animal experimental studies it has been shown that there are various sites of pathology ranging from hair cell damage and degeneration of the organ of corti, ischemia of the 8th nerve to damage of central auditory pathways (due to compromise of blood supply to the inner ear) either partly or totally. In most cases hearing impairment dissipates during subsequent post traumatic period, but some times it may persist or progress.

The causes of progression of hearing loss are not well known. Several explanations have been proposed such as development of perilymphatic fistula, secondary degenerative changes in cochlea following inner ear concussion possibly due to consequences of pre-existing autoimmune disease (or trauma itself may initiate such a reaction towards specific inner ear proteins). Progression of hearing loss can be attributed to the synergistic effects between trauma, noise exposure, medication and meningitis.

In developing countries roads are used not only by modern cars and buses, along with locally developed vehicles for public transport (three-wheeled scooter taxis, auto rickshaw's), scooters and motorcycles, bicycles, but also by rickshaws, and animal or human drawn carts that has resulted in disproportionate increase in road traffic accidents compared to developed countries. Minor head injuries (WHO 2004) constitute a major portion of all accidents. Evaluation of these patients revealed presence of hearing loss in the high frequency range. Hence auditory assessment is needed in this group of patients.

Evaluation of hearing loss in patients who sustain minor head injury has not been done in the Indian subcontinent. Therefore, this prospective study was done to evaluate the incidence of hearing loss and estimate its progression or regression by serial assessment over a period of six months

2. Classification of head injury

Hearing loss is a well known entity following head injury. The degree of hearing loss may vary depending on the severity of the head injury. The severity of Head injury is measured clinically using the Glasgow coma scale scoring system (G.C.S). The Glasgow Coma Scale was first published by Teasdale and Jennett in 1974. Several years later it was modified by Jennett and Teasdale and by Rimel et al (Rimel RW et al 1981, 1982) .This scoring system provides the best measure of severity of head injury. The score is the sum of the scale's three measures of eye opening, best motor and verbal responses. This ranges from a score of 3 for a patient with no motor, verbal response or eye opening to painful stimuli, to 15 for a patient who is oriented, follows commands, and has spontaneous eye opening. Patients, who do not follow commands, speak or open their eyes, with a score of 8 or less, are by definition in coma. Head injury is defined as mild when the GCS score is either 13 or 14–15, moderate by a score of 9–12 or 13, and severe by a score of 3–8. The GCS score on admission, and its prognostic usefulness, are easily confounded by other factors particularly substance misuse, but sequential monitoring after admission plays a crucial role in detecting early deterioration and in its management.

Culotta (Culotta VP et al, 1996) following a retrospective study found that patients with a GCS score of 13–15, represent a heterogeneous group with statistically significant different head tomography abnormalities. On the basis of findings they suggested separating patients with GCS score 13–14 into a different category from patients with a GCS score of 15, thus effectively redefining minor head injury. These findings were confirmed by a similar study by Gomez (Gomez PA,et al1996). Hsiang , on the basis of a cohort study of 1360 patients with GCS score of 13–15 suggested that this group of patients could also be divided into two subgroups, mild head injury and high risk mild head injury(Hsiang JNK et al,1997). Mild head injury is defined as GCS 15 without radiographic abnormalities, high risk mild head injury being defined as GCS 13–14, or a GCS 15 with acute radiographic abnormalities. More recently Swann and Teasdale recognizing the limitation of the GCS with regard to minor head injury have suggested another sub classification. Mild head injury is defined as GCS 13–14. Minor head injury is defined as GCS score of 15. The authors recognized in their monograph that this is a somewhat arbitrary definition. However in Clinical practice GCS is used in evaluation of Head injury (Swan LJ,Teasdale Gm 1999)

Glasgow coma scale and score (Table-1). Glasgow coma score: (E+M+V) = 3–15.

EYE OPENING	BEST MOTOR RESPONSE	VERBAL RESPONSE
Spontaneous - 4	Obeys commands - 6	Oriented - 5
To speech - 3	Localizes to pain - 5	Confused, Disoriented-4
To pain - 2	Withdraws (Flexion) - 4	Inappropriate words - 3
None - 1	Abnormal flexion -3	Incomprehensible sounds -2
	Abnormalextension - 2	No verbal response -1
	No motor response - 1	

Table 1. Glasgow coma score

In India, in the year 2000, official statistics revealed that 80,118 persons died and 3, 42,200 were injured in road traffic accidents . However this is an underestimate, as not all accidents are reported to the police. A study done in Haryana (India) recorded all traffic-related

injuries and deaths through bi-weekly home visits to all households in 9 villages for a year. This study showed that the ratio between critical, serious and minor injuries was 1:29:69. (Varghese .M .Mohan.D 2003).

2.1 Definition of a mild head injury

A mild head injury can be defined as an injury caused by blunt trauma and/ or sudden acceleration / deceleration which produces a period of unconsciousness for 20 minutes or less, a Glasgow coma scale score of 13-15, no focal neurological deficit, no intracranial complications and computed tomographic findings limited to a skull fracture without evidence of contusion or hematoma. Despite the dissemination of information that is available on diagnostic criteria, controversies still exist in defining mild head injury and collecting patients.

Estimating the duration of unconsciousness is difficult when witnesses are not available, second if the patient is intoxicated at the time of hospital admission it can obscure the assessment of severity of head injury.

3. Hearing loss in head injury

Deafness due to head injury is known since ancient times, the earliest account of which is the Edwin Smith papyrus, (Marc stiefel, 2006) the world's earliest known medical document, written around 1600 BC, but thought to be based on material from as early as 3000 BC. It is a textbook on trauma surgery, and describes anatomical observations physical examination, diagnosis, treatment, and prognosis of numerous injuries in exquisite detail. The symptoms and signs of head injury were given in considerable detail. It was noted that brain injuries were associated with changes in the function of other parts of the body. Feeble pulse and fever are associated with grievous injuries and deafness as well as aphasia are recognized in fractures of the temporal region.

Sushrutha who is known as "Father of Surgery" in India, even though he does not attach significance to the brain, however, considers head as the centre of all special senses and describes certain cranial nerves connected with specific sensory functions. He described two nerves lower down the back of the ear (vidhura), which, if cut, produce deafness; a pair of nerves (phana) situated inside the two nostrils, which if cut, cause anosmia. A pair of nerves below the outer end of the eye-brow, near the external corner of the eyeball (apanga) which if cut, cause total blindness.

Alexander and Scholl (Alexander AF and Scholl) as early as 1938 reported a 31% incidence of hearing loss in patients with head injury. In 1939 Grove (Grove W.E) reported an incidence of 32.6% of sensorineural hearing loss and suggested that bleeding in the inner ear was the cause whereas Uffenorde (Uffenorde W, 1924) stated that stretching of the fibers of the cochlear nerve in the internal auditory canal brought on the hearing loss after head injury. Similar results were reported by Gurdijan, (Gurdijan ES 1933) Fradis and Podoshin (Podoshin .L&,Fradis.M,1975) and M R Abd al Hady (M.R.Abd AL-HADY et al,1990). Griffiths (M.V.Griffiths)in 1979 reported an incidence of 56% of sensorineural deafness in cases of mild head injury . He stated that there may be difference in outcome depending on the type of violence. A blow to the head with a soft object seems to cause less damage to the hearing system than a blow to the head with a hard object with the same power at impact. The greater hearing loss according to him is due to an acoustic component.

The site of injury is important, frontal injuries resulting in a comparatively low incidence of hearing loss as compared to temporal blows. The type of audiogram recorded is an important indicator in assessing prognosis. Vertigo according to them has its own separate etiology and should be assessed and treated separately and not as a part of the post concussion syndrome.

In the immediate post injury period the incidence of hearing loss is 56% and vertigo is 24% which is very high when compared to controls (8%).Hearing loss recovered within three months. Accordingly, the mechanism of low frequency hearing loss is seen in patients with hydrops and suggests a similar peripheral mechanism. He stated that the lesions lie in the peripheral labyrinth due to edema or hydrops both of which subside with excellent prognosis. High frequency hearing loss may be caused by concussion and intense acoustic stimulation, concussion being reversible. Griffiths study showed a residual hearing loss in 14% of patients even after six months in cases of head injury with concussion without fracture.Vartiannenn (E.Vartianen et al, 1985) reported that in children who suffered blunt head trauma, 30% were found to have hearing loss of whom 16.3% had CHL and 13% had SNHL. One third of them recovered normal hearing with in six months. Similar results were reported by Zimmerman (William D.Zimmerman et al, 1993) Ludwig podoshin, (Podoshin .L. & Fradis.M, 1975) reported that conductive hearing loss due to head injury usually disappears in two months, if it persists ossicular discontinuity must be suspected.

According to Andrew T Lyos (Andrew.T.Lyos et al, 1995) in case of temporal bone fracture, immediate profound hearing loss may be caused by avulsion of the nerve or severe damage to the membranous labyrinth. Concussion directly to the otic capsule or acoustic trauma via the ossicular chain is well described. If it is not severe, it produces transient cochlear hyperemia resulting in temporary threshold shift. Feldman (Feldman H, 1987) stated that, sudden hearing loss with delayed onset can also occur following head trauma, thus it may be due to the sequelae consisting of perilymph fistula in one of the windows or a fracture of the labyrinthine capsule, which may manifest for the first time after a period of years or even decades.

Allison M Scott (Allison.M.Scot et al, 1999) found that in addition to low and high frequency hearing loss, audiograms with single and double sensorineural notches in mid frequency region may be related to head trauma.

The site of hearing impairment can be peripheral or central although the peripheral structures i.e., the middle ear and cochlea represent the most common site of injury. Nassulphis (Nassulphis P et al, 1964) found damage in the Reissner membrane and degeneration of the organ of corti in the spiral ganglion and cochlear nerve in several patients suffering from hearing loss following head injury. According to Schuknecht and Davison (Harold F.Schuknecht & Roderick C.Davison, 1956) auditory symptoms following head injury can be grouped according to the classification of labyrinthine damages which are:(a). Longitudinal fracture of temporal bone (b). Transverse fracture of temporal bone (c). Labyrinthine concussion. Labyrinthine concussion may be described as perceptive deafness and vertigo resulting from a blow to the head without fracture of bony labyrinth capsule. The nystagmus is positional and may persist for several months. The underlying pathology was thought to be due to injury to the utricle and saccule. Histopathological evidence showed rupture of the membranous walls of the utricle and saccule and degenerative changes in the macula of the saccule. This injury is commonest in ear with

longitudinal fracture of the temporal bone, secondly in an ear opposite a temporal bone fracture and thirdly in a head injury with no evidence of skull fracture. According to them to produce labyrinthine concussion a head injury must be severe enough to cause loss of consciousness.

Hearing loss is worst in the high frequency range and the peak loss is usually at 4000 Hz. The vertigo attacks are of postural type as described for patients having longitudinal fracture.

Experiments on animals show that the deafness is due to injury of the organ of corti, identical with that which results from a shock pulse in the air as a bomb blast or a pistol shot. They found that it results in violent displacement of the basilar membrane and organ of corti, that both reversible and irreversible cellular injuries result. They estimated hearing loss in animals, cats subjected to head injury. The hearing loss was estimated by audiogram and compared with a cochlear chart and found that the primary effect of trauma is to the organ of corti and the nerve degeneration is secondary. It is in fact the presence of damage to the organ of corti which ruled out nerve injury as a primary effect. The slightest detectable histological changes consisted of anatomical derangement of outer hair cells and their supporting cells. In mild injuries the outer hair cells which are normally tall and rectangular appeared shorter and wider and the nuclei were smaller and the chromatin was condensed. In severe lesions there was a loss of external hair cells and the beginning of cytological changes in the Dieters cells and the supporting cells, further progressive stages of injury consisted of flattening of the organ of corti and finally its complete disappearance. In labyrinthine concussion histological examination of the auditory system revealed the significant pathological changes to lie in the cochlea, when there was damage to the organ of corti severest in the upper basal turn, the region serving 4000Hz frequency. Thus according to them partial permanent deafness occurs in about 50% of patients who sustain a blow to the head to produce unconsciousness. Even a mild head blow without loss of consciousness can occasionally result in deafness.

According to Makashima and Snow (Kazumi Makashima & James .B. snow, 1975) experimental findings by means of assessment of preyer reflex and cochlear potentials in guinea pigs after stimulating head injury by shaking them in a padded cage till they became unconscious showed that in animals which did not have fracture of the skull showed hemorrhage in and laceration of the 8th nerve where it exits from the medulla oblongata. Animals killed after 6 days and 30 days showed slight to moderate degeneration of outer hair cells and Hensens cells in the apical and middle turns of the cochlea, changes in the Stria vascularis were minimal.

The oto-neurological manifestations vary from patient to patient with head injury. Variability exists in type, severity and mode of onset of symptoms and signs. In some patients deterioration of hearing and vestibular functions occurs immediately after head injury and it may be transient or permanent. In other patients the symptoms may not manifest until later and deterioration of function may continue. According to them these facts suggest that there are various forms of trauma in the temporal bone and central pathways could be responsible for the deterioration of function.

In a study done by EB Dorman (E.B Dorman et al 1982) the hearing loss was noted to be due to cochlear dysfunction. No 8th nerve or central abnormalities were detected. Various

hypotheses have been put forward to explain the hearing loss that appears after brain concussion.

According to Per-Olof Bergemalm (Per-olof Bergemalm, 2003) in cases of closed head injury 74% of patients showed progression of > 15dB HL which was significantly greater than the spontaneous progression in the control group. Age and temporal bone fractures were risk factors for progression but not brain contusion or Swedish Reaction Level Scale (RLS) They found an association between early PTA (Pure tone Audiometry) and progression as well as regression i.e. poorer the initial PTA the greater the progression indicating the increased instability of the auditory system. The cause of progression is usually unknown. One of the possibilities is the development of perilymphatic fistula, other reasons may be secondary degenerative changes in the cochlea following inner ear concussion and hypoxia following disturbance of micro-circulation. It has also been speculated whether progression is due to pre-existing autoimmune disease or whether the trauma itself may initiate such a reaction towards specific inner ear proteins. There may also be synergistic interaction between trauma and the effects of noise exposure (Neuberger M Korpert K et al 1992) and the use of oto-toxic agents and medication (Jacobson CA&.Jacobson JT, 1989)

According to Vernon and Press (Vernon JA, & Press LS, 1994) only 8% of the patients who sustained head injury complained of tinnitus.

Dizziness is a frequent complication of head injury. Numerous studies have attempted to quantify the incidence of neuro-otological abnormalities in patients with post traumatic dizziness. Toglia (Toglia J U et al, 1970) found out that 61% of patients had vestibular dysfunction. Gannon (Gannon RP et al, 1978) reported 32% and Wilson reported 57% neuro-otological test abnormalities in patients who sustained minor or moderate head injury. In case of recurring case of dizziness an organic etiology must be suspected. Hearing loss in the higher frequencies is sometimes seen as early as by age 20(Rakel R E, 2005) It increases systematically to age 60 (and beyond) and is largest at 4 kHz and 6 kHz and is much larger in males than in females.

A small Sensorineural hearing loss of 25dB at the age of 25 has little medical or social relevance, however by the age of 70 a hearing loss as a result of ageing is added to the pre-existing hearing loss. This results in a moderate to severe sensorineural hearing loss. In other words a seemingly minor hearing loss at a very young age may become severe when combined with other factors which affect hearing.

4. Anatomy of the ear and temporal bone

From the point of view of injury to the ear the anatomy can be divided into preauricular pinna, post auricular region, tympanic membrane, external auditory canal, middle ear and inner ear. Preauricular region is the region of the ear in front of the auricle. Post auricular region is the region behind the auricle. The temporal bone is a composite structure and consists of tympanic bone, mastoid process, squamous and petrous parts. The tympanic bone forms the anterior, inferior and parts of the posterior wall of the external auditory canal. Laterally the tympanic bone borders the cartilaginous external auditory canal. The squamous portion of the temporal bone serves as the lateral wall of middle cranial fossa and interfaces with the parietal bone superiorly and with the zygomatic process and the sphenoid anteriorly.

The mastoid portion of temporal bone is the inferiorly extending projection seen on the lateral surface of the temporal bone. It is composed of a squamous portion laterally and petrous portion medially separated by Korner's petro squamous septum. The petrous portion (Greek for 'rock like') guards the sensory organs of the inner ear.

The tegmen tympani is the bony roof of the tympanic cavity, and separates it from the dura of middle cranial fossa. It is formed in part by petrous and part by the squamous bone, and the petrosquamous suture line, unossified in the young does not close until adult life.

The floor consists of a thin plate of bone which separates the tympanic cavity from the dome of the jugular bulb, sometimes it is deficient. The anterior wall of tympanic cavity is narrow as the medial and lateral walls converge. The lower portion of the anterior wall is larger than the upper and consists of a thin plate of bone covering the carotid artery.

4.1 The cochlea

The bony cochlea lies in front of the vestibule and has an external appearance rather like the shell of a snail. The shell has approximately two and one half turns and its height is about 5mm while the greatest distance across the base is about 9 mm.

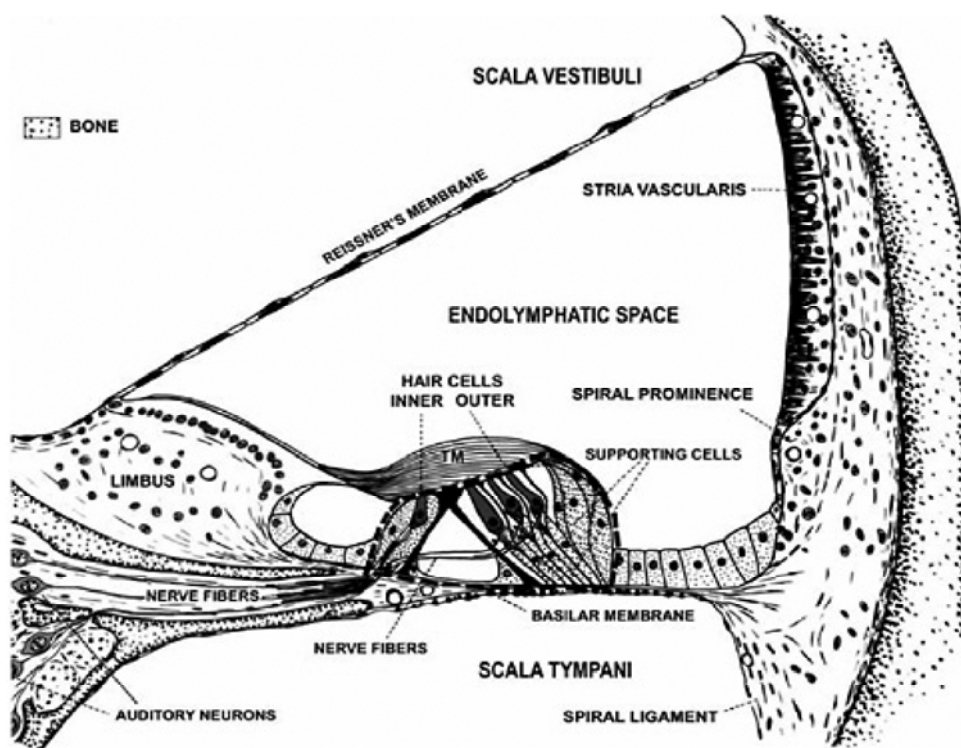


Fig. 1. Cross section of the cochlea
(SOURCE: www.nap.edu/openbook, page=35 Modified from Davis and Associates (1953))

The basilar membrane which separates the scala media from the scala tympani consists of connective tissue fibers embedded in an acellular matrix. The organ of Corti, tectorial membrane along with the basilar membrane makes up the cochlear partition. (Fig-1).

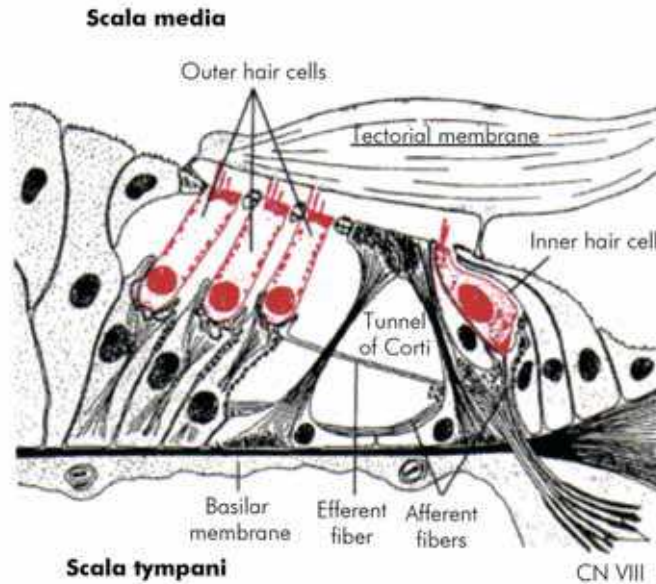


Fig. 2. Organ of Corti (Nolte (1993) *The Human Brain* 3rd Ed. Fig. 9-34B, p. 213. Cross-section through the Organ of Corti)

The organ of Corti (fig-2) is a ridge like structure containing the auditory sensory cells and a complex arrangement of supporting cells. The sensory cells are arranged in two distinct groups as inner and outer hair cells. There is a single row of inner hair cells, although occasionally extra hair cells may be apparent, and also three, four or five irregular rows of outer hair cells, with frequent gaps where individual hair cells are absent. Each hair cell consists of a body, which lies within the organ of Corti, and a thickened upper surface called the cuticular plate, from which projects a cluster of stereocilia or hairs. The stereocilia contains a core of actin molecules packed in a para crystalline array and covered with a cell membrane. The stereocilia are connected to each other along the sides by fine filaments called the side links. The tip of each stereocilium is connected to the sides of the next tallest stereocilium by a longer filament known as a tip link. The body of the inner hair cells is flask shaped, with a small apex and large cell body. The long axis of cell is inclined towards the tunnel of Corti, and nerve fibers and nerve endings are located around the lower half of the body. The stereocilia projecting from the thickened cuticular plate are arranged in two or three rows parallel to the axis of the cochlear duct. The body of the outer hair cell is cylindrical with the nucleus lying close to the lower pole, where afferent and efferent nerve endings are attached. There are several rows of stereocilia but the configuration varies from a W shape at the base, through a V shape in the middle coil, to almost a linear array at the apex. The number of stereocilia also decreases in the passage from base to apex, where as the length increases, although not in a linear fashion. The hair cells are supported with in

the organ of corti by several types of specialized, highly differentiated cells. These are the pillar cells, Dieters cells and Hensen's cells. In the fetus and the newborn there are about 3500 inner hair cells and 13000 outer hair cells.

5. Audiometric tests

5.1 Pure tone audiometry

It is the most commonly used method of measuring hearing acuity. It is a subjective test. The frequencies usually tested are at octave steps i.e., 125, 250, 500, 1000, 2000, 4000, 8000 Hz. A pure tone audiometer is an electronic instrument capable of producing pure tone sound of different frequencies at variable intensities. It helps in qualitative and quantitative diagnosis of hearing loss.

5.2 Tympanometry

It is the measurement of acoustic emissions in the external auditory meatus as a function of air pressure within the external auditory meatus. It provides a rapid atraumatic and objective technique for evaluating the integrity of (a) Middle ear transmission system, (b) Estimating middle ear pressure, (c) Estimating volume of ear canal or middle ear, (d) Evaluating Eustachian tube function.

Type A Tympanogram indicate normal middle ear pressure as indicated by tympanogram peak at 0 daPa. Normally middle ear pressure typically falls between +50 and -100 daPa.

Volume measurements more than 2 ml in children and 2.5ml in adults are usually indicative of tympanic membrane perforation or patent pressure equalization tube.

Mild cochlear hearing loss has little effect on acoustic reflex thresholds for tonal stimuli. for patients with hearing losses that exceed 70 dB reflexes are typically absent.

5.3 Oto-acoustic emissions

As early as 1948, Gold (Gold.T,1948) discovered that the outer hair cells of the cochlea could produce energy by an active mechanical process. However it was not until 1978 that Kemp (Kemp 1978) by a series of basic and clinical experiments demonstrated that the cochlea was capable of producing low intensity recordable sounds called oto-acoustic emissions (Fig-3). Oto-acoustic emissions (OAEs) can be defined as the audio frequency energy which originates in and is released from the cochlea, transmitted through the ossicular chain and tympanic membrane and measured in the external auditory meatus. They can occur either spontaneous or in response to acoustic stimulation. OAEs are believed to reflect the active biomechanical movement of the basilar membrane of the cochlea (Fig-4). This retrograde traveling wave is thought to be responsible for the sensitivity, frequency selectivity and wide dynamic range of the normal auditory system. Oto-acoustic emissions (OAEs) are believed to be the by product of pre-neural mechanisms of the cochlear amplifier and in particular, to be linked to the normal functioning of the outer hair cells. Oto-acoustic emissions are vulnerable to a variety of agents such as acoustic trauma (Hamernik RP, 1996) hypoxia, (Rebillard.G Lavigne& Rebillard.M) and oto-toxic medications (Ress .B D et al, 1999) that cause hearing loss by damaging outer hair cells.

Taking into account estimates of amplification provided by outer hair cells, complete destruction of OHC'S alone could result theoretically, in a hearing loss of 60 dB. Early investigations in to OAE'S proved that they are not present when the sensorineural hearing loss exceeds 40-50dB (Collet L, 1989), (Gorga, Michael P, 1997).

DPOAEs measures have shown excellent intra-subject test reliability which allows monitoring of dynamic changes of cochlear function (V.Rupa, 2001)

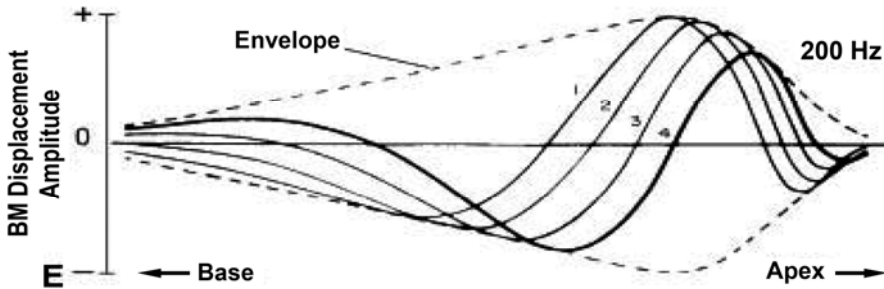


Fig. 3. Basilar membrane displacements produced in cadaveric human cochlea in response to 200Hz at 4 separate points of time. Envelope of travelling wave is also noted

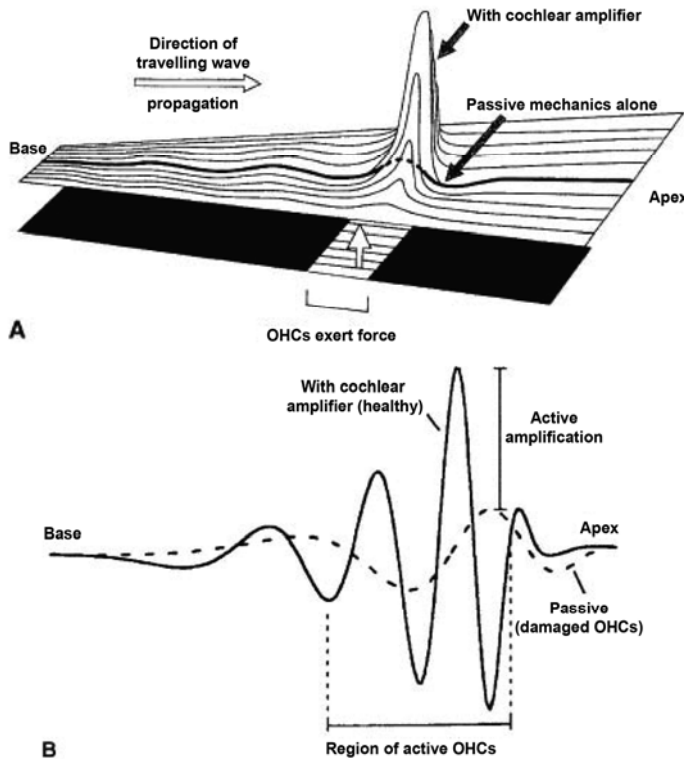


Fig. 4. Schematic representation of travelling wave along basement membrane

It has been established that DPOAEs are reduced or eliminated by compromise of middle ear conduction pathway. Normal middle ear functioning is pre-requisite for measuring DPOAE and it is therefore important to include immittance measurements while recording DPOAEs. This means is also used to confirm the presence of any middle ear pathology in MHI.

6. Study

In the study done in the ENT department of Christian Medical College India, 60 patients with history suggestive of mild head injury were evaluated over a period of six months.

INCLUSION CRITERIA: All patients with (a) history suggestive of Mild Head injury (MHI) Glasgow coma scale scoring system [GCS] 13 – 15 and improving (b) age between 6 – 60 years, (c) Patients discharged from casualty after observation period of 24 hours, (d) History of loss of consciousness of less than 20 minutes.

EXCLUSION CRITERIA: Patients with past history of ear disease, previous head injury or noise trauma. and patients having family history suggestive of autoimmune disease and hearing loss.

A detailed evaluation of the severity of injury using Glasgow coma scale scoring was done. Radiological investigations like X-Ray of skull (antero-posterior and lateral) and CT scan were used to detect skull fractures.

The external auditory canal and tympanic membrane were assessed to rule out any signs of temporal bone fracture like bleeding from external auditory canal, palpable step deformity, tympanic membrane perforation or haemotympanum. If the external auditory canal was filled with clotted blood patient was called for assessment after a period of one week. Eyes were checked for nystagmus and conjugate deviation. Facial nerve function tests were done and when the patient was cooperative facial nerve function was graded according to House Brackmann scale (House JW, & Brackmann DE 1985)

Pure tone audiometry was done and Hearing thresholds of 15-25 dB across the frequencies were considered to be as normal. Tympanometry was done using a probe tone frequency of 226Hz. An ipsilateral stapedial reflex at 1000 Hz was elicited. The ipsilateral acoustic reflex threshold was seen as normal if the level at which it is elicited falls between 70db and 100db.

DPOAE testing was done at 1000Hz, 2000Hz, 3000Hz, 4000Hz, and 6000Hz.

Repeat evaluation was done after a period of three and six months. A detailed otoneurological evaluation was done in all three visits and patients were specifically asked for symptoms of hearing loss tinnitus and vertigo

6.1 Results and analysis

Road traffic accidents (RTA) were the most common cause of Minor head injury as seen in all studies. The incidence of road traffic accidents in age groups 20-50 years, in our study, (Fig-5) was similar to the study done by Ludwig podoshin and M R Abd AL-Hady. A vast majority (75%) of the RTA's (Road traffic accidents) (Fig-6) were two wheeler accidents and none wore helmets at the time of accident.

Majority (83%) were males and 66% were between ages of 20-50 years.

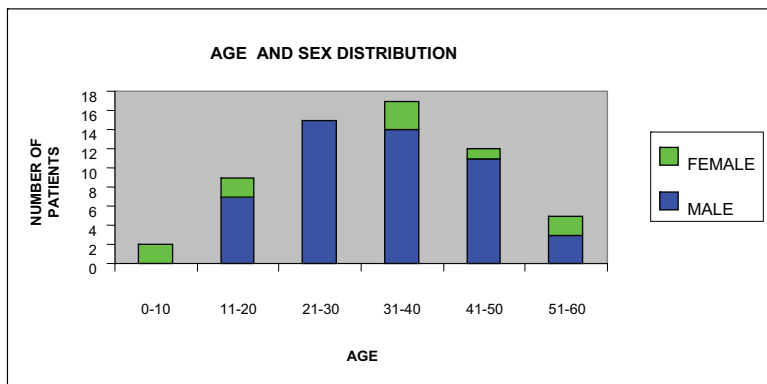


Fig. 5. Age and sex distribution

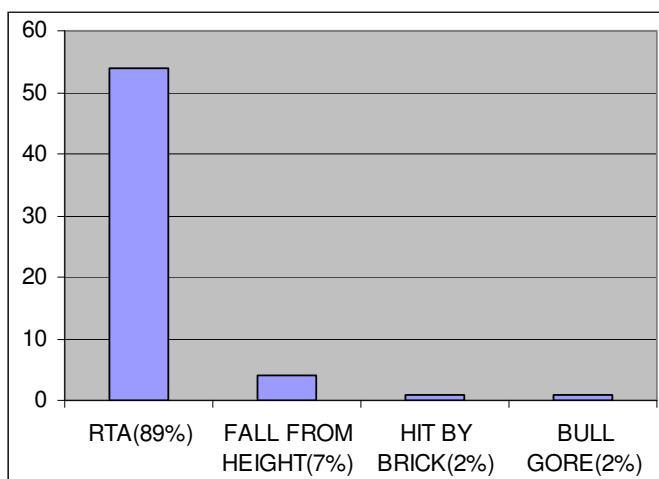


Fig. 6. Mode of injury

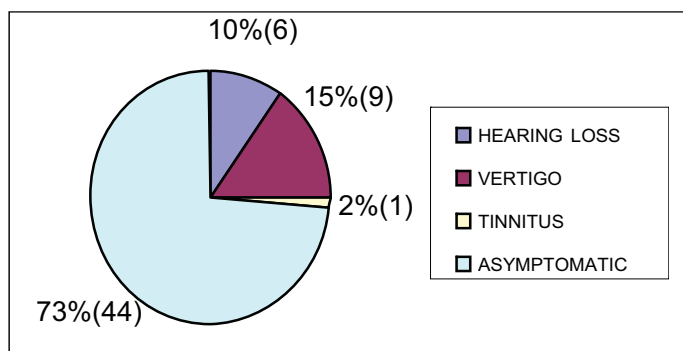


Fig. 7. Symptoms

Out of 60 patients 73% were asymptomatic, 15% complained of vertigo, 10% complained of hearing loss, and 2% complained of tinnitus (Fig-7).

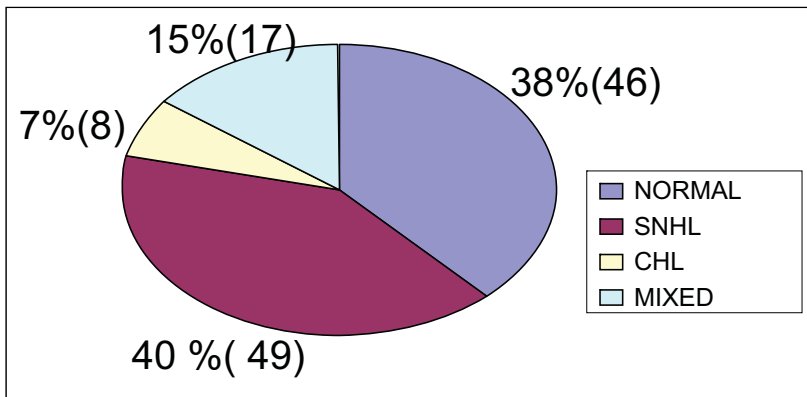


Fig. 8. Hearing loss in patients with MHI

Out of 60 patients (120 ears tested), 38 % had normal hearing, 40% had sensorineural hearing loss, 7% had conductive hearing loss, and 15 % had mixed hearing loss (fig -8).

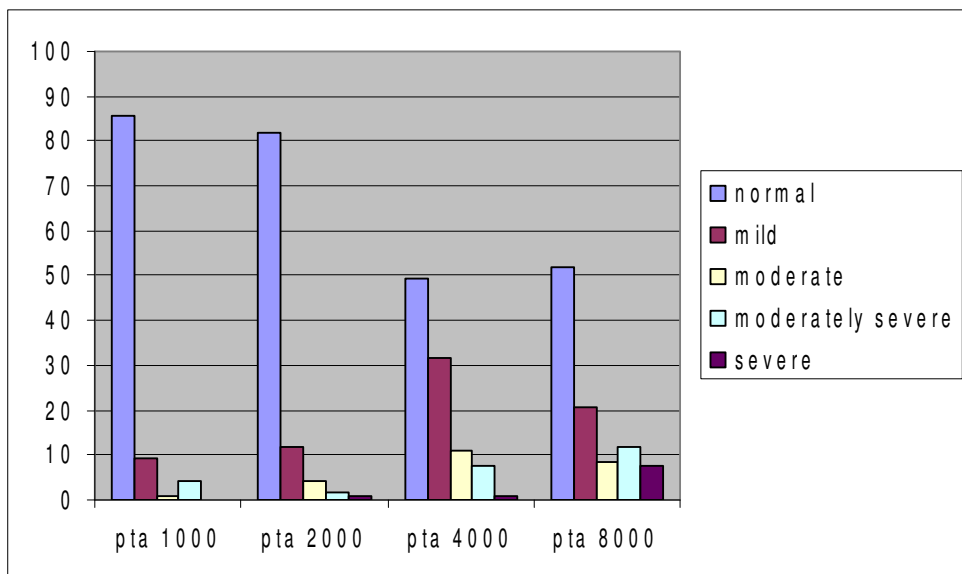


Fig. 9. Pure tone audiometry

Pure tone audiometry assessment of hearing immediately post trauma with respect to frequencies affected revealed that hearing loss was mainly in the high frequency region with greatest loss noticed at 4000 Hz and 8000 Hz (Fig-9). Significant hearing improvement on PTA was found at all the four frequencies with in three months after trauma , 1000Hz (p-

value 0.014) , 2000Hz (p-value 0.006), 4000Hz (p-value<0.001), and 8000Hz (p-value 0.002)(Fig-10) ,(Fig-11),(Fig-12) .

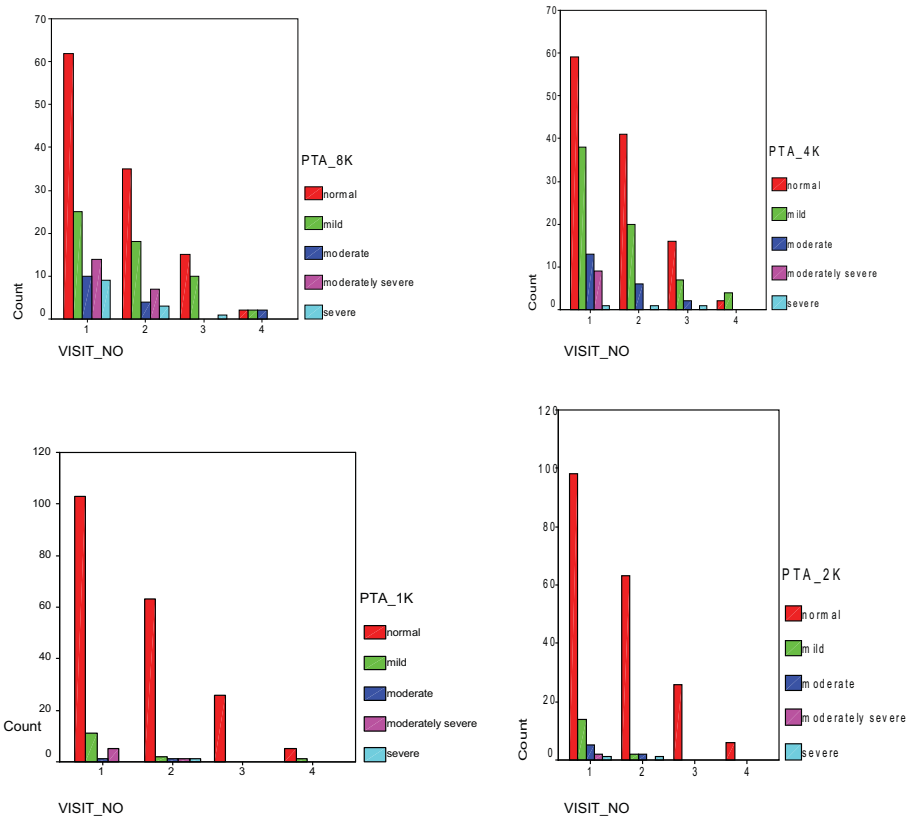


Fig. 10. Serial Pure Tone audiometry at 1000Hz,2000Hz,4000Hz,8000Hz over a period of six months

DPOAEs are present across most frequencies at and above 1000Hz in 99 to 100% of ears with normal hearing and they are absent when sensorineural hearing loss exceeds 40-50dB which was similar in our study. No studies were found in literature where DPOAE was assessed in minor head injury.

It was seen that DPOAE was absent in 38.6% at 1000Hz, 36% at 2000Hz, 29.8% at 4000Hz in patients even with normal PTA thresholds after mild head injury.

In case of Mild hearing loss on PTA, there was absence of emissions in 70% at 1000 Hz, 69% at 2000Hz, 83% at 4000Hz. This would suggest that damage to outer hair cells becomes more pronounced when there is manifest hearing loss on PTA. In few cases with normal hearing, DPOAEs were absent through out the evaluation time period suggesting irreversible damage to outer hair cells (Fig13, 14, 15).

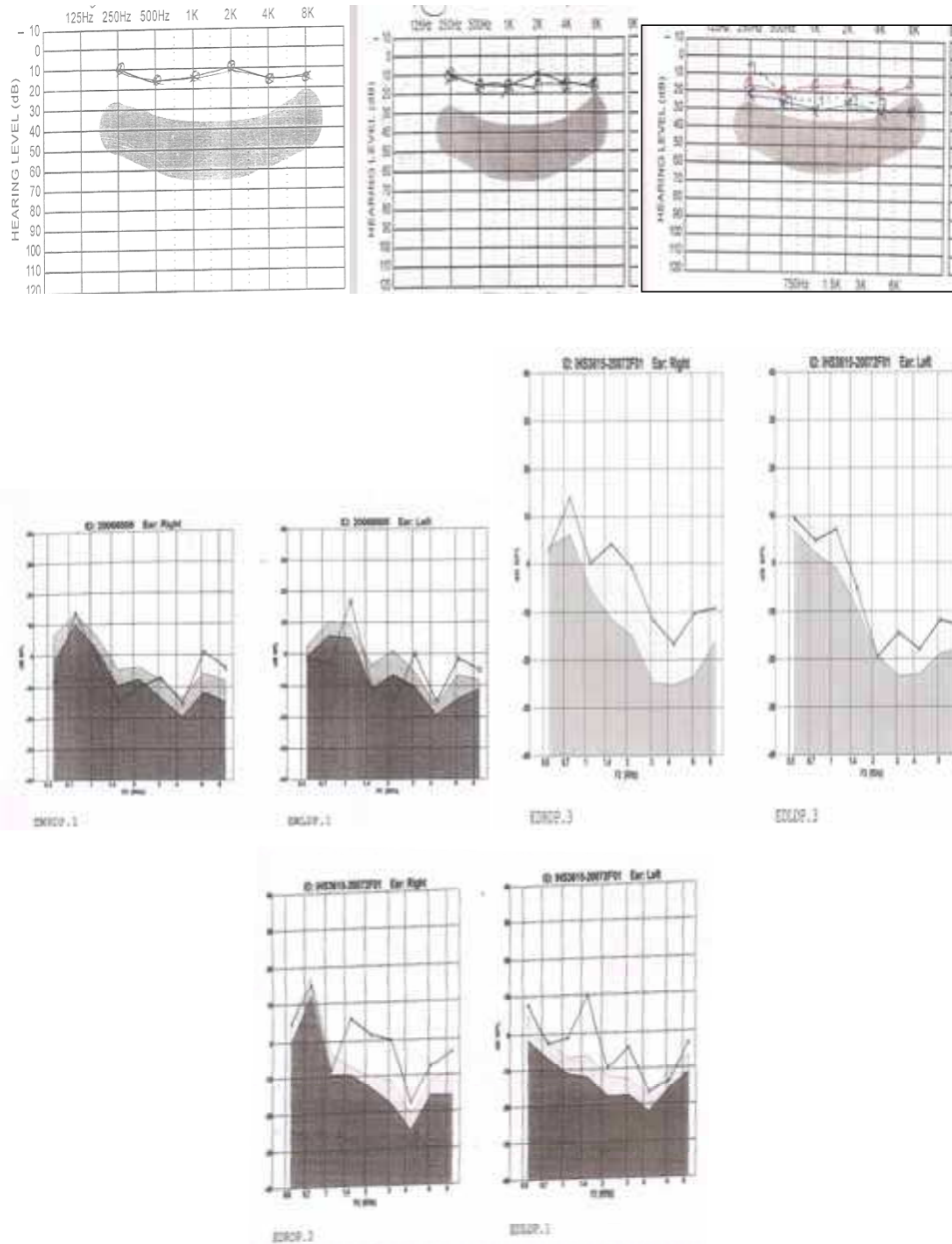


Fig. 11. Pure tone audiometry showing progression of hearing loss affecting frequency of 4000hz,8000hz in patient with left frontal bone fracture. Absence of DPOAEs at 4000hz from the time of trauma

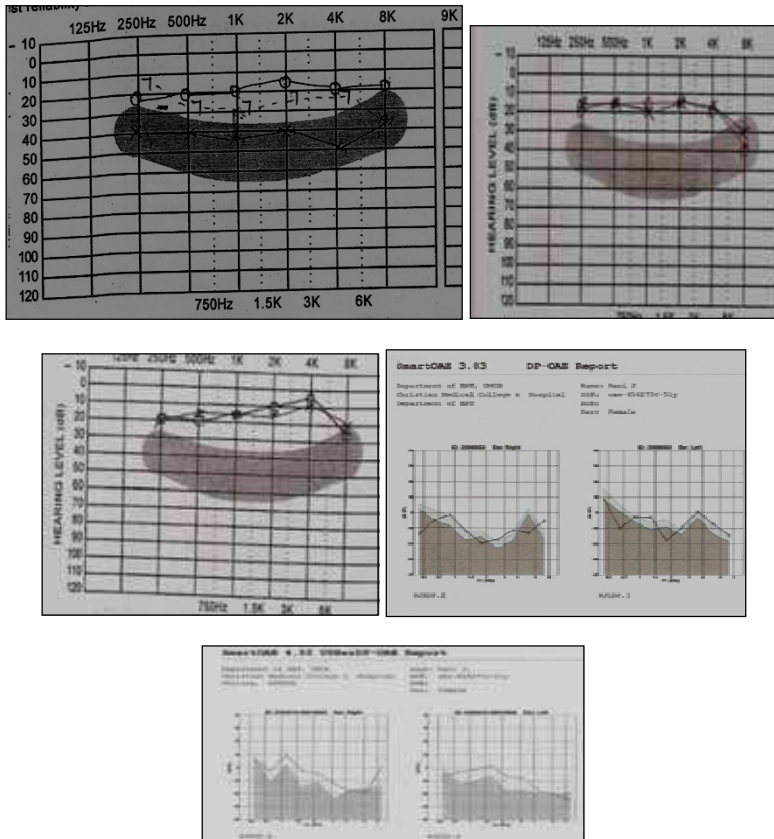


Fig. 12. Pure tone Audiometry and DPOAEs showing conductive hearing loss post trauma which returned to normal over a period of six months, but continues to have absent emissions at 4000 Hz, 6000 Hz

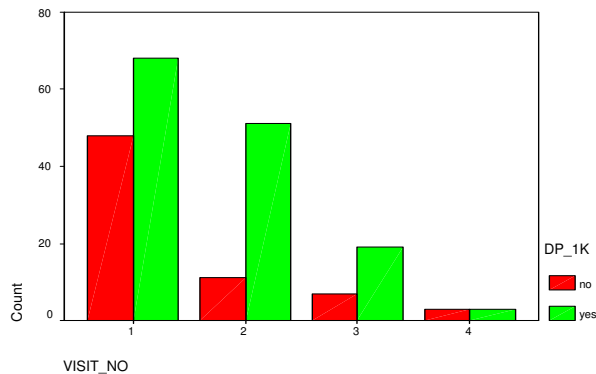


Fig. 13. DPOAE at 1000kHz

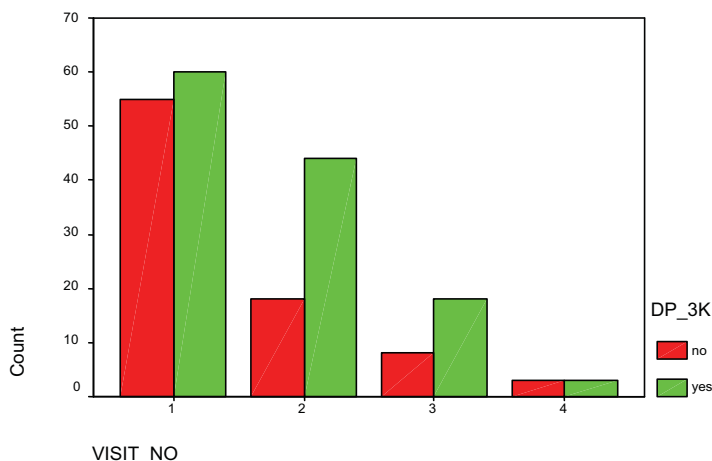


Fig. 14. DPOAE at 3000kHz

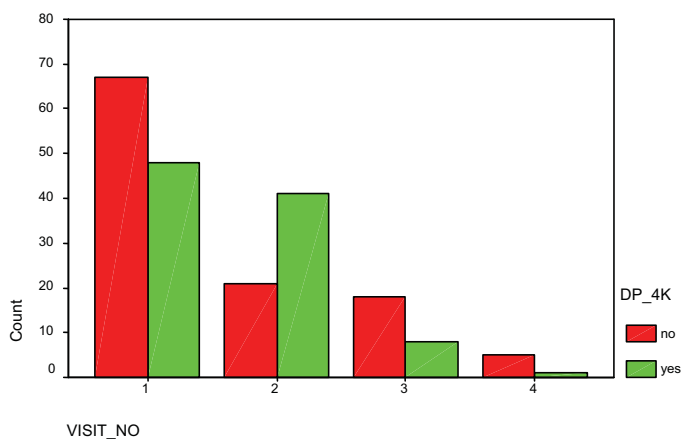


Fig. 15. DPOAE at 4000kHz

As the hearing improved oto-acoustic emissions were detectable, however in cases where the hearing loss progressed, emissions could not be recorded. Changes in DPOAEs were found to be statistically significant only at 3000 Hz (p value-0.002) and 4000Hz (p value-0.003), in mild head injury.

Dix-Hallpike positional test was positive in three patients for whom Epley's repositioning maneuver was done and rests of the patients were treated with labyrinthine suppressants. One patient complained of tinnitus.

On examination hemotympanum was noticed in 2 patients which resolved over a period of three months. 1 patient presented with laryngeal trauma, rest of the patients had bleeding either from the nose or the ear.

Bleeding from the ear was noticed to be due to laceration in the external auditory canal. Patients having ear bleeding were called after a week for auditory assessment, no active intervention was needed. 1 patient had otitis externa which was treated conservatively.

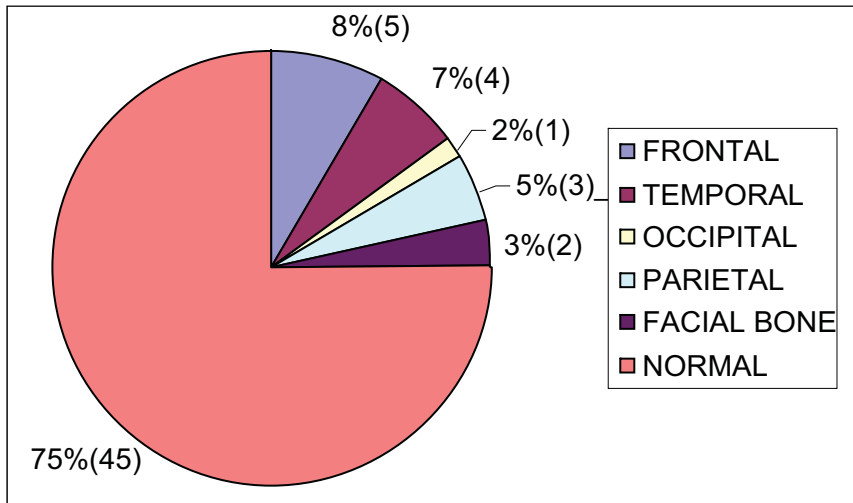


Fig. 16. Distribution of fractures

Out of 60 patients a total number of 15 patients were found to have skull fractures (fig-16).

Of 5 patients with frontal bone fractures bilateral hearing loss was noticed in all the patients, of which mixed hearing loss improved but did not become normal.

In patients who sustained temporal bone fractures, mixed fractures were seen in two patients, one patient had longitudinal fracture, and one had transverse fracture. Sensorineural hearing loss was found in four ears, mixed hearing loss was found in one ear, conductive hearing loss was noticed in one ear, and two ears were found to be normal.

Sensorineural hearing loss was noticed in the patient who sustained a fracture of the occipital bone.

Out of the three patients who sustained parietal bone fractures two patients were found to have normal hearing, the third patient had sensorineural hearing loss in one ear which became normal and mixed hearing loss in the other ear that improved.

Bilateral sensorineural hearing loss was detected in patients who sustained facial bone fractures.

Only one patient with parietal bone fracture with normal hearing complained of vertigo in which positional test was negative and was treated conservatively.

Out of the four patients who fell from a height three patients had normal hearing and one had conductive hearing loss. Parietal bone fracture was detected in one patient who had normal hearing. Hearing loss progressed in one patient.

Delayed facial nerve paresis was seen in one patient who presented with history of bull gore injury which recovered within 3 months.

7. Conclusion

This prospective study was done in a tertiary care teaching hospital to look at the incidence of hearing loss in patients who sustained minor head injury. The behavior of hearing loss was evaluated by serial assessment of hearing. Road traffic accidents (RTA) were the most common cause of Minor head injury as seen in all studies. The incidence of road traffic accidents in age groups 20-50 years, in our study, was similar to the study done by Ludwig podoshin and M R Abd AL-Hady. Whereas in the study done by Griffith, the majority were seen in late teens.

Two wheeler accidents were found to be the commonest cause of RTA causing minor head injury in our study, whereas another study (George .G.Browning at al 1982) reported that assault / fight was the major etiology causing minor head injury. 75% of the RTA's were two wheeler accidents and none of them were wearing helmets at the time of accident. In about 40% of our patient's consumption of alcohol would have contributed to the road traffic accident.

Symptoms of hearing loss were found in only 10% of patients which is in agreement with Harold F.Schuknecht (1956) and Kazumi Makashima et al (1975) due to the involvement in high frequency region. The symptoms of vertigo were found to be 15% which is low as compared with Toglia JU et al (1970) who reported an incidence of 61% and Rosalyn et al (1995) who reported 95% of patients with symptoms of vertigo . Additionally a low incidence of tinnitus was observed which is in agreement with Griffith. The incidence of Hearing loss in our study is 62% which is in agreement with a previous study Griffith (56%) with males being most affected.

The commonest type of hearing loss was sensorineural loss confined to high frequencies. The degree of hearing loss determined the out come, and it was found in our study that patients who had moderate to severe hearing loss at the time of injury had a poorer prognosis as compared to those with normal hearing. Like the results of other studies temporal bone fractures had a higher incidence of hearing loss as compared to other facial bone fractures.

In our study in India, Road traffic accidents (RTA) were the most common cause of Minor head injury. 75% of the RTA's were two wheeler accidents and none of them were wearing helmets at the time of accident. In about 40% of our patient's consumption of alcohol might have contributed to the road traffic accidents.

Only 10% of patients complained of hearing loss ,however on evaluation 62% were found to have hearing loss. The commonest type of hearing loss was sensorineural loss confined to high frequencies. The prognosis was poor if the hearing loss was more severe. The degree of hearing loss determined the outcome, and it was found in our study that patients who had moderate to severe hearing loss at the time of injury had a poorer prognosis. Temporal bone fractures have a higher incidence of hearing loss, the symptoms of vertigo was found to be 15%. Incidence of tinnitus is low after minor head injury. DPOAE assessment at 3000 Hz

and 4000 Hz is significant in assessing outer hair cell damage when compared to Pure Tone Audiometry in sub clinical hearing loss.

8. Acknowledgements

I wish to express my deep gratitude to Dr. John Mathew, Professor and Acting Head-unit-II, and Dr. Achamma Balraj, Professor Department of ENT, Christian Medical College Vellore, for their able guidance in conducting this study .

I wish to thank Dr. Anand Job, Medical superintendent, Professor and Head of unit-I, Department of ENT, and Dr. Pushparaj Singh, Head of Department of Accident and Emergency medicine for consent to use hospital facilities during the study period.

Last but not the least, I would like to thank my Parents, brother, wife, daughter, colleagues and staff of ENT for their help in making this study a reality.


I wish to thank Christoffel Blinden Mission SARO South for the financial support for Publication of this Chapter.

9. References

- Andrew.T.Lyos.Michael A .Marsh et al .Progressive Hearing loss after Transverse Temporal Bone Fracture Arch Otolaryngol Head Neck Surg Vol 121 Jul 1995: pp 795-799
- Allison.M.Scot..Christopher D.Bauch et al .Head Trauma and Mid-Frequency Hearing loss. American journal of Audiology Vol 8 December 1999: pp 101-105
- Alexander AF,Scholl R.Beschwerden und stoerungen in Hoehr und gleichgewichtsogan beim Nachuntersuchung schaedelverletzter.Monatsschr Ohren 72 1938: pp 1021
- Anthony Wright .Anatomy and ultrastructure of the human ear .In Scott-Brown's Otolaryngology, 6thedition volume 1 Alan.G Kerr .Butterworth-Heinemann, oxford ;1: 11-49
- Bergemalm P-O.Borg.E., Long term objective and subjective audiologic consequences of closed head injury.Acta Otolaryngol 2001;121: pp 724-734
- Collet L. Evoked Oto-Acoustic emissions and sensorineural hearing loss .Arch Otolaryngol Head and Neck surgery 115: pp 1060-1062
- Culotta VP semementilli ME, Gerald. Ket al.clinico-pathological heterogenicity in the classification of mild head injury. Neurosurgery 1996; 38: pp 245-250
- Dahiya.R, Keller JD et al ,Temporal bone fractures :otic capsule sparing versus otic capsule violating clinical and radiographic considerations Trauma 1999;47:pp 1079-83
- E.B Dorman,NZ Med Journal 1982;95: pp 454-455
- E.Vartianen, S.Karjalainen et al, Auditory Disorders following Head Injury in children, Acta Otolaryngol[stockh]1985;99: pp 529-536
- FELDMAN H., Sudden Hearing loss with Delayed onset following Head Trauma. Acta otolaryngol 1987; 103:pp 379-383.
- Gannon RP.Wilson GN et al .Auditory and vestibular damage in head injuries at work. Arch otolaryngol, 1978 ,104: pp 404-408.
- George .G.Browning .Iain R.C Swan et al. Hearing loss in Minor Head Injury. Arch Otolaryngol vol 108 1982: pp 474-477

- Gold.T, The physical basis of the action of the cochlea. Proc R Soc Loud B Biol Sci 1948;135: pp 492-498
- Grove W.E, Skull fractures involving the ear. Laryngoscope 1939; 69: pp 833-870
- Gorga, Michael P; Neely, Stephen .T et al .From Laboratory to clinic: A large scale study of distortion product otoacoustic emissions in ears with normal hearing and ears with hearing loss. Ear Hear Vol 18(6) December 1997 : pp 440-455
- Gomez PA,lobato RD,Ortega JM,et al.Mild head injury: Differences in prognosis among patients with a Glasgow coma scale score of 13-15 and analysis of factors associated with abnormal CT findings.Br JNeurosurgery 1996;10: pp 453-460
- Gurdijan ES:Studies on Acute cranial and intracranial injuries. Ann Surg 1933 :pp 327-367.
- H.Alexander Arts. Sensorineural Hearing loss:Evalaution and management in adults. In Charles.W.Cummings OTOLARYNGOLOGY AND HEAD AND NECK SURGERY 4TH Edition Elsevier Mosby` Part 14,Chapter 155- pp 3542
- Harvey s.Levin, Outcome from mild head injury. In Raj .K.Narayanan .Jack .E.Wiberger NEUROTRAUMA Mc-Graw Hill: chap-50 pp 749-754
- Harold F.Schuknecht and Roderick C.Davison,,Deafness and Vertigo from Head Injury,AMA Archives of Otolaryngology 1956: pp 513-528
- Hamernik RP .The cubic distortion product oto-acoustic emissions from the normal and noise damaged chinchilla cochlea. JAcoust Soc Am 1996;100: pp 1003-1012
- House JW, Brackmann DE. Facial Nerve Grading System.Otolaryngol Head and Neck surgery 1985; 93: pp 14
- Hough JVD ,Stuart WD.Middle ear injuries in skull trauma. Laryngoscope 1968;78:899
- Hsiang JNK,Yeung T,Yu ALM ,et al. High Risk mild head injury JNeurosurgery 1997:87 : pp 234-238
- Jacobson CA.Jacobson JT et al.Hearing loss in prison inmates. Ear Hear 1989;10: pp178-183
- Kazumi Makashima,James .B.snow. Pathogenesis of Hearing loss in Head Injury, Studies in Man and Experimental Animals. Arch Otolaryngol Vol 101 July 1975:pp 426-432
- Kemp DT. Stimulated acoustic emission from with in the hearing system. JAcoustic Soc Am 1978;64: pp 1386-1391
- Marc stiefel.Arlene Shaner et al .The Edwin Smith Papyrus: The Birth of Analytical Thinking in Medicine and Otolaryngology,Laryngoscope116 Feb 2006:pp 182-188
- M.R.Abd AL-HADY .O Shehata et al. The Journal of Laryngology and Otology Vol 104 December 1990: pp 927-936
- M.V.Griffiths .The incidence of auditory and vestibular concussion following minor head injury. The Journal of laryngology and Otology 1979 March;Vol 93: pp 253-265
- Nassulphis P:Die Schaedigung des innenohres und seines nerven nach Schaedeltrauma. Msch Ohr-Heilk, Jahg feb: 79-80, June,1964 :pp 222-252
- Neuberger M Korpert K et al Hearing loss from industrial noise, head injury and ear disease. Audiology 1992 ;31: pp 45-57
- Per-olof Bergemalm. Progressive Hearing loss after closed Head Injury: A Predictable Outcome?. Acta Otolaryngol 2003 ;123: pp 836-840
- Podoshin .L., Fradis.M:Hearing loss after Head Injury.Arch otolaryngol 1975;101: pp 15-18
- Rakel R E. Textbook of family practice. 6th Ed .Philadelphia PA .WB Saunders 2005 : pp 443-449
- Rebillard.G Lavigne-Rebillard.M. Effect of reversible hypoxia on the compared time courses of endocochlear potential and 2f1-f2 distortion products. Hear Res 62:pp 142-148

- Ress .B D, Sridhar K.S et al .Effects of Cis-platinum chemotherapy on Oto-Acoustic Emissions. The development of an objective screening protocol.Otolaryngol Head Neck Surg 1999; 121: pp 693-701.
- Rimel RW, Giordani B,Barth JT et al. Disability caused by minor head injury. Neurosurgery 1981;9:pp 221-8
- Rimel RW, Giordani B,Barth JT et al. Moderate head injury: Completing the clinical spectrum of brain trauma. Neurosurgery 1982;11: pp 344-51
- Robert .JRuben .MD .Hearing loss and deafness. Ear Nose and Throat Disorders .Merck .Accessed at www .merck.com
- Rosalyn A Davies. Linda M Luxon.Dizziness following head injury: A neuro-otological study. JNeurol 1995 ;242: pp 222-230
- Starmark JE .Stalhammar D.et al .The Reaction Level Scale [RLS85].Manual and Guidelines Acta Neurochir 1988;;91:pp 12-20
- Swan LJ Teasdale Gm. Current concepts in the management of patients with so called' minor' or mild head injury, Trauma 1999;1: pp143-55
- Teasdale G, Jennett B. Assessment of coma and impaired consciousness. A practical scale.Lancet1974;2:pp 81-4
- Toglia JU .Rosenberg PE et al .Post traumatic dizziness: Vestibular, audiologic and medico-legal aspects. Arch of Otolaryngol ,1970,92: pp 485-492
- Uffenorde W:Histologishe Befunde.Beiter Z Anat physiol Pathol Therap Ohrens 1924; 21:pp 282-285
- Varghese. M. Mohan. D,Transportation Injuries in rural Haryana,North India. Proceedings International conference on Traffic safety, New Delhi. Macmilan India limited:2003: p 326-329
- Vernon JA, Press LS. Characteristics of tinnitus induced by head injury. Arch Otolaryngol Head Neck Surg 1994;120:pp547-51
- V.Rupa, Clinical utility of distortion product Oto-acoustic emissions. Indian journal of otolaryngology Head and neck surgery 2001;Vol 54: pp 88-90
- World report on road traffic injury prevention,Peden marge,Scurfeild et al Editors, Edition 2004,GENEVA ,WHO .
- William D. Zimmerman Toni. M Ganzel. et al .Peripheral Hearing Loss following Head Trauma in Children Laryngoscope 103 January 1993 : pp 87-91
- Wilson GN .Gannon PR .Auditory and vestibular damage in 100 work -related head injuries .JLaryngol otol ;95: pp 1213-1219



Hearing Loss

Edited by Dr. Sadaf Naz

ISBN 978-953-51-0366-0

Hard cover, 406 pages

Publisher InTech

Published online 28, March, 2012

Published in print edition March, 2012

Authored by 17 international researchers and research teams, the book provides up-to-date insights on topics in five different research areas related to normal hearing and deafness. Techniques for assessment of hearing and the appropriateness of the Mongolian gerbil as a model for age-dependent hearing loss in humans are presented. Parental attitudes to childhood deafness and role of early intervention for better treatment of hearing loss are also discussed. Comprehensive details are provided on the role of different environmental insults including injuries in causing deafness. Additionally, many genes involved in hearing loss are reviewed and the genetics of recessively inherited moderate to severe and progressive deafness is covered for the first time. The book also details established and evolving therapies for treatment of deafness.

How to reference

In order to correctly reference this scholarly work, feel free to copy and paste the following:

Lingamdenne Paul Emerson (2012). Hearing Loss in Minor Head Injury, Hearing Loss, Dr. Sadaf Naz (Ed.), ISBN: 978-953-51-0366-0, InTech, Available from: <http://www.intechopen.com/books/hearing-loss/hearing-loss-in-minor-head-injury>

INTECH

open science | open minds

InTech Europe

University Campus STeP Ri
Slavka Krautzeka 83/A
51000 Rijeka, Croatia
Phone: +385 (51) 770 447
Fax: +385 (51) 686 166
www.intechopen.com

InTech China

Unit 405, Office Block, Hotel Equatorial Shanghai
No.65, Yan An Road (West), Shanghai, 200040, China
中国上海市延安西路65号上海国际贵都大饭店办公楼405单元
Phone: +86-21-62489820
Fax: +86-21-62489821