

# Teaching *NeuroImages*: Compression of the eighth cranial nerve causes vestibular paroxysmia

Michael Strupp, MD  
Sebastian von Stuckrad-  
Barre, MD  
Thomas Brandt, MD,  
FRCP  
Joerg Christian Tonn,  
MD

Correspondence to  
Dr. Strupp:  
Michael.Strupp@med.uni-  
muenchen.de

A 55-year-old man reported having recurrent spontaneous attacks of rotatory vertigo lasting 1–5 seconds and occurring up to 10 times daily and often associated with attacks of right ear tinnitus for more than 3 years. Caloric testing showed a right peripheral vestibular deficit. Cervical vestibular myogenic potentials showed impaired function of the right saccule. An audiogram was normal. MRI (figure, A and B) showed that the eighth nerve was in contact with the anterior inferior cerebellar artery. Vestibular paroxysmia was

diagnosed.<sup>1,2</sup> Carbamazepine resolved the symptoms but the patient discontinued it due to side effects. The symptoms recurred, and surgery was performed. Intraoperatively, compression of the eighth nerve was found (figure, C and D). He has had no further symptoms and takes no medication. These findings support the view that vascular compression of the root entry zone of the eighth cranial nerve can cause vestibular paroxysmia.

## AUTHOR CONTRIBUTIONS

M. Strupp: drafting the manuscript for content, including medical writing and idea for the case report. S. von Stuckrad-Barre: initial examination and treatment of the patient, drafting the manuscript for content. T. Brandt: discussion of the case, drafting the manuscript, including medical writing. J.C. Tonn: operation of the patient, taking micrographs, drafting the manuscript for content, including medical writing.

## ACKNOWLEDGMENT

The authors thank Dr. Jennifer Linn for evaluation of the MRI scans.

## STUDY FUNDING

Institutional (German Ministry of Education and Research [BMBF]) grant 01EO0901 to the IFB, German center for vertigo and balance disorders at the University of Munich, Campus Grosshadern, Germany.

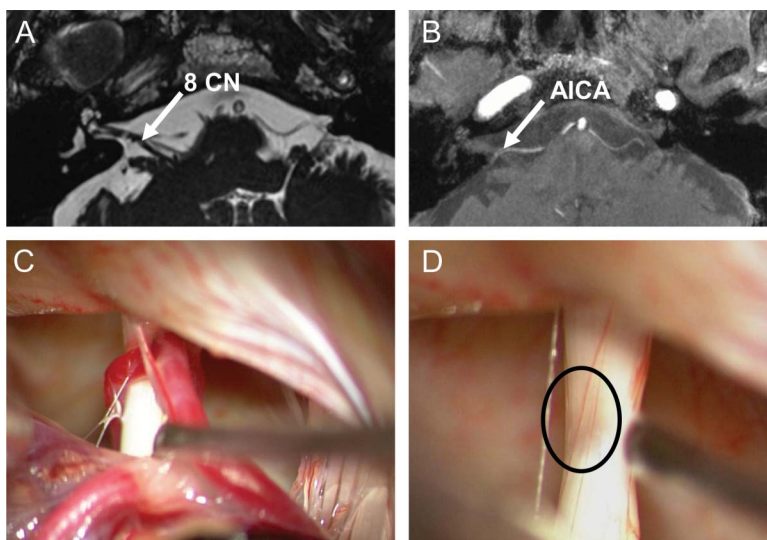
## DISCLOSURE

M. Strupp is supported by grants from BMBF no. 01EO0901 to the IFB<sup>LMU</sup> and the BMBF and DFG. S. von Stuckrad-Barre reports no disclosures. T. Brandt is supported by grants from BMBF no. 01EO0901 to the IFB<sup>LMU</sup>. J.C. Tonn reports no disclosures. Go to [Neurology.org](http://Neurology.org) for full disclosures.

## REFERENCES

1. Brandt T, Dieterich M. Vestibular paroxysmia: vascular compression of the eighth nerve? *Lancet* 1994;343:798–799.
2. Hufner K, Barresi D, Glaser M, et al. Vestibular paroxysmia: diagnostic features and medical treatment. *Neurology* 2008;71:1006–1014.

**Figure** MRI



Cranial MRI (A: constructive interference in steady-state sequence, B: time-of-flight) shows contact (arrows) between the right eighth cranial nerve (CN) and the anterior inferior cerebellar artery (AICA). Intraoperative micrographs demonstrate vascular contact (C) and considerable compression of the eighth nerve after removal of the arteries (D, circle).

# Neurology®

## Teaching *NeuroImages*: Compression of the eighth cranial nerve causes vestibular paroxysmia

Michael Strupp, Sebastian von Stuckrad-Barre, Thomas Brandt, et al.

*Neurology* 2013;80:e77

DOI 10.1212/WNL.0b013e318281cc2c

**This information is current as of February 11, 2013**

<b>Updated Information &amp; Services</b>	including high resolution figures, can be found at: <a href="http://n.neurology.org/content/80/7/e77.full.html">http://n.neurology.org/content/80/7/e77.full.html</a>
<b>References</b>	This article cites 2 articles, 1 of which you can access for free at: <a href="http://n.neurology.org/content/80/7/e77.full.html##ref-list-1">http://n.neurology.org/content/80/7/e77.full.html##ref-list-1</a>
<b>Subspecialty Collections</b>	This article, along with others on similar topics, appears in the following collection(s): <b>All Neurotology</b> <a href="http://n.neurology.org/cgi/collection/all_neurotology">http://n.neurology.org/cgi/collection/all_neurotology</a> <b>MRI</b> <a href="http://n.neurology.org/cgi/collection/mri">http://n.neurology.org/cgi/collection/mri</a> <b>Tinnitus</b> <a href="http://n.neurology.org/cgi/collection/tinnitus">http://n.neurology.org/cgi/collection/tinnitus</a> <b>Vertigo</b> <a href="http://n.neurology.org/cgi/collection/vertigo">http://n.neurology.org/cgi/collection/vertigo</a>
<b>Permissions &amp; Licensing</b>	Information about reproducing this article in parts (figures,tables) or in its entirety can be found online at: <a href="http://n.neurology.org/misc/about.xhtml#permissions">http://n.neurology.org/misc/about.xhtml#permissions</a>
<b>Reprints</b>	Information about ordering reprints can be found online: <a href="http://n.neurology.org/misc/addir.xhtml#reprintsus">http://n.neurology.org/misc/addir.xhtml#reprintsus</a>

*Neurology*® is the official journal of the American Academy of Neurology. Published continuously since 1951, it is now a weekly with 48 issues per year. Copyright © 2013 American Academy of Neurology. All rights reserved. Print ISSN: 0028-3878. Online ISSN: 1526-632X.

