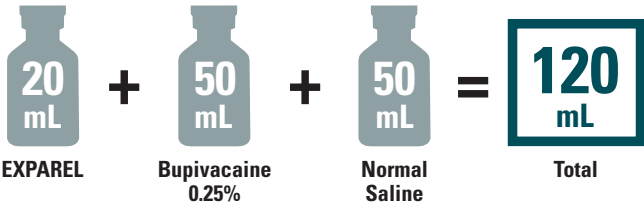


Administration Case Report With EXPAREL

This case report represents the individual experience of Dr Stan Dysart and is intended to demonstrate his methodology for using EXPAREL in a specific orthopedic procedure.

Pacira Pharmaceuticals, Inc., recognizes that there are alternative methodologies for administering local anesthetics, as well as individual patient considerations, when selecting the dose for a specific procedure.

EXPAREL is indicated for administration into the surgical site to produce postsurgical analgesia.

CASE INFORMATION	
Physician Name	Stan Dysart, MD
Affiliation	Pinnacle Orthopaedics/Wellstar Health System
Surgical Case Performed	Total knee arthroplasty (TKA)
Inpatient or Outpatient Procedure	Inpatient
PATIENT CHARACTERISTICS	
Gender	Male
Age	81 years
Patient History and Characteristics	Patient previously underwent a successful left TKA
Pathology	Patient has right knee osteoarthritis and is now undergoing a right TKA with an ERAS protocol
PROCEDURAL DETAILS	
Incision Size	15 cm
Preoperative Analgesics Used	AC block—20 mL of 0.25% bupivacaine with epinephrine
Intraoperative Analgesics Used	TIVA general—150-200 mcg/kg/min propofol titrated based on surgical needs; 50-100 mcg fentanyl as needed Periarticular injection with 20 mL EXPAREL and 50 mL 0.25% bupivacaine
Dose of EXPAREL and Total Volume Used	 <p>The diagram illustrates the total volume used for the procedure. It shows three syringes: one labeled '20 mL EXPAREL', one labeled '50 mL Bupivacaine 0.25%', and one labeled '50 mL Normal Saline'. These are summed together with plus signs and an equals sign to result in a final box labeled '120 mL Total'.</p>

AC, adductor canal; ERAS, enhanced recovery after surgery; TIVA, total intravenous anesthesia.

The recommended dose of EXPAREL is based on the size of the surgical site, the volume required to cover the area, and individual patient factors that may impact the safety of an amide local anesthetic. The maximum dose of EXPAREL should not exceed 266 mg.

EXPAREL can be administered undiluted (20 mL) or diluted to increase volume up to a total of 300 mL (final concentration of 0.89 mg/mL [ie, 1:14 dilution by volume]) with normal (0.9%) saline or lactated Ringer's solution.

Bupivacaine HCl may be administered immediately before EXPAREL or admixed in the same syringe, as long as the ratio of the milligram dose of bupivacaine HCl to EXPAREL does not exceed 1:2. Admixing may impact the pharmacokinetic and/or physiochemical properties of EXPAREL, and this effect is concentration dependent. The toxic effects of these drugs are additive and their administration should be used with caution, including monitoring for neurological and cardiovascular effects related to toxicity. Other than with bupivacaine, EXPAREL should not be admixed with other drugs prior to administration.

Please see Important Safety Information on the last page and refer to the accompanying full Prescribing Information for complete Dosage and Administration information before using EXPAREL.

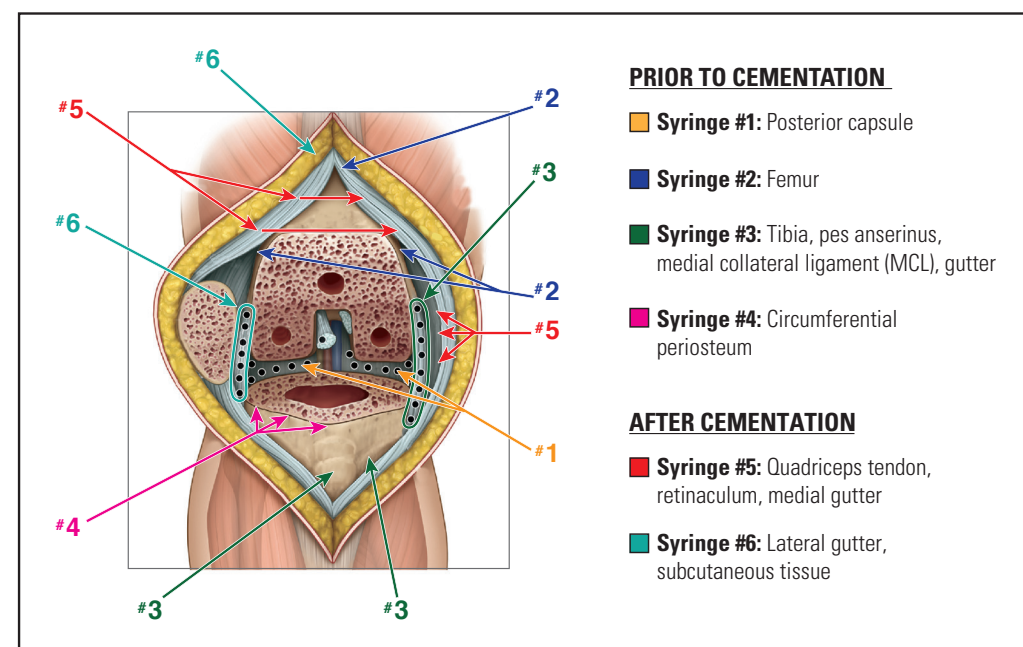
INFILTRATION NOTES

ASSESSED THE SIZE OF THE SURGICAL SITE AND DEPTH OF TISSUE, THEN PREPARED INJECTION MATERIALS ACCORDINGLY

In this procedure, Dr Dysart determined that a total volume of approximately 120 mL would be needed to cover the surgical site. He expanded 20 mL of EXPAREL with 50 mL of normal saline and admixed this solution with 50 mL of 0.25% bupivacaine. Dr Dysart added bupivacaine to provide short-term local analgesia in the postanesthesia care unit that overlapped with the long-term local analgesia provided by EXPAREL.

DIVIDED INJECTATE INTO SYRINGES WITH NEEDLE GAUGES APPROPRIATE FOR INFILTRATION (20- TO 25-GAUGE) AND PLANNED WHICH AREAS TO INFILTRATE WITH EACH INJECTION

For this procedure, Dr Dysart divided the injectate evenly into six 20-mL syringes using a 21-gauge needle and infiltrated as follows:



Adapted with permission; International Guidelines Center (guidelinecentral.com)—Erin Daniel, illustrator.

INFILTRATED AFTER THE BONY CUTS WERE PERFORMED

After completing the bony cuts, Dr Dysart inserted a laminar spreader between the cut femur and tibia, exposing the posterior capsule of the knee. He then proceeded with infiltrating the injectate as follows:

■ Syringe #1:

Medial and lateral infiltration of the posterior capsule

- Medial infiltration of posterior capsule with approximately 10 needle sticks to create a field block
- Lateral infiltration of posterior capsule with approximately 10 needle sticks

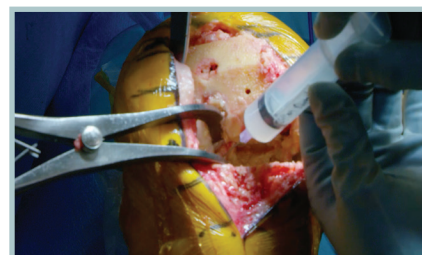


FIGURE 1. Posterior capsule



Before each injection, be sure to aspirate to minimize the risk of intravascular injection. Be sure not to inject too far laterally, and monitor the volume injected because of the proximity of the peroneal nerve.

INFILTRATION NOTES (cont)

■ Syringe #2:

Medial and lateral infiltration of femoral periosteal/synovial tissues and of suprapatellar tissue with 20 needle sticks of 1 mL to 1.5 mL per injection



Inject until a noticeable bubble forms. It is normal for there to be more dramatic swelling in this thick, fibrous layer than when soft tissue is infiltrated.

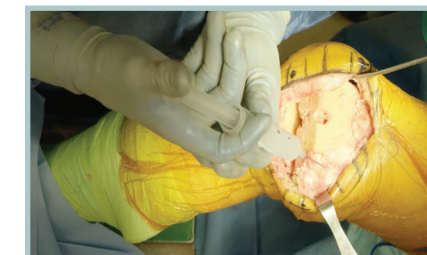


FIGURE 2. Femoral periosteal/synovial and suprapatellar tissues

■ Syringe #3:

Injection of fat pad, pes anserinus, MCL, and medial gutter, saturating the area

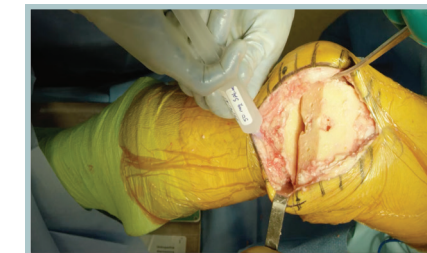

FIGURE 3. Fat pad, pes anserinus, MCL, and medial gutter

■ Syringe #4:

Medial and lateral infiltration of the circumferential periosteum of the tibia using 15 to 20 needle sticks

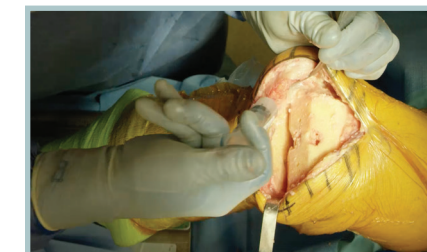

FIGURE 4. Circumferential periosteum of tibia

■ Syringe #5:

Injection of the synovial tissue beneath the quadriceps tendon and the retinacular tissue medially from the femur to the tibia

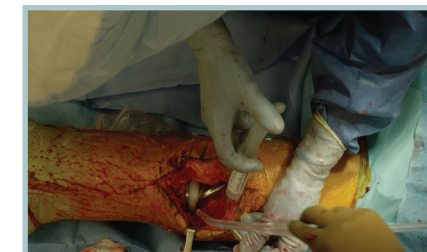

FIGURE 5. Synovial tissue (quadriceps) and medial retinacular tissue (femur to tibia)

■ Syringe #6:

Injection of the lateral gutter and the lateral retinacular tissue from the femur to the tibia. Residual volume is used in the subcutaneous tissue medially and laterally. There will likely be swelling of the tissue from fluid volume

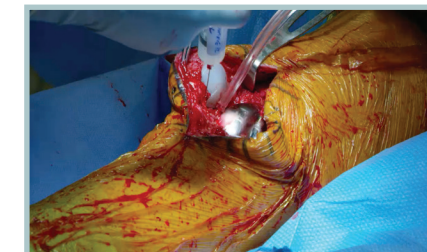

FIGURE 6. Lateral gutter and retinacular tissue (femur to tibia)



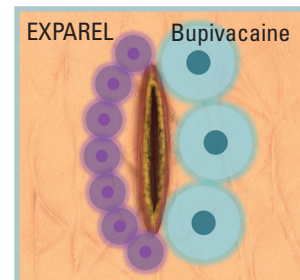
When infiltrating, stay in the tissue to reduce the amount of extravasation.

Please see Important Safety Information on the last page and refer to the accompanying full Prescribing Information for complete Dosage and Administration information before using EXPAREL.

INFILTRATION NOTES (cont)

PROPER TECHNIQUE IS CRUCIAL FOR ANALGESIC COVERAGE

When infiltrating EXPAREL, Dr Dysart makes sure to infiltrate below the fascia, above the fascia, and into the subcutaneous tissue using a moving needle technique. With a moving needle technique, the injections are spread in a rapid and precise fan-like pattern to maximize the number of injection areas. The tissues are infiltrated as the needle is advanced and withdrawn to maximize the coverage area. This technique should be systematically and meticulously repeated with each subsequent injection site, and the next site should overlap with the prior infiltrated area to maximize effect.



Watch Dr Dysart infiltrate with **EXPAREL** at www.EXPAREL.com

Important Safety Information

EXPAREL is contraindicated in obstetrical paracervical block anesthesia.

In clinical trials, the most common adverse reactions (incidence $\geq 10\%$) following EXPAREL administration were nausea, constipation, and vomiting.

EXPAREL is not recommended to be used in the following patient population: patients <18 years old and/or pregnant patients.

Because amide-type local anesthetics, such as bupivacaine, are metabolized by the liver, EXPAREL should be used cautiously in patients with hepatic disease. Patients with severe hepatic disease, because of their inability to metabolize local anesthetics normally, are at a greater risk of developing toxic plasma concentrations.

Warnings and Precautions Specific to EXPAREL

EXPAREL is not recommended for the following types or routes of administration: epidural, intrathecal, regional nerve blocks, or intravascular or intra-articular use.

Non-bupivacaine-based local anesthetics, including lidocaine, may cause an immediate release of bupivacaine from EXPAREL if administered together locally. The administration of EXPAREL may follow the administration of lidocaine after a delay of 20 minutes or more. Formulations of bupivacaine other than EXPAREL should not be administered within 96 hours following administration of EXPAREL.

Warnings and Precautions for Bupivacaine-Containing Products

Central Nervous System (CNS) Reactions: There have been reports of adverse neurologic reactions with the use of local anesthetics. These include persistent anesthesia and paresthesias. CNS reactions are characterized by excitation and/or depression.

Cardiovascular System Reactions: Toxic blood concentrations depress cardiac conductivity and excitability which may lead to dysrhythmias sometimes leading to death.

Allergic Reactions: Allergic-type reactions (eg, anaphylaxis and angioedema) are rare and may occur as a result of hypersensitivity to the local anesthetic or to other formulation ingredients.

Chondrolysis: There have been reports of chondrolysis (mostly in the shoulder joint) following intra-articular infusion of local anesthetics, which is an unapproved use.

Disclosure: Dr Dysart is a paid consultant for Pacira Pharmaceuticals, Inc.