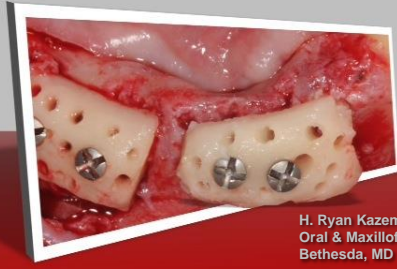
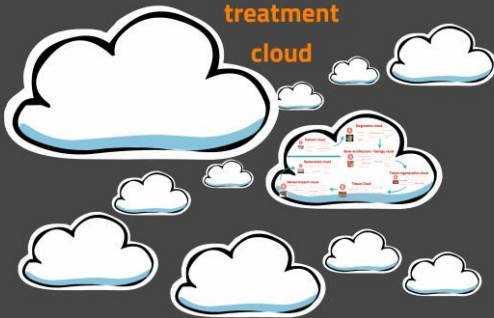

Efficiencies in Block Harvest & Fixation

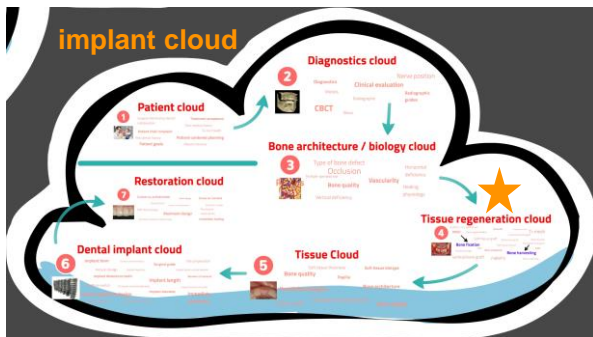


H. Ryan Kazemi, DMD
Oral & Maxillofacial Surgery
Bethesda, MD

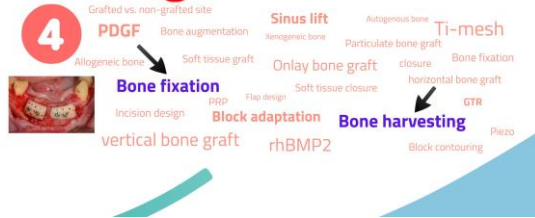treatment cloud



implant cloud



Tissue regeneration cloud





harvest

- Donor sites
 - Ramus
 - Chin
 - Tubercity
- Incision design
- Measure block
- Outline block
- Osteotomy
- Block removal
- Particulate harvest
- Hemostasis
- Closure

fixation

- Incision design
- Defect measure
- Visualize block form
- Recipient preparation
- Block adaptation
- Screw types
- Rigid fixation
- Block recontouring
- Perforations
- Gap fill
- Growth factors
- Closure



block graft

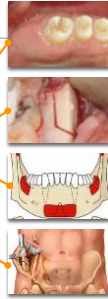
- available bone?
- stability?
- implant survival?

block graft

available bone?
stability?
implant survival?

ramus
good volume
low morbidity

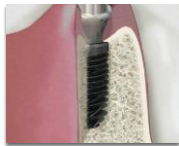donor site	bone volume
tubercity	2-5 cc
chin / ramus	5-10 cc
autogenous collection	< 1cc
iliac crest	
- anterior	30-40 cc
- posterior	70-140 cc
- trephine	10-20 cc



block graft

available bone?
stability?
implant survival?

long-term block graft stability in thin periodontal biotype patients
97% of augmented width maintained after 3.3 years
verdugo et al, Int j oral maxillofac implants 2011; 26:325-332

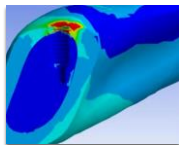


osseointegration
critical to preservation of grafted bone

block graft

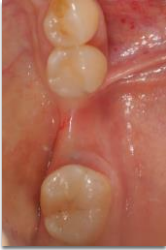available bone?
stability?
implant survival?

the potential of the horizontal ramus of the mandible as a donor site for block and particulate grafts in pre-implant surgery
99% implant survival rate
soehardi a, et al. ijomi 2009 nov; 38 (11)



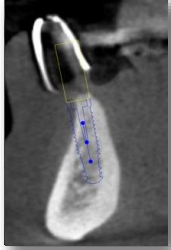
greatest stress of implant at neck / crest
+
increased bone density of block graft (D1)
=
distinct biomechanical advantage

clinical recipient cbct

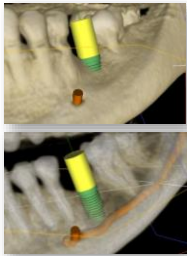


<< deficiency type
defect size
soft tissue biotype
inter-septal bone
vestibular depth

defect form
defect size
anatomy
>>



classification

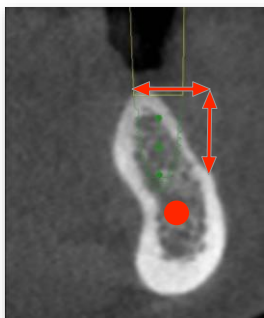


siebert
horizontal: I vertical: II mixed: III

allen
vertical: A horizontal: B mixed: C

Cologne
Orientation, graft needs, relation of graft to defect

recipient site



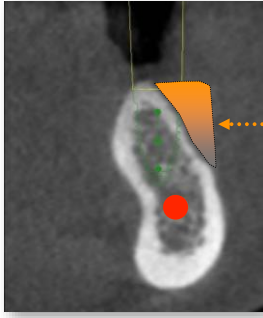
width

height

IAN



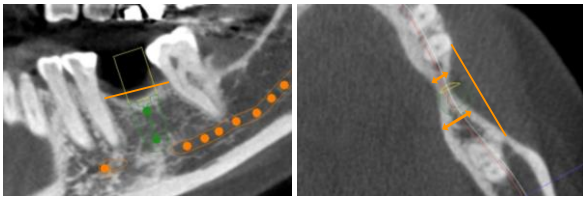
recipient site



shape of ideal block graft

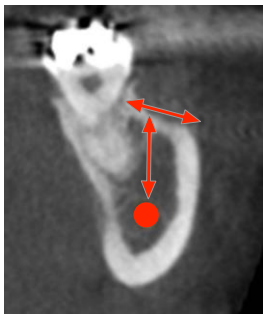


recipient site





donor site




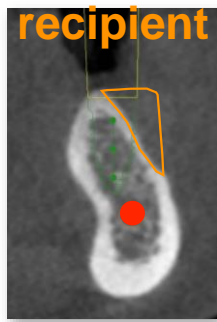
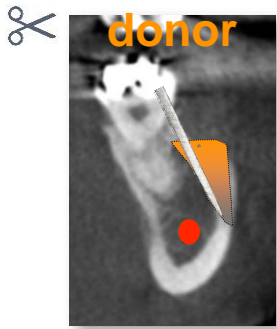
width

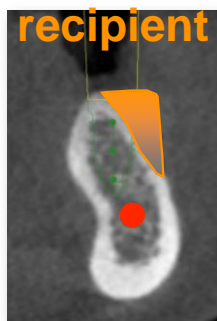
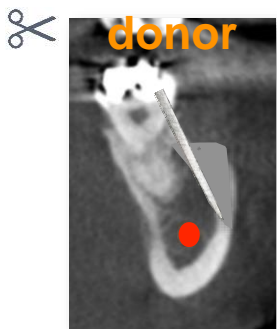
height

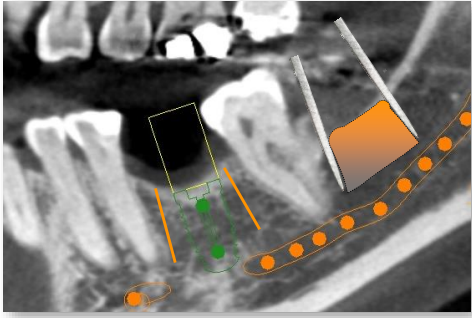
IAN

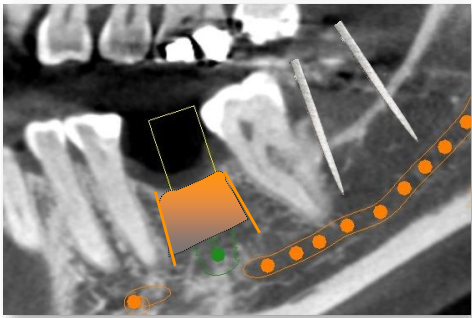
✂ **planning block form**

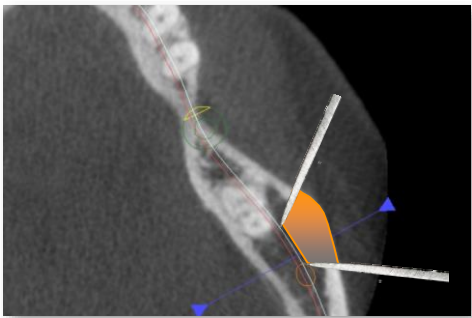


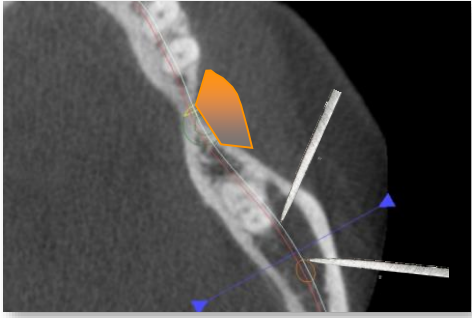












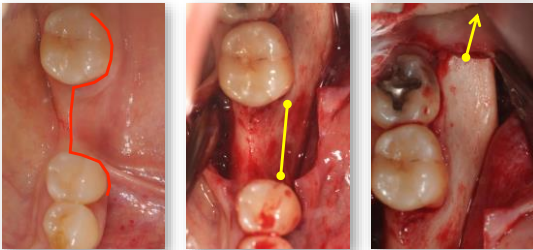
surgical order

- ①
draw
blood
for prgf
- ②
open
recipient
site
- ③
open
donor site
& harvest
block
- ④
fixate
block to
recipient





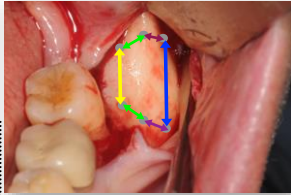
incision & flap



✂ block harvest

1 measure

- » sagittal
- » medio-lateral
- » vertical
- » caudal

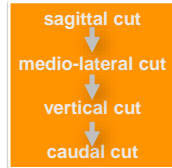
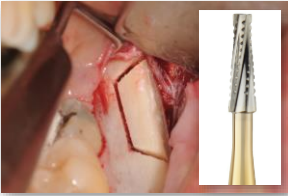


over extension

sagittal, vertical, & caudal >> 10%
 medio-lateral >> 20%

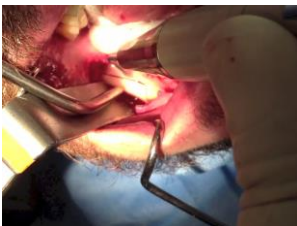✂ block harvest

2 outline

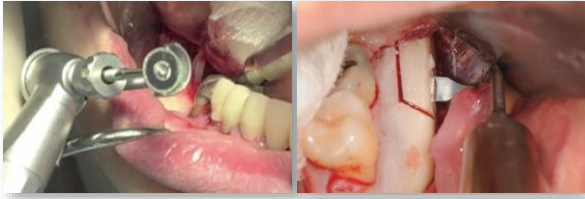

✂ block harvest

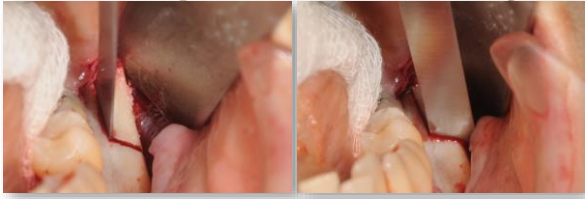2 outline



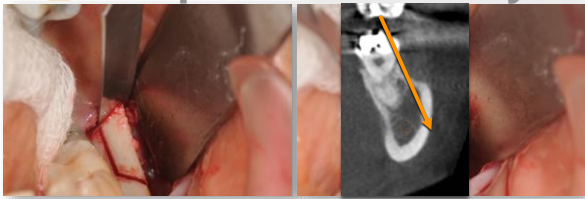
✂ **block harvest**
② outline- caudal



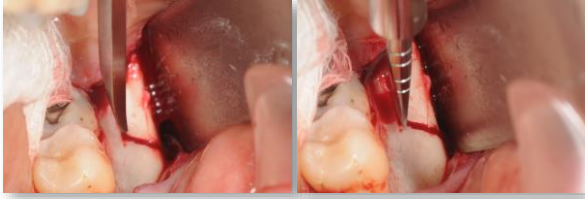✂ **block harvest**
③ complete osteotomy



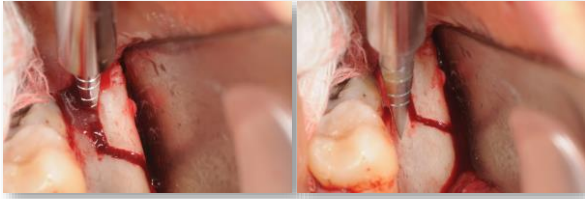✂ **block harvest**
③ complete osteotomy



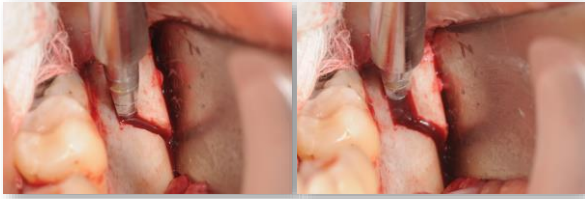✂ **block harvest**
4split



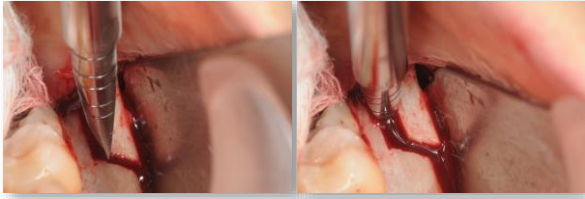✂ **block harvest**
4split



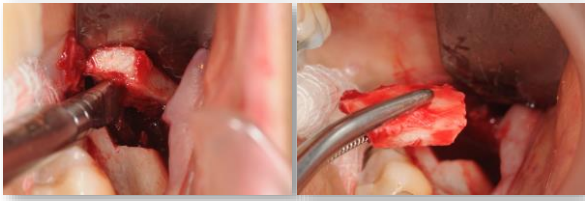
✂ **block harvest**
4split



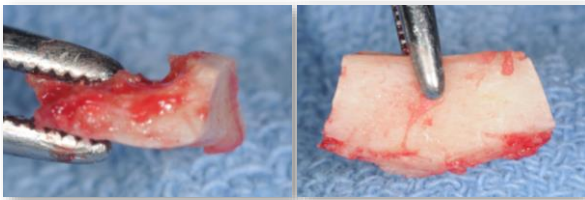
✂ **block harvest**
4 split

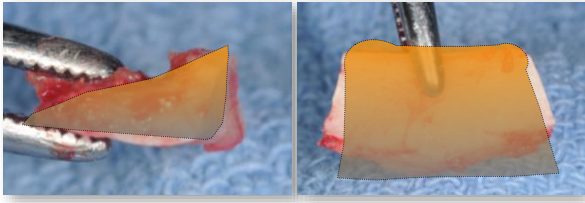


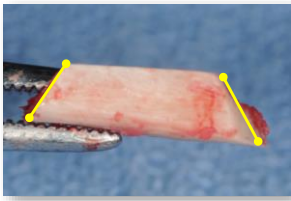
✂ **block harvest**
5 block fracture



✂







storage

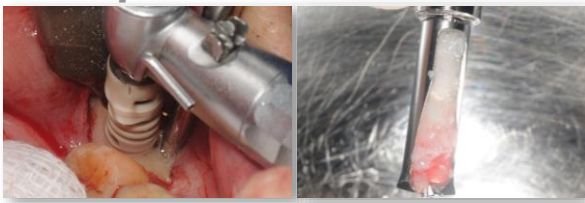- moist gauze
- prgf



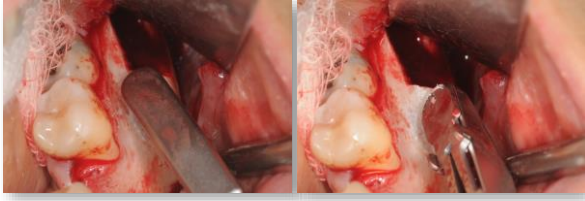NO saline immersion



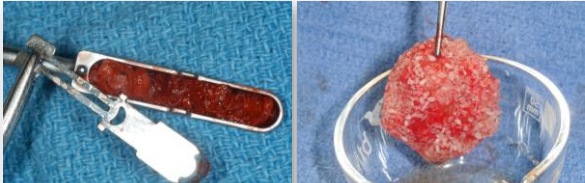
particulate harvest trephine burs



✂ **particulate harvest**
bone scraper

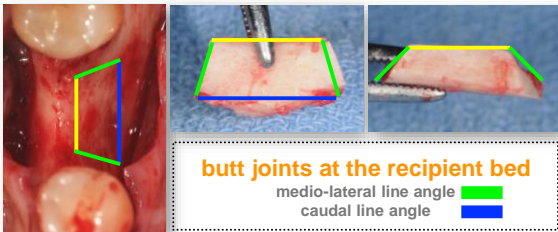


✂ **particulate harvest**
bone scraper

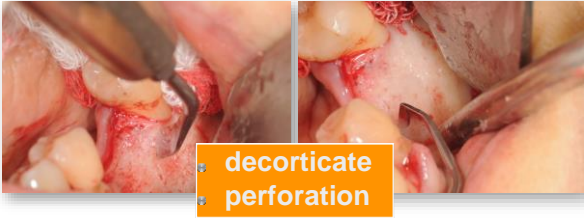

autogenous bone + mineralized bone + prgf → bone complex

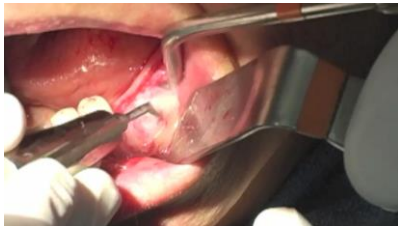📌 **prepare recipient**
maximal interface & stability



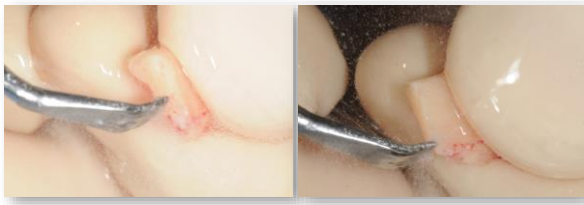
📌 prepare recipient
maximal interface & stability



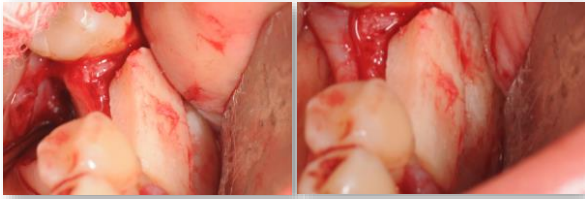
📌 prepare recipient
maximal interface & stability



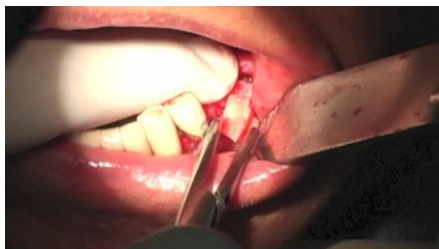✂️ modify block



adapt block



adapt block



fixation

AO - Arbeitsgemeinschaft für Osteosynthesefragen

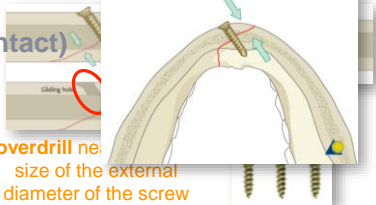
compression >> lag technique lag screw

primary bone healing

- reduction (contact)
- rigid fixation
- compression

- decreases gap
- increases stability

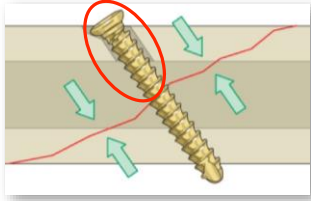
overdrill ne: size of the external diameter of the screw



screw

stability and compression of block / recipient

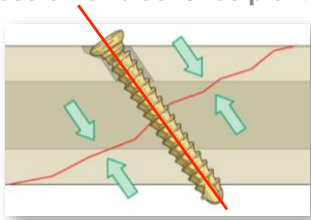
- **overdrill the block hole**
- screw perpendicular to 'fracture site'
- countersink to create a platform
- select the right screw length
- two-point fixation



screw

stability and compression of block / recipient

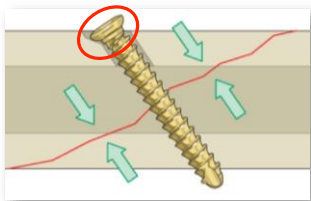
- overdrill the block hole
- **screw perpendicular to 'fracture site'**
- countersink to create a platform
- select the right screw length
- two-point fixation



screw

stability and compression of block / recipient

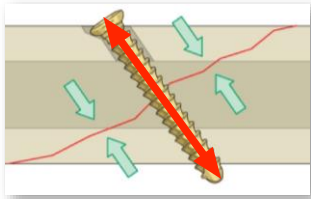
- overdrill the block hole
- screw perpendicular to 'fracture site'
- **countersink to create a platform**
- select the right screw length
- two-point fixation



screw

stability and compression of block / recipient

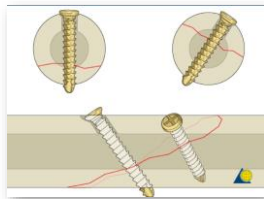
- overdrill the block hole
- screw perpendicular to 'fracture site'
- countersink to create a platform
- **select the right screw length**
- two-point fixation



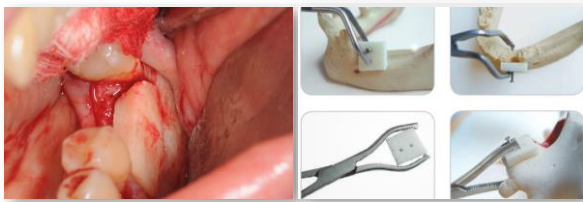screw

stability and compression of block / recipient


- overdrill the block hole
- screw perpendicular to 'fracture site'
- countersink to create a platform
- select the right screw length
- **two-point fixation**



fixation hold block

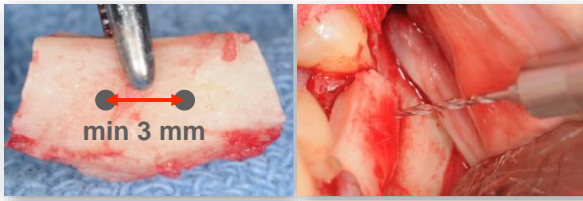


📌 fixation- 2 vs 3 point

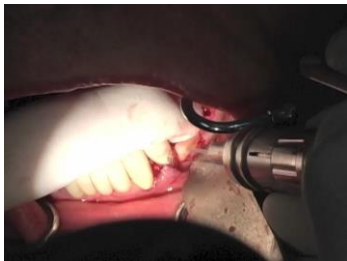

prevent stress fracture of block

📌 fixation-2 first drill



📌 fixation-2 first drill



fixation-3 over-drill

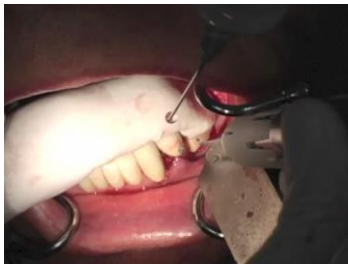

702 bur
tip 1.1 mm
head 1.6 mm
length 4.5 mm

701 bur
tip 0.8 mm
head 1.2 mm
length 3.8 mm

- lag technique
- easy rotation of screw without block displacement

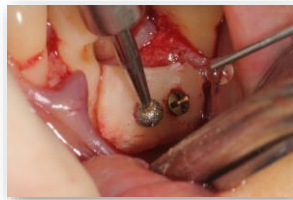
fixation-3 over-drill



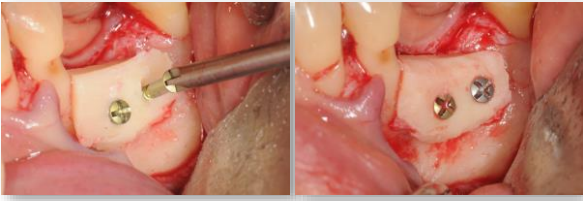
fixation-4 countersink



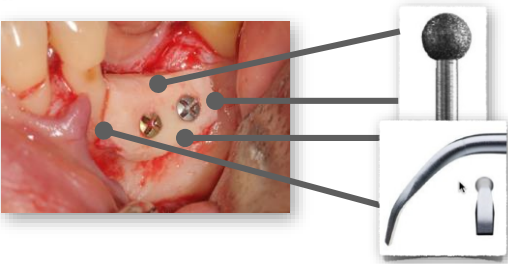
8 round diamond
diameter 3 mm



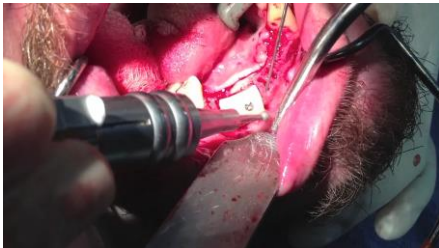
fixation-5 screw



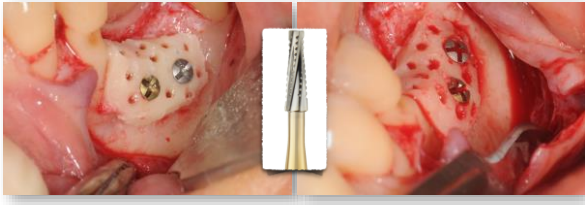fixation-6 osteoplasty



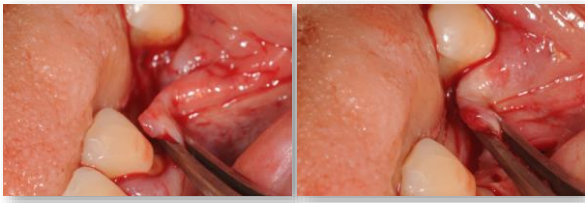
fixation-6 osteoplasty



📌 fixation-7 perforations

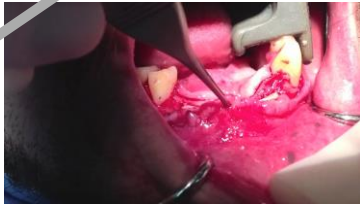

📌 flap release- tensionless

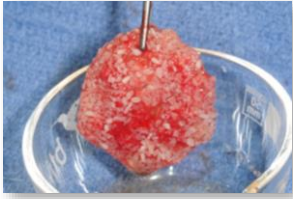


📌 flap release- tensionless

- complete flap elevation
- periosteal scoring
- supra-periosteal dissection

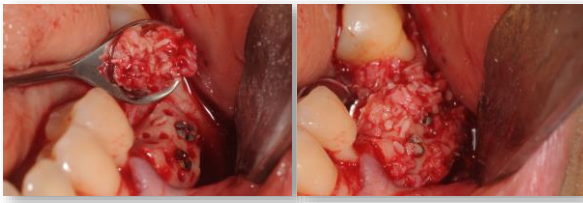


bone gap fill

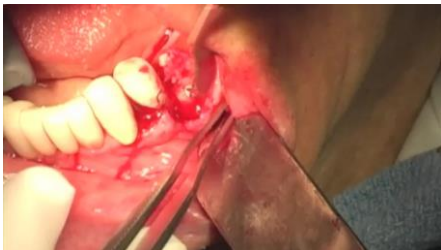

- prgf
- autogenous
- particulate bone
- mineralized
- allogenic bone to expand

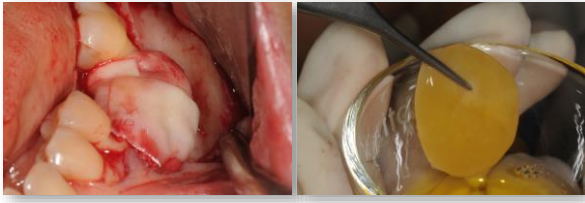bone gap fill



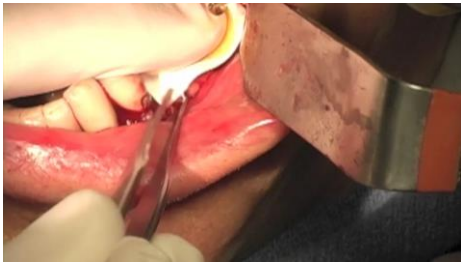bone gap fill



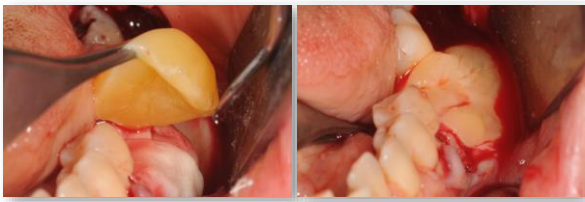membrane



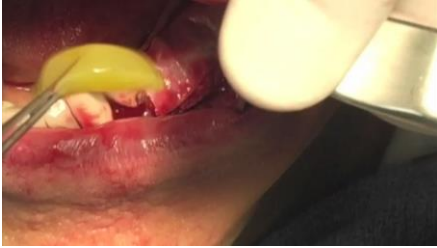membrane



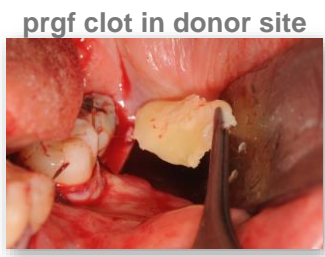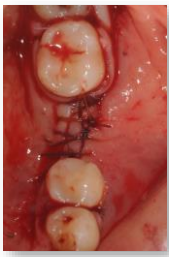prgf membrane



prgf membrane

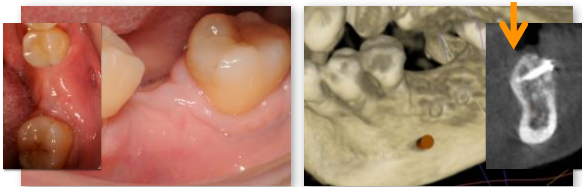


tension-less closure

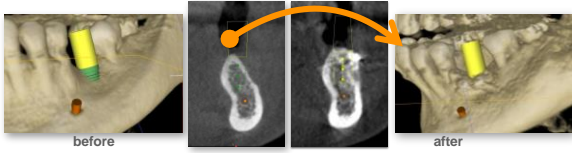


prgf clot in donor site

implant planning



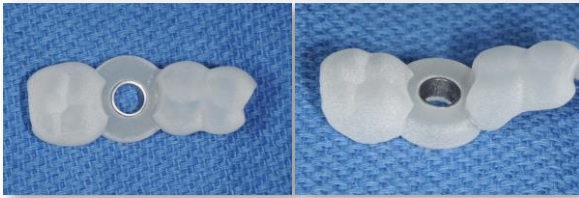implant planning



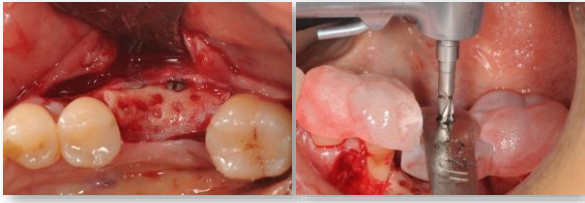
Implant Placement



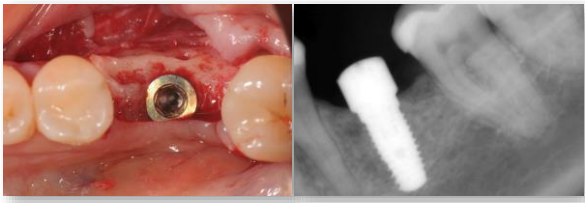Implant Placement



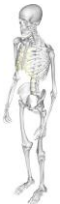Implant Placement

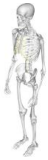

Implant Placement



cad / cam
customized
bone
blocks





pre-design & prefabricate an ideal block
↓
simplify
improve adaptation
decrease operative time

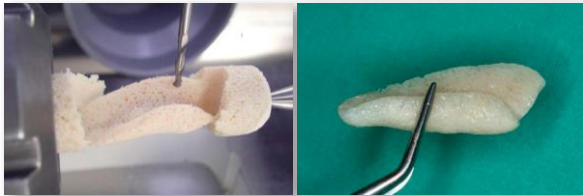


cad allografts

Ridge Augmentation Using Customized Allogenic Bone Blocks: Proof of Concept and Histological Findings
Customized Allogenic Bone Blocks
Schlee, M, Rothamel, D:
Implant Dent 2013; 0: 1-7

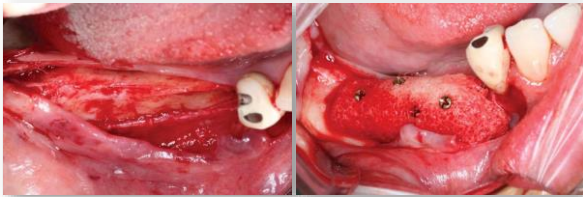
CBCT
↓
3-D planning software
↓
defect drawn on 3-D surface
↓
3-D information converted
↓
CNC programming
↓
graft milled out of a single block

cad allografts



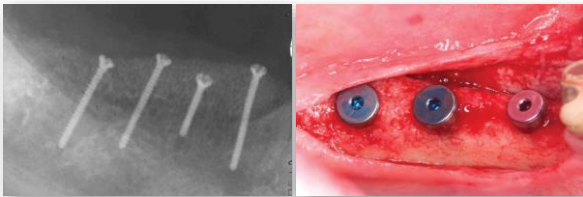
Ridge Augmentation Using Customized Allogenic Bone Blocks: Proof of Concept and Histological Findings
Schlee, M, Rothamel, D:Implant Dent 2013; 0: 1-7

cad allografts



Ridge Augmentation Using Customized Allogenic Bone Blocks: Proof of Concept and Histological Findings
Schlee, M, Rothamel, D. Implant Dent 2013; 0: 1-7

cad allografts

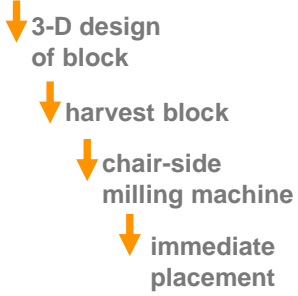


Ridge Augmentation Using Customized Allogenic Bone Blocks: Proof of Concept and Histological Findings
Schlee, M, Rothamel, D. Implant Dent 2013; 0: 1-7

cad /cam
customized
autogenous
bone
blocks

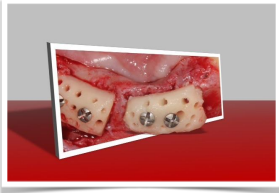

CBCT



- ? bone handling
- ? sterility
- ? cellular response
- ? cost

stay tuned

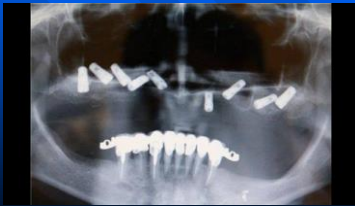

Kazemi
ORAL SURGERY &
DENTAL IMPLANTS
www.facialart.com

V. Broumand, DMD, MD

Assistant Professor of Surgery
Director of Resident Medical Education
University of Miami
Miller School of Medicine

Complications during surgery,
immediate post operative and
long term for the harvest site

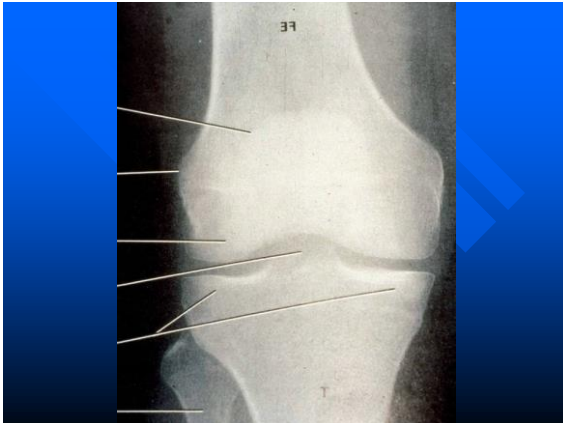


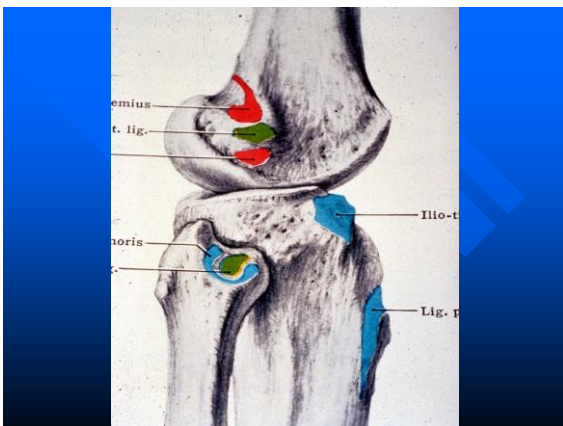
Autogenous Bone Harvesting For Ridge Augmentation

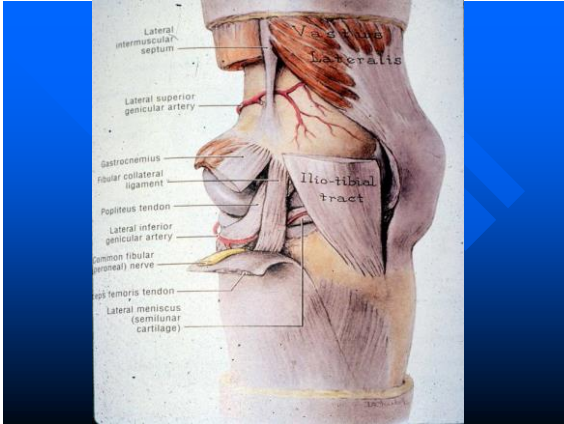
1. Tibia
2. Symphysis
3. Ramus
4. Maxillary Tuberosity

Tibia Bone Harvest

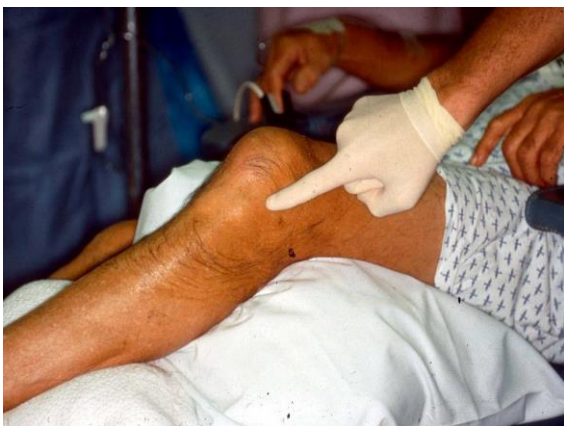An Office Procedure

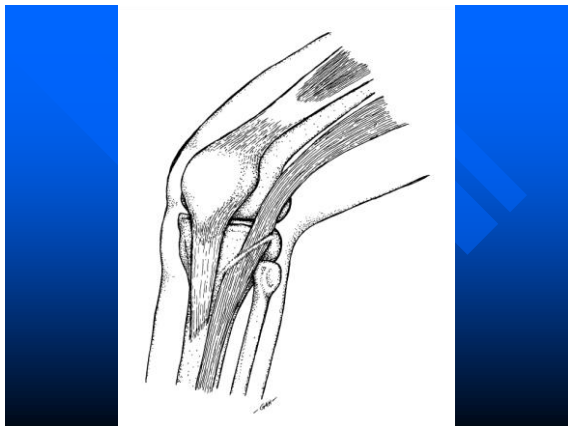


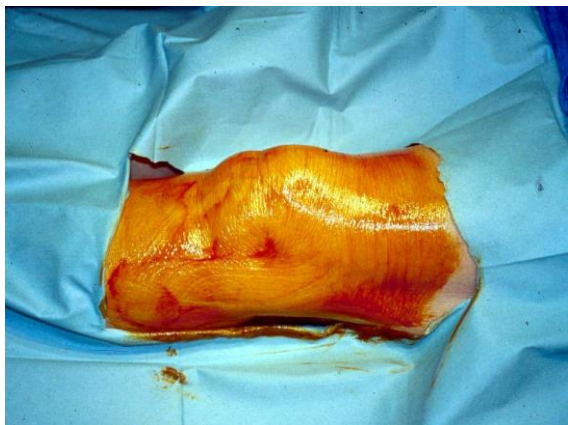

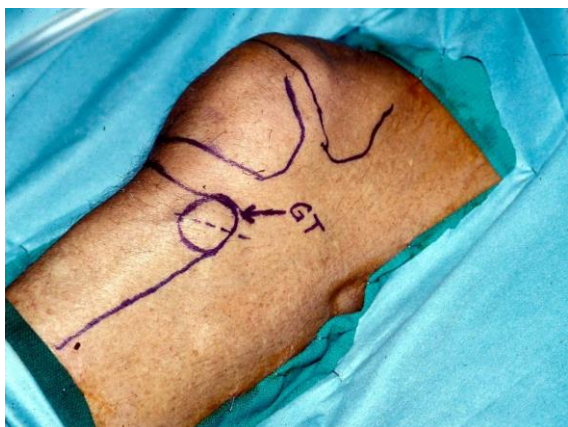


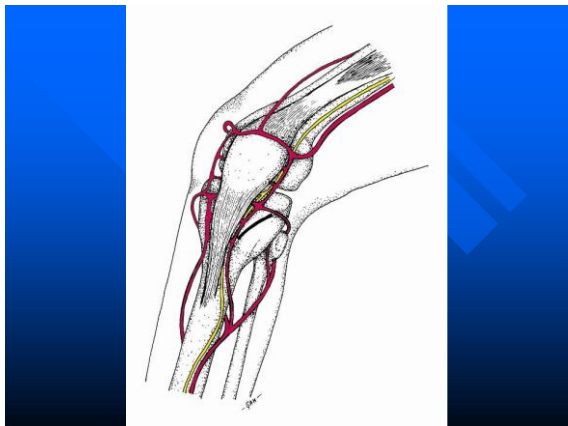
Gerdy's Tubercle

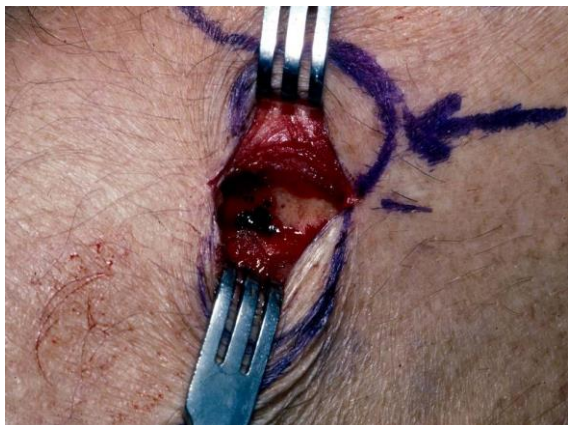

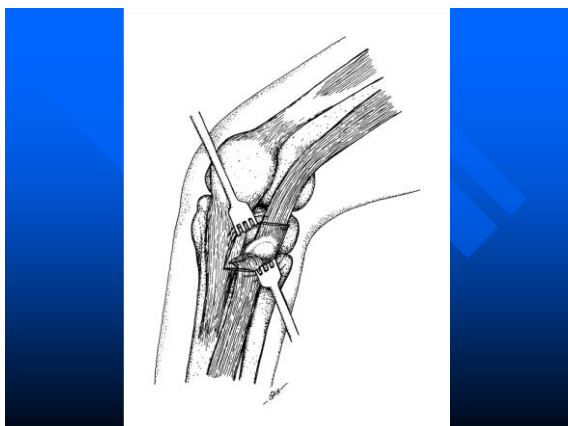


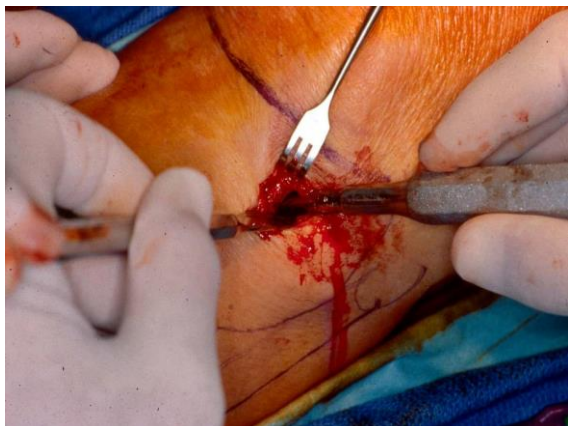



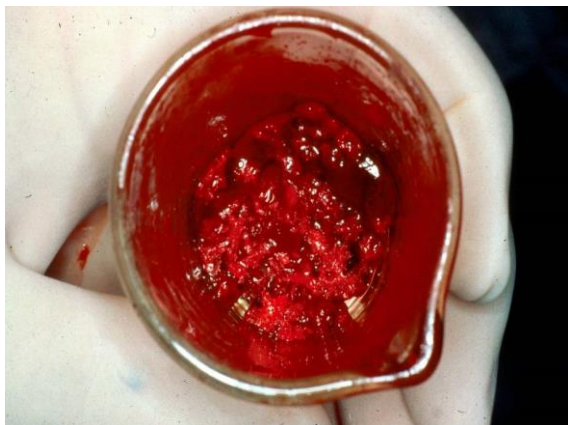


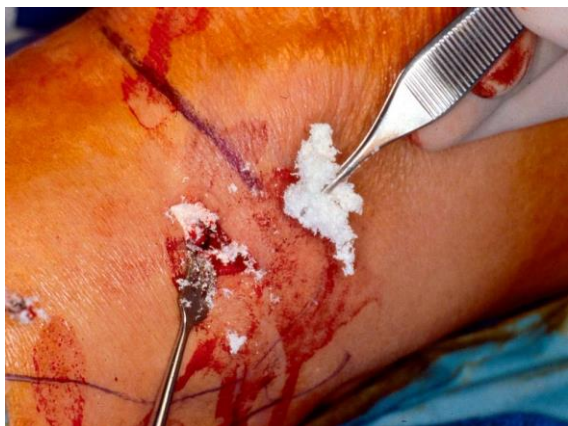


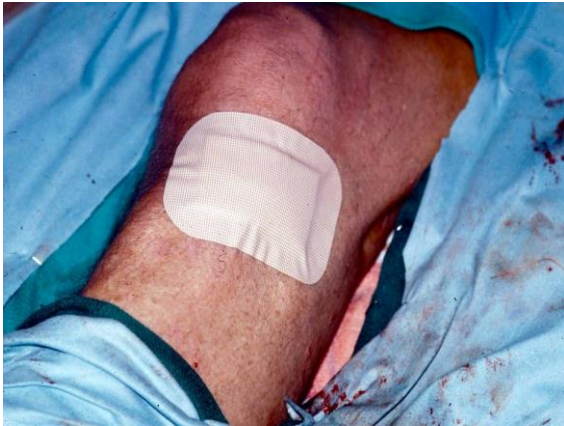






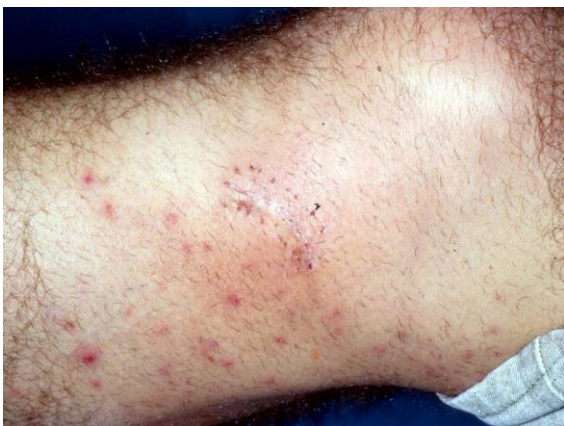

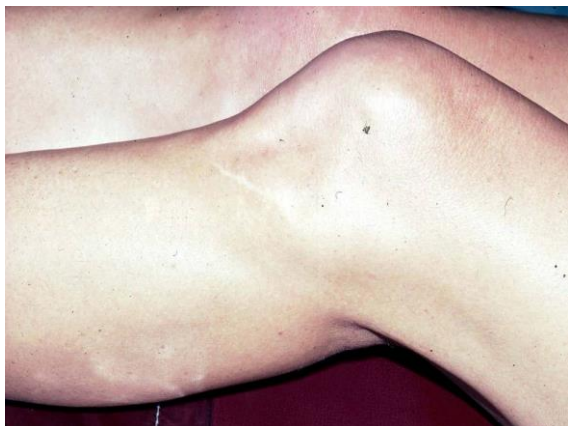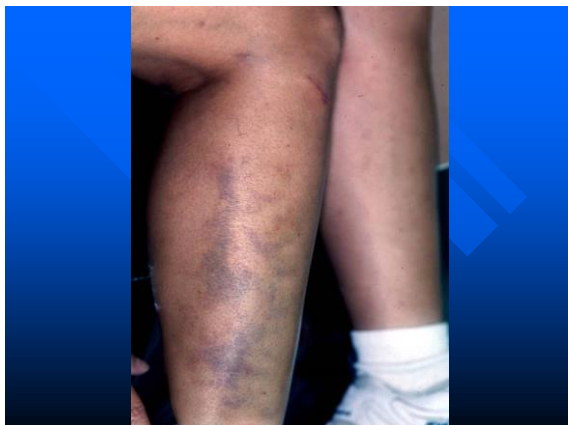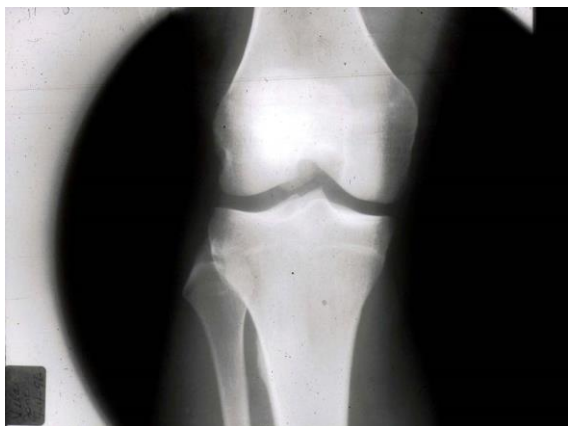Post Op Instructions

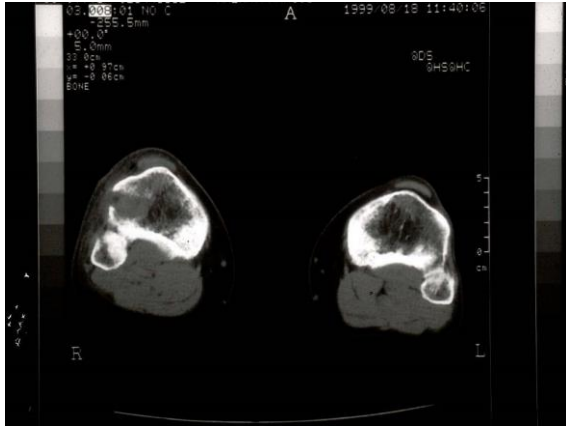
1. Normal activity
2. No sports, running, or stairs for 6 weeks
3. Ice x 48 hours
4. Elevate leg at night











Tibial Bone Harvest In Office Setting

571 consecutive tibial bone
graft donor sites were
assessed for intraoperative
and postoperative morbidity.

Results

Harvested bone
quantities ranged from
11 ml to 40 ml with a
mean of 22.4 ml.

Morbidity

Blood loss range from 25 ml to 122 ml with a mean of 45 ml.

There were no intraoperative misadventures such as knee joint entrance, cartilage damage, or affect to patellar tendon.

Potential Complications Tibia Harvest

1. Ecchymosis
2. Dehiscence
3. Hematoma
4. Entering the knee joint
5. Scar

Morbidity Parameters

Fractures	0	(0%)
Gait Disturbance	0	(0%)
Knee Joint Entrance	0	(0%)
Knee Joint Complaints	0	(0%)
Hematoma	4	(0.7%)
Dehiscence	12	(2.1%)
Objectionable Scar	9	(1.6%)
Ecchymosis	44	(7.7%)

Tibial Harvest Complications

O’Keefe in 1991 – 230 grafts for orthopedic reconstruction in operating room setting.
Complication rate 1.4%.

Tibial Harvest Complications

Marx, Schalit, Bartholomew
1997 – 2004
571 grafts in office setting for oral and maxillofacial surgery
Complication rate 1.1%

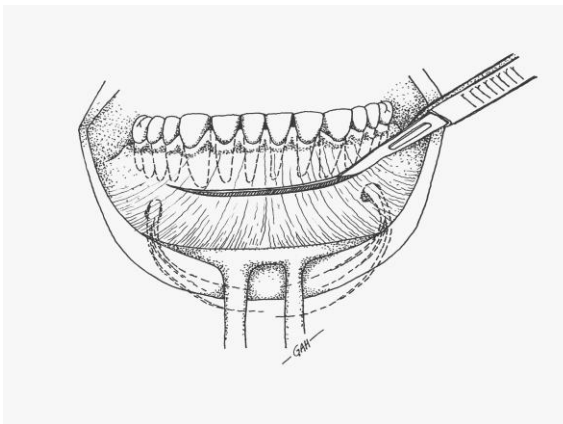
Tibia Bone Harvest Advantages

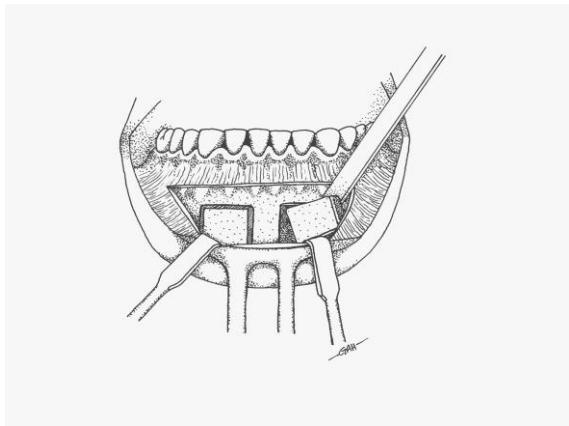
1. Minimal morbidity
2. Good quality bone (note, slightly less than ilium)
3. Office or operating room procedure
4. Straightforward anatomy and technique
5. Requires minimal instrumentation
6. Can be accomplished under IV sedation

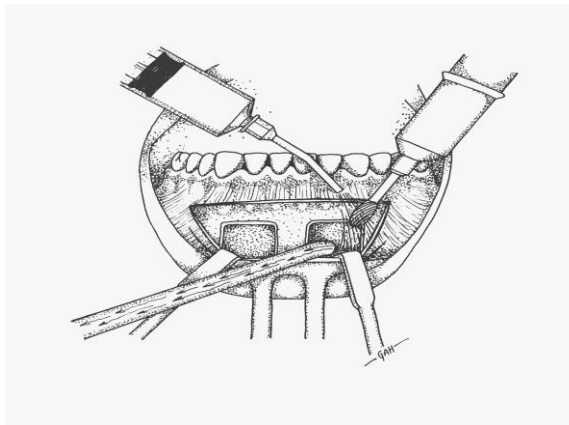
Tibia Bone Harvest Disadvantages

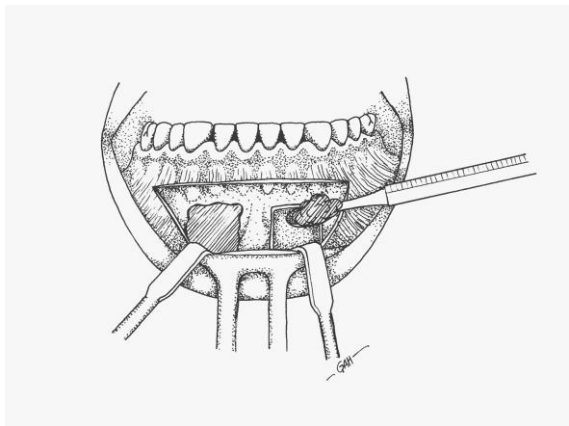
1. Limited to 30 cc of bone
2. Edema about ankles
3. No block graft capability

Symphysis Graft Harvest





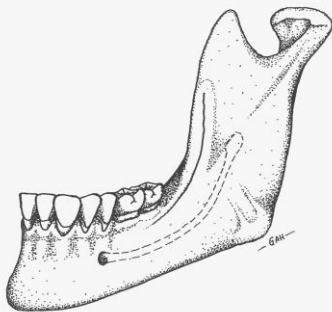


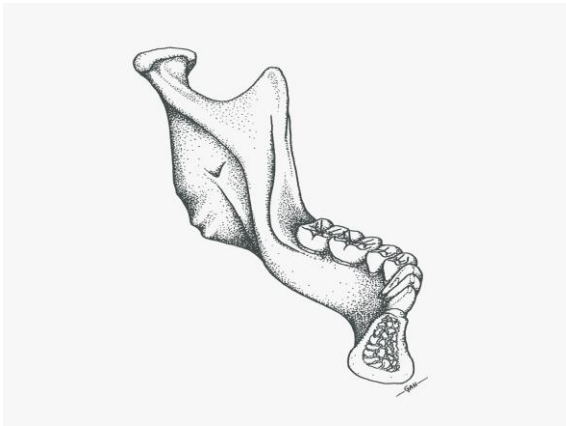


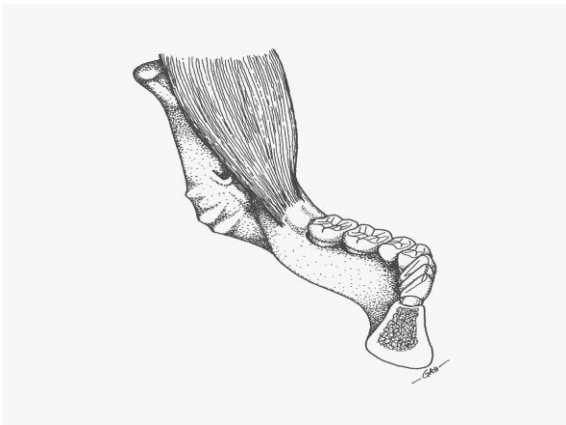Potential Complications Symphysis Harvest

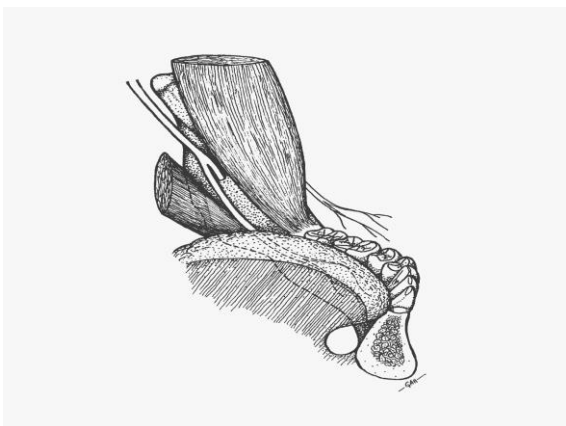
1. Parasthesia *
2. Fracture
3. Tooth root damage
4. Change in lip position

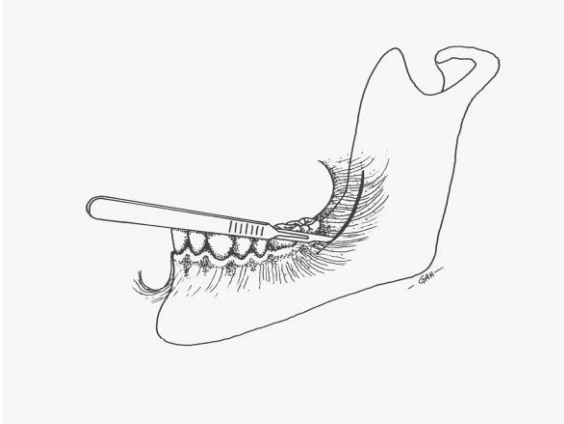
Ramus Graft Harvest

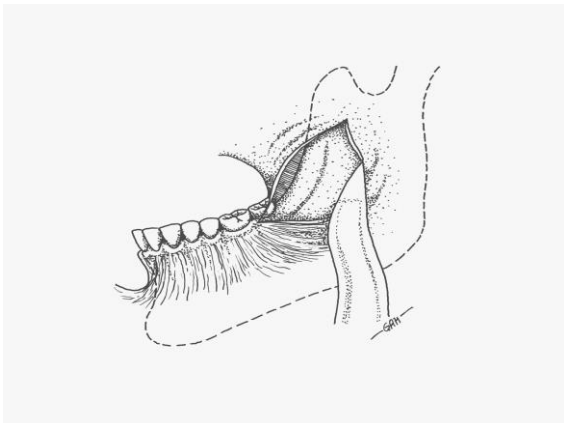


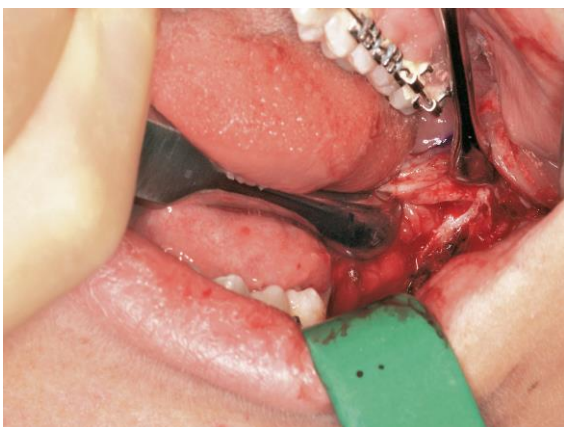


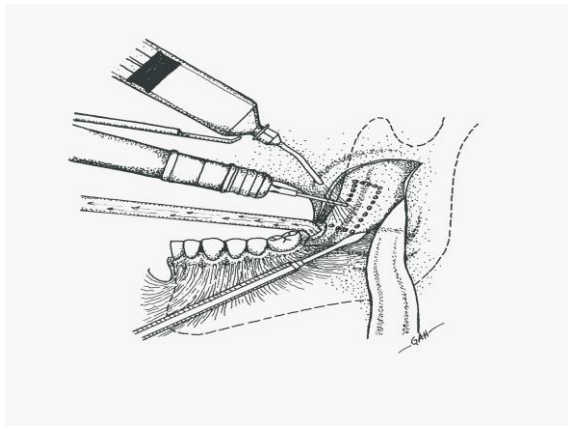


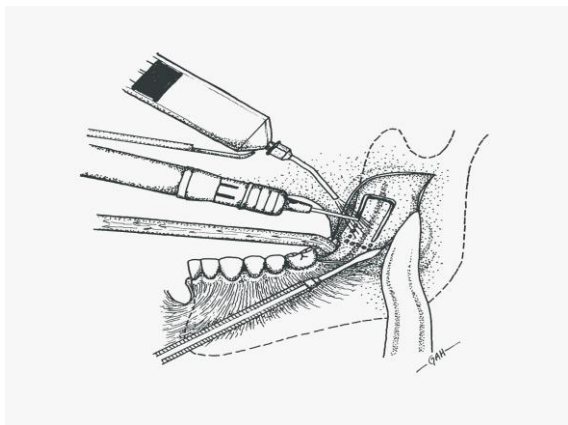


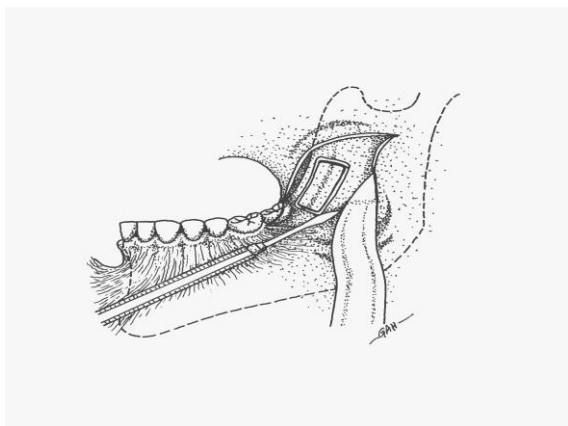


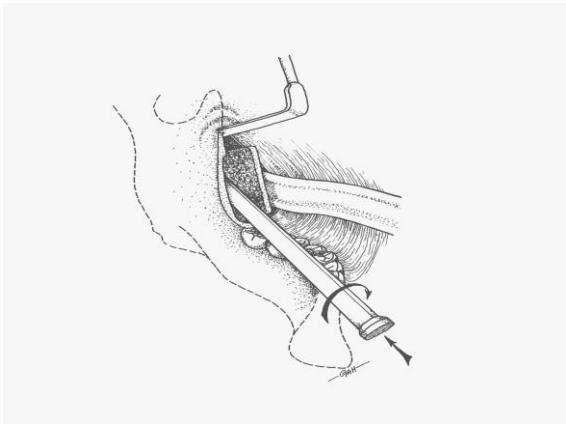


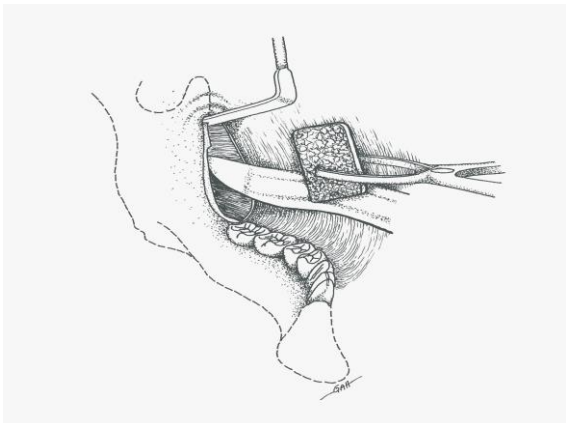


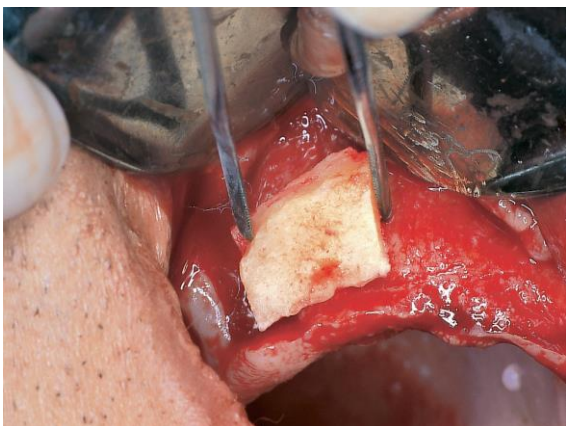

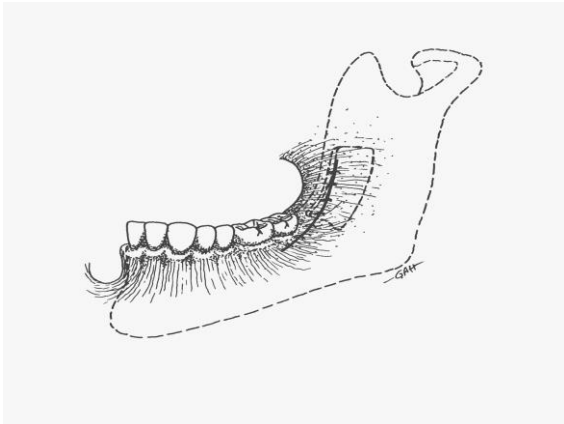






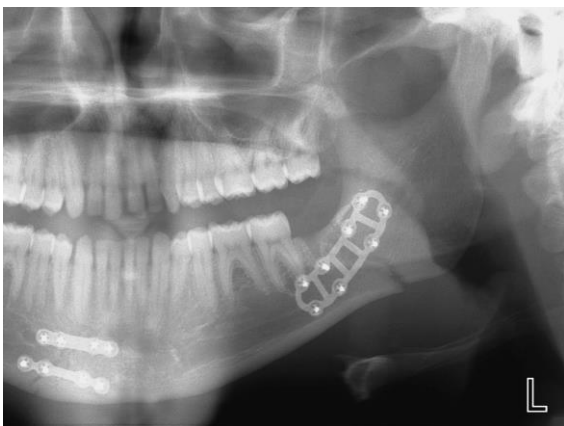


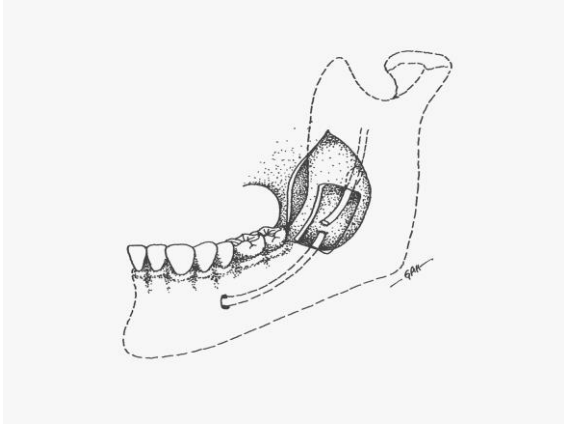


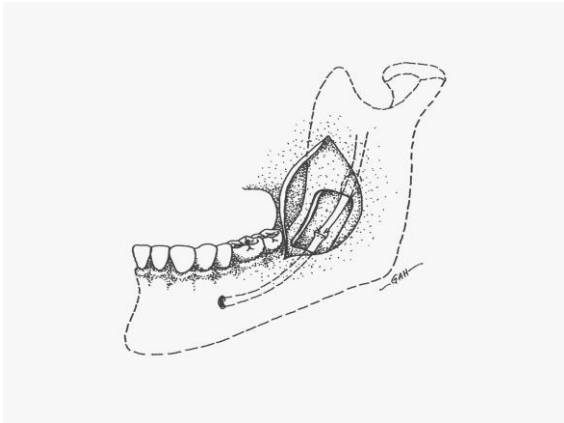


Potential Complications Ramus Harvest

1. Parasthesia *
2. Fracture
3. Nerve transection
4. Tooth root damage
5. Hematoma



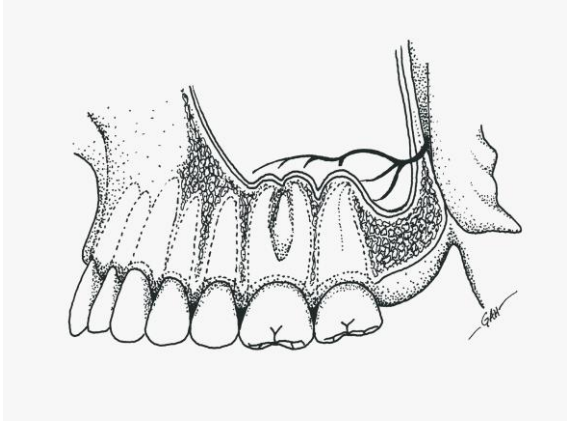


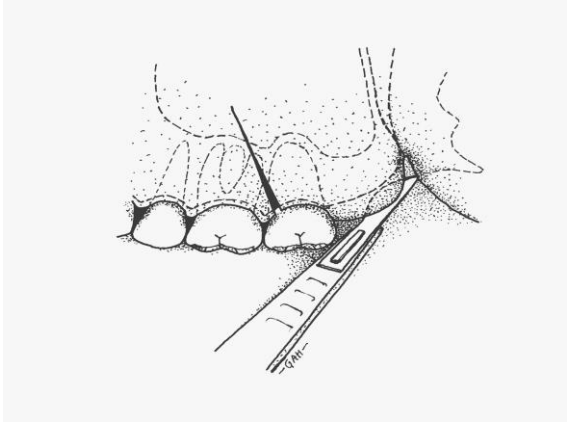


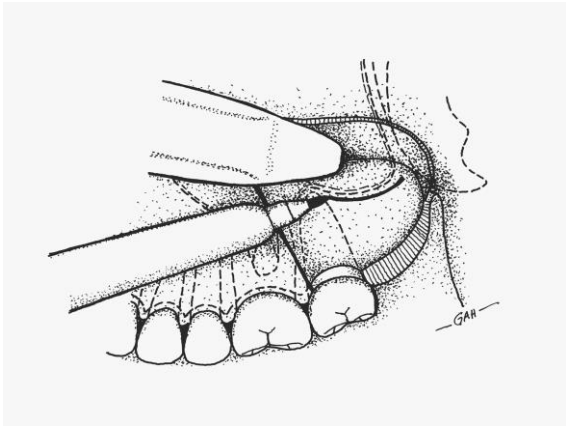
Complication
Paresthesia – Nerve Injury

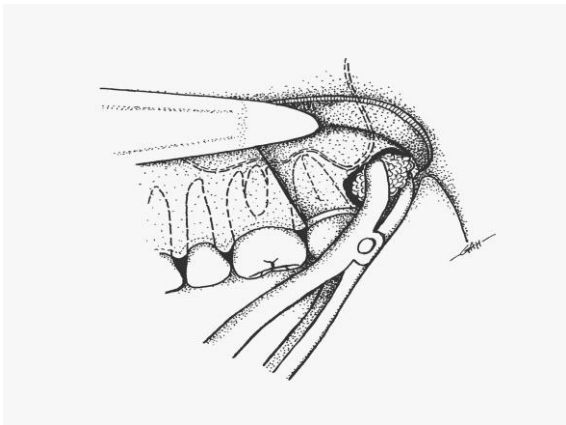
1. If no observation of nerve injury: observation
2. If nerve transected: Immediate nerve re-anastomosis or ≤ 3 months
3. If nerve observed as injured but not transected: repair immediately or ≤ 3 months
4. If paresthesia persists with unknown but suspected nerve injury: explore and repair nerve ≤ 3 months

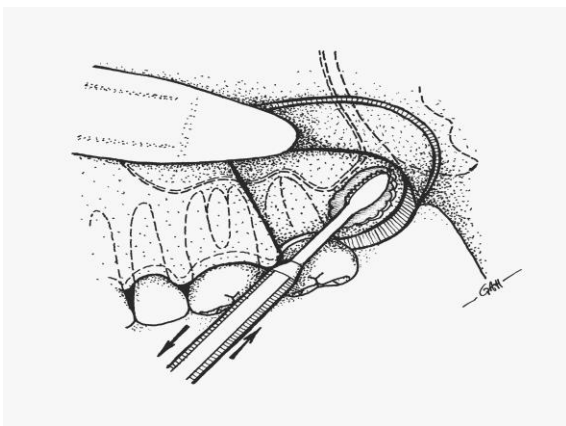
Tuberosity Graft Harvest





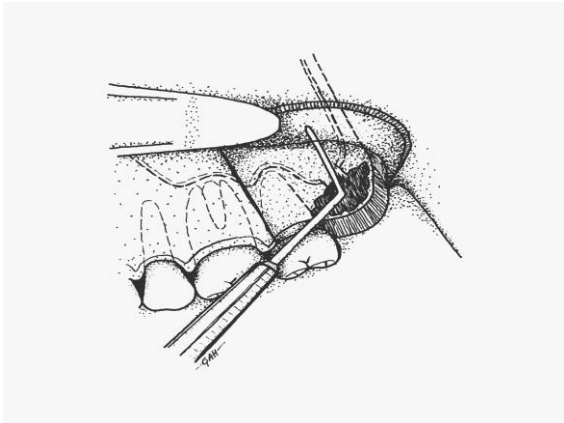


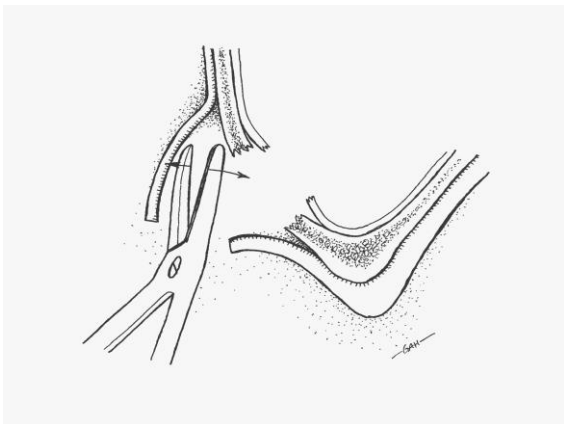


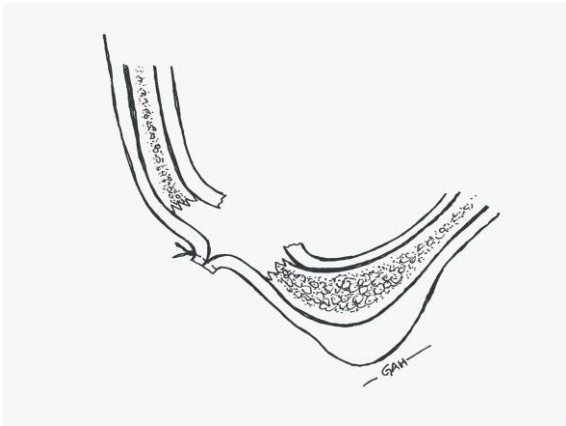


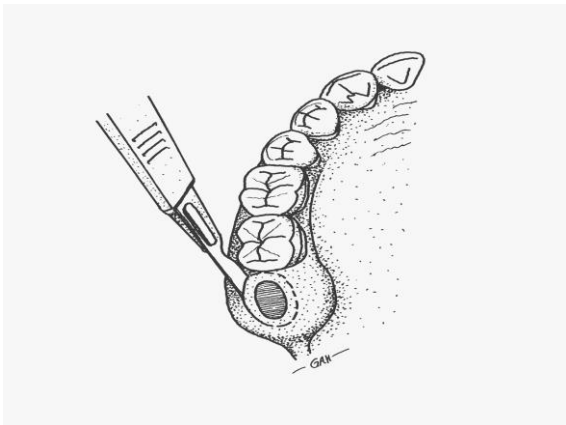
Complications Oral Antral Fistula

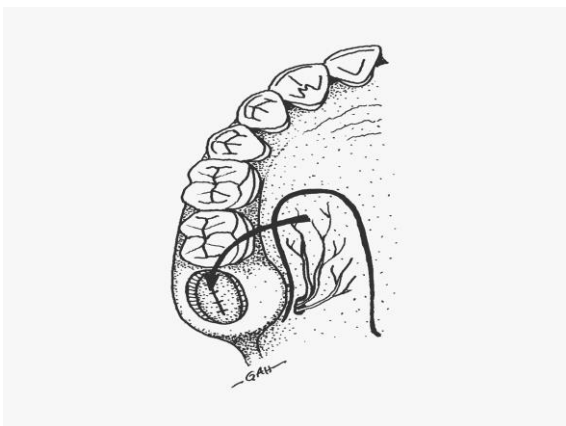
- 1. Ensure healthy sinus
- 2. Two layered closure:
 - A. local tissue inversion and palatal flap
 - B. buccal fat pad transfer and local mucosal advancement

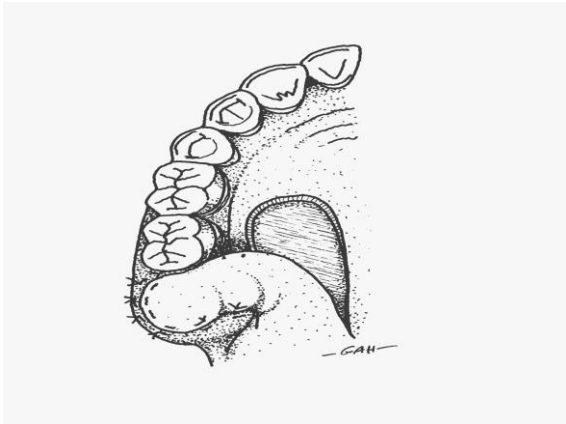


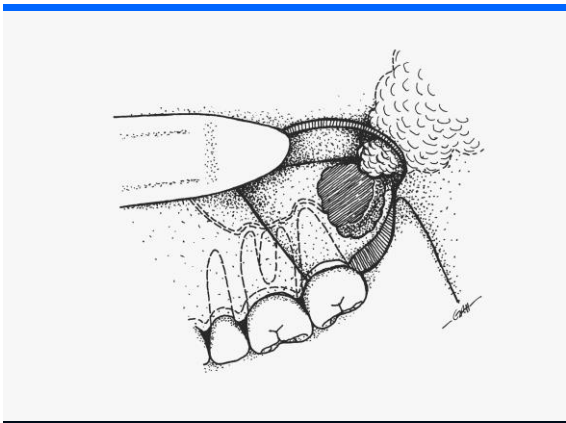


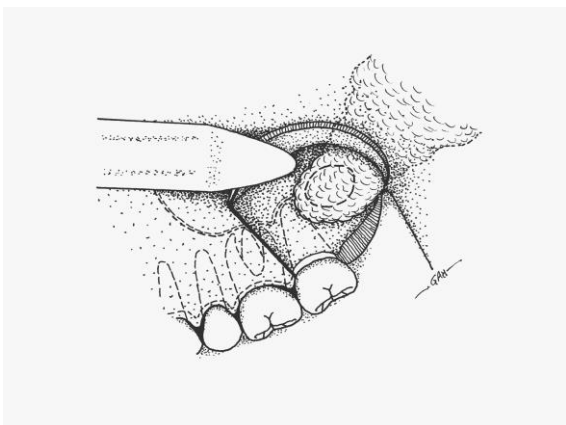


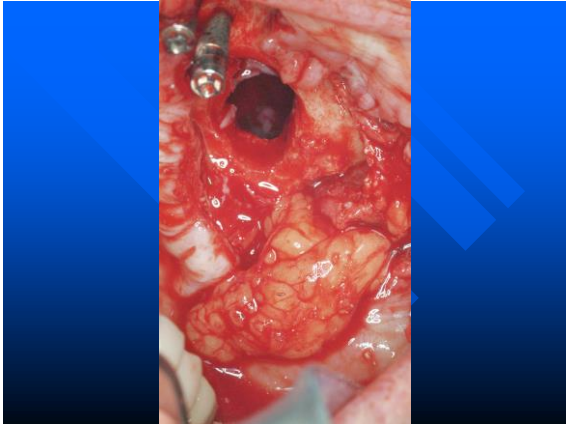


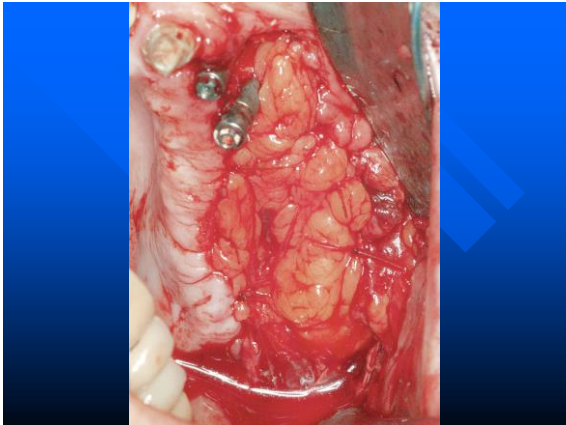

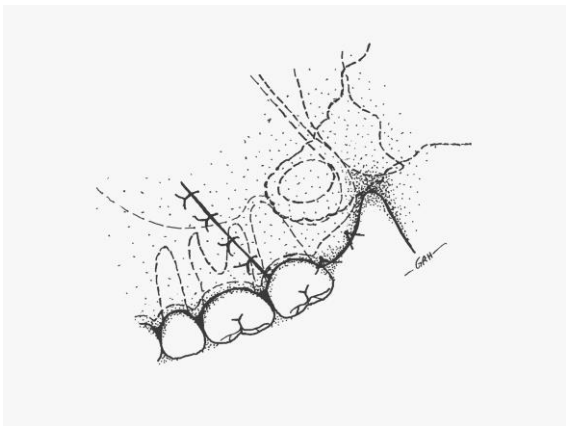








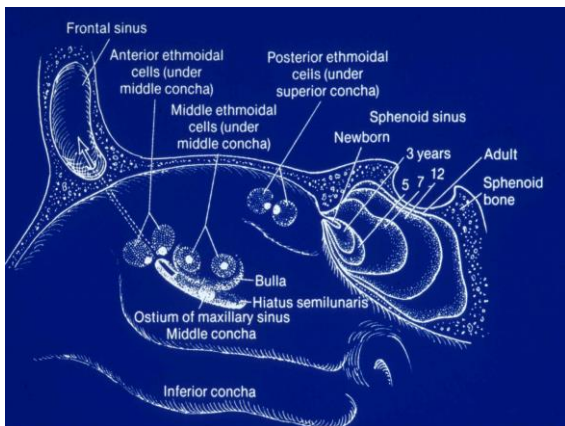


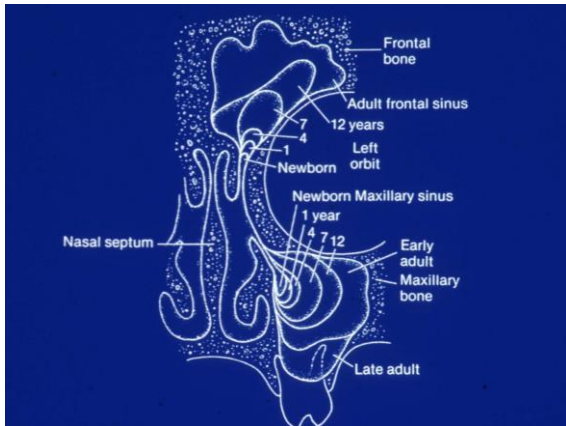


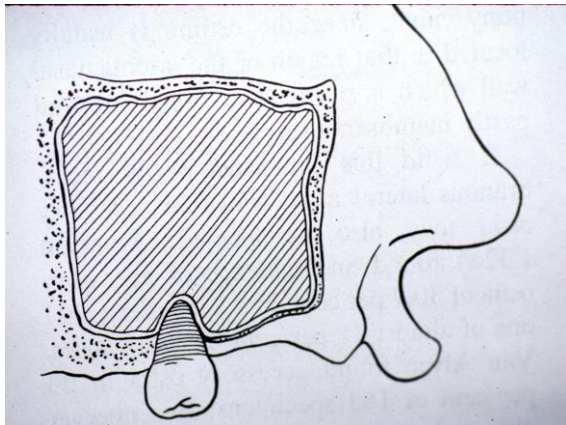
Potential Complications Tuberosity Harvest

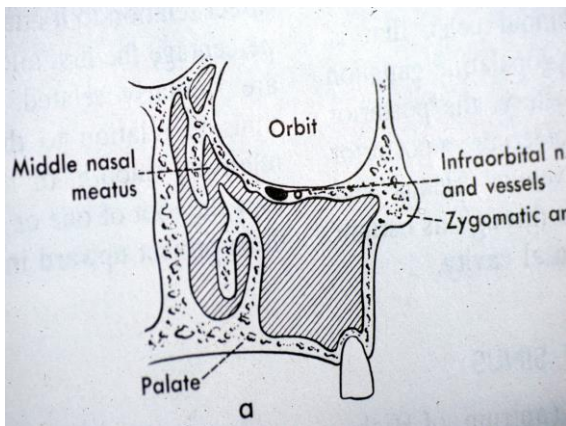
1. Oral-antral fistula
2. Sinusitis
3. Tooth root damage

Sinus Lift



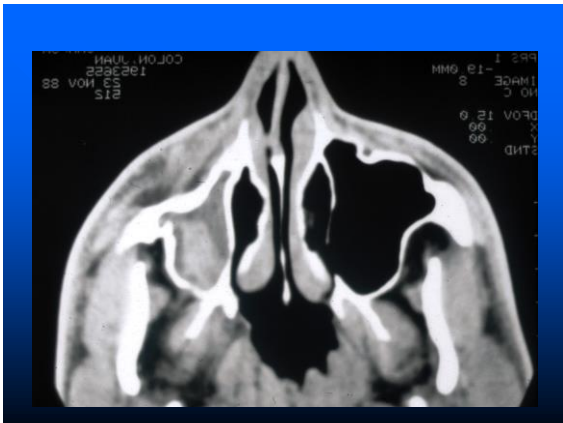


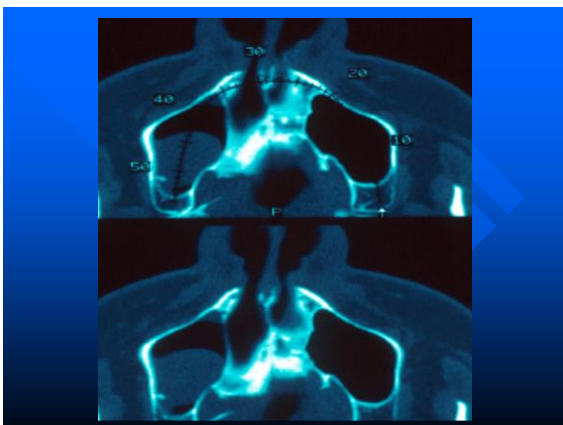


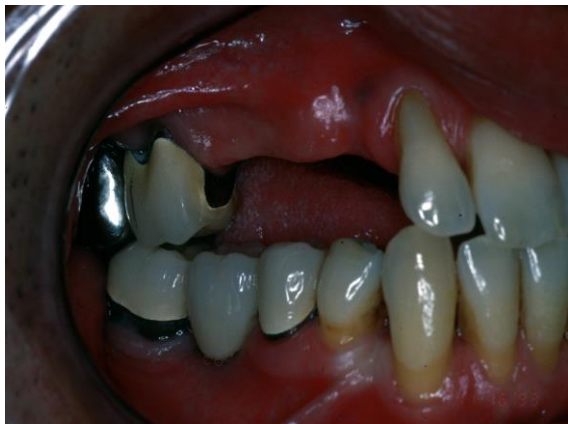

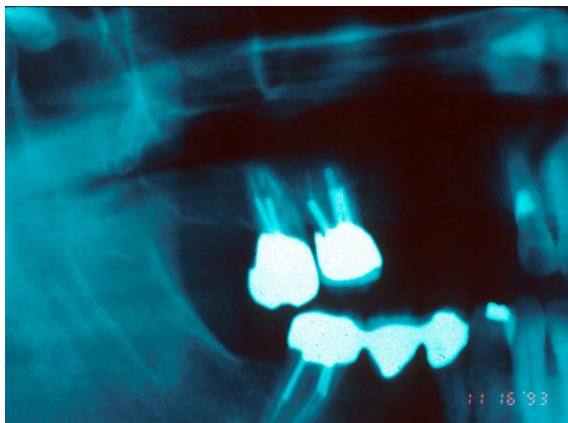
Contraindications of Maxillary Sinus Grafting

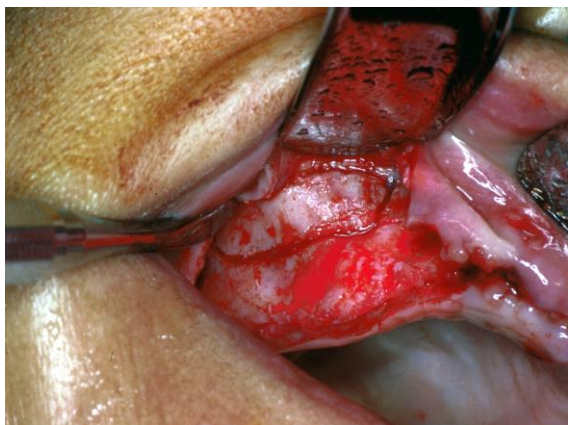
- Acute sinusitis
- Cysts
- Tumors
- Foreign Bodies

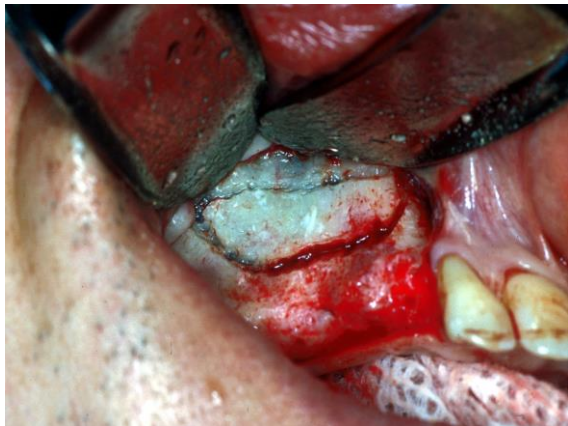

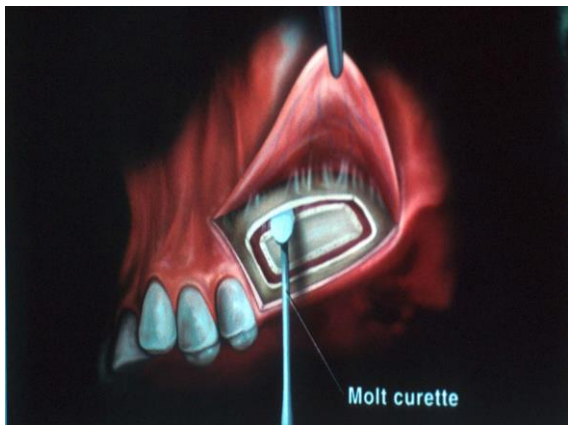


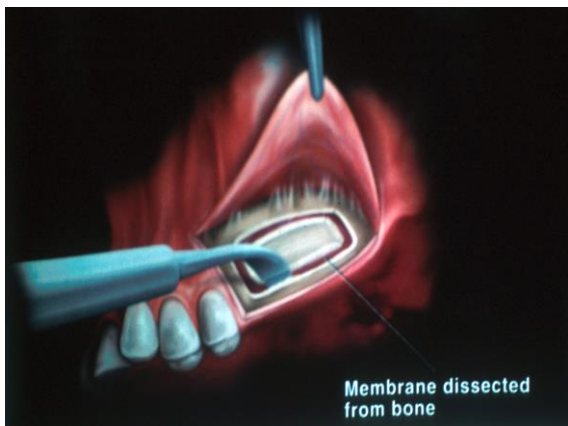


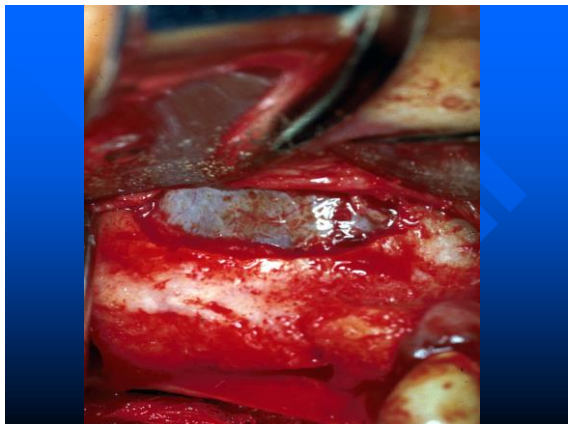



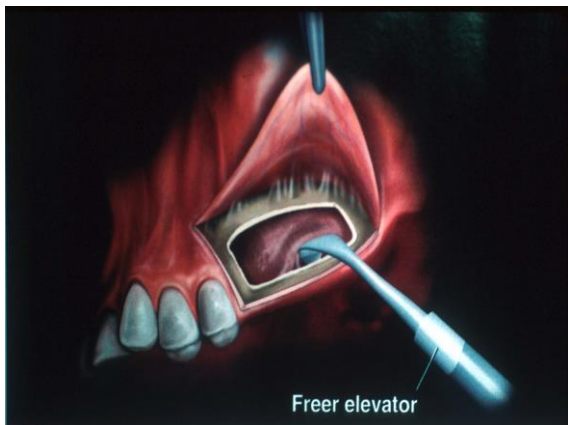


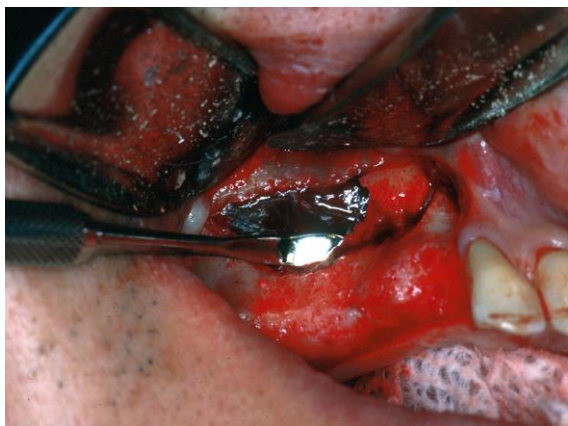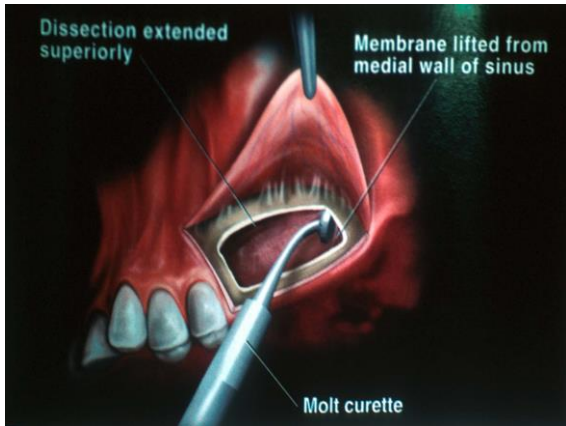




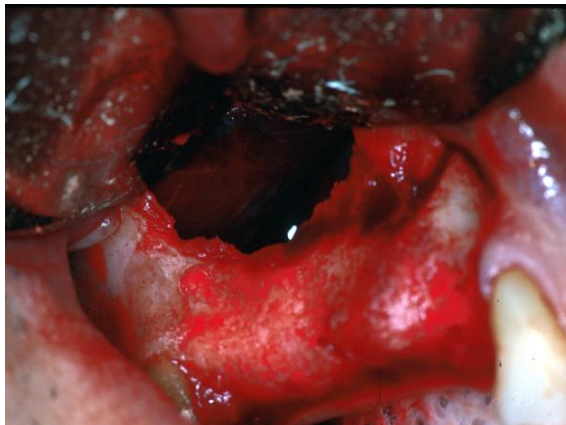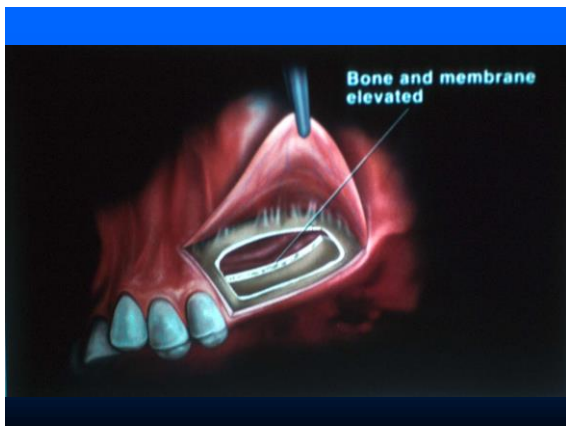






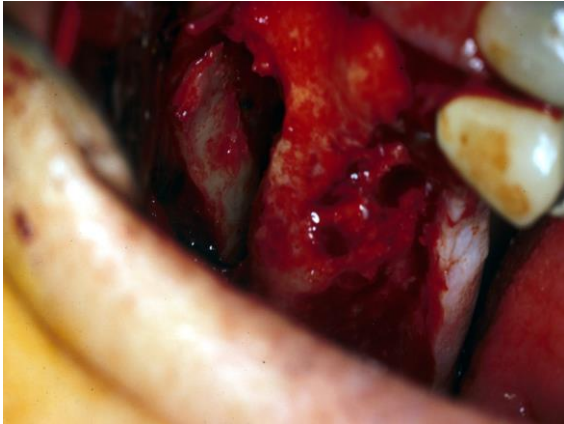


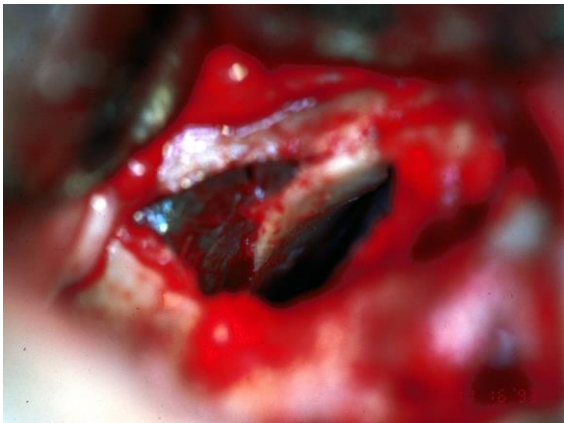




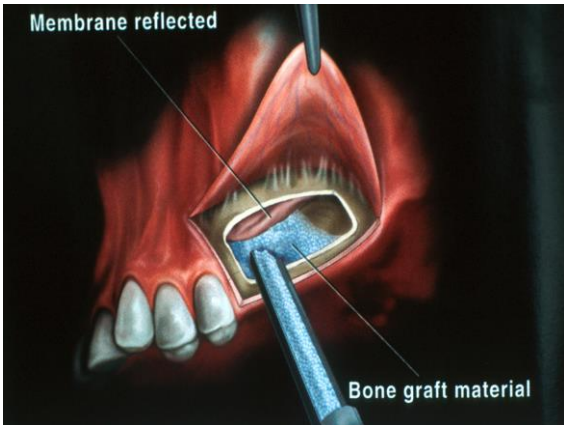


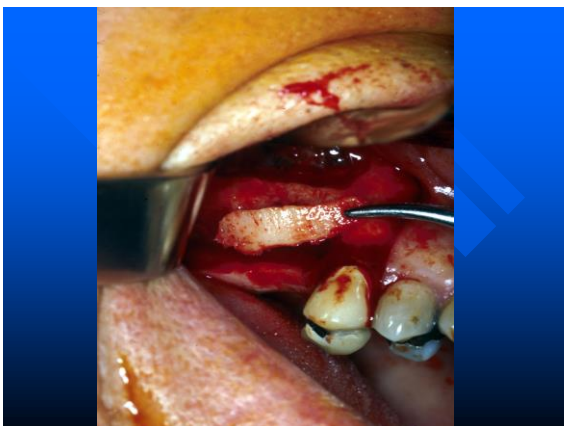Etiology of the Sinus Perforation

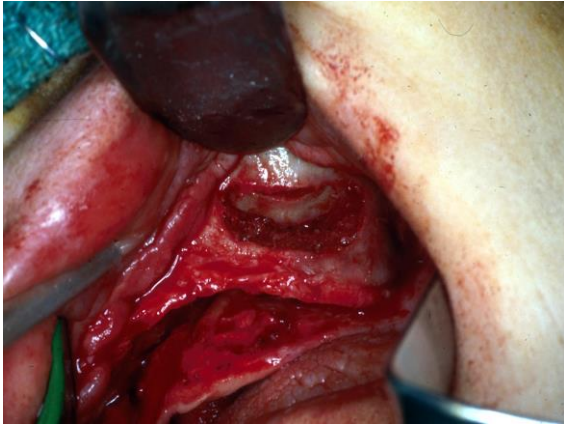
- Window osteotomy
- Infracturing of the bony window
- Reflection of the sinus membrane

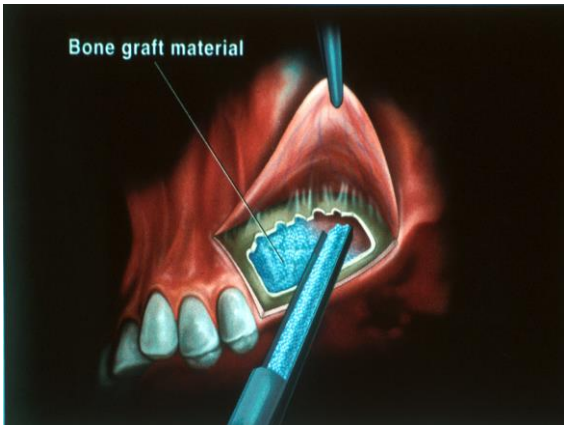Management of the Perforation

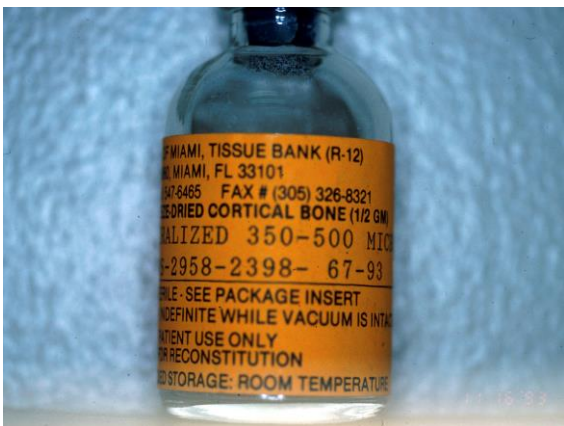
- If a large perforation cannot be sutured or covered by a collagen barrier, the graft material should not be placed

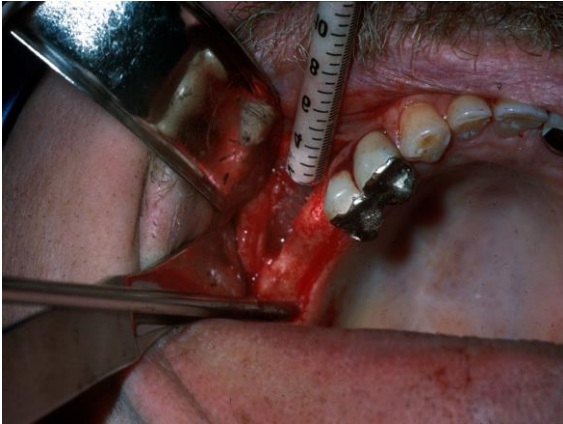


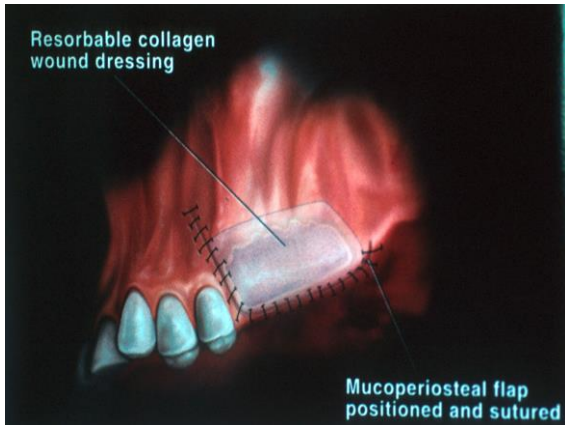








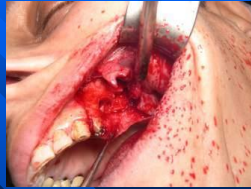



COMPLICATIONS OF THE SINUS LIFT

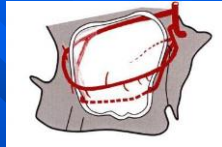
INTRAOPERATIVE COMPLICATION

- > BLEEDING
- > MEMBRANE PERFORATION
- > DAMAGE TO ADJACENT DENTITION



MAXILLARY SINUS VASCULAR SUPPLY

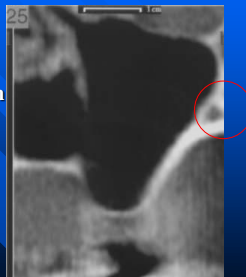- > BRANCHES OF THE MAXILLARY ARTERY
- > INFRA ORBITAL ARTERY
- > SPHENOPALATINE ARTERY
- > POSTERIOR SUPERIOR ALVEOLAR ARTERY



Solar et al COIR 1998.

BLEEDING

- > VISUALIZED IN CT SCAN - 53%
- > AVERAGE HEIGHT 16.4 mm
- > 20% OF OSTEOTOMIES
- > AGE RELATED



Elian et al JOMI 2005.

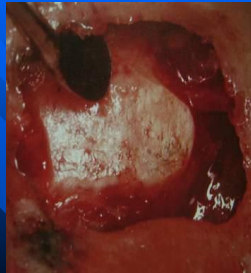BLEEDING

- > MEMBRANE ELEVATION BECOMES MORE DIFFICULT
- > INTERFERES WITH PLACEMENT OF GRAFT MATERIAL
- > HEMATOMA FORMATION

ELIAN et al JOMI 2005.
NICOLAAS et al J OMS Surg 2001.

BLEEDING

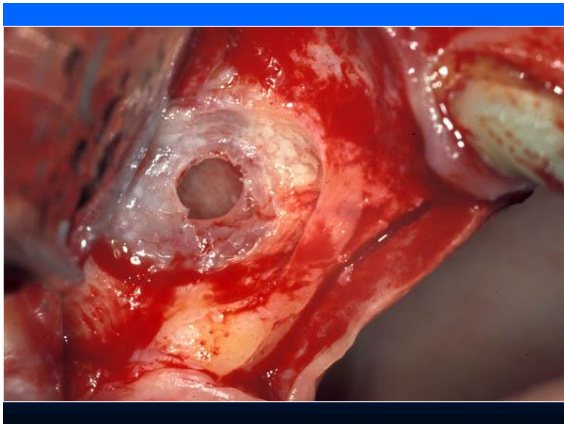
- > PREVENTION:
 - > PREOP IDENTIFICATION
 - > SMALL WINDOW
 - > TWO WINDOWS
- > MANAGEMENT
 - > PRESSURE
 - > BONE WAX
 - > CAUTERIZATION

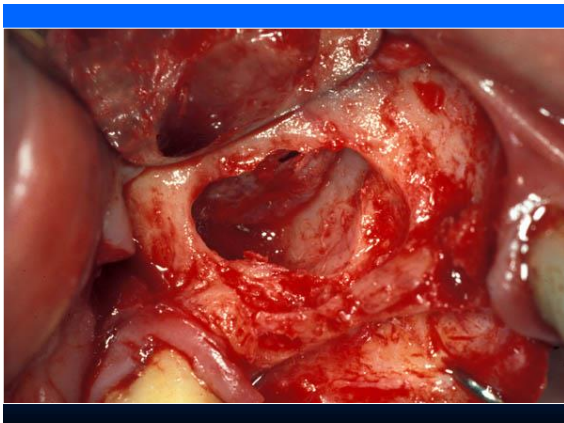


MEMBRANE PERFORATION

- > MAIN COMPLICATION INCIDENCE OF 7% - 44%
- > INFILTRATION OF GRAFT MATERIAL INTO THE SINUS
- > BACTERIAL PENETRATION INTO THE GRAFT
- > MUCOUS INVASION INTO THE GRAFT

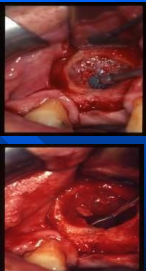
Schwartz – Arad et al J Periodontol 2004.
Periklis et al JOMI 2004.





MEMBRANE PERFORATION

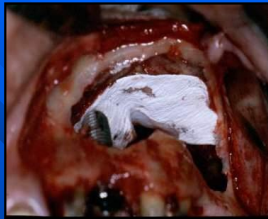
- > **WHEN DOES IT HAPPEN?**
- > **WINDOW OPENING**
- > **MEMBRANE ELEVATION**

Two small inset images showing membrane perforation and window opening. The top image shows a circular window opening in the cochlea, and the bottom image shows a larger, more irregular window opening in the cochlea.

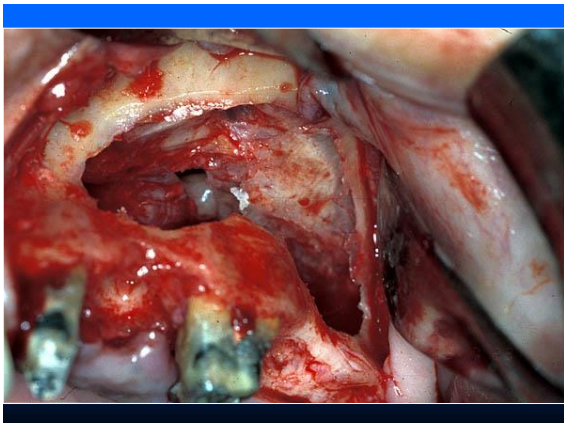
MEMBRANE PERFORATION

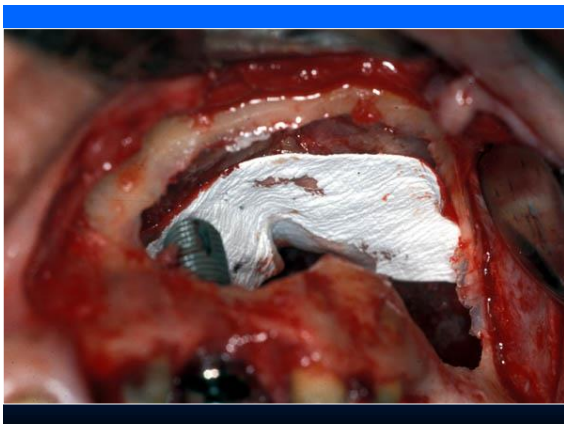MANAGEMENT OF SMALL PERFORATION

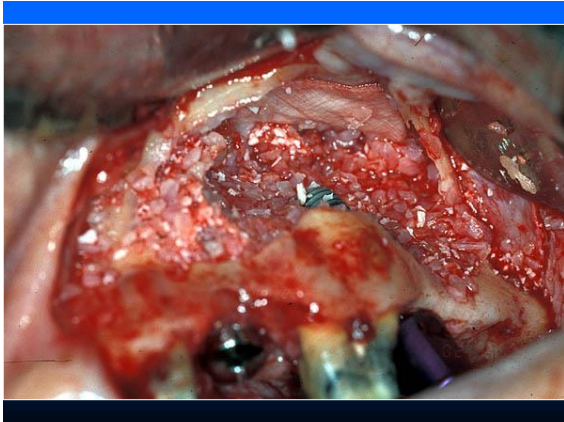- > SUTURE CLOSURE
- > FIBRIN ADHESIVE
- > COVER WITH A MEMBRANE



Schwartz - Arad et al J Periodontol 2004.



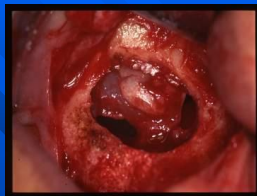



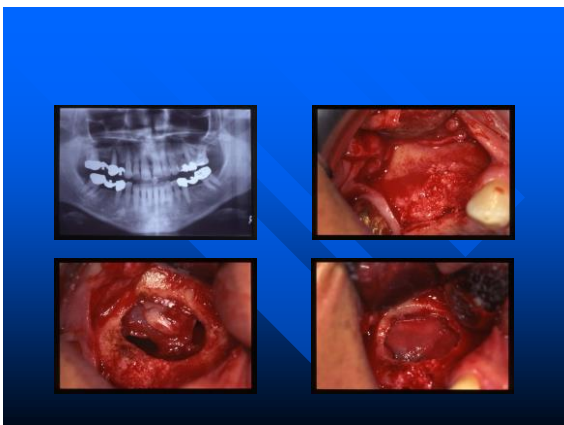
MEMBRANE PERFORATION

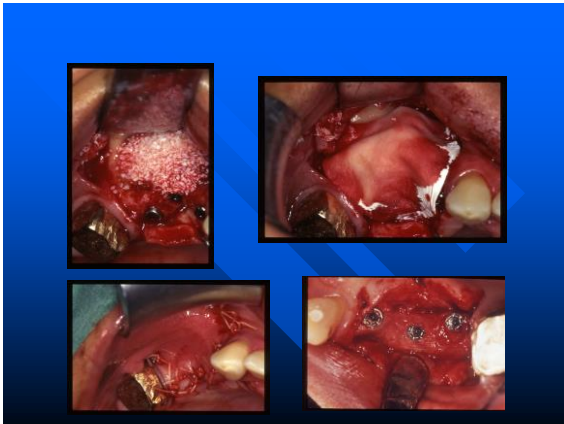
TREATMENT OF WIDE PERFORATION

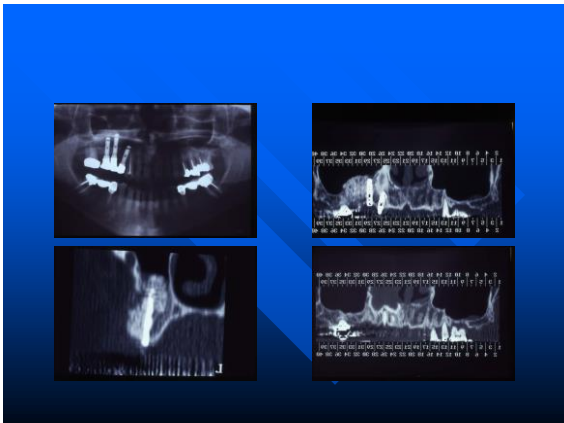
- MEMBRANE
- ABANDON PROCEDURE

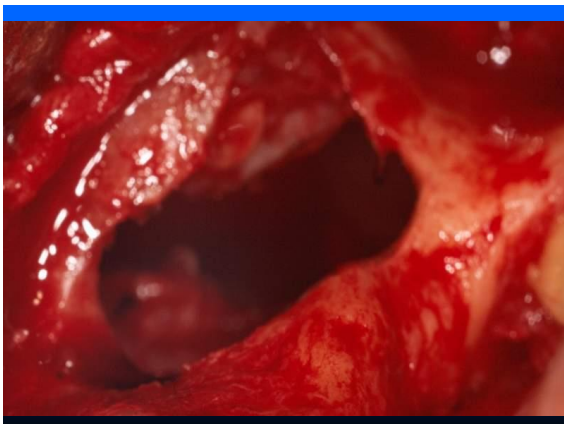

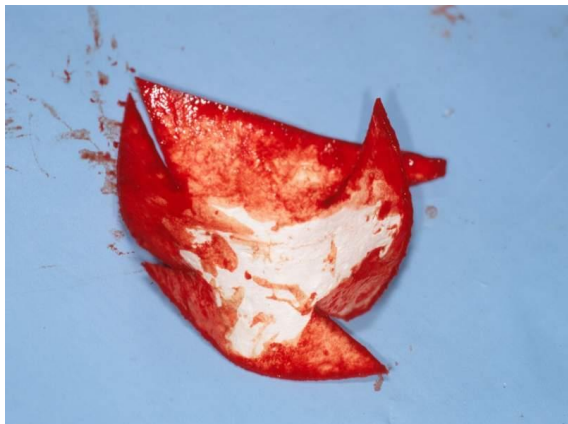*Pikos M Implant Dentistry
1999.
Fugazzotto et al Inn in Perio
2003.*

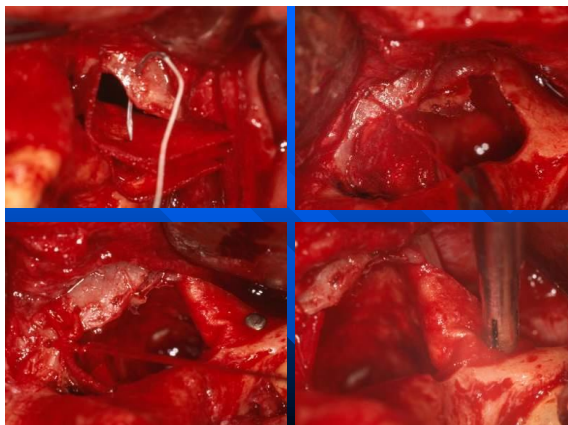


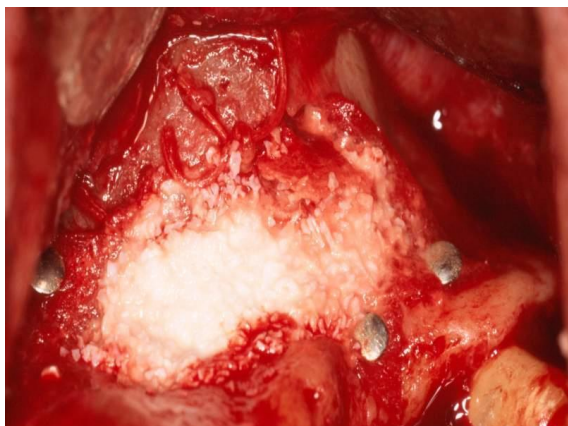

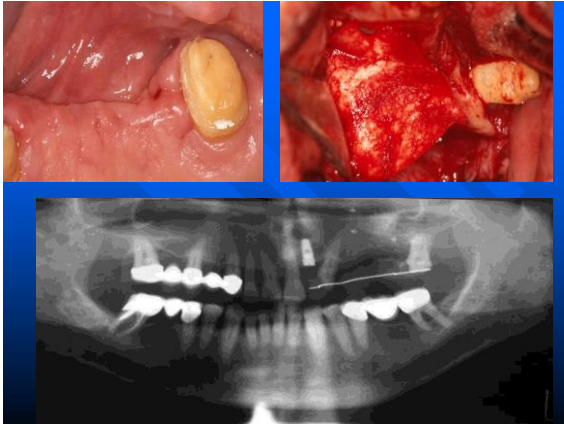







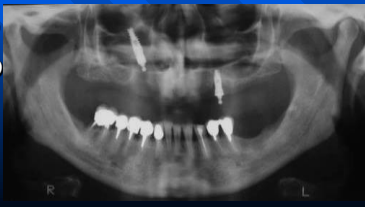
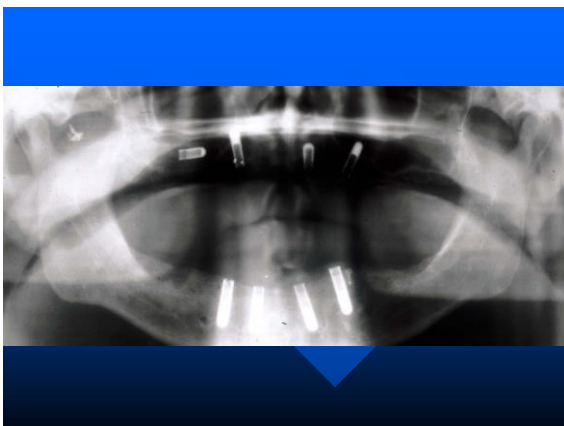




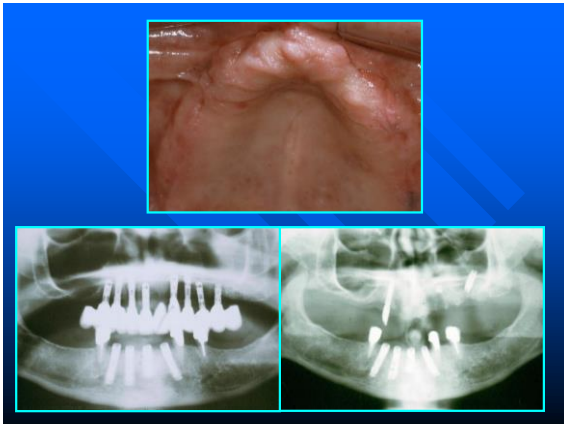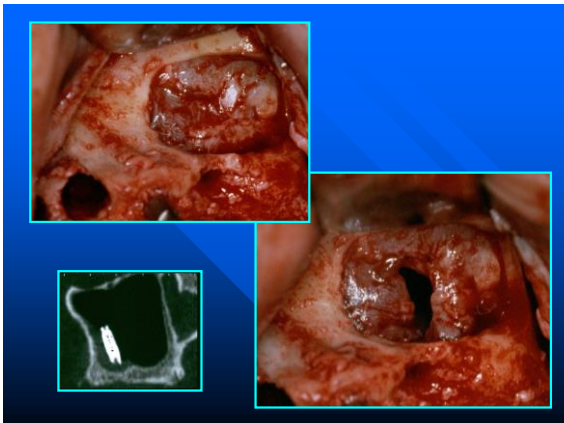
MEMBRANE PERFORATION

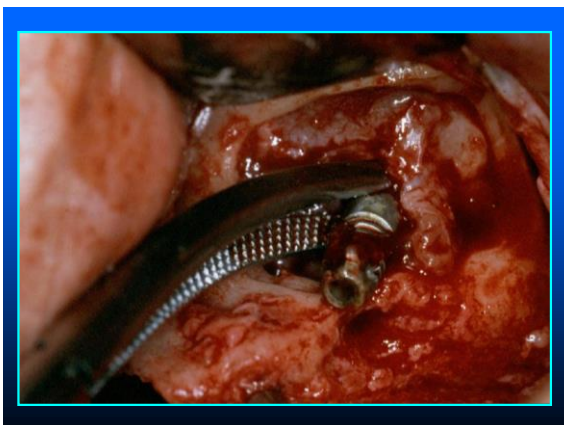
- > DENTAL RELATED
- > IMPLANT RELATED

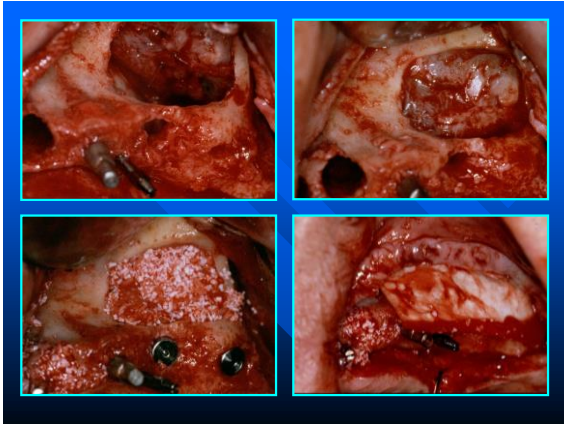


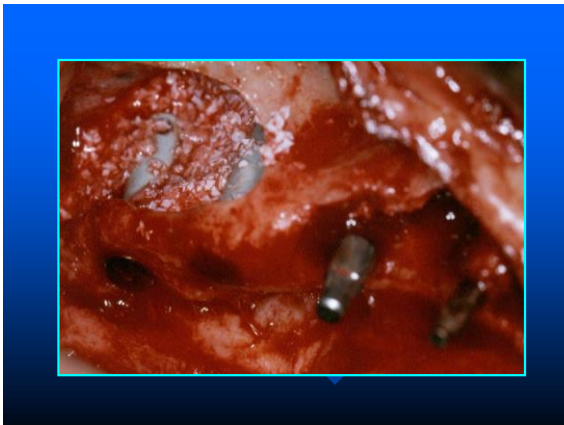

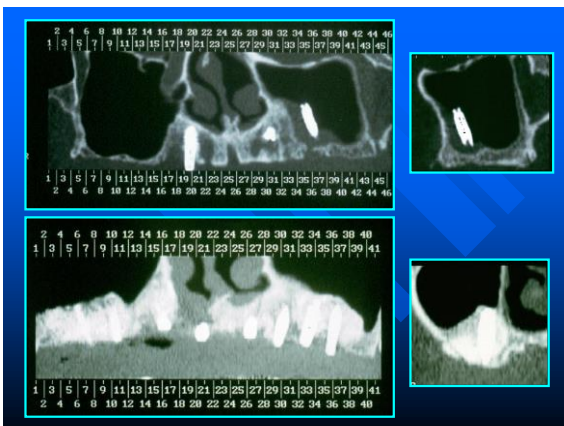


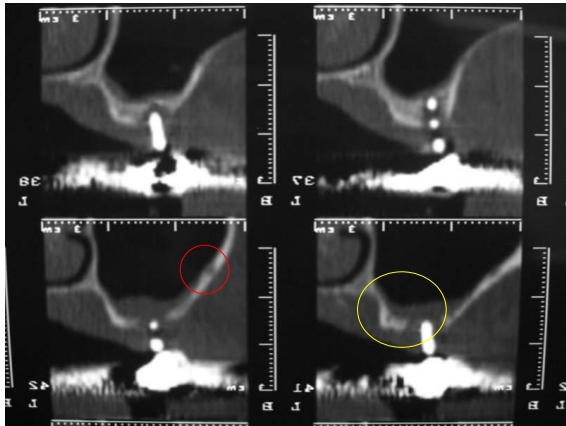



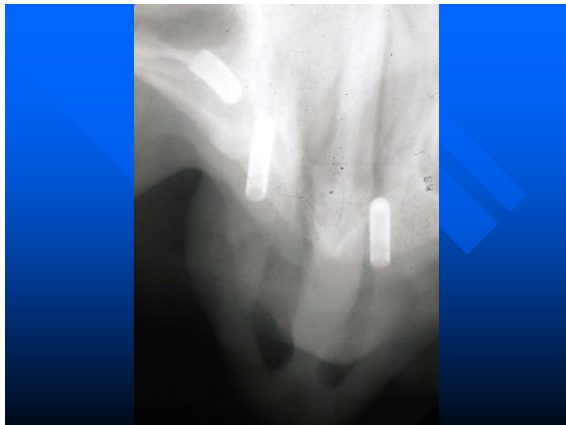




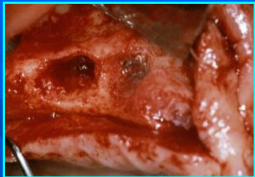


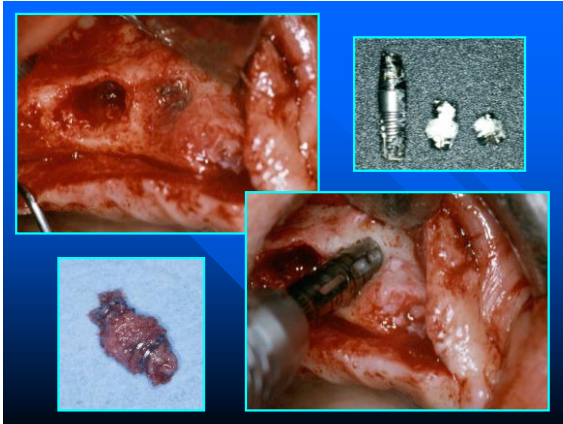




FRACTURED IMPLANTS

- INVOLVES MANUFACTURING
- USE OF EXCESSIVE FORCE
- FRACTURES ARE NOT VERY COMMON



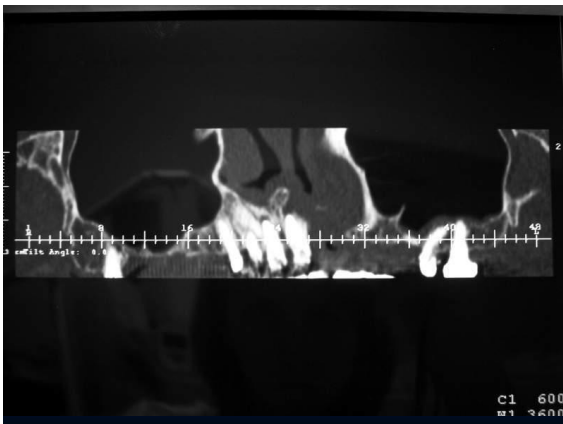

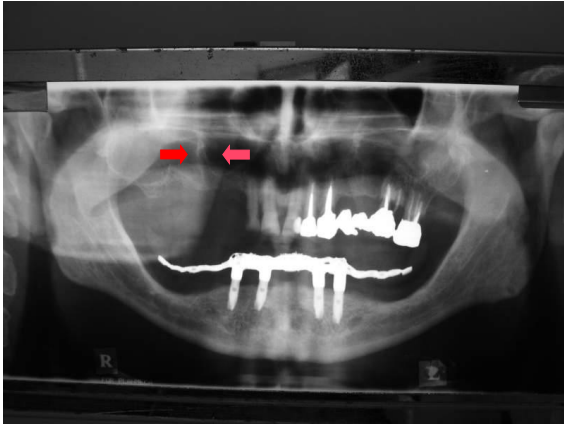
PRESENCE OF SEPTA

- > 30% INCIDENCE
- > 75% 2nd PREMOLAR – 1st MOLAR REGION
- > USUALLY BUCCOPALATAL DIRECTION
- > HIGHER RISK OF MEMBRANE PERFORATION
- > MODIFICATION OF THE WINDOW DESIGN

Ulm et al JOMI 1995.

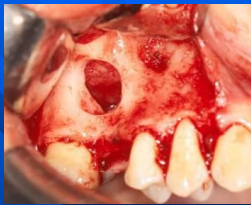Betts et al JOMS Surg 1994.





DAMAGE TO ADJACENT DENTITION

- > EXCESSIVELY LARGE WINDOW
- > DEVITALIZE ADJACENT TEETH
- > REDUCE BONY SUPPORT
- > SINGLE TOOTH SINUS LIFT



POSTOPERATIVE COMPLICATION

- > USUALLY OCCURS WITHIN THE FIRST 3 WEEKS
- > WOUND DEHISCENCE
- > INFECTION
 - > ACUTE LOCALIZED INFECTION
 - > SINUSITIS
 - > OSTEOMYELITIS
- > GRAFT / IMPLANT LOSS

Schwartz – Arad et al J Periodontol 2004.

POSTOPERATIVE COMPLICATION PREVENTION

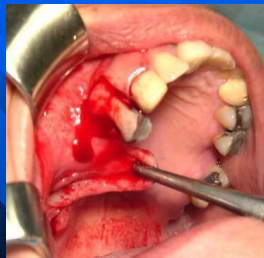- > ANTIBIOTICS
- > NASAL DECONGESTANTS
- > MOUTH RINSES
- > SINUS PRECAUTIONS



WOUND DEHISCENCE

PREVENTION

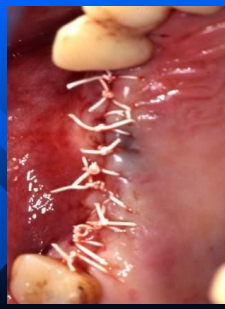- > WOUND CLOSURE OVER INTACT BONE
- > NO TENSION
- > PASSIVE CLOSURE



WOUND DEHISCENCE

PREVENTION

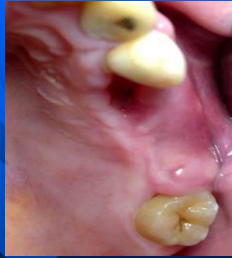- > WATER TIGHT CLOSURE
- > NO REMOVABLE PROSTHESIS



MANAGEMENT OF WOUND DEHISCENCE

- > **SMALL**
 - > MOUTH RINSE
 - > SECONDARY INTENTION

- > **LARGE**
 - > REAPPROXIMATION OF THE WOUND MARGIN



ETIOLOGY OF SINUS INFECTION FROM SINUS LIFT SURGERY

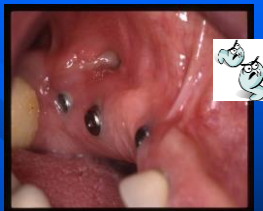- CROSS CONTAMINATION
- TRAUMATIC SURGICAL TECHNIQUE
- UNDIAGNOSED SINUS PERFORATION
- FOREIGN BODY REACTION
- IMMUNOLOGIC DISORDER
- GRAFT CONTAMINATION
- UNDIAGNOSED SINUS PATHOLOGY

INFECTION

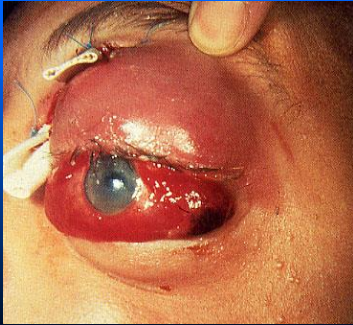
- > LEADING CAUSE OF IMPLANT FAILURE

- > BLOCKAGE OF THE OSTIUM

- > SPREAD OF INFECTION



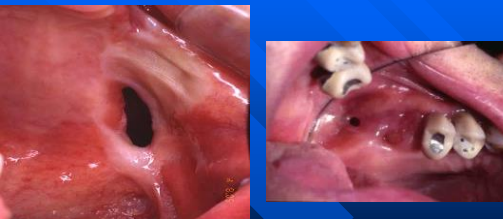
Orbital Cellulitis

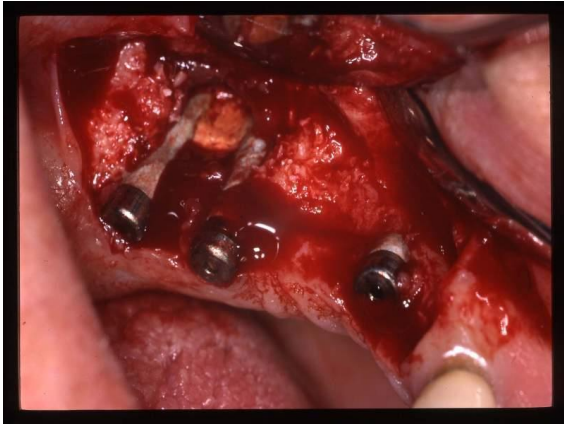


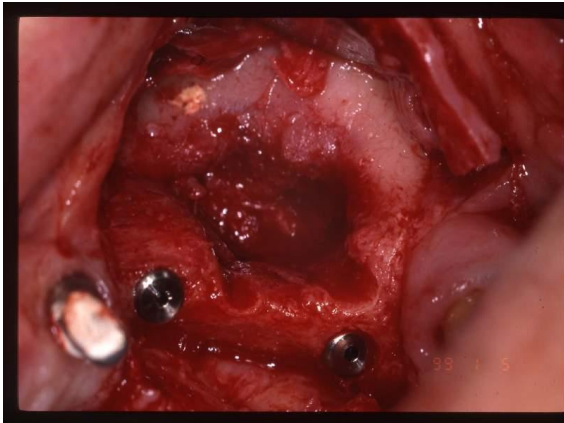
Management of Infection

- Incision and drainage
- Irrigation
- Debridement of hard and soft tissues
- Removal of graft/implant

ORO-ANTRAL FISTULA



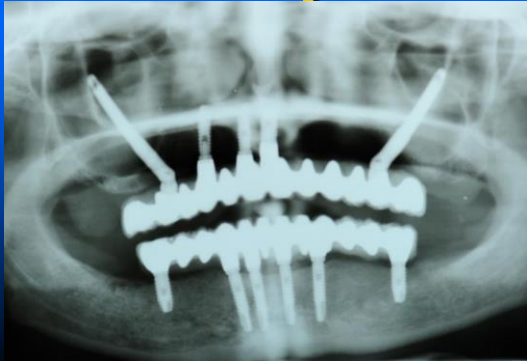




COMPLICATIONS

- **INTRAOPERATIVE**
 - BLEEDING
 - SINUS PERFORATION
 - PRESENCE OF SEPTA
 - DAMAGE TO ADJACENT TEETH
 - FRACTURED IMPLANTS
- **POSTOPERATIVE**
 - WOUND DEHISCENCE
 - INFECTION
 - FAILURE

Thank you



References

- Fonseca, R.J, Walker, R.V, Betts, N.J, Barber, H.D. Oral and Maxillofacial Trauma. Saunders. 1997
- Miloro, M, Ghali, G.E, Larsen, P.E, Waite, P.E. Peterson's Principles of Oral and Maxillofacial Surgery. BC Decker INC. 2004
- Marx, R.E. Philosophy and particulars of autogenous bone grafting. Oral and Maxillofacial Surgery Clinics of North America. 5:599-612, 1993
- Marx, R.E. Biology of Bone Grafts. Oral and Maxillofacial Surgery Knowledge Update. 1:3-17, 1994
- Picuch, J.F, Silverstein, K, Quinn, P.D. Bone grafts in Preprosthetic Surgery. Oral and Maxillofacial Surgery Knowledge Update 2:11-35, 1998
- Stevens, M.E. Bone Harvesting Techniques. Oral and Maxillofacial Knowledge Update. 1:19-34, 1994
- Roberts, W.E, Roberts, J.A, Epker, B.N, Burr, D.B. Remodeling of Mineralized Tissues, Part I: The Frost Legacy. Seminars in Orthodontics 12:216-237, 2006
- Roberts, W.E, Roberts, J.A, Epker, B.N, Burr, D.B. Remodeling of Mineralized Tissues, Part:II Control and Pathophysiology. Seminars in Orthodontics 12:238-253, 2006