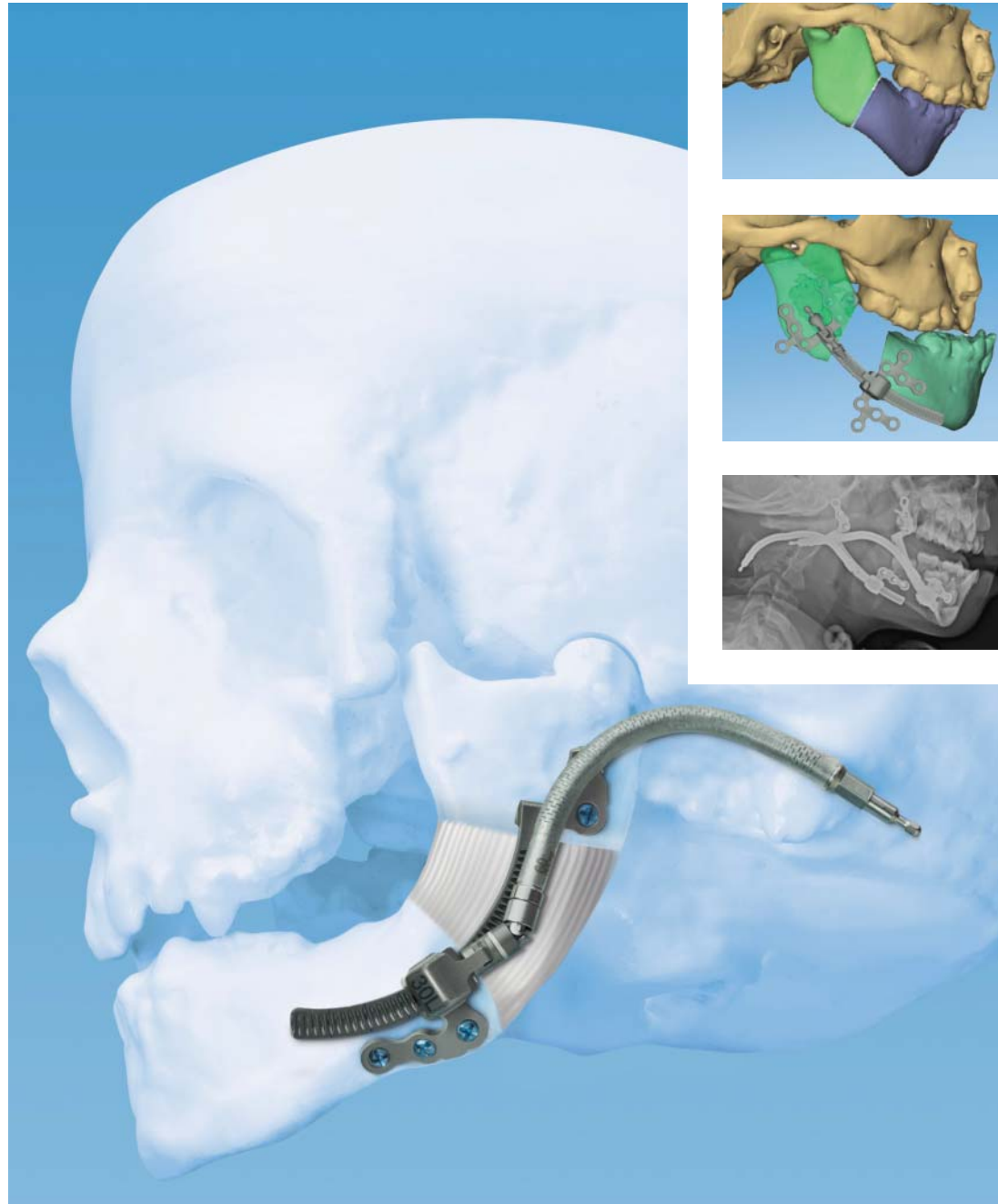


# Syndromic Micrognathia.

Preoperatively planned with ProPlan CMF and treated with Curvilinear Distraction.

Case Report



# Syndromic Micrognathia. Preoperatively planned with ProPlan CMF and treated with Curvilinear Distraction.

## Patient Profile

The patient is a 5-year-old boy with syndromic micrognathia and a history of tracheostomy dependency since infancy (Figure 1).

A preoperative sleep study demonstrated that he could not tolerate his tracheostomy being capped. He had frequent and prolonged desaturations with a nadir in the 60% range and could not adequately move air.

A CT scan revealed a retruded genial position, glossoptosis and narrowed oropharyngeal airway (Figure 2).

His parents sought consultation regarding correction of the micrognathia and removal of the tracheostomy.

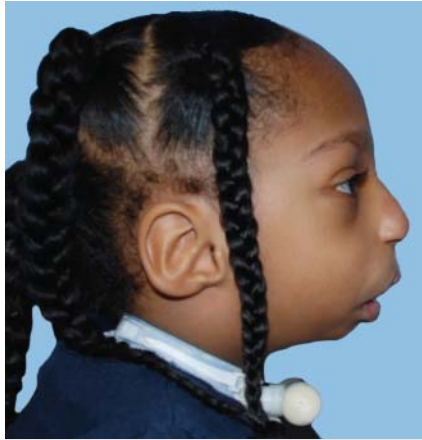

Figure 1  
Preoperative

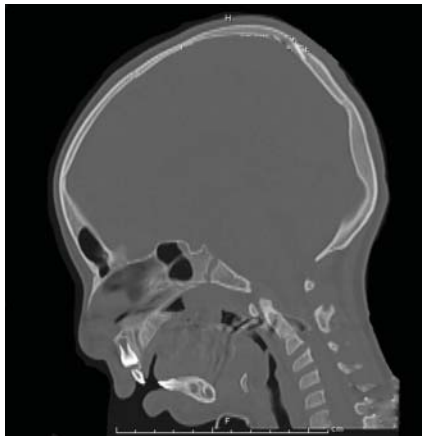

Figure 2

---

### Preoperative planning

Using the uploaded CT data, virtual surgical planning was performed using Synthes ProPlan CMF (Figure 3).

During a web-based preoperative planning session, the surgeon identified the optimal location of bilateral osteotomies and the desired final position of the distal segment of the mandible (Figures 4-5).

Once the distal mandibular segment was positioned, the optimal radius of curvature, length of advancement, and position of the devices were determined using geometric analysis. A distractor with 70 mm radius of curvature was selected bilaterally (Figure 6).

The curvilinear distractor system was chosen to attain multiple goals: promote bone growth along both horizontal and vertical vectors, avoid creating an anterior open bite secondary to the distraction procedure and create a more normal mandibular morphology.

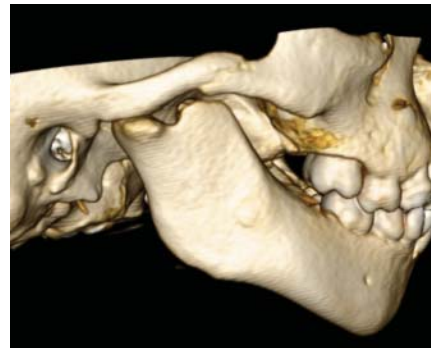

Figure 3

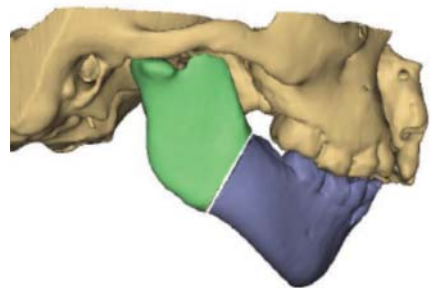


Figure 4

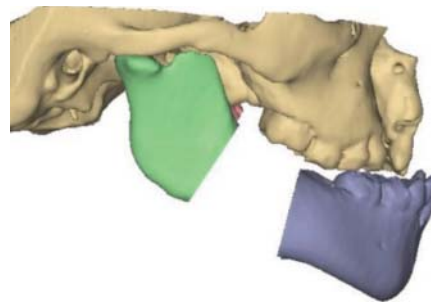


Figure 5

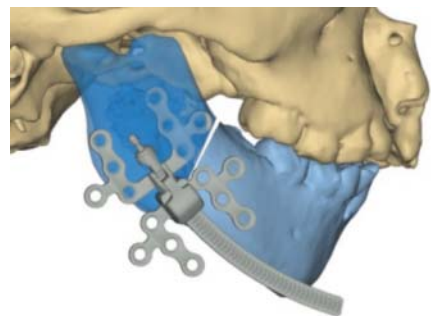


Figure 6

**Syndromic Micrognathia.** Preoperatively planned with ProPlan CMF and treated with Curvilinear Distraction.

Based on the approved plan, anatomical models and surgical guides were fabricated. The surgical guides were made from polyamide and included the planned location of the screw holes and osteotomy (Figure 7).

The planned post-distraction goal was 16.6 mm of advancement on the right and 22.7 mm on the left (Figure 8).

The distractors were cut and contoured pre-operatively by the surgeon using the bone model and surgical guides as references.




Figure 7

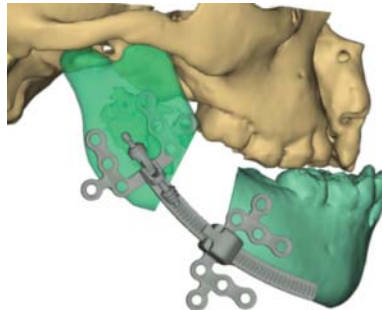


Figure 8

---

### Surgical Treatment

The inferior and posterior borders and the antegonial notch were marked on the skin (Figure 9). Bilateral submandibular incisions of 3.5 cm were made, followed by standard dissection, preserving the marginal mandibular nerve.

Once the mandible was exposed, the surgical guide was positioned on the angle of the mandible as planned (Figure 10). The corticotomy was started inferiorly through the cutting slot on the surgical guide using a reciprocating saw. Pilot holes were drilled through the holes in the surgical guide.

The surgical guide was removed. A 60 mm removable flexible extension arm was attached to the distractor. The distractor was positioned on the mandible so that the extension arm exited through the soft tissue under and behind the ear lobe.

The curvilinear distractor was attached to the mandible by inserting 2.0 mm screws, 6 mm in length, through the previously drilled screw holes. The remaining holes were drilled. A total of two screws were placed in the proximal footplate and three screws were placed in the distal footplate.

The osteotomy was completed using a combination of an osteotome and reciprocating saw, taking care to preserve the inferior alveolar nerve. The distractor was activated with the activation instrument to ensure a gap was created between the footplates. The distractor was then returned to the neutral position.

The same procedure was performed on the contralateral side.

That patient's mouth was kept closed during the entire procedure. No intraoral communication was created to help minimize the risk of infection. Skin closure was accomplished in a layered fashion including platysma, subcutaneous and subcuticular layers.

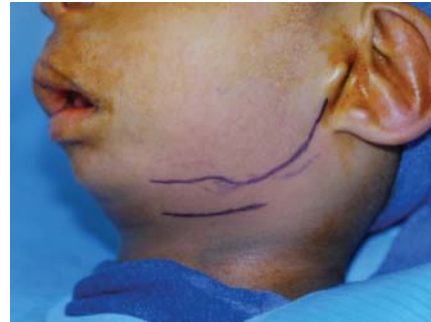

Figure 9

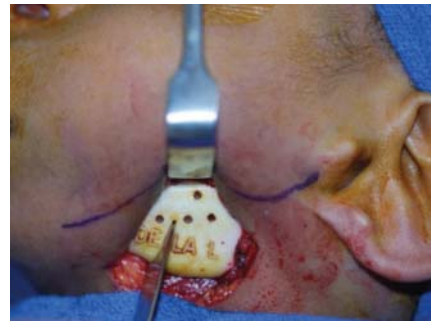


Figure 10

**Syndromic Micrognathia.** Preoperatively planned with ProPlan CMF and treated with Curvilinear Distraction.

---

### **Postoperative Management**

#### **Distraction Protocol:**

The patient was discharged on post-operative day one. After a latency phase of 72 hours, the distractors were activated 1 mm per day bilaterally by the patient's mother. During the distraction period, the patient was seen in the clinic weekly to check progress. During each follow-up visit, the surgeon activated the distractor one turn on one side and took plain X-ray films to confirm advancement (Figure 11).

#### **Extension Arm Removal and Consolidation Phase:**

After a three week distraction period, the flexible extension arms were removed in the clinic and the newly created bone was allowed to heal for two months. Once the regenerate solidified, the distractors were removed in the OR through the same incisions. The patient was discharged home on the same day.

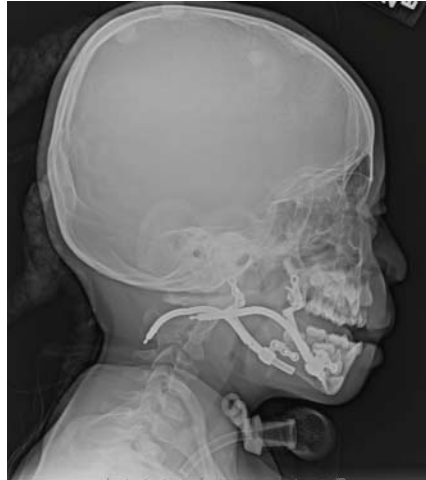

Figure 11

---

## Results

A follow-up sleep study was performed 4 weeks after device removal. The patient's tracheostomy was capped and he was able to sleep the entire night with excellent oxygen saturation. His Apnea Hypopnea Index (AHI) demonstrated correction of obstructive sleep apnea with results of < 5 episodes/hour (Figure 12).

The patient was brought in for bronchoscopy/laryngoscopy and his tracheostomy was decannulated. He spent one night in the PICU under observation. He tolerated this well with no decreases in oxygen level. He was discharged home.

The patient has been at home with his tracheostomy successfully removed for several months.

Comparing pre and post distraction, note the new mandibular and chin position and that the tracheostomy has been removed (Figures 13-14).

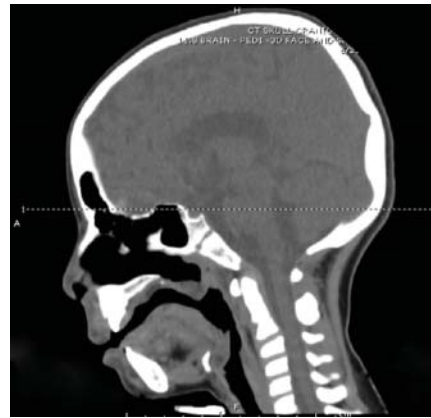

Figure 12 Post-op sagittal CT

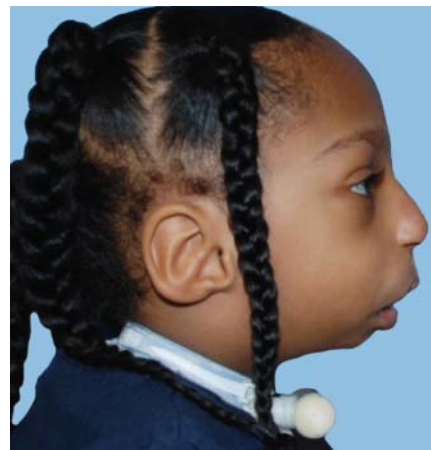

Figure 13 Pre distraction

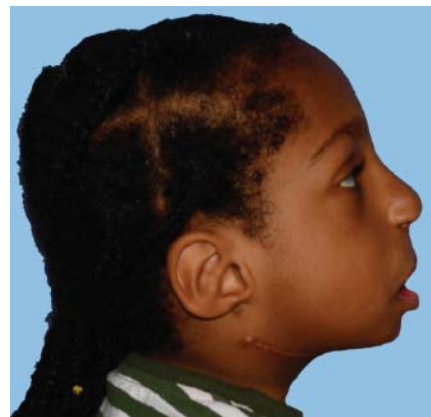

Figure 14 Post distraction



**Syndromic Micrognathia.** Preoperatively planned with ProPlan CMF and treated with Curvilinear Distraction.

## Product Information

---

04.500.170 Curvilinear Distractor, Right, 70 mm radius  
04.500.171 Curvilinear Distractor, Left, 70 mm radius



---

04.315.132 Extension arm



---

## Surgeon Profile

**Derek M. Steinbacher, MD, DMD**  
Cranio-maxillofacial Surgery  
Assistant Professor Plastic Surgery  
Yale University School of Medicine  
New Haven, CT



Results from case studies are not predictive of results in other cases.  
Results in other cases may vary.



Synthes CMF  
1302 Wrights Lane East  
West Chester, PA 19380  
Telephone: (610) 719-5000  
To order: (800) 523-0322  
Fax: (610) 251-9056

Synthes (Canada) Ltd.  
2566 Meadowpine Boulevard  
Mississauga, Ontario L5N 6P9  
Telephone: (905) 567-0440  
To order: (800) 668-1119  
Fax: (905) 567-3185

[www.synthes.com](http://www.synthes.com)