


Clinical Evidence eGuide O-arm[®] Imaging System



www.medtronicnavigation.com

Medtronic Navigation

826 Coal Creek Circle
Louisville, CO 80027 USA
Toll Free: 877-242-9504
Telephone: 720-890-3200

twitter.com/mdtnavedu

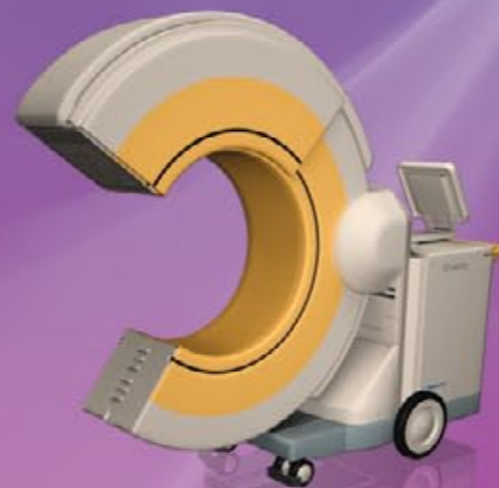facebook.com/medtronicnavigationinc

youtube.com/user/MedtronicNavEdu

© 2012 Medtronic Navigation, Inc. All Rights reserved. 9571000 v1

Innovating for life.

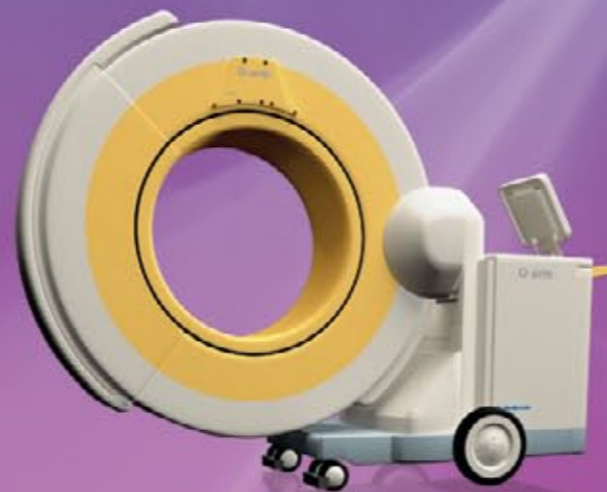Clinical Evidence eGuide O-arm® Imaging System



Purpose

This guide is to be used as an education tool. The purpose is to provide health care providers with a reference tool of peer-reviewed articles that discuss the use the O-arm[®] imaging system in surgery.

Medtronic Navigation conducted a literature search of published articles across many scientific journals. All articles found that reference the O-arm[®] imaging system were selected to be included in this guide.



Clarifications

Medtronic Navigation wishes to clarify the following points:

- (1) The O-arm[®] Intraoperative Imaging System is a Class II Medical Device in the US and has been cleared for marketing under a 510(k) submission by the FDA. This type of clearance means that FDA has concurred with the manufacturer's assertion that the device is substantially equivalent to other devices legally marketed in the US.
- (2) The O-arm[®] Intraoperative Imaging System is cleared as a Mobile X-ray System under 21 CFR 892.1720 and as a Solid State X-ray Imager under 21 CFR 892.1650. Medtronic Navigation makes no claim that the O-arm[®] system complies with the necessary performance standards to be called a Computed Tomography X-Ray System under 21 CFR 892.1750.
- (3) The cleared Indications for Use statement for the O-arm[®] Imaging System is: The O-arm[®] Imaging System is a mobile x-ray system designed for 2D fluoroscopic and 3D imaging and is intended to be used where a physician benefits from 2D and 3D information of anatomic structures and objects with high x-ray attenuation such as bony anatomy and metallic objects. The O-arm[®] imaging System is compatible with certain Image Guided Surgery Systems.

Table of Contents

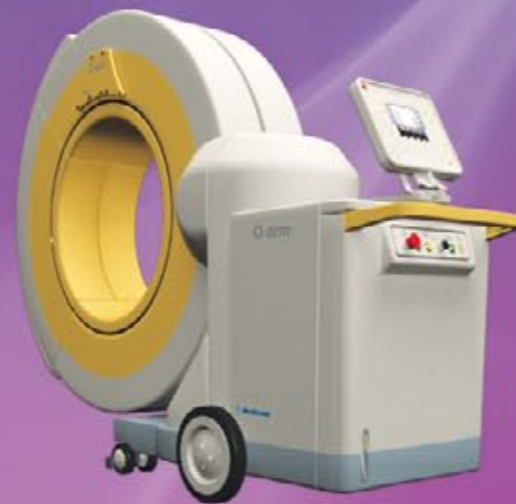

Table of contents - Spine and Orthopedics

Lead Author	Year	Abbreviated Title	Journal
Schils	2011	O-Arm–Guided Balloon Kyphoplasty: Prospective Single-Center Case Series of 54 Consecutive Patients	Neurosurgery
Oertel	2011	Clinical and methodological precision of spinal navigation assisted by 3 intraoperative O-arm radiographic imaging	Neurosurgery Spine
Silbermann	2011	Computer tomography assessment of pedicle screw placement in lumbar and sacral spine: comparison between free-hand and O-arm based navigation techniques	Eur Spine J
Wood	2011	A comparison of CT-based navigation techniques for minimally invasive lumbar pedicle screw placement.	Spinal Disorders & Techniques
Ishikawa	2011	Intraoperative, full-rotation, three-dimensional image (O-arm)–based navigation system for cervical pedicle screw insertion- Clinical Article	Journal of Neurosurgery: Spine
Sclafani	2011	Use of a quantitative pedicle screw accuracy system to assess new technology: Initial studies on O-arm navigation and its effect on the learning curve of percutaneous pedicle screw insertion.	SAS Journal
Garrido	2011	Navigated placement of iliac bolts: description of a new technique.	Spine J
Mofdi	2011	Use of Intraoperative Computed Tomography Scanning in Determining the Magnitude of Arthroscopic Osteochondroplasty	Arthroscopy
Gonschorek S	2011	O-arm based spinal navigation and intraoperative 3D-imaging: first experiences	European Journal of Trauma and Emergency Surgery
Ailawadhi	2011	Use of O-arm for spinal surgery in academic institution in India: Experience from JPN apex trauma centre	Neurology India



Please tap any title to view article

Table of contents - Spine and Orthopedics

Lead Author	Year	Abbreviated Title	Journal
Costa	2011	Evaluation of the rate of decompression in anterior cervical corpectomy using an intra-operative computerized tomography scan (O-arm system)	European Spine Journal
Santos	2011	The Accuracy of Intraoperative O-arm Images for the Assessment of Pedicle Screw Position.	Spine J
Schils F.	2011	O-arm guided balloon kyphoplasty: preliminary experience of 16 consecutive patients.	Acta Neurochirurgica
Santos	2011	Validity of surgeon perception of navigated pedicle screw position: a cadaveric study	Spine J
Kim	2011	Modified transcorporeal anterior cervical microforaminotomy assisted by O-arm-based navigation: a technical case report.	European Spine Journal
Nottmeier EW	2010	Image-guided placement of occipitocervical instrumentation using a reference arc attached to the headholder.	Neurosurgery
Nottmeier EW	2010	Three-dimensional image-guided placement of S2 alar screws to adjunct or salvage lumbosacral fixation.	Spine J
Kim	2010	Pedicle screw fixation under navigation guidance based on O-arm	The Internet Journal of Minimally Invasive Spinal Technology
Wood	2010	Improving accuracy and reducing radiation exposure in minimally invasive lumbar interbody fusion.	Neurosurgery Spine
Park	2010	Minimally invasive pedicle screw fixation utilizing O-arm fluoroscopy with computer-assisted navigation: Feasibility, technique, and preliminary results.	Surg Neurol Int.



Please tap any title to view article

Table of contents - Spine and Orthopedics

Lead Author	Year	Abbreviated Title	Journal
Kim	2010	An assistive image-guided surgical robot system using O-arm fluoroscopy for pedicle screw insertion: preliminary and cadaveric study.	Neurosurgery
Brennen	2008	Minimally invasive image-guided direct repair of bilateral L-5 pars interarticularis defects.	Neurosurgery Focus
Metz, LN	2008	Computer-Assisted Surgical Planning and Image-Guided Surgical Navigation in Refractory Adult Scoliosis Surgery: Case Report and Review of the Literature	Spine J



Please tap any title to view article

Table of contents - Cranial and ENT

Lead Author	Year	Abbreviated Title	Journal
Shahlaie K	2011	Intraoperative computed tomography for deep brain stimulation surgery: technique and accuracy assessment	Neurosurgery
Smith	2011	Frameless deep brain stimulation using intraoperative O-arm technology	Neurosurgery
Conley	2011	Comparison of Intraoperative Portable CT Scanners in Skull Base and Endoscopic Sinus Surgery: Single Center Case Series	Skull Base
Leung	2011	Advancements in computed tomography management of chronic rhinosinusitis	American Journal of Rhinology & Allergy
Caire F	2010	Intraoperative use of the Medtronic O-arm for deep brain stimulation procedures.	Stereotact Funct Neurosurg
Bloom	2009	Real-Time Intraoperative Computed Tomography to Assist Cochlear Implant Placement in the Malformed Inner Ear: Otology & Neurotology	Otology & Neurotology

Please tap any title to view article

Table of contents - Oncology

Lead Author	Year	Abbreviated Title	Journal
Wu	2011	Intraoperative Navigation for Minimally Invasive Resection of Periarticular and Pelvic Tumors.	Orthopedics
Zelevsky	2010	Real-time intraoperative computed tomography assessment of quality of permanent interstitial seed implantation for prostate cancer.	Urology

Please tap any title to view article

Table of contents - Imaging Technology

Lead Author	Year	Abbreviated Title	Journal
Abul Kasim	2011	Optimization of Radiation Exposure and Image Quality of the Cone-beam O-arm Intraoperative Imaging System in Spinal Surgery.	Journal of Spinal Disorders and Techniques
Park	2011	The perspectives of users and developers in designing and developing O-arm imaging system	Journal of X-ray Science and Technology
Park	2011	Comparison of operator radiation exposure between C-arm and O-arm fluoroscopy for orthopaedic surgery	Radiation Protection Dosimetry
Zhang	2009	Dosimetric characterization of a cone-beam O-arm imaging system.	Journal of X-ray Science and Technology

Please tap any title to view article

O-arm–Guided Balloon Kyphoplasty: Prospective Single-Center Case Series of 54 Consecutive Patients

Schils, Frédéric MD

Department of Neurosurgery, Clinique Saint Joseph, Liège, Belgium

Neurosurgery June 2011

Abstract

Background:

Balloon kyphoplasty is widely used to treat vertebral compression fractures. Procedure outcome and safety are directly linked to precise radiological imaging requiring 1 or 2 C arms to allow correct visualization throughout the procedure. This minimally invasive spinal surgery is associated with radiation exposure for both patient and surgeon. In our center, we switched from using a C-arm to an O-arm image guidance system to perform balloon kyphoplasty. Our preliminary experience is reported in *Acta Neurochirurgica*, and the encouraging results led us to study this subject more extensively. This article presents our complete results. To the best of our knowledge, there is no comparable clinical series describing O-arm use in kyphoplasty procedures published in the literature.

Objective:

To report our complete results of using the O-arm guidance system to perform balloon kyphoplasty.

Methods:

We prospectively evaluated O-arm-guided kyphoplasty procedure in 54 consecutive patients and measured x-ray exposure and fluoroscopy time.

Results:

The mean surgical time for the procedure was 38 minutes with a mean fluoroscopy procedure time of 3.1 minutes. The mean fluoroscopy time by level was 2.5 minutes. Mean irradiation dose by procedure was 220 mGy and by level was 166 mGy. There was a significant reduction in fluoroscopy time and x-ray exposure from 5.1 minutes with classic C-arm use to 3.1 minutes when with O-arm use without additional time required for positioning the system.

Conclusion:

With this new intraoperative system, the overall surgical and fluoroscopy times can be further reduced in the near future.

Clinical and methodological precision of spinal navigation assisted by 3D intraoperative O-arm radiographic imaging

Matthias F. Oertel, M.D, et al

Department of Neurosurgery, University Hospital Giessen and Marburg GmbH, Giessen, Germany

Spine J. 2011 April

Abstract

Objective:

In recent years, the importance of intraoperative navigation in neurosurgery has been increasing. Multiple studies have proven the advantages and safety of computer-assisted spinal neurosurgery. The use of intraoperative 3D radiographic imaging to acquire image information for navigational purposes has several advantages and should increase the accuracy and safety of screw guidance with navigation. The aim of this study was to evaluate the clinical and methodological precision of navigated spine surgery in combination with the O-arm multidimensional imaging system.

Methods:

Thoracic, lumbar, and sacral pedicle screws that were placed with the help of the combination of the O-arm and StealthStation TREON plus navigation systems were analyzed. To evaluate clinical precision, 278 polyaxial pedicle screws in 139 vertebrae were reviewed for medial or caudal perforations on coronal projection. For the evaluation of the methodological accuracy, virtual and intraoperative images were compared, and the angulation of the pedicle screw to the midsagittal line was measured.

Results:

Pedicle perforations were recorded in 3.2% of pedicle screws. None of the perforated pedicle screws damaged a nerve root. The difference in angulation between the actual and virtual pedicle screws was $2.8^\circ \pm 1.9^\circ$.

Conclusion:

The use of the StealthStation TREON plus navigation system in combination with the O-arm system showed the highest accuracy for spinal navigation compared with other studies that used traditional image acquisition and registration for navigation.

Computer tomography assessment of pedicle screw placement in lumbar and sacral spine: comparison between free-hand and O-arm[®] based navigation techniques

J. Silbermann, F. Riese, Y. Allam, T. Reichert, H. Koeppert and M. Gutberlet
Department of Spine Surgery, Park-Krankenhaus, Leipzig, Germany

Eur Spine J (2011)

Abstract

Transpedicular screw fixation has been accepted worldwide since Harrington et al. first placed pedicle screws through the isthmus. In vivo and in vitro studies indicated that pedicle screw insertion accuracy could be significantly improved with image-assisted systems compared with conventional approaches. The O-arm is a new generation intraoperative imaging system designed without compromise to address the needs of a modern OR like no other system currently available. The aim of our study was to check the accuracy of O-arm based and S7-navigated pedicle screw implants in comparison to free-hand technique described by Roy-Camille at the lumbar and sacral spine using CT scans.

The material of this study was divided into two groups, free-hand group (group I) (30 patients; 152 screws) and O-arm group (37 patients; 187 screws). The patients were operated upon from January to September 2009. Screw implantation was performed during PLIF or TLIF mainly for spondylolisthesis, osteochondritis and post-laminectomy syndrome.

The accuracy rate in our work was 94.1% in the free-hand group compared to 99% in the O-arm navigated group. Thus it was concluded that free-hand technique will only be safe and accurate when it is in the hands of an experienced surgeon and the accuracy of screw placement with O-arm can reach 100%.

A Comparison of CT-based Navigation Techniques for Minimally Invasive Lumbar Pedicle Screw Placement

Wood, Martin FRACS, MBChB* Mannion, Richard PhD, FRCS
The Mater Private Hospital Brisbane, Queensland, Australia.

*Journal of Spinal Disorders
& Techniques, February 2011*

Abstract

Study Design:

A comparison of 2 surgical techniques.

Objective:

To determine the relative accuracy of minimally invasive lumbar pedicle screw placement using 2 different CT-based image-guided techniques.

Summary of Background:

Three-dimensional intraoperative fluoroscopy systems have recently become available that provide the ability to use CT-quality images for navigation during image-guided minimally invasive spinal surgery. However, the cost of this equipment may negate any potential benefit in navigational accuracy. We therefore assess the accuracy of pedicle screw placement using an intraoperative 3-dimensional fluoroscope for guidance compared with a technique using preoperative CT images merged to intraoperative 2-dimensional fluoroscopy.

Methods:

Sixty-seven patients undergoing minimally invasive placement of lumbar pedicle screws (296 screws) using a navigated, image-guided technique were studied and the accuracy of pedicle screw placement assessed. Electromyography (EMG) monitoring of lumbar nerve roots was used in all.

Group 1: 24 patients in whom a preoperative CT scan was merged with intraoperative 2-dimensional fluoroscopy images on the image-guidance system. Group 2: 43 patients using intraoperative 3-dimensional fluoroscopy images as the source for the image guidance system. The frequencies of pedicle breach and EMG warnings (indicating potentially unsafe screw placement) in each group were recorded.

Results:

The rate of pedicle screw misplacement was 6.4% in group 1 vs 1.6% in group 2 ($P=0.03$). There were no cases of neurologic injury from suboptimal placement of screws. Additionally, the incidence of EMG warnings was significantly lower in group 2 (3.7% vs. 10% ($P=0.03$)).

Conclusion:

The use of an intraoperative 3-dimensional fluoroscopy system with an image-guidance system results in greater accuracy of pedicle screw placement than the use of preoperative CT scans, although potentially dangerous placement of pedicle screws can be prevented by the use of EMG monitoring of lumbar nerve roots.

Intraoperative, full-rotation, three-dimensional image (O-arm)–based navigation system for cervical pedicle screw insertion- Clinical Article

Yoshimoto Ishikawa et al. Department of Orthopedic Surgery, Spine Center, Konan Kosei Hospital, Takaya Chou, Konan City, Japan

Journal of Neurosurgery: Spine, Nov 2011

Abstract

Object:

The aim of this study was to retrospectively evaluate the reliability and accuracy of cervical pedicle screw (CPS) placement using an intraoperative, full-rotation, 3D image (O-arm)–based navigation system and to assess the advantages and disadvantages of the system.

Methods:

The study involved 21 consecutive patients undergoing posterior stabilization surgery of the cervical spine between April and December 2009. The patients, in whom 108 CPSs had been inserted, underwent screw placement based on intraoperative 3D imaging and navigation using the O-arm system. Cervical pedicle screw positions were classified into 4 grades, according to pedicle-wall perforations, by using postoperative CT.

Results:

Of the 108 CPSs, 96 (88.9%) were classified as Grade 0 (no perforation), 9 (8.3%) as Grade 1 (perforations < 2 mm, CPS exposed, and < 50% of screw diameter outside the pedicle), and 3 (2.8%) as Grade 2 (perforations between ≥ 2 and < 4 mm, CPS breached the pedicle wall, and > 50% of screw diameter outside the pedicle).

No screw was classified as Grade 3 (perforation > 4 mm, complete perforation). No neurovascular complications occurred because of CPS placement.

Conclusion:

The O-arm offers high-resolution 2D or 3D images, facilitates accurate and safe CPS insertion with high-quality navigation, and provides other substantial benefits for cervical spinal instrumentation. Even with current optimized technology, however, CPS perforation cannot be completely prevented, with 8.3% instances of minor violations, which do not cause significant complications, and 2.8% instances of major pedicle violations, which may cause catastrophic complications. Therefore, a combination of intraoperative 3D image–based navigation with other techniques may result in more accurate CPS placement.

Use of a quantitative pedicle screw accuracy system to assess new technology: Initial studies on O-arm navigation and its effect on the learning curve of percutaneous pedicle screw insertion.

Joseph A. Sclafani, MD et al. Department of Orthopaedic Surgery, University of California, San Diego, Center for Minimally Invasive Surgery at Alvarado Hospital CA, San Diego.

SAS Journal, September 2011

Abstract

Background:

A quantitative screw accuracy system is proposed that allows for high-fidelity discrimination between various methods of pedicle screw insertion. Our purpose was to study the utility of a quantitative screw accuracy scoring system to assess new imaging technologies and their effects on the minimally invasive spine learning curve.

Methods:

By use of a hypothetical "perfect screw," a scoring system is proposed that may be used to compare the position of a small number of screws inserted according to a desired optimal position. This study incorporates a retrospective review of imaging studies for 10 patients who underwent percutaneous pedicle screw placement with either navigation-assisted O-arm imaging or navigation-assisted C-arm imaging. For the learning-curve portion of the study, 2 cadaveric adult torsos were used for instrumentation. Computed tomography imaging studies were used in both studies to assess screw position in the pedicle and vertebral body in relation to an optimal screw by use of a quantitative scoring system to rate accuracy.

Results:

The quantitative scoring system allowed a statistically significant accuracy difference to be ascertained between 2 different technologies using fewer data points than previously published methods. When this screw scoring system is applied to minimally invasive percutaneous pedicle screw insertion, an optimal screw position can be achieved with greater accuracy through navigation-assisted technology (O-arm with computer-assisted navigation). When the O-arm with computer-assisted navigation was used by a novice surgeon learning the technique of percutaneous screw insertion, screws were inserted in a shorter period without loss of accuracy. In contrast, use of the traditional C-arm fluoroscopy leads to a loss of accuracy with faster insertion times. Increased accuracy can be seen clinically when compared with fluoroscopic navigation.

Conclusion:

The use of a quantitative scoring system allows for rapid assessment of screw accuracy. As additional technologies and new teaching techniques for pedicle screw insertion are developed, this scoring system may be useful as an early assessment tool.

Navigated placement of iliac bolts: description of a new technique.

Garrido BJ, Wood KE. Lake Norman Orthopedic Spine Center, 170 Medical Park Rd, Suite 102, Mooresville, NC 28117

Spine J. 2011 April

Abstract

Background Context:

Image navigation has improved the safety and ability to perform complex spinal procedures where visibility is not optimal or anatomic deformity is present. Numerous published studies are available demonstrating its effectiveness in improved pedicle screw placement in complex multiplanar deformities. Studies have also demonstrated image navigation technology versatility; however, stabilization of the lumbopelvic junction with navigated iliac bolt fixation has not been reported.

Purpose:

To describe an innovative versatile application of image navigation technology in spine surgery. We examine the safety, accuracy, and effectiveness of navigated iliac bolt placement while minimizing challenges associated with current techniques.

Study Design: Patient Sample:

Five patients requiring lumbopelvic fixation for multiple indications, including lumbosacral pseudoarthrosis, complex sacral fracture patterns, compromised revision sacral fixation, and as an adjunct to degenerative deformity with multilevel fusion, underwent navigated iliac bolt placement.

Outcome Measures:

Accurate placement was verified using intraoperative computed tomography (CT) imaging using O-ARM (Medtronic, Inc.) after placement.

Methods:

Five patients requiring lumbopelvic fixation have undergone navigated iliac bolt placement using Medtronic Stealth Station Treon in conjunction with the O-ARM (Medtronic, Inc.). A right percutaneous posterior superior iliac spine (PSIS) reference frame was placed at the superior lateral margin of the PSIS, and bilateral iliac bolts were placed via navigation using both the anatomic and traditional surgical techniques. Both techniques were performed without direct notch palpation and minimal soft-tissue exposure. Postplacement intraoperative CT imaging was obtained to confirm position and trajectory of the bolts using O-ARM (Medtronic, Inc.).

Results:

Ten iliac bolts were successfully placed in five patients. Intraoperative CT demonstrated ideal iliac screw bone placement projecting within 2 cm over sciatic notch, between pelvic tables. With image navigation, both anatomic and traditional iliac bolt placement techniques were performed with less surgical exposure, no radiation exposure, and complete accuracy using image navigation techniques with a percutaneous reference frame. The percutaneous reference frame placed in the superior lateral PSIS did not cause any interference with our navigated trajectory or bolt.

Conclusion:

Image-navigated iliac fixation allows for safe and accurate placement of bilateral iliac bolts without PSIS percutaneous reference frame interference. Image guidance eliminates fluoroscopic radiation exposure and extensive soft-tissue dissection and facilitates both traditional and anatomic iliac bolt placement techniques.

Use of intraoperative computed tomography scanning in determining the magnitude of arthroscopic osteochondroplasty

Mofidi A, Shields JS, Tan JS, Poehling GG, Stubbs AJ.

Arthroscopy. 2011 Jul

Abstract

Femoroacetabular impingement has recently become a recognized cause of disability and hip arthritis. Hip arthroscopy and femoroacetabular reshaping have been performed to treat this condition. Quantification of the excess femoral and acetabular bone requiring resection has been challenging with the less invasive arthroscopic technique. We describe the use of intraoperative computed tomography assessing osteochondroplasty during arthroscopic surgery to treat cam- and pincer-type femoroacetabular impingement. We also describe the technical steps and present the important radiologic findings we have been able to visualize.

We found intraoperative computed tomography scanning to be a reliable and reproducible method of assessing the quality of femoroacetabular impingement surgery. We believe that femoroacetabular impingement surgery can be assessed intraoperatively by use of computed tomography scanning where corrections can be made if necessary.

O-arm based spinal navigation and intraoperative 3D-imaging: first experiences

Gonschorek S. Hauck U. Spiegl T. Weis

Department of Spinal Surgery, Trauma Center, BGU-Murnau, Germany

Eur J Trauma Emerg Surg, March 2011

Abstract

Since the first use of instrument-tracking techniques in the early 1990s, image-guided technologies became a leading topic in all branches of spine surgery. Today, navigation is a widely available tool in spine surgery and has become a part of clinical routine in many centers for a large variety of indications. Spinal navigation may not only contribute to more precision during surgery, but it may also reduce radiation exposure and fluoroscopy time, with advantages not only for the patient but also for the operating room personnel. Different registration algorithms have been developed differing in terms of the type of image data used by the navigation system (preoperatively acquired computed tomography [CT] images, intraoperatively acquired fluoroscopy images) and the way virtual and physical reality is matched.

There is a tendency toward a higher accuracy for 3D fluoroscopy-based Registration algorithms. The O-arm represents a new flat-panel technology with the source and detector moving in a 360 arc around the patient. In combination with the Stealth station system, navigation may start immediately after automated registration with already referenced instruments. After instrumentation, an additional scan may confirm intraoperatively the correct positioning of the instrumentation. The first experiences with the system are described in this paper.

Use of O-arm for spinal surgery in academic institution in India: Experience from JPN apex trauma centre

Pankaj Ailawadhi et al

Department of Neurosurgery, JPN Apex Trauma Centre, All India Institute of Medical Sciences, New Delhi, India

Neurology India 2011

Abstract

There is a relatively high incidence of screw misplacement during spinal instrumentation due to distortion of normal anatomy following spinal trauma. The O-arm® is the next-generation spinal navigation tool that provides intraoperative 3-D imaging for complex spine surgeries. In this prospective study over 1-month period, 25 patients (mean age 29.16 years (range 7-58 years), 22 (88%) males) with spinal injury who underwent spinal instrumentation under O-arm® guidance were included.

Fall from height (64%) was the most common etiology seen in 16 patients. The majority (68%) had dorsolumbar fractures. Spinal canal compromise was seen in 21 patients (84%). Ten patients (40%) had American Spinal Injury Association (ASIA) grade A injuries, two patients (8%) had grade B, five patients (20%) had grade C, four patients (16%) each had grade D, and grade E injuries.

A total of 140 screws were inserted under O-arm guidance. Of these, 113 (81%) were dorsolumbar pedicle screws, 2 were odontoid screws, 12 were anterior cervical screws, and 12 screws (48%) were lateral mass screws. Mean duration of surgery was 4.5 h with a mean blood loss of 674 mL. The mean postoperative stay was 6.3 days. None of the patients had screw misplacement or canal breach. No patient deteriorated in ASIA grade postoperatively. The system was rated as excellent for ease of use by all faculty using the system. Accurate screw placement provides better patient safety and reduces the in hospital stay thereby leading early patient mobilization and may reduce the cost incurred in patient management.

Evaluation of the rate of decompression in anterior cervical corpectomy using an intra-operative computerized tomography scan (O-arm[®] system)

Francesco Costa et al

Neurosurgery Department- Istituto Clinico Humanitas,
Istituto IRCCS Galeazzi Milan, Italy

European Spine Journal 2011

Abstract

Object:

The purpose of this study was to evaluate the efficacy of intra-operative computerized tomography (CT) scanning in the analysis of bone removal accuracy during anterior cervical corpectomy, in order to allow any necessary immediate correction in the event of inadequate bone removal.

Methods:

From September 2009 to December 2010 we performed an intra-operative (CT) scan using the O-Arm[™] Image system to assess the rate of central and lateral decompression in all patients treated for cervical spondylotic myelopathy by anterior cervical corpectomy and fusion.

Results:

Out of a population of 187 patients admitted to our department, with a diagnosis of myelopathy due to spondylotic degenerative cervical stenosis, 15 patients underwent a surgical treatment with anterior cervical corpectomy and fusion. There were nine males (60%) and six females (40%); the mean age was 52.4 years, ranging from 41 to 57 years.

The pre-operative radiologic investigations (MRI and CT scans) revealed in the nine patients (60%) the extent of the compression to one vertebral body (C4 one case, C5 four cases, C6 four cases), while in the six cases (40%) the compression regarded two vertebral body (C3 and C4 one case, C4 and C5 two cases, C5 and C6 three cases). During surgery, when the decompression was judged completely, a CT scan was performed: in 11 cases (73.3%) the decompression was considered adequate, while in four cases (26.7%) it was deemed insufficient and the surgical strategy was changed in order to optimize the bone removal. In these cases an additional scan was taken to prove the efficacy of decompression, achieved in all patients.

Conclusion:

Intra-operative CT scan performed during cervical corpectomy is a really useful tool in helping to ensure complete bone removal and the adequacy of surgery. The O-arm[™] Image system grants optimal image quality, allowing correctly assessing the rate of decompression and, in any case of doubt, allows an intra-operative evaluation of the final correct positioning of the graft.

The Accuracy of Intraoperative O-arm Images for the Assessment of Pedicle Screw Position.

Santos ER, Ledonio CG, Castro CA, Truong WH, Sembrano JN.
Department of Orthopaedics, University of Minnesota

Spine 2011 Jun

Abstract

Study Design: Human cadaveric study

Objective: The objective of the study was to determine the accuracy of intraoperative O-arm images in determining pedicle screw position using open dissection as the gold standard.

Summary of Background Data: Pedicle screws are widely used in the treatment of various spinal disorders. Post-operative CT scans are the imaging gold standard to detect pedicle screw malposition. However, a second procedure is necessary if such malpositioned screws have to be revised. The O-arm is an intraoperative scanner that allows revision of a screw without having to return the patient to the OR for a separate procedure. No previous studies have looked at the accuracy of intraoperative O-arm images in determining pedicle screw position.

Methods: This factorial validation study utilized 9 cadavers in a comparison of intraoperative O-arm images and the dissection gold standard. Four hundred sixteen screws were inserted using three-dimensional image (O-arm) guidance from C2 to S1. The screw positions were randomized into three groups:

“IN” (fully contained within the pedicle), “OUT-lateral” or “OUT-medial”. After screw insertion, O-arm images were obtained and reviewed in a blinded fashion by three independent observers. Dissection identified the true position of the screws. Specificity, sensitivity, positive predictive value (PPV) and negative predictive value (NPV) were calculated using dissection results as the gold standard. The interobserver reliability was also determined.

Results: The overall accuracy, specificity, sensitivity, PPV, and NPV of O-arm images for the thoracic and lumbar spine were 73%, 76%, 71%, 74%, and 72%, respectively. Accuracy of surgeon perception in the cervical spine was significantly less than in the thoracic and lumbosacral spine. There was substantial interobserver agreement between the three readers.

Conclusion: Intraoperative O-arm images accurately detect significant pedicle screw violations in the thoracic and lumbosacral spine, but are less accurate for the cervical spine.

O-arm guided balloon kyphoplasty: preliminary experience of 16 consecutive patients

Schils F.

Department of Neurosurgery, Clinique Saint Joseph, Liège, Belgium

Acta Neurochir Suppl. 2011

Abstract

Balloon kyphoplasty is now widely used for the treatment of vertebral compression fractures. Excellent pain relief is achieved with cement injection, but the safety of the procedure relies on excellent radiological exposure. The balloon kyphoplasty technique is usually performed using one or two C-Arm devices to allow correct antero-posterior (AP) and lateral view throughout the surgical procedure. By definition, this minimal invasive spine surgery is associated with radiation exposure for both the patient and the surgeon. In our center, we recently moved from this way of proceeding to the use of an O-Arm image guidance system to perform cement augmentation in vertebral fractures.

To our knowledge, there is no clinical series describing the O-arm use in a balloon kyphoplasty procedure published in the scientific literature. We prospectively evaluate on 16 consecutive patients, the feasibility of the O-Arm guided kyphoplasty procedure with the original, usual tools, and we measured the fluoroscopy time and the X-ray exposure. We didn't experience any device related problem and demonstrated a significant reduction of X-ray exposure and time of fluoroscopy. We believe that using this new intraoperative system, the overall time of surgery and fluoroscopy could still be reduced in a near future.

Validity of surgeon perception of navigated pedicle screw position: a cadaveric study.

Santos ER, Ledonio CG, Castro CA, Truong WH, Sembrano JN.
Department of Orthopaedics, University of Minnesota

Spine 2011 Jul

Abstract

Study Design:

Human Cadaveric Experimental Study.

Objective:

To determine the validity of surgeon perception of pedicle screw position inserted using intraoperative three-dimensional (O-arm) image-guided screw insertion.

Summary of Background Data:

A surgeon's ability to detect pedicle wall violations intraoperatively is crucial for optimal pedicle screw placement. Accuracy of use of a probe or sound to assess pedicle breach is not optimal and may require experience. Intraoperative navigation has been shown to improve screw placement accuracy. It has not been shown, however, whether navigation in combination with screw tract palpation can further increase the surgeon's ability to detect a pedicle breach in pedicle screw placement in the cervical, thoracic, and lumbosacral spine.

Methods:

Four hundred eighteen screws were inserted using three-dimensional image guidance transpedicularly from C2 to S1 in 10 fresh frozen cadavers. Screw tracts were created using navigation and then probed. After probing, the surgeon stated whether he perceived that the screw would be in, out laterally, or out medially. After screw insertion for all the levels, open dissection was then performed to determine the actual pedicle screw position. The surgeon's perception of screw position was compared to the dissection results.

Results:

The overall specificity, sensitivity, positive predictive value, and negative predictive value of the surgeon perception of pedicle screw position were 87%, 80%, 78% and 88%, respectively. Accuracy of surgeon perception of pedicle screw position was significantly less than in the cervical spine when compared with thoracic and lumbosacral spine.

Conclusion:

Surgeon perception of a navigated pedicle screw position is accurate in the thoracic and lumbar spine. Detection of pedicle screw violations by surgeon perception in the cervical spine is less accurate and does not reliably lead to accurate screw placement.

Modified transcorporeal anterior cervical microforaminotomy assisted by O-arm-based navigation: a technical case report.

Kim JS, Eun SS, Prada N, Choi G, Lee SH.

Wooridul Spine Hospital, 47-4 Chungdam-dong, Gangnam-gu, Seou

Eur Spine J. 2011 Jul

Abstract

This study was done to present our surgical experience of modified transcorporeal anterior cervical microforaminotomy (MTACM) assisted by the O-arm-based navigation system for the treatment of cervical disc herniation. We present eight patients with foraminal disc herniations at the C5-C6, C6-C7, and C7-T1 levels. All patients had unilateral radicular arm pain and motor weakness. The inclusion criteria for the patients were the presence of single-level unilateral foraminal cervical disc herniation manifesting persistent radiculopathy despite conservative treatment. Hard disc herniation, down-migrated disc herniation, concomitant moderate to severe bony spur and foraminal stenosis were excluded. We performed MTACM to expose the foraminal area of the cervical disc and removed the herniated disc fragments successfully using O-arm-based navigation.

Postoperatively, the patients' symptoms improved and there was no instability during the follow-up period. MTACM assisted by O-arm-based navigation is an effective, safe, and precise minimally invasive procedure that tends to preserve non-degenerated structures as much as possible while providing a complete removal of ruptured disc fragments in the cervical spine.

Image-guided placement of occipitocervical instrumentation using a reference arc attached to the headholder.

Nottmeier EW, Young PM.

Department of Neurosurgery, Mayo Clinic, Jacksonville, FL

Neurosurgery. 2010 Mar

Abstract

Objective:

To develop a safe and accurate method of image-guided placement of instrumentation in the upper cervical spine and occiput in which the reference arc is fixed to the headholder.

Methods:

The authors describe a technique for placing screws at the occipital, C1, and C2 levels using 3-dimensional image guidance in which the reference arc is fixed to the headholder. Technical details are discussed as well as modifications to the technique to maximize navigation accuracy and decrease the need for re-registration. One of 2 paired systems, the BrainLAB Vector Vision system (BrainLAB Inc., Westchester, IL) used in conjunction with the Arcadis Orbic Isocentric C-arm (Siemens Medical Solutions, Erlangen, Germany) or the Stealth Treon system (Medtronic, Littleton, MA) paired with the O-arm (Medtronic), was used for image guidance in this study. A total of 18 patients had 82 screws placed at the occipital, C1, or C2 level using this technique. An independent radiologist interpreted postoperative computed tomographic scans of these patients and graded the screws for bony breach.

Results:

No complications resulted from the use of image guidance or from the placement of instrumentation. Postoperative computed tomography revealed 1 screw with a minimal breach of the outer lamina of C2. Another screw was replaced intraoperatively secondary to a minimal bony breach. No other bony breach occurred.

Conclusion:

This technique allows safe and accurate placement of instrumentation in the posterior occipitocervical junction using 3-dimensional image guidance in which the reference arc is attached to the headholder.

Three-dimensional image-guided placement of S2 alar screws to adjunct or salvage lumbosacral fixation.

Nottmeier EW, Pirris SM, Balseiro S, Fenton D. Department of Neurosurgery, Mayo Clinic, Jacksonville, FL - *Spine J.* 2010 Jul

Abstract

Background Context: Achieving fusion across the lumbosacral junction is challenging because of the unfavorable biomechanics associated with ending a fusion at this level. Bicortical placement of S1 pedicle screws can increase the construct stability at the lumbosacral junction; however, construct failure and pseudoarthrosis can still result. Iliac screws have been shown to increase the stiffness of lumbosacral constructs, but disadvantages include difficulty in connecting the iliac screw to adjacent sacral screws, painful screw loosening or prominence requiring removal, and the inability to place the screws in some patients with previous iliac crest autograft harvest.

Purpose: The purpose of the study is to describe a technique of S2 alar screw placement using three-dimensional image guidance.

Study Design/Setting:

The study design is a retrospective analysis.

Patient Sample: Twenty patients undergoing lumbosacral fusion had 32 screws placed using this technique.

Outcome Measures: An independent radiologist graded screw placement and lumbosacral fusion on thin-cut postoperative computed tomographic (CT) scans.

Methods: Image guidance in this study was accomplished with the Medtronic Stealth Station Treon (Medtronic Inc., Littleton, MA, USA) used in conjunction with the O-ARM (Medtronic Inc.). Indications for placement of S2 alar screws included the following:

to adjunct S1 pedicle screws in multilevel fusion cases; as an adjunct or alternative to S1 pedicle screws in pseudoarthrosis revision cases in which the S1 screws had loosened; as an alternative to S1 pedicle screws in cases where medial trajectory of an S1 pedicle screw was difficult to obtain because of a low-set lumbosacral junction; and a combination of the above. The entry point of the screw was typically chosen lateral and superior to the S2 dorsal foramen with the trajectory directed anterior, inferior, and lateral. Attempt was made to place the screw with the tip purchasing, but not penetrating through, the triangular area of cortical bone that can be found at the anterior, inferior, and lateral boundary of the sacral ala. An independent radiologist graded the placement of the screws on the intraoperative CT scan obtained with the O-ARM or on postoperative CT scans. Lumbosacral fusion was assessed on postoperative CT scans obtained at follow-up.

Results: No complications occurred in this study as a result of S2 alar screw placement or image guidance. Five screws did penetrate the anterior cortex of the sacrum, with no clinical consequence. At the time of abstract submission, 16 patients were able to have follow-up CT scans, 15 of which were graded as solid fusion at the lumbosacral junction by the grading radiologist.

Conclusion: Three-dimensional image guidance allows for safe placement of large S2 sacral alar screws that can provide additional biomechanical stability to lumbosacral constructs or serve as an alternate point of sacral fixation when S1 pedicle screws cannot be salvaged or placed in a medial trajectory.

Pedicle screw fixation under navigation guidance based on O-arm.

Jin-Sung Kim et al.

Department of Neurosurgery, Wooridul Spine Hospital . Korea

The internet Journal of Minimally Invasive Spinal Technology. 2010 Supplement

Abstract

Objectives:

The purpose of this study is to describe a surgical technique and the accuracy of pedicle screw fixation under navigation guidance based on O-arm.

Design:

Prospective study
Methods: Instrumentation using transpedicular screw fixation was performed using navigation guidance based on O-arm with 19 patients (78 screws). Evaluation of screw placement in every case was done on each instrumented vertebra by using intraoperative O-arm and plain X-ray. Screw placements were graded as good if the screws were placed in the central core of the pedicle and the cancellous portion of the body. Screw placements were graded as fair if the screws were placed slightly eccentrically, causing erosion of the pedicle cortex, and with less than a 2-mm perforation of the pedicular cortex. Screw placements were graded as poor if the screws were placed eccentrically with large portion of the screw extending outside the cortical margin of the pedicle and with more than a 2-mm perforation of the pedicular cortex, causing erosion of the pedicle cortex, and with less than a 2-mm perforation of the pedicular cortex.

Results:

1 patient was excluded due to connection error between O-arm and navigation. A total 72 pedicle screws were placed in 18 patients. 94.4% (68/72) were categorized as good; 5.6% (4/72), fair; and 0% were poor. All 4 fair screws were placed extending lateral margin of the pedicle without any neurologic complications. Conclusions: Aided by navigation guidance based on O-arm, surgeons can more safely navigate complex anatomy, and more accurately complete the procedure making this technology particularly helpful for pedicle screw fixation. This technique also makes complete avoidance of radiation exposure to surgeons while increasing accuracy and reliability of the surgical procedure for pedicle screw fixation

Improving accuracy and reducing radiation exposure in minimally invasive lumbar interbody fusion.

Wood MJ, Mannion RJ.

Department of Neurosurgery, The Princess Alexandra Hospital, Brisbane, Australia

J Neurosurg Spine. 2010 May

Abstract

Objective:

The authors assessed the accuracy of placement of lumbar transpedicular screws by using a computer-assisted, imaged-guided, minimally invasive technique with continuous electromyography (EMG) monitoring.

Methods:

This was a consecutive case series with prospective assessment of procedural accuracy. Forty-seven consecutive patients underwent minimally invasive lumbar interbody fusion and placement of pedicle screws (PSs). A computer-assisted image guidance system involving CT-based images was used to guide screw placement, while EMG continuously monitored the lumbar nerve roots at the operated levels with a 5-mA stimulus applied through the pedicle access needle. All patients underwent CT scanning to determine accuracy of PS placement. All episodes of adjusted screw trajectory based on positive EMG responses were recorded. Pedicle screw misplacement was defined as breach of the pedicle cortex by the screw of more than 2 mm.

Results:

Two hundred twelve PSs were inserted in 47 patients. The screw misplacement rate was 4.7%. One patient experienced new postoperative radiculopathy resulting from a sacral screw that was too long, with lumbosacral trunk impingement. The trajectory of the pedicle access needle was altered intraoperatively on 20 occasions (9.4% of the PSs) based on positive EMG responses, suggesting that nerve root impingement may have resulted from these screws had the EMG monitoring not been used.

Conclusion:

The combination of computer-assisted navigation combined with continuous EMG monitoring during pedicle cannulation results in a low rate of PS misplacement, with avoidance of screw positions that might cause neural injury. Furthermore, this technique allows reduction of the radiation exposure for the surgical team without compromising the accuracy of screw placement.

Minimally invasive pedicle screw fixation utilizing O-arm fluoroscopy with computer-assisted navigation: Feasibility, technique, and preliminary results.

Park P, Foley KT, Cowan JA, Marca FL.

Department of Neurosurgery, University of Michigan Health System, Ann Arbor, MI, USA

Surg Neurol Int. 2010 Aug

Abstract

Background:

Pedicle screw misplacement is relatively common, with reported rates ranging up to 42%. Although computer-assisted image guidance (CaIG) has been shown to improve accuracy in open spinal surgery, its use in minimally invasive procedures has not been as well evaluated. We present our technique and review the results from a cohort of patients who underwent minimally invasive lumbar pedicle screw placement utilizing the O-arm imaging unit in conjunction with the StealthStation Treon System.

Methods:

A retrospective review of patients who underwent minimally invasive pedicle screw fixation with CaIG was performed. Eleven consecutive patients were identified and all were included. Nine patients underwent a single-level transforaminal lumbar interbody fusion. Two patients underwent multi-level fusion. Inaccurate pedicle screw placement was determined by postoperative computed tomography (CT) and graded as 0-2, 2-4, 4-6, or 6-8 mm.

Results:

A total of 52 screws were placed. Forty screws were inserted in eight patients who had postoperative CT, and a misplacement rate of 7.5% was noted including one lateral and two medial breaches. All breaches were graded as 0-2 mm and were asymptomatic. In the remaining three patients, post-instrumentation O-arm imaging did not demonstrate pedicle screw misplacement.

Conclusion:

Although this initial study evaluates a relatively small number of patients, minimally invasive pedicle screw fixation utilizing the O-arm and StealthStation for CaIG appears to be safe and accurate.

An assistive image-guided surgical robot system using o-arm fluoroscopy for pedicle screw insertion: preliminary and cadaveric study.

Kim S, Chung J, Yi BJ, Kim YS.

Hanyang University, Seoul. Kyushu University, Fukuoka, Japan

Neurosurgery. 2010 Dec

Abstract

Background:

The biplane fluoroscopy guided robot system (BFRS) was developed for surgical robotic systems, minimally invasive surgeries, and cooperative robotic systems, as well as enhanced surgical planning and navigation with preoperative and intraoperative image data.

Objective:

To propose a novel surgical robot system for percutaneous pedicle screw insertion.

Methods:

The BFRS consists of an O-shaped biplane fluoroscope (O-arm), a surgical planning and operating system, and an assistive robot. Each part of the BFRS has a role in conducting percutaneous pedicle screw placements. To evaluate BFRS accuracy, each part was analyzed, and to assess the safety and feasibility of percutaneous pedicle screw insertions with the BFRS, cadaveric studies involving 14 levels in the thoracic and lumbar spine regions were conducted on 2 cadavers.

Results:

Errors in each part of the system and within the entire system were evaluated. The accuracy of generating coordinates using O-arm images was 0.30 ± 0.15 mm. The robot demonstrated a duplication value of $4.97 \mu\text{m}$ RMS and an accuracy of 0.358 mm RMS. Total system error was 1.38 ± 0.21 mm. The results of the cadaveric studies show that inserted pedicular screws were adequately located within the spine with no unexpected malpositioning of the screws. The axial angle difference between planned and postoperative data was $2.45 \pm 2.56^\circ$, and the sagittal angle difference was $0.71 \pm 1.21^\circ$.

Conclusion:

The BFRS might be helpful in improving the accuracy of percutaneous pedicular screw insertion procedures. In the future, we will attempt to improve the accuracy and reliability of the BFRS and to determine new clinical applications for the BFRS.

Minimally invasive image-guided direct repair of bilateral L-5 pars interarticularis defects.

Brennen, R, et al.

Technical Note. Neurosurgery Focus 2008

Abstract

Objective:

Lower back pain from spondylolysis historically has been treated with a variety of options ranging from conservative care to open fusion.

The authors describe the novel technique of minimally invasive bilateral pars interarticularis screw placement by utilizing intraoperative 3D imaging and frameless navigation in a 17-year-old male athlete. This technique is a modification of the open technique first described in 1970 by Buck and has the advantages of minimal dissection requirements with improved screw trajectory visualization.

The patient's postoperative course is discussed, followed by a brief literature review of pars interarticularis defect treatment.

Conclusion:

We described a modified form of the Buck screw procedure with a minimally invasive, image-guided method of pars interarticularis fixation. The utilization of image guidance simplifies the otherwise difficult visualization required for pars interarticularis screw placement and allows minimal skin and muscle dissection, which may translate into a more rapid postoperative recovery. Future applications of frameless navigation in the spine may allow such uncommon hardware applications to be both successful and less invasive.

Computer-Assisted Surgical Planning and Image-Guided Surgical Navigation in Refractory Adult Scoliosis Surgery: Case Report and Review of the Literature

Metz, LN & Burch S.,

Spine Journal 33(9): E287-E292

Abstract

Objective:

Objective: In this case report, we present the utility of computer-assisted surgical planning and image-guided surgical navigation in the planning and execution of a major osteotomy to correct severe kyphoscoliosis.

Summary of Background Data:

Computer-assisted surgical planning is useful to appreciate the three-dimensional nature of scoliotic deformities and allows for operative maneuvers to be simulated on a computer before their implementation in the operating room. Imageguided surgical navigation improves surgical accuracy and can help translate a virtual surgical plan to the operative setting.

Methods:

We report the case of a 38- year-old woman with severe, congenital kyphoscoliosis refractory to many previous surgeries, who presents with moderate progressive myelopathy and severe pain attributable to a sharp angular deformity at T12. Three-dimensional computed tomography reconstruction and computer-assisted surgical planning were used to determine the optimal corrective osteotomy. The surgical plan was translated to the operating room where a posterior vertebrectomy and instrumented correction were executed with the aid of image-guided surgical navigation.

Results:

The osteotomy was safely performed resulting in improved sagittal and coronal alignments, as well as, correction of the sharp kyphoscoliotic deformity at the thoracolumbar junction. At 6-month follow-up, the patient's myelopathy and pain had largely resolved and she expressed high satisfaction with the procedure.

Conclusion:

We advocate this novel application of virtual surgical planning and intraoperative surgical navigation to improve the safety and efficacy of complex spinal deformity corrections.

Intraoperative computed tomography for deep brain stimulation surgery: technique and accuracy assessment.

Shahlaie K, Larson PS, Starr PA.

University of California, San Francisco and San Francisco Veterans Affairs Medical Center, San Francisco, California, USA

Neurosurgery. 2011 Mar

Abstract

Background:

The efficacy of deep brain stimulation (DBS) is highly dependent on the accuracy of lead placement.

Objective:

To describe the use of intraoperative computed tomography (iCT) to confirm lead location before surgical closure and to study the accuracy of this technique.

Methods:

Fifteen patients underwent awake microelectrode-guided DBS surgery in a stereotactic frame. A portable iCT scanner (Medtronic O-arm) was positioned around the patient's head throughout the procedure and was used to confirm lead location before fixation of the lead to the skull. Images were computationally fused with preoperative magnetic resonance imaging (MRI), and lead tip coordinates with respect to the midpoint of the anterior commissure-posterior commissure line were measured. Tip coordinates were compared with those obtained from postoperative MRI.

Results:

iCT was integrated into standard frame-based microelectrode-guided DBS surgery with a minimal increase in surgical time or complexity. Technically adequate 2-dimensional and 3-dimensional images were obtained in all cases. Head positioning and fixation techniques that allow unobstructed imaging are described. Lead tip measurements on iCT fused with preoperative MRI were statistically indistinguishable from those obtained with postoperative MRI.

Conclusion:

iCT can be easily incorporated into standard DBS surgery, replaces the need for C-arm fluoroscopy, and provides accurate intraoperative 3-dimensional confirmation of electrode tip locations relative to preoperative images and surgical plans. iCT fused to preoperative MRI may obviate the need for routine postoperative MRI in DBS surgery. Technical nuances that must be mastered for the efficient use of iCT during DBS implantation are described.

Frameless deep brain stimulation using intraoperative O-arm technology

Adam P. Smith, M.D., and Roy A. E. Bakay, M.D.

Department of Neurosurgery, Rush University Medical Center, Chicago, Illinois

J Neurosurg / April 15, 2011

Abstract

Objective:

Correct lead location in the desired target has been proven to be a strong influential factor for good clinical outcome in deep brain stimulation (DBS) surgery. Commonly, a surgeon's first reliable assessment of such location is made on postoperative imaging. While intraoperative CT (iCT) and intraoperative MR imaging have been previously described, the authors present a series of frameless DBS procedures using O-arm iCT.

Methods:

Twelve consecutive patients with 15 leads underwent frameless DBS placement using electrophysiological testing and O-arm iCT. Initial target coordinates were made using standard indirect and direct assessment. Microelectrode recording (MER) with kinesthetic responses was performed, followed by microstimulation to evaluate the side-effect profile. Intraoperative 3D CT acquisitions obtained between each MER pass and after final lead placement were fused with the preoperative MR image to verify intended MER movements around the target area and to identify the final lead location. Tip coordinates from the initial plan, final intended target, and actual lead location on iCT were later compared with the lead location on postoperative MR imaging, and euclidean distances were calculated. The amount of radiation exposure during each procedure was calculated and compared with the estimated radiation exposure if iCT was not performed.

Results:

The mean euclidean distances between the coordinates for the initial plan, final intended target, and actual lead on iCT compared with the lead coordinates on postoperative MR imaging were 3.04 ± 1.45 mm ($p = 0.0001$), 2.62 ± 1.50 mm ($p = 0.0001$), and 1.52 ± 1.78 mm ($p = 0.0052$), respectively. The authors obtained good merging error during image fusion, and postoperative brain shift was minimal. The actual radiation exposure from iCT was invariably less than estimates of exposure using standard lateral fluoroscopy and anteroposterior radiographs ($p < 0.0001$).

Conclusion:

O-arm iCT may be useful in frameless DBS surgery to approximate microelectrode or lead locations intraoperatively. Intraoperative CT, however, may not replace fundamental DBS surgical techniques such as electrophysiological testing in movement disorder surgery. Despite the lack of evidence for brain shift from the procedure, iCT-measured coordinates were statistically different from those obtained postoperatively, probably indicating image merging inaccuracy and the difficulties in accurately denoting lead location. Therefore, electrophysiological testing may truly be the only means of precisely knowing the location in 3D space intraoperatively. While iCT may provide clues to electrode or lead location during the procedure, its true utility may be in DBS

Comparison of Intraoperative Portable CT Scanners in Skull Base and Endoscopic Sinus Surgery: Single Center Case Series

David B. Conley et al.

Northwestern University Feinberg School of Medicine, Chicago

Skull Base 2011

Abstract

Precise and safe management of complex skull base lesions can be enhanced by intraoperative computed tomography (CT) scanning. Surgery in these areas requires real-time feedback of anatomic landmarks.

Several portable CT scanners are currently available. We present a comparison of our clinical experience with three portable scanners in skull base and craniofacial surgery. We present clinical case series and the participants were from the Northwestern Memorial Hospital. Three scanners are studied: one conventional multidetector CT (MDCT), two digital flat panel cone-beam CT (CBCT) devices.

Technical considerations, ease of use, image characteristics, and integration with image guidance are presented for each device. All three scanners provide good quality images. Intraoperative scanning can be used to update the image guidance system in real time. The conventional MDCT is unique in its ability to resolve soft tissue.

The flat panel CBCT scanners generally emit lower levels of radiation and have less metal artifact effect. In this series, intraoperative CT scanning was technically feasible and deemed useful in surgical decision-making in 75% of patients.

Intraoperative portable CT scanning has significant utility in complex skull base surgery. This technology informs the surgeon of the precise extent of dissection and updates intraoperative stereotactic navigation.

Advancements in computed tomography management of chronic rhinosinusitis

Leung, Randy et al

American Journal of Rhinology & Allergy, 2011

Abstract

Background:

Advances in cone beam computed tomography (CBCT) technology have allowed for reduction in radiation dosages as well as the miniaturization of CT scanner units. This has given rise to new applications for CT scanning, including point-of-care (POC) in-office and intraoperative applications.

Methods:

A review of recent changes to radiological modalities as applied to otolaryngology-head and neck surgery was performed. A discussion of the physics, applications, and role of diagnostic imaging in the evaluation of chronic rhinosinusitis (CRS) is conducted.

Results:

The adaptation of cone beam technology has allowed for the practical implementation of CT scanning at the bedside, be it in the clinic or operating room setting.

Conclusion:

Given their relative low cost, ease of storage, and low-dose radiation exposure, POC-CT scanners have become an indispensable tool in the diagnosis and treatment of CRS. In the setting of increasing antibiotic costs, overtreatment with antibiotics, and fewer required return visits, POC-CT challenges the conventional role of empiric medical therapy before progression to imaging for the diagnosis of CRS.

Intraoperative use of the Medtronic O-arm for deep brain stimulation procedures.

Caire F, Gantois C, Torny F, Ranoux D, Maubon A, Moreau JJ.

Service de Neurochirurgie, Centre Hospitalier Universitaire de Limoges, Hôpital Dupuytren, Limoges, France.

Stereotact Funct Neurosurg. 2010

Abstract

The purpose of this study was to analyze the feasibility and utility of 3D imaging to help lead positioning during a deep brain stimulation (DBS) procedure. A bilateral subthalamic DBS procedure was conducted in 2 patients for idiopathic Parkinson's disease. Subthalamic nucleus targeting was based on preoperative stereotactic MRI.

We used the Medtronic O-arm to perform 2D-imaging control (frontal and lateral) as well as quick (<30 s) 3D acquisition. This allowed us to check the positioning of micro-macro electrodes and definite electrodes. 3D images were fused with postoperative CT to assess their accuracy, and with preoperative MRI to visualize the anatomical location of the electrodes.

3D imaging is a quick and safe method to ensure perioperative control of lead placement during DBS procedures.

Real-Time Intraoperative Computed Tomography to Assist Cochlear Implant Placement in the Malformed Inner Ear

Bloom, J, et al.

Otology & Neurotology January 2009

Abstract

Objective:

Cochlear implantation is increasingly being performed in children with inner ear malformations. In severe cochleovestibular anomalies, such as severe partitioning defects and common cavity dysplasia, positioning of the electrode array can be hazardous, with inadvertent placement into the internal auditory canal (IAC) or carotid canal being well known. We describe a case in which real-time intraoperative computed tomographic scanning was used to help achieve proper electrode positioning in a child with a severe malformation.

Patient:

Child with common cavity malformations undergoing cochlear implantation. Intervention: Intraoperative computed tomography used during implantation procedure.

Main Outcome Measure:

Use of technique in determining electrode position.

Results:

A 10-year-old patient with bilateral common cavity malformations presented with declining performance in a functioning implant placed 7 years earlier. The family elected implantation of the contralateral ear. Via a posterior labyrinthotomy approach, a straight array was placed into the common cavity. Intraoperative computed tomographic scanning was immediately performed on the operating room table, showing that the array was in the IAC. A second attempt with a different insertion angle also resulted in IAC placement. In a third attempt, the electrode was advanced as a loop, grasping the tip through an adjacent second labyrinthotomy. Computed tomography confirmed good position against the outer wall of the cavity.

Conclusion:

Real-time intraoperative computed tomography is a new technology with many potential applications in surgery. In our patient, it allowed rapid and accurate determination of electrode position and helped achieve ideal placement in a severely malformed inner ear.

Intraoperative Navigation for Minimally Invasive Resection of Periarticular and Pelvic Tumors

Karl Wu, MD; Nicholas P. Webber, MD; Russell A. Ward, MD; Kevin B. Jones, MD; R. Lor Randall, MD Huntsman Cancer Institute, Utah, USA.

ORTHOPEDICS May 2011

Abstract

The surgical approach to benign, metastatic, and some low-grade malignant tumors is often difficult due to their typically precarious locations. This article presents a series of cases where intraoperative stealth navigation was used to treat periarticular tumors. The use of paired point imaging with image fusion has made approaching tumors through an accurate and minimally invasive technique a viable option for the treatment of a subset of musculoskeletal tumors.

Conventional resection of periarticular and pelvic tumors of bone usually requires an extensive surgical approach to adequately visualize the tumor and protect the nearby neurovascular structures. When tumors in periarticular locations are encountered, dislocation of the affected joint may be necessary, putting periarticular and subchondral bone at risk for osseous necrosis and articular surfaces at risk of mechanical insult at the time of dislocation. While arthroscopic techniques may enable a minimally invasive mode of surgical approach in certain anatomic locations, this is not always feasible and can add additional operative time and morbidity to the patient. This article describes 5 cases where locally aggressive tumors in challenging periarticular anatomic locations were treated in a minimally invasive manner with the assistance of image fusion and paired-point registration.

Results:

All of the patients in this case series had an excellent Musculoskeletal Tumor Society Functional Score (range, 26–29) postoperatively. Basic demographic data and postoperative results are listed in the Table. Average follow-up was 8.8 months (range, 6–16 months). Musculoskeletal Tumor Society Functional Scores were satisfactory in all patients. Near-complete relief of preoperative symptoms was obtained in all patients. Excellent 3-D multiplanar visualization of the tumor was obtained in all patients, and minimal invasive approaches were completed successfully by using intraoperative navigation guidance. No surgery-related complications were encountered during any of the procedures. Average intraoperative blood loss was 78 mL (range, 10–100 mL). Average operative time was 92 minutes (range, 65–125 minutes).

Real-time intraoperative computed tomography assessment of quality of permanent interstitial seed implantation for prostate cancer.

Zelevsky MJ, et al.

Brachytherapy Service, Memorial Sloan-Kettering Cancer Center, New York, NY

Urology. 2010 Nov

Abstract

Objectives:

To evaluate the use of real-time kilovoltage cone-beam computed tomography (CBCT) during prostate brachytherapy for intraoperative dosimetric assessment and correcting deficient dose regions.

Methods:

A total of 20 patients were evaluated intraoperatively with a mobile CBCT unit immediately after implantation while still anesthetized. The source detector system was enclosed in a circular CT-like geometry with a bore that accommodates patients in the lithotomy position. After seed deposition, the CBCT scans were obtained. The dosimetry was evaluated and compared with the standard post-implantation CT-based assessment. In 8 patients, the deposited seeds were localized in the intraoperative CBCT frame of reference and registered to the intraoperative transrectal ultrasound images. With this information, a second intraoperative plan was generated to ascertain whether additional seeds were needed to achieve the planned prescription dose. The final dosimetry was compared with the postimplantation scan assessment.

Results:

The mean differences between the dosimetric parameters from the intraoperative CBCT and postimplant CT scans were $< .5\%$ for percentage of volume receiving 100% of the prescription dose, minimal dose received by 90% of the prostate, and percentage of volume receiving 150% of the prescription dose. The minimal dose received by 5% (maximal dose) of the urethra differed by 8% on average and for the rectum an average difference of approximately 18% was observed. After fusion of the implanted seed coordinates from the intraoperative CBCT scans to the intraoperative transrectal ultrasound images, the dosimetric outcomes were not significantly different from the postimplantation CT dosimetric results.

Conclusion:

Intraoperative CT-based dosimetric evaluation of prostate permanent seed implantation before anesthesia reversal is feasible and might avert misadministration of dose delivery. The dosimetric measurements using the intraoperative CBCT scans were dependable and correlated well with the postimplant diagnostic CT findings.

Optimization of Radiation Exposure and Image Quality of the Cone-beam O-arm Intraoperative Imaging System in Spinal Surgery.

Abul-Kasim K, Söderberg M, Selariu E, Gunnarsson M, Kherad M, Ohlin A.
Skåne University Hospital, Lund University, Malmö, Sweden.

J Spinal Disord Tech. 2011 Mar

Abstract

Study Design:

Retrospective study.

Objectives:

To optimize the radiation doses and image quality for the cone-beam O-arm surgical imaging system in spinal surgery.

Summary of Background:

Neurovascular compromise has been reported after screw misplacement during thoracic pedicle screw insertion. The use of O-arm with or without navigation system during spinal surgery has been shown to lower the rate of screw misplacement. The main drawback of such imaging surgical systems is the high radiation exposure.

Methods:

Chest phantom and cadaveric pig spine were examined on the O-arm with different scan settings: 2 were recommended by the O-arm manufacturer (120 kV/320 mAs, and 120 kV/128 mAs), and 3 low-dose settings (80 kV/80 mAs, 80 kV/40 mAs, and 60 kV/40 mAs). The radiation doses were estimated by Monte Carlo calculations. Objective evaluation of image quality included interobserver agreement in the measurement of pedicular width in chest phantom and assessment of screw placement in cadaveric pig spine.

Results:

The effective dose/cm for 120 kV/320 mAs scan was 13, 26, and 69 times higher than those delivered with 80 kV/80 mAs, 80 kV/40 mAs, and 60 kV/40 mAs scans, respectively. Images with 60 kV/40 mAs were unreliable. Images with 80 kV/80 mAs were considered reliable with good interobserver agreement when measuring the pedicular width (random error 0.38 mm and intraclass correlation coefficient 0.979) and almost perfect agreement when evaluating the screw placement (κ value 0.86).

Conclusions:

The radiation doses of the O-arm system can be reduced 5 to 13 times without negative impact on image quality with regard to information required for spinal surgery.

The perspectives of users and developers in designing and developing O-arm imaging system

Park MS, Chung CY, Kwon DG, Huh Y, Lee K, Lee KM.

Department of Orthopedic Surgery, Seoul National University Bundang Hospital

J Xray Sci Technol 2011

Abstract

A questionnaire survey was performed to investigate the different knowledge of radiation exposure, awareness and expectation for O-arm imaging system between the users (orthopaedic surgeons) and the developers (engineers). A total of 93 orthopaedic surgeons and 19 engineers participated and answered the questionnaire consisting of 18 items designed for this study.

The items were focused on knowledge, awareness, and expectation. Orthopaedic surgeons had higher scores for items of knowledge domains regarding radiation exposure than the engineers while the engineers were more sensitive to radiation hazards and adopted higher levels of radiation protection than orthopaedic surgeons in the awareness domain. Most engineers and orthopaedic surgeons answered that the requirements of diagnostic and intraoperative imaging systems differ.

Image resolution, a low radiation exposure, and the time required for image acquisition was the top three requirements of O-arm selected by engineers. On the other hand, the top three requirements according to orthopaedic surgeons were; image resolution, expediency, and spatial occupancy. User requirements need to be reflected in developing O-arm along with basic requirements such as image resolution and low radiation exposure.

Comparison Of Operator Radiation Exposure Between C-arm And O-arm Fluoroscopy For Orthopaedic Surgery

Moon Seok Park, Kyoung Min Lee, Boram Lee, et al.

Department of Orthopedic Surgery, Seoul National University Bundang Hospital

Radiation Protection Dosimetry April 2011

Abstract

The O-arm system has recently been introduced and has the capability of combined two-dimensional (2-D) fluoroscopy imaging and three-dimensional computed tomography imaging. In this study, an orthopaedic surgical procedure using C-arm and O-arm systems in their 2-D fluoroscopy modes was simulated and the radiation doses to susceptible organs to which operators can be exposed were investigated.

The experiments were performed in four configurations of the location of the X-ray source and detector. Shielding effects on the thyroid surface and the direct exposure delivered to the surgeon's hands were also compared. The results obtained show that the O-arm delivered higher doses to the sensitive organs of the operator in all configurations. The thyroid shield cut-off 89 % of the dose in the posteroanterior configuration of both imaging systems. Thus, the operators need to pay more attention to managing radiation exposure, especially when using the O-arm system

Dosimetric characterization of a cone-beam O-arm imaging system.

Zhang J, Weir V, Fajardo L, Lin J, Hsiung H, Ritenour ER.

Medical Physics Section, Department of Radiology, University of Minnesota,
Minneapolis, MN

J Xray Sci Technol. 2009

Abstract

This study compared patient dose and image quality of a mobile O-arm cone beam imaging system in the 3D scan acquisition mode to those of a 64 slice Computed Tomography (CT) imaging system. The investigation included patient dose, scattered radiation, and image quality measurements. The patient dose was measured using a 0.6 cc Farmer ion chamber and 30 cm long Computed Tomography (CT) head and body polymethylmethacrylate (PMMA) phantoms. The results show that under identical radiographic techniques (kVp, mAs, etc.) and with the same scan length, the O-arm in 3D scan acquisition mode delivers approximately half the radiation dose of a 64 slice CT scanner. Scattered radiation was measured at several locations around the O-arm, at 1 m, 2 m and 3 m distances in 3D CT scan acquisition mode with a RadCal 10 x 5-180 pancake ion chamber using a 30 cm long CT body phantom as the source of scatter. Similar measurements were made in a 64 slice CT scanner.

The data demonstrate that scattered radiation from the O-arm to personnel involved in a clinical procedure is comparable to that from a 64 slice CT scanner. Image quality was compared by exposing a CATPHAN phantom to comparable doses in both the O-arm and the CT scanner. The resultant images were then evaluated for modulation transfer function (MTF), high-contrast spatial resolution, and low contrast sensitivity for clinical application purpose. The O-arm shows comparable high contrast to the CT (7 lp/cm vs. 8 lp/cm). The low contrast in the O-arm is not visible due to fixed pattern noise. For image guided surgery applications where the location of a structure is emphasized over a survey of all image details, the O-arm has some advantages due to wide radiation beam coverage and lower patient dose. The image quality of the O-arm needs significant improvement for other clinical applications where high image quality is desired.