

Patient care report for a patient undergoing screening of the vertebral column

Abstract

Radiography of the spine poses various challenges that can be reduced by efficient planning and preparation. By understanding the relevant anatomy and its relationship to the primary beam as well as the aims of the study, diagnostic images can be produced. This report discusses the importance of accurate positioning and collimation, and highlights how systematic appraisal of images can identify faults and enable necessary measures to be taken to improve outcomes.

Key words: Radiography, spine, positioning, x-ray, vertebrae

This report reviews a radiographic study of the spine that was carried out in practice using a step-by-step approach to appraise each image in an attempt to recognise where improvements are required and how future studies can be approached.

Species: Canine

Breed: Border Collie

Age: 8 years 7 months

Sex: Male

Weight: 28.8 kg

Presenting problem/clinical history

This Border Collie had trouble rising and a gradual worsening of general stiffness. Clinical examination localised his discomfort to the lumbar-sacral areas with bilateral hip and cervical pain. A short trial on meloxicam improved his comfort levels and general demeanour.

Discussion of nursing intervention

Care of the patient

The patient was prepared for radiographic imaging of the spine (*Tables 1 and 2*). The patient was anaesthetised, as supported by McKee (1996) and Kirberger (2006), who advise that this will allow relaxation of the spine and reduce muscle spasms; this enables accurate positioning, which is essential to achieve good radiographs. The anaesthetic protocol involved a pre-medication of 30 µg/kg acepromazine maleate (Calmivet,

Vetoquinol) and 20 µg/kg buprenorphine (Vetergesic, Alstoe limited) subcutaneously. Anaesthesia was induced with intravenous propofol (PropoFlo plus, Abbott Animal Health) given to effect. Anaesthesia was maintained with isoflurane (Isoflo, Abbott Animal Health) vaporised in 100% oxygen.

Preventive measures were taken to minimise heat loss during the procedure. These included use of bubble-wrap socks, placement onto a covered heat-pad and covering whenever possible. This prevents peri- and post-operative hypothermia that can have consequences such as depression of the cardiovascular system, increased risk of cardiac arrhythmias and increased shivering, which decreases effective ventilation and increases pain levels (Clark, 2003; Dix et al, 2006; Archer, 2007; Lamb, 2009). The temperature was monitored every 15 minutes throughout the procedure.

Care was taken when manoeuvring the patient. Two veterinary nurses were always involved in turning the patient, which was achieved in one movement; this prevented twisting of the spine, which could result in further damage. Dewey (2008) advises that sedation or anaesthesia increase this risk as a result of the laxity of the paraspinal musculature, which causes instability of the spine.

The patient's anaesthesia became unsettled during all attempts to position him. His respiratory rate and

Table 1. Radiographic imaging information

Imaging investigation	Full spine screening and hips
Method of restraint	General anaesthesia
Parts radiographed	Cervical, thoracic and lumbar spine lateral and VD. Hips — extended VD view (this is not discussed in this report)
Machine used	Raymax 30 kilowatt high frequency x-ray machine with a charge coupled device digital detector with cesium iodide screen
Film focal distance	100 cm
Grid	Focused
VD, ventrodorsal	

Katie Lock Grad dip VN RVN MBVNA is Head Surgical Nurse, Wilbury Veterinary Surgery, Hove, East Sussex

Table 2. Anatomical positioning of the radiographs

Number	Radiographic view	kV	mAs	Anatomical landmarks
1	Lateral cervical spine	70	6.0	Centre over C4–C5 Collimate from base of skull to spine of scapula
2	Lateral thoracic spine	82	14.0	Centre over caudal border of scapula/T7 Collimate from spine of scapula to halfway between xiphoid and last rib. Include C7 and L1
3	Lateral lumbar spine	82	14.0	Centre over L4–L5 Collimate to include T13 and cranial sacrum
4	VD cervical spine	70	6.0	As lateral
5	VD thoracic spine	84	15	As lateral
6	VD lumbar spine	84	15	As lateral
VD, ventrodorsal				

the intensity of his breaths increased, his pupils dilated and his heart rate and reflexes increased. These signs indicated that the patient was not reaching a suitable plane of anaesthesia, which was most likely because of discomfort. Jolliffe (2011) advises that radiography may be a painful procedure for some animals, and suitable levels of analgesia are required to ensure a more stable plane of anaesthesia.

The consequences of the patient's discomfort were that he required high levels of volatile gas to maintain his anaesthetic, which heightened the chance of vasodilation, myocardial depression and hypotension (Smith, 2012). It also meant that positioning was more problematic as is apparent from the resulting images. The veterinary surgeon was informed of the problem, and her decision was to position as best as possible in order to minimise anaesthetic time.

As well as adequate analgesia, simple measures such as use of a radiolucent foam mattress may have improved the patient's comfort in this case. Corzo-Menéndez (2007) advises that these positioning aids have many benefits, including increasing patient comfort and decreasing patient movement, therefore reducing the need for multiple exposures and decreasing the likelihood of hypothermia.

Positioning

Achieving good radiographs is dependent on precise positioning; failure to attain such an outcome can have significant consequences on the diagnostic value of the image, which can lead to pathology that is missed or over interpreted (Ewers, 2007; Agthe, 2008).

Standard positioning of the affected anatomy is important, as this makes interpretation easier and future

radiographs more easily comparable (Corzo-Menéndez, 2007; Ewers, 2007; Agthe, 2008). Standard positioning of the spine is shown in *Box 1*.

Sagging and rotation of the spine will cause geometric distortion of the vertebrae. Pettet (2008) warns that this is a common reason for overdiagnosis of intervertebral disc disease, as the beam passes through at an oblique angle causing a false impression of narrowing. This can be prevented by positioning the spine so that it lies parallel to the film, which was attempted in this case. Foam wedges were used as detailed in *Box 1* to correct areas of sagging, and in between the limbs to prevent rotation; items such as cotton wool or bandages can also be used (McKee, 2000; Varga, 2012). Sirois et al (2010) recommend placing a piece of tape along the spinal column at the start of the procedure to help highlight any rotation.

Accurate positioning was not achieved very well in this case; evidence of rotation can be seen on most exposures (*Table 3*). The veterinary surgeon did not want any of the exposures repeated; however, if this was required, it is recommended that the patient is

Box 1. Positioning for views of the spine

Lateral

- Patient is in lateral recumbency
- Foam wedges/cotton wool/bandages should be placed to ensure the vertebral column is parallel to the table; most commonly this is under the nose, neck, lumbar region, sternum and in between the limbs
- Exact placement of positioning aids varies between patients, and they should be placed after visual assessment. For example, a barrel-chested breed such as a Greyhound will require more support under the sternum, and a large-skulled breed such as a Staffordshire Bull Terrier will need extra support of its head to prevent cervical rotation
- The support in between the limbs should ensure the limbs lay parallel to each other and the horizontal plane, which will prevent ventral rotation
- Extend pelvic limbs caudally and secure if exposing the cervical vertebrae, and cranially for all other sections
- Extend hind limbs caudally and secure

Ventrodorsal

- Patient is in dorsal recumbency secured by trough or sandbags
- The sternum and the spine must be in the same vertical plane
- Extend pelvic limbs caudally, and secure if exposing the cervical vertebrae, and cranially for all other sections

not moved until the images have been evaluated, as this makes corrections to positioning easier to achieve (Agthe, 2008).

Centring and collimation

Close collimation and precise centring is vital for any radiographic study to ensure accurate representation of the anatomy. Excessive collimation will increase the amount of scattered radiation and therefore compromise the quality of the image (Corzo-Menéndez, 2007; Agthe, 2008). It also increases the amount of radiation received by the patient, which is an unnecessary health hazard (Ewers, 2007). This was not achieved well in this case, as both excessive collimation and inaccurate centring is seen on the exposures (*Table 3*).

The radiographs were taken as instructed by the veterinary surgeon, which was in line with McKee (2000)

and Pettett's (2008) recommendations that the spine should be radiographed in sections rather than as one exposure. However, a more diagnostic image would have been achieved by sectioning even further, as areas such as the thoracic vertebrae show narrowing of the vertebral spaces towards the edges of the image. This is unlikely to be a true representation of the joint spaces, but rather caused by the divergence of the primary beam at the periphery of the collimated area (Ewers, 2007; Agthe, 2008).

Agthe (2008) recommends using the information gained from the clinical examination to localise the problem areas as accurately as possible when planning a radiographic study. In this case, the problem areas were known to be lumbar-sacral and cervical; it may have been advantageous to section the cervical area into cranial and caudal and focus on lumbar-sac-

Table 3. Radiographic images of the spine and their appraisal


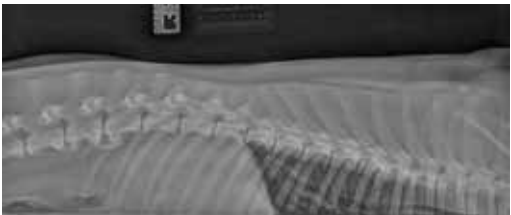
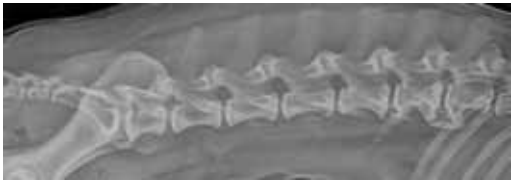



View	Radiograph	Film appraisal
Lateral cervical		Positioning <ul style="list-style-type: none"> Sagging of vertebrae towards plate. Transverse processes should be superimposed Required positioning corrections <ul style="list-style-type: none"> Use of wedges/bandages under neck to correct sagging Collimation <ul style="list-style-type: none"> Too wide Centring <ul style="list-style-type: none"> Too dorsal Exposure <ul style="list-style-type: none"> Good Other <ul style="list-style-type: none"> Positional marker and ruler included
Lateral thoracic		Positioning <ul style="list-style-type: none"> Rotated. Rib insertion point should be superimposed Required positioning corrections <ul style="list-style-type: none"> Ensure spine and sternum on same horizontal plane by use of correct size radiolucent wedges Collimation <ul style="list-style-type: none"> Could have moved cranially to include all of T1 and fewer lumbar vertebrae. Ideally should be split into smaller sections as x-ray beam diverged at edges Centring <ul style="list-style-type: none"> Could be improved Exposure <ul style="list-style-type: none"> Good Other <ul style="list-style-type: none"> Positional marker and ruler included
Lateral lumbar		Positioning <ul style="list-style-type: none"> Good Collimation <ul style="list-style-type: none"> Good — includes landmark vertebrae T13 and S1 Centring <ul style="list-style-type: none"> Good Exposure <ul style="list-style-type: none"> Good Other <ul style="list-style-type: none"> No markers

Table 3 (continued). Radiographic images of the spine and their appraisal

View	Radiograph	Film appraisal
VD cervical		<p>Positioning</p> <ul style="list-style-type: none"> • Rotated and not straight. Transverse processes should look symmetrical • Spinal processes should be central <p>Required positioning corrections</p> <ul style="list-style-type: none"> • Ensure no longitudinal rotation from tip of nose to tail by adjusting traction on limb ties or body support. Ensure patient lying straight in primary beam • Support under neck if sagging evident <p>Collimation</p> <ul style="list-style-type: none"> • Too wide vertically <p>Centring</p> <ul style="list-style-type: none"> • OK <p>Exposure</p> <ul style="list-style-type: none"> • Good <p>Other</p> <ul style="list-style-type: none"> • No markers • Endotracheal tube visible
VD thoracic		<p>Positioning</p> <ul style="list-style-type: none"> • Rotated, especially cranially • Spinal processes are deviated laterally • Sternum should be superimposed. Ideally should be split into smaller sections <p>Required positioning corrections</p> <ul style="list-style-type: none"> • As above <p>Collimation</p> <ul style="list-style-type: none"> • Good <p>Centring</p> <ul style="list-style-type: none"> • Good <p>Exposure</p> <ul style="list-style-type: none"> • Good <p>Other</p> <ul style="list-style-type: none"> • No markers
VD lumbar		<p>Positioning</p> <ul style="list-style-type: none"> • Rotated, especially caudally • Not straight <p>Required positioning corrections</p> <ul style="list-style-type: none"> • Ensure no longitudinal rotation from tip of nose to tail by adjusting traction on limb ties or adjusting body support. Ensure patient lying straight in primary beam <p>Collimation</p> <ul style="list-style-type: none"> • Good <p>Centring</p> <ul style="list-style-type: none"> • Good <p>Exposure</p> <ul style="list-style-type: none"> • Under exposed <p>Other</p> <ul style="list-style-type: none"> • No markers • Edge of trough is overlying L1/
VD, ventrodorsal		

ral area by centring on L7 to include the entire lumbar–sacral area. McKee (2000) recommends that the whole vertebral column is radiographed regardless of the problem area, as he advises that failure to do this

may miss any ‘silent’ lesions; however, smaller sections would have been beneficial in this study. Pettett (2008) advises that up to six films is a suitable number for a large dog.

Conclusion

The images achieved from this study were of a substandard quality, showing evidence of rotation, excessive collimation and inaccurate centring. It is questionable whether these exposures had much diagnostic value; however, the veterinary surgeon was satisfied that they ruled out any major pathology such as tumours.

The author's recommendations to improve the quality of the images would be to provide better analgesia to the patient to facilitate a smoother anaesthetic, to use a wider range of positioning aids and to increase the number of exposures taken to enable focusing on smaller sections of the vertebral column in each exposure. **VN**

Conflict of interest: none.

References

- Agthe P (2008) Practice radiography. How to improve image quality: part 1. *UK Vet J* **13**(8): 1–5
- Archer E (2007) Maintaining body temperature. *Vet Nurs J* **22**(3): 16–20
- Clark L (2003) Monitoring the anaesthetised patient. In: Welsh L, ed. *Anaesthesia for Veterinary Nurses*. Wiley-Blackwell, Chichester: 233–66
- Corzo-Menéndez N (2007) How to improve radiographic quality in practice. *Irish Vet J* **60**(4): 241–6
- Dewey CW (2008) *A Practical Guide to Canine and Feline Neurology*. 2nd edn. Blackwell Publishing, Iowa
- Dix GM, Jones A, Knowles T G, Holt PE (2006) Methods used in veterinary practice to maintain the temperature of intravenous fluids. *Vet Record* **159**(14): 451–6
- Ewers R (2007) Getting the best results from radiography. *In Practice* **29**(8): 464–9
- Jolliffe C (2011) Approaches to anaesthesia protocols. *Vet Times* **41**(42): 12–18
- Kirberger RM (2006) Spine — general. In: Barr FJ, Kirberger RM, eds. *BSAVA Manual of Canine and Feline Musculoskeletal Imaging*. BSAVA, Gloucester: 220–32
- Lamb S (2009) Perioperative hypothermia — prevention is better than cure. *VN Times* **9**(10): 22–4
- McKee M (1996) Cervical pain in small animals. *In Practice* **18**(4): 169–84
- McKee M (2000) Intervertebral disc disease in the dog 1. Pathophysiology and diagnosis. *In Practice* **22**(7): 355–69
- Pettett R (2008) Getting small animals back into health: spinal disease diagnosis. *Vet Times* **38**(21): 28–30
- Sirois M, Anthony E, Mauragis D (2010) *Handbook of Radiographic Positioning for Veterinary Technicians*. Delmar Cengage Learning, New York
- Smith M (2012) Small animal anaesthesia: part two. *Vet Nurs Times* **12**(5): 20–22
- Varga C (2012) Avoiding radiography pitfalls to obtain the perfect image. *Vet Nurs Times* **12**(7): 22–3

Key Points

- The veterinary nurse can play an important role in radiography.
- Correct preparation of the patient including suitable analgesia is essential for both patient comfort and ease of positioning.
- Standard positioning of anatomy is important to make interpretation easier and future radiographs more easily comparable.
- Accurate positioning is vital to achieve diagnostic radiographs.
- Close collimation and precise centring is required for any radiographic study to ensure accurate representation of the anatomy.

Acknowledgements: This article was written as part of the Graduate Diploma in Professional and Clinical Veterinary Nursing, diagnostic imaging module.