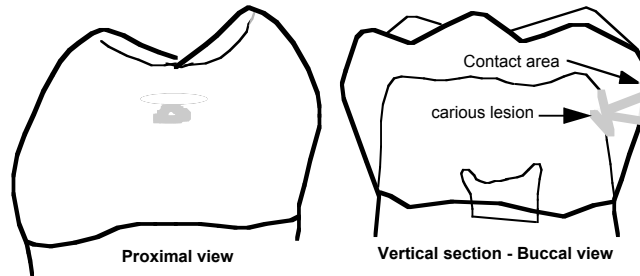


CLASS II CAVITY PREPARATION CHARACTERISTICS OF AN IDEAL CLASS II



Class II carious lesions are diagnosed using **bitewing** radiographs. In reading a bitewing radiograph, it is important to know that a proximal lesion that appears to be 2/3 or more through enamel toward the DEJ has actually penetrated the DEJ. It is also important to remember that even if caries have slightly penetrated DEJ, they can still be remineralized in the right environment (frequent cleaning of the proximal surface and use of fluoride). In most cases, restoration due to proximal caries should not be undertaken unless there is spread of the caries at the DEJ (occluso-cervically) that can be determined from the radiograph.

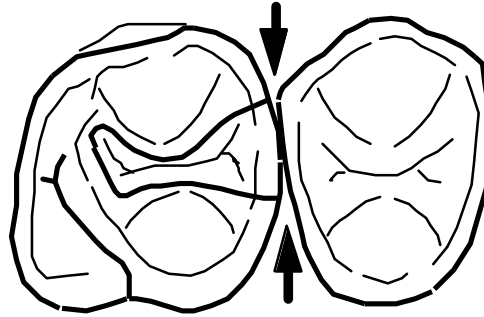
Class II silver amalgam preparations will vary with the morphology, anatomy and extent of carious involvement of the individual tooth being restored. However, certain **fundamentals are common to all Class II silver amalgam cavity preparations**. The Class II silver amalgam cavity preparation consists of:

- A- Occlusal segment and
- B- Proximal segment:

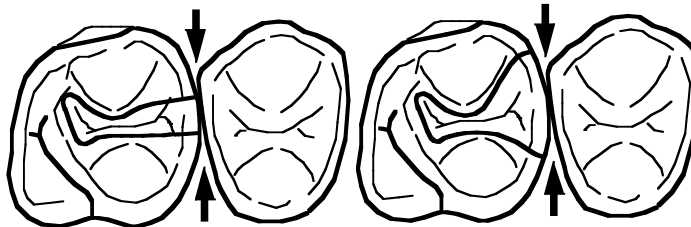
A- The Occlusal Segment:

-Outline Form:

The occlusal segment follows the same fundamentals already given for the Class I silver amalgam **except that the external outline is extended proximally toward defective proximal surface** (s). The occlusal outline form **in the region** of the **proximal box** is determined primarily by the bucco-lingual position of the **contact** and the extent of the carious lesion. The occlusal outline at the proximal marginal ridge(s) **must be extended enough to make breaking of the contact with the adjacent tooth easy.**



Ideal External outline form on the occlusal segment is enough extended to **jus** break contact with the adjacent tooth



Under-extended

Over-extended

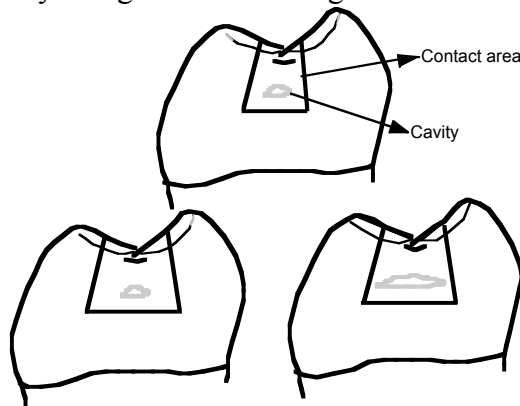
B- The Proximal Segment(s):

-External outline:

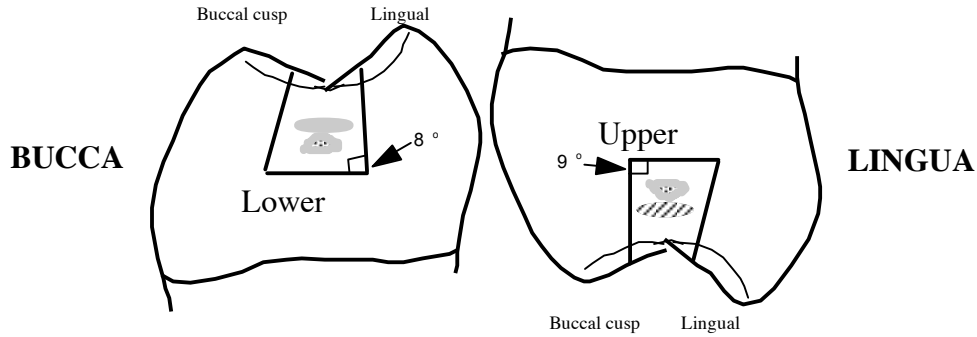
a- Bucco and linguo-proximal margins are **extended**:

1- to include caries

2- to break contact with the adjacent tooth (cow-horn explorer's **TIP** should pass through easily) to provide **convenience form and** uniform accessibility along their entire lengths.

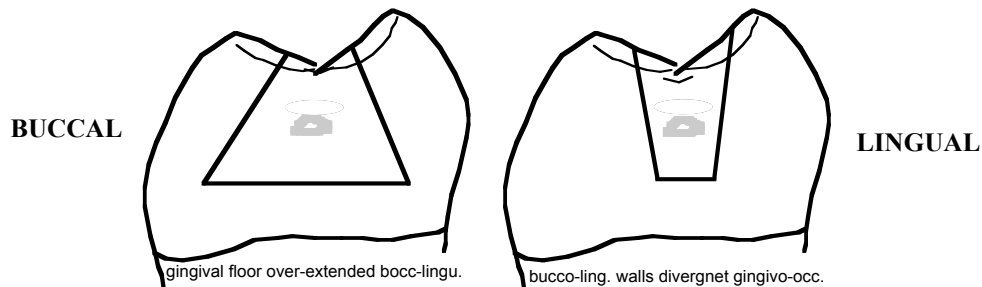


NOTICE: Because of the **convexity** and **morphological shape** of the proximal surfaces, the direction of proximal walls occluso-gingivally are different for upper and lower posterior teeth:



The directions of the buccal and lingual proximal walls (occluso-cervically) are determined by tooth morphology, anatomy and position of the adjacent tooth.

Common Mistakes:



b- Gingival floor is extended to include caries and break contact with the adjacent tooth gingivally. It is a straight line between the gingival termination of the buccal and lingual proximal CSM. Proximal walls meet gingival floor to form a radius. A **minimum of .3 mm of separation should be allowed between gingival cavo surface and the proximal surface of the adjacent tooth** (cow horn explorer's **TIP** should pass through easily).

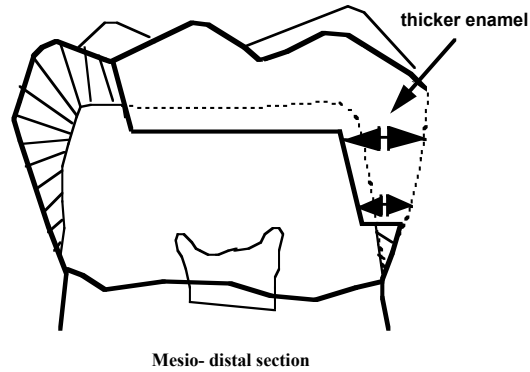
- Internal outline:

a- Axial Wall should:

- be placed into dentin approximately 0.5 - 0.8 mm from DEJ.
- follow curvature of DEJ **bucco-lingually**
- follow curvature of DEJ **occluso-lingually** (tapered occlusally).

NOTE: Proximal depth (from the proximal surface to the axial wall) at the level of pulpo-axial line angle is greater than at the gingival floor area.

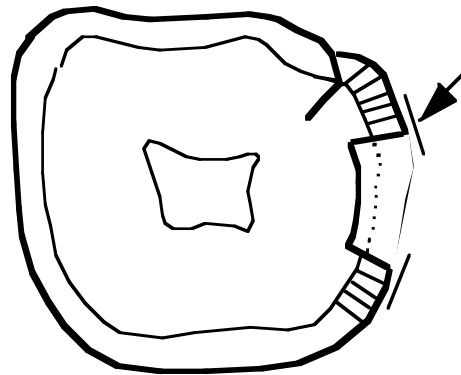
REASON: enamel is thicker occlusally than in the gingival region.



Mesio- distal section

b- Proximal Walls Direction (axio-proximally)

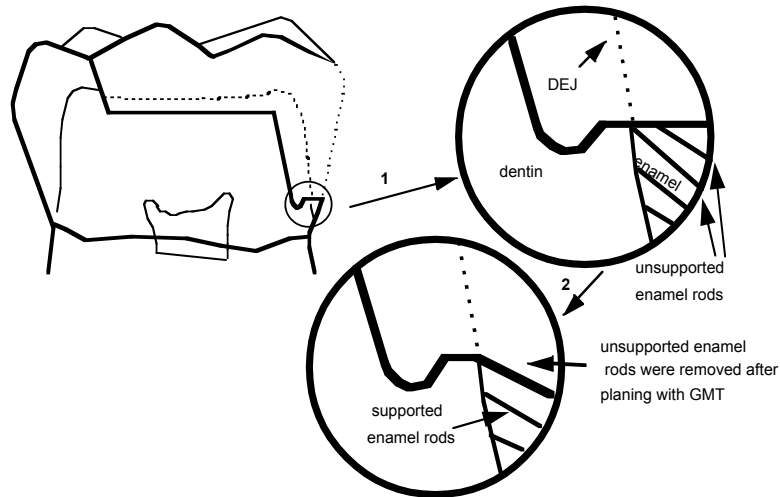
- Buccal and lingual proximal walls are parallel to the enamel rods' direction and/or perpendicular to the tangent of the tooth surface.



Horizontal view

REASON: The enamel rod radiates from the DEJ at right angles to the tangent on the outer surface of the tooth. In other words, the enamel rods approximately radiate from the center of the tooth like spokes of a wheel.

c- Gingival floor (axio-proximally): parallels the enamel rod directions; often cervically inclined.



- Mesio-distally: Gingival floor is kept parallel to the pulpal floor (WHY)
- Bucco-lingually: Gingival floor is independent from the pulpal floor direction, but it is **usually** kept parallel to the direction of the pulpal floor.

C Margins:
Smooth, well defined.

D Retention:
Rounded grooves within dentin at bucco and linguo- proximal walls and gingival floor.

DRAWING EXTERNAL OUTLINE FORM

1. Draw an ideal occlusal outline form on your tooth (with a **very sharp** pencil) with the exception **that it is extended** to the defective marginal ridge area where it seems to break the contact with the adjacent tooth. Fig 1
2. **Occlusal outline at the marginal ridge area** - Extension of the buccal and lingual walls is primarily determined by the **contacting surface** of the adjoining tooth. In a relatively **ideal** cavity this clearance need to be only the thickness of the tip of cow horn explorer (0.3 mm). To determine the proper occluso-proximal extension of your cavity preparation, place the cow horn #3 into the buccal and lingual embrasure until it wedges between the tooth you are working and the adjacent tooth. Mark on the marginal ridge where tip of the explorer is contacting the teeth.
NOTE: This amount of extension will give you access for proper finishing and polishing of the restoration as well as access for proper home care. Extending too far buccally or lingually weakens the restoration and the tooth structure.

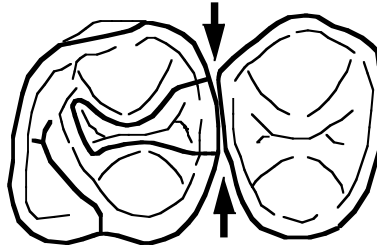


Fig 1

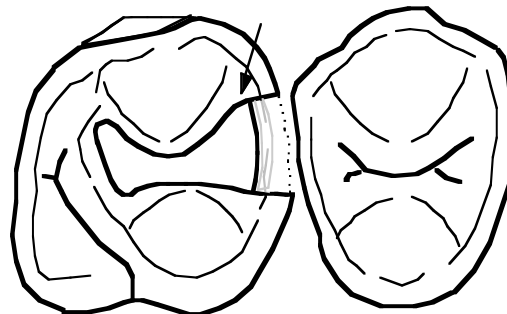
NOTE: Particularly in the maxillary teeth the proximal contact point lies toward the buccal surface of the crowns, whereas the groove line occurs in the central portion of the occlusal table. This disparity necessitates an occlusal outline with a **REVERSE CURVE** on the buccal and a straight line (or nearly straight) on the lingual.

Reverse Curve:

a- preserves triangular ridge of the cusp (prep goes around it).

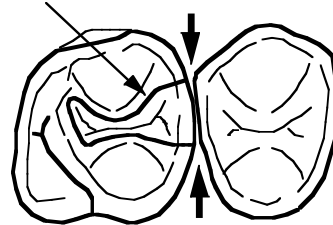
b- facilitates formation of a 90 degree angle between proximal wall(s) and the tangent of the proximal surface.

Reverse curve starts about where pulpo-axial line is located

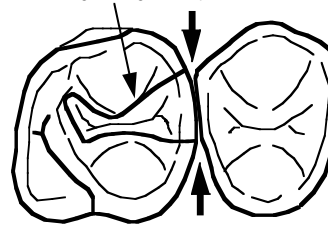


Smooth curve around tri-angular ridge

cut through tri-angular cusp

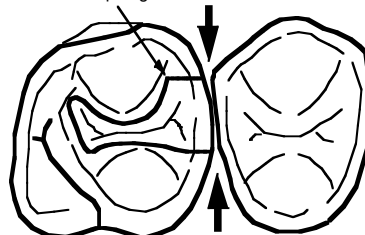


Correct



Incorrect

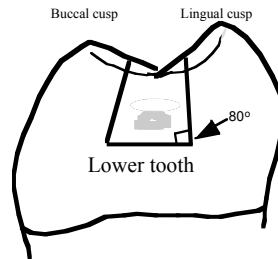
too sharp angle



Incorrect

- 3. Proximal outline** –To locate the buccal and lingual proximal margins, with a sharpened pencil scribe a line across the buccal and lingual proximal surfaces

with the point as far into the embrasure as possible, touching the adjacent tooth. Draw a second line parallel to the first line medially from the **marks on the bucco and linguo-occlusal marginal ridge**. Extension of the buccal and lingual walls is primarily determined by the extent of **carious lesion** and **contacting surface** with the adjoining tooth. The directions of buccal and lingual proximal walls (cervico occlusally) are determined by the tooth morphology and the anatomy and position of the adjacent tooth.

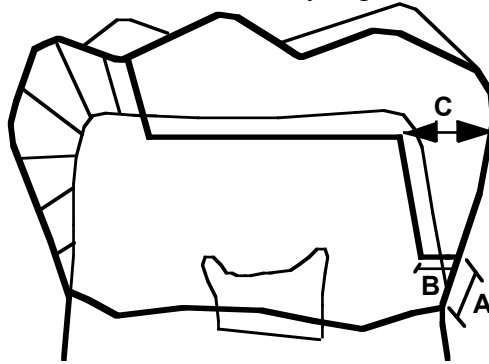


The interproximal outline form is designed to:

- include all **decay** and **decalcified tissue** as well as
 - providing **convenience for finishing and restoring** the prepared cavity by breaking the contact with the adjacent tooth.
4. The bucco and linguo-proximal extensions are connected to the occlusal outline form at the occlusal marginal ridge area.
 - 5- The **gingival floor** is extended by anatomy and position of the adjacent tooth. The gingival wall is extended far enough gingivally to include **decay, decalcification and the contact area**. The gingival margin should extend far enough below the contact area to provide **convenience for finishing and restoring** (condensing, carving and finishing) the prepared cavity. You may terminate the gingival extension when .3 mm (thickness of the tip of #3 cow horn explorer) of separation exists between the cavo surface margin of the preparation and the adjacent tooth.

CLASS 2 CAVITY PREPARATION

FOR THE SAKE OF this PRACTICE and laboratory exercises, we will arbitrarily assign following measurements for cavity depth and cavity walls:



Occlusal Segment: follow the same criteria as Class 1 cavity preparation

Proximal Segment:

MOLAR

A= 1 to 1.5mm (from CEJ)
B= 1.2 to 1.5mm
C= Should be longer than B

PREMOLAR

A= 1 to 1.5mm (from CEJ)
B= 1 to 1.2mm
C= Should be longer than B

IMPORTANT CLINICAL HINT: As an extra guide for cavity preparation and restoration, before placing the rubber dam, mark the centric stops using articulating paper, observe the height of the defective marginal ridge(s) and its relation to the adjacent marginal ridge(s).

Instruments List:

Examination instruments:

mouth mirror (1)
explorers (2)
Calibrated condenser (21)
cotton pliers (5)

Pre-molar Tooth

Rotary Instruments

bur #256 high speed
bur # 256 low speed
bur # 1/4 round bur low speed

Hand Instruments:

*chisel (Item #12 in roll-up) 15-8-14
*hatchet (Item #6 in roll-up) 15-8-14

- *Gingival Margin Trimmer (Item #7 Mesial, 8 Distal or both in roll-up)
- *Angle Former (Item #14 Mesial, 15 Distal or both pair in roll-up)

Molar Tooth

Rotary Instruments:

- bur #256 high speed
- bur #256 low speed
- bur # 1/4 round bur

Hand Instruments:

- *Chisel (Item #12 in roll-up) 15-8-14
- *Hatchet (Item #6 in roll-up) 15-8-14
- *Gingival Margin Trimmer (Item #9 Mesial, 10 Distal or both in roll-up)
- *Angle Former (Item #14 Mesial, 15 Distal or both pair in roll-up)

REMINDER: *Chisel and Hatchet (10-8-14)* are used only to remove ledges from axio-bucco proximal and axio linguo-proximal line angles of proximal boxes.

***Dependent upon the quadrant you are working, if you are right or left handed and if you are preparing an MO, DO, or MOD**

**“IMPORTANT TO REMEMBER”
BEFORE STARTING ANY INTER-PROXIMAL CAVITY
PREPARATION, REMEMBER TO PLACE A WEDGE
BETWEEN THE TWO ADJOINING TEETH**

Why??

Wedges

- depress interproximal gingival apically
- prevent injury to soft tissue & rubber dam
- prevent seepage of saliva and blood
- cause minute separation of teeth
- indicate gingival CSM breakage (occlusal reflection of its color)

- * hold matrix band tightly against tooth
- * compensate for matrix band thickness

* These are discussed later on with the matrix band placement

MOLAR CAVITY PREPARATION

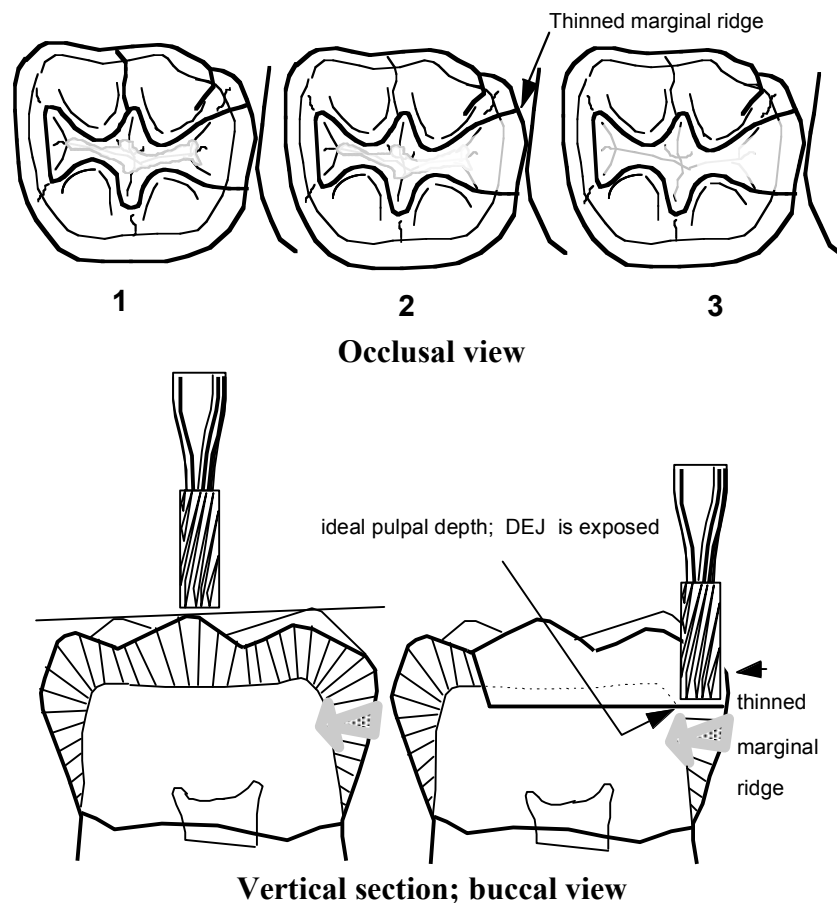
Class 2 cavity preparation is divided into **two** segments:

- A-** Occlusal segment preparation
- B-** Proximal segment preparation

A. Occlusal Segment Preparation

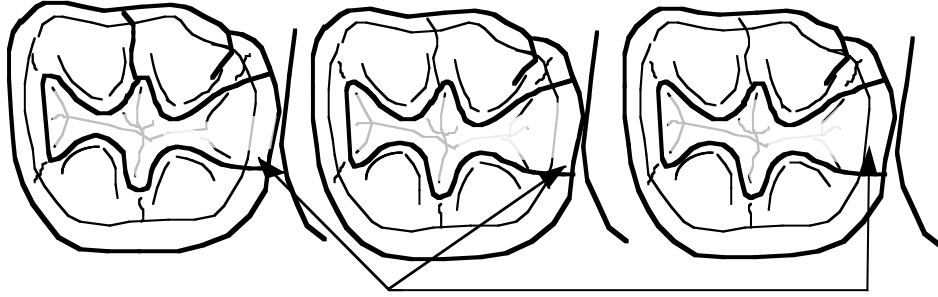
1. Select a **#256** (high speed) carbide bur to penetrate the **occlusal segment** of the cavity to:
 - a- extend into each of the fissures to a depth of 0.3 mm into dentin and to remove all enamel faults.
 - b- extend toward the defective proximal surface(s) to thin **the marginal ridge(s)** and to **expose dej**.

Following initial penetration into all occlusal fissures, use the **#256** (low speed) bur to extend the cavity. The pulpal floor and occlusal walls should be finished and be established to its ultimate outline form by utilizing hand instruments. Air water spray is used clinically as a coolant with high volume evacuation to clear the field. (For further information regarding occlusal segment preparation, refer to your class 1 cavity preparation). **Unlike Class 1 occlusal cavity** preparations, the occlusal segment of the class 2 cavity preparation is extended toward the defective marginal ridge(s). The marginal ridge(s) should be **THINNED** but **NOT** be removed.

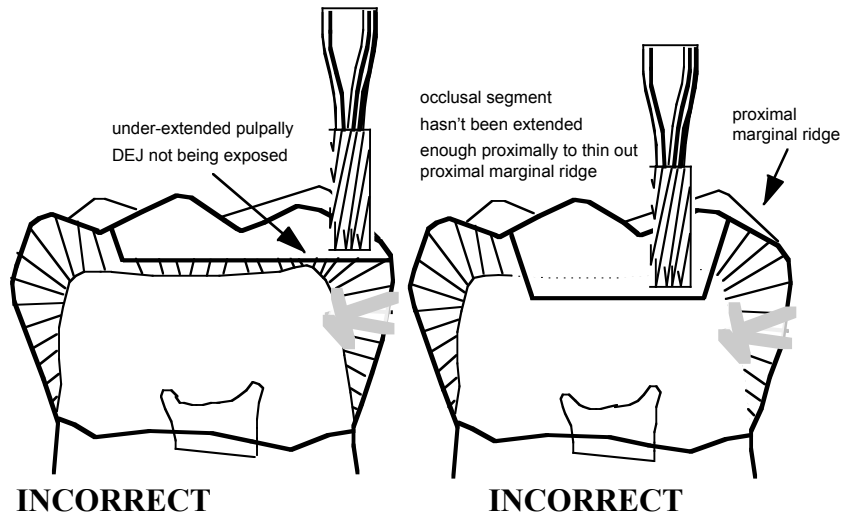


Common Mistakes:

In the figures below, marginal ridges are thinned but not extended fully to break the contacts with the adjacent tooth.



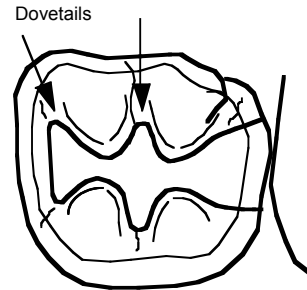
Not extended enough proximally and/ or short of extending to the marginal line angles



2. Occlusal segment retention: The external outline of the occlusal portion of a class2 cavity preparation should provide a retentive design to resist dislodgment of the restoration towards the involved proximal surface(s). In most teeth, the routine extension into occlusal fissures will provide such retention (**dovetail**), but on occasion, it will be necessary to widen the end of the occlusal groove slightly and **with a gentle curve** to develop a retentive dovetail.

Occlusal segment retention is achieved by:

- parallel buccal and lingual walls
- defined points and line angles
- dovetail

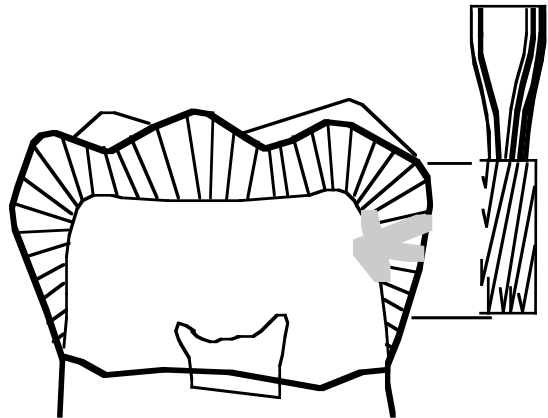


B. Proximal Segment:

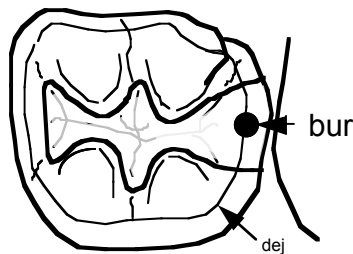
VERY IMPORTANT: Before starting the preparation of the proximal box make sure that the occlusal segment is fully completed. Check the following and consult with your instructor:

- **Pulpal depth** (minimum of 2mm. from CSM to pulpal floor)
- **Wall directions**
- **Line and point angles definition**
- **Thinning of the defective marginal ridge in the area of contact with the adjacent tooth**

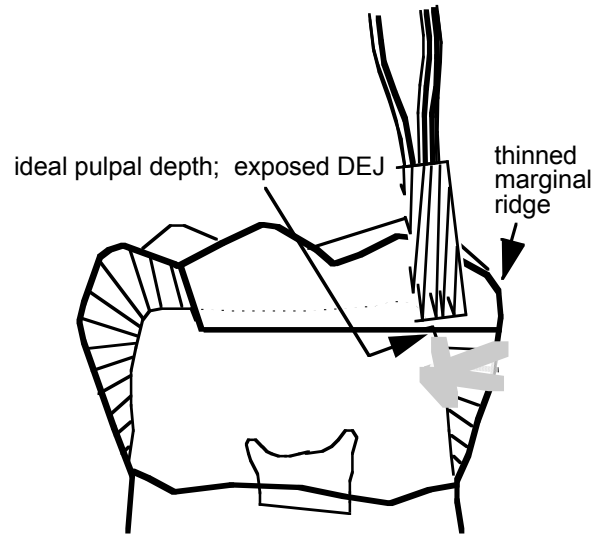
3- Use the F.G. #256 (High speed) bur as a yard-stick. Place it next to the buccal surface at the approximate desired gingival depth of the proximal box. Note the height of the bur in relation to thinned marginal ridge. This will act as the guide for the desired gingival depth of the proximal box.



4. Place bur # 256 (high speed) at the exposed DEJ. The thinned marginal ridge (proximal wall) is maintained in place to protect the adjacent tooth.



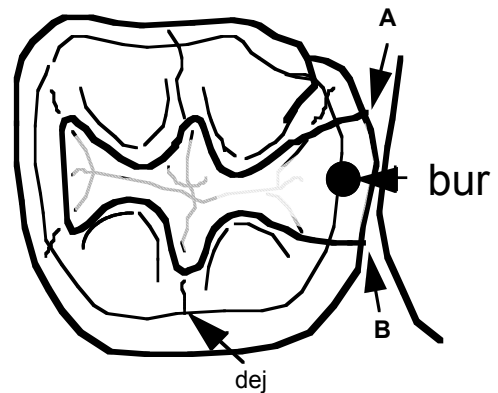
Occlusal view



Vertical section; Buccal view

The bur is placed halfway between buccal and lingual walls; keep the end of the bur mostly on enamel and the edge at the dentino-enamel junction. Now penetrate apically with your bur and prepare a slot at the DE junction. Pendulate the bur **all the way to the points A and B** for the most effective cutting. Keep the bur direction occluso-lingually to create a triangular proximal box (refer to page 3). Check at intervals, the height of the bur in relation to the height of the thinned marginal ridge.

As you penetrate apically keep in mind the proximal external form (shape) that you want to achieve (refer to page 3).

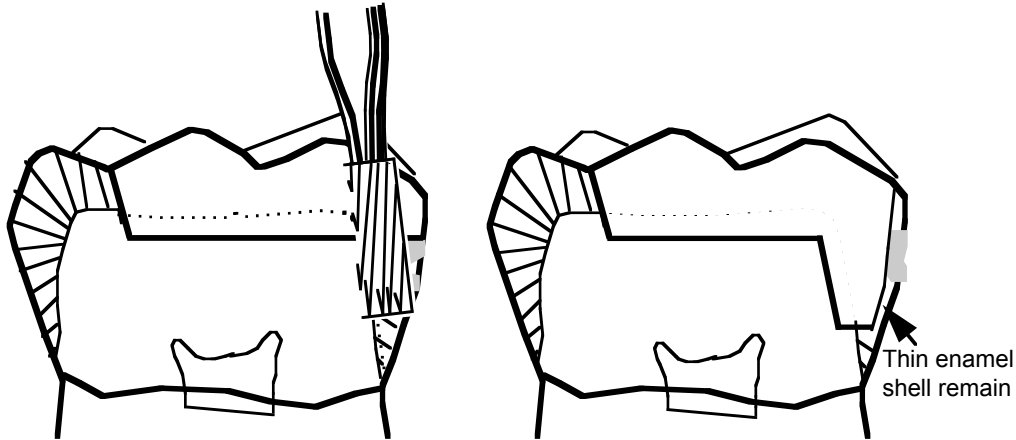


Maintain the axial wall uniformly 1/2 mm in dentin. Gingivo-occlusally, the axial wall should be occlusally tapered. This forms an obtuse angle at the gingivo-axial line angle. This taper is necessary to keep axial wall evenly in dentin (WHY?). Bucco-lingually, the axial wall is convex and parallels to the outer-surface of the proximal enamel.

The axial wall is curved in a bucco-lingual direction following the curvature of the dentino-enamel junction. To establish the proper curvature, taper and depth of the axial wall, place **the side (secondary cutting edge)** of a #15 binangle chisel /hatchet against the axial wall. The instrument should lean toward the center of the tooth to establish the taper (gingivo-occlusally). With firm axial pressure, the instrument is thrust in the buccal and lingual directions using the side of the instrument to plane the axial wall. The axial wall should be planed until it is uniformly 1/2 mm within the dentino-enamel

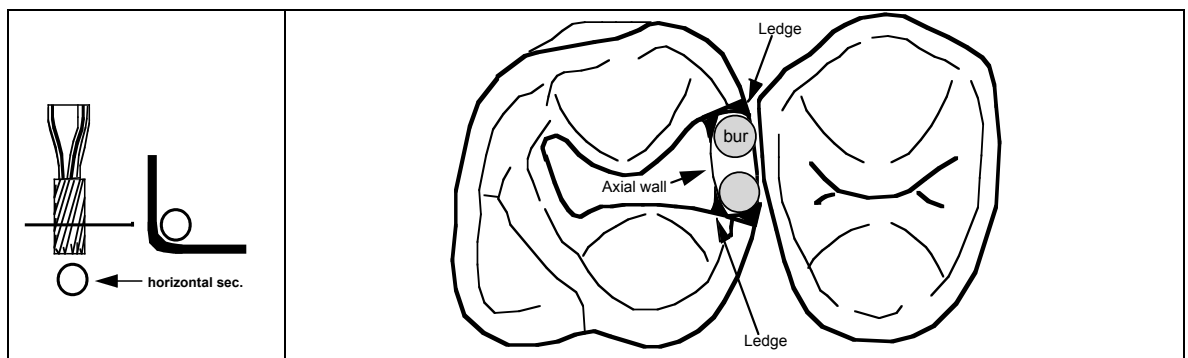
junction. The 1/2 mm depth within the Dentino-enamel junction can easily be judged when **1/3 of the width of the instrument is axial to the dej**. The #15 binangle chisel or hatchet is moved to a more upright position and thrust in a buccal and lingual direction to plane and smooth gingival floor.

5- Now use the #256 bur (low speed) to extend into the proximal box with a pendulating motion and to further thin the entire inter-proximal enamel. When the proximal enamel is thinned sufficiently*, use an enamel hatchet/chisel to fracture the remainder away.



* Test the strength of the marginal ridge in the proximal box area with an enamel hatchet/chisel to determine whether further thinning of proximal enamel wall is required before using hand instruments to remove it.

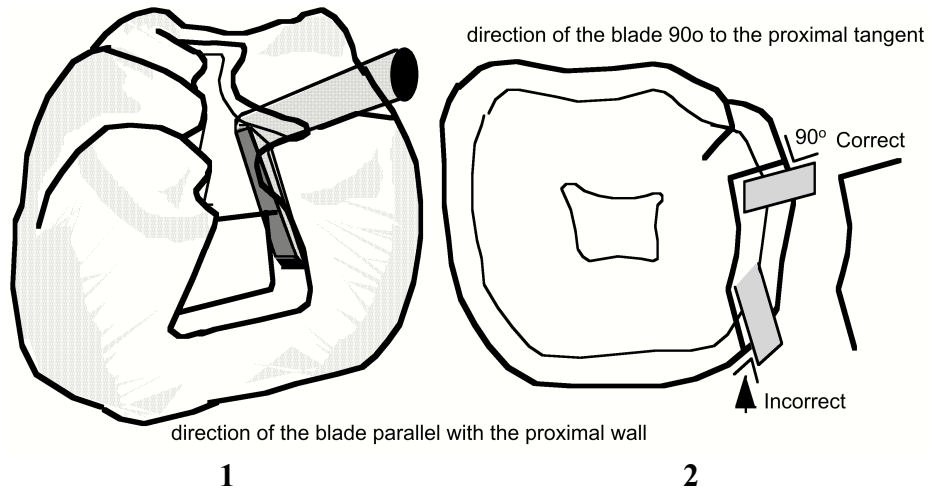
6- Due to the round shape of the bur, enamel lips (ledges) will be left at the bucco and linguo - proximal margins and dentinal lips (ledges) will be left at bucco and linguo- axial line angles as the bur is moved bucco lingually.



Eliminate these **enamel lips** with a hatchet/chisel by thrusting from the occlusal in the gingival. Orient the hatchet/chisel's blade in two directions:

1- hold the instrument's blade parallel to the direction of the proximal wall occluso-gingivally (Fig. 1).

2- hold the instrument's cutting edge perpendicular to the tangent of the proximal surface axio-proximally (Fig. 2)

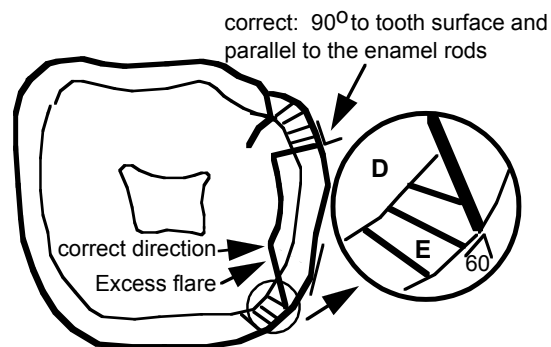


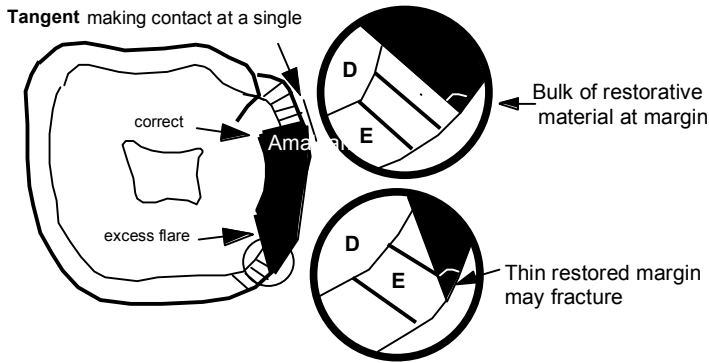
The removal of the enamel lips on the buccal and lingual proximal walls should extend the buccal and lingual proximal walls to their **final extension**. Adequate extension of bucco-lingual proximal walls should allow the **TIP of a #3 cow horn explorer to pass easily between the buccal and lingual proximal cavo-surface margin and the adjacent tooth**.

Plane the proximal walls so that they **flare perpendicular to the outer tooth surface**. If further extension is required, additional cavo surface planing should be done while **maintaining the buccal and lingual proximal wall in the direction of the enamel rods**. Wrong instrumentation might cause **Excess flare** or **Lack of flare**:

a- Excess flare :

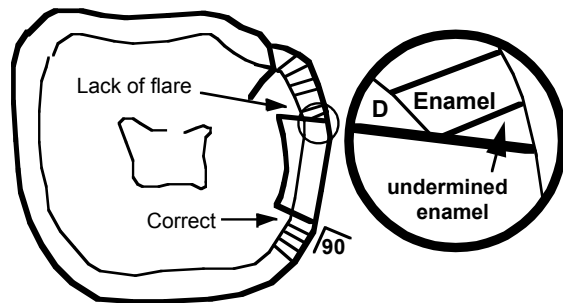
- **reduces** retention form.
- **reduces** fracture resistance of the restoration at margin.
- **reduces** convenience for placement of materials.





b- Lack of flare:

- creates unsupported enamel rods.
- reduces fracture resistance of the tooth at margin

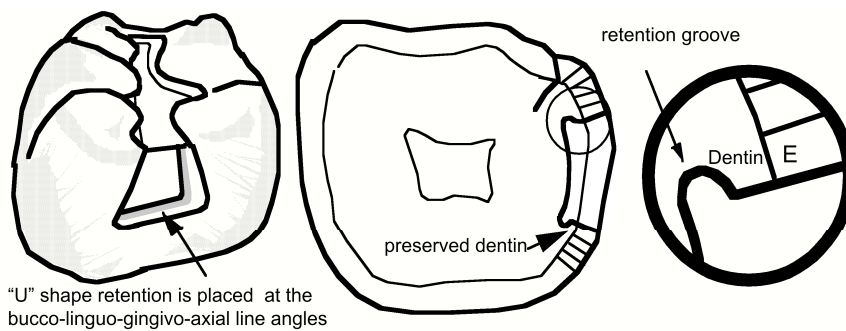


8- Retention groove placement:

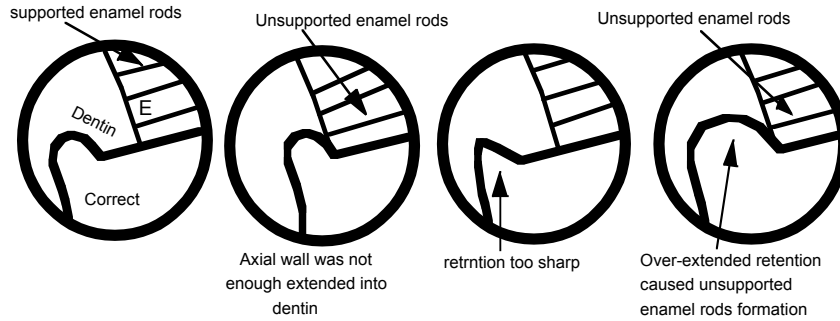
VERY IMPORTANT: Before placing proximal retention be sure that the Class2 cavity preparation is completed. Check the following and consult with your instructor:

- Pulpal, axial and gingival floor depth
- Walls direction at occlusal and proximal segments
- Line and point angles definition

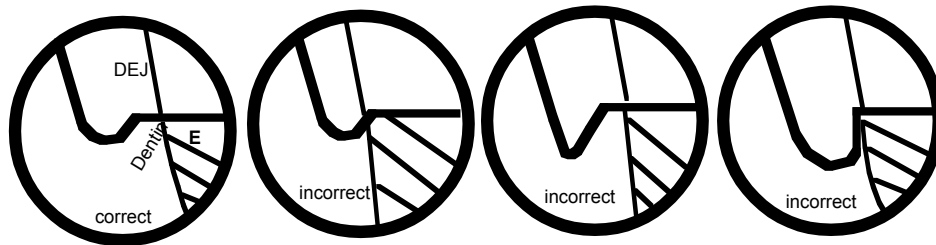
Retention is placed **ENTIRELY IN DENTIN** so as **not** to undermine the proximal enamel rods.



Horizontal section

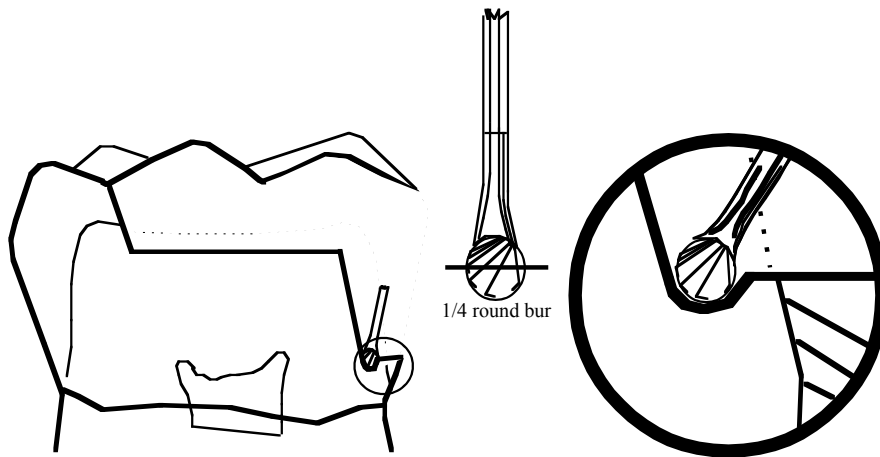


Sagittal View of "U" shape of the above retention groove



Vertical section

To place proximal retention groove, use a **#1/4 round bur** and rotate it at a very low speed with a **minimal pressure**. It should be a continuous groove along the line angle between gingival floor, linguo- proximal wall, and buccal proximal wall with the axial wall. The groove is **U-shaped** and should be continuous with the axial wall and **NOT impinge in the pulpal direction**.

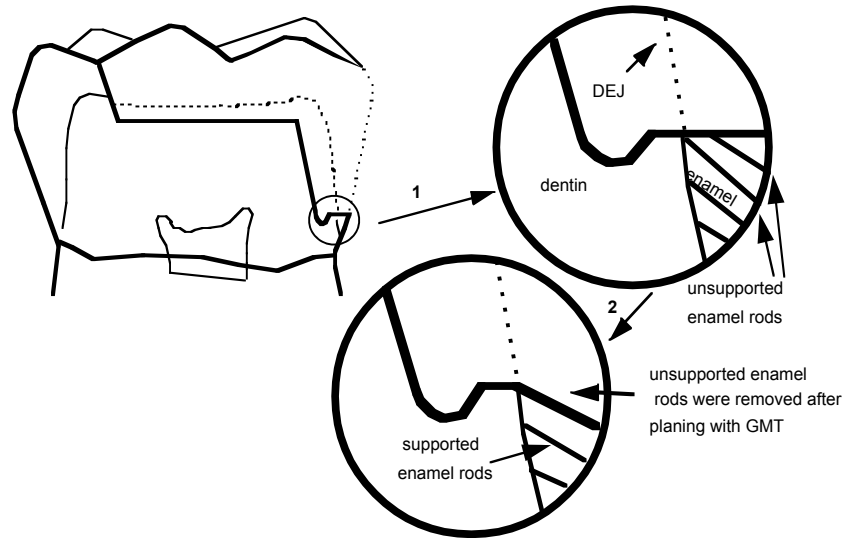


Proximal segment retention consists of:

- divergent bucco and linguo proximal walls (occluso-pulpally)
- defined line and point angles
- **"U" shaped groove**

9- Planing Gingival Cavo-surface Margin:

a- Planing gingival csm margin (removal of unsupported enamel rods): The gingival margin trimmers or angle formers (Distal, Mesial) should be used to **plane the gingival cavo-surface margin**.



b- Gingival margin trimmers can also be used to define retention grooves. However, in this case, the distal gingival margin trimmer is used for the mesial box and the mesial gingival margin trimmer is utilized for the distal box.

c- Gingival margin trimmers can also be used to round the pulpo-axial line angle.

The gingival margin trimmers and angle formers are used with a lateral scraping motion

INTERNAL OUTLINES

Now you are ready to evaluate the following internal features of your cavity preparation.

A- Axial depth and direction of axial wall

Axial depth and direction of axial walls are essential not only for maintaining the tooth's strength but also for providing enough thickness for the amalgam restoration to resist fracture. The depth of the gingival floor must be a **MINIMUM of 1 mm** as measured from the cavo surface (at the gingival floor level) to the axial wall. Half a millimeter of the **MINIMUM 1 mm** axial wall depth must be placed into dentin.

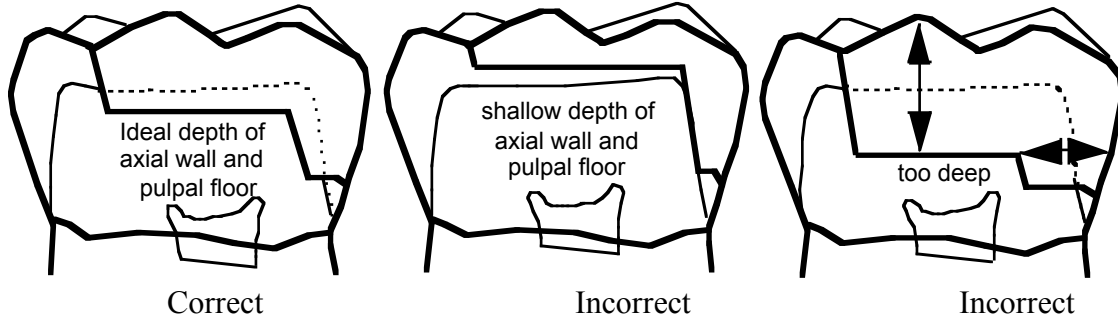
NOTE: The most practical way to measure the width of the gingival floor (or depth of the axial wall pulpally) is to use either a chisel or a hatchet (this is where you use your hand instrument as a **gauge**).

10- Final Inspection

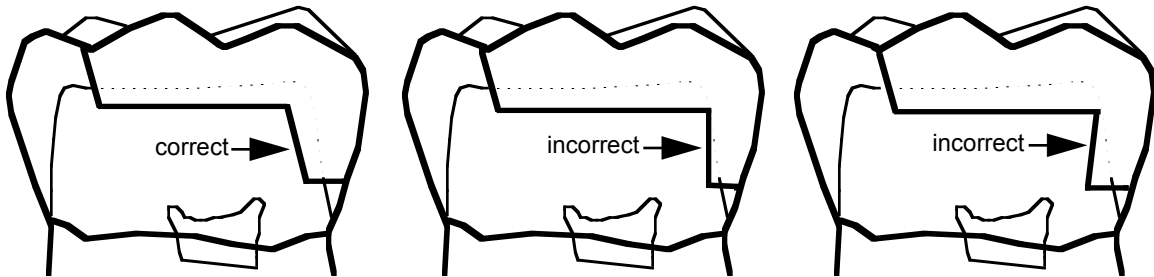
The cavity should be cleansed and carefully inspected with the aid of a mouth mirror and explorer. Be as critical of your work as possible and **demand the finest work you are capable of performing.**

Self-evaluation. An instructor must check your cavity preparation before proceeding to the next assignment.

Common mistakes



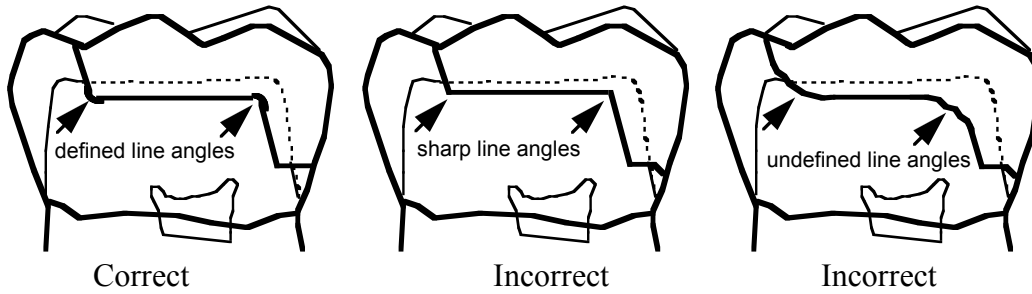
Pulpal floor and axial wall placement



Axial wall direction

B. Proximal retention

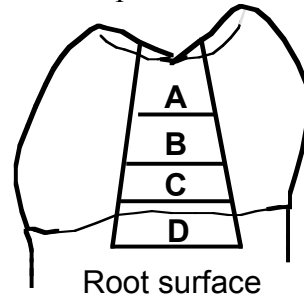
C. Occlusal proximal internal line angle. All the line angles should be defined



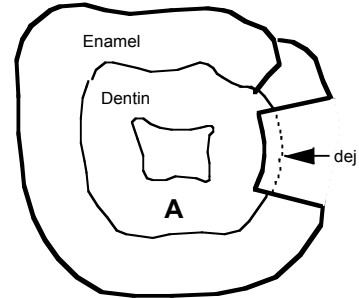
Appendix

Gingival floor Width - depends on where the gingival floor is on the proximal surface:

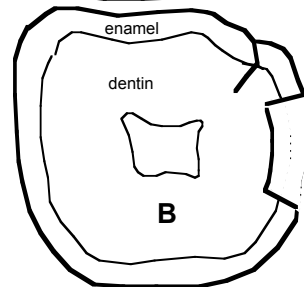
Figure shows horizontal section of tooth showing enamel thickness and related gingival floor depth at (A) occlusal one-third of; (B) middle one-third of; (C) gingival one-third of crown; and (D) root surface



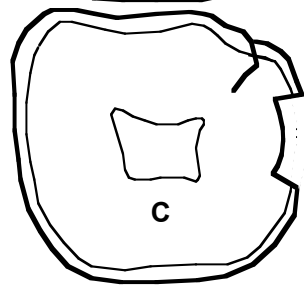
A- shows more than 1.25 mm thickness of enamel and .5 mm axial extension into dentin. Width of gingival floor is 1.75 mm.



B- shows 1 mm thickness of enamel and .5 mm axial extension into dentin. Width of gingival floor is 1.5 mm.



C- shows 1/2 mm thickness of enamel and 1/2 mm axial extension into dentin. Width of gingival floor is 1 mm.



D- shows no enamel. Width of gingival floor is 1 mm.

NOTICE: Minimum depth of gingival floor should be 1mm for convenience and strength of restoration

