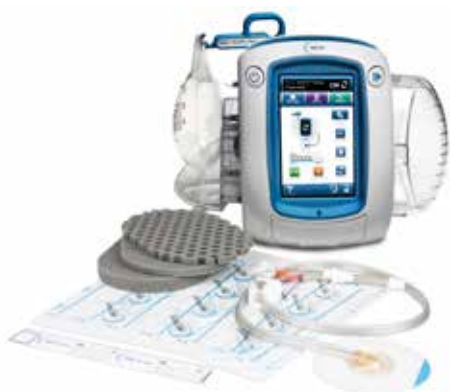



# When surgical debridement must be delayed, now you have another choice!



V.A.C. VERAFLU™ Therapy, using V.A.C. VERAFLU CLEANSE CHOICE™ Dressing provides an option to help cleanse the wound to facilitate removal of infectious material such as thick fibrinous exudate and slough.

## What you'll need to initiate therapy!



V.A.C. ULTA™ Therapy Unit




V.A.C. ULTA™ Canister - 1000ml



V.A.C. VERALINK™ CASSETTE



Topical wound solution - saline



V.A.C. VERAFLU CLEANSE CHOICE™ Dressing Kit - Medium

## Initiating V.A.C. VERAFLU™ Therapy

### V.A.C. VERAFLU CLEANSE CHOICE™ Dressing Application

Similar to V.A.C.® Therapy, dress the wound as you normally would but ensuring the honeycombed layer is the primary wound contact layer.

### Dressing change frequency

Minimum three times weekly recommended (every 48-72 hrs)

### Default therapy settings (adjust as prescribed)

Soak time 10 minutes

V.A.C.® Therapy time of 3.5 hours at -125mmHg

**On day 7 assess the wound.**



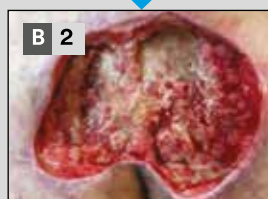
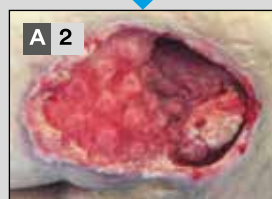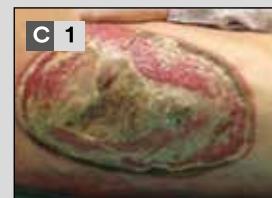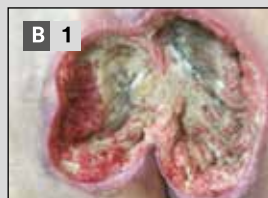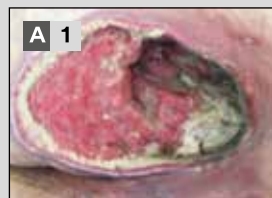# A retrospective study:<sup>1</sup>

## Novel foam dressing using negative pressure wound therapy with instillation to remove thick exudate.

A retrospective data analysis on 21 patients with 21 large complex wounds that contained substantial areas of devitalized and/or yellow fibrinous slough were treated in one hospital by several surgeons.

V.A.C. VERAFLOR<sup>TM</sup> Therapy was delivered with the following settings:

**Solution:** Normal saline  
**Soak time:** 10 minutes



**VAC Therapy:** 3.5 hours  
**Target pressure:** -125mmHg

**Mean # of dressing changes:** 2.9  
**Mean duration of NPWTi-d:** 8.7 days

### Patients:

- 11/21 (52.4%) received surgical debridement prior to NPWTi-d with ROCF-CC.
- 10/21 (47.6%) did not receive surgical debridement prior to NPWTi-D with ROCF-CC (received autolytic debridement, incomplete excisional debridement using a scalpel or curette or no debridement)
- 15/21 (71.4%) has confirmed and treated bone infection

### Results:

- 18/21 (85.7%) wounds had less than 10% surface area with black non-viable tissue remaining after an average of 1-3 dressing applications.
- 12/21 (57.1%) wounds had less than 10% surface area with yellow fibrinous slough remaining after an average of 1-3 dressing applications
- 20/21 (95.2%) wounds displayed rapid granulation tissue formation under the portion of the foam directly in contact with wound bed

As with any case study, the results and outcomes should not be interpreted as a guarantee or warranty of similar results. Individual results may vary depending on the patient's circumstances and condition.

Photos and case study: Photos and case study courtesy of Luc Teot, MD, PhD

**For more information, please contact your 3M + KCI representative**

#### References

1. Teot L, Boissiere F, Fluieraru S. Novel foam dressing using negative pressure wound therapy with instillation to remove thick exudate. Int Wound J 2017;14:842-848.

**NOTE: Specific indications, contraindications, warnings, precautions and safety information exist for these products and therapies. Please consult a physician and product instructions for use prior to application. This material is intended for healthcare professionals.**

©Copyright 2020 3M. All rights reserved. 3M and the other marks shown are marks and/or registered marks. Unauthorized use prohibited. PRA-PM-EU-00269 (03/20)

