

# Microscopic Dentistry A Practical Guide



# Microscopic Dentistry A Practical Guide

**Publisher**

Carl Zeiss

**Authors**

Dr. José Aranguren Cangas  
Dr. Kristina Badalyan  
Dr. Rino Burkhardt  
Dr. Annett Burzlaff  
Dr. Maciej Goczewski  
Dr. Manor Haas  
Oscar Freiherr von Stetten  
Dr. Bijan Vahedi  
Dr. Maxim Stosek  
Dr. Claudia Cia Worschech  
Dr. Tony Druttman

**Editors**

Dr. Tony Druttman  
Dr. Greg Finn

**Coordination**

Slaven Sestic



Dear Reader,

Enhancing the visualization of medical professionals is a core focal point for us at the Medical Technology Business of ZEISS. We strive to help our users across a broad range of medical disciplines see more. Seeing more can help clinicians to generate better outcomes, master even highly complex cases, to gain greater enjoyment and satisfaction from their work and finally - but most importantly - improve patients' lives.

Since its inception in 1921, surgical microscopy has been crucial for the advancement of several surgical fields, such as brain tumour surgery, vascular neurosurgery, cataract or retinal surgery.

As Pioneer in Surgical Microscopes, we have constantly pushed the boundaries of visualization. Today, a large number of the mentioned surgical procedures would not be conceivable without the use of a surgical microscope.

In dental visualization we are at an earlier stage of this journey. Even though the surgical microscope has become the standard of care in endodontics, today only a single-digit percentage of all dentists worldwide enjoy the benefits of working with this tool. We firmly believe that this will change as the surgical microscope will pave the way to accelerated medical progress in many applications in dentistry by giving the clinician a greater degree of control in a range of delicate procedural steps.

In endodontics, the surgical microscope is already an integral part of the postgraduate curriculum. For other dental applications, we are not there yet. Therefore many dentists are seeking guidance on how to integrate microscopy into their daily practice, beyond endodontics. To help fill this gap, we asked leading clinical specialists in different disciplines of micro-dentistry to contribute to this publication.

The authors have succeeded in providing a most valuable guide to using the surgical microscope in a range of dental applications. The articles were written with the idea in mind that they shall enable a step-by-step implementation that unlocks the full potential of surgical microscopy in your daily practice:

How can the surgical microscope support an ergonomically correct, upright working position which is health promoting for the dentist over the long term?

How can the surgical microscope broaden your clinical scope and increase your efficiency - as key to the realization of a return on your investments?

How can the use of the surgical microscope add crucial benefit to specific procedural steps in every major dental application?

How can documentation with the surgical microscope increase patients' involvement in the treatment and demonstrate your skills?

I am confident that implementing some of the precious insights of this book in your daily practice will change your professional life for the better.

Sincerely,

A handwritten signature in black ink, appearing to read 'C. Schwedes'.

Dr. Christian Schwedes  
Director Business Sector Dental & Office,  
Carl Zeiss Meditec AG

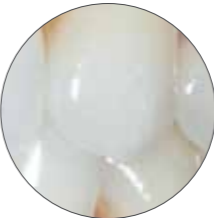<b>1</b> The OPMI	<b>2</b> Ergonomics	<b>3</b> OPMI in Endodontics	<b>4</b> OPMI in Periodontology and Implantology	<b>5</b> OPMI in Restorative and Prosthodontics	<b>6</b> Documentation	<b>7</b> Practice Management
25 <b>Why use a surgical microscope?</b>	55 <b>Definitions of ergonomics</b>	73 <b>Introduction</b>	105 <b>Do we need an OPMI in periodontal and implant therapy?</b>	135 <b>Why use the surgical microscope in restorative and prosthodontic dentistry?</b>	181 <b>Why?</b>	191 <b>The benefits of the OPMI extend far beyond the obvious and well-proven clinical benefits.</b>
26 Benefits	56 <b>Overloads</b>	74 <b>Magnification in endodontics</b> Working magnification	106 <b>What are the advantages and disadvantages of the use of an OPMI in periodontology and implantology?</b>	136 <b>Prevention and diagnosis</b>	182 <b>How?</b> Photo/video	192 <b>Integration into clinical practice</b>
27 How the OPMI differs from medical loupes and the intra-oral camera	58 <b>Minimizing overloads</b>	75 Uses of the OPMI in endodontics	110 <b>What does the “microsurgical concept” consist of?</b>	137 <b>Bacterial plaque</b>	186 <b>Practical advice</b>	193 <b>The OPMI as a communication tool</b> Dento-legal aspects
28 <b>The human eye – how it works and why it is limited</b> Accommodation	60 Position of dentist	76 <b>Microendodontic instruments</b>	122 <b>Which are the first steps to getting used to working with the OPMI?</b>	138 <b>Caries</b>		194 <b>Marketing the OPMI</b>
29 Stereoscopy	61 Operator range of 9-12 o'clock working positions	77 Ultrasonics Ultrasonics tips Uses of ultrasonics in endodontics	126 <b>How can you acquire expertise in periodontal and peri-implant microsurgery?</b>	142 <b>Fractured line – “cracks”</b>		195 <b>Health benefits to the dentist</b>
30 <b>The components of an OPMI</b>	62 Position of the patient	78 Mirrors Micro instruments Files with a handle Stropko syringe	128 <b>Which are the common errors in the use of the OPMI in surgical practice?</b>	148 <b>Preparation control</b>		196 <b>Financials of the OPMI</b>
31 Objective lens	64 OPMI position	79 Burs Dyes	130 <b>References</b>	150 <b>Matrix adaptation</b>		
32 Varioscope	66 <b>Functional design</b>	80 <b>Examination of the external surface of the tooth</b>		153 <b>Rubber dam applications in anterior and posterior areas</b>		
34 Magnification changer	67 <b>OPMI assistance</b>	82 Identification of the floor of the pulp chamber		154 <b>Cervical lesions</b>		
35 Zoom system		83 Removal of coronal restorations Preservation of tooth structure		156 <b>Finishing and polishing</b>		
36 Binocular tube		84 Assessment of canal cleanliness after preparation		160 <b>Possibilities for analyzing the surgical field at different magnifications</b>		
37 Eyepieces		85 Identification of internal cracks		164 <b>Replacements – avoiding wear</b>		
38 Set-up OPMI – Quick Guide		86 Canal location		166 <b>The Tunnel preparation technique</b>		
40 Co-observation		88 Calcified canals		168 <b>Indirect restorations</b>		
41 <b>Optics</b> Correction for chromatic aberration		91 Evaluation and management of perforations		172 <b>Instruments</b>		
42 High transmission of light Depth of field		92 Obturation of the canal Non-surgical retreatment		174 <b>Excellence in operative and prosthetic dentistry with regard to communication with patients</b>		
44 Field of view		93 Uses of the OPMI in non-surgical retreatment:		176 <b>References</b>		
45 How to calculate end magnification		95 Apical plug with MTA File evaluation				
46 <b>Ergonomics and workflow</b> Varioscope		94 <b>Endodontic root-end surgery</b>				
47 Looking around the corner – MORA interface and angled optics						
48 <b>Light</b> Light sources						
49 Filters and pinhole diaphragm						
50 <b>Free floating system – balanced system and magnetic brakes</b>						
51 <b>Maintenance</b>						

The moment you see a hidden detail  
reveal a visible success.

**This is the moment we work for.**



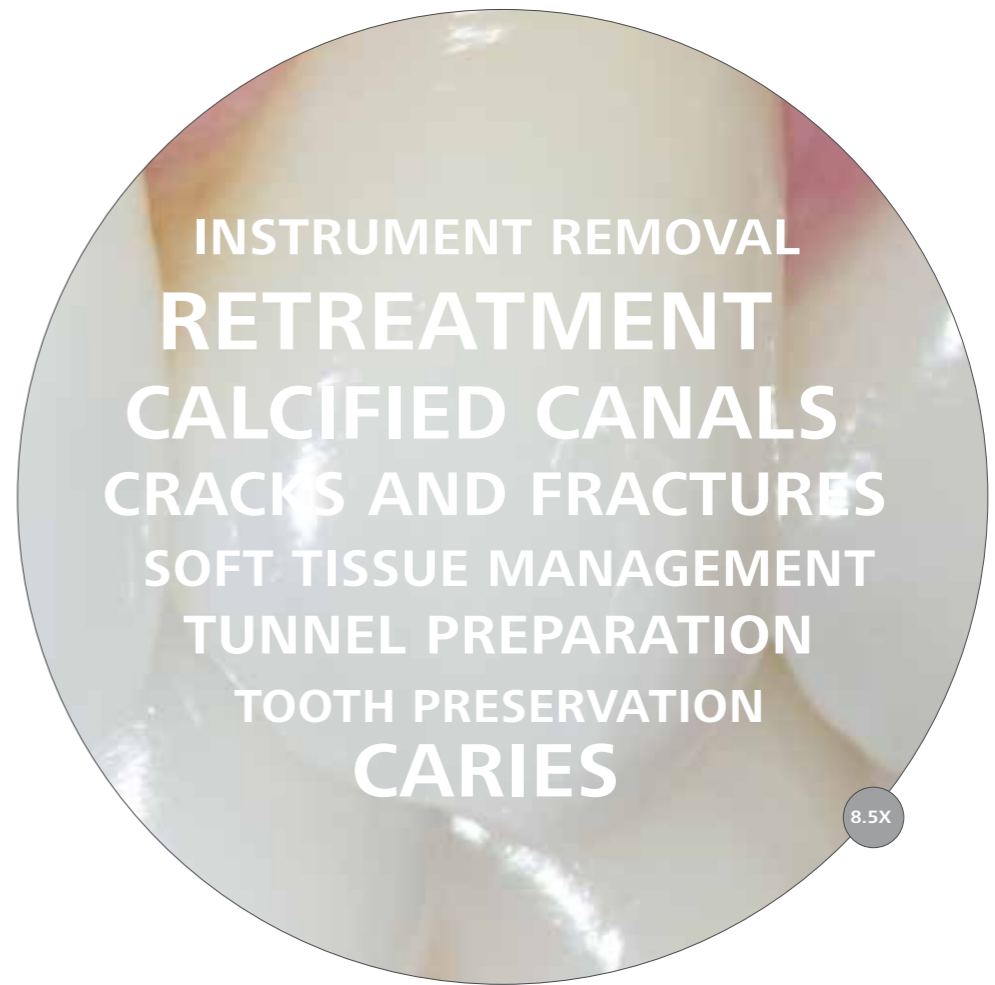Key benefit 1 // **Magnification with OPMI\***



You can only treat what you can see...

\*OPMI – Operation Microscope

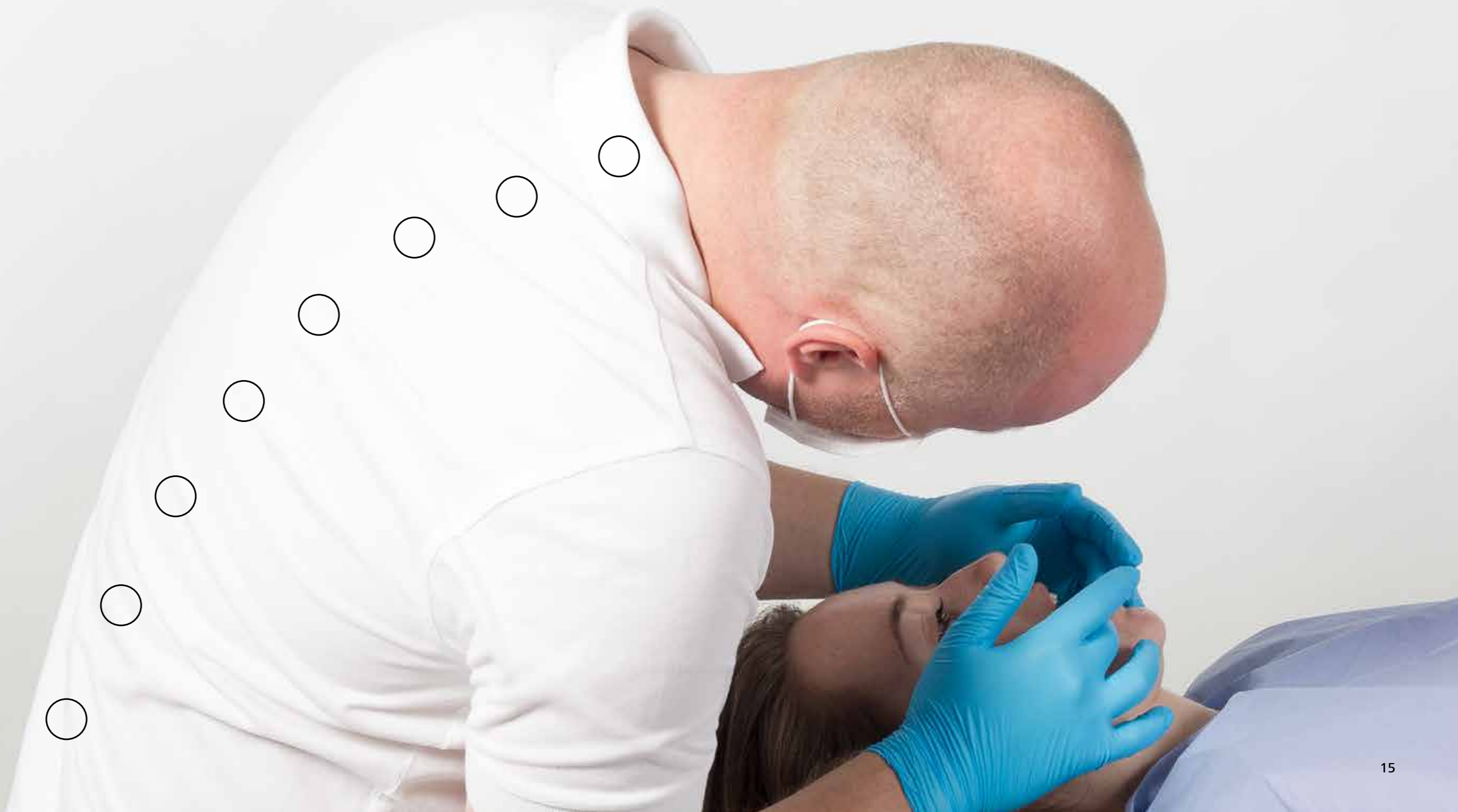Key benefit 1 // **Magnification with OPMI**



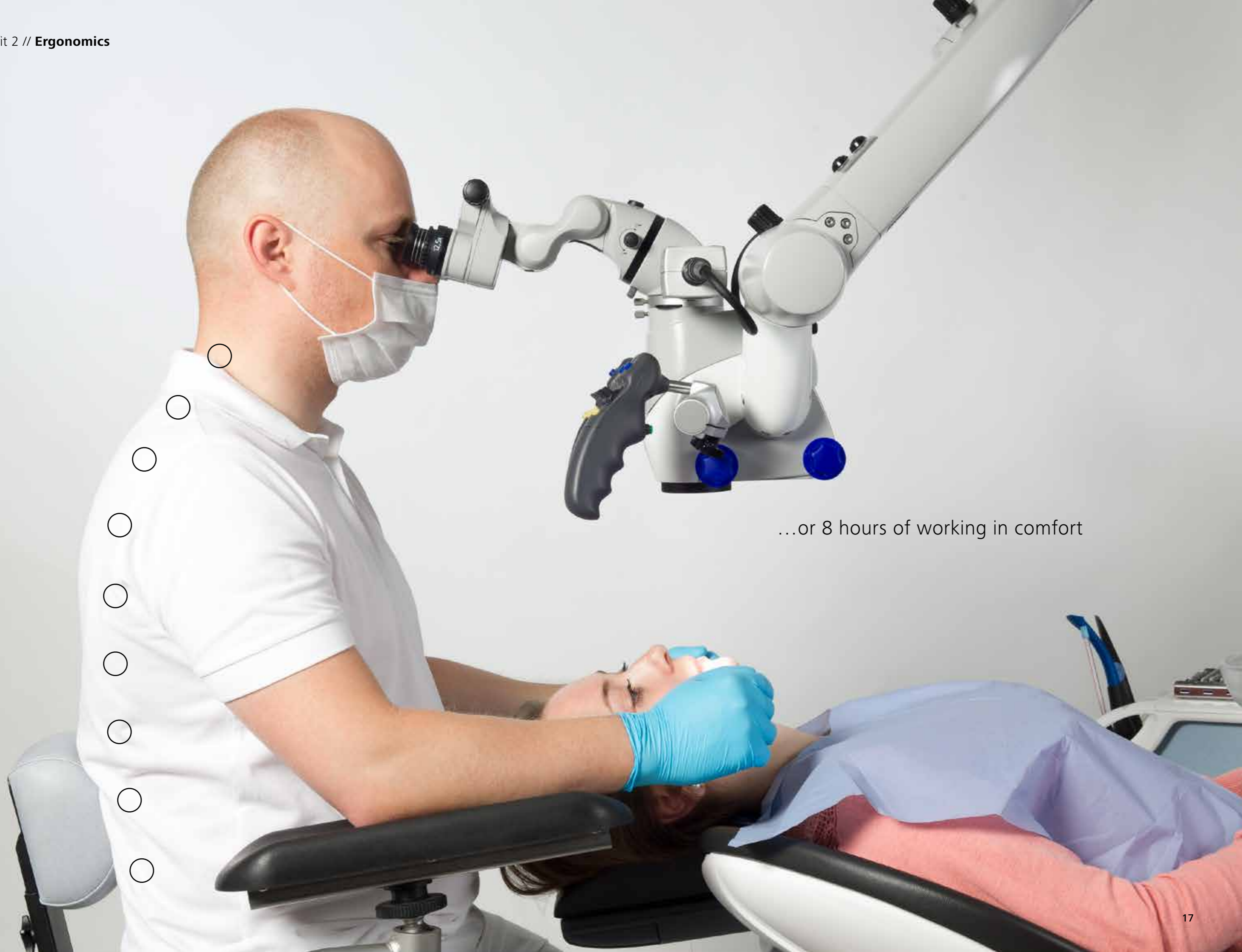...or you see more and treat more

13.6X

8 hours of spine strain...

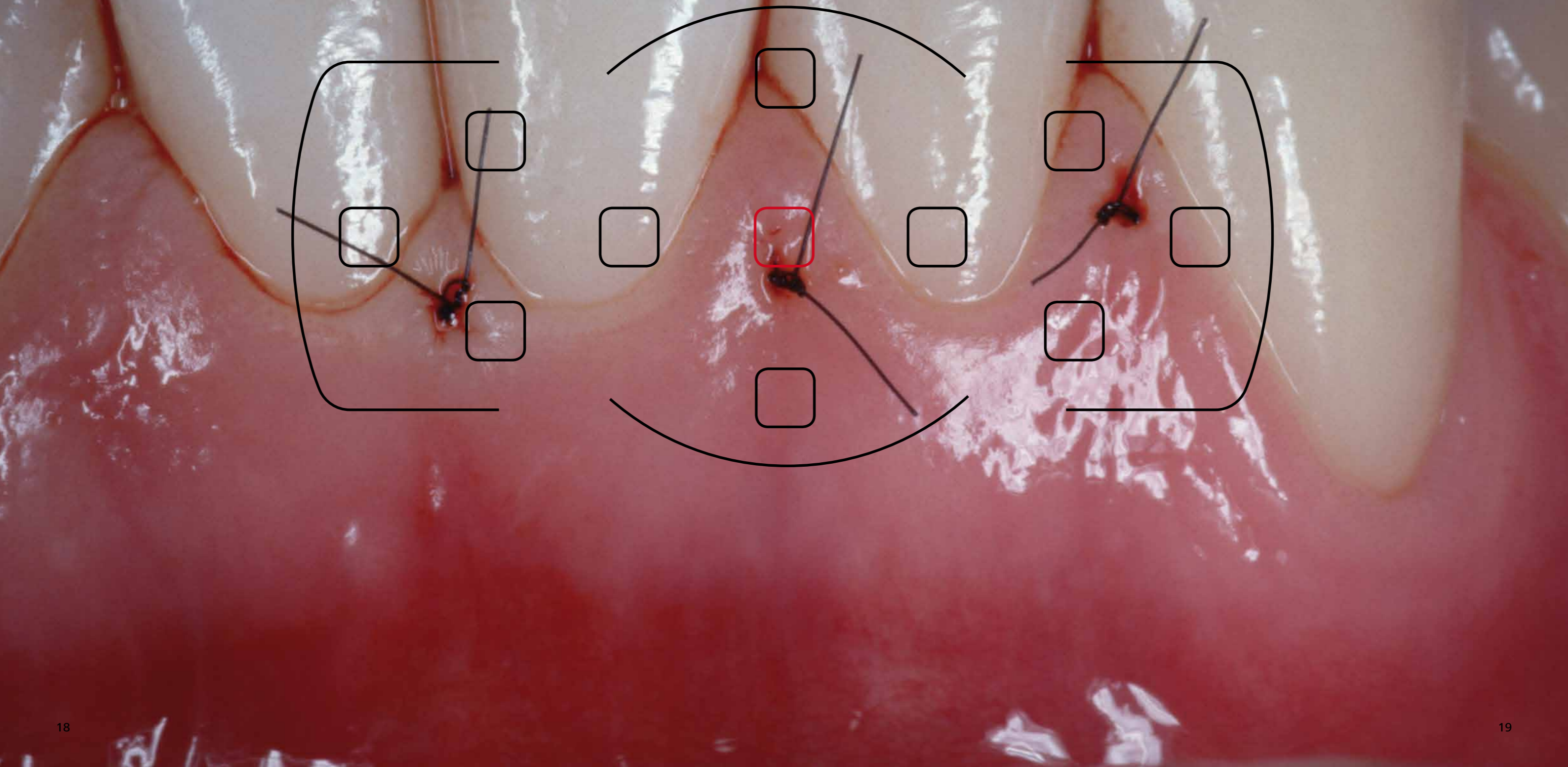


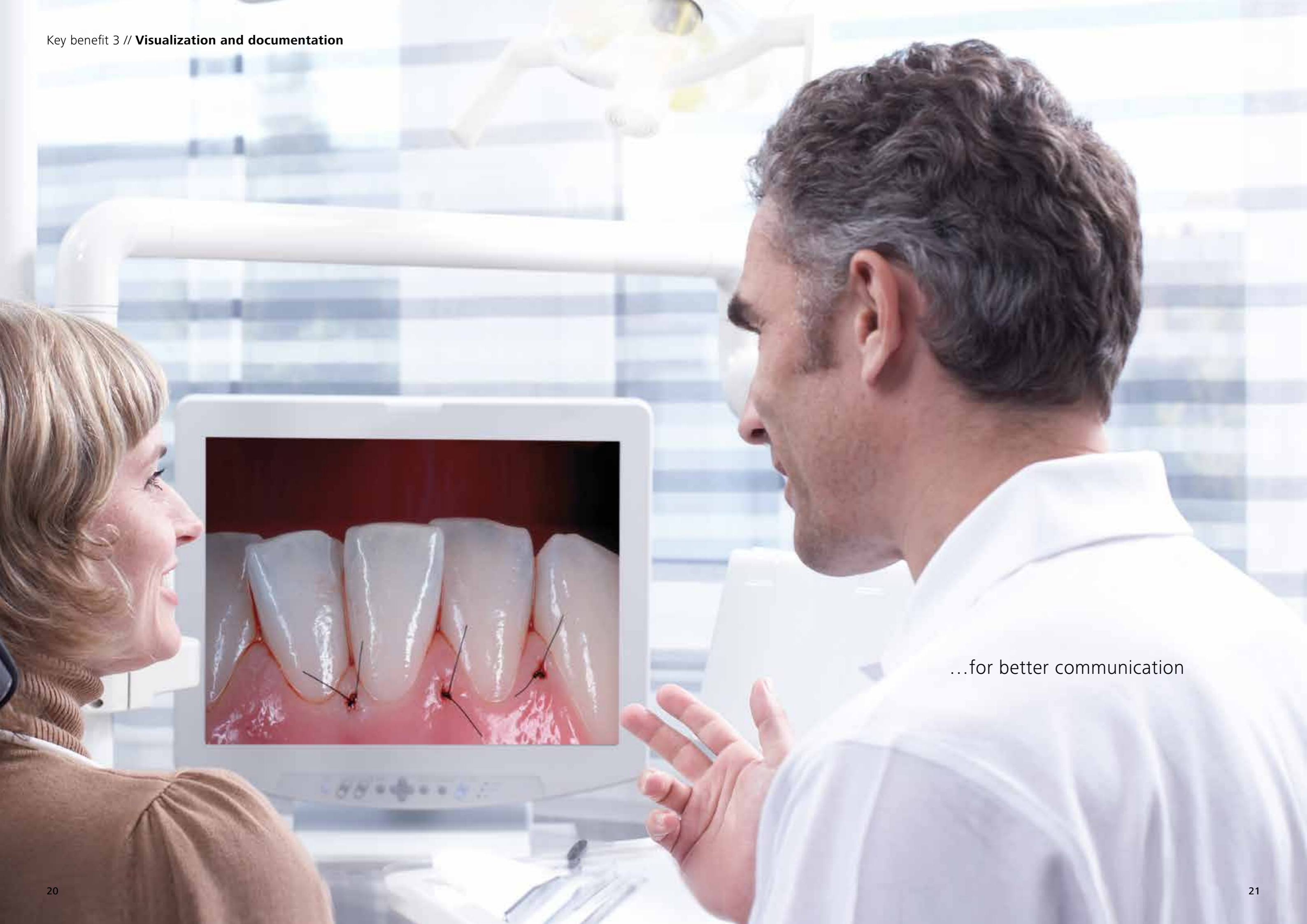




...or 8 hours of working in comfort

A picture is worth a thousand words...





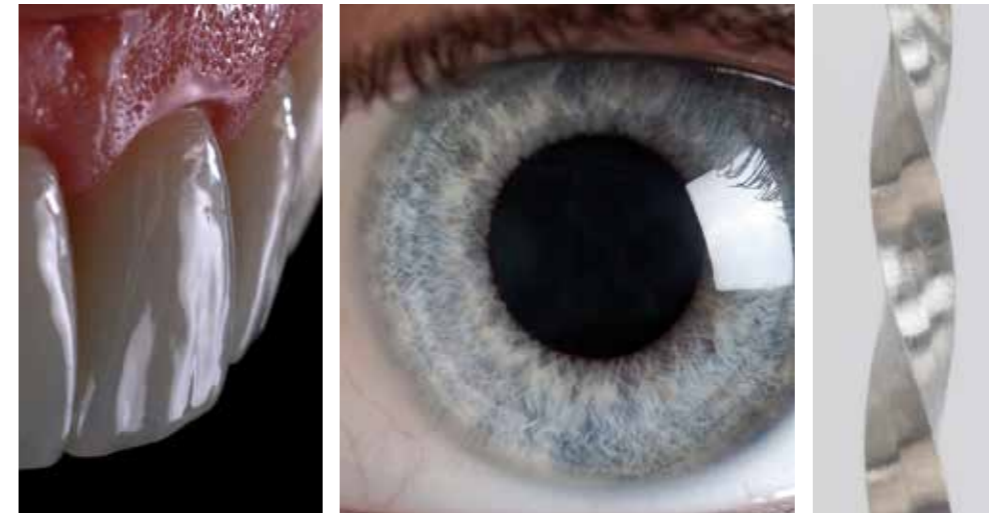
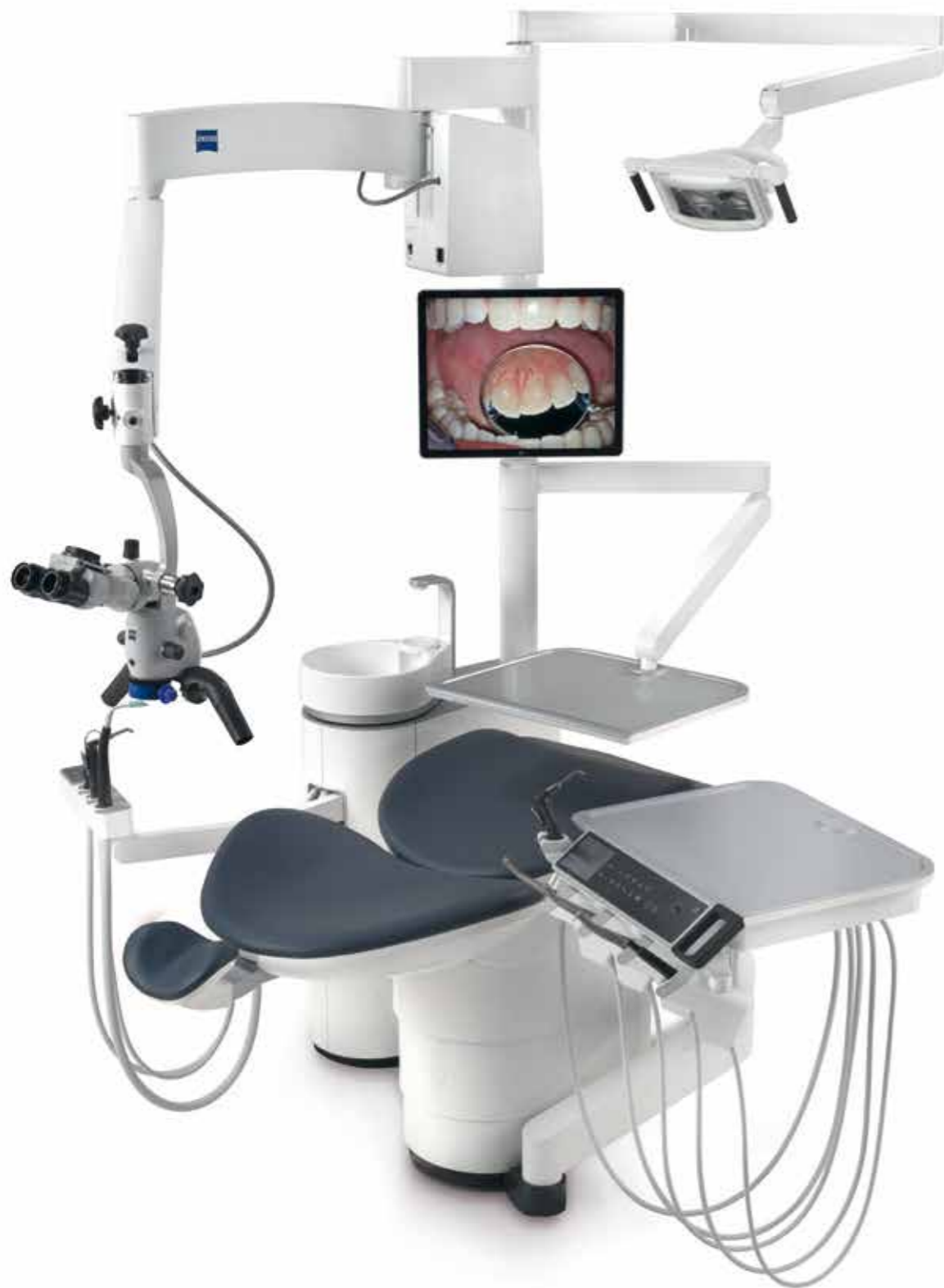...for better communication

# 1

## 1 The OPMI

Author: **Dr. Annett Burzlaff**

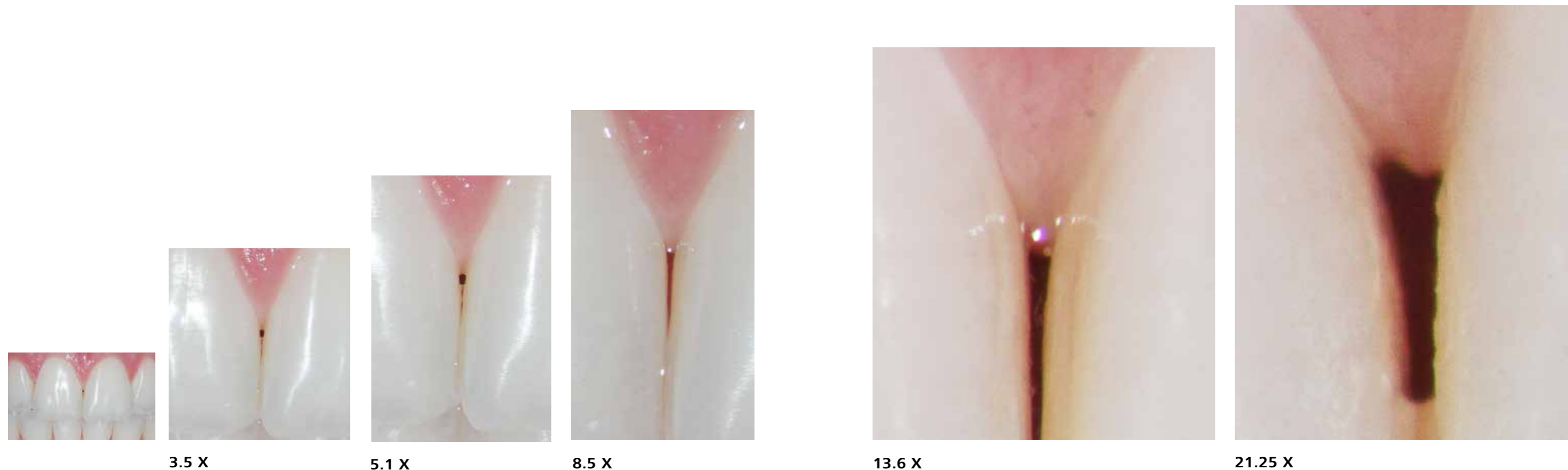
- 25 **Why use a surgical microscope?**
- 26 Benefits
- 27 How the OPMI differs from medical loupes and intra-oral camera
- 28 **The human eye – how it works and why it is limited**
- Accommodation
- 29 Stereoscopy
- 30 **The components of an OPMI**
- 31 Objective lens
- 32 Varioscope
- 34 Magnification changer
- 35 Zoom system
- 36 Binocular tube
- 37 Eyepieces
- 38 Set-up OPMI – Quick Guide
- 40 Co-observation
- 41 **Optics**
- Correction for chromatic aberration
- 42 High transmission of light
- Depth of field
- 44 Field of view
- 45 How to calculate end magnification
- 46 **Ergonomics and workflow**
- Varioscope
- 47 Looking around the corner – MORA interface and angled optics
- 48 **Light**
- Light sources
- 49 Filters and pinhole diaphragm
- 50 **Free floating system – balanced system and magnetic brakes**
- 51 **Maintenance**



## Why use an OPMI?

Can you still remember the first time you looked through a microscope or magnifying glass? Perhaps the first thing you saw was a daisy which you thought you knew well, but which then under the OPMI opened up a new world for you. We are not only drawn into the microcosm by our curiosity, but we also benefit from the insight we can gain into intricate details and structures. Microscopy is an integral part of many surgical disciplines nowadays. Doctors first used the surgical microscope for microsurgical operations in the ENT area in 1921. Ophthalmologists then attached lighting technology to the surgical microscope and used it to perform eye operations. In the mid-1960s, neurosurgeons recognized the advantages of using OPMIs for operations. Neurosurgery is today no longer imaginable without documentation and navigation systems. The OPMI had been undergoing development for around 60 years before finding its way into the world of dentistry.

Beginning in 1990, many innovative dentists from numerous countries pressed for the use of OPMIs in dentistry: this drive towards microdentistry was led by Dr. Syngcuk Kim (Philadelphia, Pennsylvania) and Dr. Clifford Ruddle (Santa Barbara, California) in the USA, as well as Dr. Peter Velvart (Zurich, Switzerland) in Europe, among others. While endodontics is the main discipline in which OPMIs are used in dentistry, other disciplines such as periodontology, implantology or restorative dentistry are adopting the use of magnification technology. The dentist benefits from several advantages of OPMIs, regardless of the discipline. Magnification enhances the visual acuity and supports more precise treatment. However, no light means no information. OPMIs are therefore designed in such a way that they combine the magnifying lens and the light source. No matter whether they are working with low or high magnification, the dentists benefit from shadow-free, direct light. It is natural for us to orientate ourselves visually in our surroundings. That is how we judge distances and perceive size and space. We are able to do this thanks to stereoscopic vision. An OPMI provides the conditions required for stereoscopic vision and therefore for depth orientation. This, in turn, enables the safe, precise use of instruments and improves ergonomics. Relaxed eye muscles and being able to sit upright during treatment prevent fatigue and posture impairments.



### Benefits

When working with instruments on a patient, a certain distance is required between the object, i.e. the tooth in the oral cavity, and the front lens of the OPMI. This is what is referred to as the working distance. In dentistry, the working distance with an OPMI is usually between 200 and 300 mm to ensure that enough space is provided to handle the instruments over the patient. The correct working distance depends on the height of the dentist. The taller the dentist, the longer the working distance. Using the correct individual working distance on an OPMI is crucial for a correct working posture. Using an OPMI supports the ergonomics of the dentist as the microscope can more or less look "around the corner". Therefore, the dentist can sit upright and benefits from good ergonomics.

A correctly configured OPMI can prevent symptoms of fatigue. On the following pages you will find detailed information about the components of an OPMI, what makes a good image and how to best configure the microscope.

### How the OPMI differs from medical loupes and the intra-oral camera

In dentistry, the first introduction into the world of magnification is generally a medical loupe. A medical loupe fulfills some of the aforementioned requirements and benefits, but compared to an OPMI is somewhat limited in its options. Medical loupes are available with a fixed magnification between 2 - 5 times. If the dentist wishes to have a different magnification, this requires using a different pair of loupes. The magnification factor of an OPMI is variable between approximately 1.5 - 30 times and can be altered by using the magnification changer or zoom system, depending on the model of OPMI. While an overview of the mouth can be seen at lower magnifications, detailed structures can be viewed better using the higher magnification of an OPMI, e.g. to locate a root canal, or to find additional root canals. This

enables the dentist to switch between overview to detailed view in a matter of seconds. The working distance of a medical loupe is fixed. Since a medical loupe is worn on the dentist's head, it follows every movement of the wearer. For the duration of the movement, the field of view is blurred to a greater or lesser extent. The dentist has to find the correct working distance to enjoy a fully focused image again. The OPMI on the other hand, is mounted on a stand, is moved into position by the dentist and then remains stable. Special optics allow the working distance to be changed to ensure a comfortable working posture of the dentist. The higher the magnification of loupes, the heavier they become and therefore potentially more uncomfortable. Modern loupes also have a battery operated headlight which needs to be recharged periodically.

Intra-oral cameras also provide magnified images, but they are only two-dimensional and do not provide any depth information. When looking through the OPMI, the dentist has three-dimensional vision which is important for orientation and perception of spatial dimensions. This is necessary, for example, to correctly position the dental instruments. In addition, when using the intra-oral camera the dentist has to interrupt the workflows to record images. Video recording of treatment has to be done by a third party. Conversely with an integrated camera or with still or video cameras attached to the OPMI, images or video recordings of exceptional quality can be obtained while treatment is being carried out.

# The human eye – how it works and why it is limited

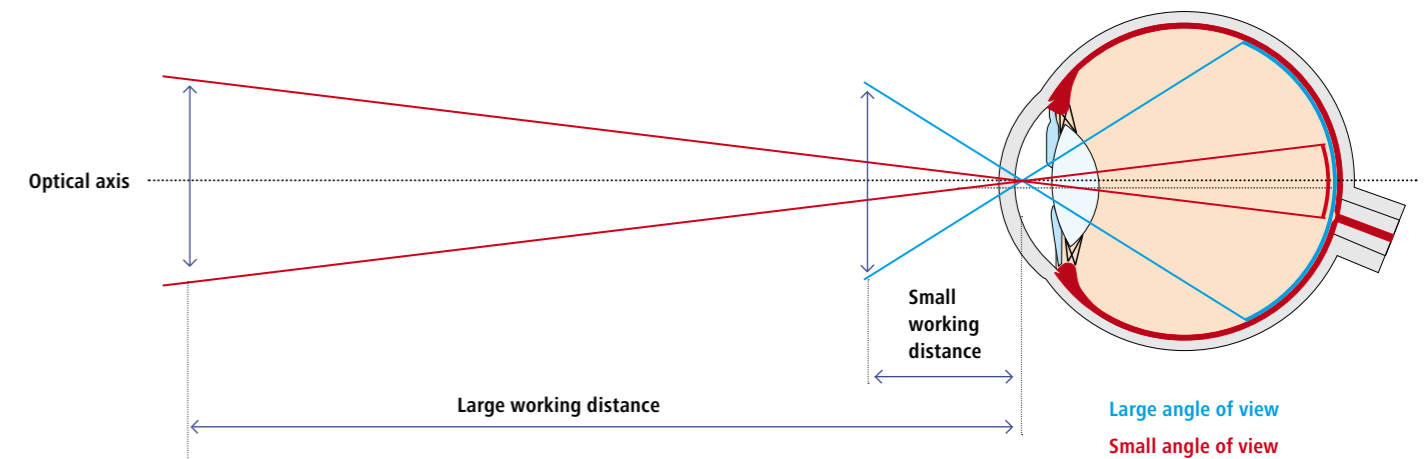
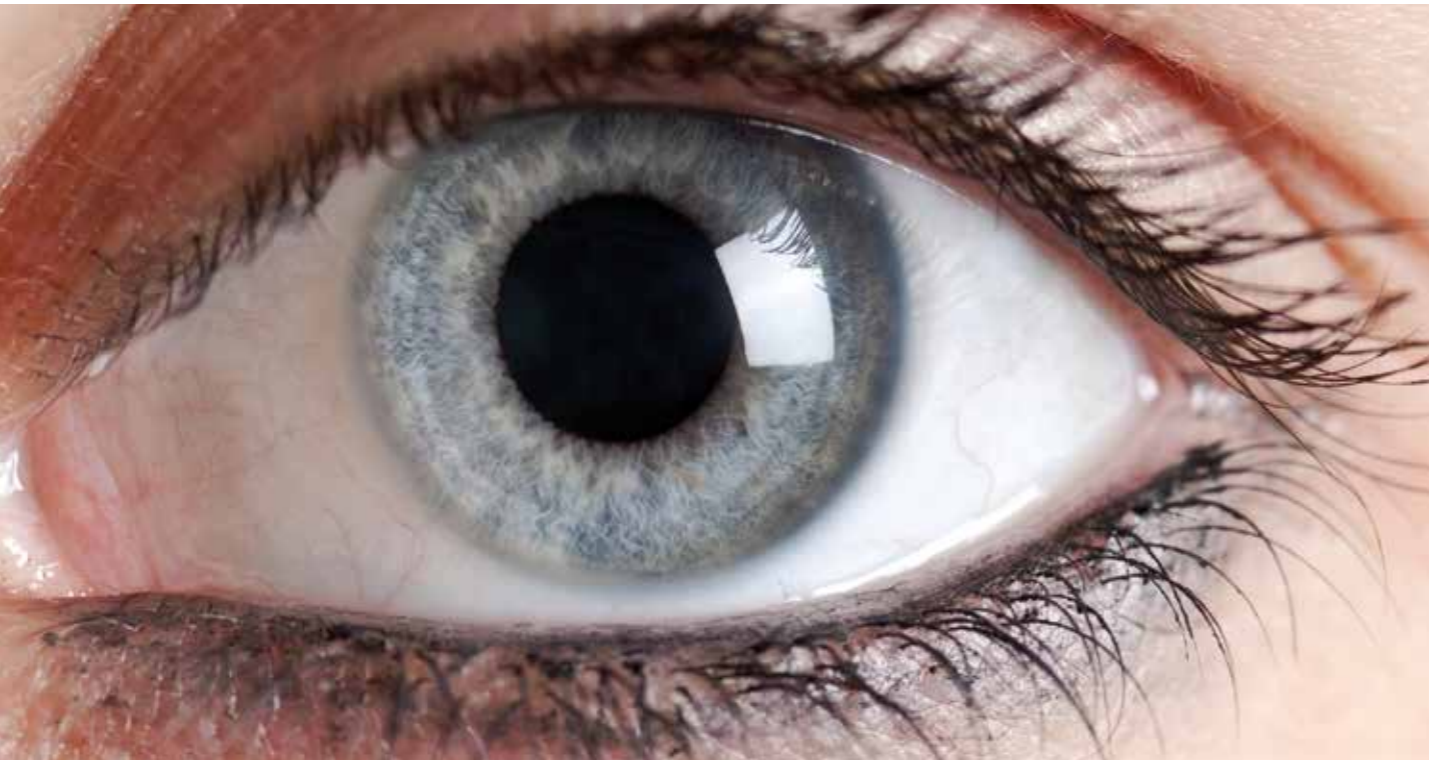


Figure 1.1: The focused object is on the optical axis. The farther the object is removed from the eye, the smaller the angle at which it is projected on the retina. Finer details can be recognized only if the object is closer to the eye and thus the angle to the retina is greater

## Accommodation

The human eye is a flexible optical system that can adapt to various requirements. It can produce an image of objects at a great distance, but we can also read a text that is only 30 cm away. The eye adjusts to various distances. In order to focus objects at various distances, a system of muscles generates the required refractive power for the lenses of the eyes. If we look at a landscape, the ciliary muscle is relaxed and the lens is flat. However, if we read text, the ciliary muscles contract, causing the lens to become convex. The refractive power is thus increased and we can clearly recognize small letters. Extended contraction of the ciliary muscle can cause fatigue. In order to relax the eyes, we look to a more distant scene. If we look at a small object from a greater distance, it is

depicted on the retina with a small angle of view. To be able to see fine details, we have to bring the object closer to the eye. As a result, the angle of view increases and we can break down the individual structures (Figure 1.1). This is why a dentist has to bend down over the patient's oral cavity in order to be able to see details at a distance of approximately 30 cm. The easiest type of magnification is therefore to bring an object closer to the eye. However, the eye's abilities are limited. A baby can clearly see objects that are 7 cm away, a 30 year-old person at 30 cm. On reaching the age of 40, most people become presbyopic and the distance between the object and the eye becomes increasingly bigger. The eye's ability to accommodate to short distances deteriorates, meaning that we can no longer focus as well on

near objects. The ability to see detailed structures also begins to deteriorate. An OPMI overcomes these natural limitations. On the one hand, it magnifies detailed structures, and the fine structures can then be distinguished. On the other hand, the eye can adjust almost to infinity when looking through an OPMI. This relaxes the ciliary muscles and fatigue symptoms are reduced.

## Stereoscopy

The fact that we have two eyes that are adjacent to one another forms the basis of stereoscopic vision. The left and right eyes perceive a particular object from two different angles (parallax). The brain then puts these two slightly different sets of visual information together to form a 3D image. This allows us to see the third dimension, to estimate distance, size and position and to orientate ourselves. We also require three-dimensional image information when looking at a treatment area. Only with three-dimensional vision are we able to determine whether the tip of

an instrument is in front of, next to or behind an anatomical structure. In order to enable this orientation, OPMI's are designed as stereomicroscopes. This enables the left and right eyes to view an object from slightly different angles. We can then retain three-dimensional vision and this depth perception when looking through the OPMI.

# The components of an OPMI

Before going into greater detail about the individual components of an OPMI, let us first look at the optical paths (Figure 1.2).

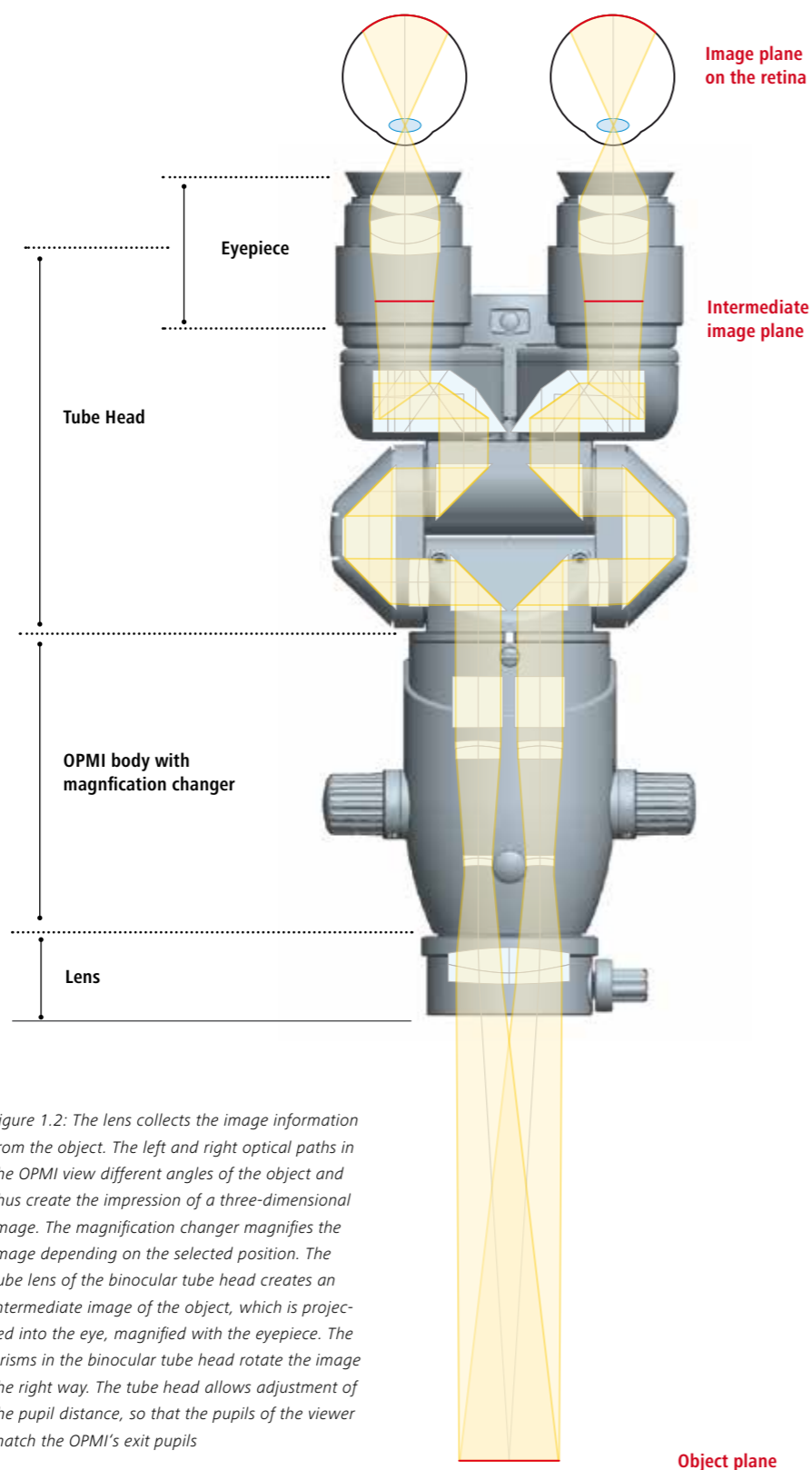


Figure 1.2: The lens collects the image information from the object. The left and right optical paths in the OPMI view different angles of the object and thus create the impression of a three-dimensional image. The magnification changer magnifies the image depending on the selected position. The tube lens of the binocular tube head creates an intermediate image of the object, which is projected into the eye, magnified with the eyepiece. The prisms in the binocular tube head rotate the image the right way. The tube head allows adjustment of the pupil distance, so that the pupils of the viewer match the OPMI's exit pupils

If the treatment field is in the focal plane of the objective lens, the objective lens creates an image at infinity. Behind the main objective lens the optical paths are parallel. Different components like the magnification changer or the beam splitter can be inserted. The magnification changer magnifies or minimizes the image by a given factor. The binocular tube head is placed on the OPMI body and contains the two eyepieces for the left and right eyes. The two optical paths provide slightly different viewing angles, which creates the stereoscopic image impression. The distance between the two optical paths is referred to as the stereo base. The stereo base is essential for producing a three-dimensional image. The binocular tube creates an intermediate image which is magnified by the eyepiece and projected onto the exit pupils. The lens of the eye then receives the image and focuses it on the retina.

## Objective lens

The objective lens is the first optical component that the image information crosses on its path from the object to the eye. The lenses vary in their focal distance (= focal length). This influences the working distance (i.e. the distance between the object in the treatment field and the surface of the lens), the magnification and the resolution. These three criteria influence one another. The most common working distances are 200, 250 and 300 mm. The focal distance of e.g.  $f = 250$  mm is engraved on the lens mount. This roughly equates to the working distance of the lens. In order to view the image clearly, the OPMI lens ( e.g.  $f = 250$  mm) must have a working distance of approximately 250 mm to the object. The object is then within the focal point of the lens. The OPMI can be raised or lowered to focus the object, provided the lens has been set to a distance of e.g. 250 mm from the object. The shorter

the focal distance, i.e. the working distance of the lens, the greater the end magnification (for calculation of the end magnification, see Section 4.5) and the greater the resolution. The lens should be equipped with a fine-focus knob. That means that even at high magnification levels, images can be precisely focused over a short distance (e.g. when viewing root canals in great detail). To change the working distance, the lens must be unscrewed and replaced with an lens with a different focal distance. However, this is impractical in practice and interrupts the workflow. A varioscope is useful in this event and offers much more flexibility as it can change the working distance continuously.





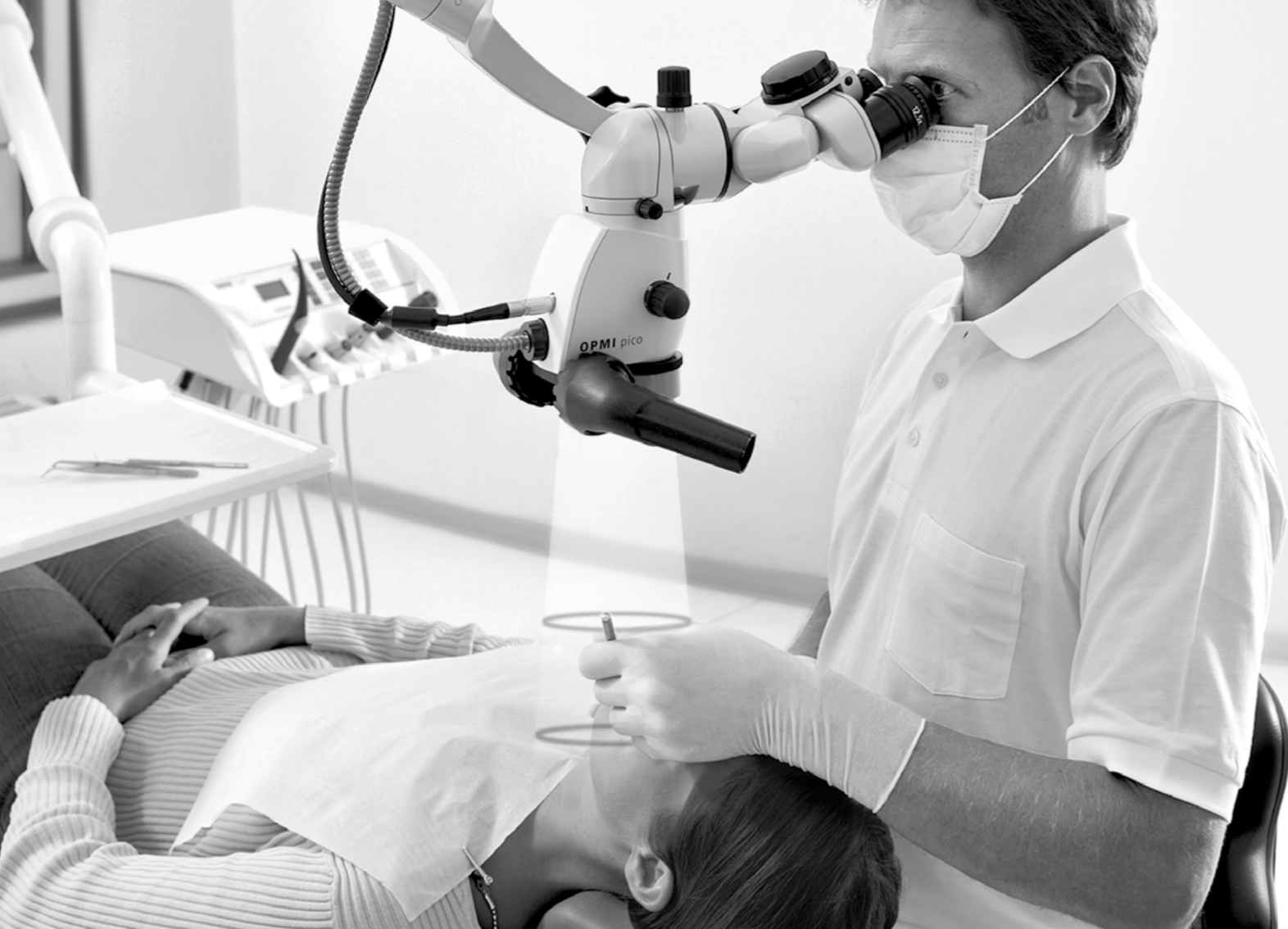

Figure 1.3: Using Varioskop 100 of OPMI pico the dentist can focus continuously, for example, from the incisors to the molars in the patient's oral cavity without changing the position of the OPMI. The height of OPMI pico can be set in a range from 200 to 300 mm above the patient's oral cavity allowing adaptation to the personal ergonomic needs of the dentist.

### Varioscope

Unlike an objective lens with fixed focal length, a varioscope has a variable focal length. Therefore, it can be set to a range of working distances to meet different application and ergonomic requirements. The focal range of a varioscope can be varied from 200 to 300 mm or even from 200 to 415 mm depending on the OPMI. This ensures a wide range of working distances for a comfortable working position, even for hours at a time. Unlike an OPMI with a fixed focal length lens, it is not necessary to raise or lower an OPMI with a varioscope to focus it within its focal range. For example, it is possible to focus by turning the focus knob of the varioscope from the incisors to the molars in the patient's oral cavity without moving the OPMI. Using the varioscope instead of moving the OPMI

up and down results in much more precise focusing and speeds up the workflow. How is this possible? The lens system of a varioscope is composed of two lens groups. To focus at a selected working distance, the upper lens group is repositioned along the optical axis (Figure 1.4). The adjustment of the focal plane within the working distance range can be performed manually (S100 / OPMI pico with Varioskop 100) or motorized (S7 / OPMI PROergo). When using a manual Varioskop 100 on OPMI pico, it can be controlled by manually turning the knob on the varioscope (Figure 1.3). When using a

motorized varioscope of OPMI PROergo, it can be controlled by pressing a button on the handgrip (Figure 1.5). This makes the workflow more efficient and contributes significantly to the ergonomics of the OPMI. Automatic focus is even more convenient. By pressing a single button, the ZEISS SpeedFocus system of the OPMI PROergo focuses the OPMI in a matter of seconds by analyzing live images recorded by a camera.

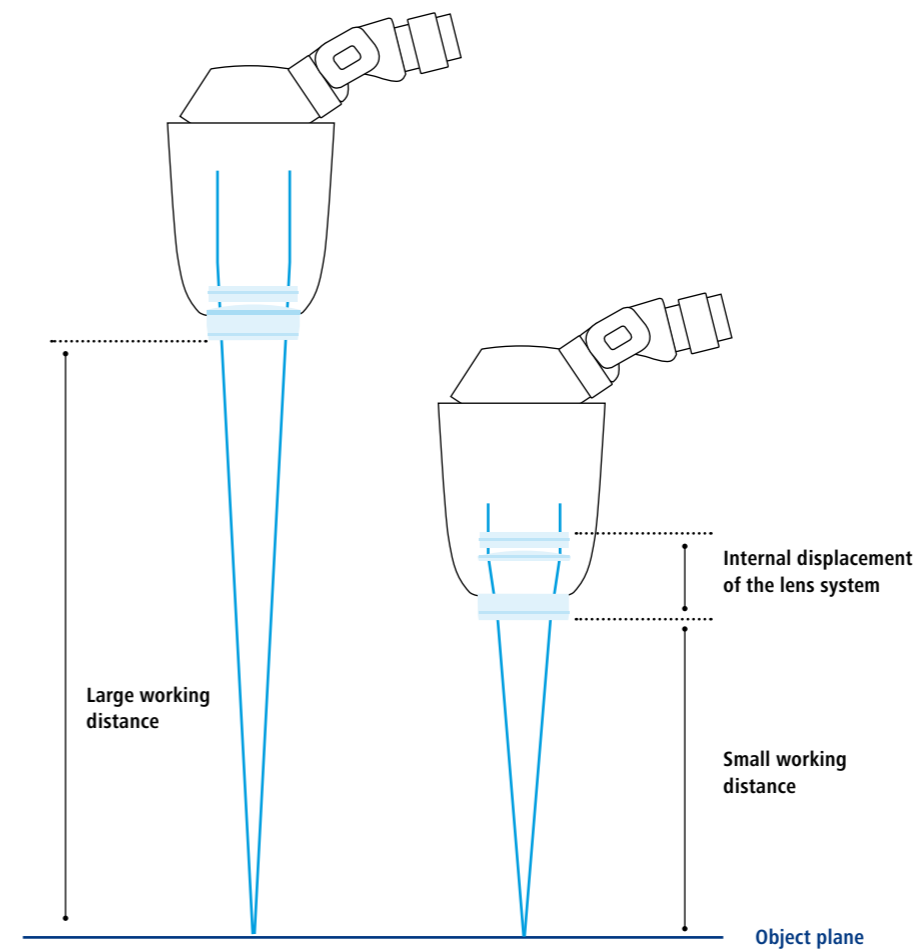


Figure 1.4: The working distance can be changed according to the internal displacement of the varioscope's second lens system. There are motorized varioscopes which focus on the image at the press of a button. Therefore, the dentist can focus without changing his or her own seated position. The height of the OPMI can be set in a range from 200 to 415 mm, e.g. above the patient's oral cavity. This allows the dentist to adjust the OPMI to suit his or her individual ergonomic needs

Figures 1.5a, 1.5b: OPMI PROergo comes with a motorized varioscope. The dentist can vary the working distance over a range of 200 – 415 mm by using the control button of the handgrip

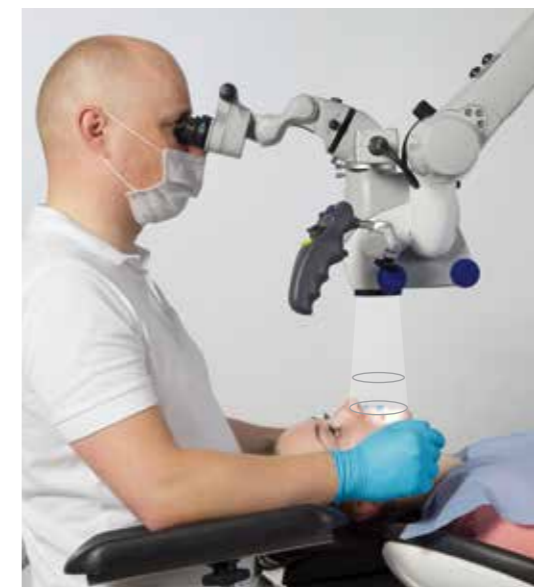



Figure 1.6: A five-step magnification changer is composed of a turret with two telescopes and one position without a lens. Depending on the position of the magnification changer in the optical path, there are different magnification factors. The factor in the lens-free position is 1.

### Magnification changer

During treatment it is important that the magnification factor can be altered to gain an overview at lower magnifications and to view in more detail at higher magnifications. There are two technical solutions for this purpose: the magnification changer (= Galilean changer) and the stepless zoom system. The majority of OPMI are fitted with a magnification changer. The most common magnification changer has 5 steps. The optical principle is an astronomical telescope, called the Galilean telescope after its inventor.

The magnification changer is composed of a turret with two telescope systems of different magnification factors (Figure 1.6). By turning the turret the telescopic systems can be viewed in either direction to achieve different magnification factors. There is a total of four magnification factors plus one

empty position without optics that provides a magnification factor of 1. Therefore, a total of 5 magnification factors are available. Usually the magnification factors are 0.4, 0.6, 1.0, 1.6, 2.5. (Please note that these numbers are not the end magnifications. To calculate the end magnification, further optical parameters must be considered, as described in Section 4.5). The ratio between the largest and the smallest magnification factor gives the extension range of the magnification changer:  $2.5 / 0.4 = 6.25$ . The magnification ratio is 1:6.25.

The advantage of step magnification changers is their compact construction with low technical complexity, yet high optical quality and efficiency. The limitation is that magnification can only be selected in steps, and the view of the treatment area is blocked while the turret is being turned. Turning the magnification factor must be performed manually. Zoom systems are considerably more convenient.

### Zoom system

Zoom systems allow the magnification of the overall system to be set as required by the treatment. The dentist can continuously change between overview and a detailed view. As with the magnification changer, the zoom ratio (1:6) can be calculated by dividing the highest magnification factor (2.4) by the smallest (0.4). The zoom system is composed of several optical elements, of which two are adjustable. By altering the position of the two adjustable elements over a precisely calculated curve, the various magnification factors can be achieved smoothly along the magnification range. In order to achieve the stereoscopic effect, there are two parallel optical paths in the zoom system that must behave absolutely identical with regard to their optics and precision.

#### A zoom system shows its full potential when motorized as in S7 / OPMI PROergo:

- stepless zoom
- faster adjustment of magnification
- control via multi-functional handgrip
- control via foot switch. If the dentist uses a foot switch, he or she can adjust the zoom factor without having to take their hands off the instrument.
- the magnification level can be checked: in combination with an internal video camera, the end magnification or a scale bar can be displayed on the monitor.
- For the purposes of documentation, the image section can be optimally adjusted to the size of the camera sensor, so that a tooth, for example, can be displayed to fill the whole photo or monitor.



Figure 1.7a: For more user comfort, the distance to the surgical field can be adjusted as needed with the multi-link design of the foldable tube f170/f260 head.

### Binocular tube

OPMIs are used in an almost perpendicular position above the patient in dentistry. In order to provide the dentist with a comfortable and ergonomic view into the OPMI, a inclinable or foldable tube head is mounted to the OPMI body and directs the optical path to the eyes of the dentist. A 45° inclined tube head is fixed at an angle of 45° and offers limited ergonomics. A inclinable tube head (0-180°) allows the dentist to alter the angle of the eyepiece holders by 180°. That means that the viewing angle of the tube can be adjusted to the position of the OPMI in such a way that the dentist's head can remain upright and the dentist does not have to lean backwards or forwards - an important requirement for relaxed, ergonomic work. Even more flexible and adaptable to different body heights and working postures of the dentist is the foldable tube head (Figure 1.7). Thanks to its

long reach and multilink design this tube head accommodates different ergonomics of different operators or different positions of the patient.

The tube head also uses the stereoscopic principle of the left and right optical path for a three dimensional image. The binocular tube head contains a lens and has a defined focal distance (e.g.  $f=170$  mm as shown on the tube head). Prisms inside the tube head create an upright, accurate image. The eyepieces in the binocular tube head are the interface between the OPMI and the dentist's eyes. The distance between the pupils varies from person to person and ranges from 54 to 76 mm. It is essential to set the correct individual distance, otherwise the eyes quickly become fatigued and 3D perception is lost. The setting of the eyepieces is described in Section 3.6.

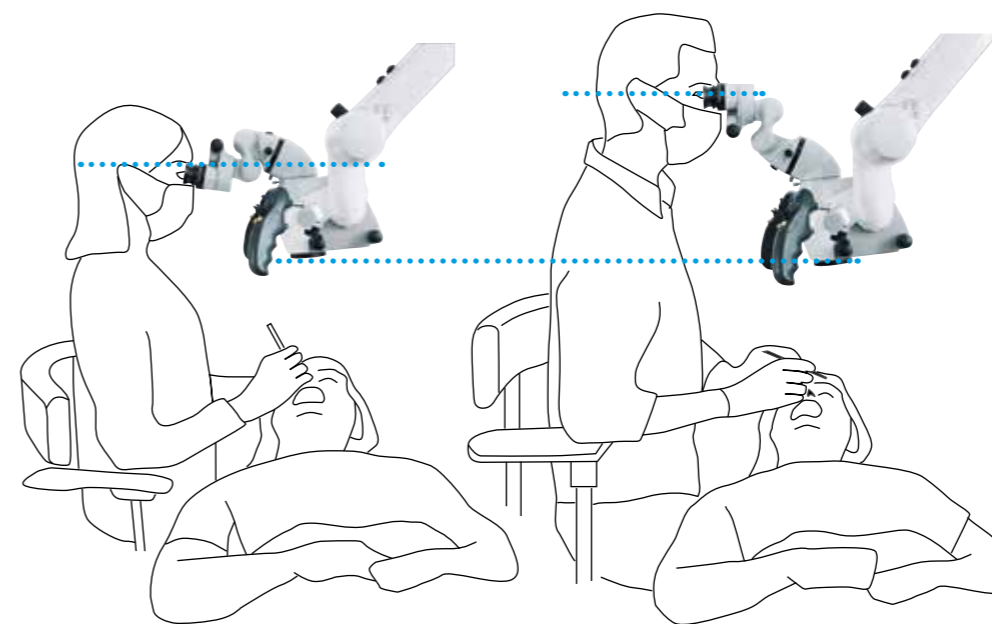


Figure 1.7b: The foldable tube f170 / f260 head accommodates easily to the various ergonomics of different operators. Both dentists can work with the same working distance as the different eye levels of the dentists are compensated for by the adjustable foldable tube f170 / f260 head. The foldable tube head can be mounted to OPMI pico or OPMI PROergo

### Eyepieces

Just like a magnifying glass, the two eyepieces magnify the intermediate image produced in the tube.

The magnification factor (10x or 12.5x) is labeled on the eyepieces. Thus, the eyepieces have an effect on the end magnification. Anyone requiring as high a magnification as possible (e.g. for endodontics) will choose eyepieces with 12.5x magnification. Eyepieces with 10x magnification do, however, provide a considerably larger field of view, and can therefore provide a better overview of the entire treatment area (Figure 1.8).

Eyepieces are fitted with a ring for dioptic adjustment. This means that dentists with perfect or impaired vision can use the OPMI. Ametropia can be corrected to a limited extent. Dentists with impaired vision should wear their glasses or contact lenses when using the OPMI, because the OPMI's corrective

ability is limited and the dentist needs to be able to see normally when not looking through the OPMI. Certain eye problems, e.g. astigmatism, cannot be corrected by the eyepiece. If the refractive error of the eye is corrected by prescription lenses, the dioptic correction of the eyepiece should be set to 0. The dentist's eyes must be at a certain distance to the eyepieces so that they are in the exit pupils of the eyepieces and can see the entire field of view. Eyecups or distancing rings should be extended when using the OPMI without glasses. Dentists who wear glasses should retract the distancing rings as the glasses already function as a spacer. Figure 1.9 (next page) shows the individual steps for personal configuration of the OPMI.

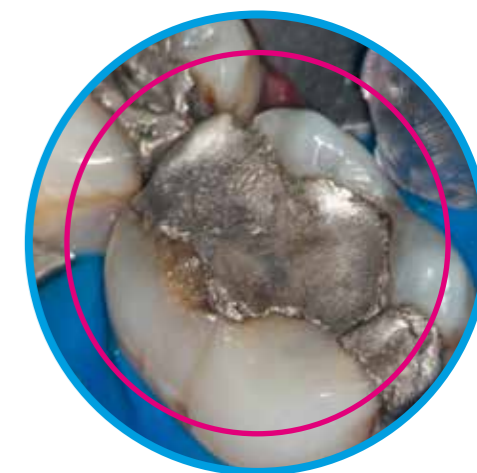

Figure 1.8: The blue circle corresponds to the field of view of a 10x eyepiece and the red circle corresponds to the field of view of a 12.5x eyepiece. An eyepiece with 10x magnification provides about 20 percent more field of view than an eyepiece with a factor of 12.5x. This means that, conversely, the maximum final magnification is higher when using a 12.5x eyepiece

# Set-up of OPMI

## Quick Guide

### 1

#### Initial setting

Set the OPMI to the lowest magnification. Select the magnification factor 0.4 on the magnification changer (Figure 1.9). Focus: To focus the image move the OPMI up and down to achieve the correct working distance in accordance with the focal length of the objective lens (e.g. 250 mm).

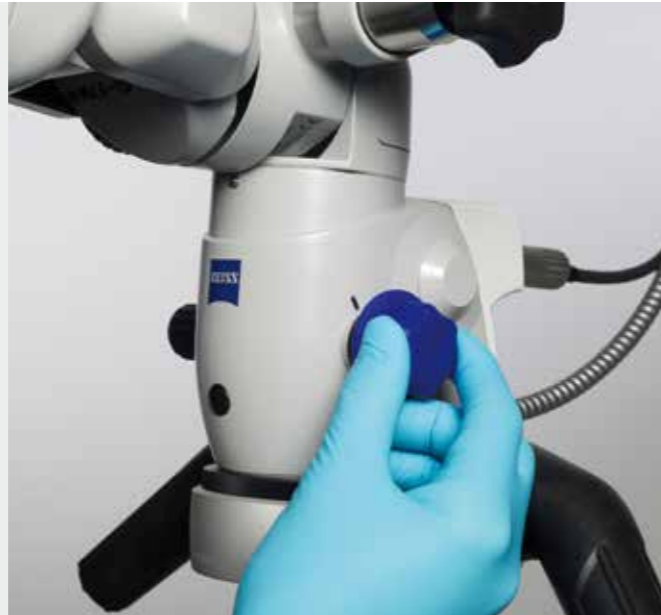

Figure 1.9 magnification changer

### 2

#### Adjusting the interpupillary distance

Start from the widest position of the eyepieces and use knob of the tube head to adjust the distance of the eyepieces to your interpupillary distance (Figure 1.11) so that the two eyepiece images merge into one (Fig 1.10a - c)

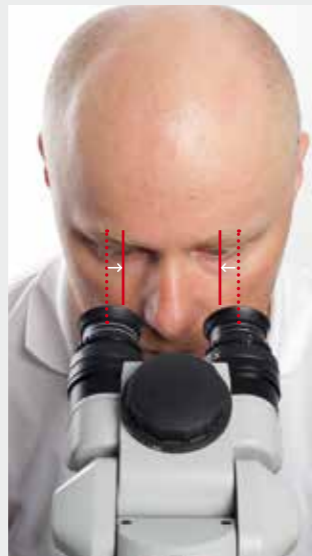


Figure 1.10a Widest position

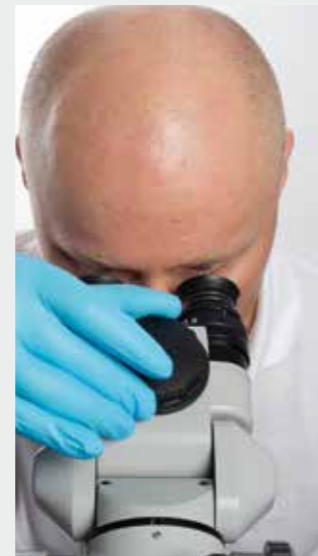

Figure 1.10b Adjusting the distance

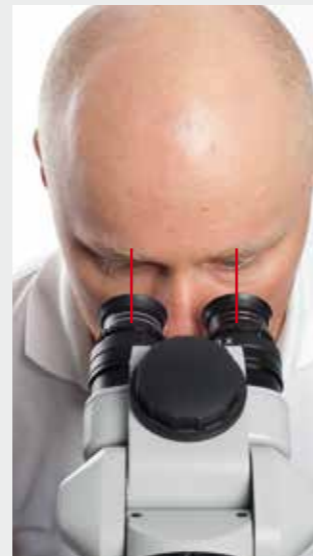

Figure 1.10c Correct distance



Figure 1.11 Interpupillary distance in mm at  $\infty$

### 3

#### Adjusting the eyepieces

##### Eyecups

Adjust the eyecups in such a way that the entire field of view can be seen.

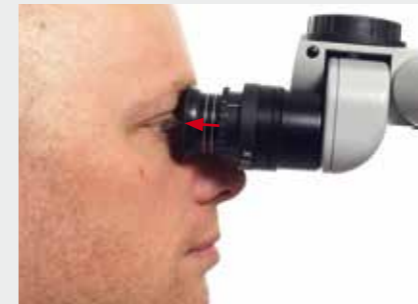

Figure 1.12a Viewing without eyeglasses: screw out the eyecups until 2-3 silver rings are visible

##### Dioptre correction

Set the diopter setting ring on the OPMI to 0 dioptres.



Figure 1.12b Viewing without eyeglasses: set dioptre correction according to your correction value of the eye (e.g. -1)

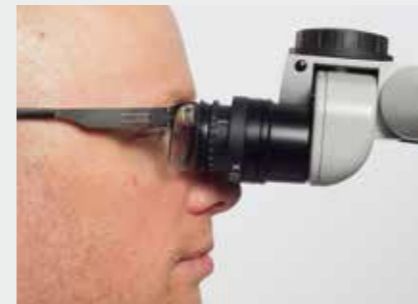

Figure 1.12c Viewing with eyeglasses: screw in the eyecups all the way (no silver ring visible)



Figure 1.12d Viewing with eyeglasses: set dioptre setting ring on the OPMI to 0 dioptres

### 4

#### Adjusting magnification and focus

Select the maximum magnification and focus: focus on the object by lifting and lowering the OPMI and/or using the focusing dial (Fig 1.13). Select the magnification required. The focal plane is retained.



Figure 1.13 Adjusting the focus dial



Figure 1.14: The stereo co-observation tube is coupled with the OPMI via a beam splitter and can be put in the required position using pivot joints.

### Co-observation

Co-observation means that a second person (e.g. assistant) or even more persons (e.g. students, colleagues) can follow the treatment under the OPMI. Usually a camera is used to show the live image on a monitor. The advantage of a camera-based co-observation is that one or more persons can follow the treatment without directly looking through the OPMI. At the same time it is possible to record videos or to make still images for documentation.

An integrated camera is built into the OPMI body and does not add much weight to the system, which makes the handling of the OPMI easy. On the other hand, the video image on the screen is two-dimensional and has no depth. To achieve 3D perception for the co-observer it is possible to mount a co-observation tube on the OPMI. A co-observation tube enables a second person to look into the OPMI. Thus, the

operator can look down the binocular tube and the co-observer, e.g. the assistant, or assistant surgeon can look down the co-observation tube. The co-observation tube can be connected via an optical splitter between the OPMI body and the binocular tube. The optical splitter splits the image information from one of the observation optical paths and redirects it into the co-observation tube. The co-observer therefore has the same view of the treatment area as the dentist.

#### There are two kinds of co-observation tubes:

1. The stereoscopic co-observation tube. With this tube, the co-observer looks into a binocular tube with both eyes and sees a stereo image (Figure 1.14), although the stereoscopic effect is slightly reduced for the co-observer compared to that of the main observer because

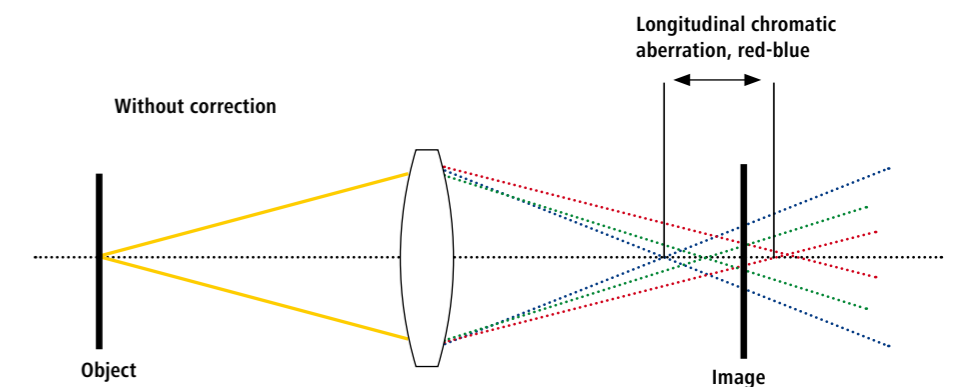
the stereo base is smaller. The stereoscopic co-observer tube can be tilted and turned, thus providing convenient viewing. An image rotation prism places the image in the desired position. The stereo co-observation tube adds weight to the OPMI. Before mounting a co-observation tube to the OPMI it is important to check whether the suspension system of the OPMI can carry the additional weight.

2. The monocular co-observation tube. This offers the co-observer a view with only one eye. This can be used, for example, for workshop OPMI's if the teacher would like to co-observe the student's work under the OPMI.

## Optics

**In order to see fine detail on the treatment field, good image quality is essential. But what exactly is good image quality?**

The most important criteria are discussed here in more detail.



### Correction of chromatic aberration

If you hold a prism in the sunlight, the white light is split up into its separate colors - we see the colors of the spectrum. This happens because the shorter-wave blue light is refracted more strongly than the longer-wave red light. A similar phenomenon occurs when light passes through a lens. The focal distance of the blue light is shorter than the focal distance of the red light. The focal point of the blue light is therefore closer to the lens than that of the red light. As a consequence, the back focal point becomes blurred, which leads to poor contrast, chromatic aberration and low resolution (Figure 1.15). Correction of these chromatic effects is essential for brilliant image quality. OPMI's that contain apochromatically corrected lens systems stand out because of their increased resolution and high contrast, even at the periphery of the viewing area. No chromatic aberrations can be seen.

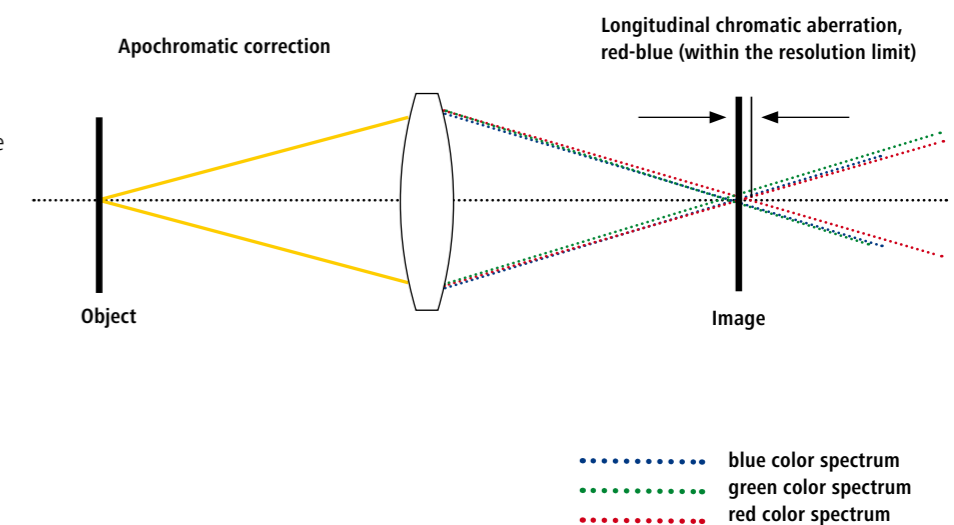


Figure 1.15: When white light passes through a lens, it is broken into its spectral components. Blue light is refracted more than red and thus focuses closer to the lens. Therefore, there is no single focal point for all colors. After apochromatic correction, the different colour components of light are nearly focused at a single point. The result is brilliant image quality without visible chromatic aberration.

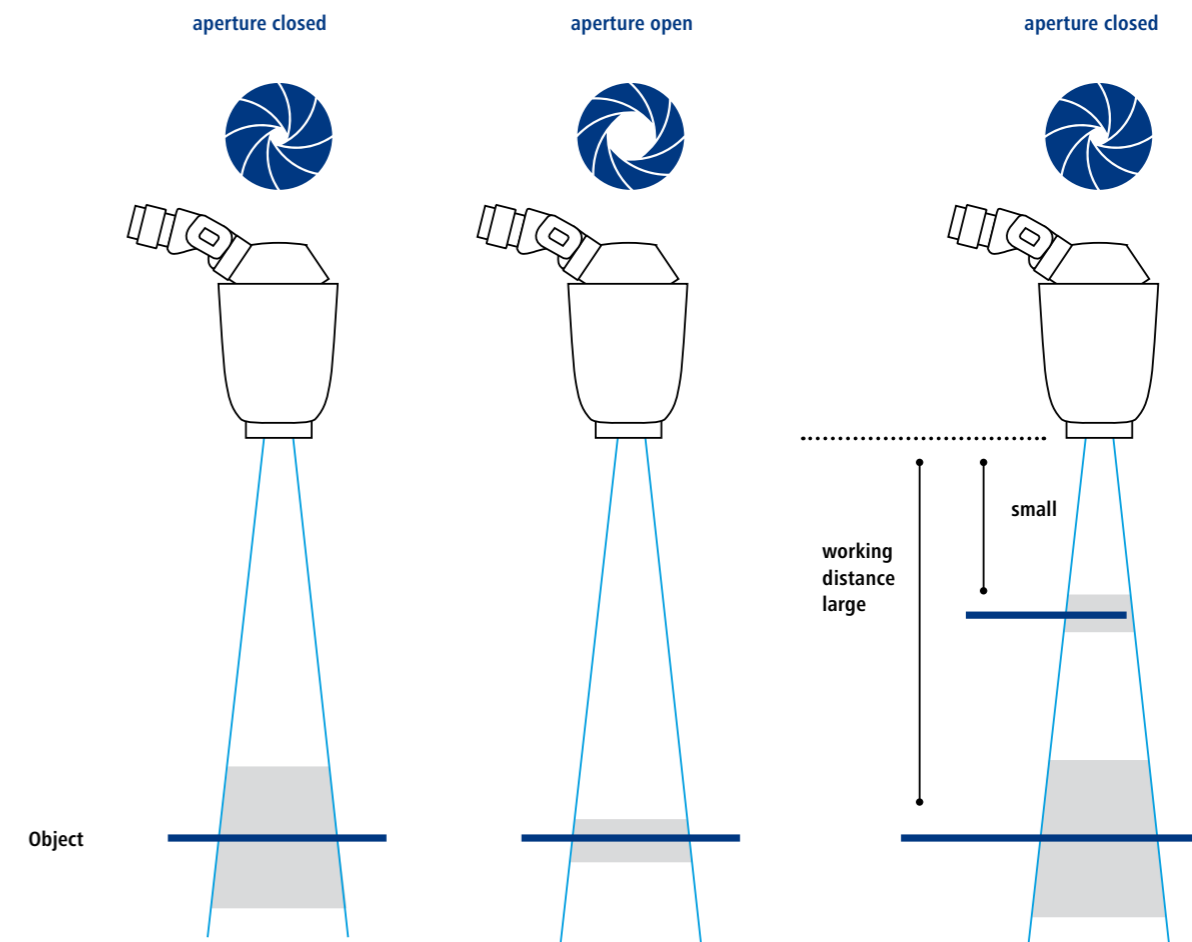


Figure 1.16: The depth of field is the area above and below the focal plane, which appears in focus to the viewer. The smaller the selected magnification and the larger the working distance, the greater the depth of field becomes. If a double-iris aperture is included in the light path, you can close this to increase the depth of field

### High transmission of light

When light crosses the optical elements of the OPMI, it can cause reflections on the surfaces of the lenses. These reduce the clarity of the image and can lead to a loss of light. Coating all lenses and prisms reduces reflections within the OPMI. Light transmission and image contrast are then higher.

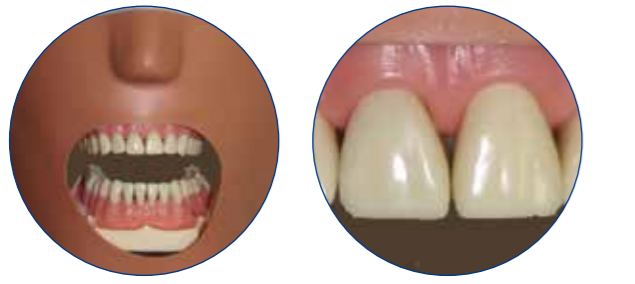### Depth of field

When focusing an object in the OPMI, we focus on a particular focal plane. We can also see an area above and below the focused area with equal clarity. These areas are referred to as the depth of field. Needless to say, it is most comfortable to work with as high a depth of field as possible as this allows better spatial orientation. However, depth of field is an optical property that is influenced by several parameters.

- 1. Magnification:** the lower the magnification, the greater the depth of field.
- 2. Working distance:** the greater the working distance, the greater the depth of field.
- 3. Aperture of the objective lens:** the aperture determines at what angle light beams are still captured by the lens. The lower the angular aperture of the lens, the greater the depth of field.
- 4. Adaptability of the observer:** this is where biology comes into play. A younger dentist's eyes generally adapt better, and can therefore make out depth of field over a longer area. With increasing age, the adaptability of the eyes decreases, as does the depth of field.

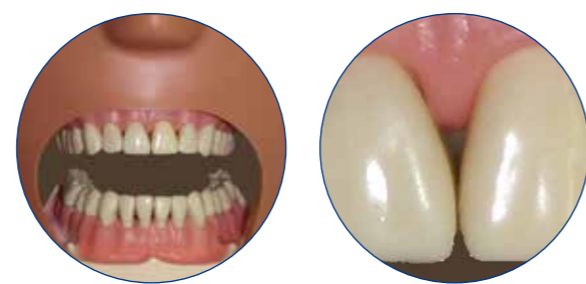From the first two of the three parameters stated, depth of field can indeed be calculated. The biological component does however vary on an individual basis, which is why OPMI manufacturers generally do not state the depth of field. However, depth of field can be increased by inserting a double iris aperture in the optical path. If it is closed, the depth of field increases, especially in the medium magnification range (Figure 1.16). The disadvantage is that light is lost in this process and therefore the light intensity has to be increased. Closing the aperture reduces the resolution, meaning that the resolution of very small structures is reduced. If the double iris aperture is opened, the image becomes brighter and the resolution of fine details increases. The use of a

double iris aperture therefore depends on the desired effect with a particular application. Usually the double iris is used for high-end photography



**Working distance 415 mm, 12.5x eyepiece**

Zoom factor 0.4	Zoom factor 2.4
End magnification 1.9x	End magnification 10.9x
Field of view 116 mm (diameter)	Field of view 20 mm (diameter)



**Working distance 200 mm, 12.5x eyepiece**

Zoom factor 0.4	Zoom factor 2.4
End magnification 3x	End magnification 18.2x
Field of view 73 mm (diameter)	Field of view 12 mm (diameter)

Figure 1.17: The S7 / OPMI PROergo manufactured by ZEISS reaches up to a 116 mm field of view at the lowest magnification, a 12.5x eyepiece, a tube focal distance of 170 mm and a working distance of 415 mm. The diameter of the field of view and magnification depend on the working distance. If the working distance is shortened (e.g. to 200 mm), then the field of view decreases and the magnification increases

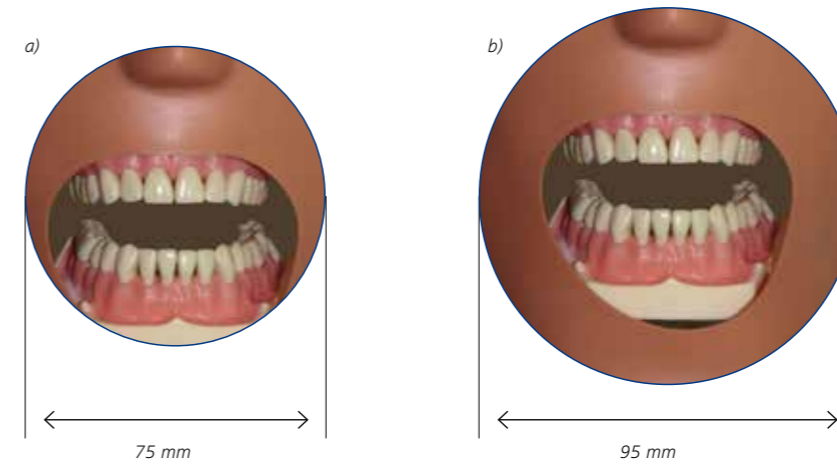


Figure 1.18a OPMI pico with fixed focal length lens with 250 mm focal length covers a field of view of 75 mm.

Figure 1.18b OPMI pico with Varioskop 100 covers a field of view of 95 mm at same magnification. (a and b with 10x eyepiece, magnification factor 0.4, binocular tube f=170 mm)

It can be calculated easily with the following formula:

$$\text{End magnification} = \frac{\text{Tube focal distance}}{\text{Lens focal distance}} \times \text{Magnification changer factor} \times \text{Eyepiece factor}$$

**Field of view**

The field of view is the area of the treatment field that can be seen through the OPMI. For the purposes of orientation, it is most convenient to work with as large a field of view as possible.

**The following applies:**

- 1. Magnification:** the lower the magnification, the larger the field of view.
- 2. Working distance:** the greater the working distance, the larger the field of view.
- 3. Lens system:** the size of the fields of view depends on the lens design.

**How to calculate end magnification**

The magnification with which we can see a structure in the eyepiece is the end magnification. It is the end result of the various optical components of an OPMI.

The formula for the calculation of the end magnification applies to OPMI with fixed focal distance. This formula cannot be used for OPMI with a varioscope because the working distance does not equate to the focal distance. The best way to find out the end magnification in this case is to ask the manufacturer.

Example 1:	Example 2:
Focal distance tube: <b>f = 170mm</b>	Focal distance tube: <b>f = 170mm</b>
Focal distance of lens: <b>f = 250 mm</b>	Focal distance of lens: <b>f = 250 mm</b>
Magnification changer factor: <b>0.4x</b>	Magnification changer factor: <b>2.5 x</b>
Eyepiece factor: <b>12.5x</b>	Eyepiece factor: <b>12.5x</b>
<b><math>\frac{170}{250} \times 0.4 \times 12.5 = 3.4</math></b>	<b><math>\frac{170}{250} \times 2.5 \times 12.5 = 21.25</math></b>
<b>3.4x is the lowest magnification in this example.</b>	<b>21.25x is the highest magnification at a magnification factor of 2.5, with the other parameters identical to those in example 1.</b>

## Ergonomics and workflow

**Surgical microscope provides proper ergonomics for the eyes and for the back. If a dentist works on a patient without magnification, his or her eyes accommodate to a distance of about 30 cm and tire easily. However, if he or she looks through an OPMI, the eyes accommodate almost to infinity, which serves to prevent fatigue.**

An OPMI supports the dentist's ergonomic sitting position. Normally, the dentist leans over the mouth of the patient, which can lead to back problems. If the dentist works with an OPMI, then he or she sits upright and looks straight ahead into the eyepieces of the OPMI. Inclinable tubes allow the viewing angle to be adjusted in line with the working height and seating position of the dentist.

### Varioscope

A varioscope contributes significantly to ergonomics, as it allows you to change the working distance within a range of e.g. 200 – 300 mm or even 200 to 415 mm without requiring the dentist to change his or her working position. Motorized zoom and focus at the push of a button on the handgrip of the OPMI accelerate the workflow.



Figure 1.19a: The Varioskop 100 of S100 / OPMI pico allows focussing in the range from 200 - 300 mm by turning the focus knob manually.



Figure 1.19b: The motorized varioscope of S7 / OPMI PROergo provides a focusing range of 200 - 415 mm and can be controlled by autofocus or by the push of button.

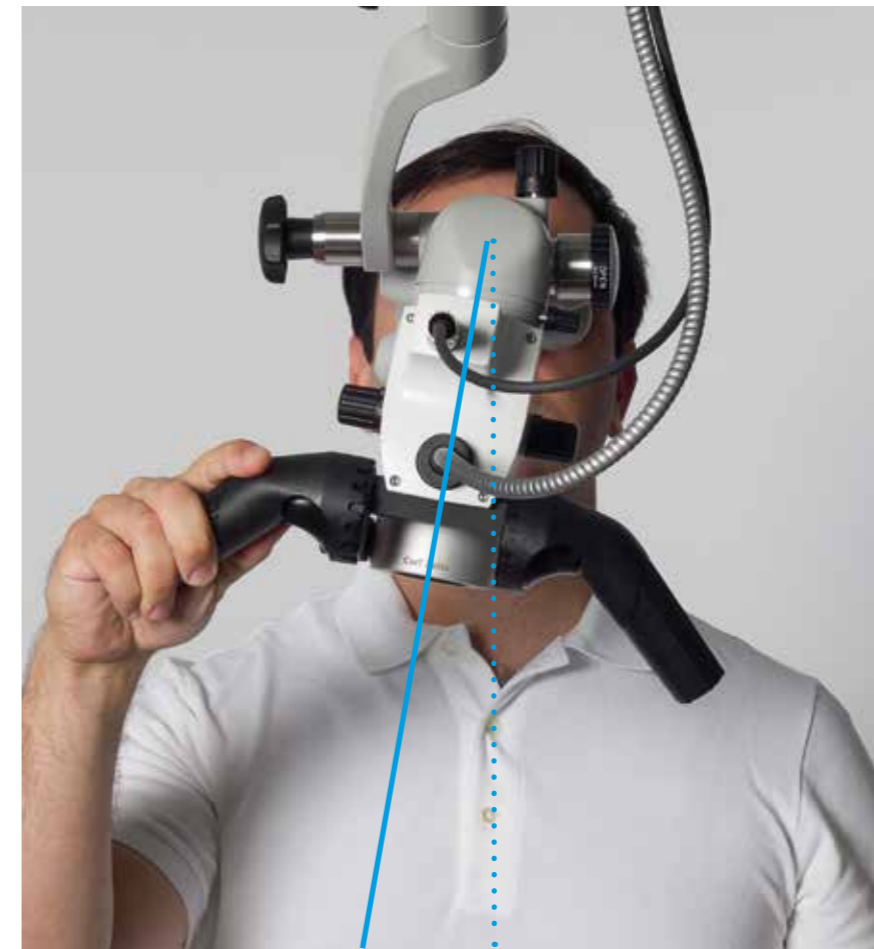

Figure 1.20: The MORA interface allows the OPMI to be tilted to the left or right. The eyepieces retain their horizontal position, so that the dentist has a straight, ergonomic seating position when looking into the OPMI.

### Looking around the corner – MORA interface and angled optics

If the OPMI is equipped with a MORA interface, the microscope body can be moved to the left or the right by hand without changing the position of the binocular tube head (Figure 1.20). The dentist's head and upper body remain upright and relaxed. The OPMI looks "around the corner". As an alternative to the MORA interface, angled optics can be used, which also serve to guide the image to the viewer's eyes. An angled optic is usually combined with a rotatable dovetail mount. Therefore, the dentist can swing the OPMI to the side and bring the tube into a nearly straight position with a second hand motion. In contrast to the MORA interface, this way of working requires two hand movements instead of one, thus providing a less efficient workflow. Another advantage of the MORA interface over an angled optic consists of the better weight distribution and

balance of the OPMI. This is especially important when it comes to external camera attachments. A MORA interface can be combined with a documentation output port, and the camera is thus directly attached to the MORA interface. Therefore, the camera attachment is not moved when the OPMI body is swung. Angled optics, on the other hand, require the entire OPMI to be moved, including the external camera. This is less ergonomic.



## Light

**Light is the eye's information medium. But the light situation is difficult in the patient's oral cavity. Surgery lamps are good for illuminating the area being treated, but a root canal or fracture can often be in shadowed areas.**

In an OPMI, the light is integrated coaxially via the lens (Figure 1.21), thus ensuring optimum illumination of cavities (e.g. root canals).

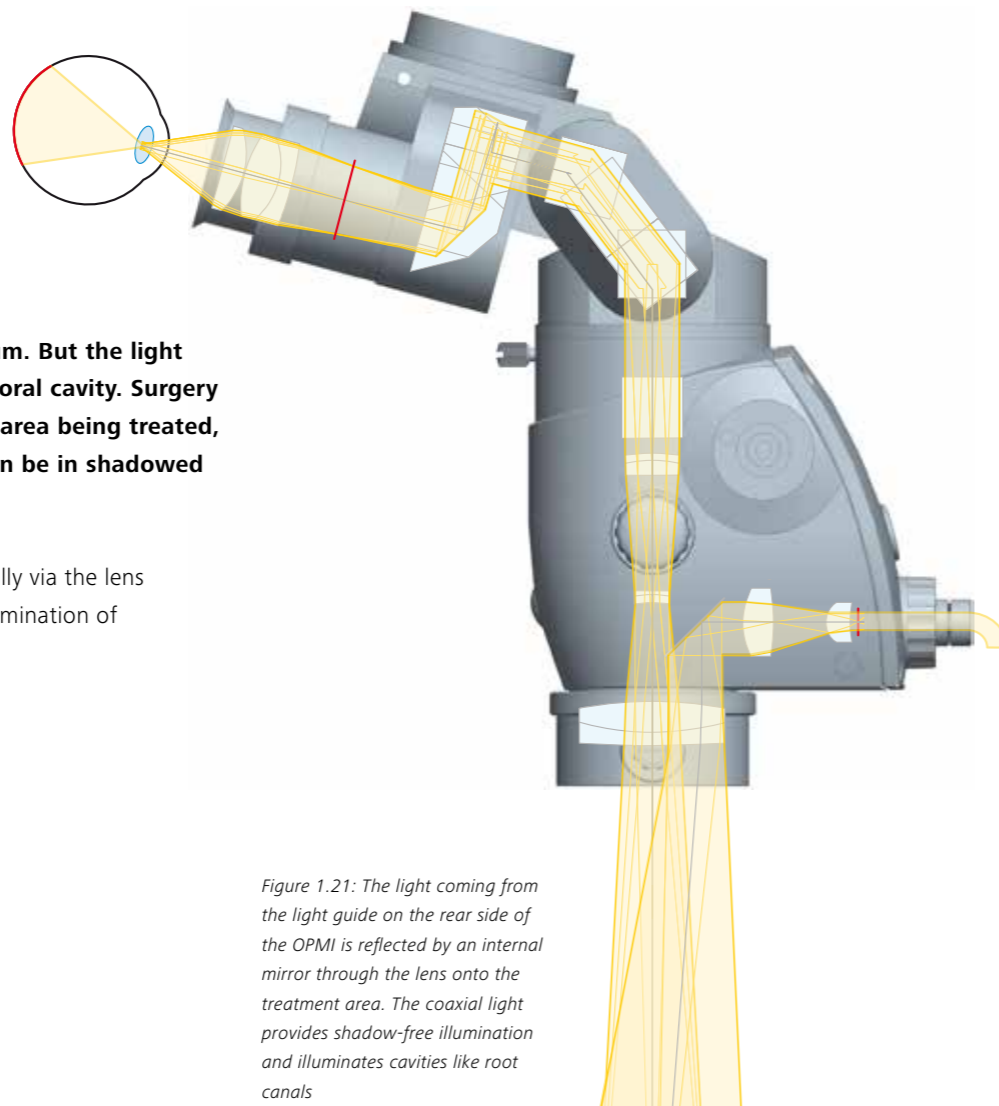


Figure 1.21: The light coming from the light guide on the rear side of the OPMI is reflected by an internal mirror through the lens onto the treatment area. The coaxial light provides shadow-free illumination and illuminates cavities like root canals

### Light sources

Xenon light has the advantage that its color temperature is similar to that of daylight. In other words, it is white light. White light gives the viewer the impression that the object looks natural and also provides true-color reproduction for documentation (Figure 1.21). The intensity of xenon lamps is 180 watts for example, and is therefore higher than that of conventional 100-watt halogen lights. Light intensity is particularly important when the dentist works with high magnification for example on root canals and for documentation. Especially those dentists working with SLR cameras depend on a high level of intensity to keep exposure times short and thus minimize the risk of camera movement affecting the image. The larger the working distance when using an OPMI the further light has to travel. If the working distance is doubled (e.g. if a working distance of 400 mm is selected instead of 200 mm),

then the intensity of light at the object is reduced to a quarter. With increasing magnification, brightness also decreases at the viewer's eye.

High-end OPMI's like OPMI PROergo automatically compensate for this by adapting the light intensity to the selected magnification (e.g. increasing it at higher levels of magnification). The life of a xenon lamp is defined by the manufacturer (e.g. 500 hours). The xenon lamp should be replaced so as not to pose the risk of flare or non-homogeneous illumination. An alternative to xenon light is LED light. LED light comes close to a color temperature similar to that of daylight. The intensity of an LED light source is lower compared to xenon. Currently LED lighting cannot yet replace traditional xenon lighting in terms of intensity. The big advantage of LED is its considerably longer lifetime. The service life of LED is

usually specified at 70000 hours (based on average use of the light intensity similar to maximum halogen light). Compared to LED and xenon, halogen has a lower color temperature and thus appears yellowish to the eye. In addition to this, the color temperature changes when the intensity is regulated. If the intensity is adjusted to a low setting using a potentiometer, then the spectrum of the halogen lamp becomes even more reddish. The life of a halogen lamp (e.g. 50 hours) is also much shorter than that of a xenon lamp or LED.

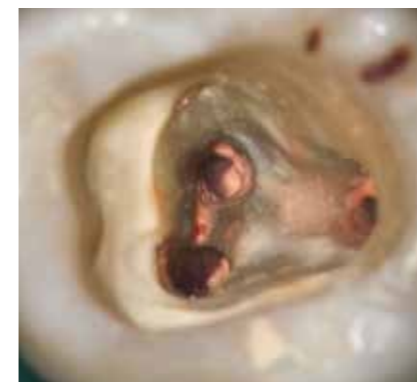

Figure 1.22a: Halogen

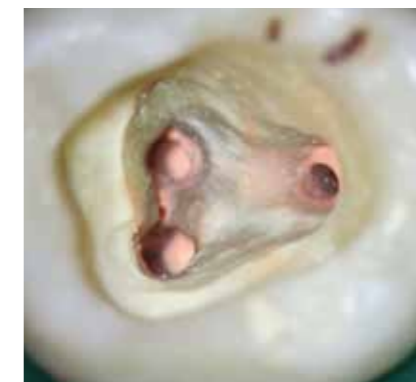

Figure 1.22b: LED

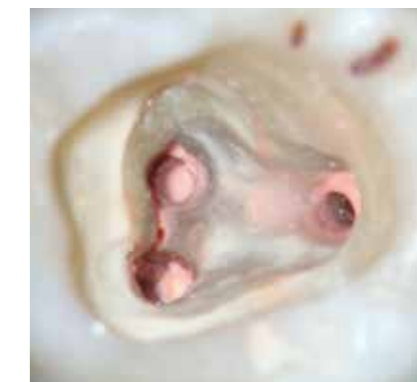

Figure 1.22c: Xenon

Figure 1.22a -1.22c: Compared to halogen light source, LED and xenon show light that resembles natural daylight. Xenon light features the highest intensity of all three light sources and enables short exposure times for sharp image documentation.

### Filters and pinhole diaphragm

In order to prevent premature curing of composite material, OPMI's are equipped with an orange filter. This can be placed in the light path when working with composite material. A green filter increases the contrast between the blood-filled and bloodless tissue, thus making details more visible. OPMI PROergo is equipped with a pinhole diaphragm in the lighting unit, which reduces the size of the illuminated area. This is useful at higher levels of magnification because the field of view is smaller. It is not necessary to illuminate a large area. Therefore, the diameter of the illuminated area can be reduced using the pinhole diaphragm.

This makes sense for two reasons:

1. The contrast of the microscopic image increases, because light is reflected off fewer structures (e.g. instruments) and thus less diffused light is produced.
2. The dentist increases light intensity at higher levels of magnification and therefore the field of view is brightly illuminated. The bright light and reflective instruments could impair the assistant's ability to see properly. The pinhole diaphragm can be closed to the extent that the field of view is illuminated, but annoying reflections are reduced.

## Free floating system

Balanced system and magnetic brakes



There are several ways to mount an OPMI:

### Movable floor stand

#### Wall mount

#### Ceiling mount

The choice of suspension system depends on the conditions at hand. A floor stand allows you to roll the OPMI from one treatment room to another. Ceiling and wall mounts are firmly anchored in place and require no floor space. When planning wall and ceiling mounts, it is essential to test the sturdiness of the wall and ceiling as well as possible sources of vibration (such as elevators, air conditioners, intensive heavy traffic on the road). Vibrations can be transferred to the stand and affect the image quality.

While working, it should be easy to position the OPMI above the patient and it should require no effort to move it out of the way after completing treatment. The stands are equipped with a balance system for easy and precise OPMI positioning. Depending on the weight of the OPMI, the balance system can be set, so that the OPMI seems almost weightless when moving. Magnetic brakes are advantageous because they fix the position of the OPMI (S7 / OPMI PROergo). If the OPMI has to be moved, then the brakes are released by pushing a button, the device is repositioned and the brakes are applied again by releasing the control buttons. If you change the weight of the OPMI system, for example, by adding or removing an external camera, then you have to balance the device again.

## Maintenance

Smudged optical surfaces dramatically reduce image quality. Image quality is impaired by even slight soiling of the optics or by a fingerprint. Spatter on the lens reduces contrast and sharpness. In order to protect optical surfaces of an OPMI from dirt, it is advisable to cover the microscope when not in use. During use, the lens can be covered with a splash guard. This prevents splashing of the lens with blood and aqueous solutions and can be easily cleaned. Clean the exterior surfaces of the optical components (eyepieces, objective lenses) only when necessary. Do not use any aggressive or abrasive agents. Remove dust from the optical surfaces using a squeeze blower or a clean, grease-free

brush. For cleaning of objective lenses and eyepieces, it is recommended to use optical cleaning solutions and a microfiber cloth.

The mechanical surfaces of the OPMI can be cleaned by wiping with a damp cloth. Clean off any residue using a mixture of 50 percent ethyl alcohol and 50 percent distilled water plus a dash of household dishwashing liquid.

# 2

## 2 Ergonomics

Author: **Dr. Bijan Vahedi**  
**Dr. Maciej Goczewski**  
**Oscar Freiherr von Stetten**

55 **Definitions  
of ergonomics**

56 **Overloads**

58 **Minimizing overloads**

60 Position of dentist

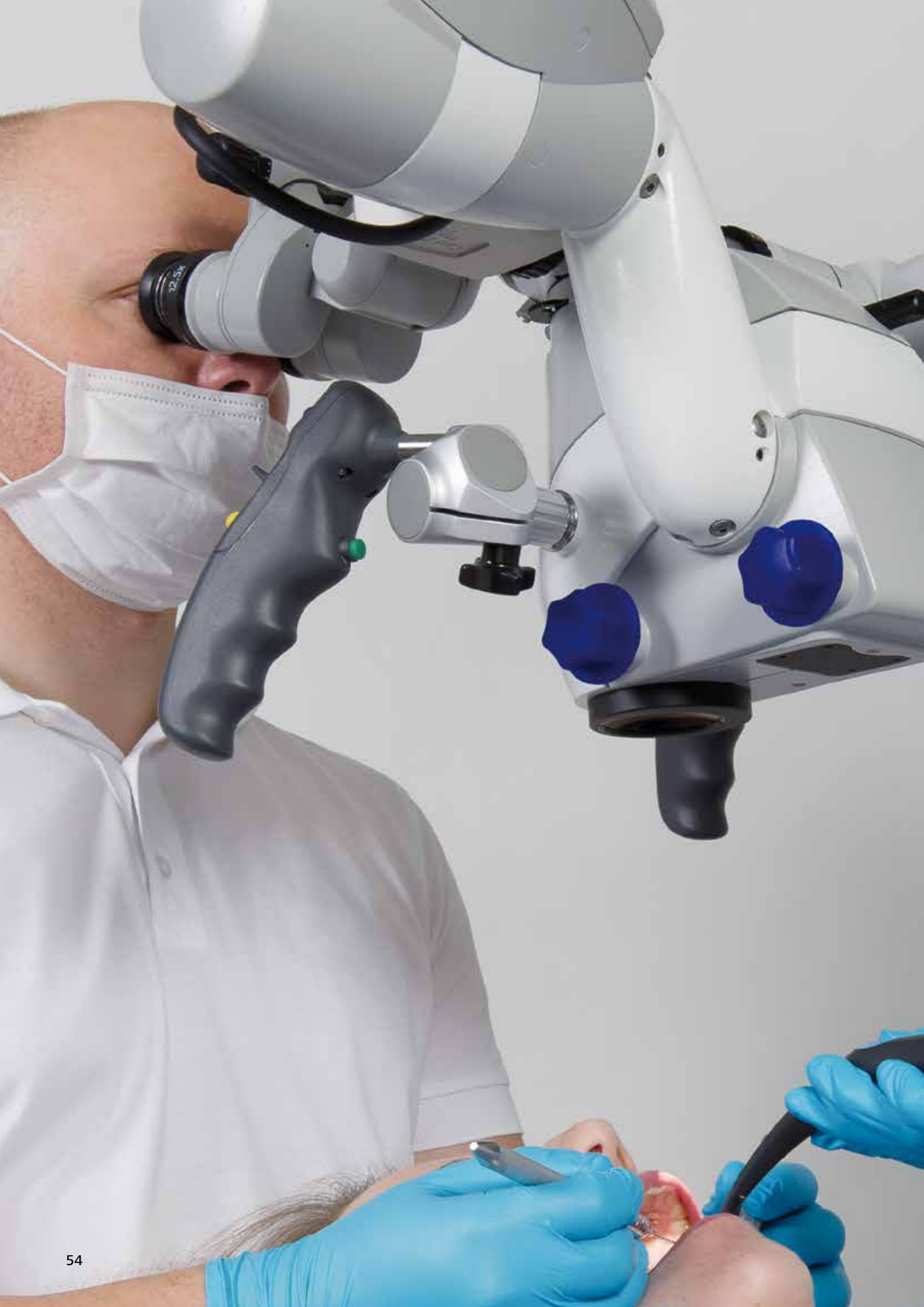61 Operator range of 9-12 o'clock  
working positions

62 Position of the patient

64 OPMI position

66 **Functional design**

67 **OPMI assistance**



## Definition of ergonomics

**Ergonomics is the scientific discipline concerned with the understanding of interactions between humans and other elements of a system. Ergonomics is also the science that applies theory, principle, data and methods to design in order to optimise human well-being and overall system performance.**

The word ergonomics comes from the Greek. It stems from two separate words – ergon, which means work, and nomos, which means correctness. In short, we can say that ergonomics means working correctly.

Figure 2.1

## Overload

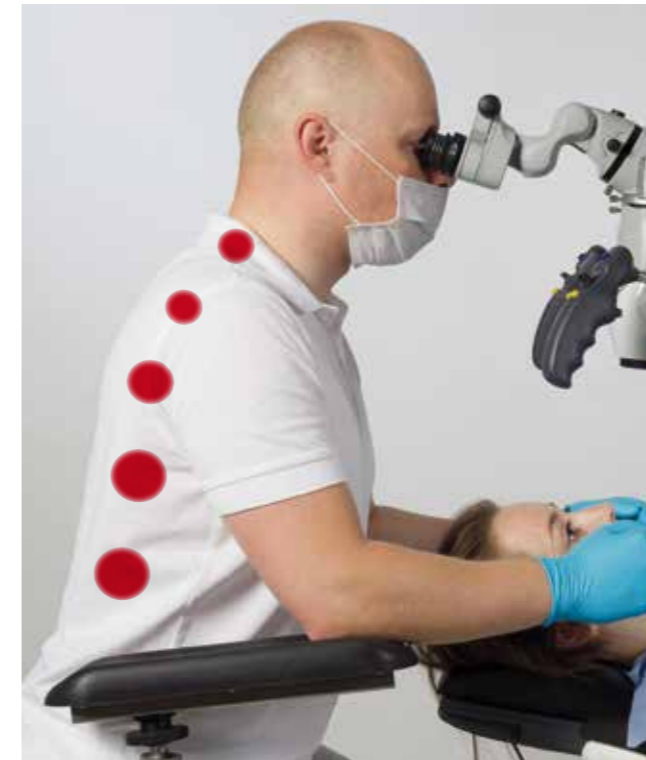
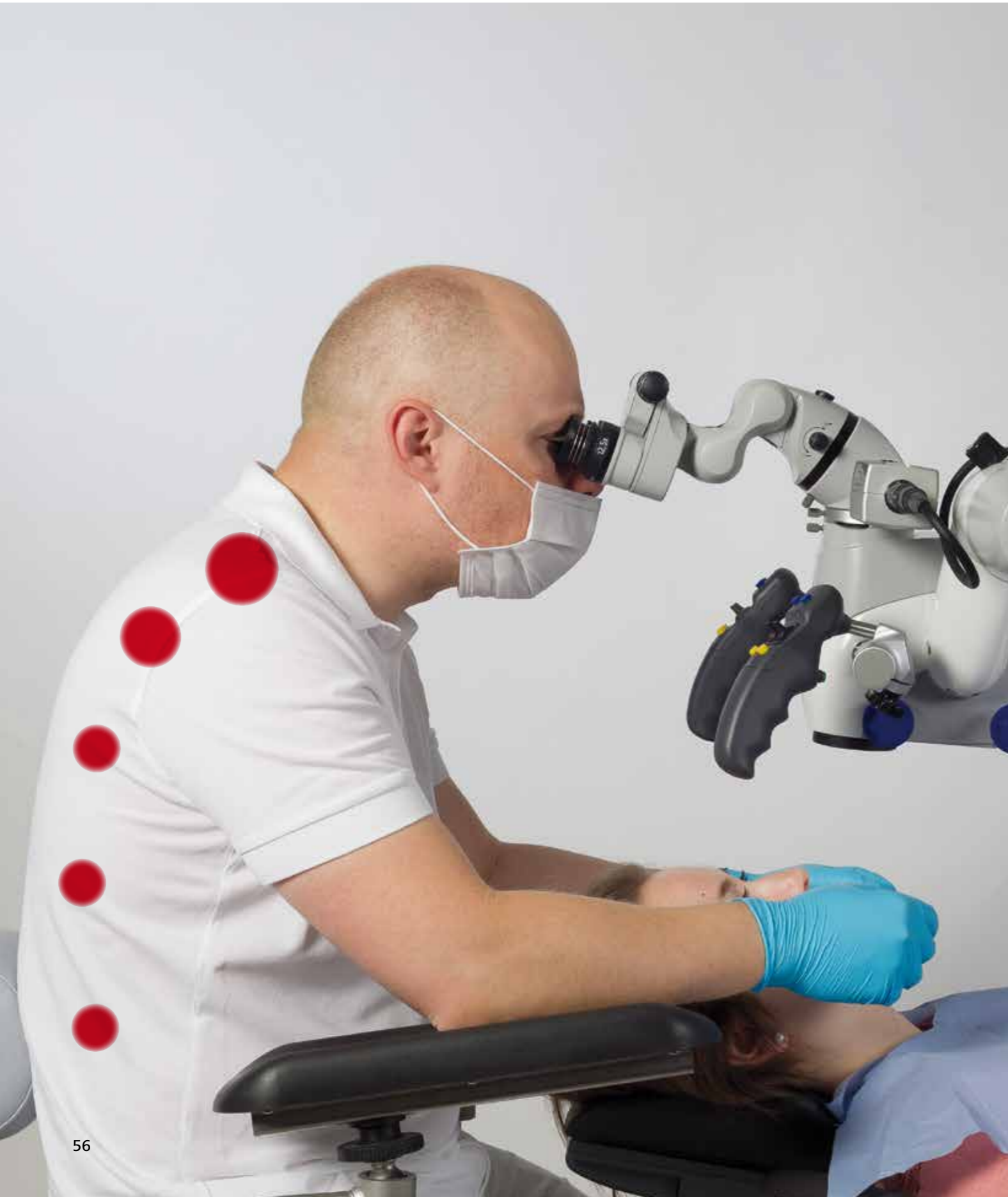
Figure 2.3

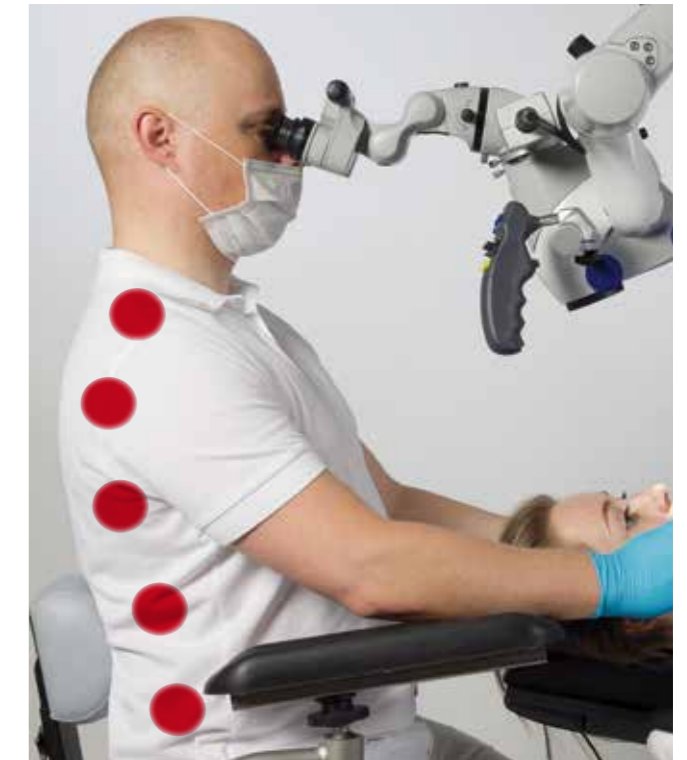

Figure 2.4

If the settings of the System Operator-OPMI are not set correct, an advert affect in terms of Back/Neck-Discomforts can appear.

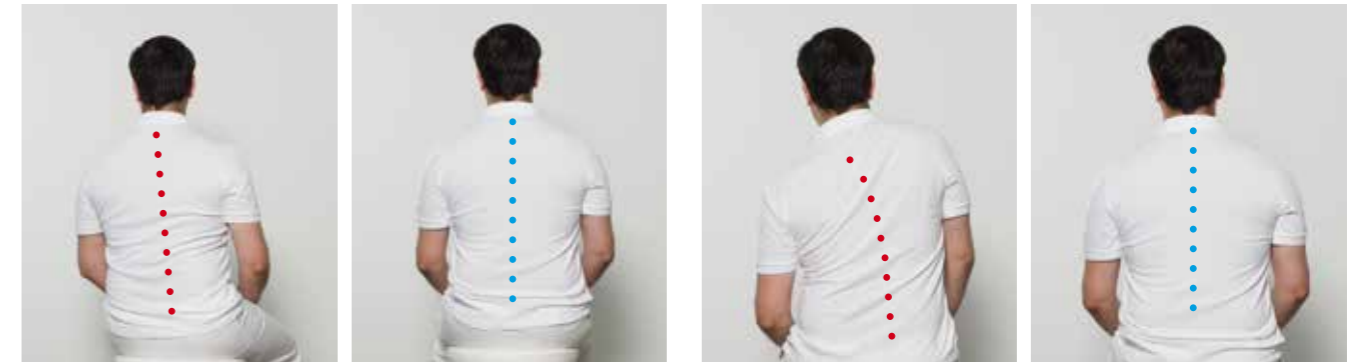
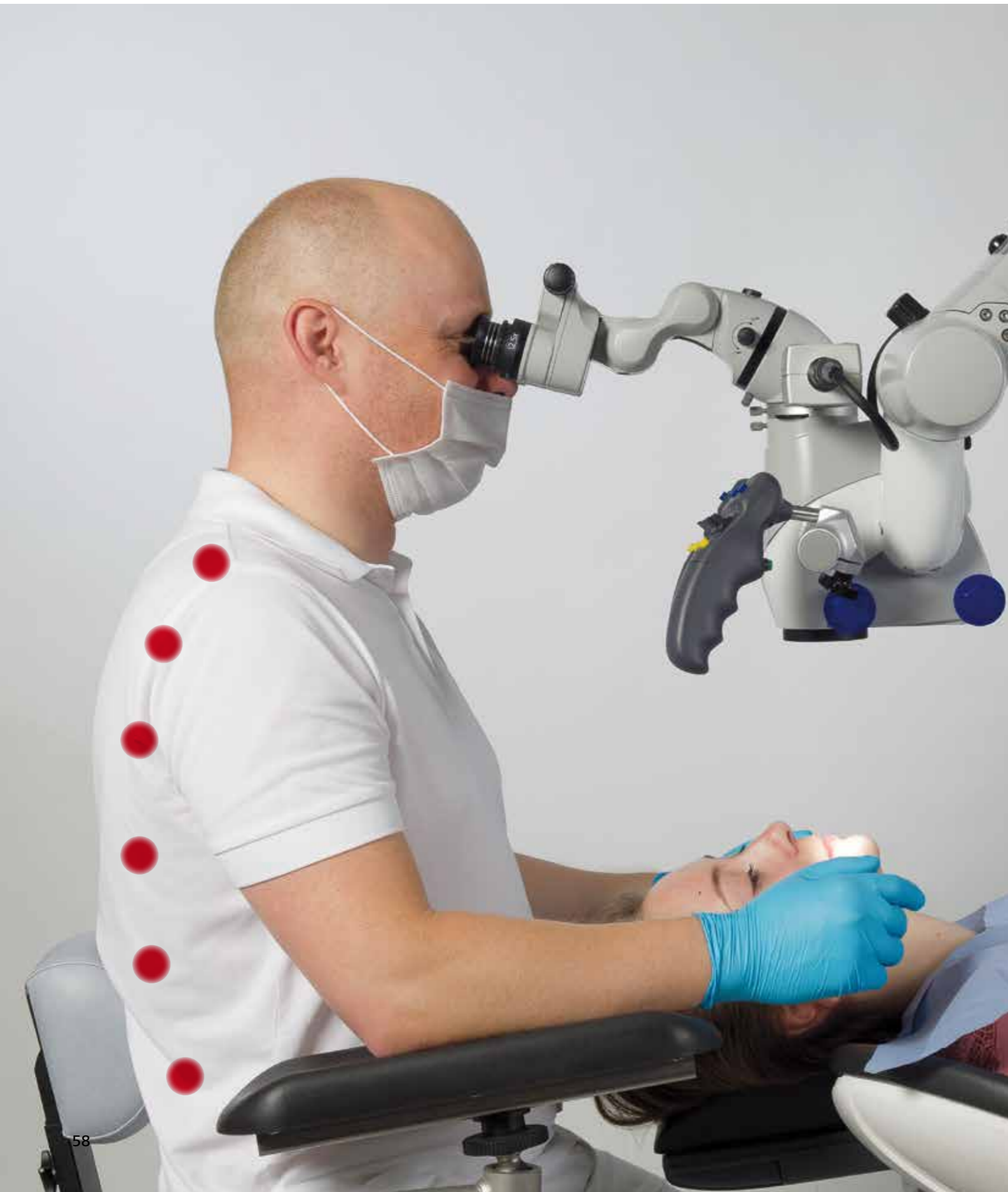This phenomenon stems mainly from muscle overload that cannot be eliminated entirely, but can be reduced to such an extent, that it no longer causes any discomfort.

In order to minimize overload, we have to work ergonomically, which means that we have to eliminate incorrect posture and alter our technique accordingly. There are two types of muscle overload - static and dynamic.

Static overload results from prolonged periods of work in one position, immobility and muscle cramp. Dynamic overload results from frequent repetition the same movements.

Figure 2.2

## Minimizing overload

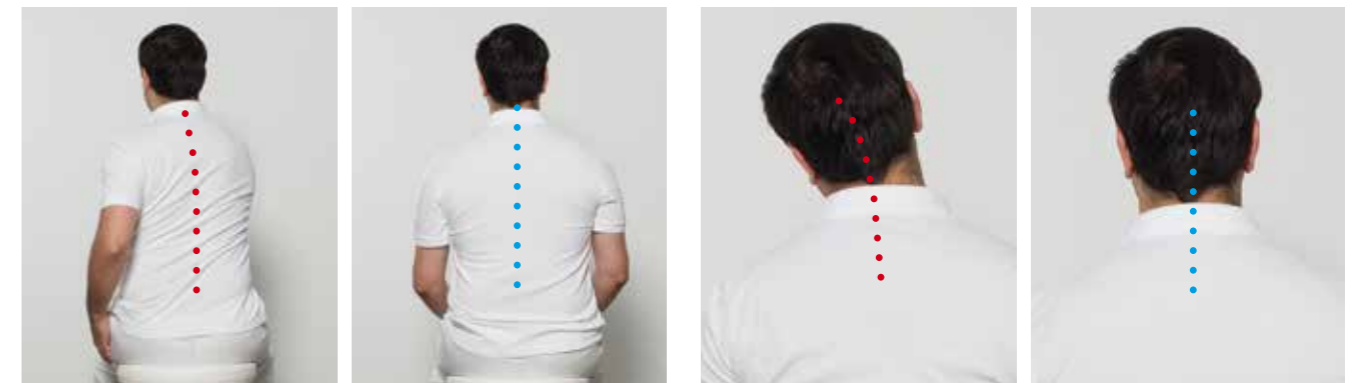


2.6 a Rotating hips

2.6 b

2.6 c Raised shoulders

2.6 d



2.6 e Rotating torso

2.6 f

2.6 g Tilted neck

2.6 h

The following basic positions should be used to reduce overload. First, the dentist should assume an adequate seated position. Second, the patient should be placed in the correct position. Third, the OPMI should be positioned comfortably.

Figure 2.5

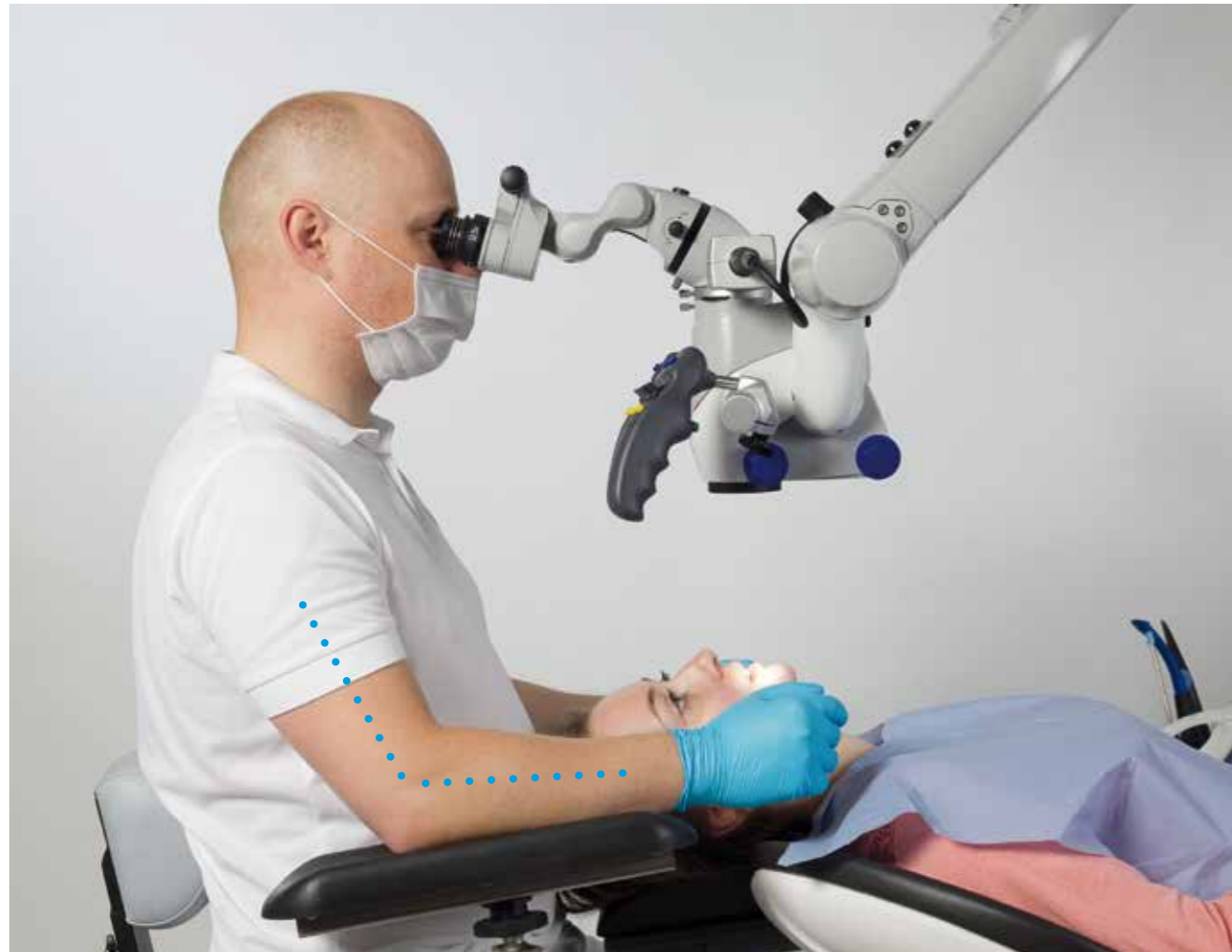

Figure 2.7

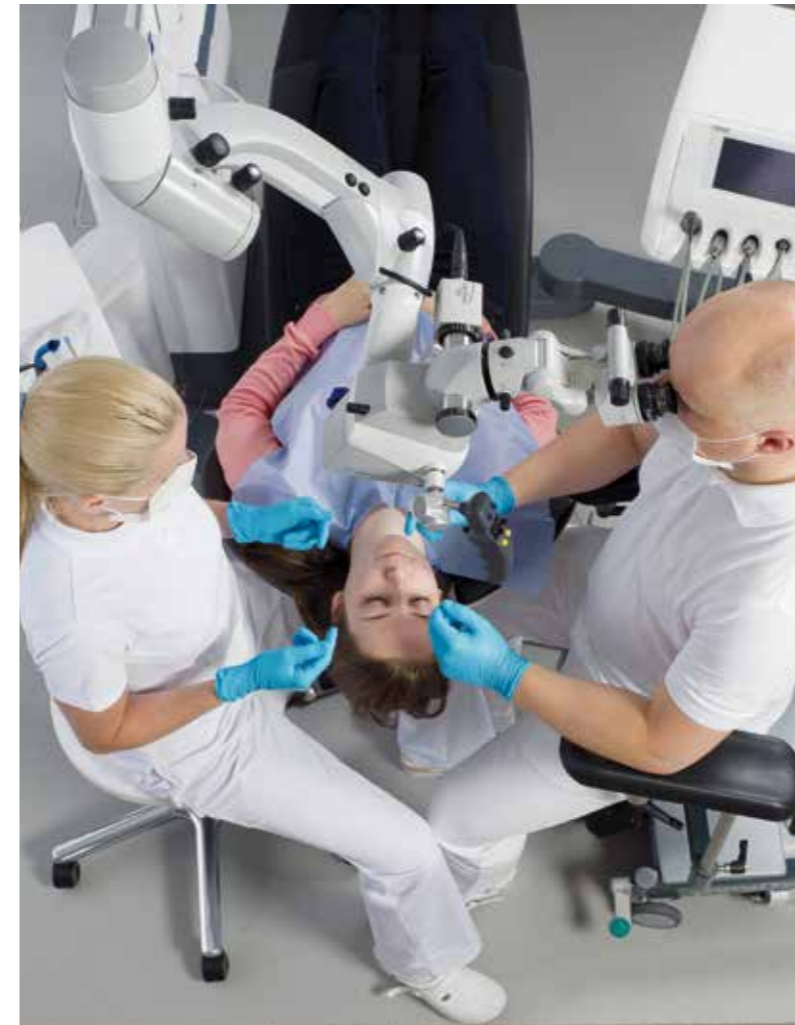

Figure 2.8a 9 o'clock position

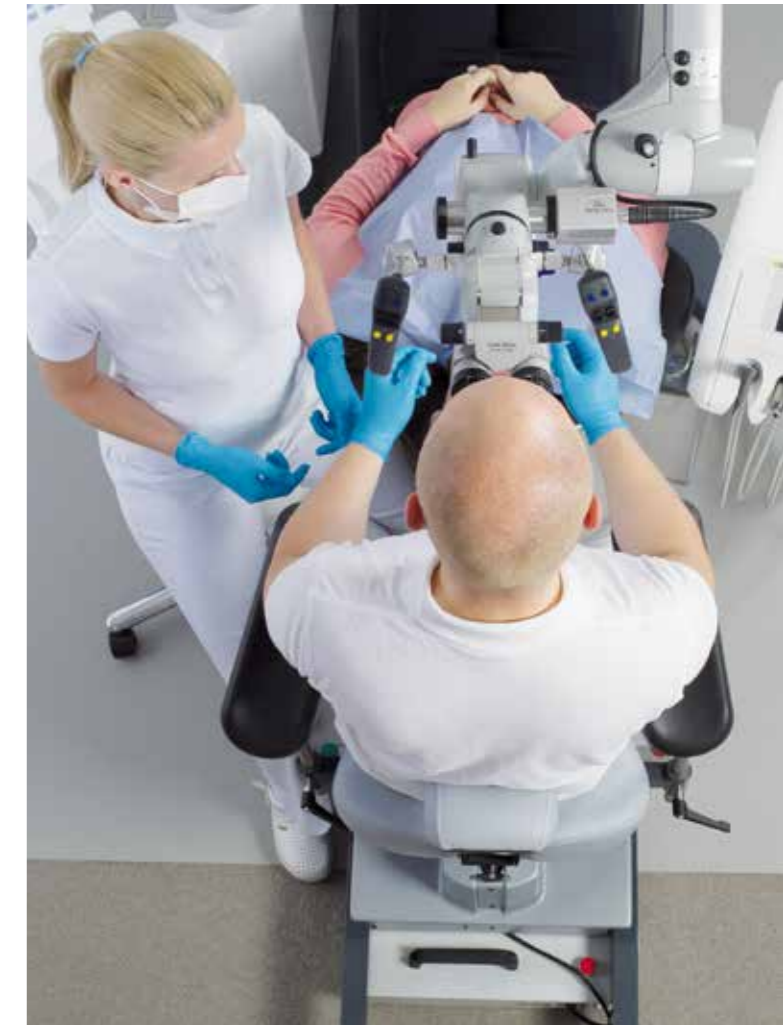

Figure 2.8b 12 o'clock position

### Position of dentist

Standard dental treatment often results in tension in the shoulders and neck. This is due to a statically overloaded seated position.

Avoiding overload for the treating dentist, particularly in the critical shoulder-neck area, requires an adequately supported seated position.

A chair featuring individually adjustable armrests and support for the lower back area is recommended as seen in figure 2.7.

When the dentist sits in this supported and comfortable position, this reduces static overload and enables more precise motor coordination during work.

### Operator range of 9-12 o'clock working positions

The position of the dentist in relation to the patient is ideal at a range from 9-12 o'clock. However, when using an OPMI, the position during most treatments moves from the 9 to the 12 o'clock position.

The 12 o'clock position behind the head of the supine patient is the ergonomical position for most dental procedures.

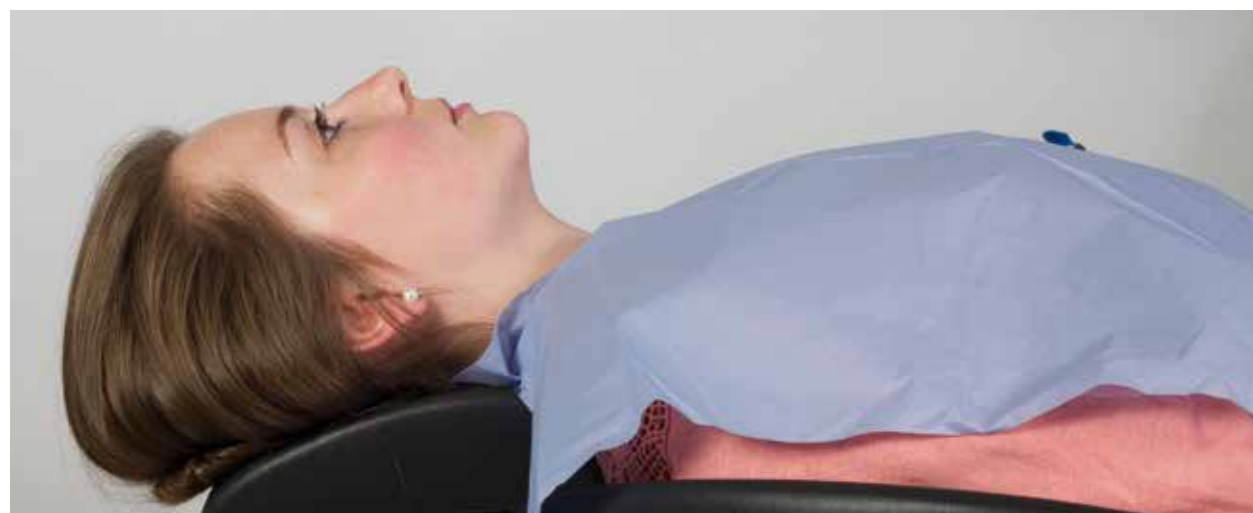

Figure 2.9

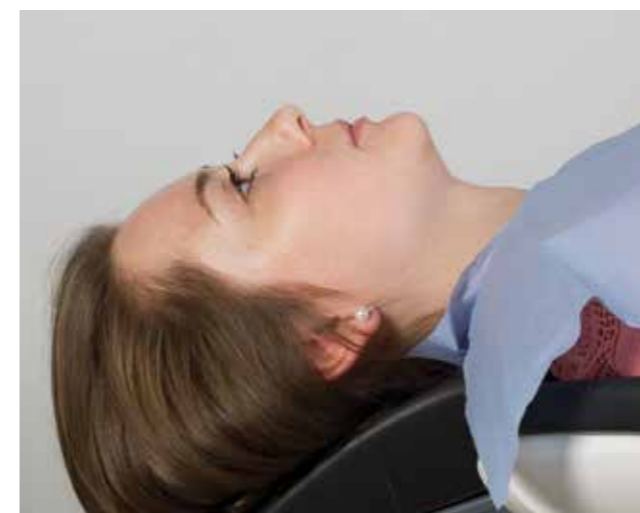

Figure 2.11a Head rest adjusted for indirect (mirror) view of mandible where the mandibular occlusal plane is vertical.

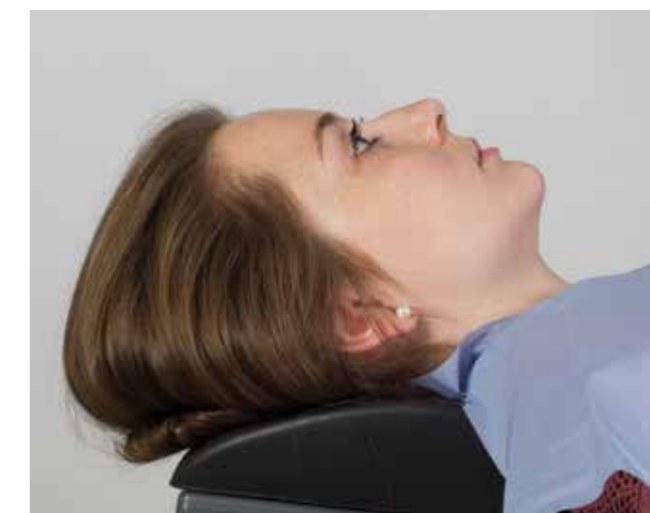

Figure 2.11b Head rest positioned for indirect view of the maxillary teeth with maxillary occlusal plane vertical.

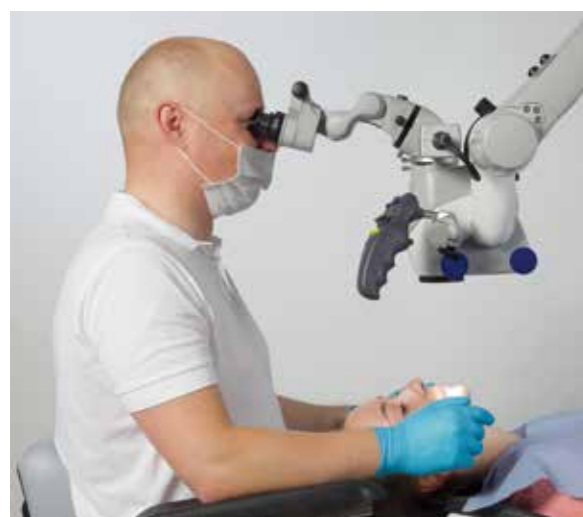

Figure 2.10a

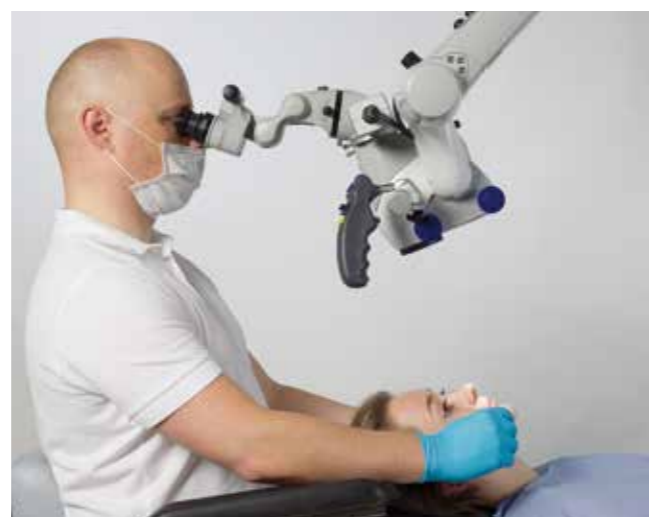

Figure 2.10b

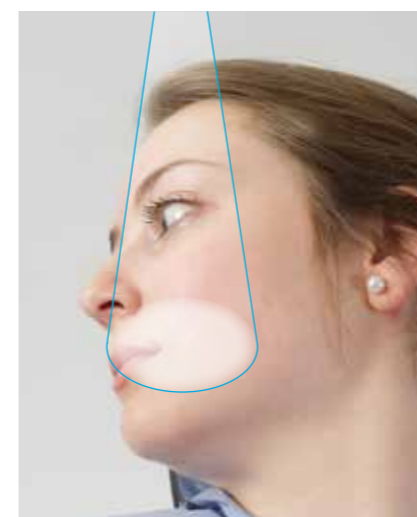


Figure 2.12a

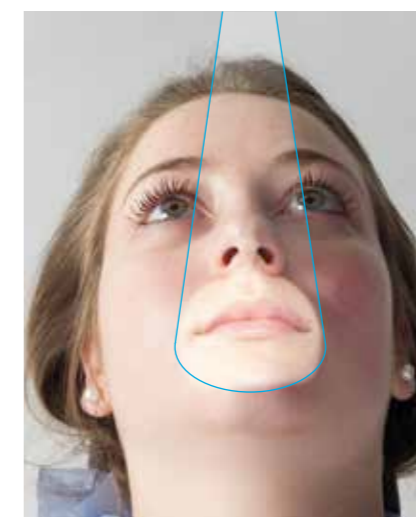


Figure 2.12b

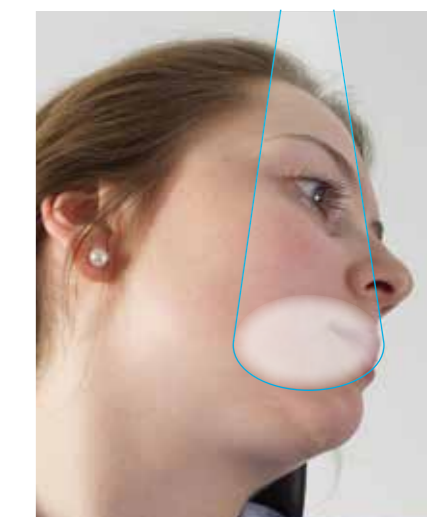


Figure 2.12c

**Position of the patient**

Once the dentist is seated correctly, the patient must be moved into a suitable treatment position.

For the patient, a comfortable, supine position should be found. This can be improved through special padding and head-and-neck supports.

Most treatments can be performed on the upper jaw when the patient is lying flat or slightly inclined.

For the lower jaw, most treatments can be performed when the patient is lying flat.

When indirect viewing via a mirror is required and visibility is poor, it is often necessary to lower the patient or their head backwards in order to generate a better viewing angle.

Endodontic treatments are usually performed by indirect vision using a mirror. Here, moving the patient's head 10°-20° degrees backwards is a good approach.

In order to obtain a good view of the treatment field, it is often unnecessary for the dentist to move into a different position or to move the OPMI. Often, it is enough to simply move the patient's head to the left or right. In many cases, this provides a direct view of the treatment field.



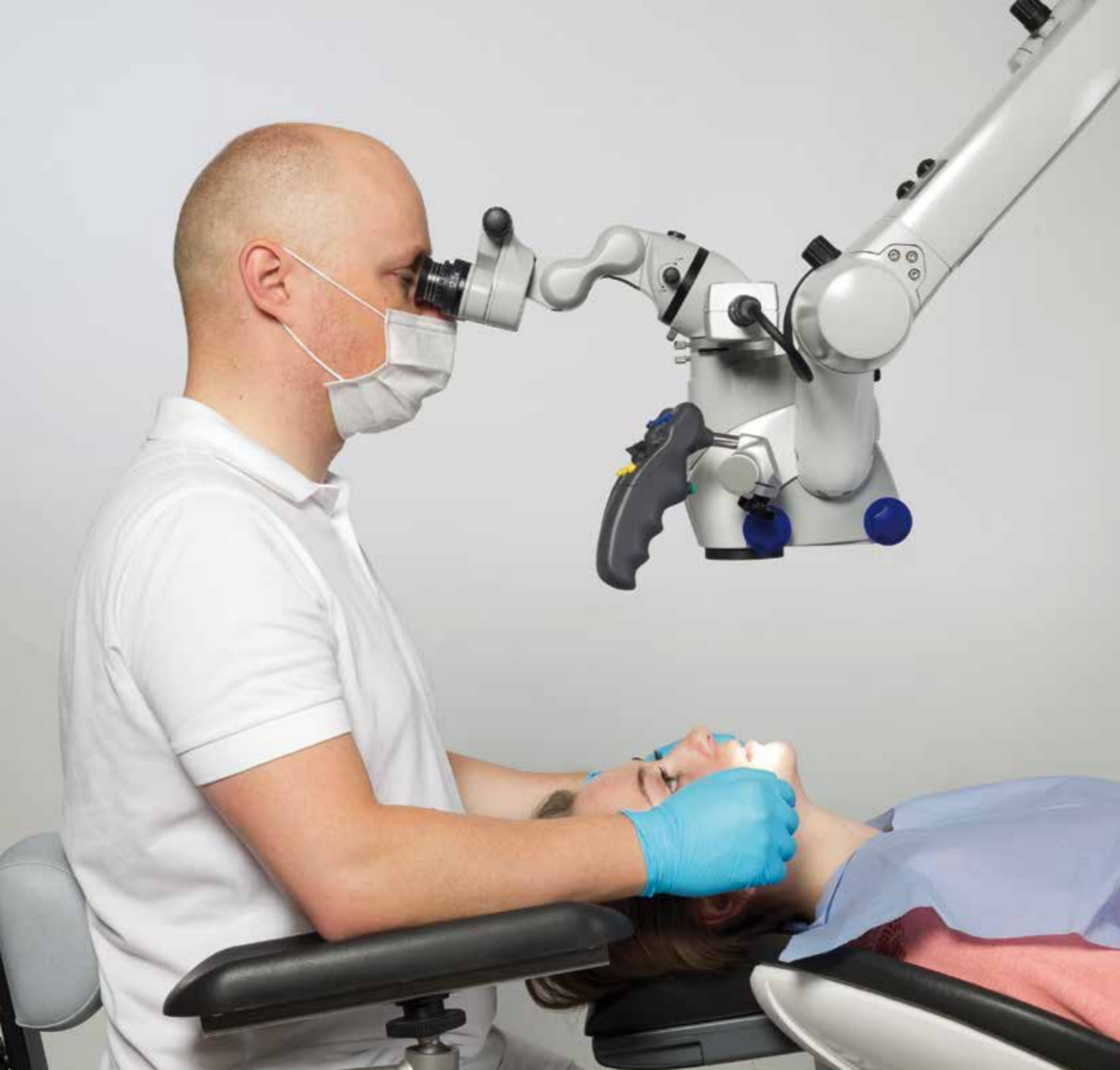

Figure 2.13

### OPMI position

After establishing the basic position of the dentist and the patient, the OPMI needs to be positioned.

To ensure that the dentist can work in an ergonomically correct position, the OPMI must be set to the right working distance or be equipped with a varioscope.

In general, the OPMI is positioned at an angle of 90° to the floor. Several treatment situations require the OPMI to be moved from this position.

Tilting it along the vertical axis changes the support position of the dentist, which results in less support for the pectoral girdle. Tilting the OPMI along the lateral axis leads to a lateral tilt of the head and thus to static overload of the cervical spine.

If the OPMI must be moved, it is possible to correctly configure the eyepieces horizontally via a rotary plate.

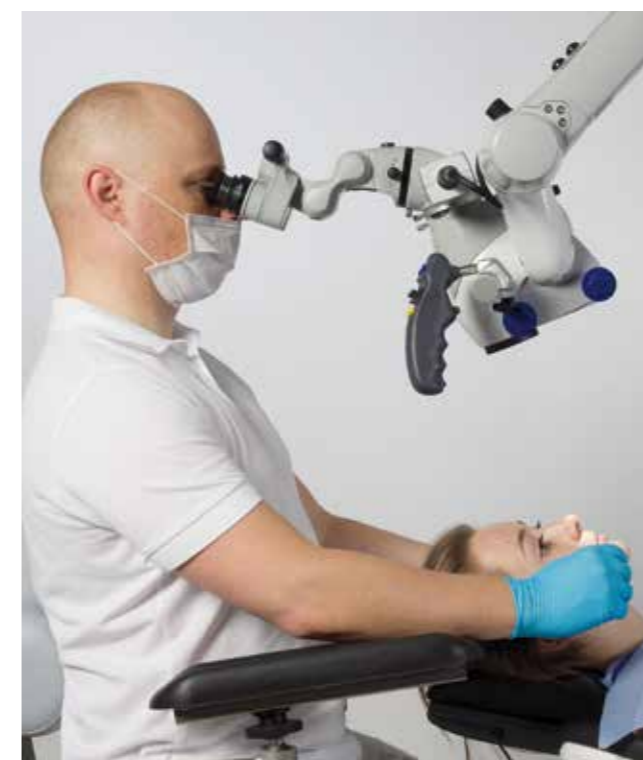

Figure 2.14

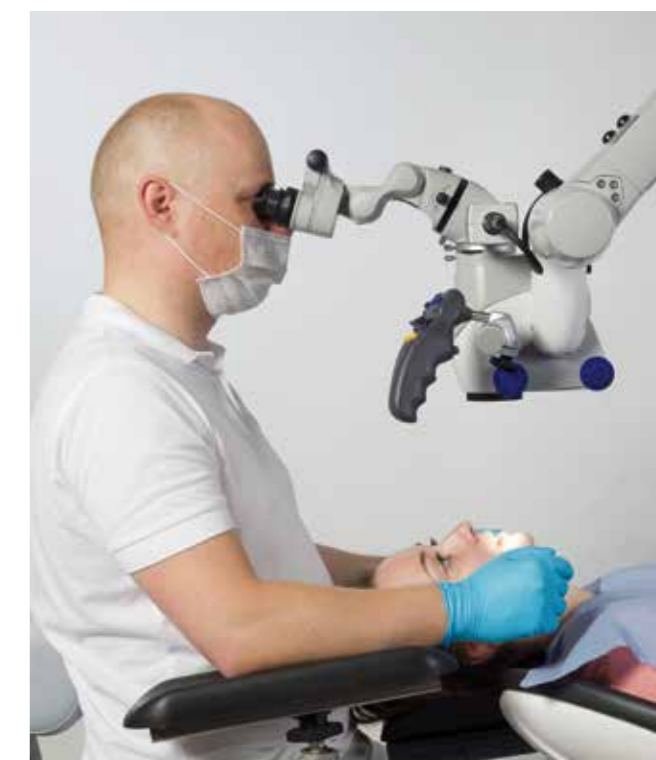

Figure 2.15

The S100 / OPMI pico with MORA interface is unique in this context: it enables tilting of the OPMI body in the lateral axis via the Mora interface without also moving the eyepieces.

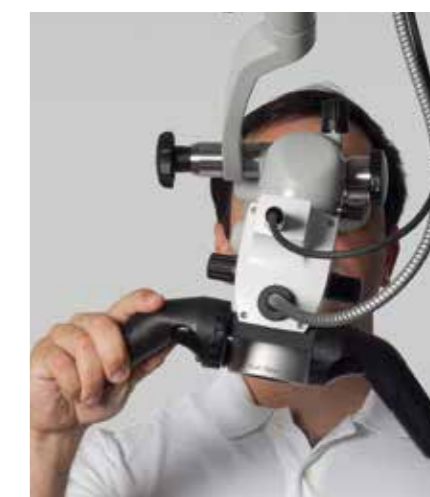

Figure 2.16

## Functional design

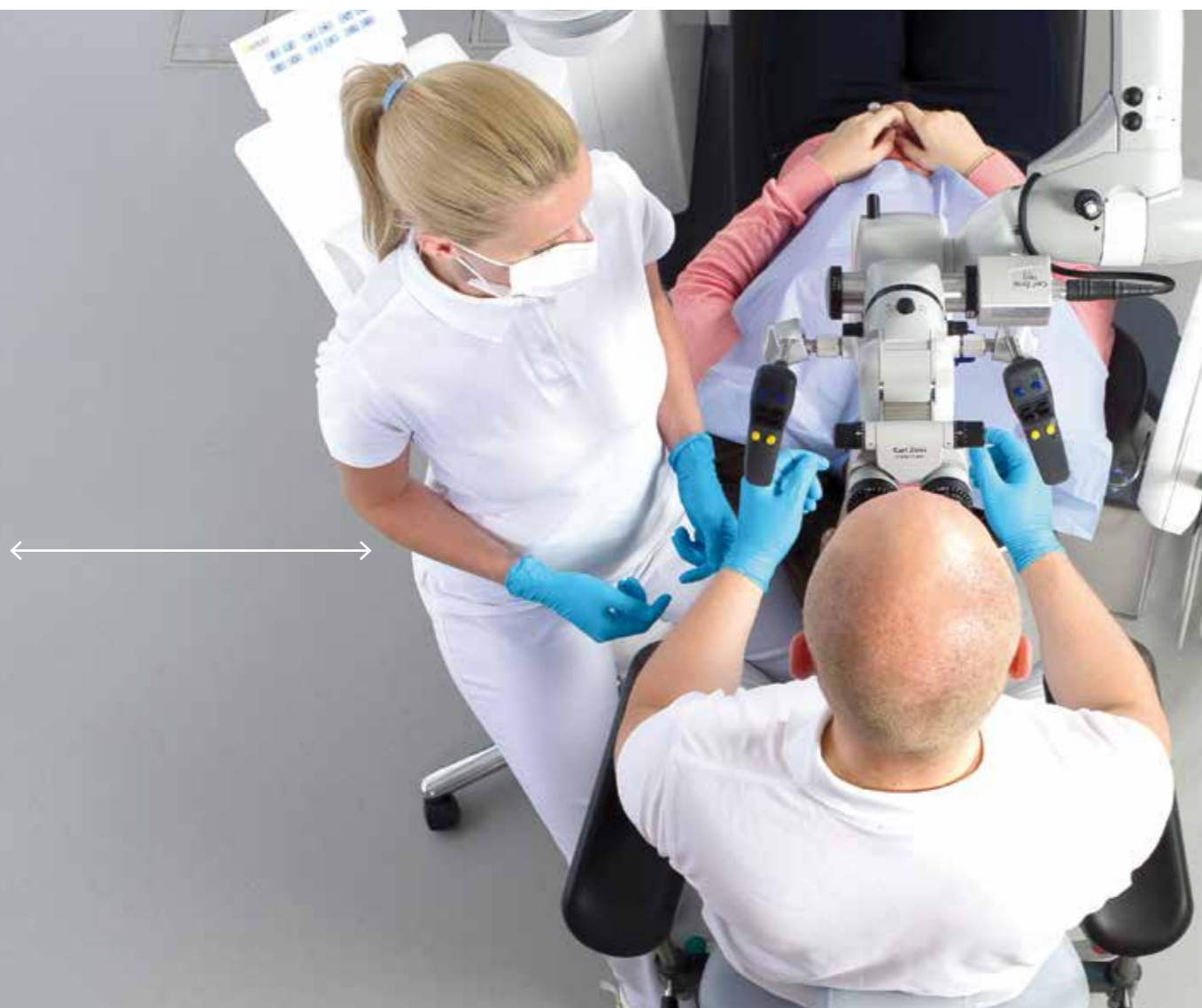


Figure 2.17

As 12 o'clock is the most frequent seated position for the dentist during treatment, the treatment room must be configured so that ample space is available behind the patient to ensure not only that the dentist can sit there, but also that enough room is provided for assistants to move to and fro.

## OPMI assistance

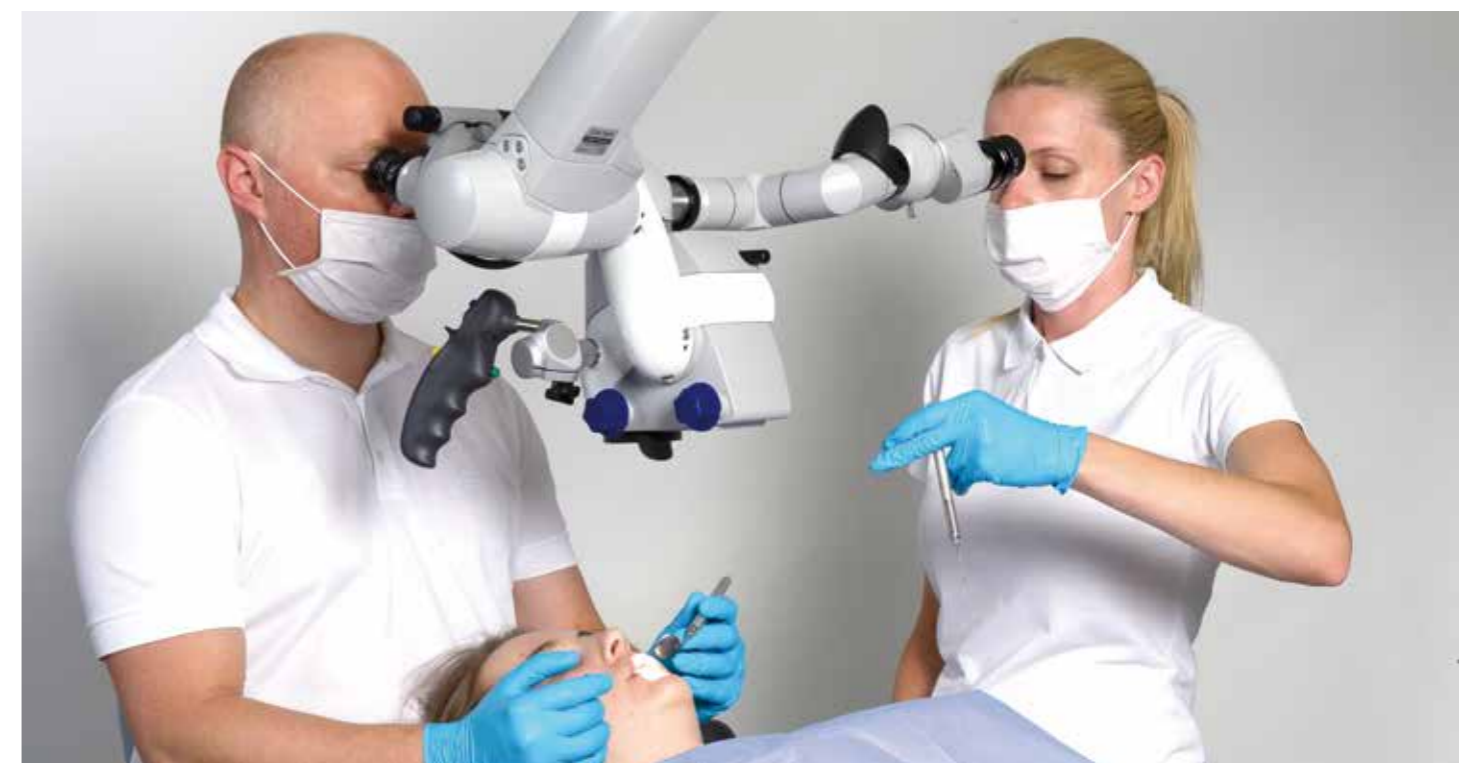

Figure 2.18

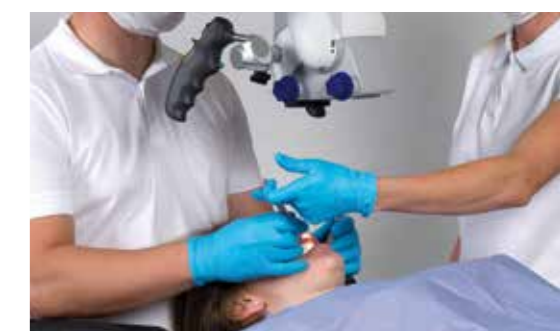

Figure 2.19

To enable efficient treatment, it is advisable to position all necessary instruments, materials and devices around the dentist and the assistant in order to ensure that they are easily accessible. For this reason, the use of a cart is ideal. All instruments and materials required for a procedure can be placed on them and made ready for a procedure in advance.

To enable the work to be carried out ergonomically, assistance tailored specifically to the needs of microdentistry is essential.

Instruments are frequently changed during a dental procedure. Because dentists constantly look through the eyepieces, they cannot see the required instruments and materials, making it necessary for the assistant to hand them over.

This aspect must not be underestimated because it contributes to efficient workflow during a procedure.

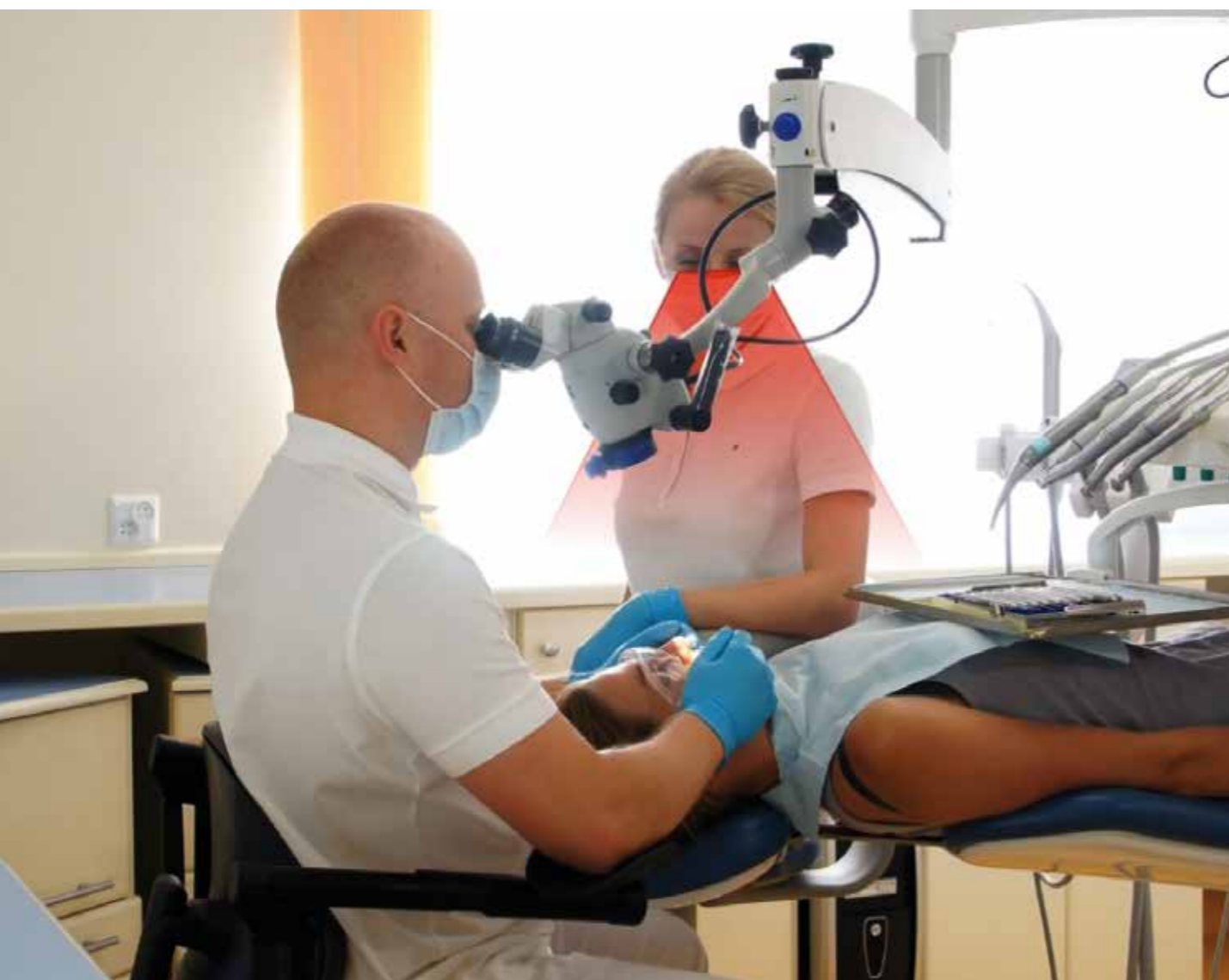

Figure 2.20

The assistant must be able to see what the dentist sees in order to adequately support him or her in the respective treatment situation. While co-observation tubes, are available in the vast majority of cases, it is better to have a monitor with the video image from a video camera connected to the OPMI. This ensures that the assistant can optimally use the OPMI image to provide adequate support while keeping the treatment field in view.

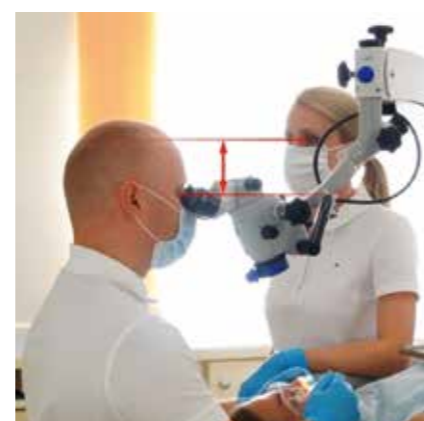

Figure 2.21

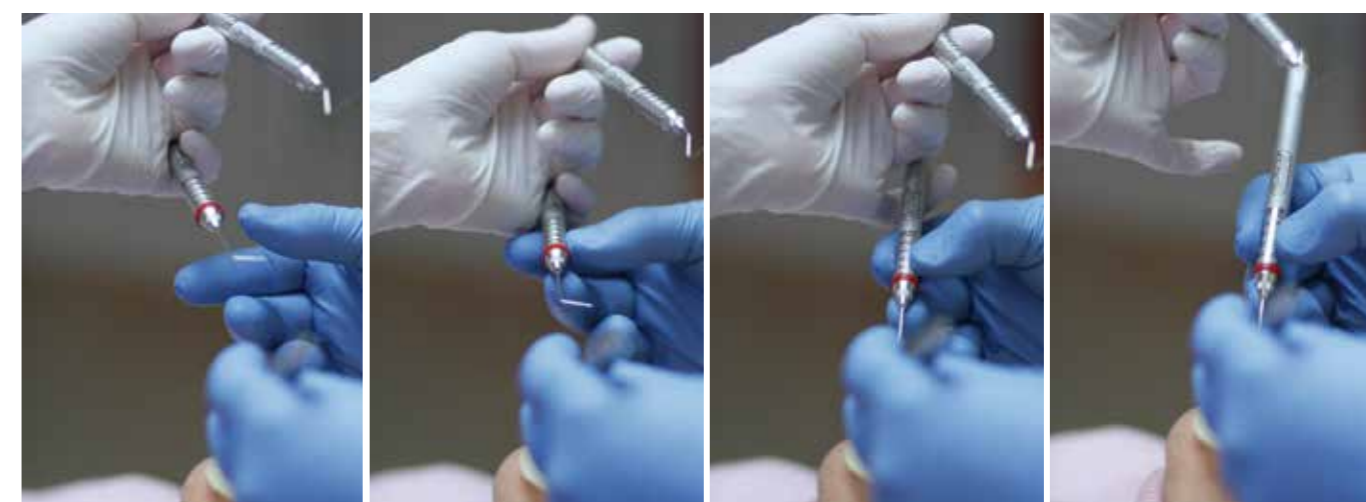
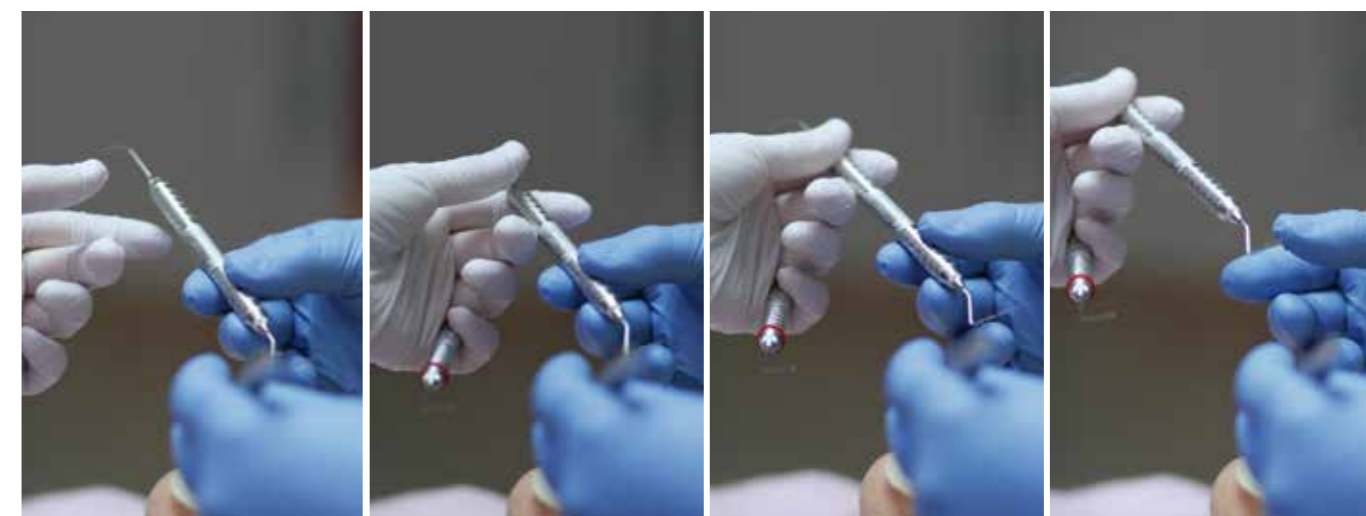


Figure 2.22

It is important to point out two aspects in regards to the hand over of instruments.

First, to clearly communicate when a used instrument is being returned, which new instrument is needed and when it should be handed to the dentist. This can be verbal communication, or increasingly non-verbal when the dentists and the assistant have gained experience in working as a team.

Second, the correct and precise handover of the instrument from the assistant to the dentist is vital. Because the handover position is outside the dentist's field of view, the instrument must be given to the dentist with the correct orientation relative to the treatment field and with the right grip position. If not, there is a certain risk of injury to the patient as a result of sharp or pointed instruments. Dentists often have to change their grip, which draws

their view away from the OPMI and thus interrupts the workflow and leads to fatigue.

Because assistants have to carry out multiple procedures including aspiration of the patient's mouth, it is beneficial if they can receive and pass an instrument with the same hand at the same time.

# 3

## 3

### OPMI in endodontics

Author: **Prof. Dr. José Aranguren Cangas**

**Dr. Manor Haas**

**Dr. Tony Druttman**

#### 73 **Introduction**

#### 74 **Magnification in endodontics**

Working magnification

75 Uses of the OPMI in endodontics

#### 76 **Microendodontic instruments**

77 Ultrasonics

Ultrasonics tips

Uses of ultrasonics in endodontics

78 Mirrors

Micro instruments Files with a handle

Stropko syringe

79 Burs

Dyes

#### 80 **Examination of the external surface of the tooth**

82 Identification of the floor of the pulp chamber

83 Removal of coronal restorations  
Preservation of tooth structure

84 Assessment of canal cleanliness after preparation

85 Identification of internal cracks

86 Canal location

88 Calcified canals

91 Evaluation and management of perforations

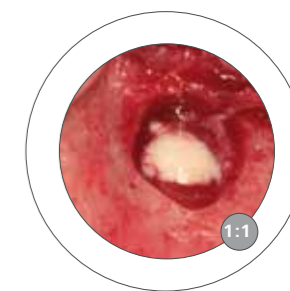
92 Obturation of the canal  
Non-surgical retreatment

93 Uses of the OPMI in non-surgical retreatment:

95 Apical plug with MTA

File evaluation

#### 94 **Endodontic root-end surgery**



## Introduction

In the 21st century the OPMI plays a vital role in endodontics and endodontists have led the way in embracing the OPMI into daily clinical practice. Endodontic treatments can be very challenging due to the complexity of the anatomy of the root canal system. In the past root canal treatment was performed predominantly by feel. With the aid of the OPMI, structures can be seen that remain hidden to the naked eye and treatment can be carried out with far greater precision and predictably than ever before. Microscopy in endodontics has become a way of life.

Figure 3.1

## Magnification in endodontics



Figure 3.2a magnification 3.5x

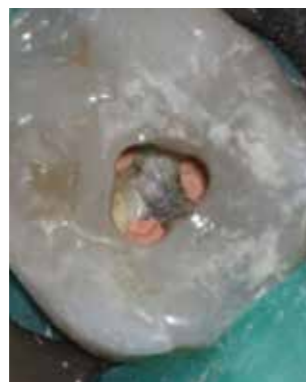

Figure 3.2b magnification 5.1x

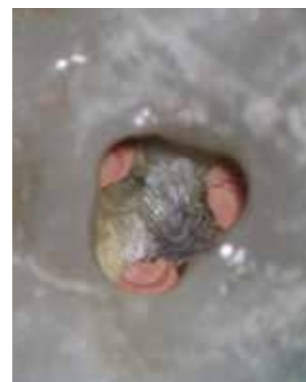

Figure 3.2c magnification 8.5x

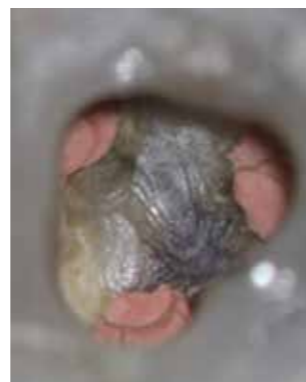

Figure 3.2d magnification 13.6x

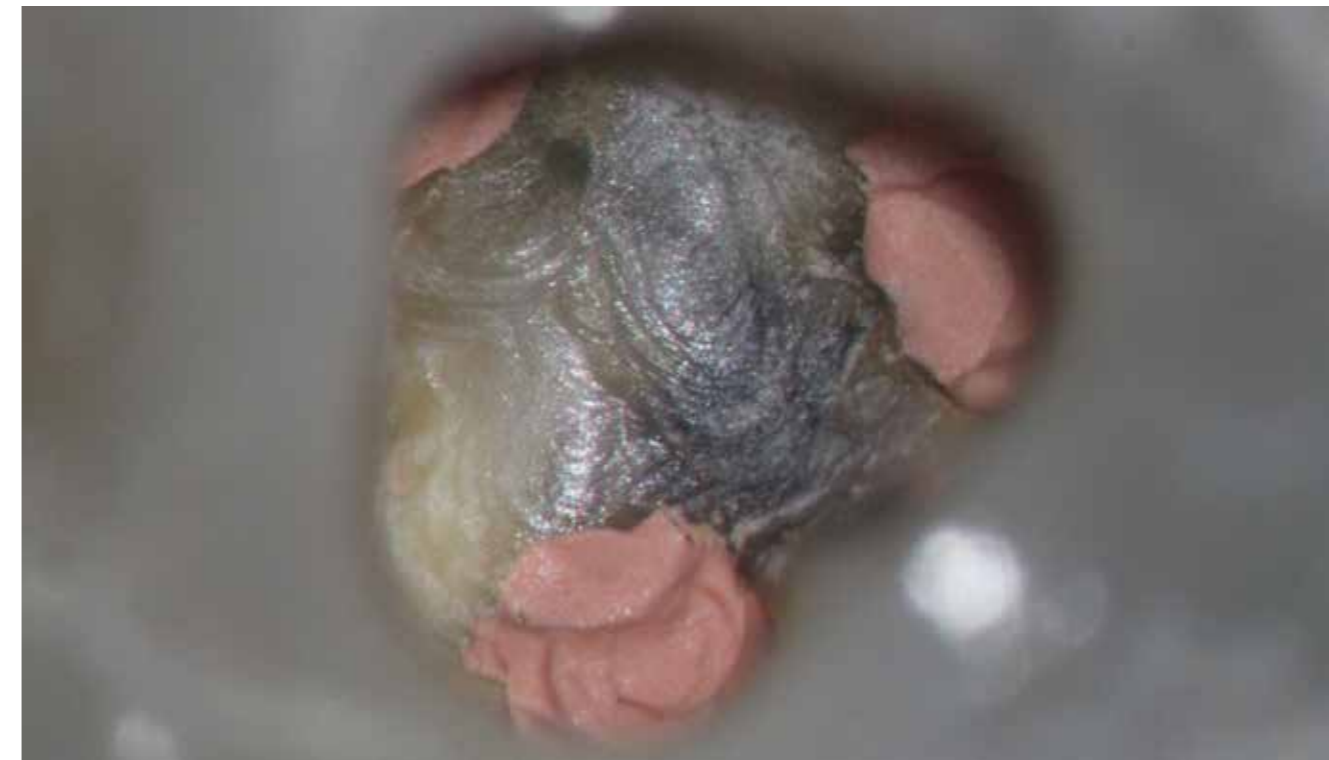

Figure 3.2e magnification 21.25x

### Working magnification

In endodontics we are used to working with 8.5x magnification. However, if we have to work in the canal or we want to record the treatment we need 13.6x or 21.25x magnification.

### Magnification factors

#### 0.4x - 0.6x

This is used mainly for periapical surgery

#### 1.0x

More common magnification

#### 1.6x - 2.5x

Used to visualize fine details and for documentation.

### Uses of the OPMI in endodontics

1. Examination of the external surface of the tooth
2. Removal of coronal restorations
3. Preservation of tooth structure
4. Identification of the floor of the pulp chamber
5. Location of sclerosed canals
6. Identification and orientation of curvatures in the radicular access
7. Identification of internal cracks, ledges and blockages in the root canal
8. Evaluation of canal cleanliness after preparation
9. Ensure optimal obturation
10. Assessment of existing root fillings
11. Identification and management of perforations
12. Assessment of coronal leakage
13. Evaluation of endodontic instruments after use
14. Removal of root filling materials in non surgical re-treatment
15. Management of soft and hard tissues in surgical re-treatment

## Micro endodontic instruments

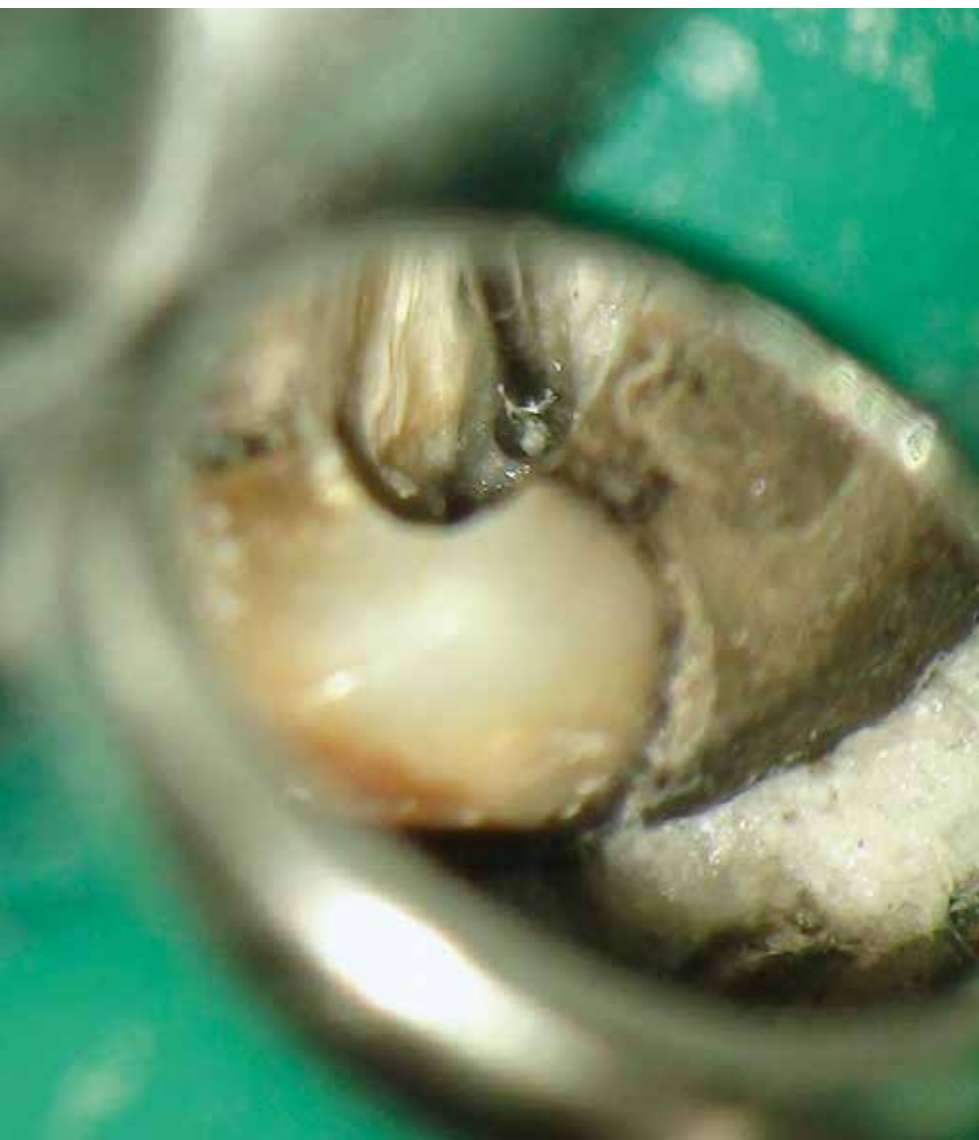

Figure 3.3 Accurate positioning of an LN bur (0.5mm dia) while working with indirect vision under an OPMI

Because of the level of precision that can be achieved when using the OPMI, special instruments are required. These include instruments that help to identify structures and allow the more accurate removal of tooth tissue by improving visual access.

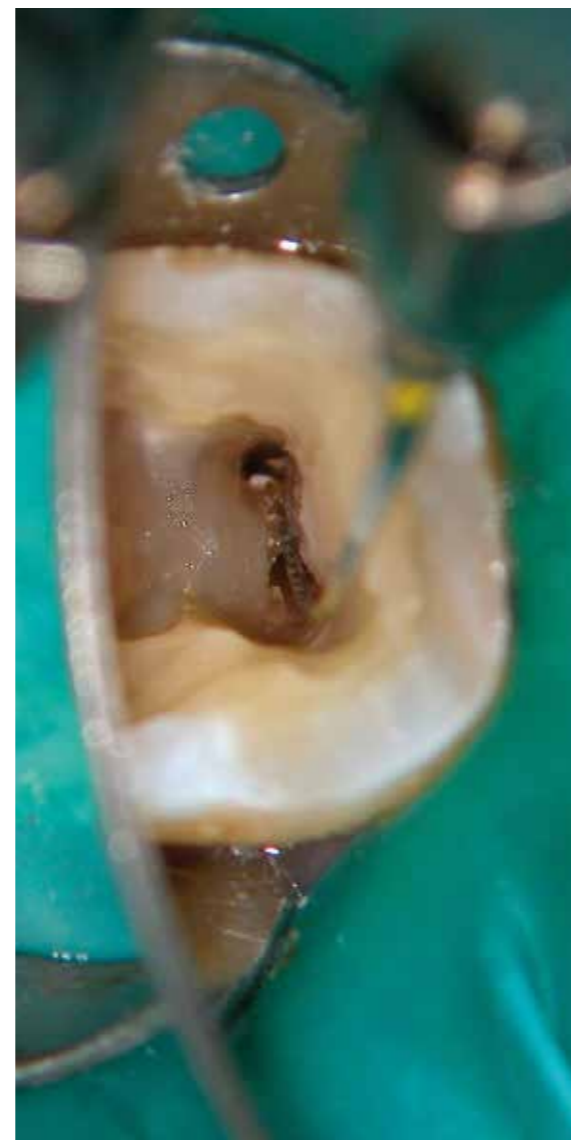

Figure 3.4 Ultrasonic preparation of the isthmus in a lower molar using ultrasonic k-files



Figure 3.5a EndoSuccess™ ET 25 ultrasonic tip straight

### Ultrasonics

Ultrasonic instrumentation is a vital part of the armamentarium needed in primary and re-treatment cases, both surgical and non surgical. For endodontic uses, ultrasonic devices have to be set at a lower power range than for other applications such as scaling, otherwise the delicate tips can fracture easily.

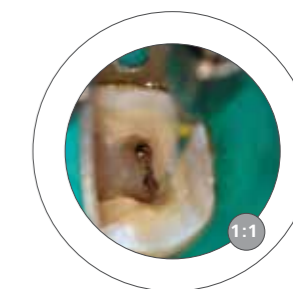


Figure 3.5b EndoSuccess™ ET 25 ultrasonic tip curved

### Ultrasonic tips

There are many different ultrasonic tips on the market. Some have a smooth surface, others diamond coated. Some are rigid, while others are flexible to improve visibility. Even K-files can be used ultrasonically. The tips can be used with irrigant or dry. The advantage of ultrasonic instruments over conventional handpieces is one of visual access.

### Uses of ultrasonics in endodontics

1. to refine access cavities
2. canal location (especially where canals are sclerosed)
3. refinement of canal preparation
4. removal of fractured instruments from canals
5. post removal
6. root end preparation in endodontic surgery



Figure 3.6 Fig HR mirrors in Size 000, 0, 4 and 8

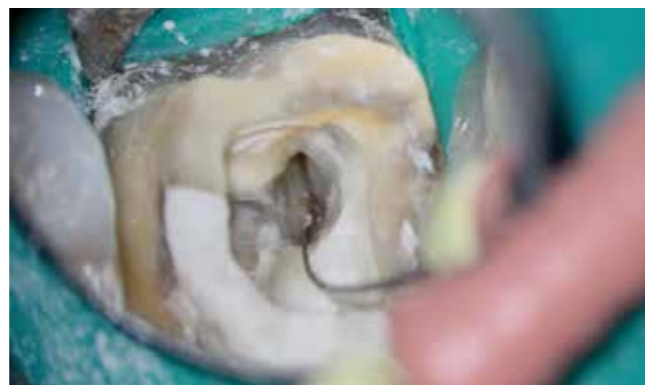

Figure 3.7 06 handfile attached through the hole in the handle using Hu Friedy DP18L locking tweezers

**Mirrors**

Mirrors are essential to the use of the OPMI because there are very few areas of the mouth that can be viewed by direct vision. It is therefore important that silver fronted mirrors are used so that there is no distortion of the reflected image. Because it is necessary to have the maximum amount of light to illuminate the depths of the root canal, it is also important that as little light as possible is absorbed by the surface of the mirror.

There are three different mirror surfaces:

- Standard
- Rhodium
- HR mirrors

To work with the OPMI, we need at least rhodium mirrors, these reflect 75% of the light. Standard mirrors result in double images and a loss in definition. HR mirror have the highest reflectivity on the market today (99.9%).

Mirror size is also important. While size 4, the standard size (22mm dia) are used in most situations, other sizes are available. Size 8 (30mm) is very useful

for documentation as the mirror can be rested against a rubber dam clamp for stabilization. Small diameter mirrors are very useful where access is limited as the mirrors can be moved further away from the operating filed. Size 000 (10mm) and size 0 (14mm) are very useful for upper second and third molars. Micro mirrors of different shapes are used in surgical endodontics to examine the cut root face and crypt.

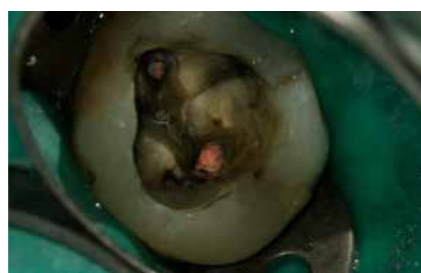

Figure 3.9a rhodium mirror

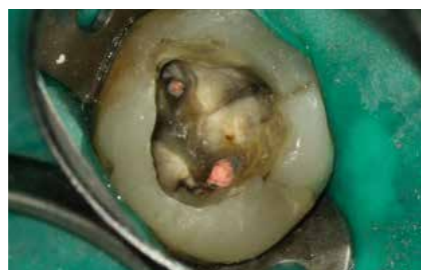

Figure 3.9b HR mirror

**Micro-instruments Files with a handle:**

Special instruments for working with the OPMI include the micro-opener and the micro-debrider. Both instruments are very useful as they allow working in the canal with unimpaired visual access.

The micro - opener is used to look for the entrance of the canal It may also be useful in the identification of a bifurcation or a ledge. The micro-debrider which is based on a Hedstrom file is used to remove tissue from the wall of the canal or root filling material.

Regular hand instruments can also be used by attaching them to locking tweezers (Figure 3.11).

**Stropko syringe:**

This instrument is really useful for drying the canal at a precise point. It is used in micro apical surgery for drying the canal before obturation.

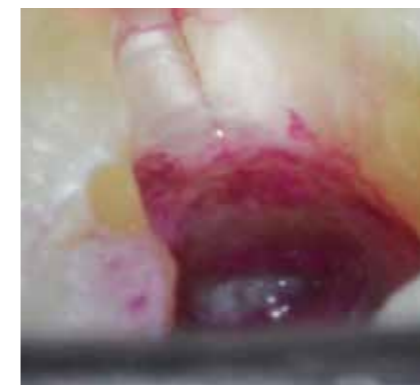

Figure 3.8a Fucsin

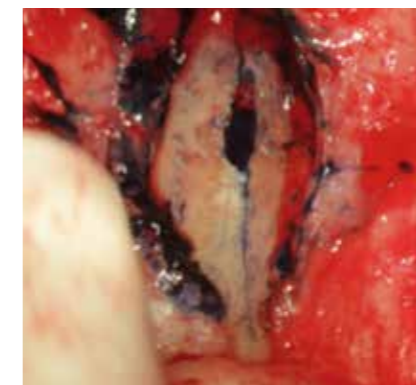

Figure 3.8b Methylene blue

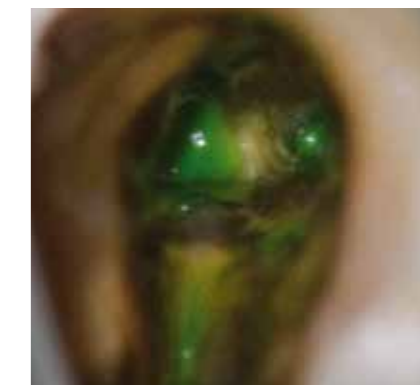

Figure 3.8c Fluorescein

**Burs**

Very few standard burs can be used with the OPMI, because usually the shank is too short and visual access is impaired by the head of the handpiece. It is important therefore to use long shank burs so that tip of the bur can be controlled precisely.




Figure 3.10 A selection of slow and high speed burs used for endodontic access cavity preparation

**Dyes**

The dyes are used to find fractures, or cracks and hidden canals. The two most important dyes are Fluorescein and methylene blue. Fucsin can also be used.

- **Fluorescein** is a red-orange dye mainly used in calcified canals. With the xenon source, organic tissue is dyed fluorescent green.
- **Methylene blue** is used in crack diagnosis and apical surgery, is a blue dye (from light-dark), and dyes the surface of the fractured organic tissue dark-blue. It is very useful in apical surgery as it dyes the perimeter of the root and the different apical foramina.




Figure 3.11 Hu Friedy DP18L locking tweezers inserted into a standard hand file



## Examination of the external surface of the tooth

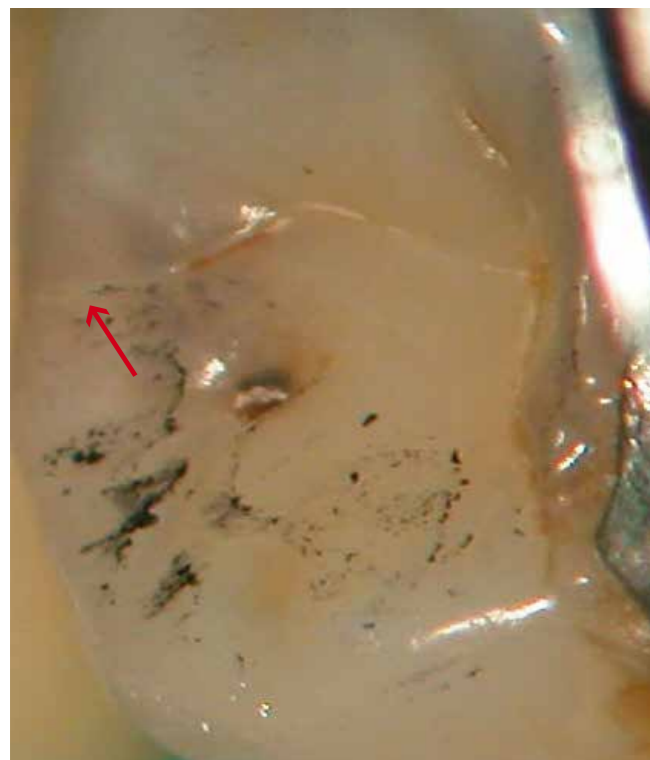


Figure 3.12 crack through mesial marginal ridge (arrow)

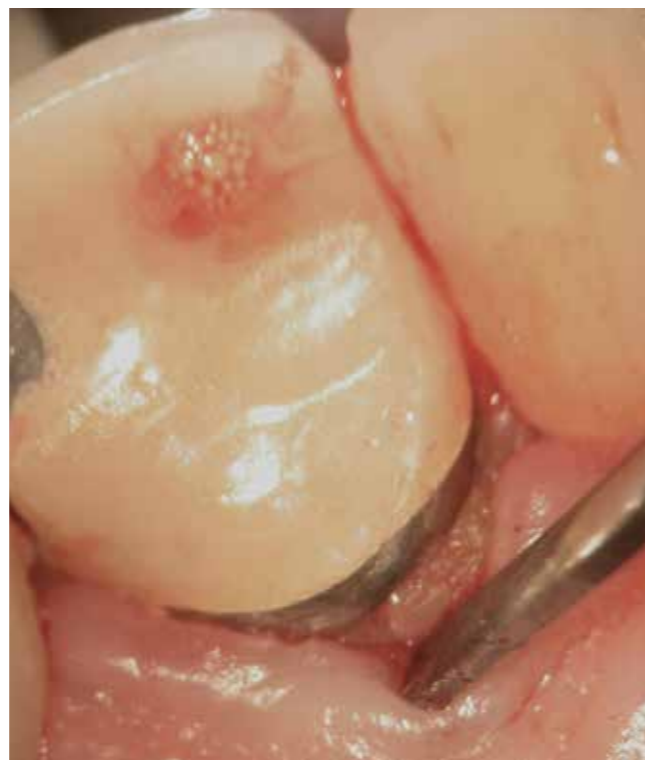

Figure 3.13 vertical root fracture seen through the microscope while retracting gingival margin

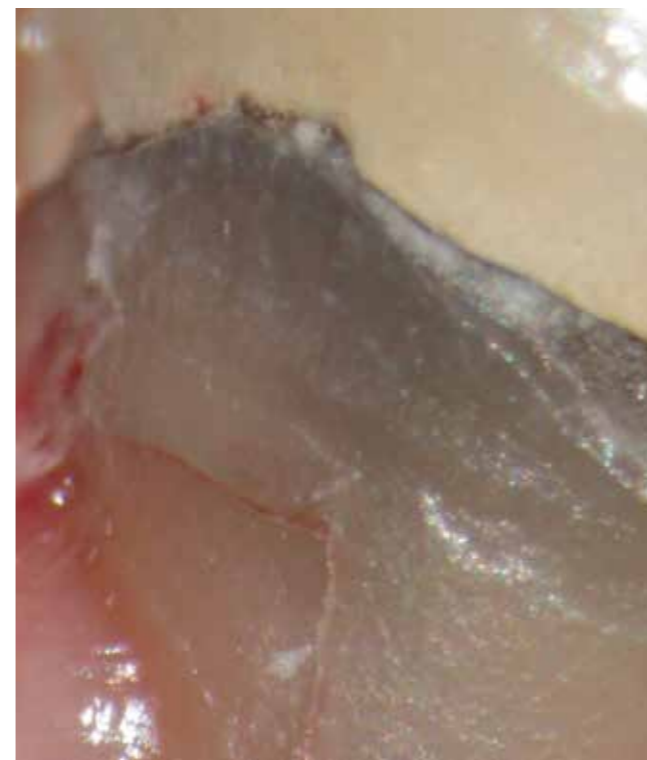


Figure 3.14 vertical root fracture seen below crown margin

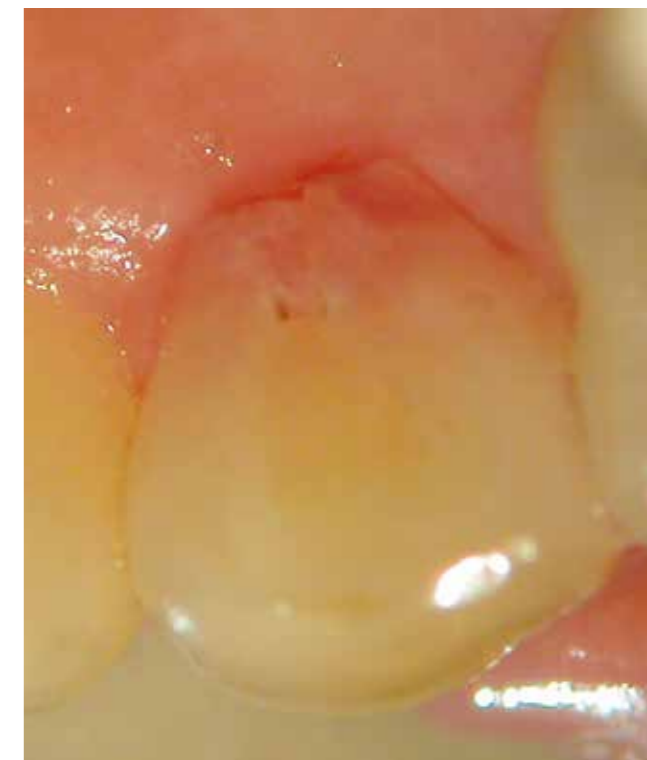

Figure 3.15 external resorption

Prior to starting endodontic treatment the OPMI is particularly useful for examination of the external surface of the tooth. Caries can be identified in areas that are difficult to see without magnification and illumination. Vertical and horizontal cracks, root fractures and external root resorptions are more easily identified with an OPMI

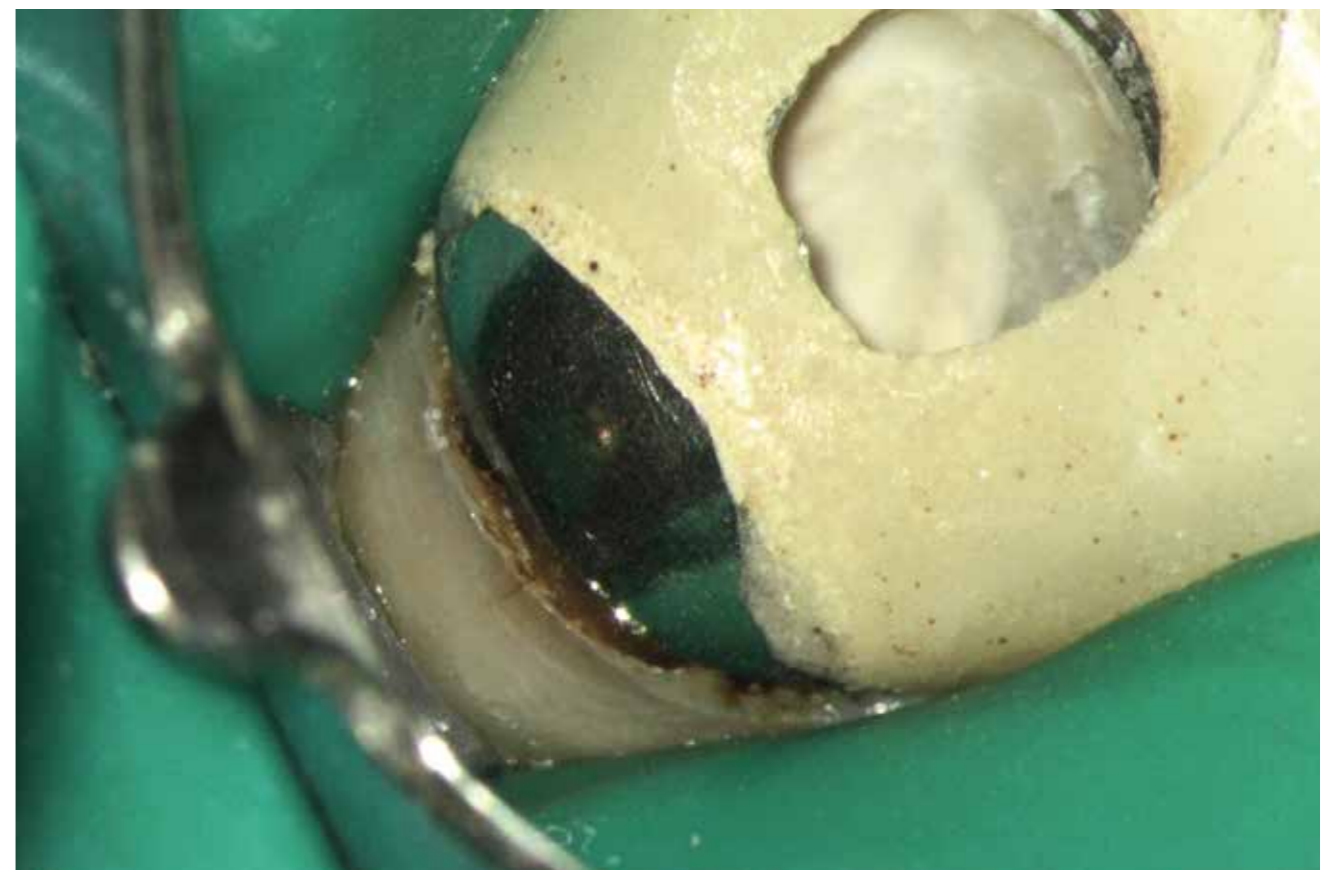


Figure 3.16 Examination of crown margin

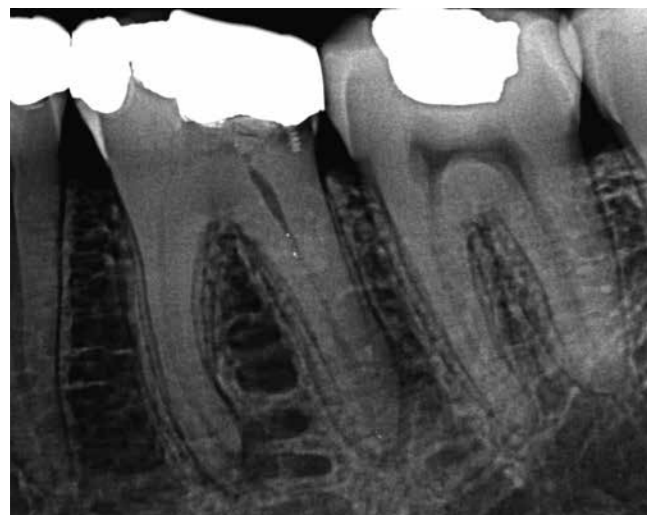

Figure 3.17 Sclerosed pulp chamber in lower left first molar due to a deep restoration and recurrent caries

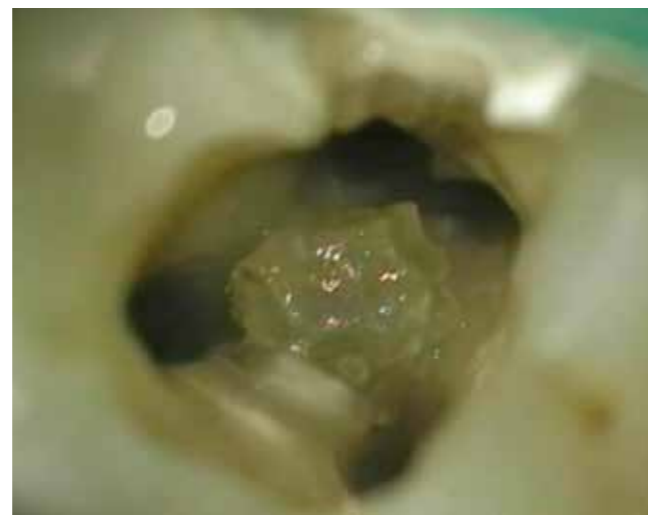


Figure 3.18a View of a pulp stone as seen via the OPMI. Note the rough pulp floor surface, indicative of pulp stones

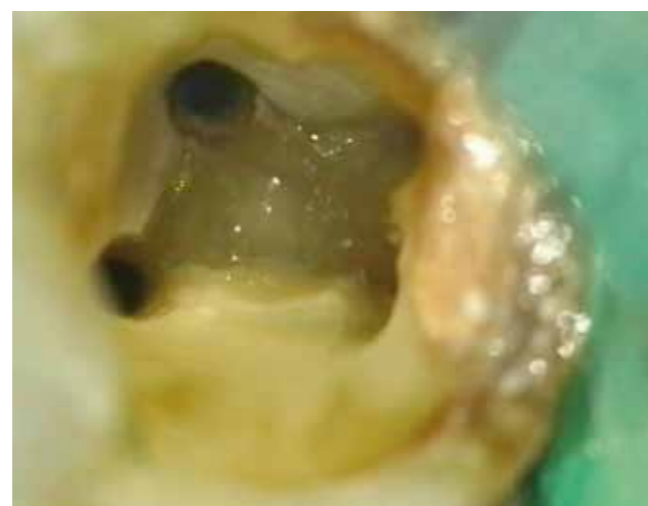

Figure 3.18b This is the view of the above access after the pulp stones were removed with micro-ultrasonics or slow-speed, surgical-length, round burs. Note the smooth floor

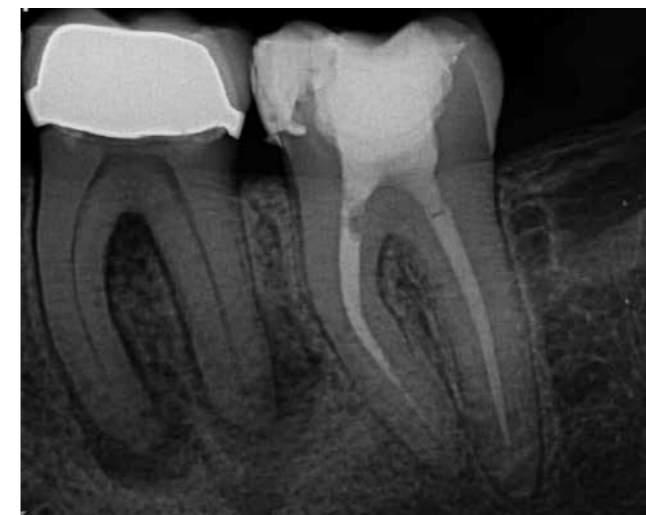

Figure 3.19a Radiograph of lower left second molar in figure 3.19b and 3.19c

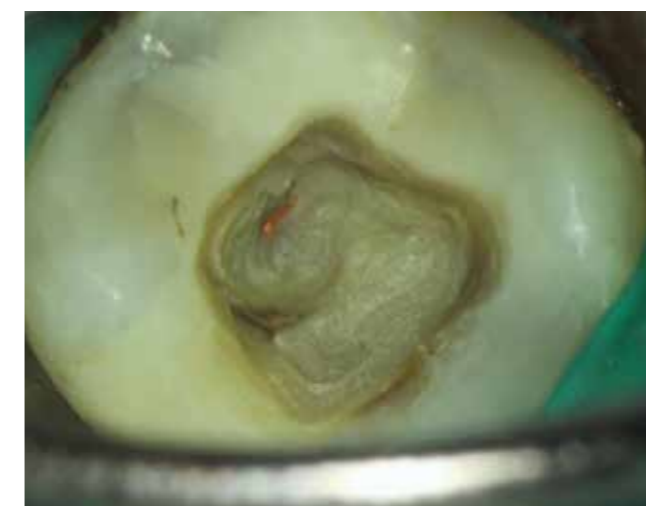

Figure 3.19b Composite is partially removed to expose the floor of the pulp chamber in an endodontic re-treatment case

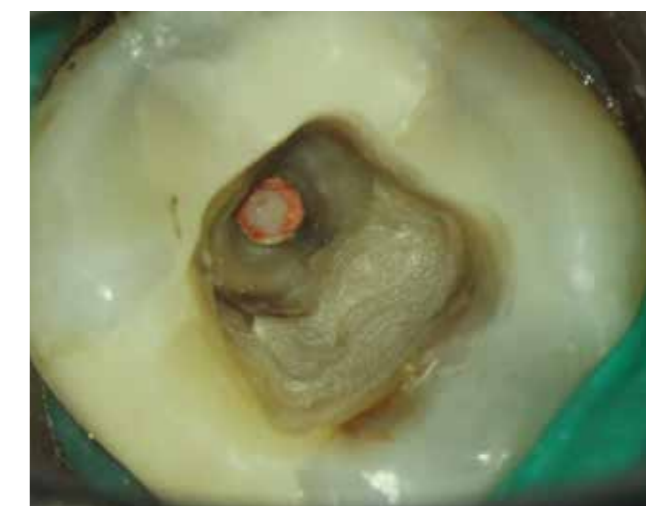

Figure 3.19c The floor of the pulp chamber has been revealed in the distal half of the access cavity

### Identification of the floor of the pulp chamber

Insult to the pulp (caries, cracks, restorations) can make the floor of the pulp chamber difficult to identify (Figure 3.17). Using the OPMI it is possible to distinguish between pulp stones, reparative dentine and the true floor of the pulp chamber. Differences

between calcifications in the pulp chamber (i.e. pulp stones) and the floor of the pulp chamber can be distinguished by colour and texture. Medium to high magnification is recommended.

### Removal of coronal restorations

Increasingly composite is replacing amalgam as the material of choice for coronal restorations. As the colour of composite can be very similar to that of dentine, its removal can be difficult without a microscope (Figures 3.19a and 3.19b).

### Preservation of tooth structure

The removal of excessive amounts of tooth structure, both coronal and radicular leads to weakening of the tooth. This can result in fracture of either the coronal restoration or root fracture. The OPMI allows for the strategic removal of tooth tissue during preparation and refinement of the access cavity, the removal of core materials in re-treatment cases and the preparation of canals with a non-circular cross section.

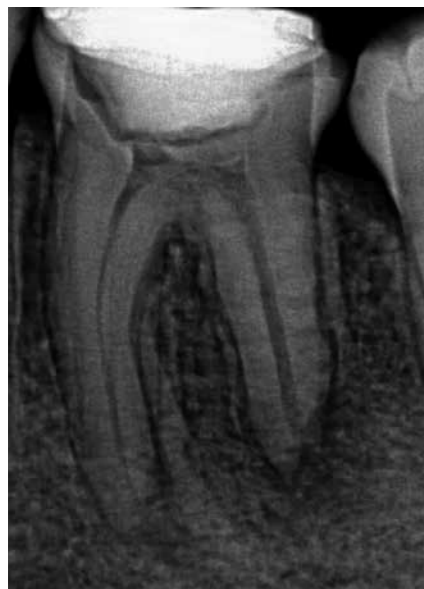

Figure 3.20a Pre-operative radiograph of lower left first molar

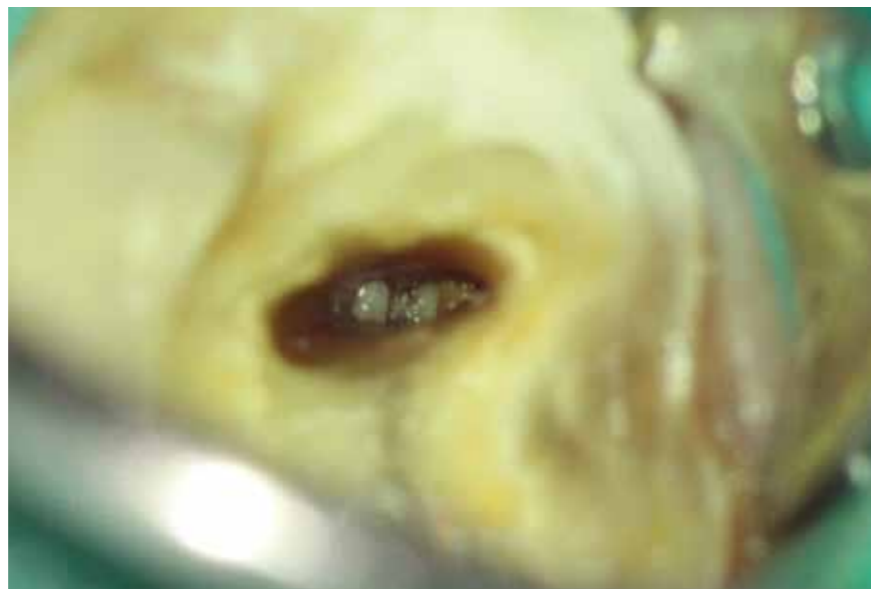

Figure 3.20c debris left in the distal canal of a lower first molar after instrumentation with rotary instruments and irrigation.

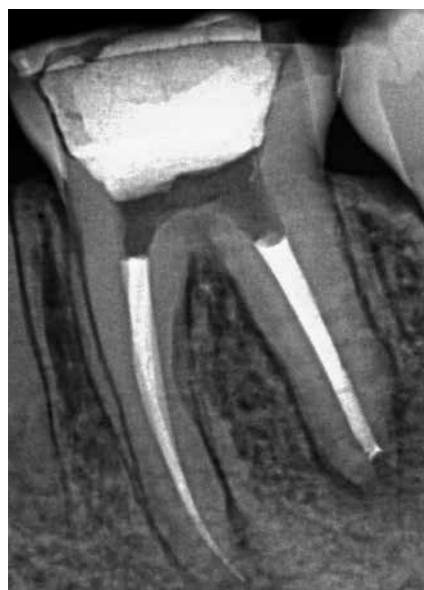

Figure 3.20b Post-operative radiograph of lower left first molar

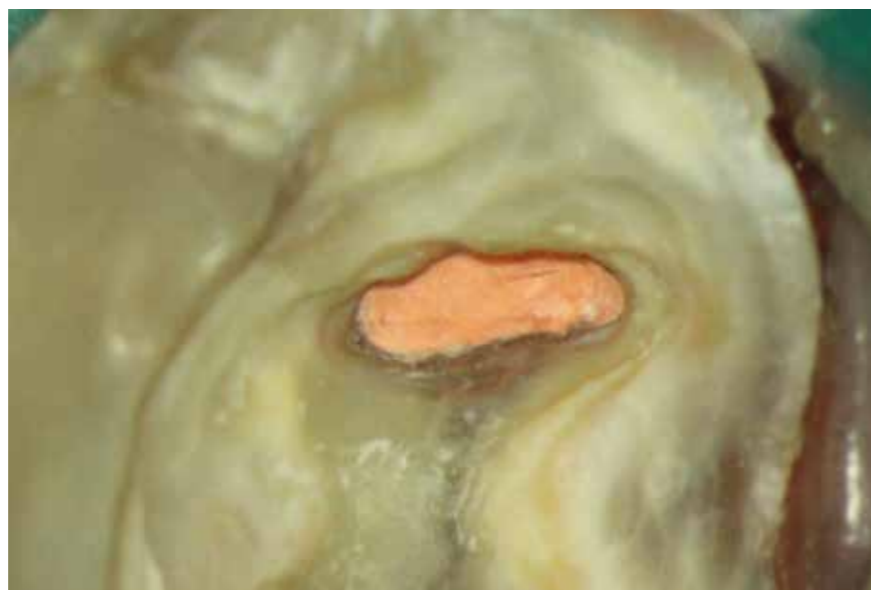

Figure 3.20d distal canal obturated

#### Assessment of canal cleanliness after preparation

Not all canals are circular in cross section and when oval canals are prepared with rotary instruments, debris can easily be left behind. The OPMI can be used to evaluate canal cleanliness after

preparation and post instrumentation irrigation and any remaining debris removed before obturation (Figure 3.20c).

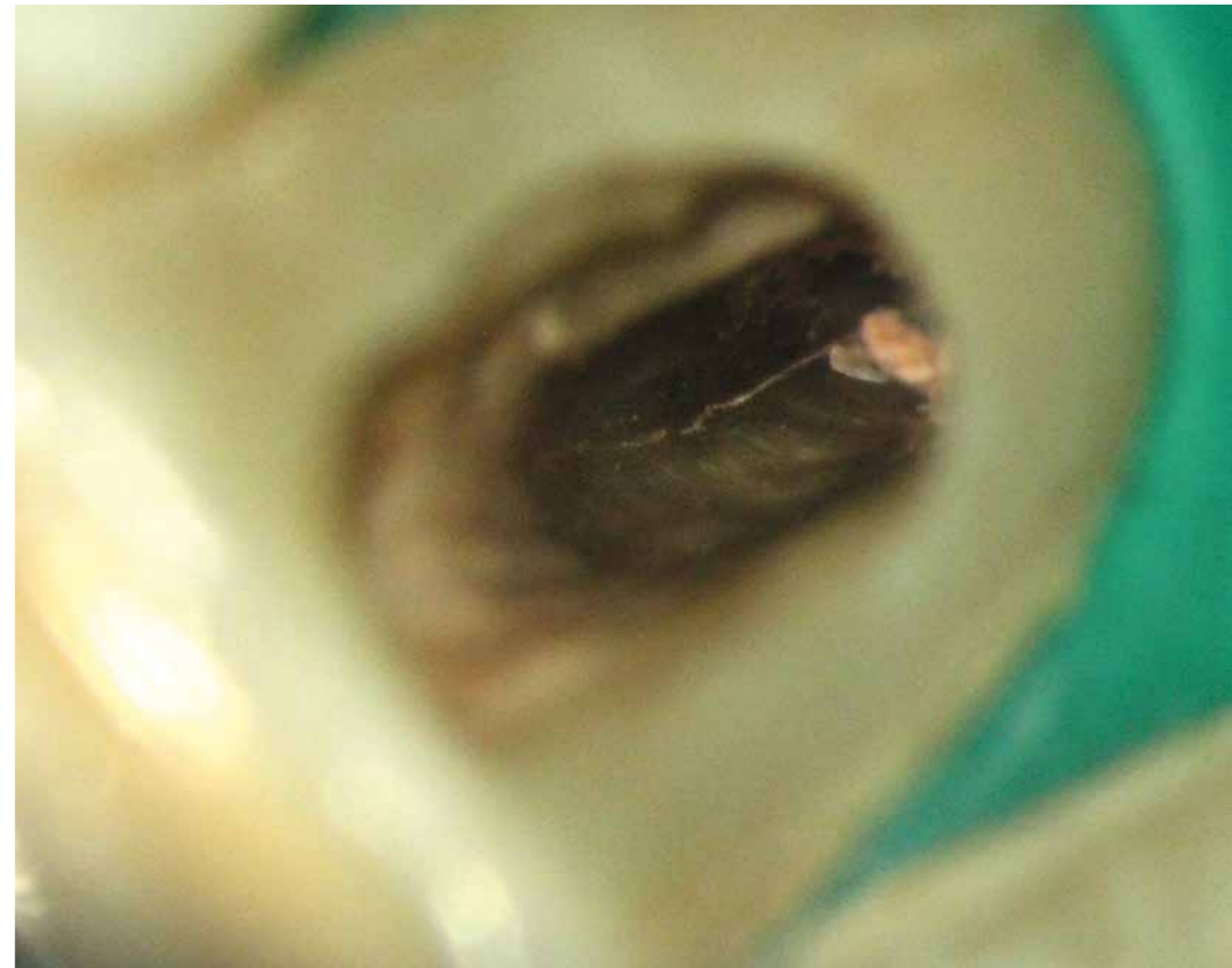


Figure 3.21 Radicular crack

#### Identification of internal cracks

The dentist should always look for internal vertical coronal and radicular cracks and fractures when using the OPMI. These would be difficult or impossible to detect without the high magnification and illumination provided by the OPMI.

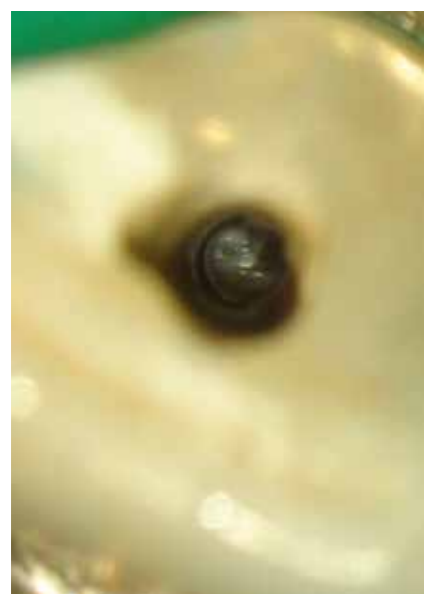


Figure 3.22a Upper central incisor with unusual canal anatomy. The canals could be identified using the OPMI at high power and maximum illumination

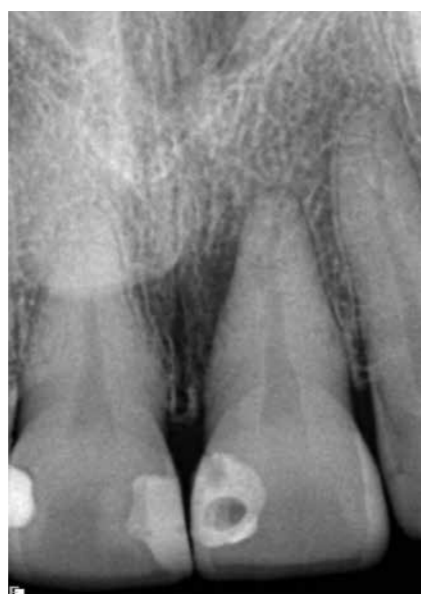

Figure 3.22b Pre-operative radiograph of tooth 21 shown in fig 3.22a

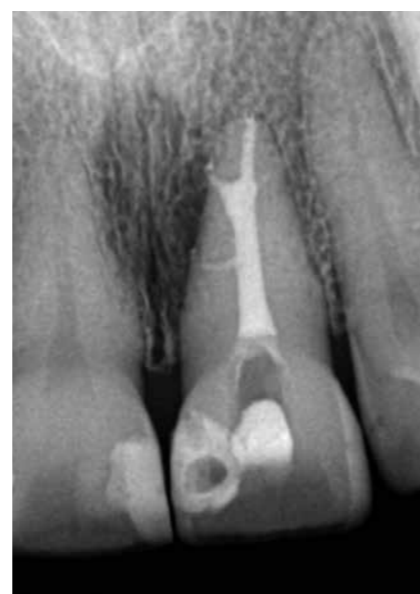

Figure 3.22c Post-operative radiograph showing the intricacies of the canal anatomy

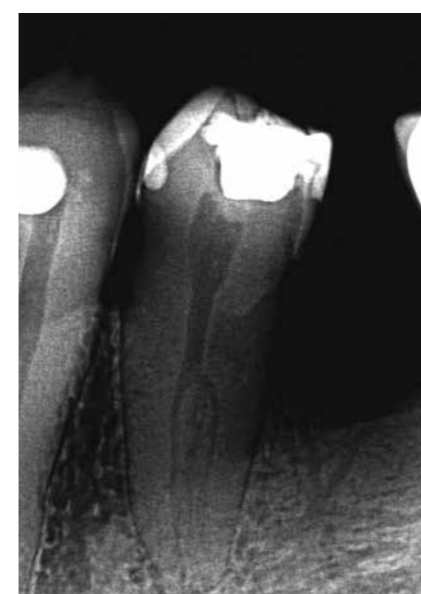

Figure 3.24a Pre-operative radiograph of lower left first premolar rotated through 90 deg. Note the bifurcation of the canal on the middle third of the root

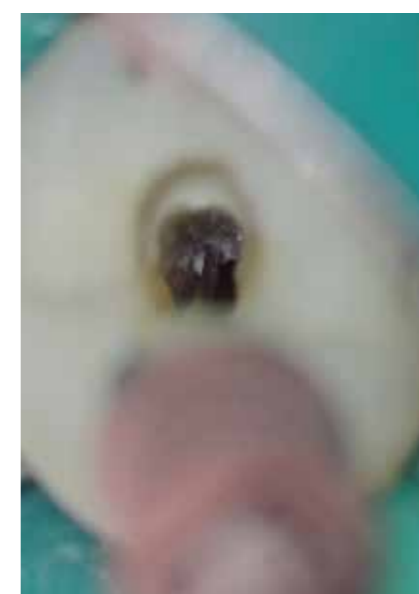

Figure 3.24b The lingual canal has been identified after the buccal canal preparation has been completed, an 06 hand file has been precurved and positioned into the lingual canal with the aid of the OPMI

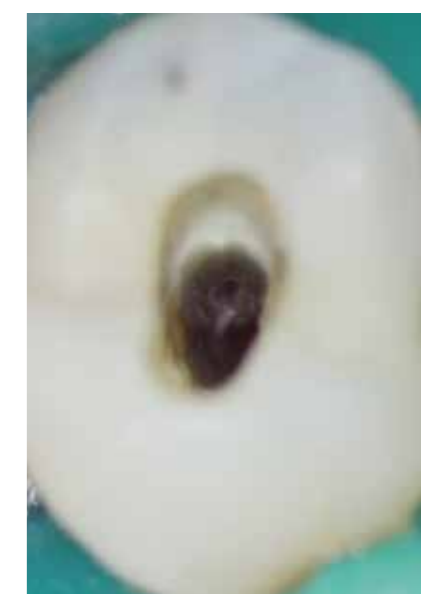

Figure 3.24c Lingual canal preparation started with pre-curved hand files, at 90 deg to the buccal canal, and the angle reduced with ultrasonically energised k-files and preparation completed with nickel titanium rotary files

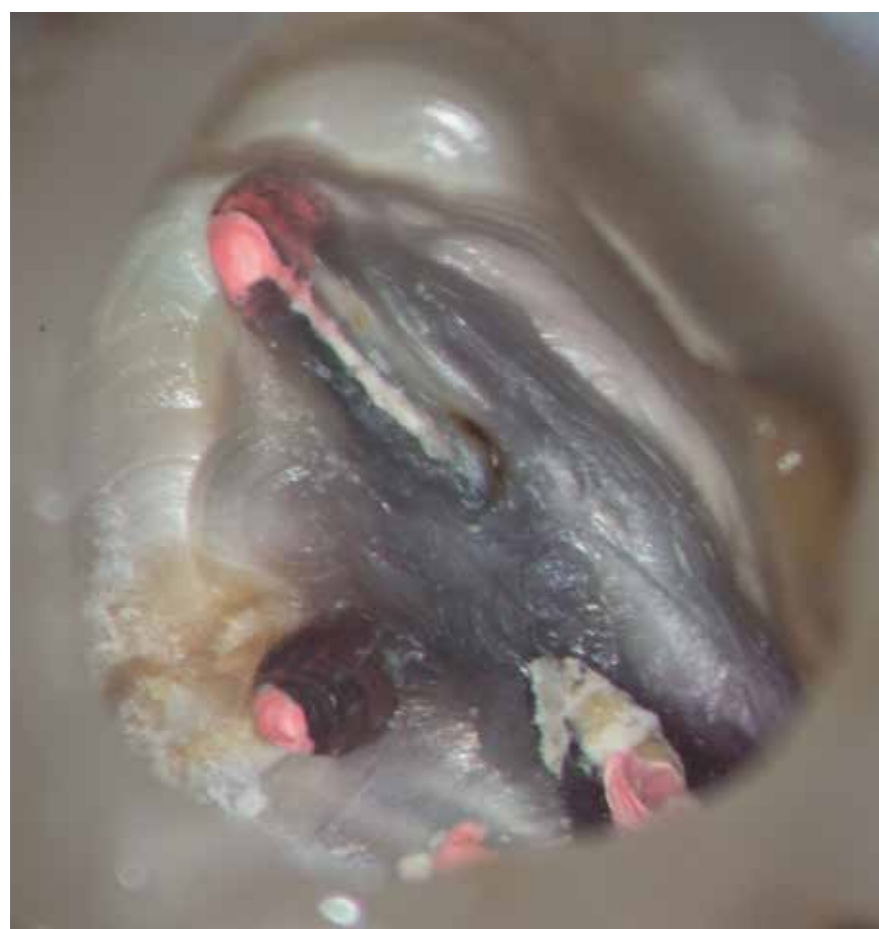

Figure 3.23 Floor of the pulp chamber viewed through an OPMI. Note how easy it is to locate the calcification over the MB2 canal.

### Canal location

The root canal anatomy of teeth can be very variable and missed canals are a major cause of failure of root canal treatment. The OPMI plays a vital role in helping to identify accessory canals at whatever level they may be. Commonly missed canals are the MB2 canal in maxillary molars and to a lesser degree, the mid-mesial canal in mandibular molars, buccal canals of lower incisors and second and third canals in premolars.

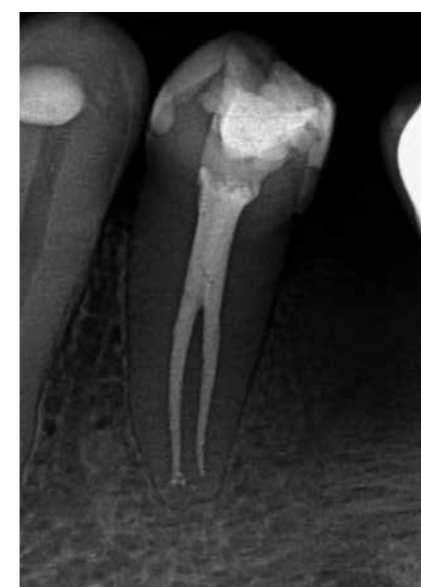

Figure 3.24d Post-operative radiograph showing how the lingual canal has been straightened

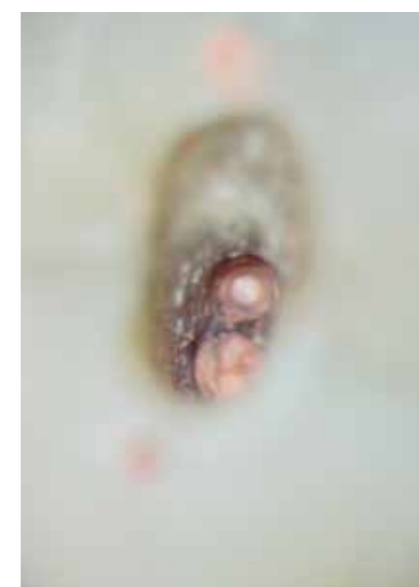

Figure 3.24e Both canals obturated using warm vertically compacted gutta percha

- Small canals can be located using the OPMI at higher magnification and with medium to high illumination.
- MB2 canals are often sclerosed in the pulp chamber and require small diameter, surgical-length, slow-speed and round burs or ultrasonic tips. For improved precision the tip of the bur or ultrasonic instrument should be visible at all times during canal location. Flexible ultrasonic tips which have been pre-curved are particularly useful in these situations.
- Once the canals are located, very small hand files should be used to negotiate canals.

Figure 3.25a MB2 visible as a white spot, too small for a 0.06 file to enter

Figure 3.25b MB2 canal has been chased with a 0.5mm rosehead bur and prepared with rotary files

Figure 3.25c MB1 has been obturated and sealer has been forced into the MB2 canal indicating that MB1 and MB2 canals join

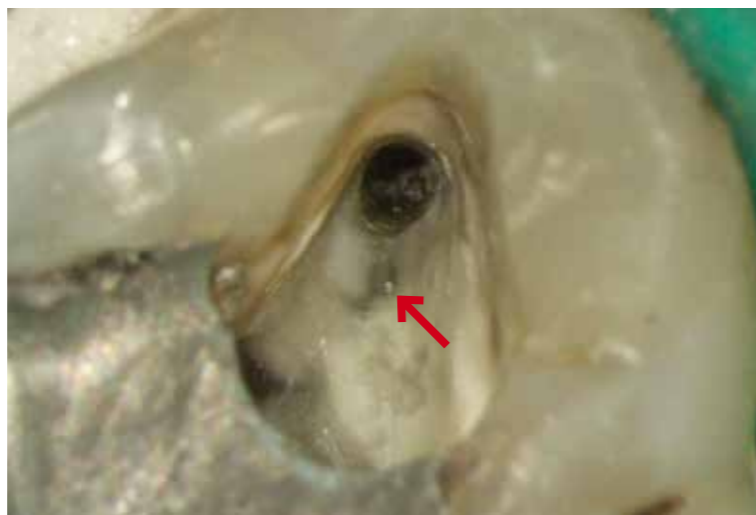

Figure 3.25a

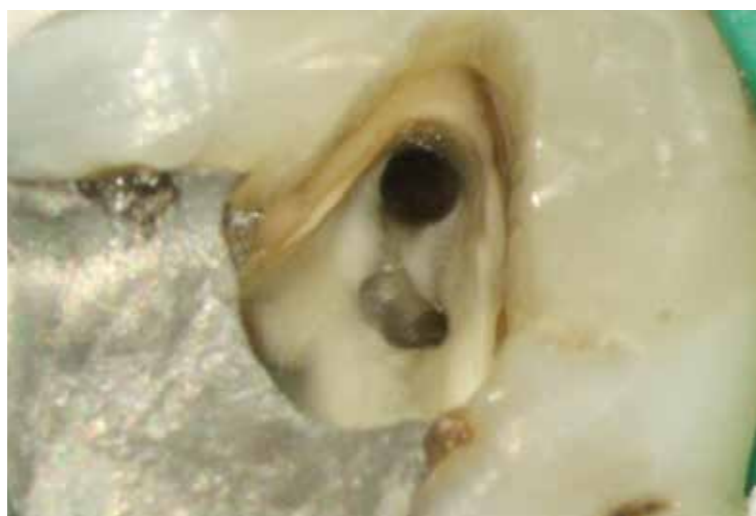

Figure 3.25b

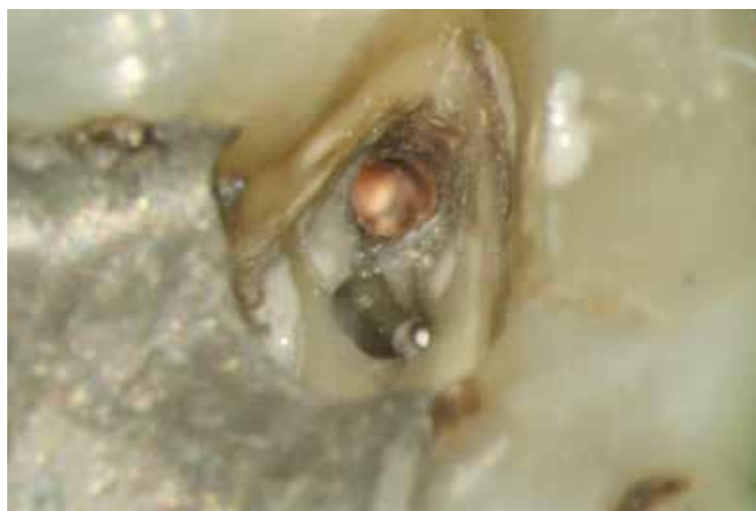

Figure 3.25c

**Calcified canals**

One of the greatest challenges in endodontics is locating canals, especially calcified canals. Canals sclerose from coronal to apical and several millimetres of sclerotic dentine may have to be removed before the canal is found. The OPMI tremendously facilitates this important part of endodontic treatment. Use medium to high magnification and maximum illumination when searching for small canals.

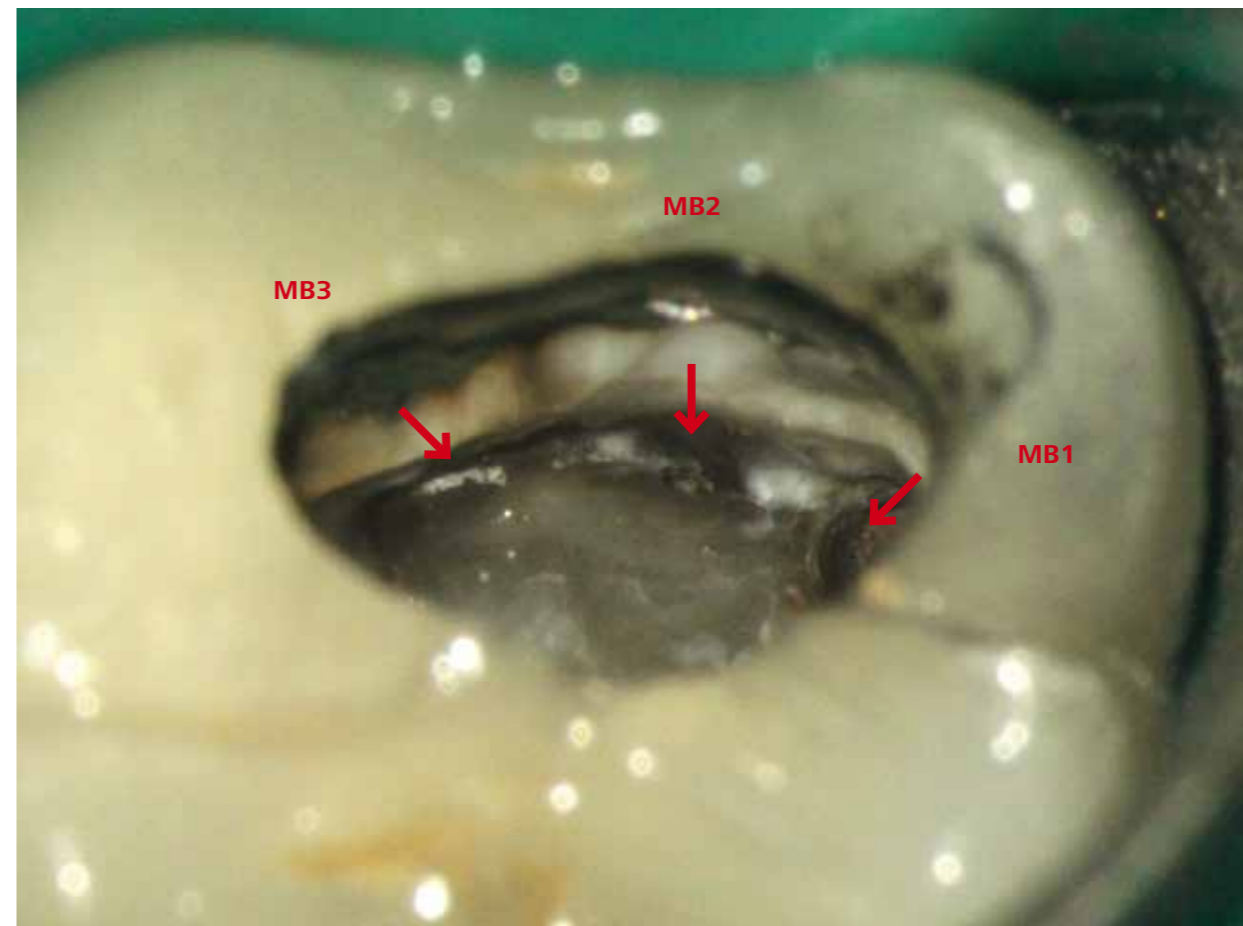


Figure 3.26a MB2 and MB3 canals identified during access cavity preparation

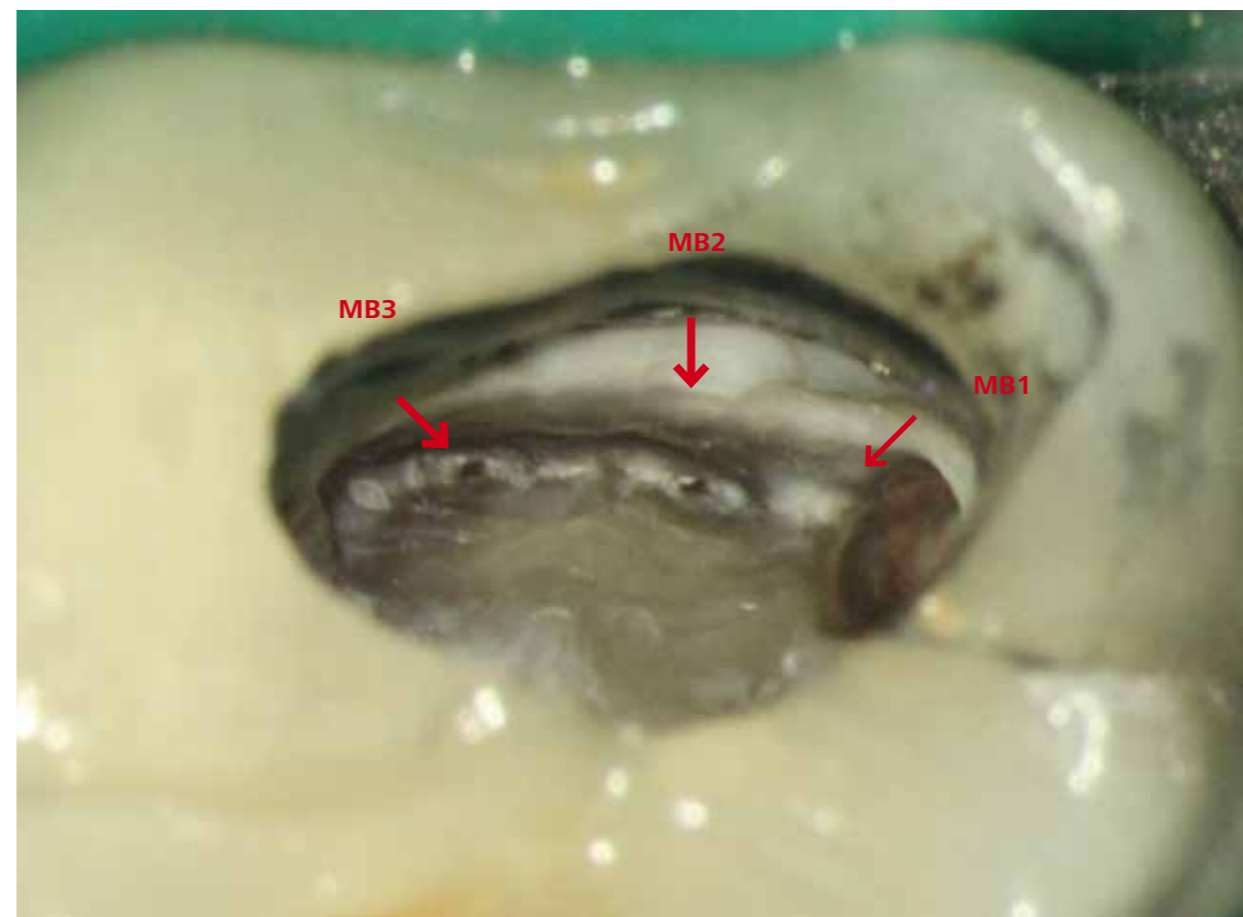


Figure 3.26b Radicular access into MB2 and MB3 canals prepared with 0.5 mm rosehead bur

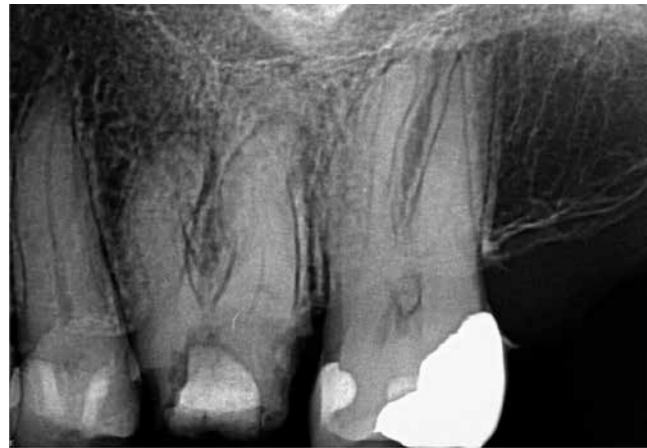

Figure 3.27a Upper left first molar with sclerosed canals, pre-operative radiograph

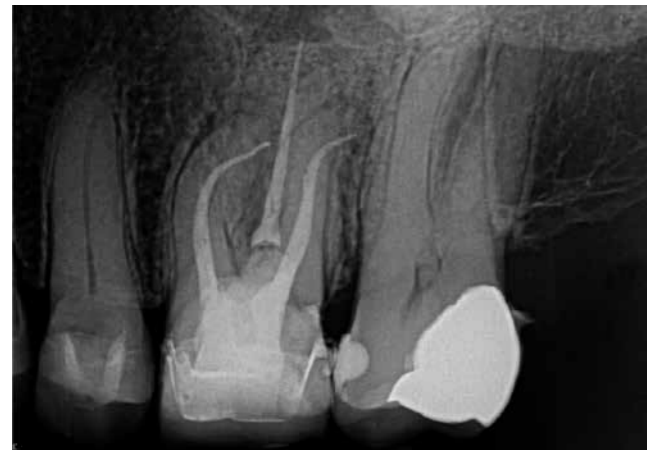

Figure 3.27b Tooth above post-operative radiograph

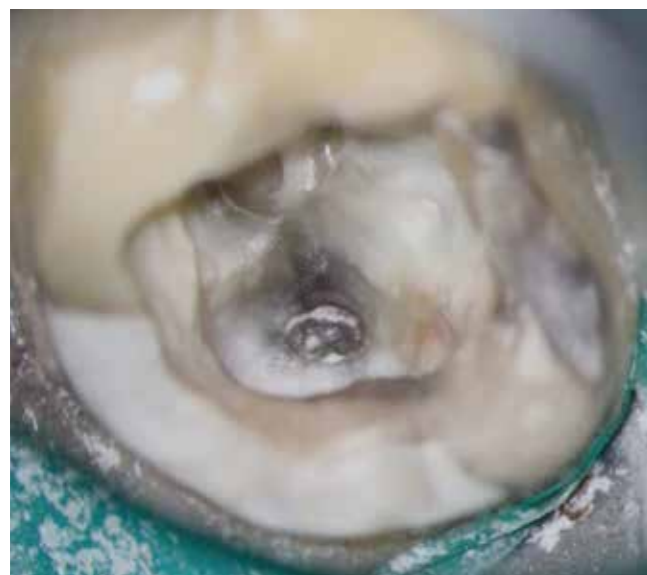

Figure 3.27c Tooth above showing sclerosed tertiary dentine in the coronal part of the palatal root canal. 4-5mm of tissue had to be removed before an entrance into the canal could be found

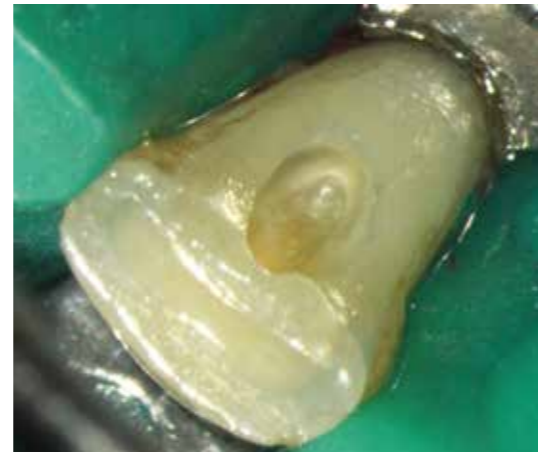

Figure 3.28a Sclerosed canal in lower incisor

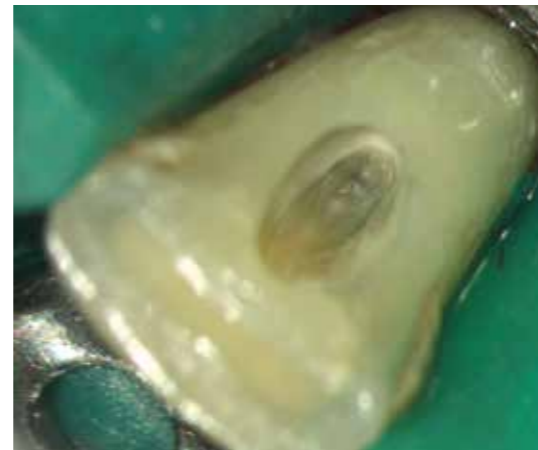


Figure 3.28b The gradual removal of tertiary dentine reveals the entrance to the canal

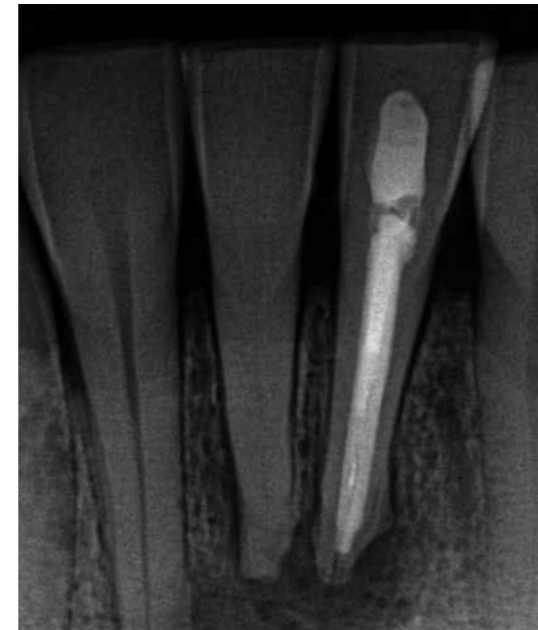



Figure 3.28c sclerosed lower right central incisor



**Evaluation and management of perforations**

The ability to visualize and determine the exact extent of a perforation helps determine treatment options and prognosis and makes it possible to repair the site.

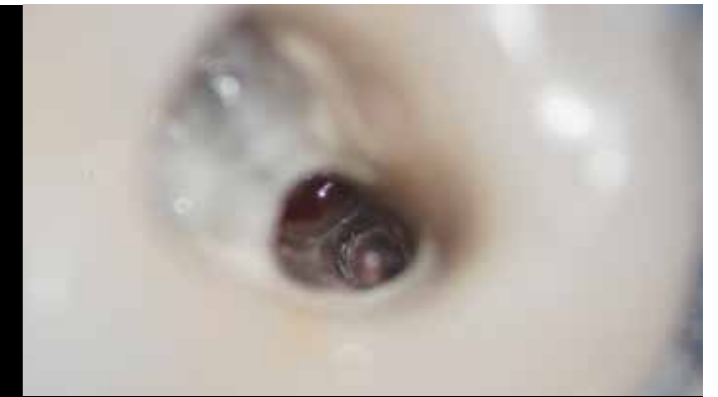

Figure 3.29a

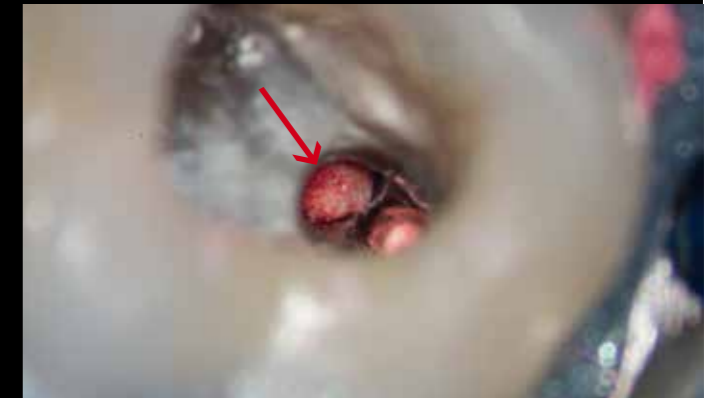

Figure 3.29b

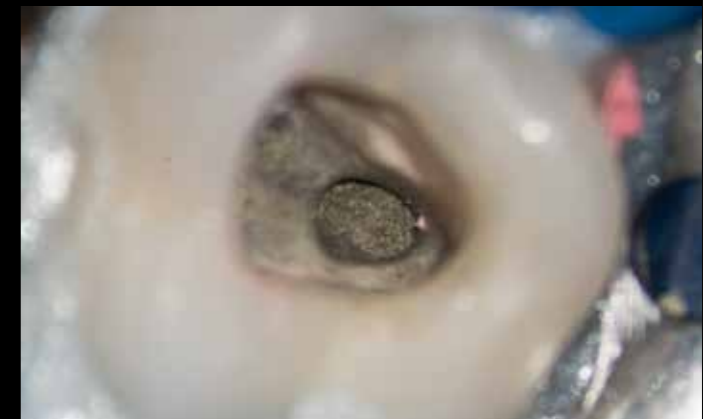

Figure 3.29c

Figure 3.29a Canal and perforation after post removal  
 Figure 3.29b Root filling and collagen matrix (indicated by arrow)  
 Figure 3.29c MTA perforation repair

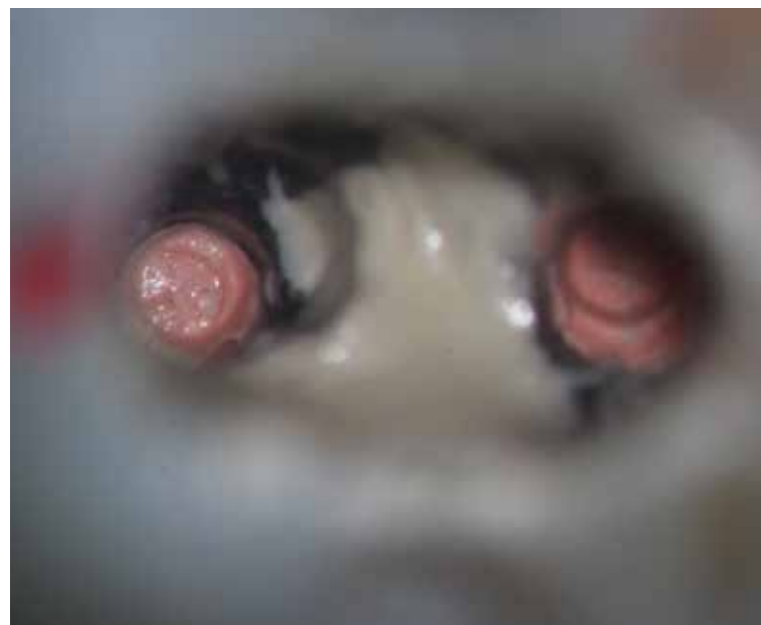

Figure 3.30 Obturation of circular canals

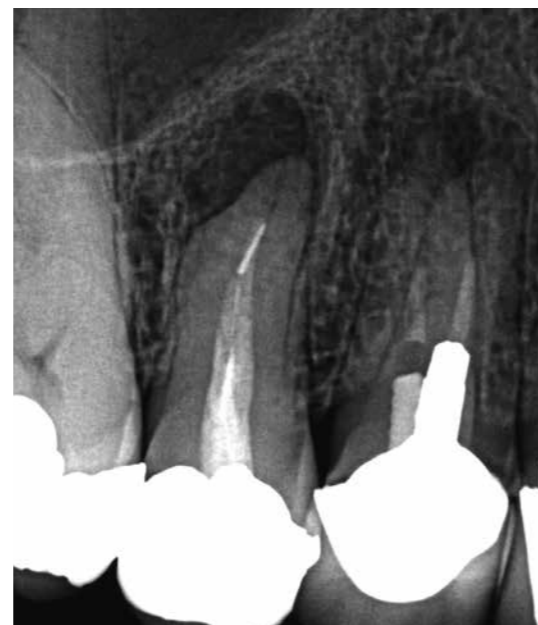

Figure 3.32a Fig Pre-operative radiograph of upper right first premolar showing metal posts

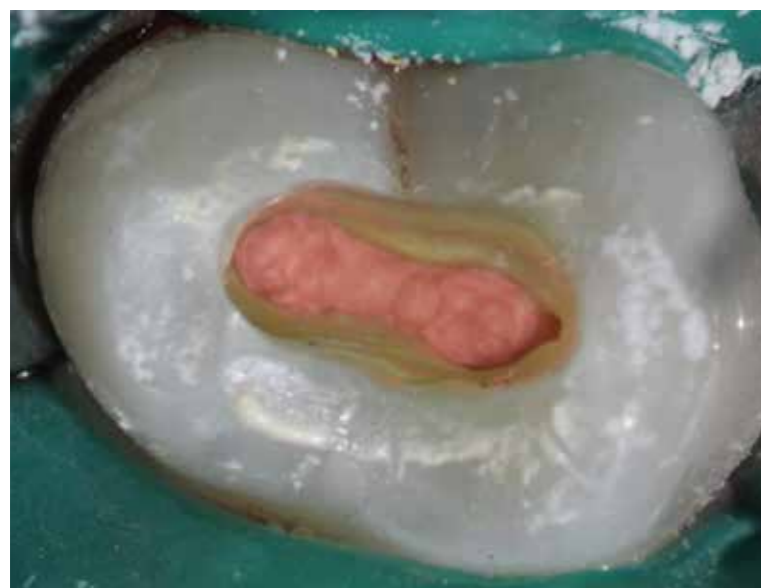

Figure 3.31 Obturation of oval canal

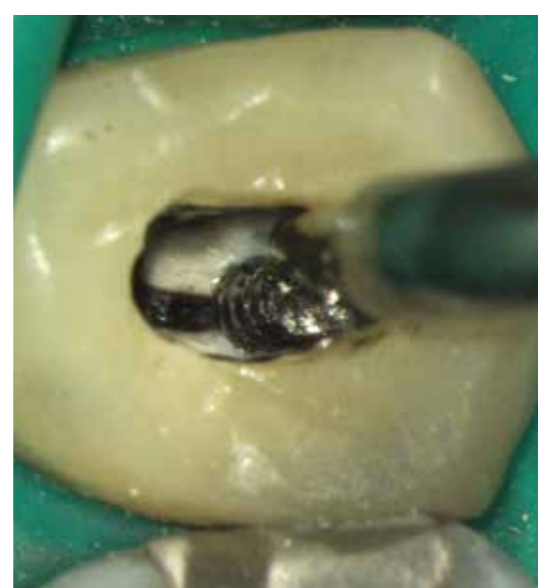


Figure 3.32b Intracoronary removal of the post and core while retaining the crown. The post is being removed with ultrasonics

**Obturation of the canal**

Most canals are not circular in cross section and obturating them under the control of the OPMI ensures that the canals are filled with the root filling material in all dimensions.

**Non-surgical re-treatment**

Endodontic re-treatment is considered to be one of the most challenging procedures in endodontics. In these situations the OPMI is essential.

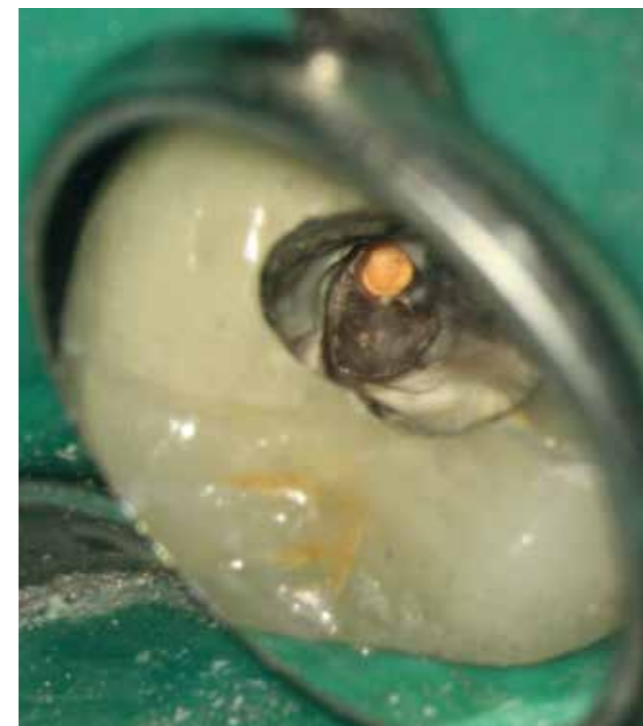

Figure 3.33a Pulp stone in the palatal canal adjacent to the root filling

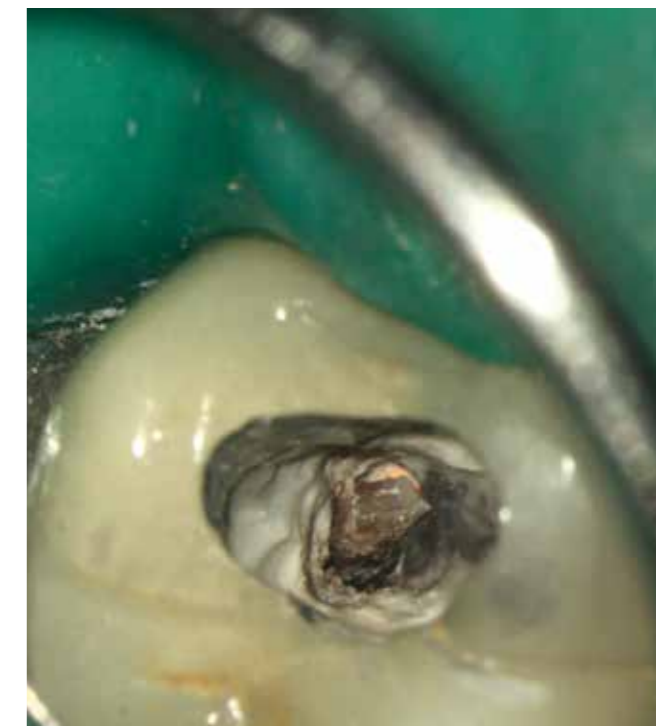

Figure 3.33b Pulp stone partially removed from canal

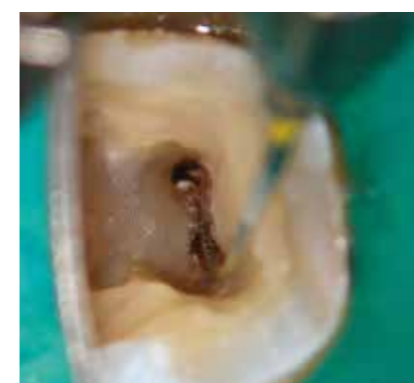

Figure 3.34 Removal of tissue from the isthmus between the mesial canals of a lower molar using ultrasonically energised K-files



Figure 3.35 Failed root treatment where the floor of the pulp chamber has not been exposed

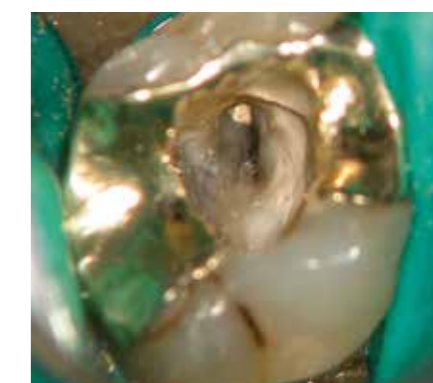


Figure 3.36 MB2 canal has been missed

**Uses of the OPMI in non-surgical re-treatment:**

- removal of existing restorations, posts and core materials (especially useful for removal of composite cores)
- location of missed canals
- removal of existing root filling materials
- evaluation of the condition of the canals after removal of root filling materials
- removal of necrotic tissue and residual root filling materials after re-preparation of the root canals
- evaluation of the canal walls for cracks
- overcoming ledges and blockages
- removing fractured instruments
- evaluation and repair of perforations

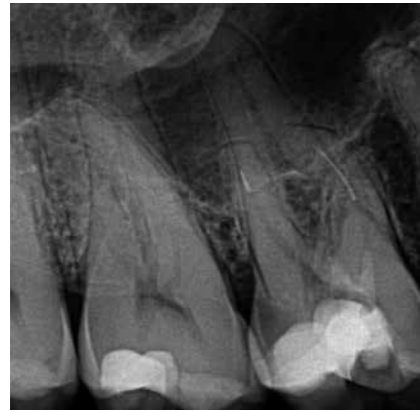

Figure 3.37a Pre-operative radiograph of upper right first molar tooth with two fractured instruments

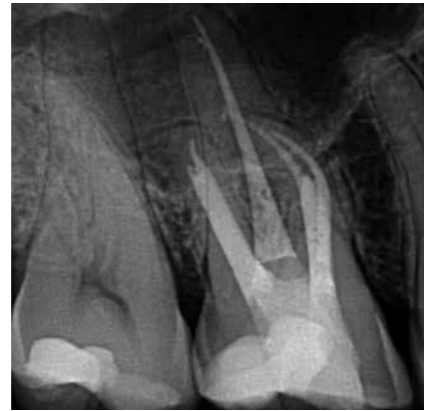

Figure 3.37b Post-operative radiograph of the same tooth with the instruments removed using ultrasonic instruments controlled under the OPMI. Note that the canals were curved in a bucco-palatal direction.

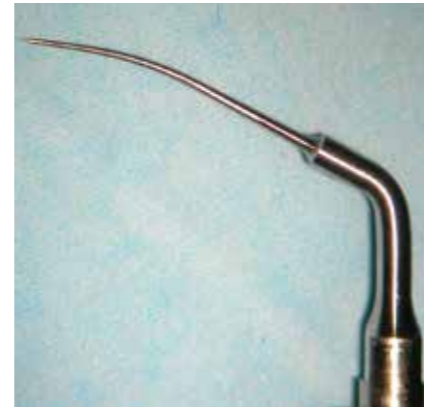

Figure 3.37c Endo Success ET 25 ultrasonic tip has been pre-curved to improve visual access for the removal of fractured instruments

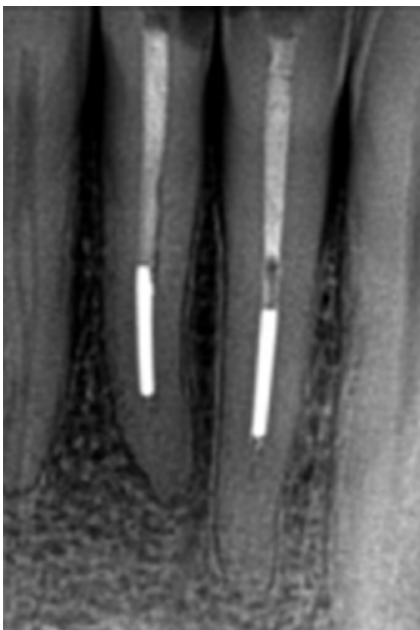


Figure 3.38a Pre-operative radiograph of two lower incisors with apically placed silver point root fillings

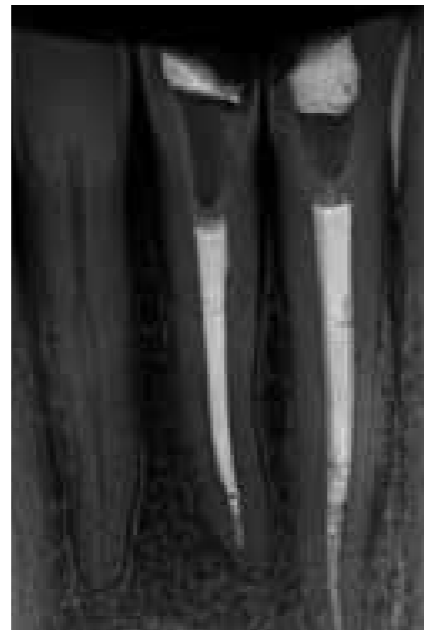

Figure 3.38b Post-operative radiograph of lower incisors with silver points removed



Figure 3.38c The OPMI was used to position and engage two Hedstrom files around the silver points

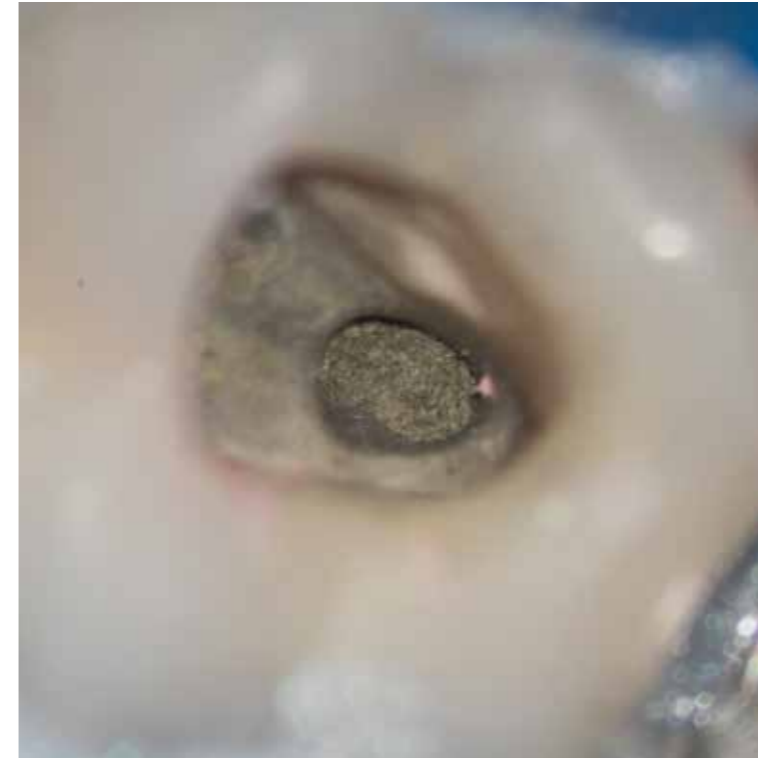


Figure 3.39 apical plug with MTA

### Apical plug with MTA

MTA is an excellent material for repairing perforations and sealing large apical foramina. The material can be placed with a great deal of control when using the OPMI to ensure that there are no voids (Figure 3.36).



Figure 3.40 a distorted rotary file viewed at high magnification under the OPMI

### File evaluation

Evaluation of stainless steel hand and NiTi rotary files under magnification and enhanced illumination is an excellent and quick way to determine if files are weakening and are at risk of separating. The dentist should look for overwound file flutes (flutes too close to each other) or unwinding flutes (the space between the flutes increases, which makes it appear shiny under enhanced lighting). Identifying this helps reduce the chance of file separation. It is much easier to identify these weak points in a file under magnification.



## Endodontic root-end surgery

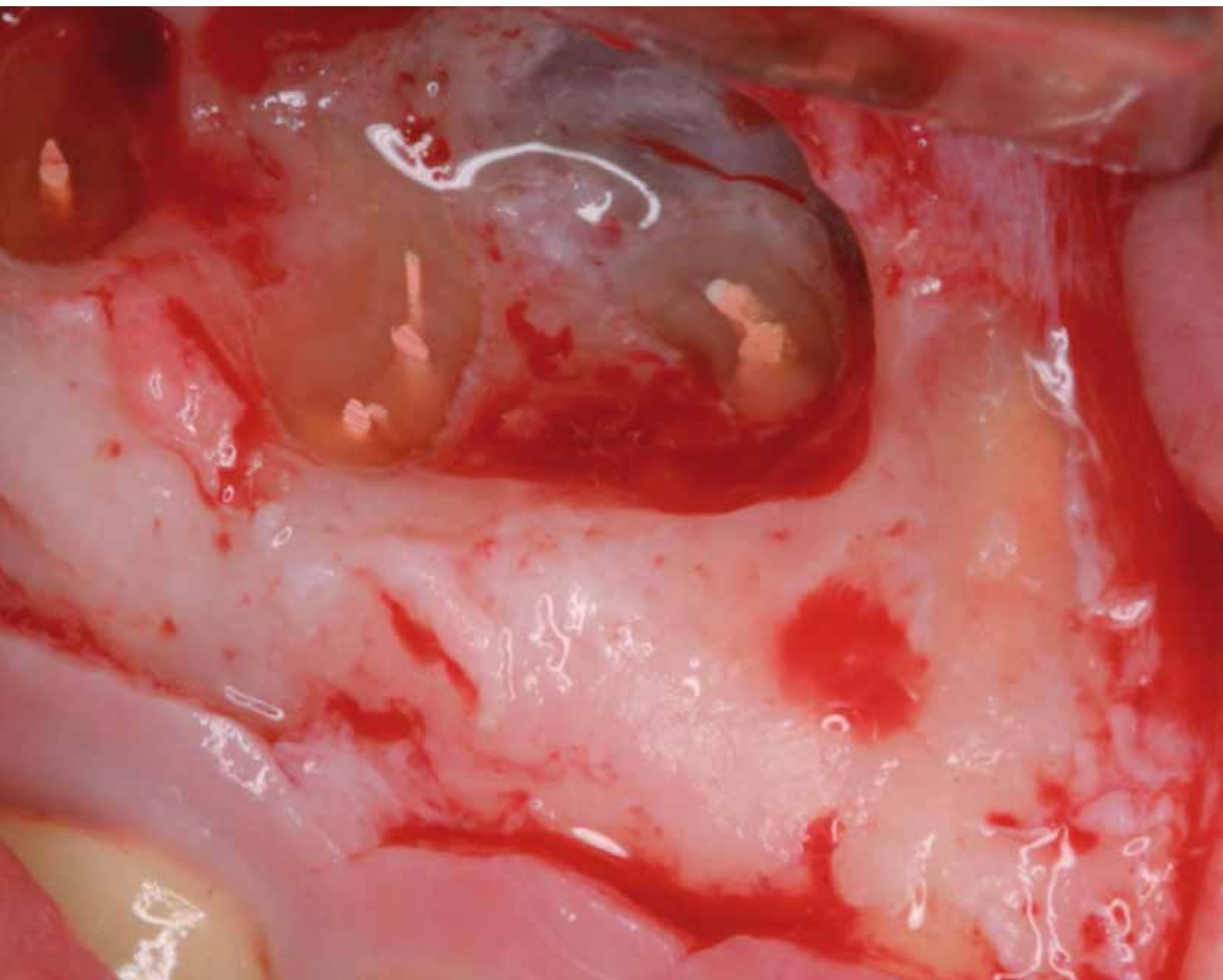


Figure 3.41a After root-end resection, isthmuses can be visualized under the optical magnification

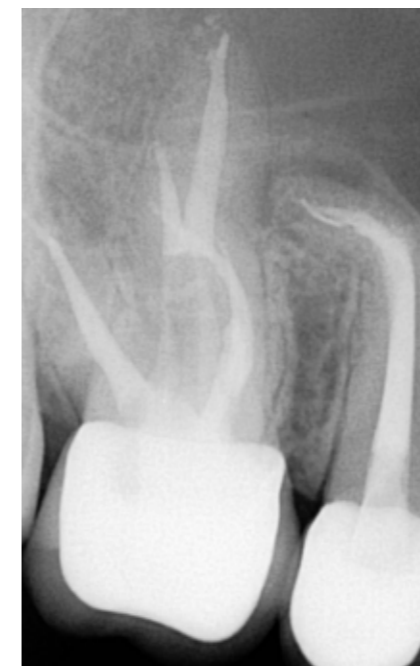

Figure 3.41b Complex anatomy of root canal system

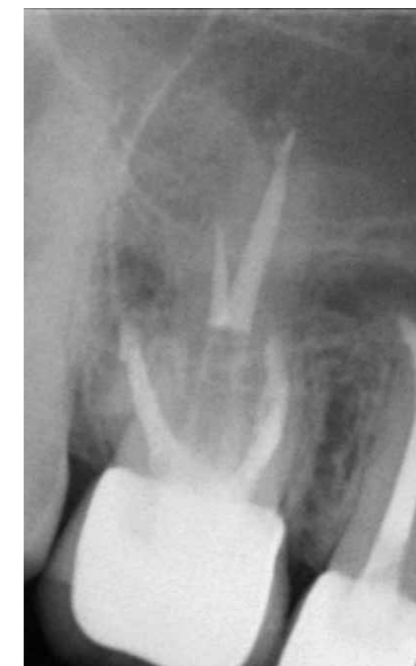
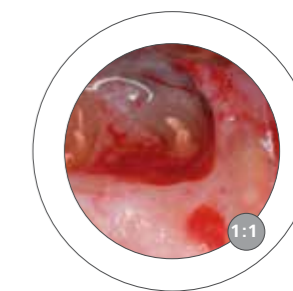
Figure 3.41c X-ray after surgery



Thanks to the improved visualization provided by the OPMI along with microsurgical instruments, this procedure can be performed much more conservatively. For instance, the amount of apical bone removal/osteotomy size does not need to be large when using the OPMI. Hence, the procedure could be considered as minimally invasive.

- The smaller apical osteotomy / access improves hard-tissue healing and success rates.
- The OPMI enables the dentist to locate isthmuses (often infected) joining adjacent canals (ie isthmus between MB1 and MB2 in maxillary molars or MB and ML canals in lower molars)
- The OPMI enables the identification of fractured instruments at the root apex.

- Using an OPMI enables the dentist to diagnose/locate root-end microfractures.
- Root-end canal preparation can be done more precisely and conservatively with use of micro-ultrasonic tips made specifically for surgery. For this, one should use high magnification and high illumination.
- Flaps are improved with the ability to make incisions more precisely with micro-scalpels.
- Suturing under the OPMI should be more precise and less traumatic. This is made possible since very fine sutures (i.e. 6-0) could be better visualized under the OPMI. This is especially important in the aesthetic area.

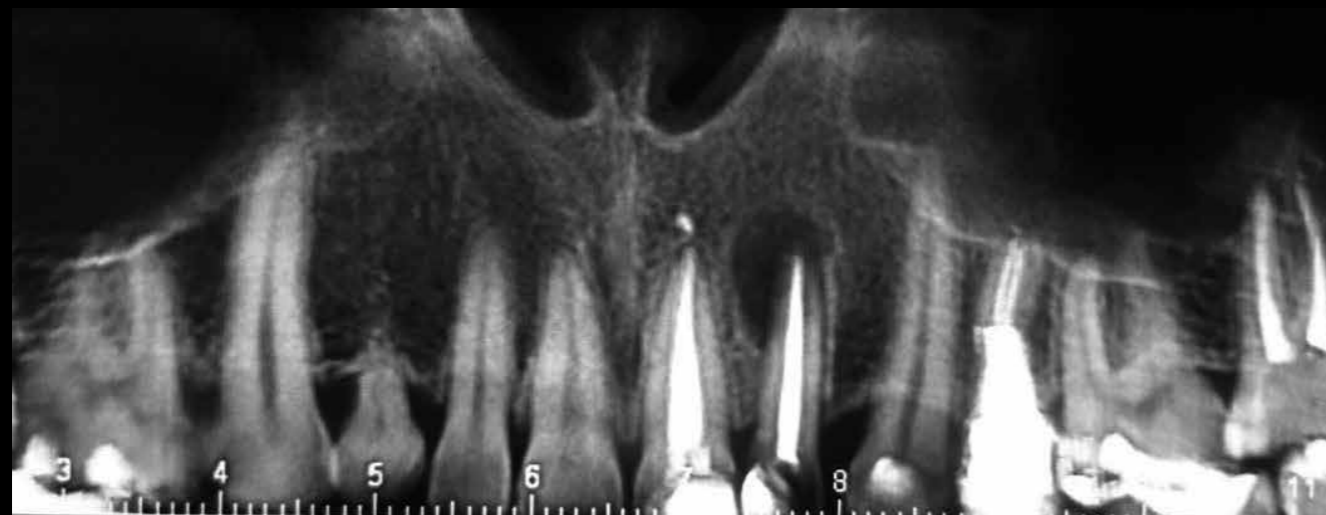

Figure 3.42 Periapical lesions in 21 22 (computer tomography)

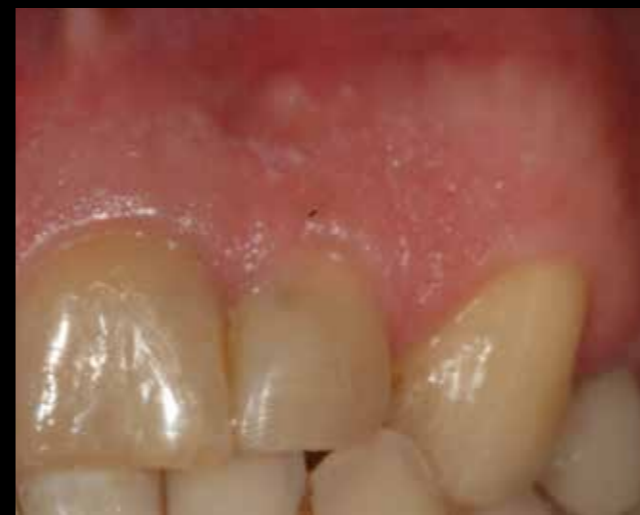

Figure 3.43 Fistula in 22 area

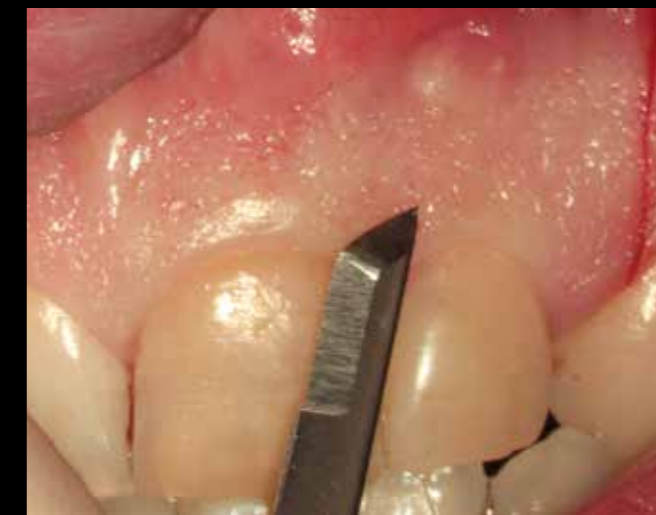

Figure 3.44 Micro-scalpel for atraumatic incision with tissue preservation

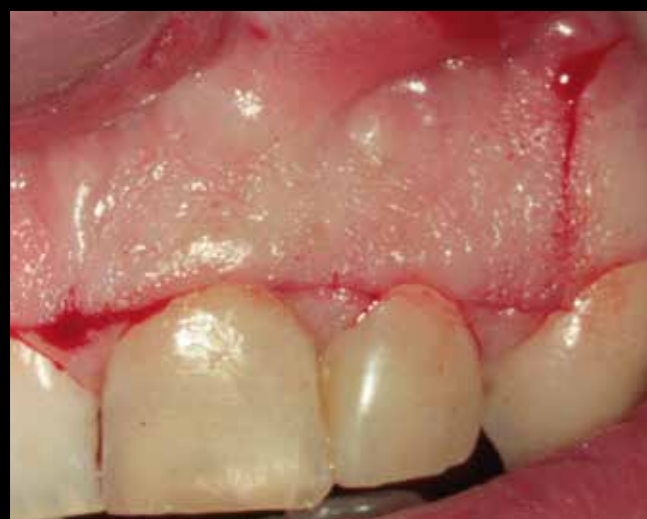

Figure 3.45 Incision line

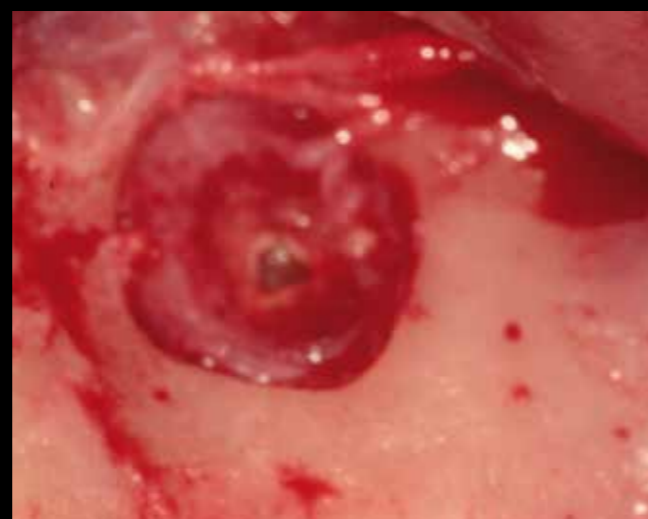

Figure 3.46 Intrabony defect found after flap elevation

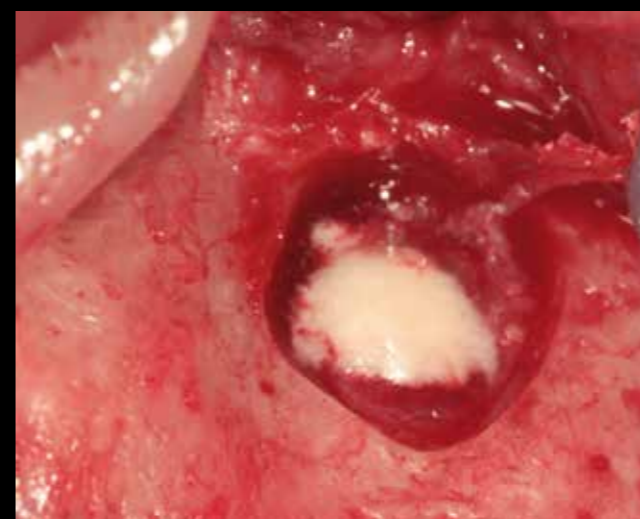

Figure 3.47 Purulent discharge

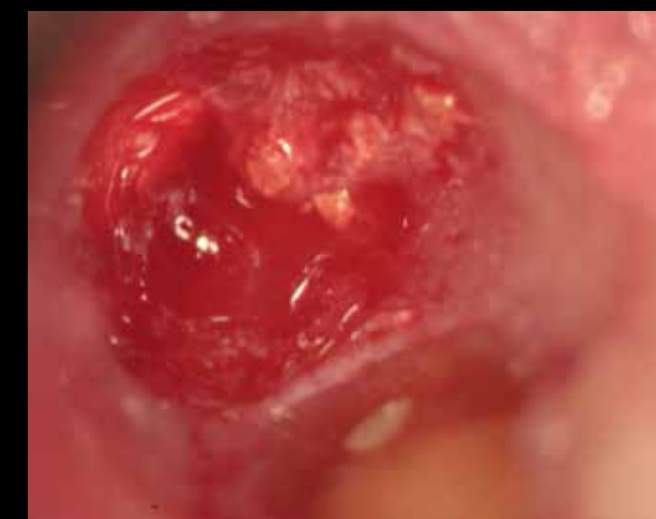

Figure 3.48 Maxillary left lateral incisor apicoectomy (after enucleation of lesion)

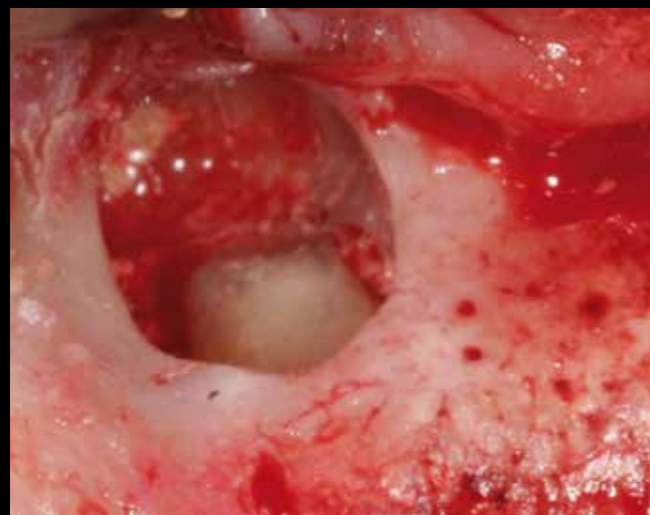


Figure 3.49 Checking with micro mirror

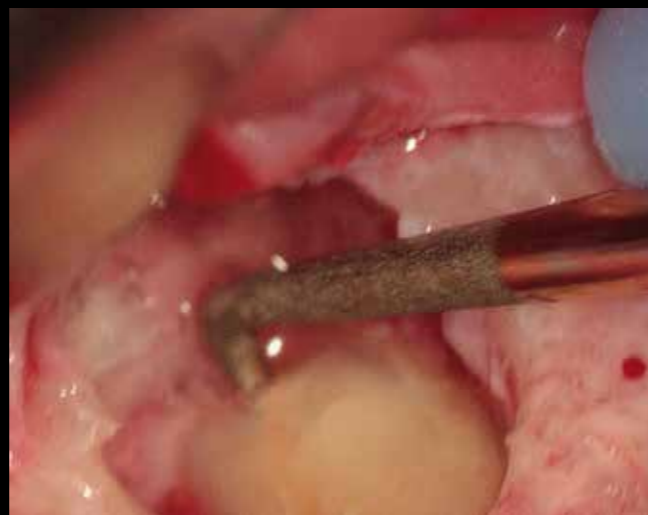

Figure 3.50 Ultrasonic instrumentation

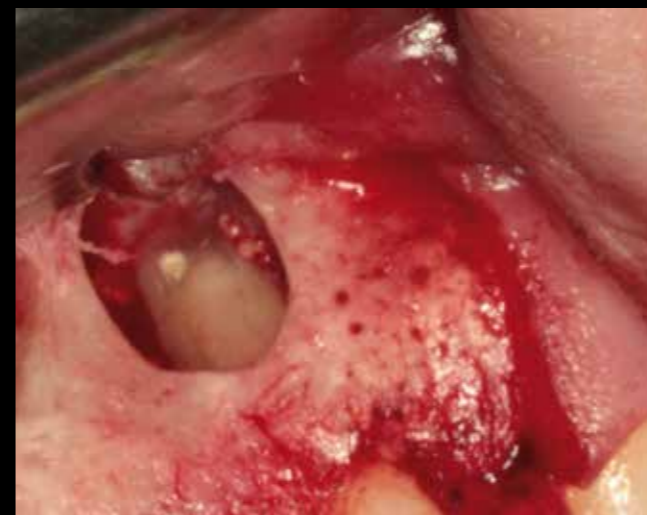

Figure 3.51 Obturation of the canal by MTA ProRoot

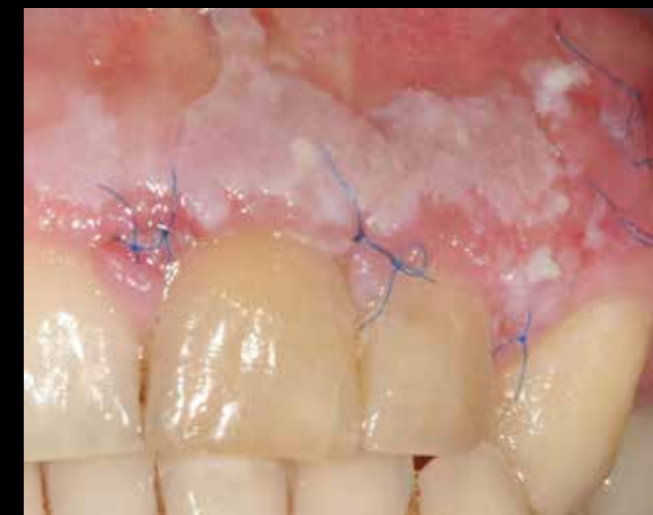

Figure 3.52 Suturing the wound and 3 days after surgery. Note debris over mucoae due to heavy smoking

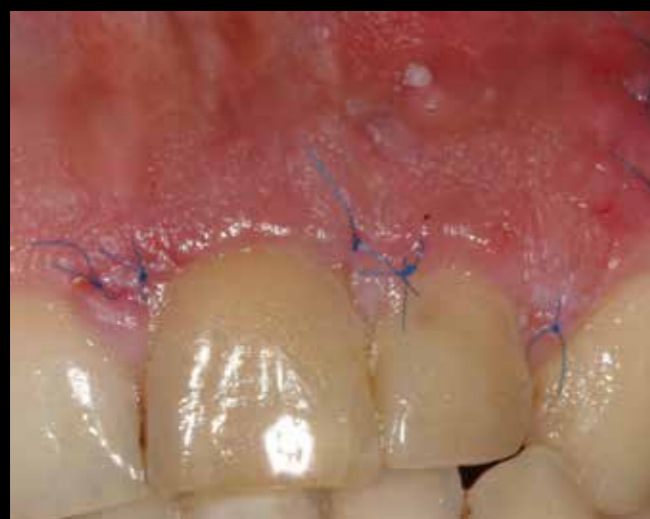

Figure 3.53 First intention healing is a fast healing process of a small wound because of atraumatic re-approximation of the incision edges

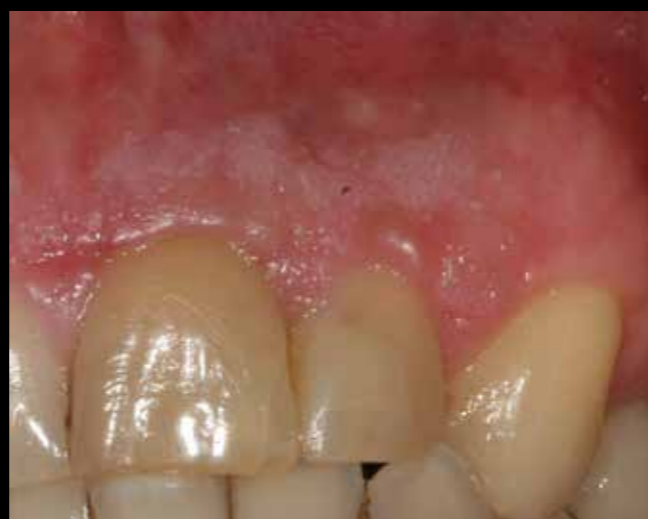

Figure 3.54 7 days after surgery

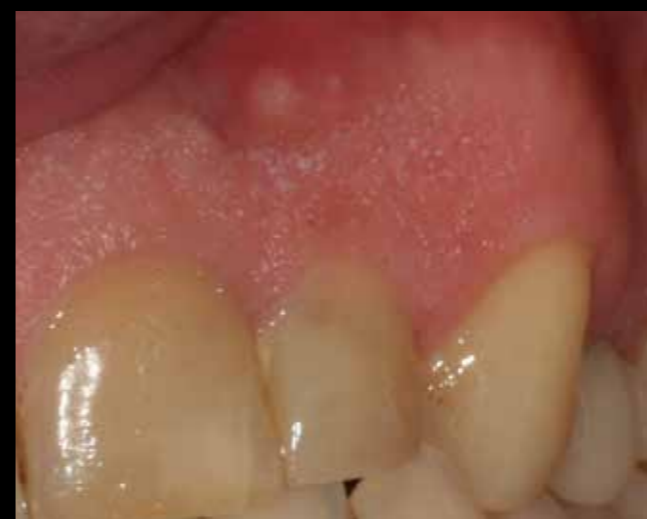

Figure 3.55 1 year after surgery

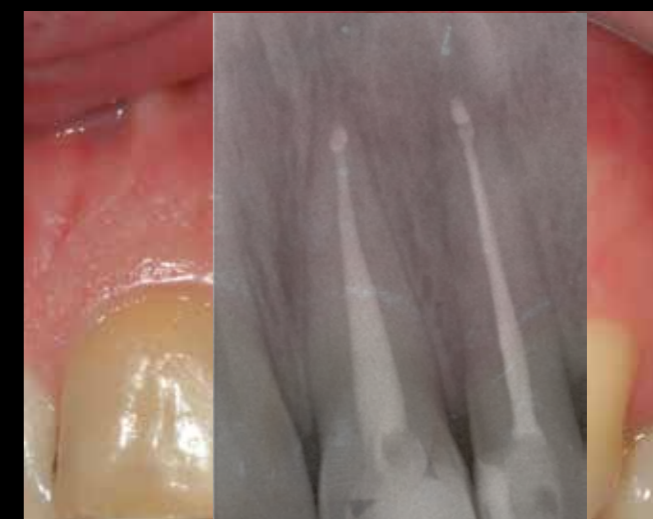

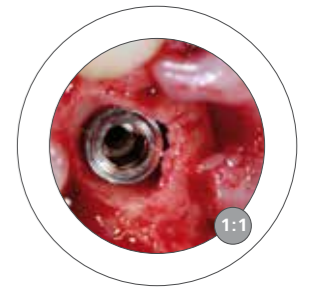
Figure 3.56 X-ray after 1 year

# 4

## 4 OPMI in periodontology and implantology

Authors: **Dr. Kristina Badalyan &  
Dr. Rino Burkhardt**

- 105 **Do we need an OPMI in periodontal and implant therapy?**
- 106 **What are the advantages and disadvantages of the use of an OPMI in periodontology and implantology?**
- 110 **What does the "microsurgical concept" consist of?**
- 122 **Which are the first steps to getting used to working with the OPMI?**
- 126 **How can you acquire expertise in periodontal and peri-implant microsurgery?**
- 128 **Which are the common errors in the use of the OPMI in surgical practice?**
- 130 **References**



## Do we need an OPMI in periodontal and implant therapy?

Undoubtedly, microscopic enhanced periodontal and implant therapies have reshaped clinical practice and created a potential for higher standard of care. Throughout the world, the benefits of the OPMI in these specialties are clearly evident from the positive feedback from clinicians and patients alike. Additionally, the advantages are supported by several high ranking clinical studies in the evidence hierarchy.

Despite the positive results in prospective comparative studies, the OPMI is experiencing a slow acceptance in the periodontology and implantology specialties.

What then can be the reason for the delay in taking advantage of such microsurgically modified therapies? The main reason is that most of the surgeons do not adapt to the use of the OPMI and those who have been using OPMI's successfully, have not made adequate in-depth practical recommendations to help other colleagues to overcome their initial problems. Working with magnification requires the clinician to adjust to a small field of view and learning to look in one direction whilst the hands are working in another direction. Additionally, the minimal size of tissue structures and suture threads requires a guidance of movements by

visual rather than tactile control. This altered clinical situation, combined with the impaired manoeuvrability of the OPMI, requires a process of readjustment by the surgeon, which in turn can only be achieved by the appropriate training.

It is the aim of the chapter

- to describe the use of the OPMI in periodontology and implantology for diagnostic as well as therapeutic reasons
- to list the benefits of an OPMI-enhanced treatment for patients and clinicians
- to give practical recommendations for beginners and those who are interested in working with magnifying eyeglasses to encourage clinicians to take advantage of the use of an OPMI in daily clinical practice.

Figure 4.1

## What are the advantages and disadvantages of the use of an OPMI in periodontology and implantology?

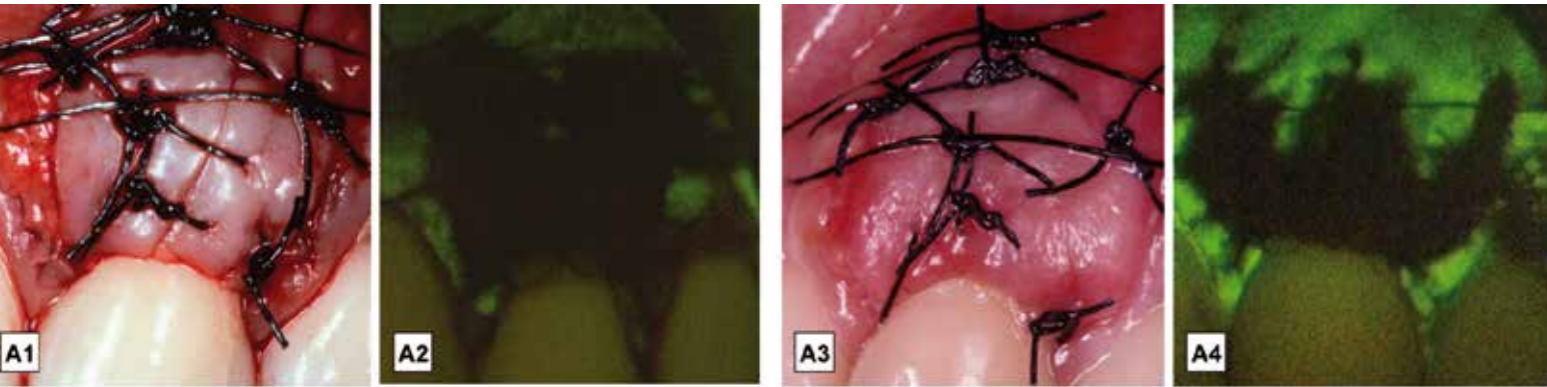


Figure 4.2  
Recession coverage: Macro- and microsurgery in comparison\*  
Macrosurgical recession coverage (A). A1) immediately after the surgical intervention, A2) corresponding angiographic evaluation after the intervention, A3) healing after 7 days, A4) angiographic evaluation after 7 days

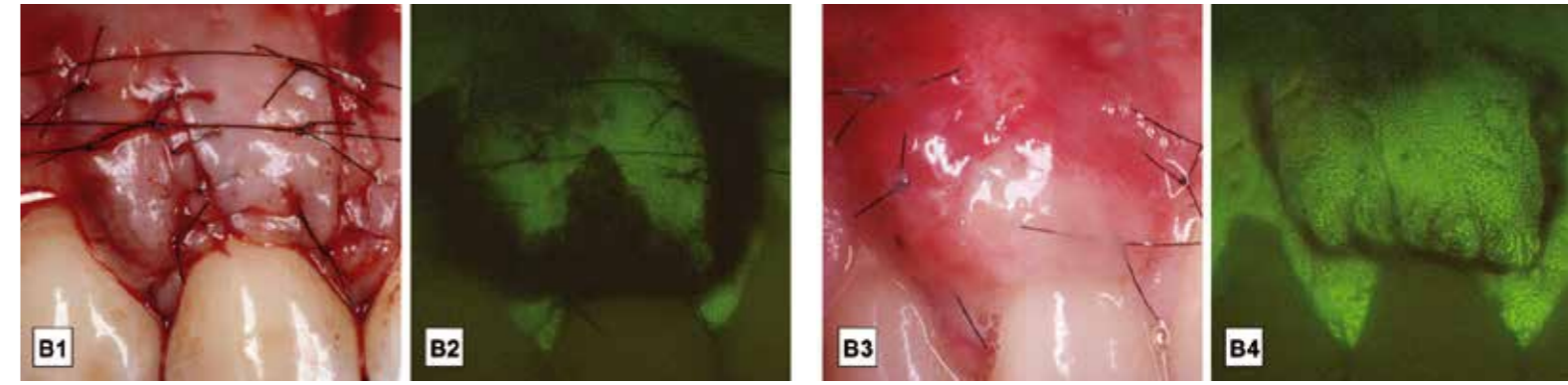


Figure 4.3  
Microsurgical recession coverage (B). B1) immediately after the surgical intervention, B2) corresponding angiographic evaluation after the intervention, B3) healing after 7 days, B4) angiographic evaluation after 7 days

To ensure proper diagnosis and treatment planning which are fundamental requirements in all kinds of periodontal and implant therapies, the required information must be obtained by clinical examination and additional appropriate image-guided diagnostics. Regarding the former we can only record what we see. Accordingly, the better we see, the more precise our data for the diagnostic result will be.

In a recent experiment the use of an OPMI enabled dentists to find a greater number of defects than with either magnifying loupes or the naked eye. Additionally, the OPMI users profited most from an ergonomic posture and did not report any neck or back pain. This comparative study clearly demonstrated the beneficial effects of using an OPMI as a diagnostic tool. It may be of value in the location and visualization of a variety of substances and defects. These include, for example the detection of subgingival calculus

and biofilm, the evaluation of furcation entries of molars, the recording of root surface characteristics (enamel pearls, concavities, grooves) and many other findings which are essential for a proper diagnosis.

Another enormous advantage of an OPMI-supported approach in periodontology relates to the enhanced visual acuity associated with magnification and illumination while performing clinical interventions such as defect debridement, root planing or any other surgical procedure which requires a controlled manipulation of the delicate oral soft tissues.

A microsurgical approach improves tissue preservation and handling while using specific flap designs to access the defects. It optimizes flap mobility in order to achieve primary closure or to cover mucosal recession, and it reduces the trauma caused to the tissues by enabling the use of smaller

suture diameters. The latter is not only less traumatic, but also reduces the tension which can be applied to the tissue margins during wound closure. However, finer threads are more prone to breakage than thicker ones and may rupture before tissues are torn.

These advantages are especially useful when dealing with fragile tissues with a limited vascular network such as the interdental mucosa. The use of an OPMI greatly improves the surgical access to interdental or interimplant spaces. These delicate and narrow soft tissues can be sharply dissected and preserved using microblades with the aid of clear magnified vision, thus reducing trauma and facilitating accurate wound closure (Figure 4.4). It is generally recognized that wound healing is improved in a sealed environment with minimal levels of bacterial contamination and optimal stability of the wound margins.

It has been shown that the incidence and severity of complications and pain following periodontal surgery are correlated well with the duration of the surgical procedure, an argument used by opponents of periodontal and peri-implant microsurgery.

Studies comparing micro- and macrosurgical approaches show no difference in this respect.

In view of this situation, there are no clinical contraindications for the use of an OPMI in periodontal and implant surgery, for diagnostic as well as

therapeutic purposes. From a practical point of view, there are a few areas of the oral cavity which may be difficult to access with an OPMI, limiting its application. Under these circumstances and in surgical interventions which require a frequent change of position, the use of loupes may be preferable.

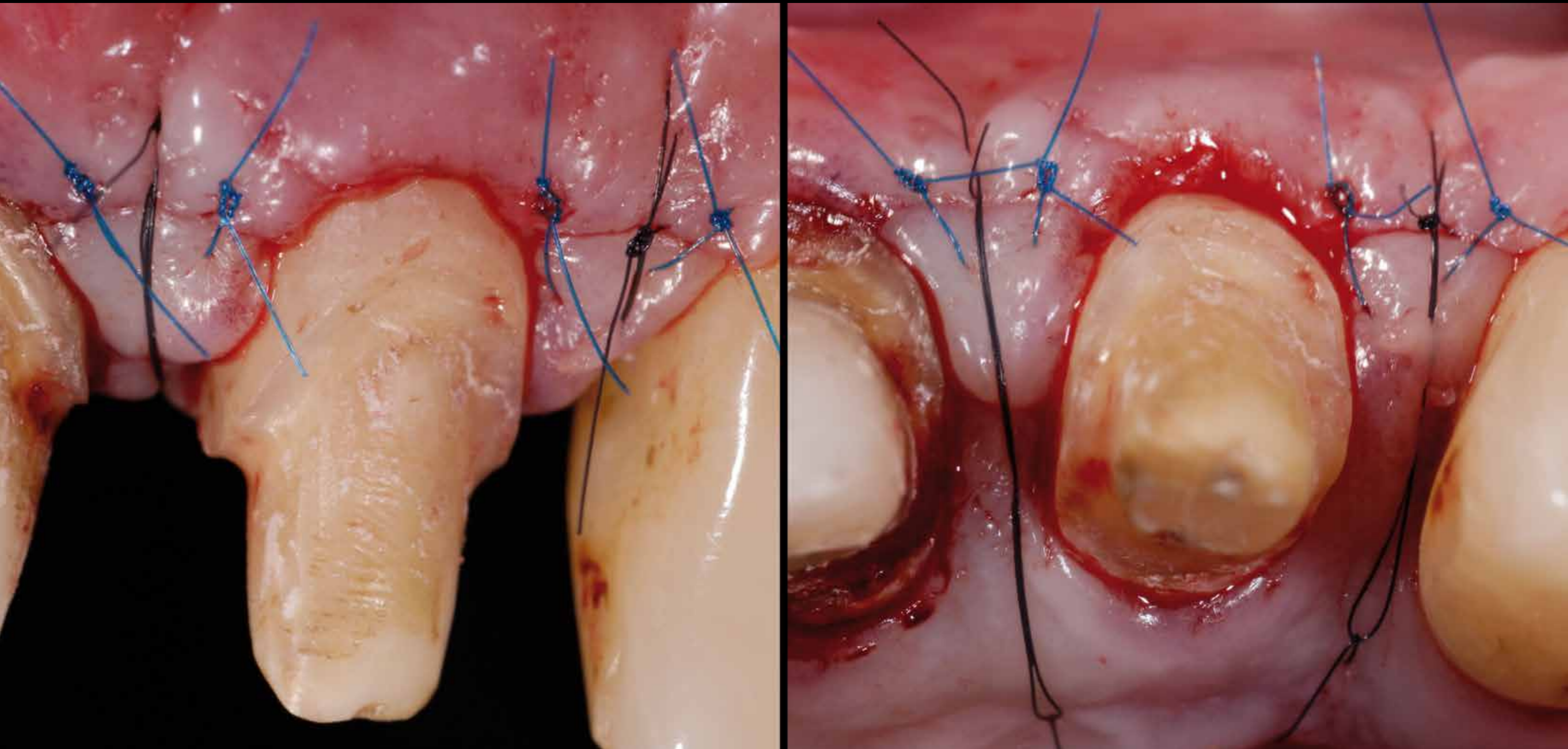
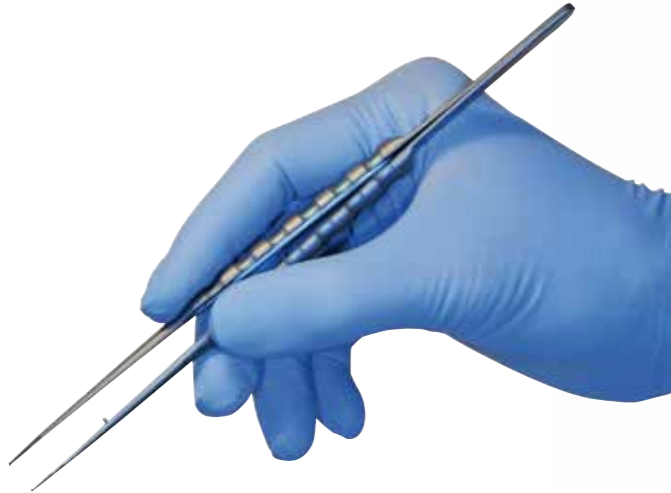

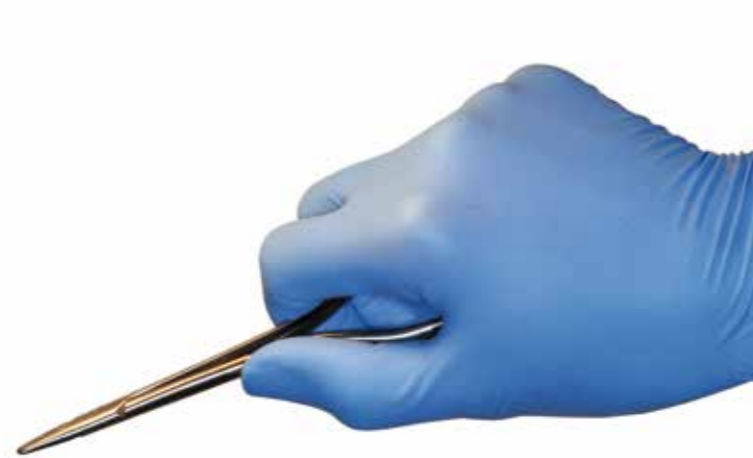Figure 4.4  
 Left: Buccal view of primary wound closure with fine suture threads after modified papilla preservation flap  
 Right: Occlusal view of the same site. Note the intact mucosal surface of the delicate col area

## What does the “microsurgical concept” consist of?

**Correct instrument handling**



**Incorrect instrument handling**



*Figure 4.5*

*Left: Microsurgical instrument which can be precisely rotated by the thumb, index and middle finger*

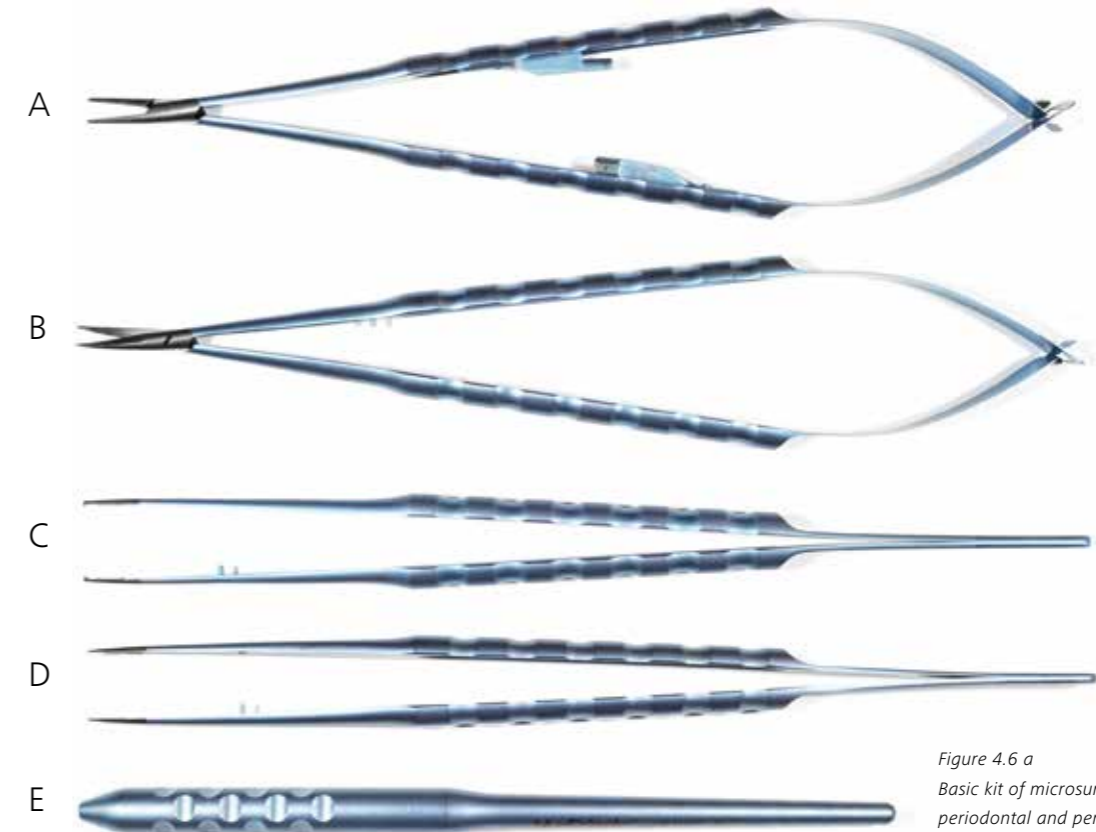*Right: Conventional instrument without rounded handle. Its rotation can only be performed by turning the wrist, which is a less precise movement*

The ongoing development of OPMI, the refinement of surgical instruments, the production of improved suture materials and the emergence of suitable training laboratories have played a decisive role in the worldwide establishment of microsurgical techniques. The three elements, magnification, illumination and instrumentation, are called the microsurgical triad, the combined use of which is the prerequisite for improved accuracy in surgical interventions. Without any of these, microsurgery is not possible. The first two have already been described at the beginning of this book, so let us now focus directly on the instruments.

### Technical aspects of instruments

Proper instrumentation is of fundamental importance for a microsurgical intervention. While various manufacturers have sets of microsurgical instruments, they are generally designed for vascular and

neurosurgery and are therefore, inappropriate for the use in periodontal and implant plastic surgery. As the instruments are primarily manipulated by the thumb, index and middle fingers, their handles should be rounded, yet provide traction so that finely controlled rotating movements can be executed. The rotating movement of the hand from two o'clock to seven o'clock (for right-handed persons) is the most precise movement that the human body is able to perform. The instruments should be approximately 18 cm long and lie on the saddle between the operator's thumb and the index finger and simultaneously be slightly top-heavy to facilitate accurate handling (Figure 4.5). In order to avoid unfavorable metallic glare under the OPMI illumination, the instruments often have a coloured coating surface. The weight of each instrument should not exceed 15 g to 20 g (0.15- 0.20 N) in order to avoid hand and arm muscle fatigue. The needle holder should be equipped with



*Figure 4.6 a*

*Basic kit of microsurgical instruments for periodontal and peri-implant surgery: A) needle holder, B) scissor, C) surgical forceps, D) anatomical forceps and E) blade holder*

a precise lock that features a locking force of no more than 50 g (0.5 N). High locking forces generate tremor, and low locking forces reduce the security of the lock. Appropriate sets of steel or titanium instruments for periodontal surgery are available from different manufacturers.

A basic set comprises a needle holder, micro-scissors, micro-scalpel holder, anatomical and surgical forceps and a set of various elevators (Figure 4.6a - 4.6b). In order to avoid sliding of the thread when tying the knot, the tips of the forceps have flat surfaces or can be finely coated with a diamond grain that improves the grip by which the needle holder holds a surgical needle. The configuration of the needle holder jaw has considerable influence on needle holding security. The presence of teeth in the tungsten carbide inserts provides the greatest resistance to either twisting or rotation of the needle

between the needle holder jaws. This benefit must be weighted against the potential damaging effects of the teeth on suture material. Smooth jaws without teeth cause no demonstrable damage to 6-0 monofilament nylon sutures, whereas needle holder jaws with teeth (7000/sq.in) markedly reduced the suture breaking strength. Additionally, the sharp outer edges of the needle holder jaws must be rounded to avoid breakage of fine suture materials. When the needle holder jaws are closed, no light must pass through the tips. Locks aid in the execution of controlled rotation movements on the instrument handles without pressure. The tips of the forceps should be approximately 1 mm to 2 mm apart,


*Figure 4.6b*

*Rounded handle of the blade holder allows a finely rotating movement of the fingers and precise guidance of the surgical microblade*

when the instrument lies in the hand without any pressure. Before purchasing a set of microsurgical instruments, appropriate time should be allowed for selection and clinical testing. Ill-fitted, imprecise or damaged instruments will negatively influence the performance and make a microsurgical procedure almost impossible. It is recommended to choose an instrument brand from a company which is already familiar with the production of dental or oral surgical instruments. These manufacturers are more likely to be familiar with the typical aspects of an intra-oral mucosal surgery and incorporate the above-mentioned instrument characteristics in their production (Hu-Friedy, Chicago, USA). Such basic instrument kits can be recommended for all kinds of periodontal and implant surgical interventions.







A Macrosurgical blade, No 15

B Macrosurgical blade, No 15c

C Periodontal microblade straight

D Periodontal microblade curved

Figure 4.7  
Macro- and microsurgical scalpel types from different manufacturers (A & B Swann Morton Ltd., Sheffield, UK; C & D Sharpoint™ by ©Angiotech, Inc., Vancouver, BC, Canada)

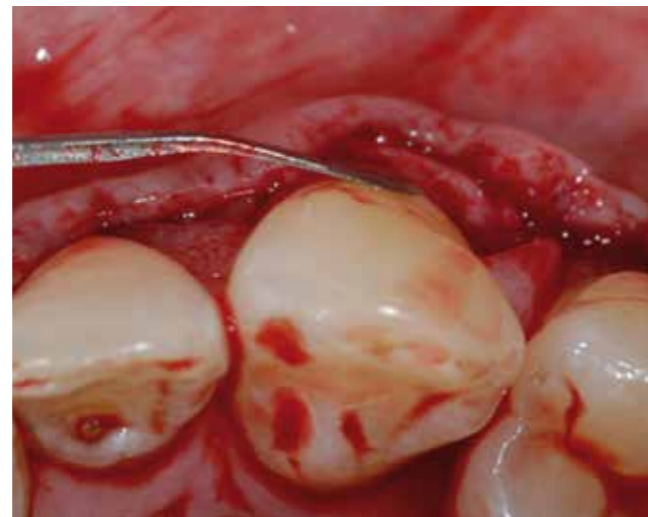

Figure 4.8 Clinical situation represents the preparation of the buccal mucosa in the area of the root prominence. Note the specific curved shaft of the scalpel to reduce the risk of accidental mucosal penetration

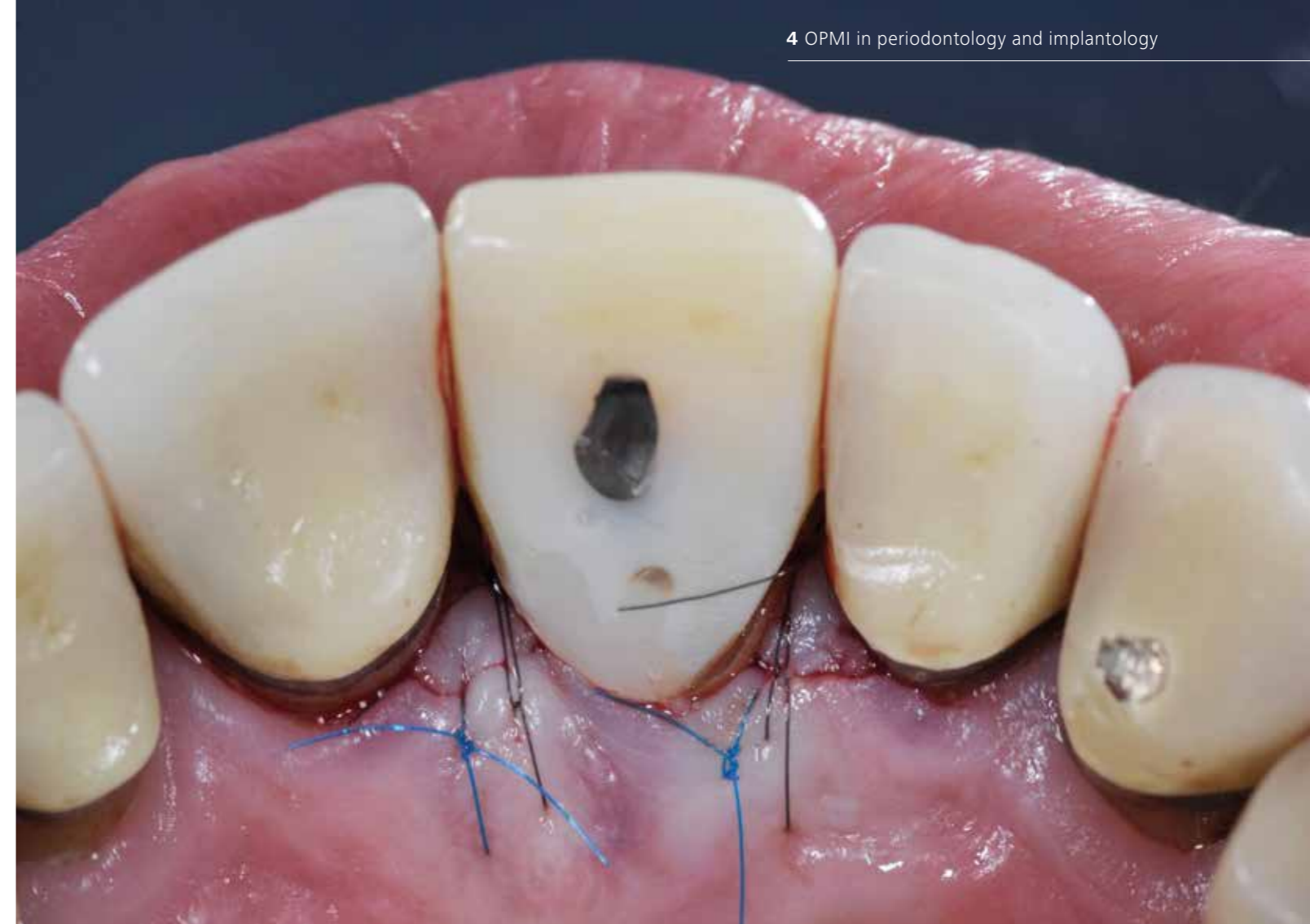

Figure 4.10 Papilla preservation technique. Primary closure of palatal papillae with fine suture materials (7-0 polypropylene)

Various shapes and sizes of micro-scalpels from the disciplines of ophthalmology or plastic surgery (Figure 4.7) can be used and complement the periodontal basic instrument sets, additionally supplemented with fine chisels, raspatories, elevators, hooks and suction tips (Figure 4.9).



Figure 4.9  
Fine working end of a microsurgical elevator. The underlying stamp illustrates the small size of the instrument




Figure 4.11  
Example of container or tray system to store the fragile microsurgical instruments and to prevent them from damage during washing, sterilization and transportation

In order to prevent damage, micro-instruments are stored in a sterile container or tray. The tips of the instruments must not touch each other during sterilization procedures or transportation. The practice staff should be thoroughly trained in the cleaning and maintenance of such instruments, as cleaning in a thermo disinfectant without instrument fixation can irreparably damage the tip of these delicate microsurgical instruments

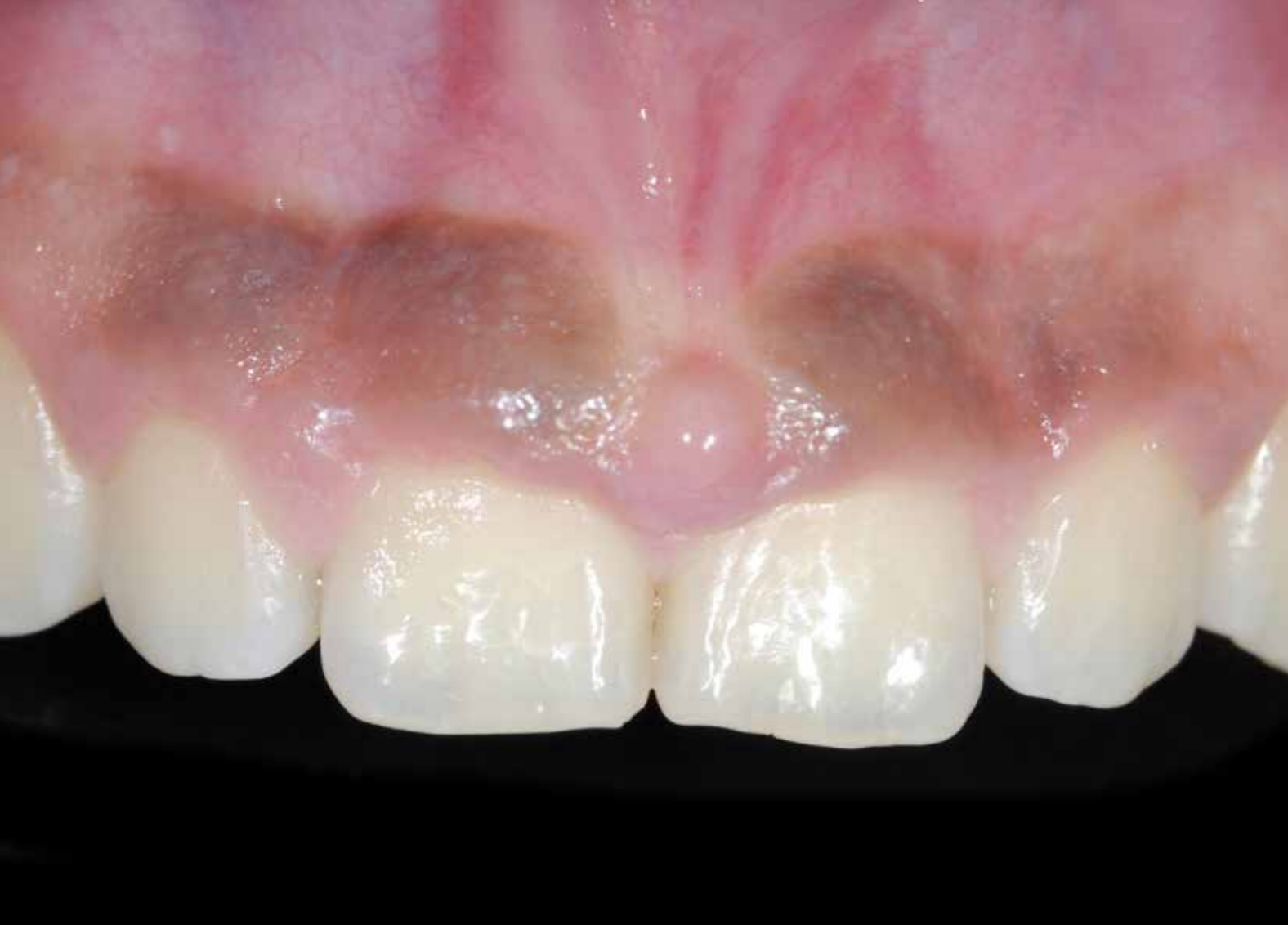

Figure 4.12 Before microsurgical crown lengthening

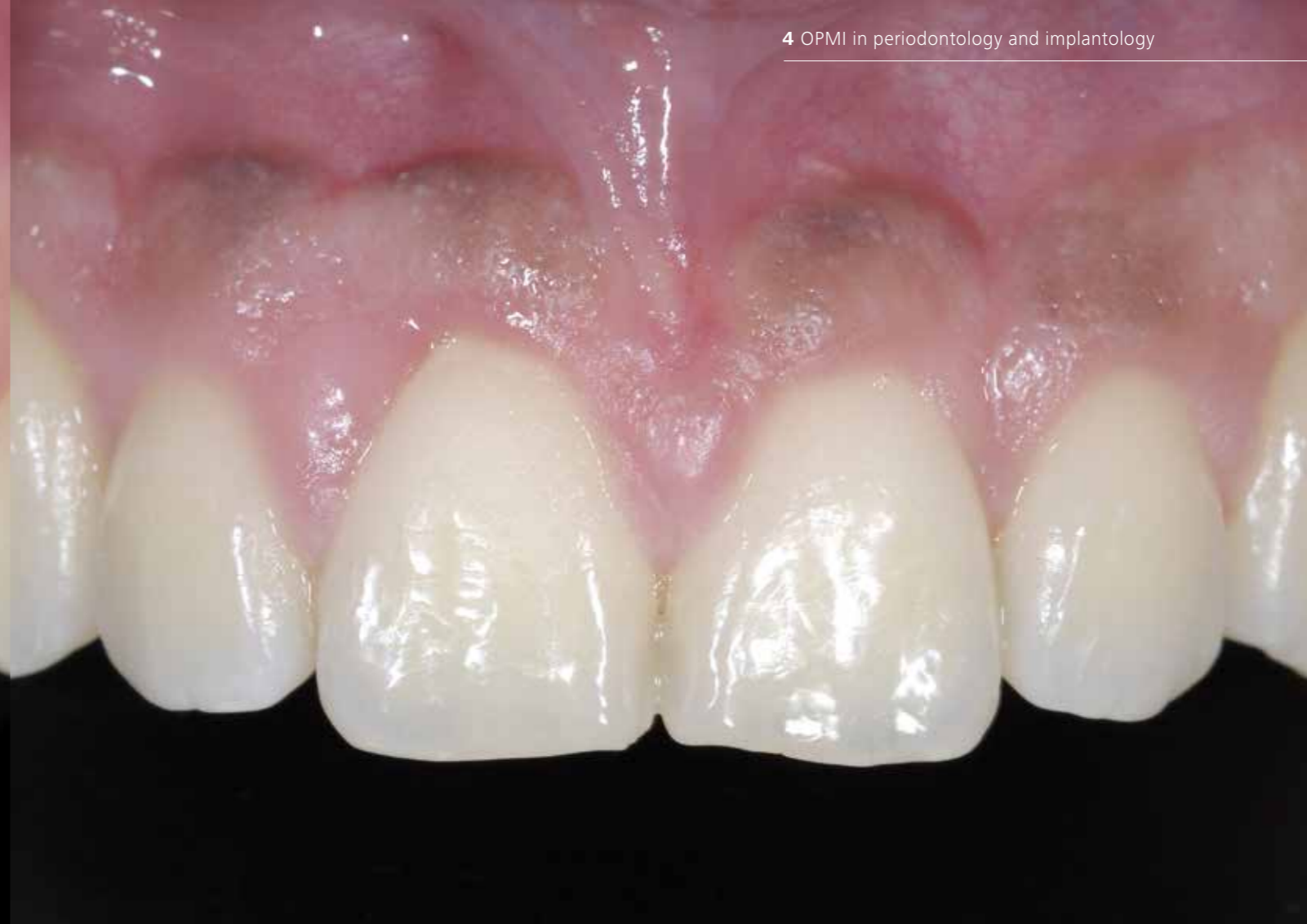

Figure 4.14 After microsurgical crown lengthening (two months postoperatively)

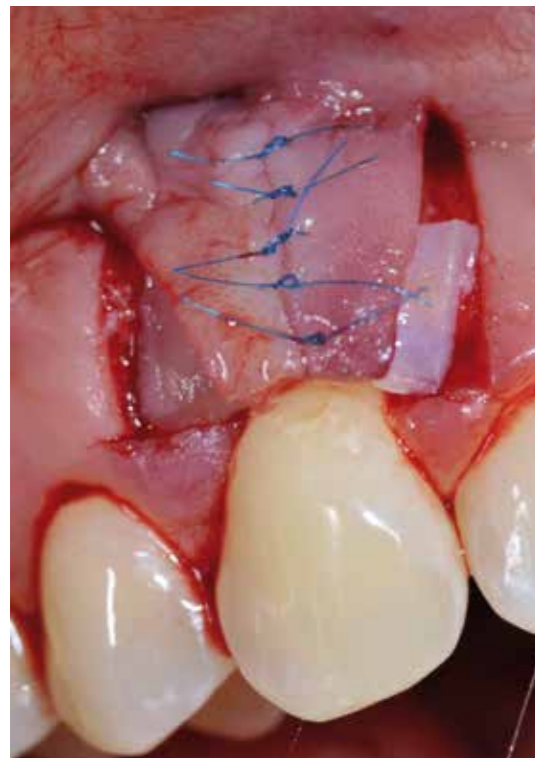

Figure 4.13 Microsurgical wound closure with 8-0 sutures provides a precise flap adaptation

#### Suture materials

Suture materials and techniques are essential factors to consider in microsurgery. Wound closure is a key prerequisite for healing following surgical interventions and most important to avoid complications. The most popular technique for wound closure is the use of sutures that stabilizes the wound margins sufficiently and ensures a proper closure over a defined period of time. However, the penetration of a needle through the soft tissue in itself causes trauma and the presence of foreign materials in

a wound may significantly enhance the susceptibility to infection. Hence, it is obvious that needle and thread characteristics also influence the wound healing and surgical outcome.




Figure 4.15  
Flattened needle body ensures a firm seat of the needle in the needle holder and prevents the needle from twisting to either one or the other side





Figure 4.16  
Left: Sharp tip (spatula) of a microsurgical needle (200x magnification)  
Right: Damaged needle tip after touching the enamel surface of a neighbouring tooth



### Characteristics of the needle

Needles consist of a swage, body and tip and differ in their material, length, size, tip configuration, body diameter and the manner of connection between needle and thread. In atraumatic sutures the thread is firmly connected to the needle through a press-fit swage or inserted in a laser-drilled opening. There is no difference concerning stability between the two attachment modalities. The body of the needle should be flattened to prevent twisting or rotation in the needle holder (Figure 4.15). The needle tips differ widely depending on the specialty in which they are used. Tips of cutting needles are appropriate for coarse tissues

or less traumatic penetrations. In order to minimize tissue trauma in periodontal microsurgery the sharpest needles, namely reverse cutting needles with precision tips or spatula needles with micro tips are preferred (Figure 4.16). The shape of the needle can be straight or bent to various degrees. For periodontal microsurgery the 3/8" circular needle generally ensures optimum results. The lengths, as measured along the needle curvature from the tip to the proximal end of the needle lock, extend over a wide range. For papillary sutures in the posterior area needle lengths of 14 mm to 16 mm are appropriate. The same task

in the anterior aspect requires needle lengths of 10 mm to 13 mm, and for closing a buccal releasing incision, needle lengths of 5 mm to 8 mm are adequate. To guarantee perpendicular penetration through the soft tissues that prevents tearing an asymptotic curved needle is advantageous in areas where narrow penetrations are required (e.g. margins of gingivae, basis of papillae). To fulfill these prerequisites for ideal wound closure at least two different sutures are used in most surgical interventions. Table 4.1 serves as a basic guide to select the appropriate suture material.

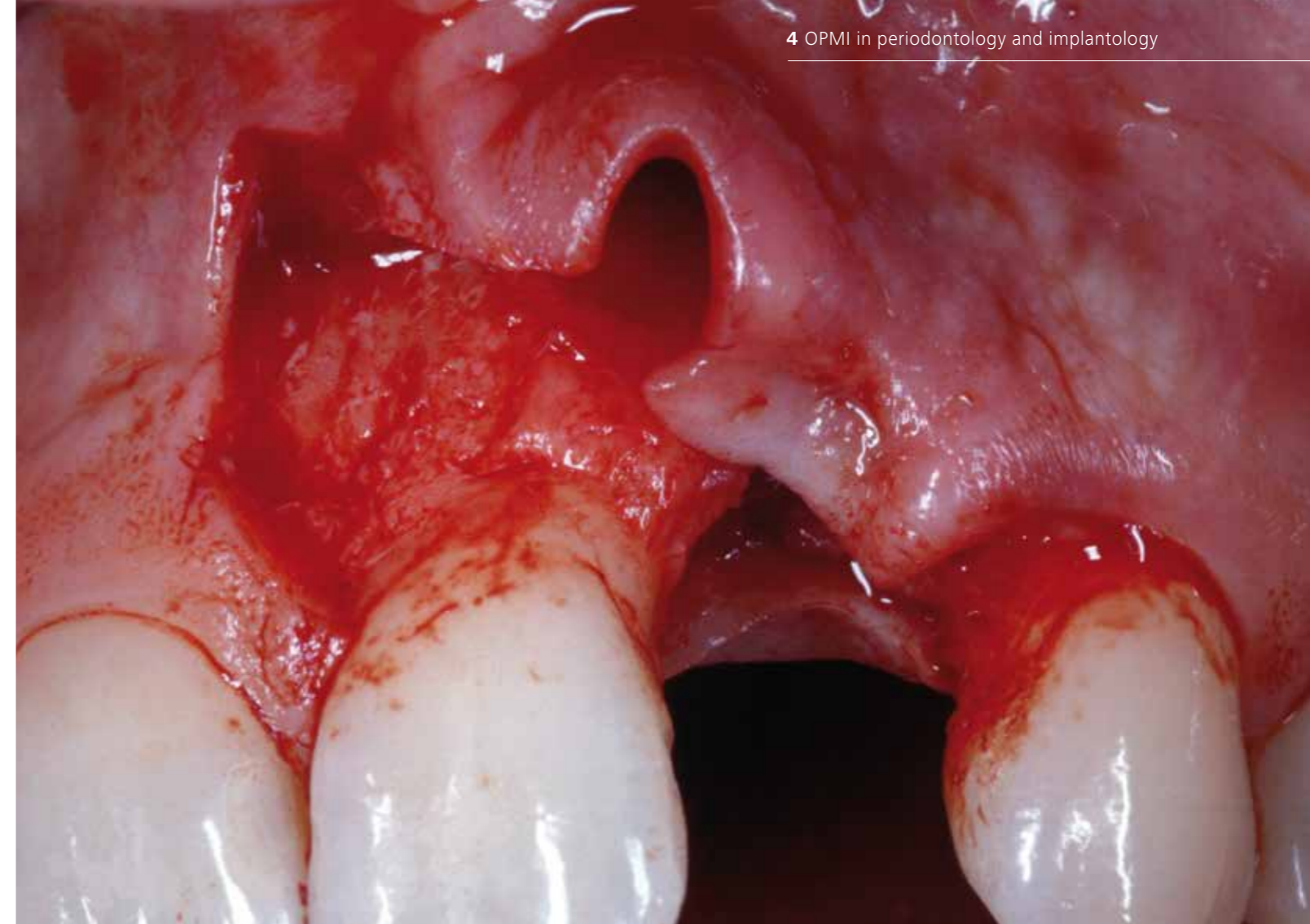

Figure 4.17 Surgical site before microsurgical wound closure

Indications	Suture strength	Needle characteristics	Thread materials	Product name
Buccal releasing incisions	7-0	3/8 curvature, cutting needle, length 7mm DSM 7	polyamide	Resolon®
	7-0	3/8 curvature, cutting needle, length 7mm DSM 7	polypropylene	Mopylen®
	10-0	3/8 curvature needle, cutting needle, length 6mm DSM 6	polyamide	Nylon
Interdental sutures, front area	6-0	3/8 curvature, cutting needle, length 11mm, DSMF 11	polypropylene	Mopylen®
	7-0	3/8 curvature, cutting needle, length 11mm, DSMF 11	polypropylene	Mopylen®
Interdental sutures, premolar area	6-0	3/8 curvature, cutting needle, length 13mm DSMF 13	polypropylene	Mopylen®
	6-0	3/8 curvature, cutting needle, length 13mm DSMF 13	polyamide	Resolon®
Interdental suture, molar area	6-0	3/8 curvature, cutting needle, length 16mm DSM 16 /DSMF 16	polyamide	Resolon®
Crestal incisions	7-0	3/8 curvature, cutting needle, length 11mm DSMF 11	polypropylene	Mopylen®
	6-0	3/8 curvature, cutting needle, length 13mm DSMF 13	polyamide	Resolon®
Papilla basis incisions	7-0	3/8 curvature, cutting needle, length 7mm DSM 7	polypropylene	Mopylen®
	6-0	3/8 curvature, cutting needle, length 7mm DSM 7	polypropylene	Mopylen®

Table 4.1  
Ideal needle-thread combinations (non resorbable) for the use in periodontal and peri-implant microsurgery (Resorba GmbH, 90475 Nuremberg, Germany)

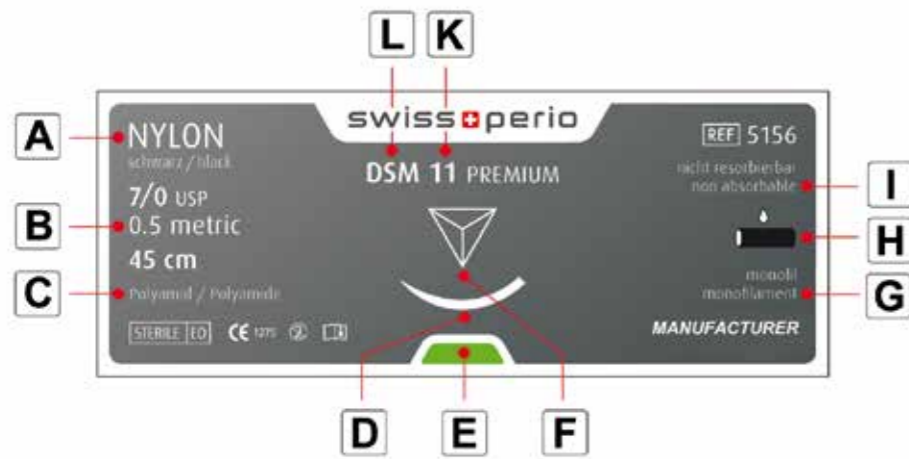

Figure 4.18 Example of a suture package with explanation of the relevant notations, abbreviations, symbols and signs (A Product name of specific suture, often referring to the suture material, B diameter of the suture thread, see Table 2, C suture material, D curvature and length of the needle, E colour code of the suture (facilitates the identification), F configuration of the needle tip, G composition of the thread (monofilament / polyfilament), H pictogram for absorbability / non absorbability and composition of the thread, I thread characteristics (text), K needle length (measured from the tip to the end of the needle), L configuration of the needle (manufacturer specific)

The characteristics of needle and thread configurations are marked on each suture package (Figure 4.18). Suturing threads are classified according to their thickness (Table 4.2). Depending on the manufacturers, it is important to note that either the European or the American nomenclature will apply. While the former follows a metric, the latter follows an arbitrary classification system. European products strictly comply with the European system and reveal the thickness of the thread. However, the American products do not follow the classification according to the diameter of the threads.

European pharmacopoe		American pharmacopoe		
All suturing materials, resorbable and nonresorbable		All suturing materials, except collagen	Collagenous suturing materials	
metric no.	mm-scale	USP no.	mm-scale	USP no.
0.1	0.010-0.019	11-0	0.010-0.019	
0.2	0.020-0.029	10-0	0.020-0.029	
0.3	0.030-0.039	9-0	0.030-0.039	
0.4	0.040-0.049	8-0	0.040-0.049	
0.5	0.050-0.069	7-0	0.050-0.069	
0.7	0.070-0.099	6-0	0.070-0.099	7-0
1	0.100-0.149	5-0	0.100-0.149	6-0
1.5	0.150-0.199	4-0	0.150-0.199	5-0
2	0.200-0.249	3-0	0.200-0.249	4-0
3	0.300-0.349	2-0	0.300-0.349	3-0
3.5	0.350-0.399	0	0.350-0.399	2-0
4	0.400-0.499	1	0.400-0.499	0
5	0.500-0.599	2	0.500-0.599	1
6	0.600-0.699	3 + 4	0.600-0.699	2
7	0.700-0.799	5	0.700-0.799	3
8	0.800-0.899	6	0.800-0.899	4
9	0.900-0.999	7	0.900-0.999	5
10	1.000-1.099	8	1.000-1.099	6

Table 4.2. Classification of suturing materials (diameter of the threads)

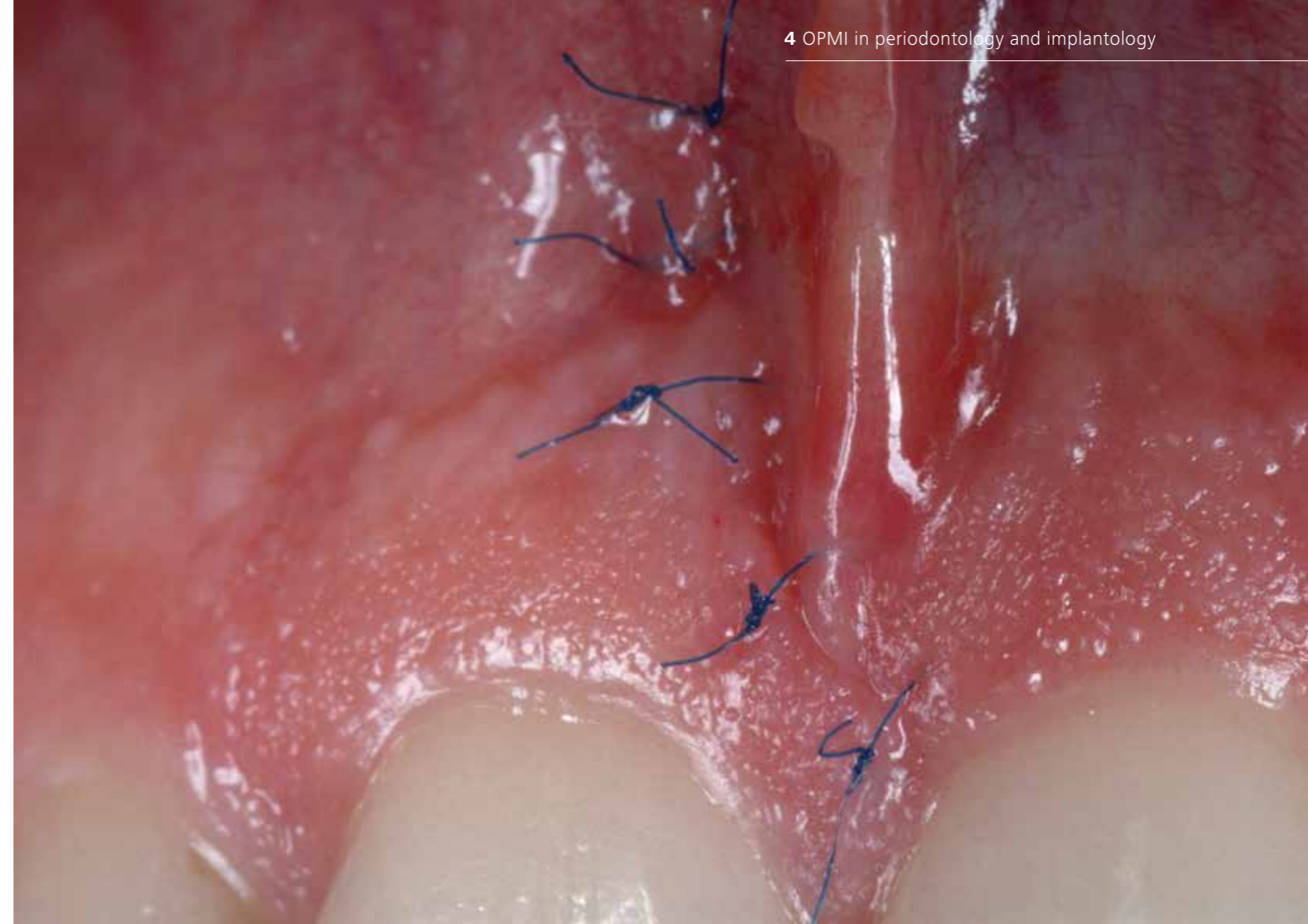


Figure 4.19 Surgical site three days post-operatively before suture removal

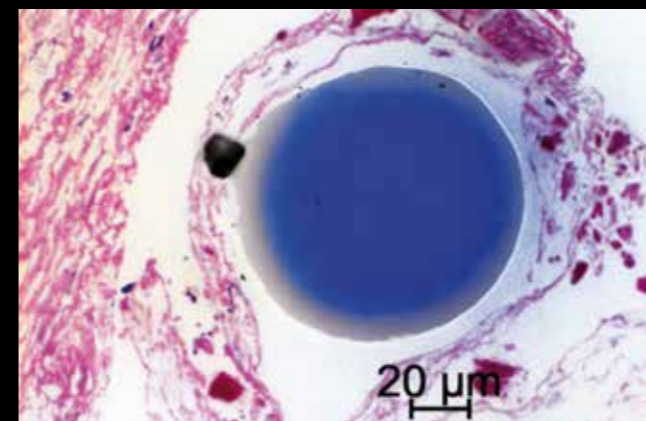
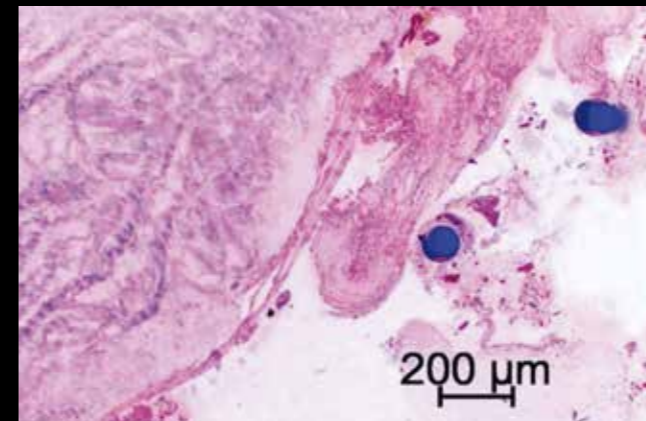


Figure 4.20: In thicker tissues detected suture filaments, bright colored alcian blue in the absence of inflammatory reactions in the surrounding tissue. The suture in the gingival tissues. No pronounced inflammatory reaction. Alcian blue coloration. Increase x50 (top) x 400 (below)

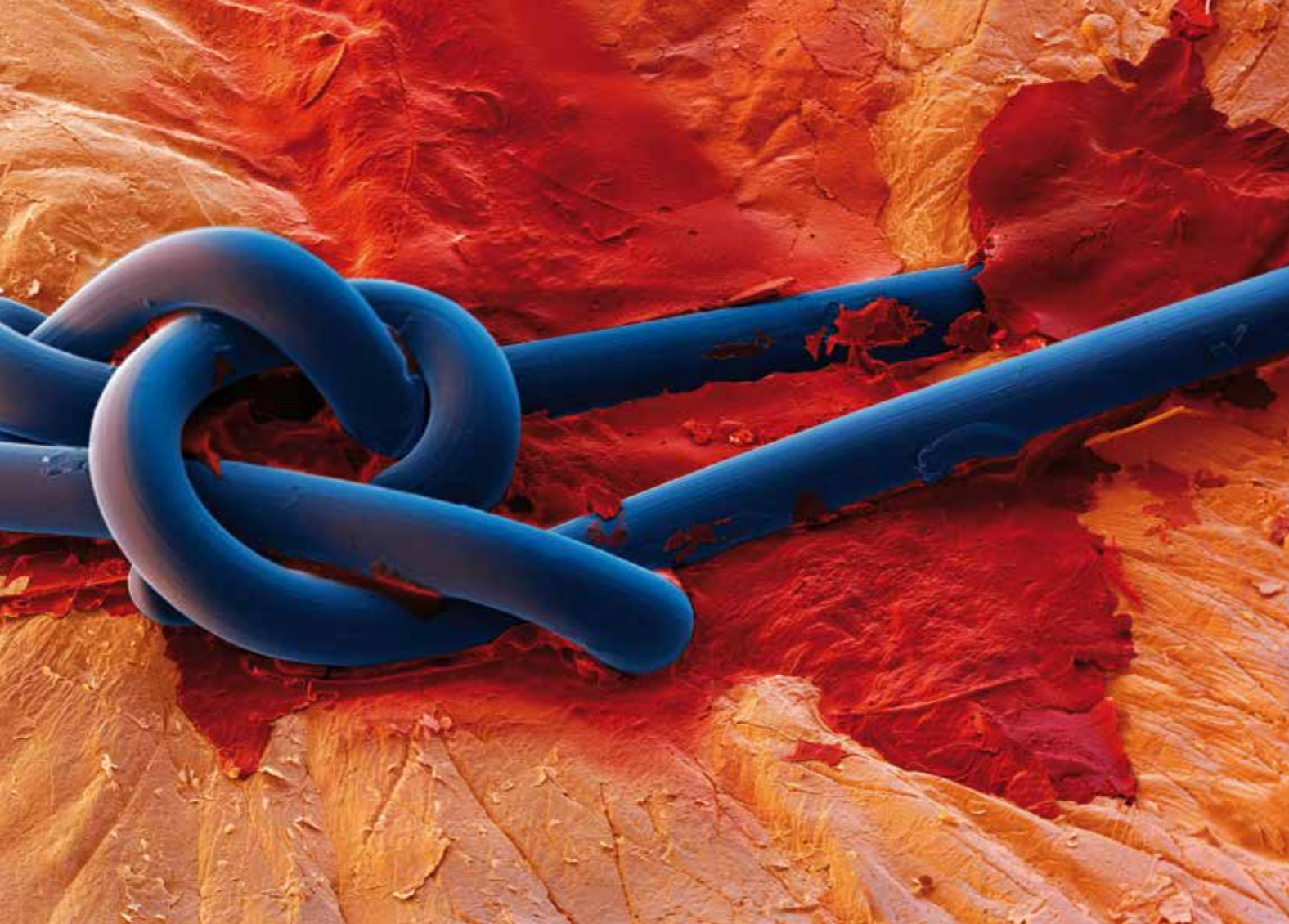

Figure 4.21 High magnification of suture placed to close a skin wound

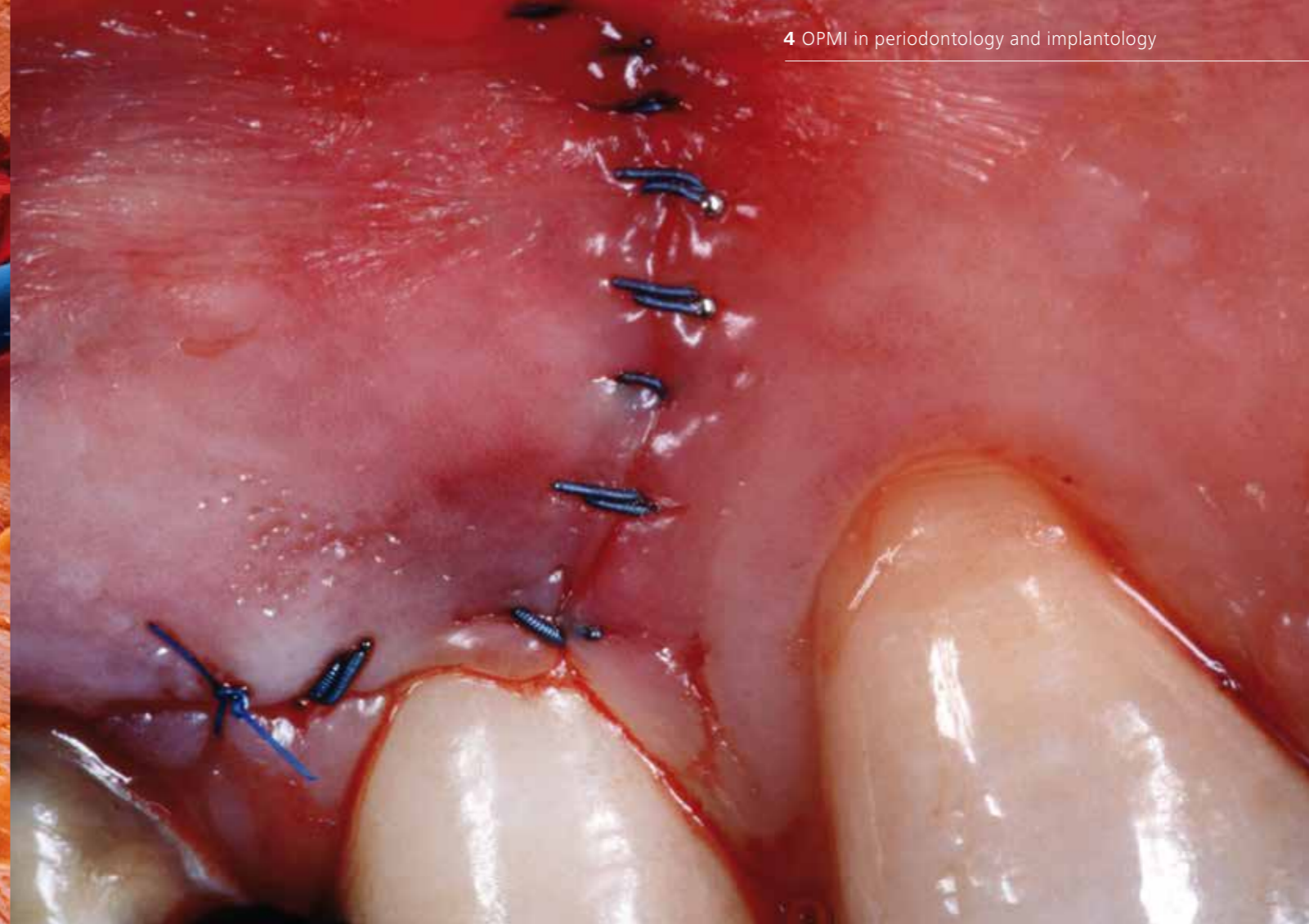


Figure 4.22 Microclips as an alternative to microsutures no mention of microclips in the text

### Characteristics of the thread

The thread may be classified into either resorbable or nonresorbable materials. Within these two categories the materials can be further divided into monofilament and polyfilament threads. The bacterial load of the oral cavity also requires special attention in the choice of the suture material. Generally, in the oral cavity the wound healing processes is uneventful thereby reducing the risk of infection caused by contamination of the thread. As polyfilament threads are characterized by a high capillarity, monofilament qualities are to be preferred. Pseudomonofilament sutures are coated polyfilament threads with the aim of reducing the mechanical

tissue trauma. During suturing the coating will break and the properties of the pseudomonofilament thread then corresponds to that of the polyfilament threads. Additionally fragments of the coating may invade the surrounding tissues and elicit a foreign body reaction.

### Resorbable sutures

Resorbable threads may be categorized as natural or synthetic. Natural threads (i.e. surgical gut) are produced from intestinal mucosa of sheep or cattle. The twisted and polished thread loses its stability within six to fourteen days by enzymatic breakdown. Histological examinations confirmed the inflammatory tissue reactions with

a distinct infiltrate. For that reason natural resorbable threads are generally obsolete. Synthetic threads, however, are advantageous due to their constant physical and biological properties. The materials used belong to the polyamides, the polyolefines or the polyesters that disintegrate by hydration into alcohol and acid. Polyester threads are mechanically stable and based on their different hydrolytic properties, lose their firmness in different, but constant times. A 50 percent reduction of breaking resistance can be expected after two to three weeks for polyglycolic acid and polyglactin threads, four weeks for polyglyconate and five weeks for polydioxanone threads. The threads are available in twisted polyfilament

versions and in monofilament versions for finer suture materials. The capillary effect is limited and hardly exists for polyglactin sutures.

### Nonresorbable sutures

Polyamide is a commonly used material for fine monofilament threads (0.1 mm to 0.01 mm) that show adequate tissue properties. Tissue reactions seldom occur except after errors in the polymerization process. Polyolefines, as an alternative, are inert materials that remain in the tissues without hydrolytic degradation. Materials with excellent tissue properties are polypropylene and its most recent enhancement, polyhexafluoropropylene.

After suturing the thread will be encapsulated in connective tissues and keep its stability for a longer period. In 5-0 and thicker sutures the monofilament threads are relatively stiff and for that reason may impair the patient's comfort.

A substance with similar biological, but improved handling properties is polytetrafluoroethylene. Due to its porous surface structure the monofilament threads should only be used with restriction in the bacterially loaded oral cavity (we recommend avoiding the zone of aesthetic priority). With the sophisticated surgical procedures applied today, there is a greater need for knowledge with regard

to the various types of suture materials and suturing techniques available in order to help obtain optimal wound closure and stability. Despite the many technical solutions available on the market, there are no true alternatives to suture threads which could prove their benefit in clinical practice. While tissue adhesives are difficult to apply in aqueous environments and critical to withstand wound margin tensions, the indication of microclips (Fig. 4.22) is limited to the wound closure of releasing or crestal incisions. Even if they are easy and fast to apply, the closing forces cannot be influenced by the surgeon and no sling or mattress sutures can be executed.

## Which are the first steps in getting used to working with the OPMI?

There is no doubt that, by using an OPMI the operating team is confronted with a completely new environment and the surgeons and assistants first have to adjust to the changed situation. Before starting with the clinical work on the patients the clinicians should become familiar with the impaired manoeuvrability of the OPMI, the new requirements for hand-eye coordination and the initial difficulties which can arise from the new task-sharing conditions between surgeon and clinical assistant. Without appropriate training, periodontal surgery cannot be performed with ease in a stress-free environment.

### Acquaintance with the OPMI in clinical practice

A substantial number of periodontists have already adopted the use of low magnification in their practices and recognize its great benefits. Loupes have the advantage over the OPMI in that they have a reduced technique sensitivity, they cost less and a shorter learning curve can be expected before they can be used as a matter of routine. At present, it can only be speculated how significantly the selection of magnification influences the result of the operation. The magnification recommended for surgical interventions ranges from 2.5x to 20x. In periodontal

surgery, magnifications of 4x to 5x for loupes and 8x to 20x for OPMI appear to be ideal depending on the kind of intervention. As the depth of field decreases with increasing magnification, the maximum magnification for a surgical intervention is limited to about 12x to 15x, when dealing with a localized problem such as the coverage of a single soft tissue recession or the interdental wound closure after guided tissue regeneration of an infrabony defect. A magnification range of 6x to 8x seems appropriate for clinical inspections or surgical interventions when the entire quadrant is under operation. Higher magnifications of 15x to 25x are more likely limited to the visual examination of clinical details, such as furcation morphologies or root surface pathologies. It is highly questionable if the previous use of loupe magnification may help the beginner to get acquainted to the OPMI. We strongly believe that it will not substantially shorten the learning curve as other influencing factors play a more important role than magnification. Working under the OPMI does not only mean working with higher magnification within an even more restricted field of view, but it also requires the user to become acquainted with a totally new technical setup. Similar to the formation of a new team (Tuckman's group development model),

one can classify the familiarization process with an OPMI into four different stages: 1) forming, 2) storming, 3) norming and 4) performing. The initial stage includes the first steps in the training laboratory with the goal to automate the instrument handling and get used to the new conditions. It is important to allow enough time for this initial familiarization process. It should take place beyond the daily busy schedule with patient treatments and not exceed the duration of 30 to 40 minutes per session. As an approximate guideline, a frequency of three to four training units per week is ideal to get familiar with the new technical equipment and the related restrictions regarding manoeuvrability. Over and above the mere hours of training, the structure of the exercises is of the utmost importance to ensure that maximum benefit can be gained and that the user's expertise is improved accordingly. This initial stage can last from one to several months and may also include first clinical examinations on patients.

When the trainee is able to manage the basic clinical procedures with the OPMI under laboratory conditions and they are increasingly becoming a matter of routine, the learned skills can be transferred to actual clinical practice. Despite the previous familiarization

exercises, the second stage confronts the trainee with several new aspects which in turn impair fluent clinical work (storming phase). These include the inclusion of the assistant in the surgical procedure and the more dynamic environment. The storming phase is necessary for the growth of the treatment team. It can be unpleasant and exhausting and the speed of progress in the familiarization process with the OPMI may decrease. Some teams will never develop past this stage.

Those that have successfully managed the problems of the storming phase and found their workflow, now enter the norming phase. It is characterized by a mutual plan between the surgeon, the chairside assistant and other team members involved to further improve the workflow smoothly and effectively. The norming phase consists of task-sharing and working for a common goal. All of the team members have their allocated responsibilities and, more importantly than in a conventional surgical approach, the well-organized, interdependent relationship between surgeon and chairside assistant makes the team function. After a corresponding period of clinical training, it is possible for some teams to reach the performing stage. These teams are able to function efficiently and effectively as a treatment unit and

perform almost all surgeries under the OPMI with the highest accuracy possible. If there are not many positional changes required during the surgery, such high-performing teams can accomplish a surgical intervention within the same time or even faster than without the use of an OPMI.

For acquiring clinical expertise in periodontal and peri-implant microsurgery, time and training play an important role. Therefore, most clinicians believe that they automatically become better over time, which is just partly true. Once a daily routine is achieved and a surgical procedure can be performed with ease (performing stage), ongoing training is mandatory to further improve the dexterity of the surgeon's hands. The finely orchestrated sequential finger movements need a stimulus coming from the brain. Otherwise, no further apparent improvements in the micro hand movements can be expected (see below).

### The importance of the hand-eye-brain coordination for fluent surgery

Our lives are so full of commonplace experience in which our hands are so skillfully and silently involved that we rarely consider how dependent upon them we actually are. One hand consists of 27 bones and 39 muscles which are responsible for the control of the finger joints and the wrist. The number of muscles exceeds by far the number of degrees of freedom which are provided by the finger joints - from a biomechanical point of view a complete overconstruction!

But likewise, for a dexterous manipulation, the role of the sensory feedback in controlling the induced motion must not be underestimated. Which are now the key issues for precise hand and finger movements? Which body parts can and should be trained? How do we become good surgeons? The questions are serious ones and of intense interest to the people responsible for training surgeons and microsurgeons. The Loyola Medical Center has investigated several aspects of prospective surgeons related to their predictive value to become good surgeons. They looked at manual speed, fine motor coordination, and bimanual sequencing; they looked at

visual perception, including the ability to see important patterns buried in visual clutter and the ability to solve maze problems; they tested spatial memory; they tested the ability to perform under stress. The tests were subdivided into three major headings: psychomotor abilities, complex visuospatial organization and stress tolerance. After processing their data, they looked to see what the highest achievers in the programme had, that the lesser surgeons lacked, or had less of, based on the psychological tests. Guess what? The eyes have it!

This is not to imply that manual dexterity is not important to microsurgeons in performing their activities - they obviously are quite significant, but the distinguishing features of the superior practitioner are his/her ability to see the relevant anatomical structures of the operative site, even when this might not be immediately visible, to quickly identify important landmarks in the incision and to mentally organize multisensory data and actions at any given point of the procedure so as to allow a smooth and efficient sequence of responses. From this data we can conclude that appropriate microsurgical training must not only focus on the pure psychomotor skills but also on the perceptual abilities of the trainee.

At first sight it is not self-evident that the human hand is capable of performing finer movements than the naked eye is able to control. In macrosurgery, movements are controlled by the proprioceptive tactility of the fingers and the palm. Since the adductor and abductor finger muscles are relatively coarse, microsurgical training attempts to improve the fine-tuning of the motor muscles of the hand and arm and the training of the clinician's cognitive abilities as mentioned above.

A thread of a 10-0 suture has a diameter of only 20  $\mu\text{m}$  to 29  $\mu\text{m}$ . Therefore, tying a knot can only be controlled visually. When working under the OPMI with 10x through 20x magnification, just the instrument tips are visible and the appropriate suture material has a diameter five times smaller than a single human hair.

It is surprising, and not so obvious, how much almost all physical skill flows from the maturation of motor skills under the guidance of both visual and kinesthetic monitoring. Both the hand and the eye develop as sense organs through practise, which means that the brain teaches itself to synthesize visual and tactile perceptions by making the hand and eye learn to work together.

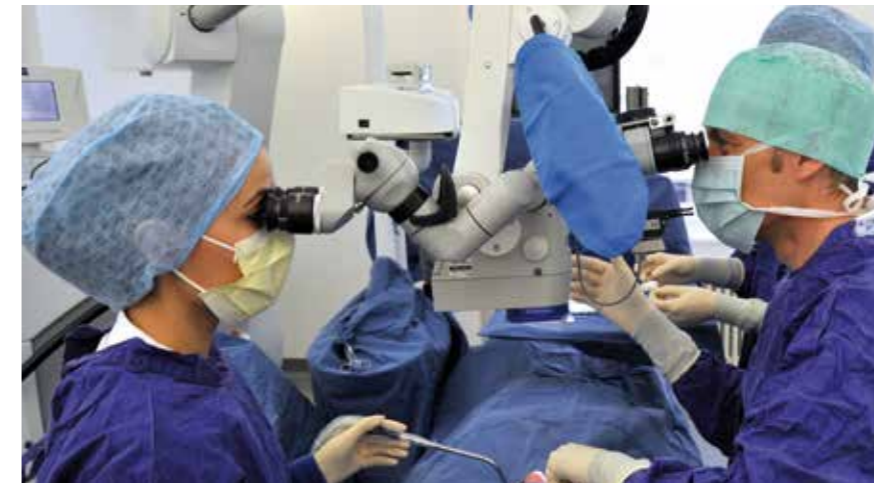

Figure 4.23  
Clinical set-up for a surgical periodontal intervention with the OPMI. Note the opposite position of the assistant when working with the co-observer tubes (OPMI without sterile drape to demonstrate the position of the OPMI components)

### Task-sharing between surgeon and assistant (teamwork)

In microdentistry, many clinical procedures are performed with a minimum number of position changes of the operators. Focusing can easily be achieved by moving the mirror towards or away from the objective lenses. In periodontal and peri-implant surgery both hands are used to hold the instruments. Position changes are more frequently required, increasing the demands on the operating team and necessitating ideal cooperation between surgeon and assistant.

In all surgeries at least two operators are involved, a surgeon and an assistant who supports the surgeon in the most rudimentary tasks in the operation. However, the tasks that the assistant constantly repeats in almost all operations with varying levels of skill are considered. These tasks include flap retraction, suction, rinsing and cutting the sutures. To guarantee a continuous workflow during the surgical intervention, a second assistant who arranges the instruments is frequently desirable. Additionally, this second assistant monitors the well-being of the patient. Depending on the working configuration (loupe, video screen or co-observer tubes), this task might be difficult to perform by the chairside

assistant due to the restricted peripheral view.

In periodontal microsurgery, where the surgeon has very poor access, retraction is absolutely vital. The retraction should be done in different positions and must be devoid of all tremor or movement. This is an exceptionally strenuous task as the assistant is expected to maintain the same posture for a period of time which can extend to one hour or even more. As flap retraction is extremely energy-consuming, the fatigue experienced by the assistant would increase the chances of tremor as time goes by.

For an optimal workflow, magnification is also required for the assisting person.

Only co-observer tubes allow the same view for surgeon and assistant, allowing the assistant to direct the suction tube accurately and keep the field of view clear (Figure 4.23). This also becomes an issue during suturing when the air intake of the suction tube can easily aspirate the fine threads. One disadvantage of this working configuration that must be mentioned, is the impaired manoeuvrability of the operating team, since each movement of the surgeon must be compensated for by the same movement of the assistant in the opposite direction.

Therefore, it is recommended to get used to working in the centre of the field of view. That way an upcoming movement of the OPMI can be anticipated by the assisting person, which in turn facilitates the workflow. Working with a co-observer tube is a team approach and requires specific training of all included persons in a simulated clinical environment.

## How can expertise be acquired in periodontal and peri-implant microsurgery?

Most microsurgical training programmes are related to beginners, focusing on the forming phase (mentioned above). They are designed to give an insight into the world of magnification, accompanied by technical information about the OPMI and personal recommendations of the lecturer. These courses mainly consist of basic exercises and cover topics such as how to pick up the needles, tie the knots and suture under the OPMI. Usually, after the course the student is abandoned to his fate.

This is somewhat surprising as most courses last only one or two days, and just communicating the message is simply not enough! No matter how sincere the inquiry, a great deal of practise and a special kind of practise is necessary for real understanding. This is no drawback, since many people currently invest large amounts of motor skill practise time with no noticeable results.

We recommend a three step training programme: In the first course, the trainee is initiated into the world of microdentistry. Basic aspects such as positioning for an ergonomic posture and how to reduce natural hand tremor are taught. The latter is of the utmost importance as even normal tremor of the fingertips with excursions of a

few tenths of a millimeter can make a surgical intervention impossible. Its physiological basis is uncertain, but it is important to be aware of the causes in order to prevent them. The body posture must be natural, with the spinal column straight and the forearms and hands fully supported. An adjustable chair, preferably with wheels is recommended for the surgeon who should place him/herself in the most comfortable position. Tremor varies with individuals and even in the same individual it varies under different conditions. In some people, coffee, tea or alcohol may increase the tremor; in others, emotions, physical exercise or the carrying of heavy weights.

During the basic course a number of exercises are shown and practised. These are the same for all the different microsurgical specialties. The exercises should be adjusted individually depending on the progress of each single participant. This guarantees the best learning effect. The initial training lasts two days and the models used are mainly two dimensional ones. The third day of the basic course is dedicated to the specific periodontal and peri-implant exercises. These are performed on models which mimic the restricted access area of the oral cavity, the depth of the working field from the

incisor to the last molar and the three dimensionality of the oral mucosa. For completion of the initial phase, the trainee is given a booklet with exercises based on increasing levels of difficulty. This serves as a basic guideline for training at home and includes several tests for self-evaluation.

After the corresponding training in the lab and before starting with the first microsurgeries on the patient, the trainee attends a second course that lasts one day. It is the aim of the course to control the learned hand and finger movements for their correctness and to instruct the clinician about the ergonomic aspects that may facilitate one's life in clinical practice. These include good hand support during microsurgical interventions, which can easily be achieved by positioning folded cloth rolls on the shoulders of the patient before placing the sterile drape (Figure 4.24a/Figure 4.24b). After this second instruction, the trainee is provided with all the necessary theoretical information and manual skills to start with the first surgical interventions, thus turning into an apprentice.

In the following period, the young microsurgical team must acquire clinical routine and eliminate small errors.

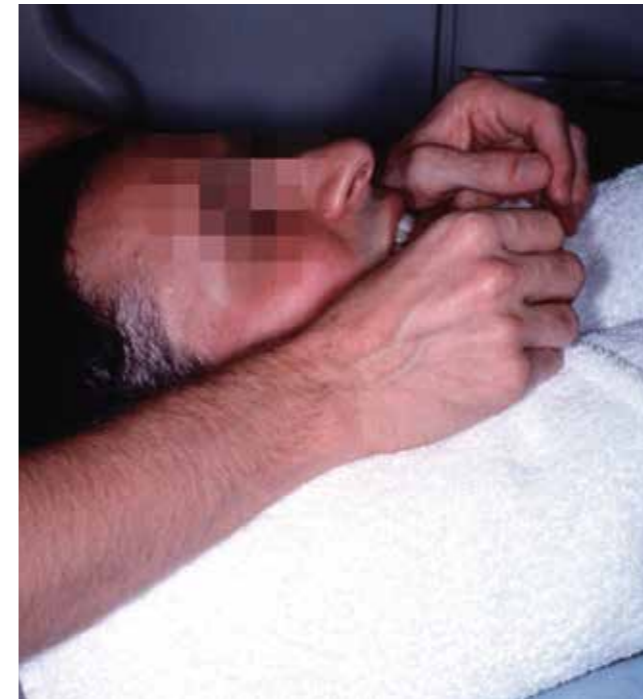

Figure 4.24a Folded cloth rolls on the patient's shoulders provide an excellent hand support to avoid an unfavourable tremor

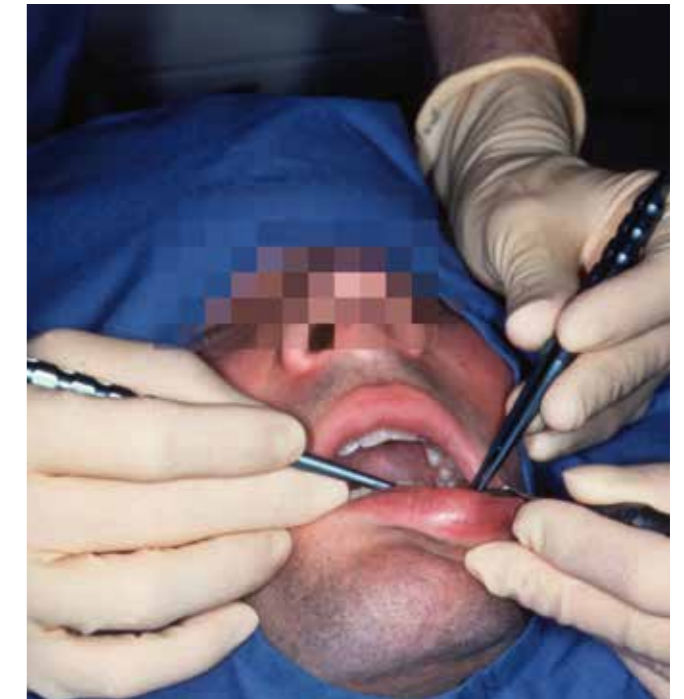

Figure 4.24b Clinical situation with a sterile drape covering the hand rests and the face of the patient

During this phase an expert can just support with advice or recommendations while the new treatment team forms by itself. Following the learning curve and acquiring expertise, the apprentice gains proficiency. The team is now qualified to manage well-known procedures successfully under the OPMI without any increase in duration. Intuitively, one might suppose that practise pays off by making movements increasingly more precise as time passes by. That, however, turns out to be a terrible mistake, because the hand needs a new, more difficult task as a stimulus for further improvement. In other words, getting better means improving one's ability to

deal with difficult situations. For that reason, after several years of clinical practice, and to become an expert, the microsurgeon may attend a third course which is focused on specific exercises at the highest level of difficulties. Such a course can just present the suitable exercises and provide the participants with the appropriate training models. We are convinced that even a master in periodontal microsurgery must undergo lab training from time to time and that the lifetime training is a prerequisite to constantly improve manual skills.



## Which are the most common errors made in the use of the OPMI in surgical practice?

The three most common errors in the use of the OPMI are:

### 1) using magnification that is too high

### 2) changing techniques too rapidly

### 3) lack of practise

#### High magnification

There is a tendency to use magnification that is too high. One of the basic principles of optics is the higher the magnification, the narrower the field of view and the smaller its depth. This concept is important because high magnification causes surgery to become more difficult, especially when it involves considerable movement. In these circumstances low magnification of 4x to 7x should be used. On the other hand, higher magnification of 10x to 15x may be useful when dissecting within a small area requiring less movement, e.g. in papilla preservation techniques (Figure 1). In general, the magnification should be chosen to allow the surgeons to operate with ease and without increasing their usual operating time required for a particular surgical procedure. Surgical time does not have to be increased once the surgeon has adapted fully to the OPMI. The more experienced and skilled the surgeons are with the OPMI, the higher the magnification they can use with ease.

It may take six months or more for surgeons to be familiar with magnification of 12x, which usually is the maximum used in plastic periodontal and implant surgery. A point of diminishing returns will eventually be reached at the point of magnification where the advantages of magnification are outweighed by the disadvantages of a narrower field of view.

#### Changing techniques too rapidly

One unfortunate aspect in the use of the OPMI is the failure to define its purpose clearly. Many scientific publications on the use of the OPMI in periodontal and implant surgery emphasize new techniques or technological advances, some of which are mainly for research while others are so sophisticated that they are beyond the scope of most clinicians in practice.

There has thus been a consistent failure on the part of microsurgeons to stress the advantage of the OPMI. The OPMI is not only useful in research and for periodontal specialists, but also helps a general practitioner to perform conventional periodontal and peri-implant operations with greater precision and accuracy. It follows that with the use of the OPMI, surgeons do not need to change their techniques necessarily, but should continue with those with which they are most familiar. Changing techniques should be deliberately resisted until the initial adjustment difficulties have been overcome.

#### Lack of Practise

Working with high magnification (12-20x) the surgeon has to adjust to being a "prisoner" within a narrow field of view. A new co-ordination has to be sought between the surgeon's eyes and hands – an adjustment which can come after much regular practice with simple surgical procedures only. If periodontal surgeons say that they use the OPMI only for difficult procedures, such as guided tissue regeneration or recession coverage, it is likely that they have not adjusted to the OPMI. The same applies if their operating time is significantly increased or if they are not using the OPMI for all their surgeries, at the least those that do not require positional changes.

Once the periodontal surgeons are able to do more difficult procedures and suture the wounds with very fine suture materials (8-0, 9-0, 10-0) as a matter of routine, the standard of their basic surgeries will also improve even if these are performed with lower magnification. However, this progress can only be attained with regular practise, which seems to be one of the key factors in becoming an experienced microsurgeon.

To acquire expertise in periodontal and peri-implant microsurgery, correct implementation of the exercises is more important than time exposure (further information: [www.swiss-perio.com](http://www.swiss-perio.com)).

## References

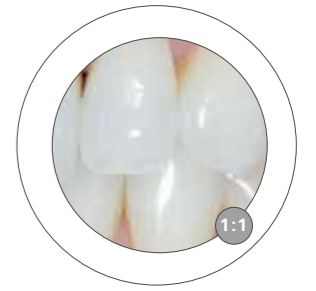- ABIDIN, M.R., TOWLER, M.A., THACKER, J.G., NOCHIMSON, G.D., MCGREGOR, W. & EDLICH, R.F. (1989) NEW ATRAUMATIC ROUNDED-EDGE SURGICAL NEEDLE HOLDER JAWS. *THE AMERICAN JOURNAL OF SURGERY* 157: 241-242.
- ABIDIN, M.R., DUNLAPP, J.A., TOWLER, M.A., BECKER, D.G., THACKER, J.G., MCGREGOR, W. & EDLICH, R.F. (1990) METALLURGICALLY BONDED NEEDLE HOLDER JAWS. A TECHNIQUE TO ENHANCE NEEDLE HOLDING SECURITY WITHOUT SUTURAL DAMAGE. *THE AMERICAN SURGEON* 56: 643-647.
- BERGENHOLTZ, A. & ISAKSSON, B. (1967) TISSUE REACTIONS IN THE ORAL MUCOSA TO CATGUT, SILK AND MERSILENE SUTURES. *ODONTOLOGISK REVY* 18: 237-250.
- BLOMSTEDT, B., ÖSTERBERG, B. & BERGSTRAND, A. (1977) SUTURE MATERIAL AND BACTERIAL TRANSPORT. AN EXPERIMENTAL STUDY. *ACTA CHIRURGICA SCANDINAVICA* 143: 71-73.
- BURKHARDT, R. & HUERZELER, M. B. (2000) UTILIZATION OF THE OPMI FOR ADVANCED PLASTIC PERIODONTAL SURGERY. *PRACTICAL PERIODONTICS AND AESTHETIC DENTISTRY* 12: 171-180.
- BURKHARDT, R. & LANG, N.P. (2005) COVERAGE OF LOCALIZED GINGIVAL RECESSIONS: COMPARISON OF MICRO- AND MACROSURGICAL TECHNIQUES. *JOURNAL OF PERIODONTOLOGY* 32: 287-293.
- BURKHARDT, R., PREISS, A., JOSS, A. & LANG, N.P. (2008) INFLUENCE OF SUTURE TENSION TO THE TEARING CHARACTERISTICS OF THE SOFT TISSUES: AN IN VITRO EXPERIMENT. *CLINICAL ORAL IMPLANTS RESEARCH* 19: 314-319.
- BURKHARDT, R. & LANG, N.P. (2014) FUNDAMENTAL PRINCIPLES IN PERIODONTAL PLASTIC SURGERY AND MUCOSAL AUGMENTATION - A NARRATIVE REVIEW. *JOURNAL OF CLINICAL PERIODONTOLOGY* (ACCEPTED FOR PUBLICATION).
- CHU, C.C. & WILLIAMS, D.G. (1984) EFFECTS OF PHYSICAL CONFIGURATION AND CHEMICAL STRUCTURE OF SUTURE MATERIALS ON BACTERIAL ADHESION. *AMERICAN JOURNAL OF SURGERY* 147: 197-204.
- CORTELLINI, P. & TONETTI, M.S. (2001) MICROSURGICAL APPROACH TO PERIODONTAL REGENERATION. INITIAL EVALUATION IN A CASE COHORT. *JOURNAL OF PERIODONTOLOGY* 72: 559-569.
- CURTIS, J. W., MCLAIN, J. B. & HUTCHINSON, R.A. (1985) THE INCIDENCE AND SEVERITY OF COMPLICATIONS AND PAIN FOLLOWING PERIODONTAL SURGERY. *JOURNAL OF PERIODONTOLOGY* 10: 597-601.
- DE CAMPOS, G.V., BITTENCOURT, S., SALLUM, A.W., NOCITI JR., F.H., SALLUM, E.A. & CASATI, M.Z. (2006) ACHIEVING PRIMARY CLOSURE AND ENHANCING AESTHETICS WITH PERIODONTAL MICROSURGERY. *PRACTICAL PROCEDURES AND AESTHETIC DENTISTRY* 18: 449-454.
- HELPAF, B., STAIB, I., SEIB, U., OSSWALD, J. & HARTUNG, H. (1973) TISSUE REACTION OF PARENCHYMATOUS ORGANS FOLLOWING IMPLANTATION OF CONVENTIONALLY AND RADIATION STERILIZED CATGUT. *BRUN'S BEITRÄGE FÜR KLINISCHE CHIRURGIE* 220: 323-333.
- LEVIN, M.R. (1980). PERIODONTAL SUTURE MATERIALS AND SURGICAL DRESSINGS. *DENTAL CLINICS OF NORTH AMERICA* 24: 767-781.
- MACHT, S.D. & KRIZEK, T.J. (1978). SUTURES AND SUTURING – CURRENT CONCEPTS. *JOURNAL OF ORAL SURGERY* 36: 710-712.
- MEYER, R.D. & ANTONINI, C.J. (1989) A REVIEW OF SUTURE MATERIALS, PART I. *COMPENDIUM OF CONTINUING EDUCATION IN DENTISTRY* 10: 260-265.
- MICHAELIDES, P.L. (1996) USE OF THE OPERATING MICROSCOPE IN DENTISTRY. *JOURNAL OF THE CALIFORNIA DENTAL ASSOCIATION* 24: 45-50.
- MOUZAS, G.L. & YEADON, A. (1975) DOES THE CHOICE OF SUTURE MATERIAL AFFECT THE INCIDENCE OF WOUND INFECTION? *BRITISH JOURNAL OF SURGERY* 62: 952-955.
- NOCKEMANN, P.F. (1981) WOUND HEALING AND MANAGEMENT OF WOUNDS FROM THE POINT OF VIEW OF PLASTIC SURGERY OPERATIONS IN GYNECOLOGY. *GYNÄKOLOGE* 14: 2-13.
- POSTLETHWAIT, R.W. & SMITH, B. (1975) A NEW SYNTHETIC ABSORBABLE SUTURE. *SURGERY, GYNECOLOGY AND OBSTETRICS* 140: 377-380.
- ROTHENBURGER, S., SPANGLER, D., BHENDE, S. & BURKLEY, D. (2002) IN VITRO ANTIMICROBIAL EVALUATION OF COATED VICRYL PLUS ANTIBACTERIAL SUTURE (COATED POLYGLACTIN 910 WITH TRICLOSAN) USING ZONE OF INHIBITION ASSAYS. *SURGICAL INFECTIONS* 3 (SUPPL 1): 79 – 87.
- SALTHOUSE, T.N. (1980). BIOLOGIC RESPONSE TO SUTURES. *OTOLARYNGOLOGICAL HEAD AND NECK SURGERY* 88: 658-664.
- SCHEUNEMANN, A. & PICKLEMAN, J. (1993) NEUROPSYCHOLOGICAL ANALYSIS OF SURGICAL SKILL. IN: STARKES, J.L. & ALLARD, F. EDS. *COGNITIVE ISSUES IN MOTOR EXPERTISE*, P 189. AMSTERDAM: ELSEVIER SCIENCE PUBLISHER B.V.
- SHANELEC, D.A. & TIBBETTS, L.S. (1994) PERIODONTAL MICROSURGERY. *PERIODONTAL INSIGHTS* 1: 4-7.
- SHANELEC, D.A. & TIBBETTS, L.S. (1996) A PERSPECTIVE ON THE FUTURE OF PERIODONTAL MICROSURGERY. *PERIODONTOLOGY* 2000 11: 58-64.
- THACKER, J.G., RODEHEAVER, G.T. & TOWLER, M.A. (1989) SURGICAL NEEDLE SHARPNESS. *AMERICAN JOURNAL OF SURGERY* 157: 334-339.
- VON FRAUNHOFER & J.A., JOHNSON, J.D. (1992) A NEW SURGICAL NEEDLE FOR PERIODONTOLOGY. *GENERAL DENTISTRY* 5: 418- 420.
- ZAUGG, B., STASSINAKIS, A. & HOTZ, P. (2004) INFLUENCE OF MAGNIFICATION TOOLS ON THE RECOGNITION OF SIMULATED PREPARATION AND FILLING ERRORS. *SCHWEIZERISCHE MONATSSCHRIFT FÜR ZAHNHEILKUNDE* 114:890-896.

# 5

## 5 Restorative and prosthodontic Dentistry

Author: **Prof. Dr. Claudia Cia Worschech**  
**Dr. Maxim Stosek**

- 135 **Why use the surgical microscope in restorative and prosthodontic dentistry?**
- 136 **Prevention and diagnosis**
- 137 **Bacterial plaque**
- 138 **Caries**
- 142 **Fractured line – “cracks”**
- 148 **Preparation control**
- 150 **Matrix adaptation**
- 153 **Rubber dam applications in anterior and posterior areas**
- 154 **Cervical lesions**
- 156 **Finishing and polishing**
- 160 **Possibilities for analyzing the surgical field at different magnifications**
- 164 **Replacements – avoiding wear**
- 166 **The Tunnel preparation technique**
- 168 **Indirect restorations**
- 172 **Instruments**
- 174 **Excellence in operative and prosthetic dentistry with regard to communication with patients**
- 176 **References**



## Why use the OPMI in Restorative and Prosthetic Dentistry?

This is one of the first questions asked by the dentists who are not endodontists.

Modern dentistry is based on precision, and precision is an absolute must to achieve high quality standards. Why was the use of the OPMI use in dentistry limited to the endodontic specialty for many years? No other specialty has made such intensive use of the OPMI as this branch of dentistry. However some form of magnification is indicated in all fields of dentistry and should be utilized by all dentists, in all areas. All restorative procedures have become more complex, more sophisticated and require more focus and attention. New materials and techniques have been developed in recent years and are continuing to improve on a daily basis. In conjunction with the development of new materials and techniques there has been a massive incorporation of technology in the profession.

Dentistry today demands the intensive utilization of computers and many other new technologies to aid the management of all the clinical information, digital documentation and record-keeping generated during the diagnosis and execution of clinical cases. As a direct consequence of all this technological development and the incorporation of new materials and techniques, dentistry today demands a multidisciplinary approach in contrast to the unilateral perspective of the past. Different treatment modalities can be presented and performed for the resolution of one specific clinical situation due to the many valuable treatment options available.

The OPMI can be used for the whole spectrum of restorative procedures. Nowadays, the OPMI is an “innovative” way to see and to do dentistry. It enhances the quality of the treatment procedure by permitting enhanced viewing of the surgical field thanks to the quality, direction and intensity of the light as well as the magnification process. It is much easier to achieve excellent results if the surgical area is clear. The current treatment philosophy is to prevent and detect dental disease at the earliest stage in order to avoid invasive treatment.

With the current understanding of the nature of dental disease and its process, the treatment philosophy is now changing to a more conservative approach, and the concept of minimal intervention is gaining popularity in modern dentistry throughout the world. When intervention is indicated, the less invasive techniques such as preventive resin restoration and minimal cavity preparation are utilized. Early diagnosis can allow minimally invasive treatments to be performed, thus preserving tooth structure. In the long term, this conservative approach should lead to fewer complications such as tooth fracture and pulpitis.

Besides caries detection and the minimally invasive approach using resin or other kinds of materials such as ionomers, many points are important to allow the maximum longevity of the restorations. Direct or indirect and marginal integrity is the first point to be analyzed for measuring this success. If margins display gaps and excessive material, longevity could be affected due to microleakage. During this chapter we will show you how you can view every step in operative dentistry and prosthodontics and show you that magnification is the way to the future.

Figure 5.1

## Prevention and diagnosis

Careful examination and correct diagnosis are the prerequisite of any dental professional. This requires clear visualization of the both hard and soft tissues. The OPMI is very helpful in many different specialties including restorative dentistry and prosthodontics. Figures 5.1 to 5.8 illustrate how every detail becomes very sharp and clear.

## Bacterial plaque

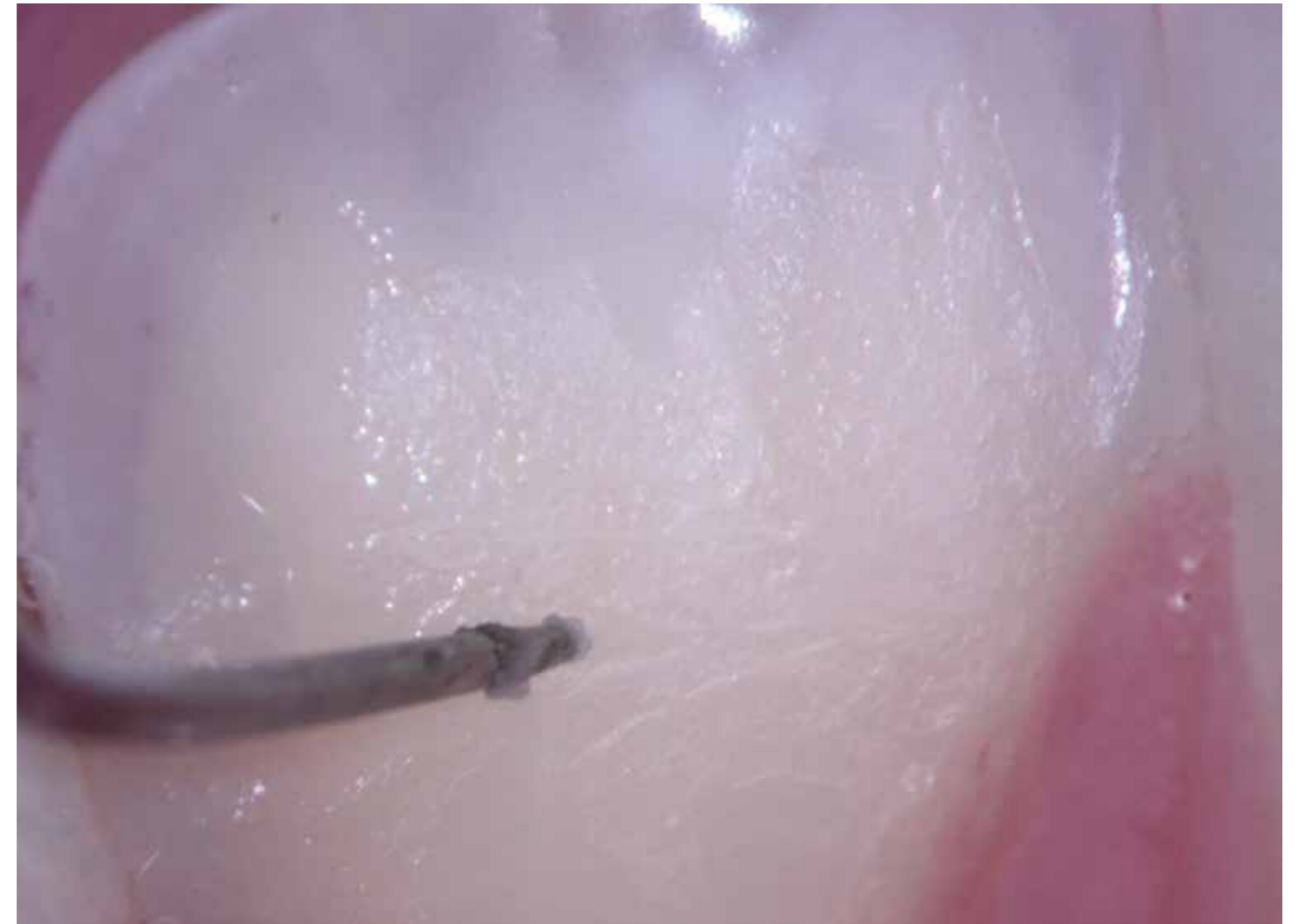

Figure 5.2: Plaque in the labial area.

Many imperfect surfaces provide a favorable site for residue and plaque deposition. This process promotes the development of caries and periodontal diseases. Imperfect surfaces like rough or overcontoured surfaces can shorten the longevity of direct or indirect restorations. The cavity preparations, restorative procedures and finishing process adopted are considered "key factors" for the long-term success and aesthetic outcomes for all restorations.

Achieving a smooth tooth restoration interface clinically to aid the cooperative motivated patient in biofilm removal is an essential prerequisite to prevent further secondary caries and improve the longevity of all restorations.

# Caries

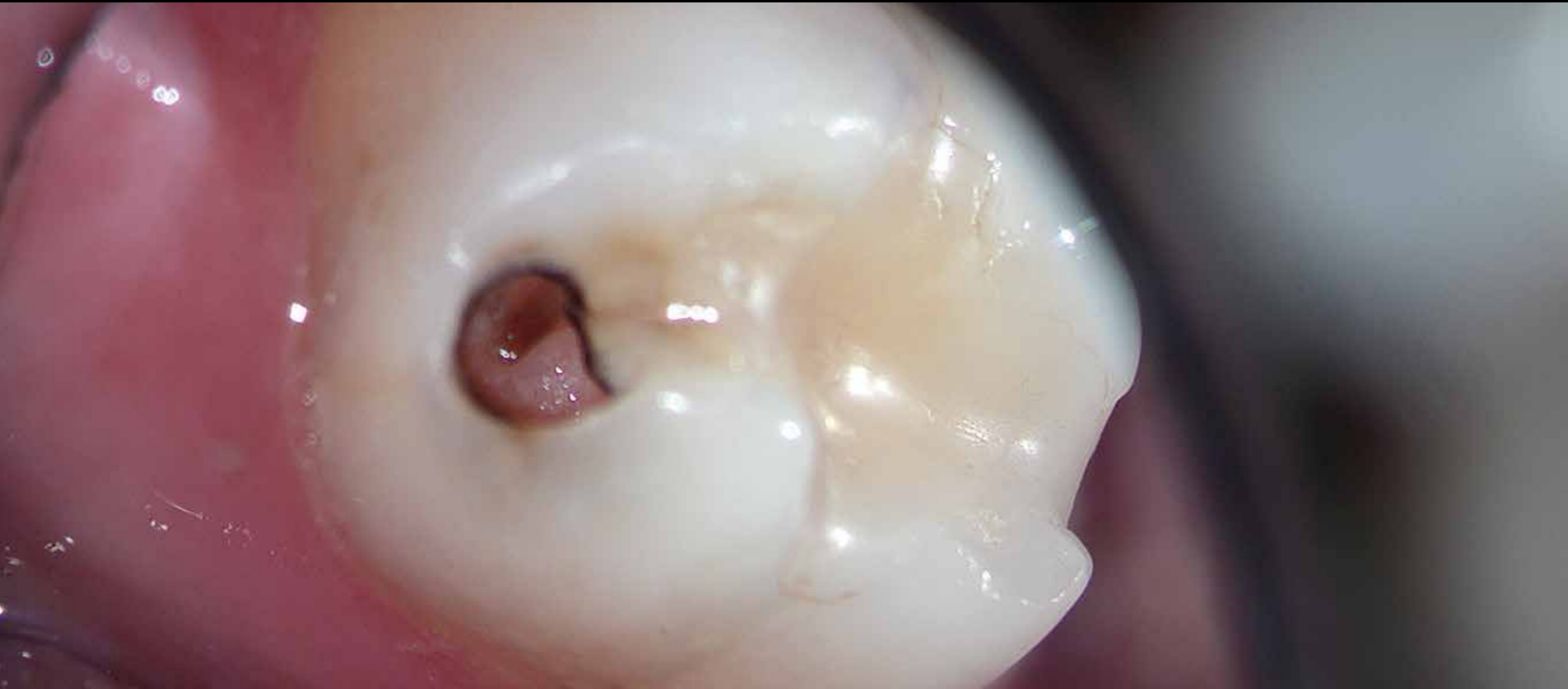

Figure 5.2: Occlusal caries viewed at high magnification in lower molar

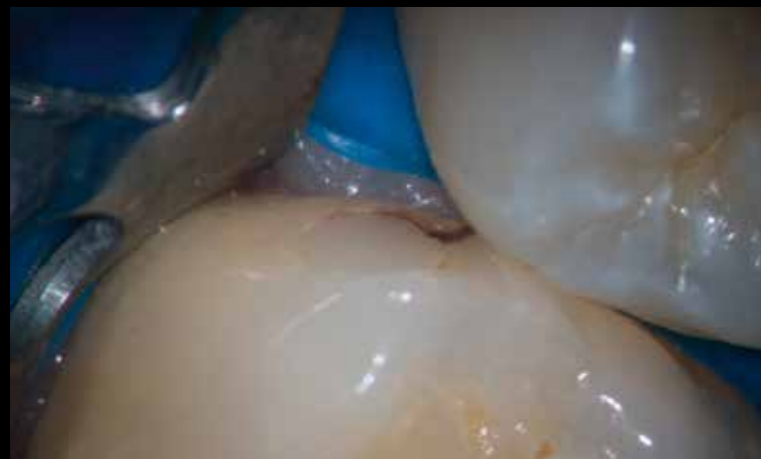

Figure 5.3: Approximal and secondary caries

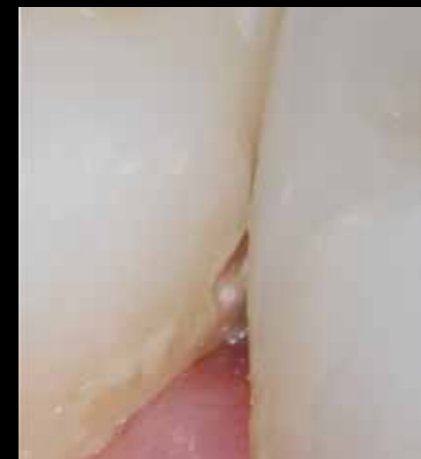

Figure 5.4: Approximal caries on distal wall, first upper molar plaque accumulation

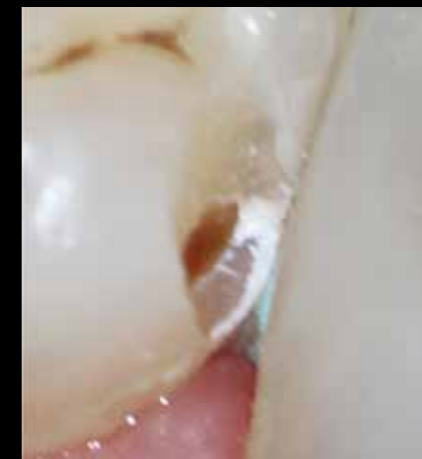

Figure 5.5: Caries opening

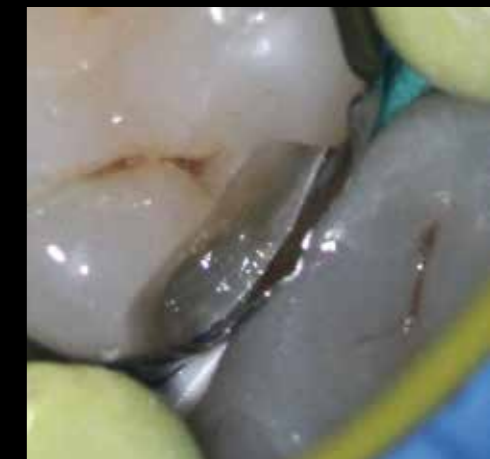

Figure 5.6: After the caries removal and matrix adaptation

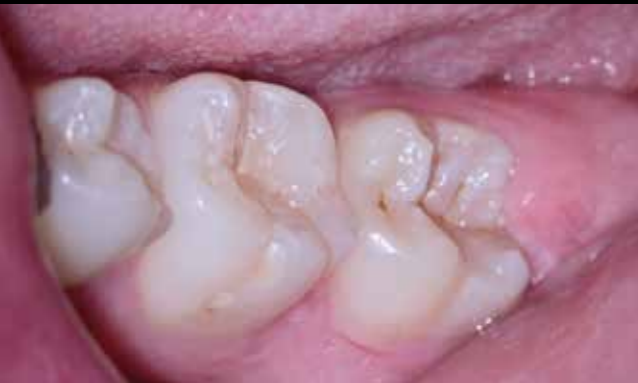
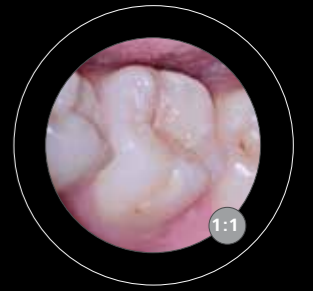
Figure 5.8a

Figure 8a, 8b,8c: Non-caries stain at different magnifications ( low, medium and high)

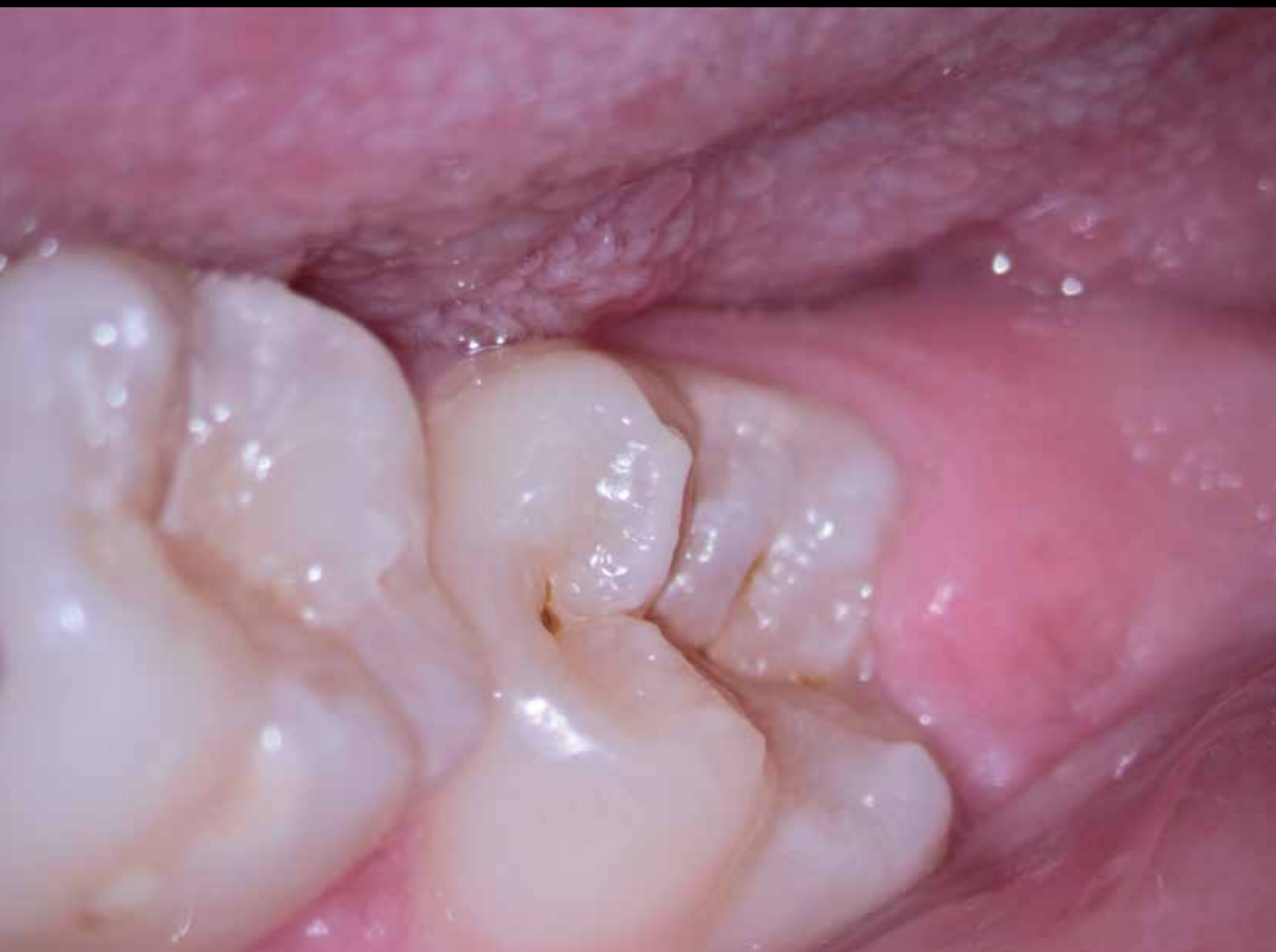

Figure 5.8b

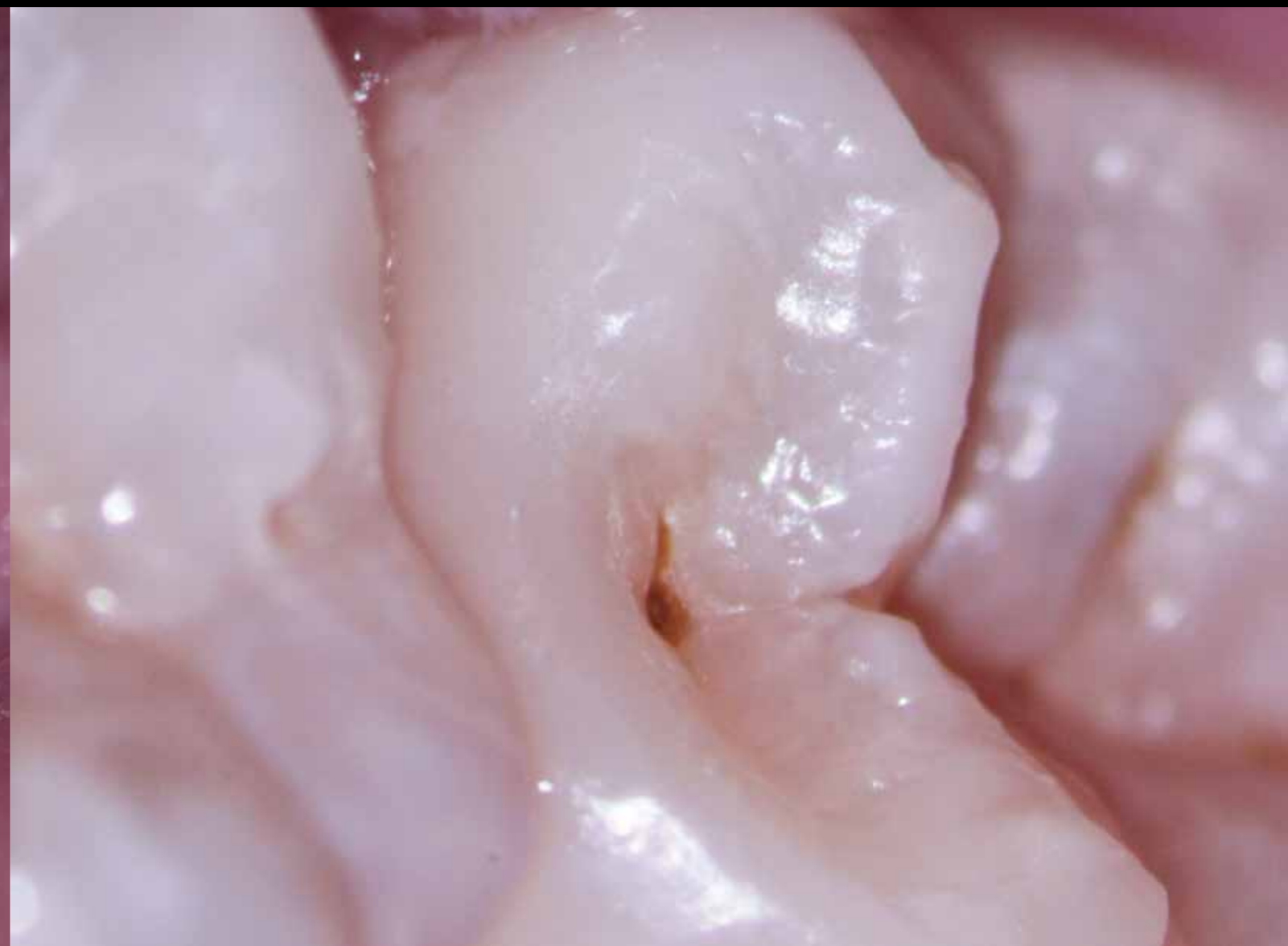

Figure 5.8c

## Fractured line – “cracks”

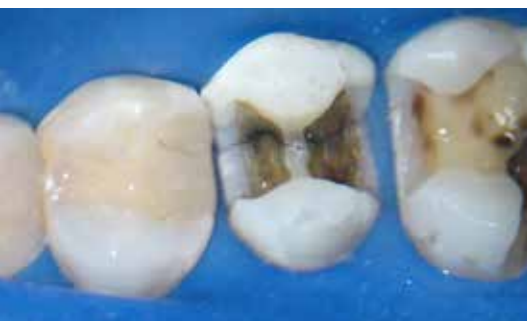

Figure 5.9a

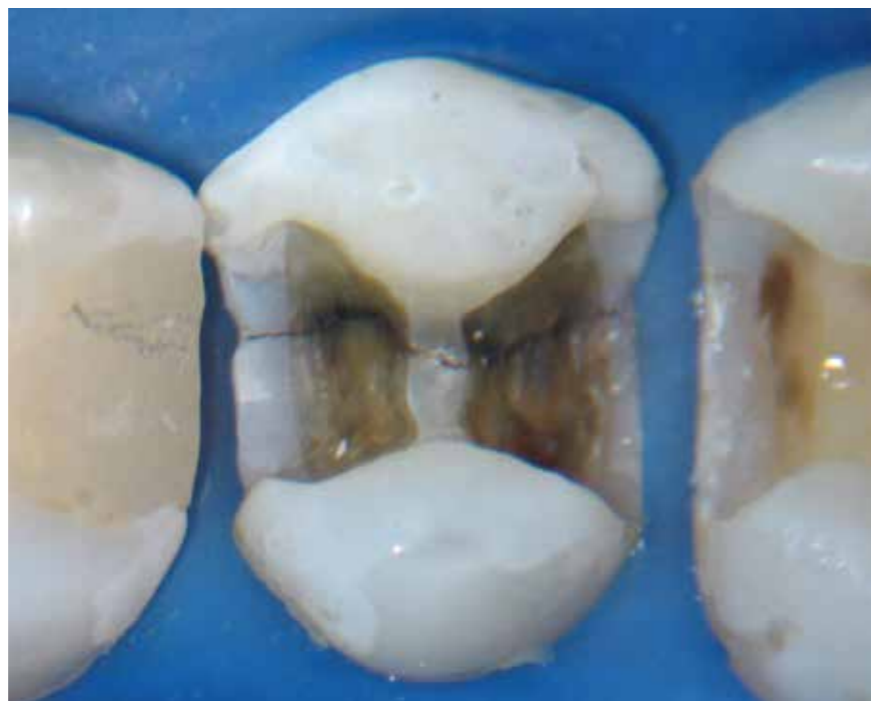


Figure 5.9b

Clinicians have had the ability to observe cracks under extreme magnification for nearly a decade. Patterns have become clear that can lead to appropriate treatment prior to symptoms or before devastation of tooth structure occurs. Conversely, many cracks are not structural and can lead to misdiagnosis and overtreatment.

Methodical microscopic examination, an understanding of crack progression, and an appreciation of the types of cracks will guide the dentist to making appropriate decisions. Teeth can have structural cracks at various stages. To date, diagnosis and treatment have very often been made at a late stage of the crack.

Without the information provided by microscopic inspection at high power, many teeth with structurally significant cracks would have been treated only when they were symptomatic. This can result in more complicated, involved treatment, or even a catastrophic event that leads to tooth loss.

Most of these superficial fractures are relatively undetectable without magnification, but when viewed under high power, hairline cracks appear as crevasses.

Figures 5.9a, 5.9b and 5.9c:  
Fractured premolar viewed  
at low, medium and high  
magnification

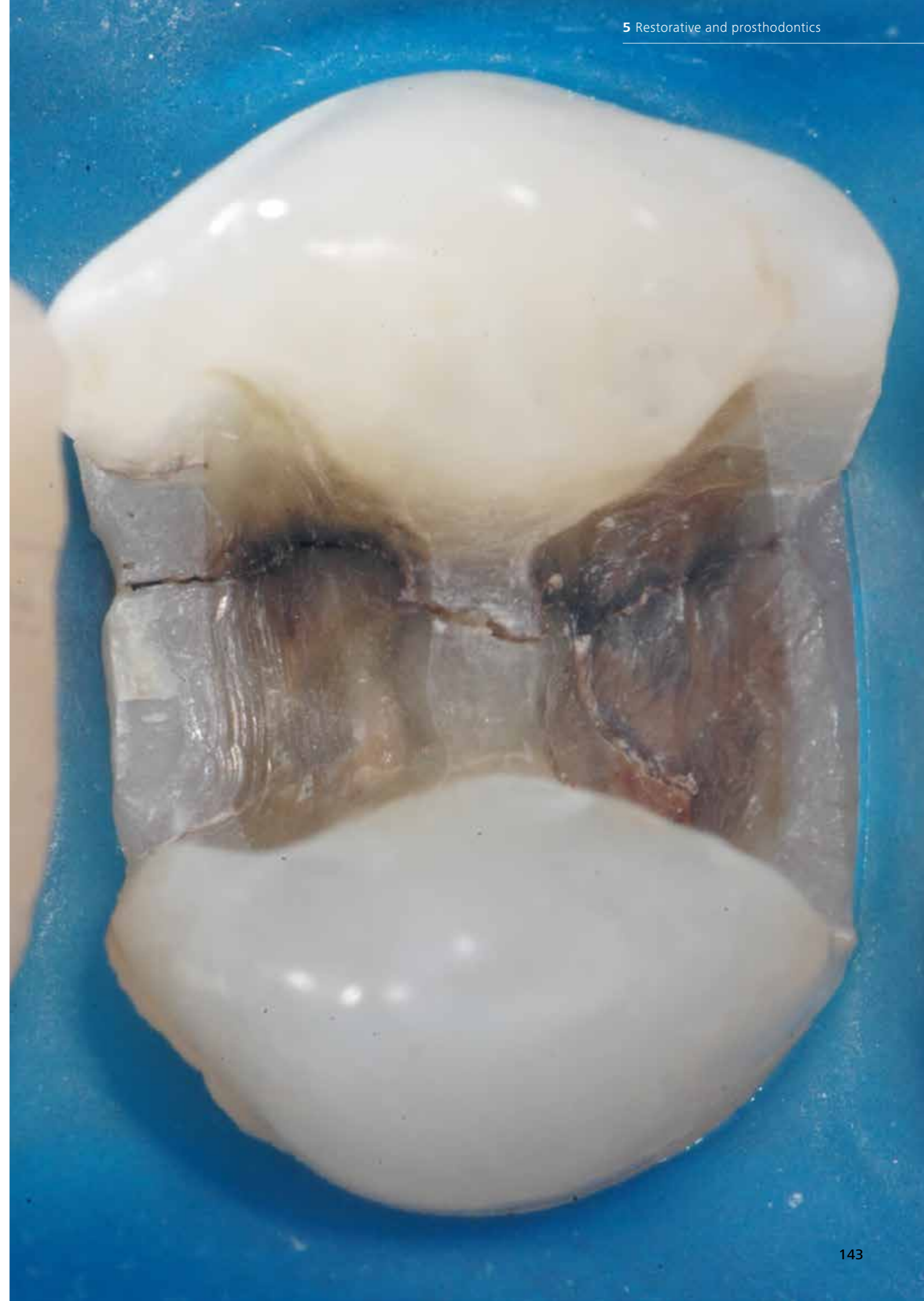

Figure 5.9c



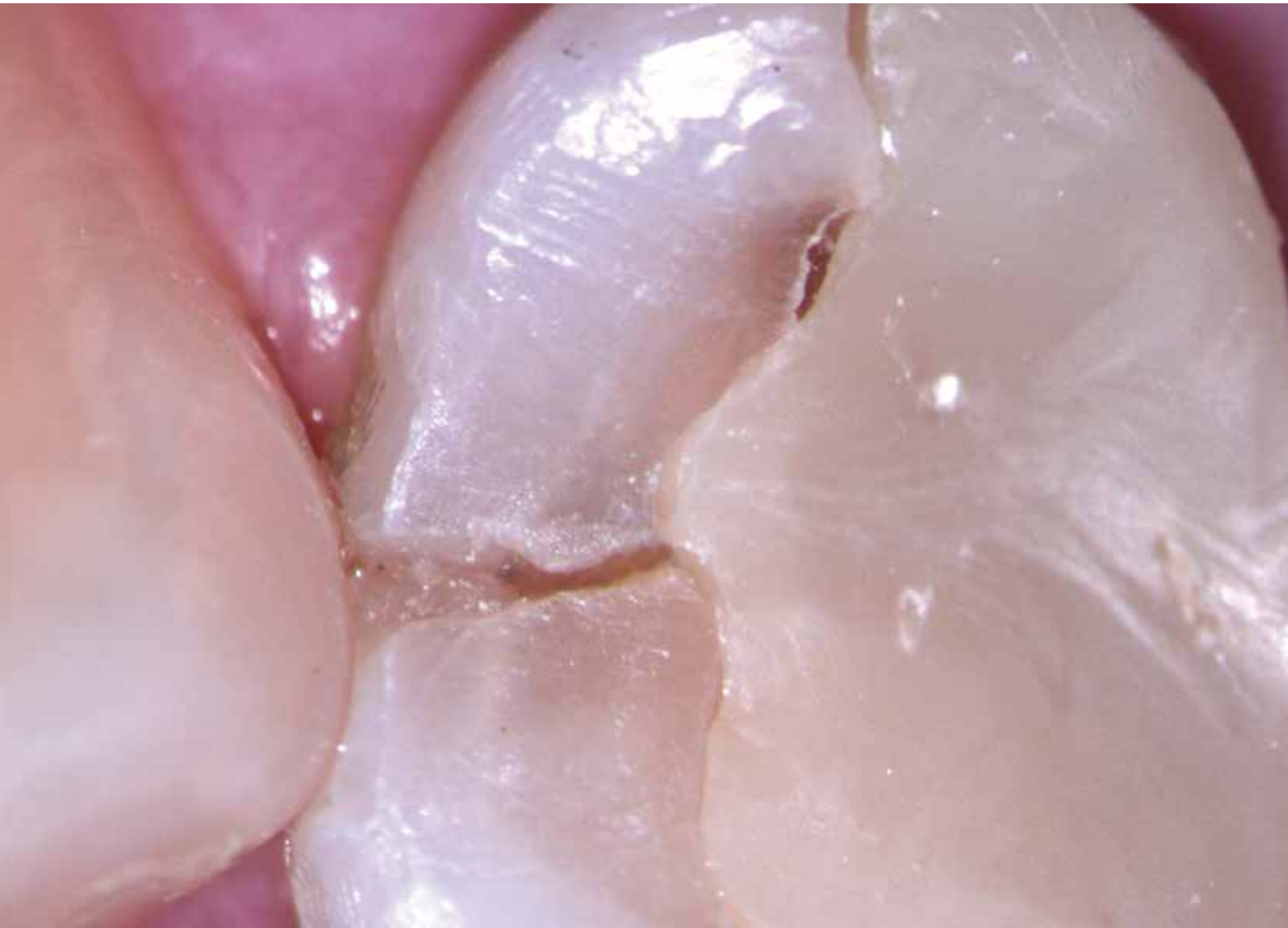

Figure 5.10 Fractured premolar

Many fractures like this are not observed without high quality light and magnification.

Cracks can occur in teeth restored with amalgam due to the physical and chemical properties of the restorative material (setting expansion, corrosion, coefficient of thermal expansion etc). The forces on the remaining tooth structure can cause deflection of the cusps, cracking and ultimately fracture of the cusps.

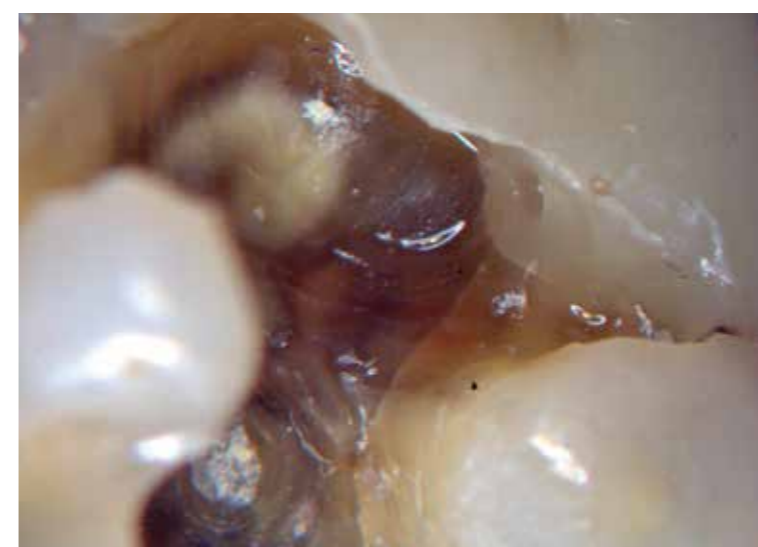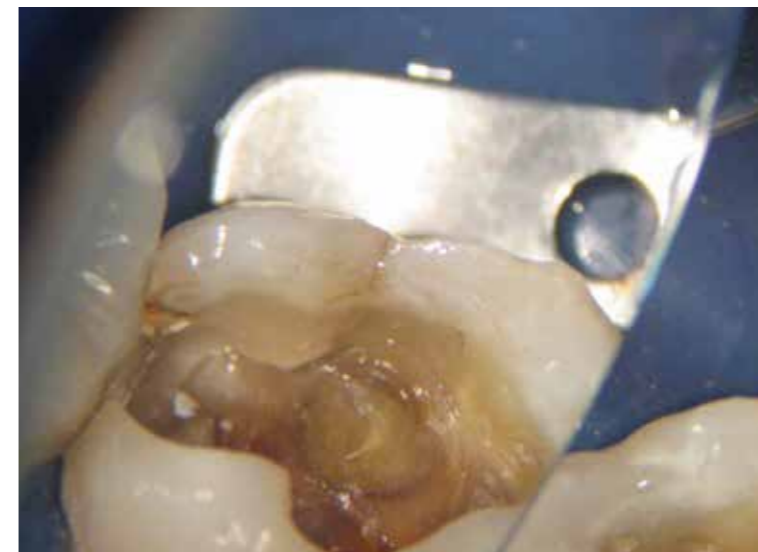

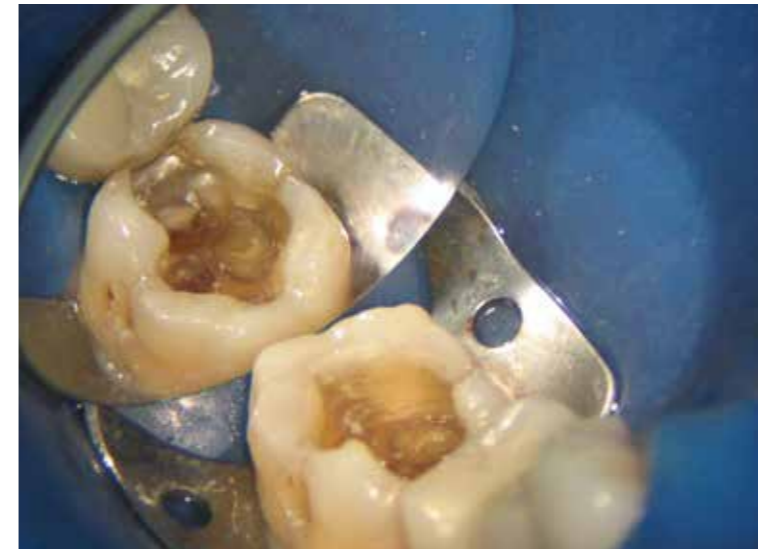
Figure 5.11 Molar presenting crack under the cusp (low magnification; medium magnification and high magnification).

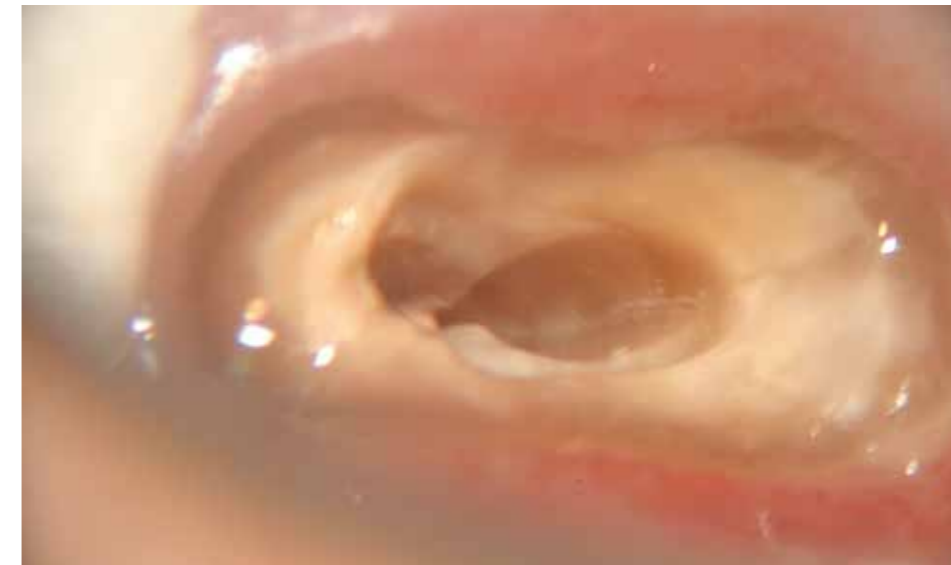
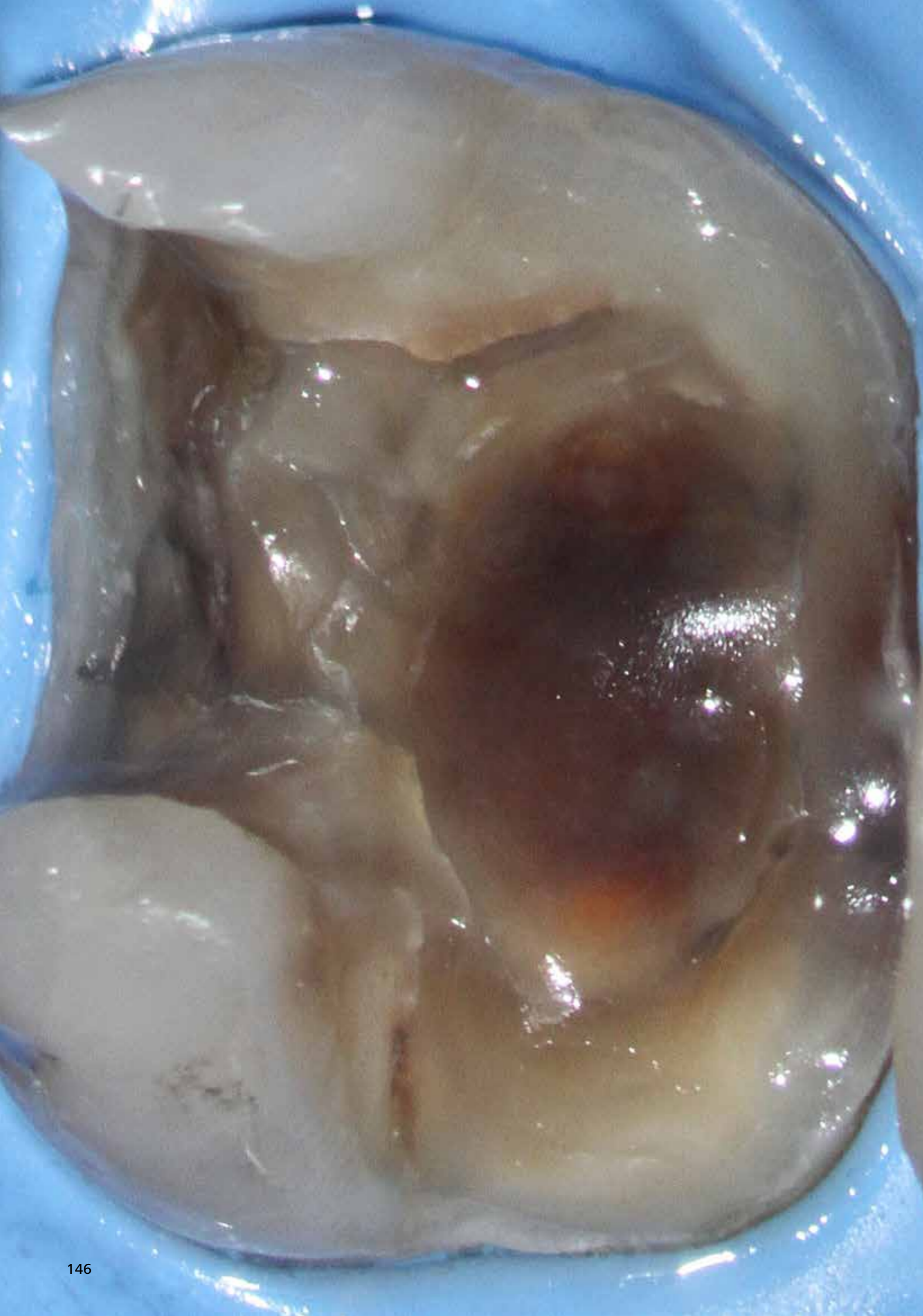


Figure 5.13: This image demonstrates the ability of the OPMI to show a vertical root fracture

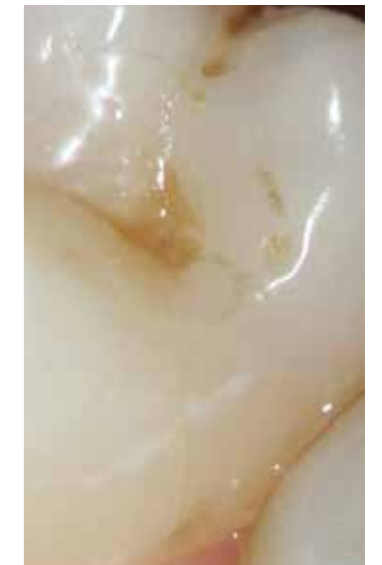
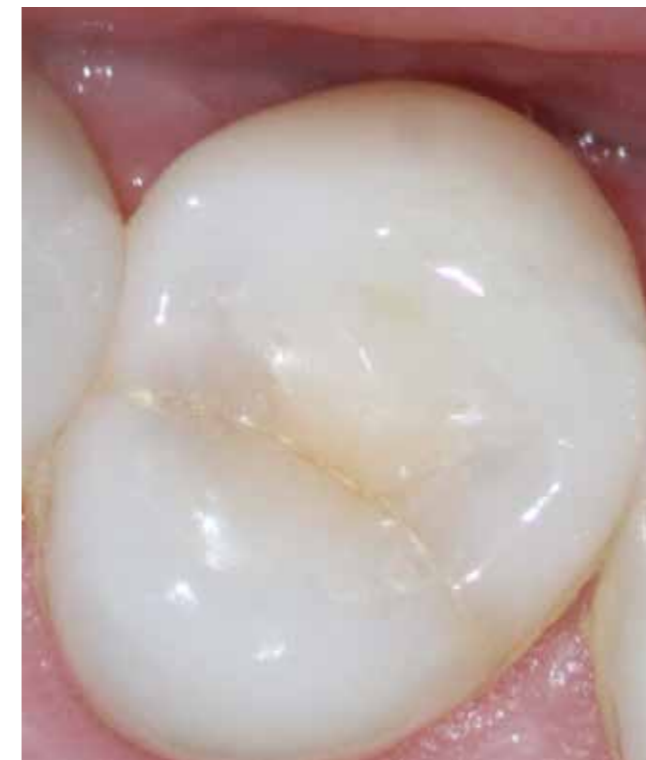
Figure 5.14: Cracked tooth syndrome. Note the enamel crack disto-palatally



Figures 5.15a Mesio-distal crack viewed with the aid of the operating light of the OPMI

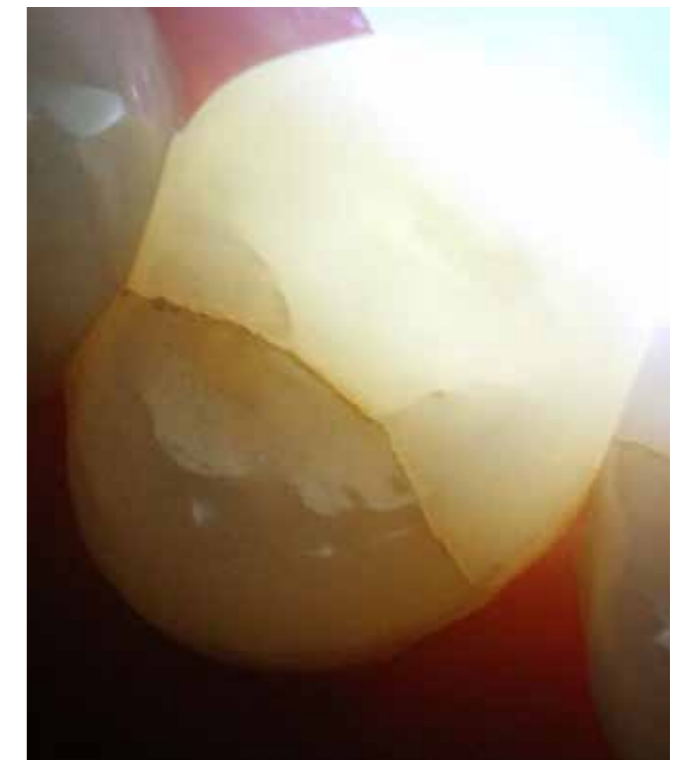
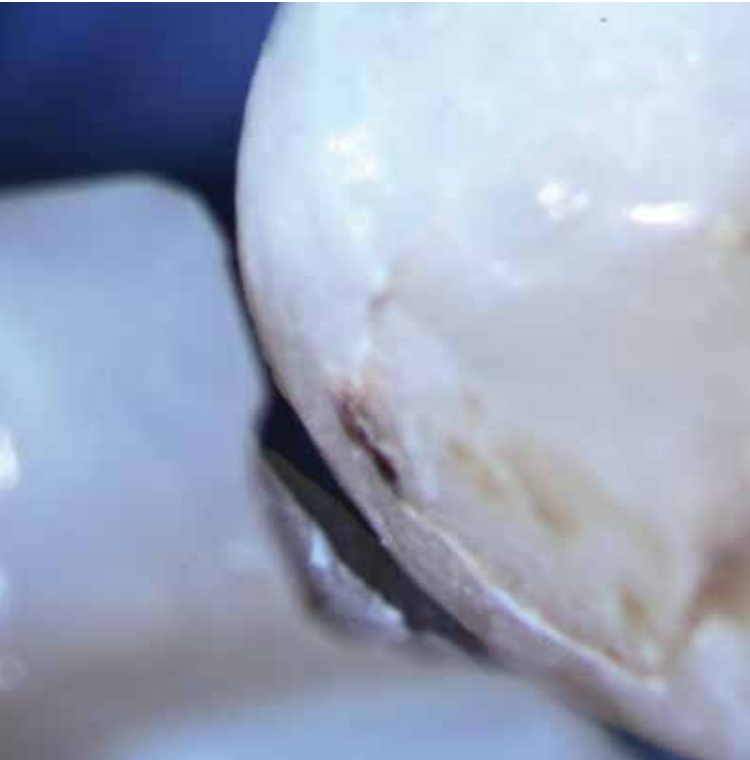
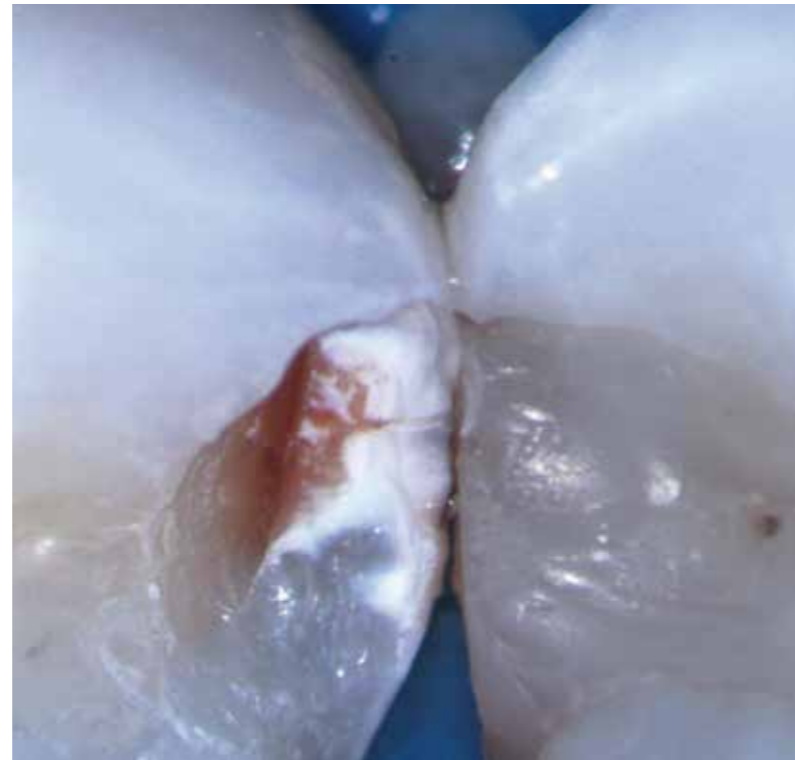Figure 5.15b The same crack viewed using transillumination

Figure 5.12 Fracture line in the floor of the cavity and under the cusp visible in high magnification.

## Preparation control



Figures 5.16a



Figures 5.16b

*Figures 5.16a and 5.16b: Note recurrent caries reaching the dento-enamel junction and leakage around the restoration in the adjacent tooth.*

Magnification is really useful to avoid unnecessary destruction of healthy dental tissue because it is possible to see the boundaries between the restorative material and dental tissue in great detail. Without magnification, this cannot be seen with the same clarity leading to more extensive tooth preparation, loss of healthy tissue and potential damage to the pulp.

Preparation for indirect restorations are vastly enhanced with the aid of the OPMI as prepared surfaces can be finished with greater accuracy leading to better fitting restorations.

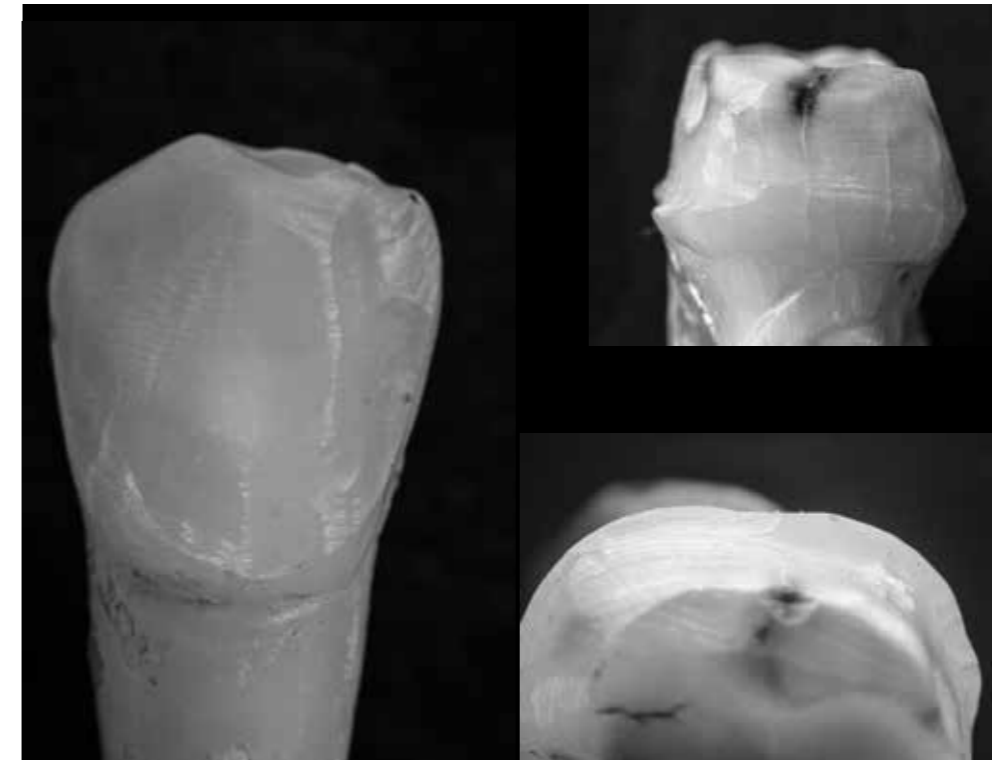


Figure 5.17a Without OPMI

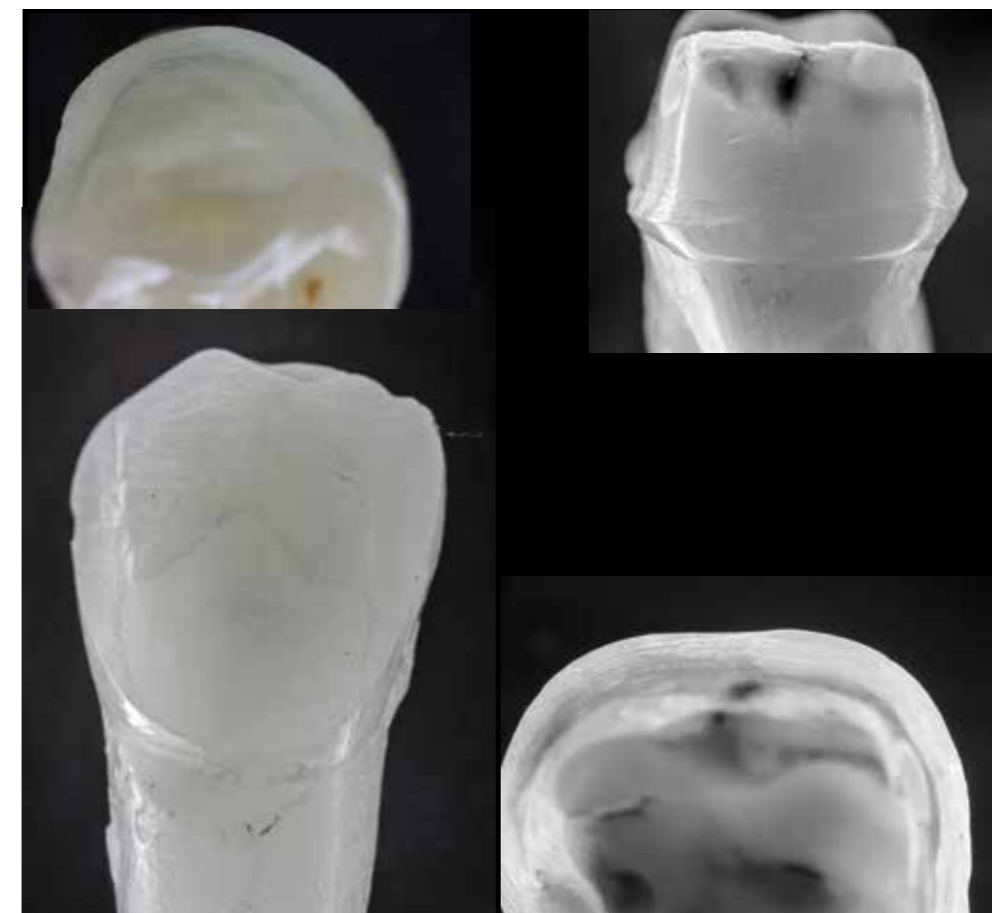

Figure 5.17b With OPMI

## Matrix adaptation



Figure 5.18a



Figure 5.18b

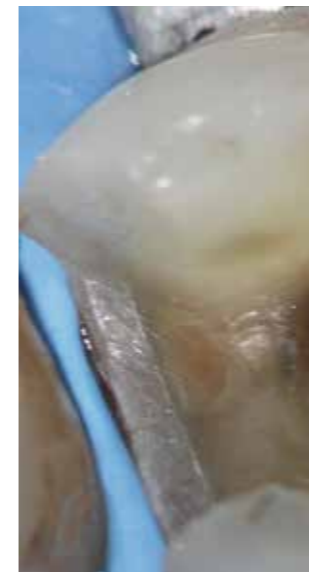

Figure 5.19a: situation before the matrix placement. Note the small space between the rubber dam slightly not adapted to the mesial wall of the cavity

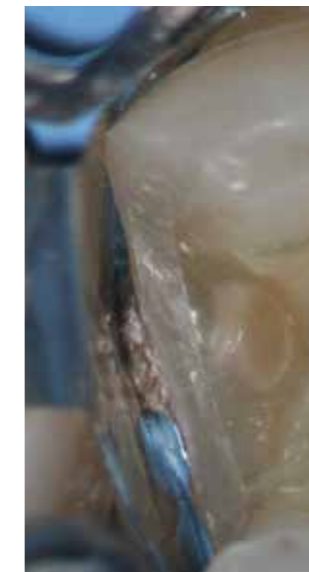


Figure 5.19b: subgingival calculus obstructing the correct placement of the matrix

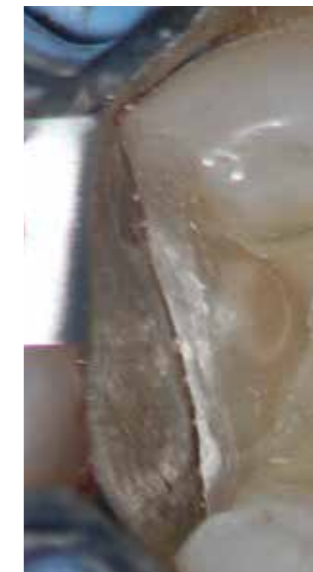

Figure 5.19c: Correct matrix adaption but note the decalcified enamel at the marginal line

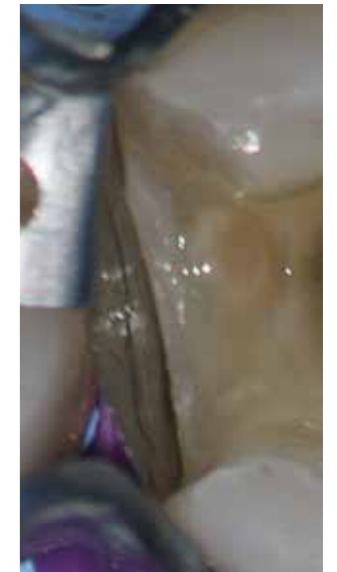

Figure 5.19d: Correct right matrix adaptation, after the final enamel preparation

When direct restorations are made, special attention needs to be paid to margins, especially dentine margins.

The biggest problems continue to be the adequate sealing of the margins and the correct contact point, for most kinds of restorations and independently of the materials used. (See Figures 5.18a - 5.19d).

Eliminating or reducing the gap formation on the gingival floor is a challenge.

The simple fact of working with cavities on opposite walls from dissimilar tissues like dentine and enamel creates intrinsic problems in itself. Managing their completely different adhesive behavior is one aspect that should not be overlooked.

Any excess or roughness of restorative material should be avoided. Plaque retention, gingival inflammation, and occurrence of carious lesions represent not only a failure of the restoration but also a creation of new problems to the patient. Techniques with minimum need of finishing and polishing are ideal, but properly contoured restorations are seldom achieved without the need to remove excess of material.

Figures 5.18a and 5.18b: Note the image on the left where the matrix band is not adapted

## Rubber dam applications in anterior and posterior areas

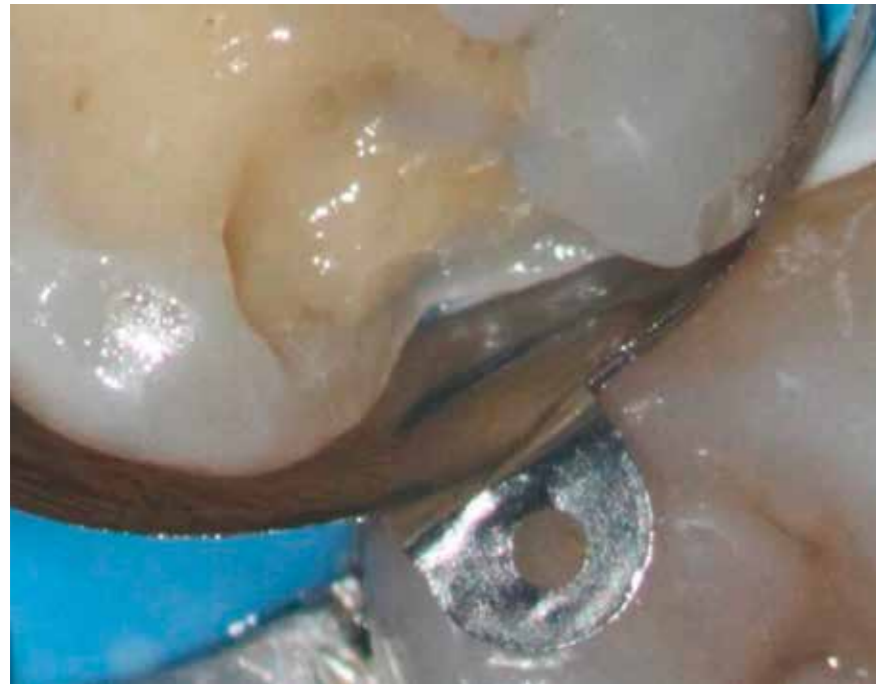

Figure 5.20: Note the poor cervical adaptation of the matrix and incorrectly shaped contact point

The cervical adaptation of the restoration is important. This defect can be illustrated with the scanning electron microscope image (fig 5.21), which shows us the imperfection on the approximal wall. A gap often results if the matrix is not correctly adapted. Clinically, we deduce why the restoration has failed. Because the interface between the tooth and the composite resin is not sealed, a gap emerges and the patient may feel pain or sensitivity. Sometimes the restoration has to be replaced.

Cervical enamel has an important impact on the performance of Class II composite restorations by improving strength and adhesive properties of the restoration.

Another critical factor associated with restorations in general and with indirect aesthetics restorations in particular is periodontal health, and for longevity of restorations the precision of the margins at the periodontal-restorative interface is required. Improper margins can cause overhangs and over-contouring that may ultimately result in caries, periodontal inflammation and breakdown, and compromised aesthetics. In order to prevent pathology at the restorative tooth interface, each phase of the aesthetic treatment must be performed with precision and care.

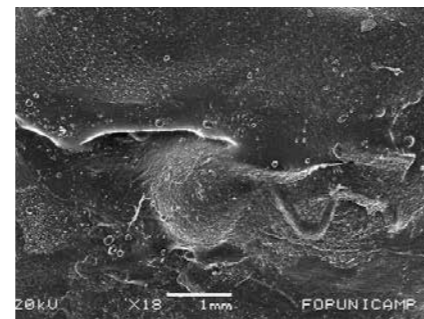


Figure 5.21: Through a scanning electron microscope it is possible to see a gap between the resin restoration and the tooth surface, probably because of incorrect matrix position and poor adaptation of resin against the matrix

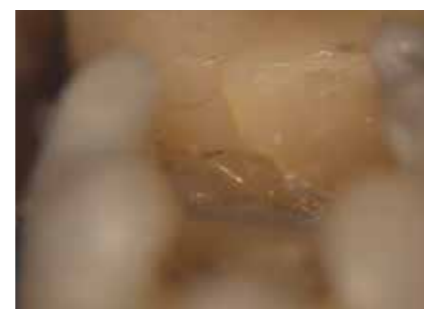

Figure 5.22: This image shows current lack of adaptation of resin restoration in mesial surface of molar

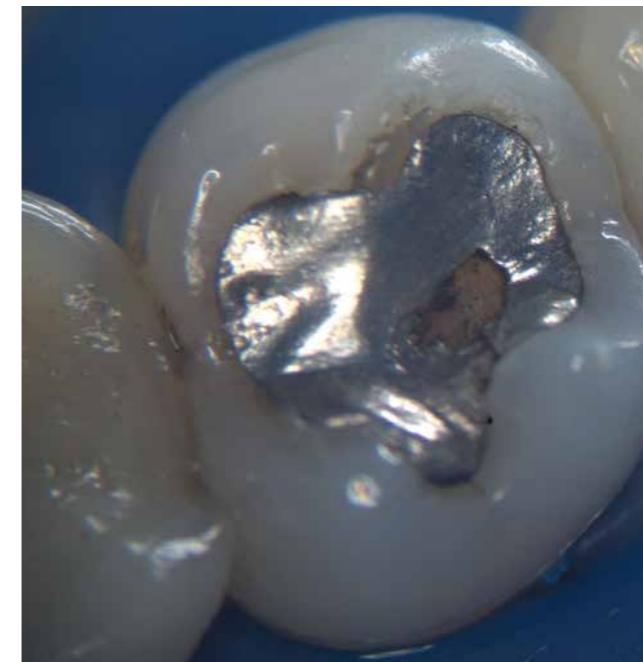

Figure 5.23

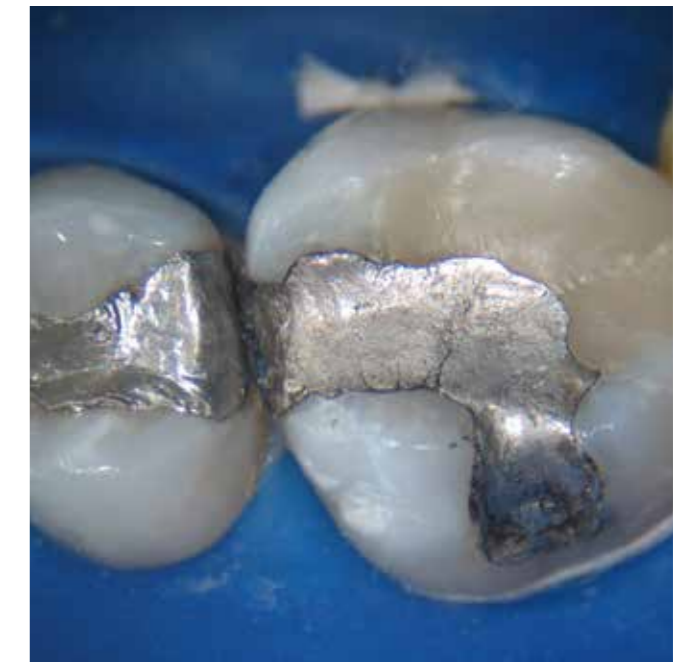

Figure 5.24

Figures 5.23 and 5.24 the correct insertion of rubber dam applications. In fact, the OPMI can be used during all procedures related to restorative and prosthodontics

Rubber dam can be used to achieve more effective isolation of the surgical field or for better insertion of a retraction cord, thus avoiding bleeding. Figures 5.23 and 5.24.

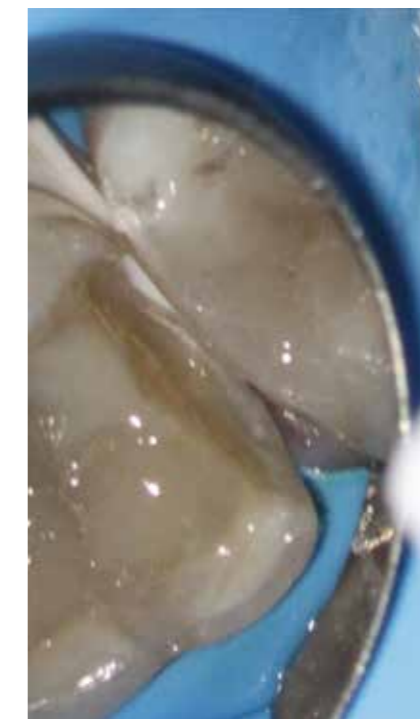

Figure 5.25 Note the imperfect application of the rubber dam, clearly visible under magnification

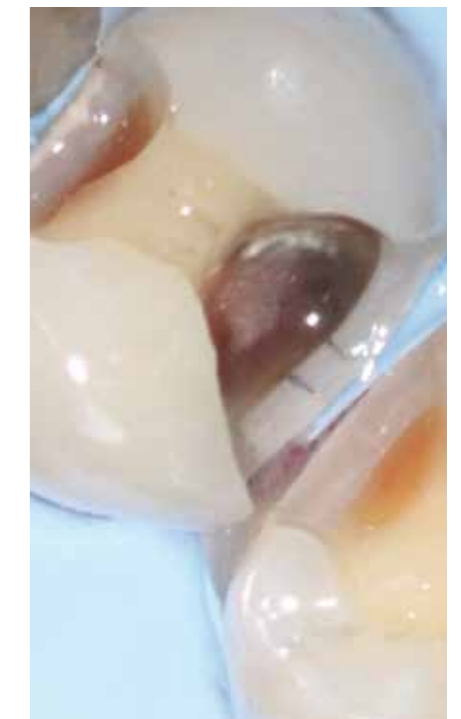

Figure 5.26

## Cervical lesion

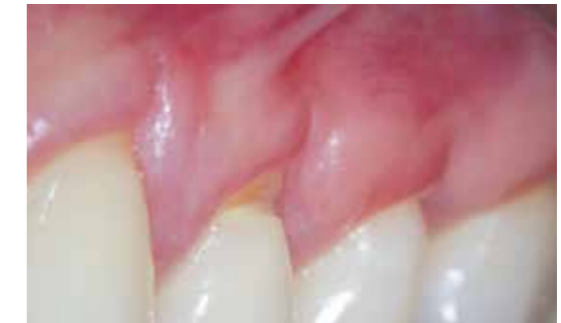
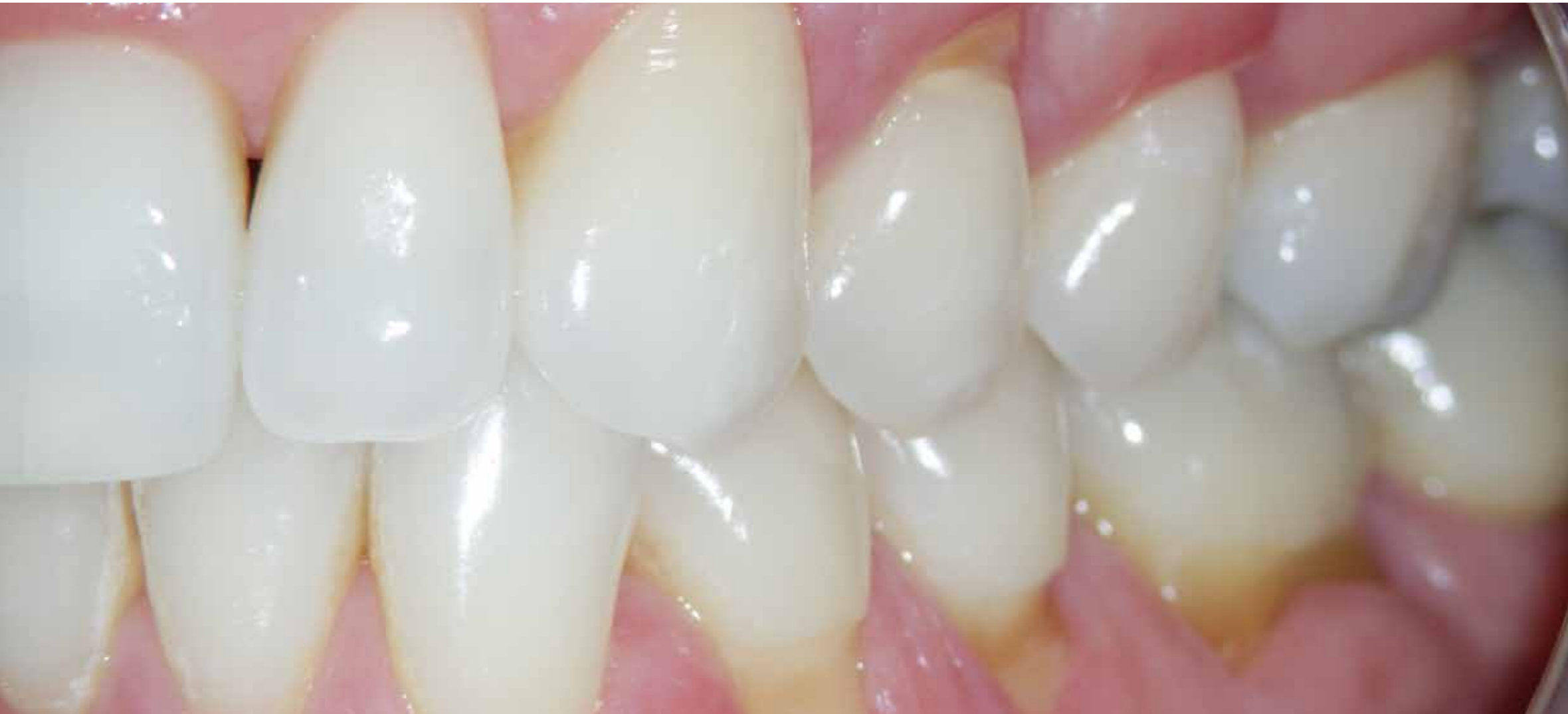
Figure 5.28

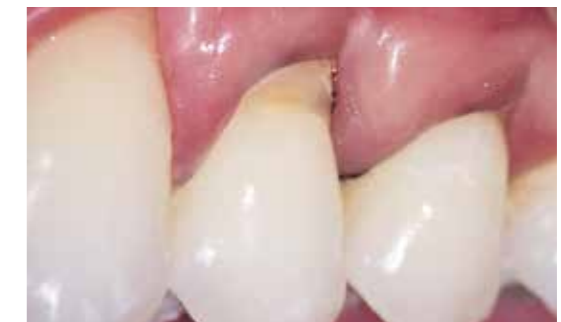

Figure 5.29

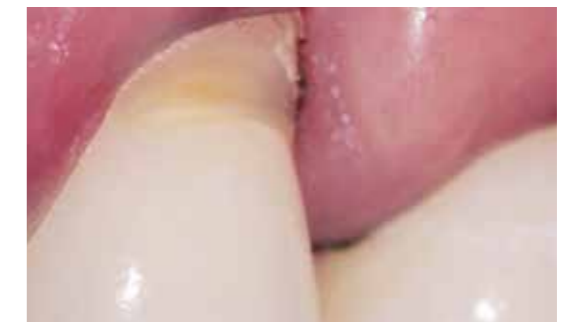

Figure 5.30

Cervical lesion can be viewed perfectly through the OPMI - from minimal to pronounced lesions involving pulp inflammation. Attention should be given to non-carious lesions in cervical areas. Cervical restorations need to be very well adapted because they can lead to an increase in the level of plaque, potentially resulting in secondary caries and periodontal disease.

Proper rubber dam isolation is very difficult, sometimes impossible, when lesions extend approximally or subgingivally. Sometimes part of the structure cannot be isolated and the dam promotes accumulation of the restorative material. Access is also limited, causing problems related to insertion of the restoration. When adequate rubber dam isolation is not possible, an alternative method of isolation (i.e. cotton rolls) has to be employed. See Figures 5.26 - 5.31

*Figures 5.26 - 5.31: Non-carious lesions were viewed at low, medium and high magnifications. Note the presence of calculus around the lesion on the cervical surface. This calculus should be removed before the resin insertion. Magnification was essential to allow correct viewing and removal*

Figure 5.26

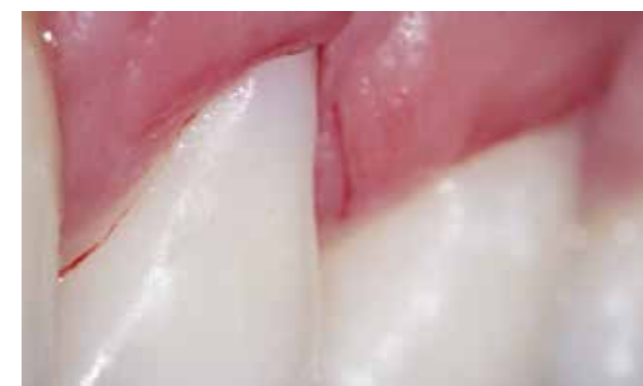

Figure 5.27

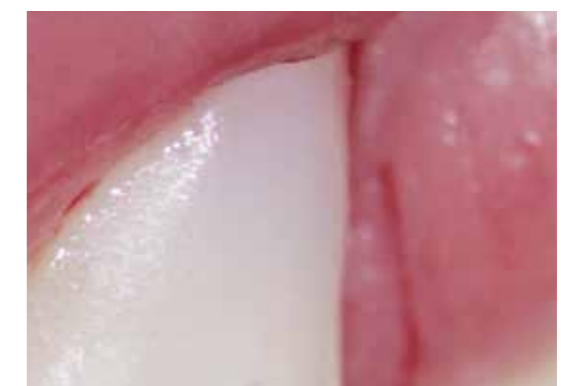

Figure 5.31

## Finishing and polishing

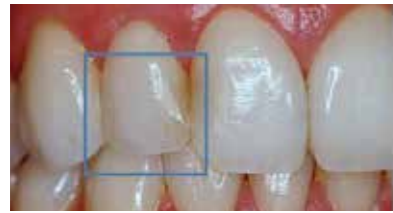

Figure 5.32a

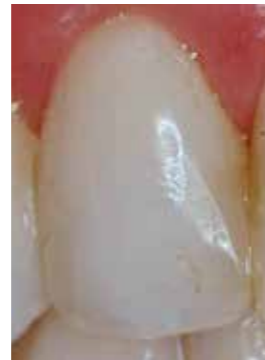

Figure 5.32b




Figure 5.33




Figure 5.34 Through the scanning electron microscope this excess of material is viewed easily and concur with the images provide through the OPMI

Figure 5.32a - 5.32b: These images showed direct restorations after polishing, without OPMI usage. Note that a certain amount of resin was kept over the surface, toughening the gingival margin. This could not be seen without magnification, but was clearly visible under the OPMI

The clinical case below showed how important it is to remove and clean residues around composite resins. Gingival irritation and marginal tissue inflammation could be avoided using simple procedures and thanks to the high-precision view of the surgical field enjoyed by the dentist.

Most of the time, patients are not as discriminating in their ability to identify small color differences between composite restoration and tooth as dental professionals. On the other hand, all patients notice when restorations are not accurate, when there is a gap,

or when dental floss remains jammed between the teeth. Here, the OPMI can help dentists and technicians to achieve precision in restoration margins of direct or indirect restorations.

When adhesive material accumulates near gingival tissue, inflammation may result, and pain and discomfort could require replacement of the restoration. Aesthetic restorations can be harmful due to imperfect finishing of margins, resulting in pigment retention and an unattractive appearance. In most clinical cases of this kind, these restorations have to be replaced in an attempt

to improve the appearance and health aspects. In many cases, these restorations have to be either replaced, resulting in the potential further destruction of healthy tissues, or adjusted to improve the existing result. Adjustment can be very challenging especially in areas where the access is difficult. A good gingival displacement and the use of enhancing optical devices are indicated. See Figures 5.32 - 5.41 for images showing perfect and imperfect polishing, reflecting light zone, etc.

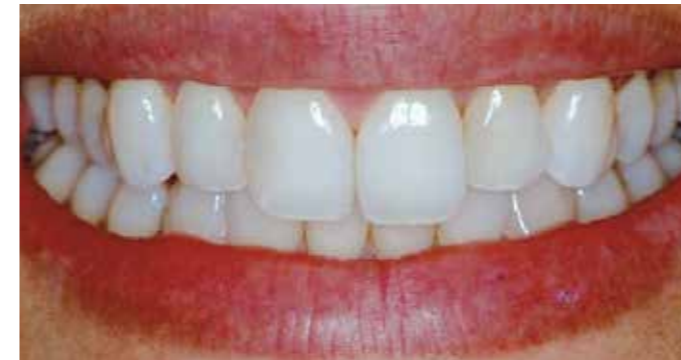

Figure 5.35a

Figures 5.35a and 5.35b: This clinical case exemplifies the resin restoration which was polished without an OPMI

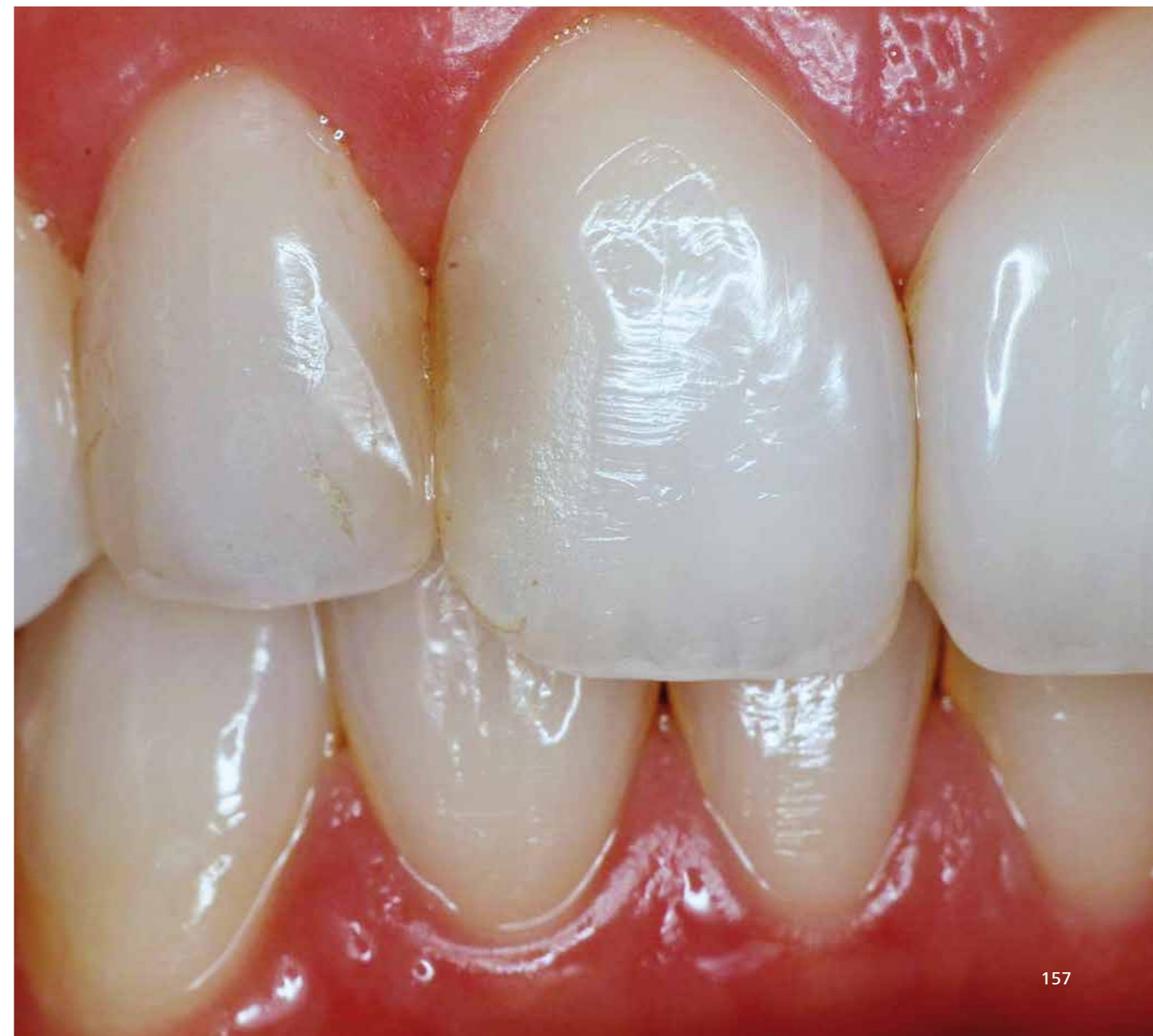
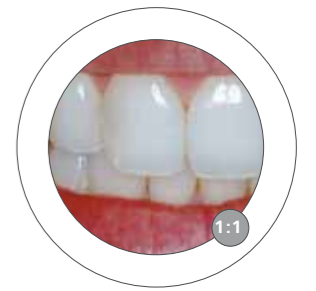
Figure 5.35b



Figure 5.36




Figure 5.37

Figures 5.36 and 5.37: At high magnification you can see details of irregular surfaces after polishing (left). The image through a scanning electron microscope shows the rough surface on an incisal area

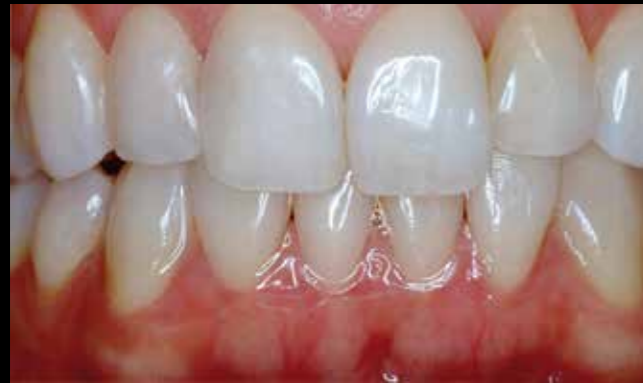

Figure 5.38a

Figures 38a and 38b: Restoration was re-polished. Note the much smoother surface

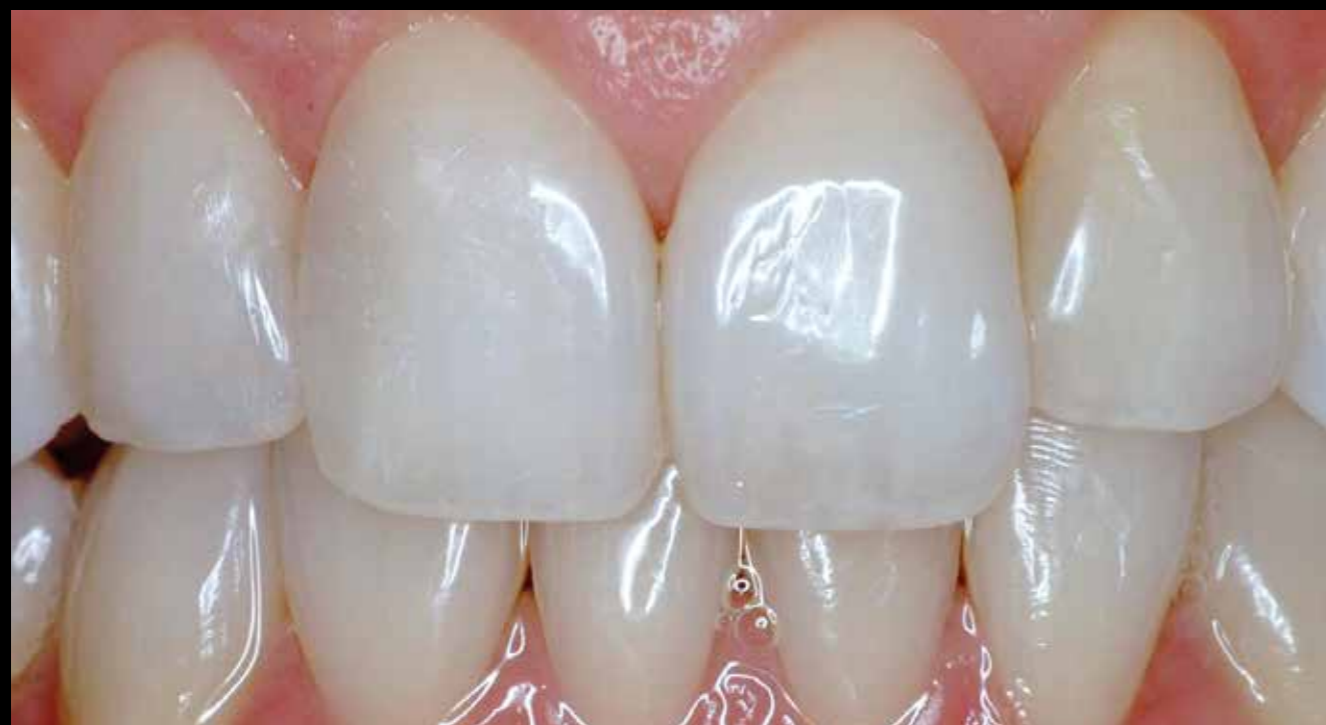

Figure 5.38b



Figure 5.39




Figure 5.40

Figures 5.39 and 5.40: Close-up of texture and polishing on the left. On the right you can see the image captured through a scanning electron microscope



Figure 5.41a

Figures 5.41a and 5.41b: Note the polishing after bracket removal. All resin used to bracket fixation was removed without damage to the enamel

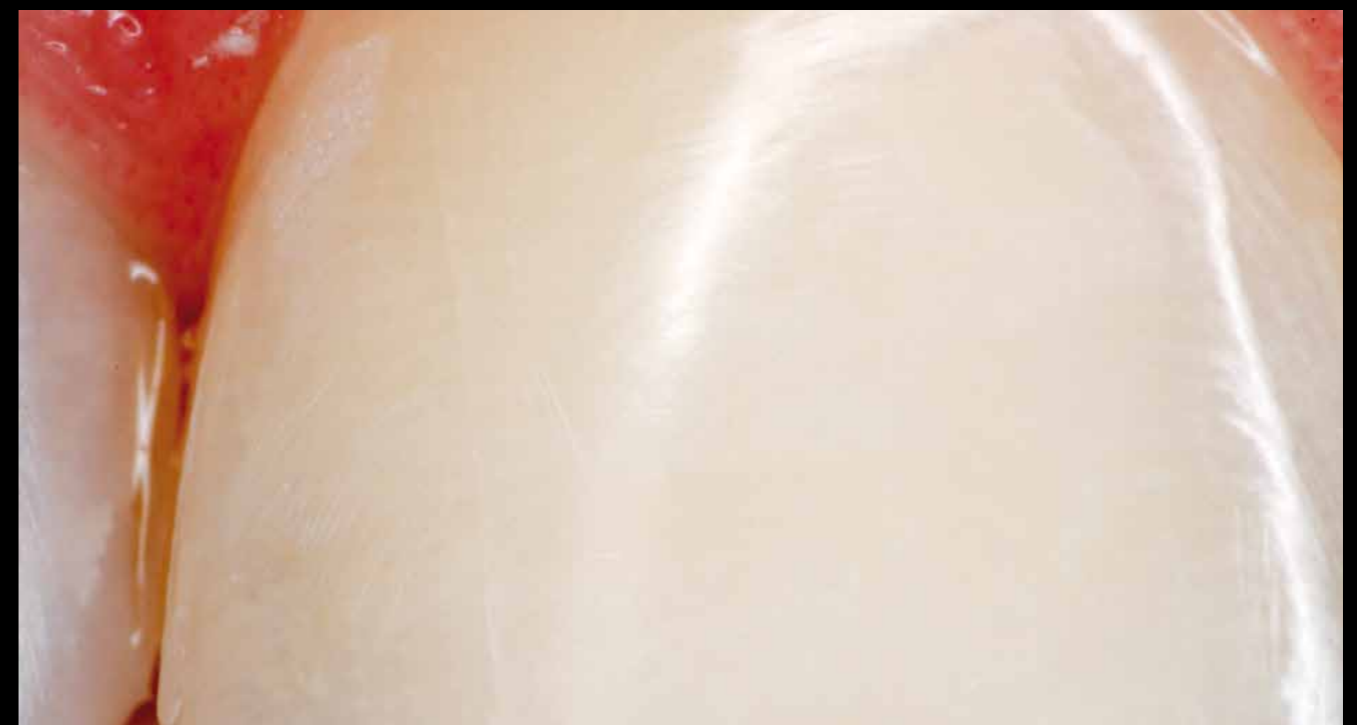

Figure 5.41b



## Possibilities for analyzing the surgical field at different magnifications

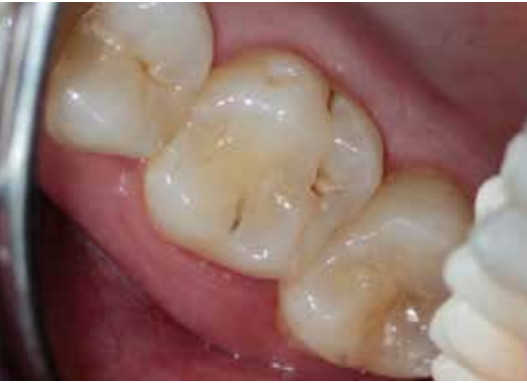

Figure 5.42a

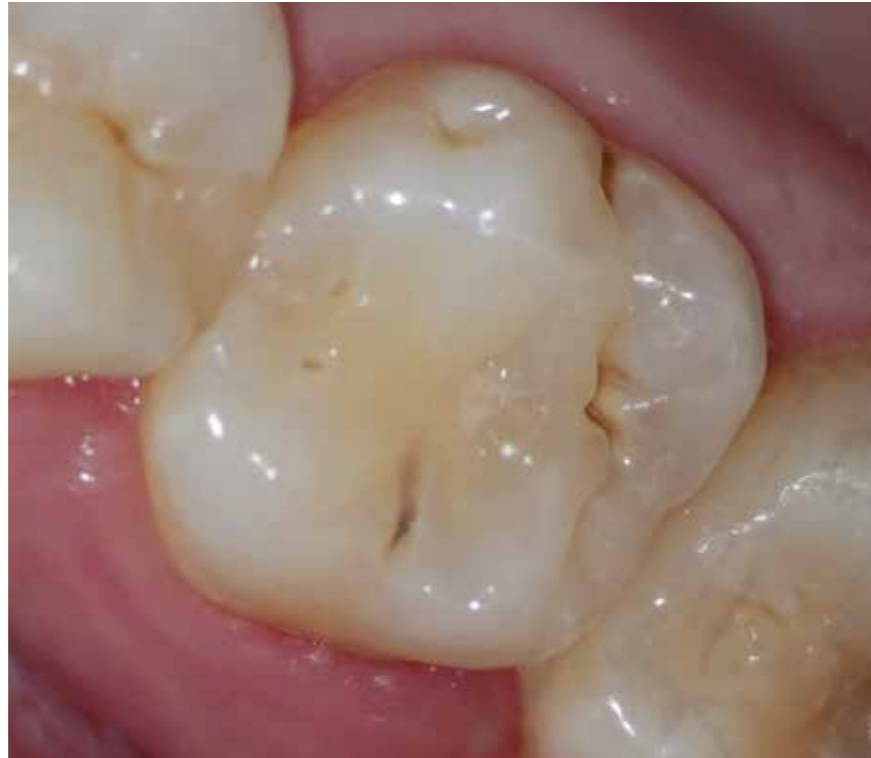

Figure 5.42b

Working with the OPMI provides many possibilities for viewing the surgical field. This is one of the most important advantages offered by OPMI, besides excellent quality of light. See Figures 5.42a - 5.42c. In restorative and prosthodontic dentistry it is very important because the dentist can see much more than the tooth that is being treated.

Figures 5.42a, 5.42b and 5.42c:  
Surgical field at low, medium and high magnifications

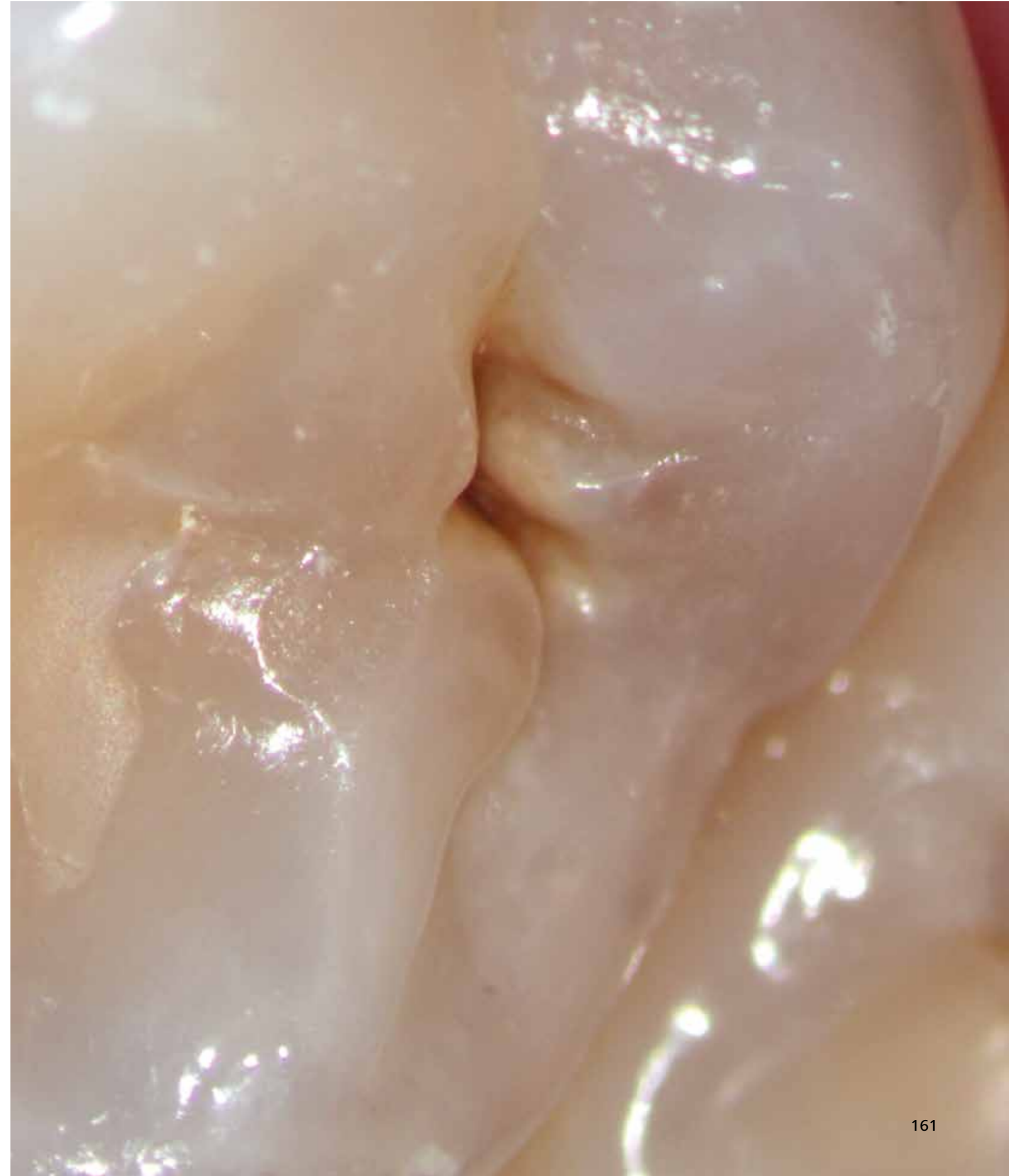

Figure 5.42c

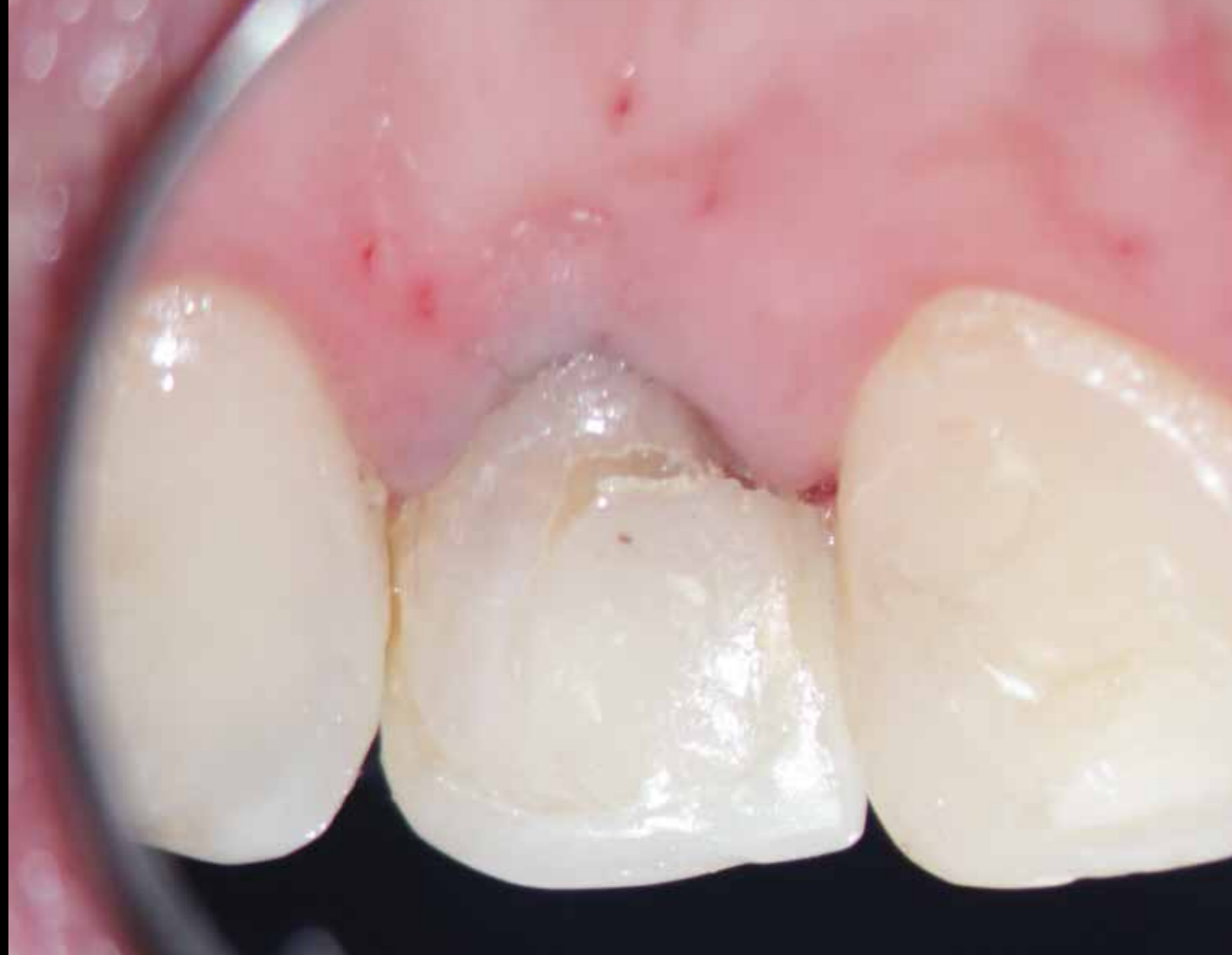

Figure 5.43b

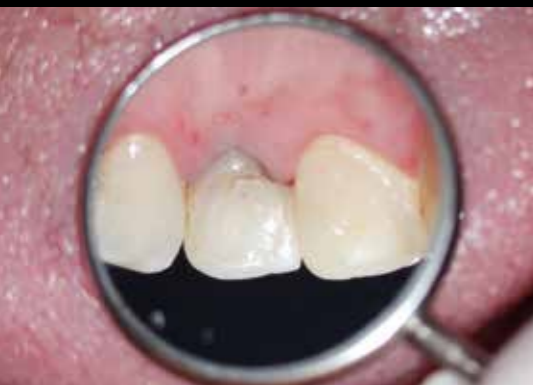
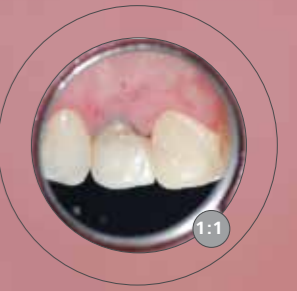
Figure 5.43a

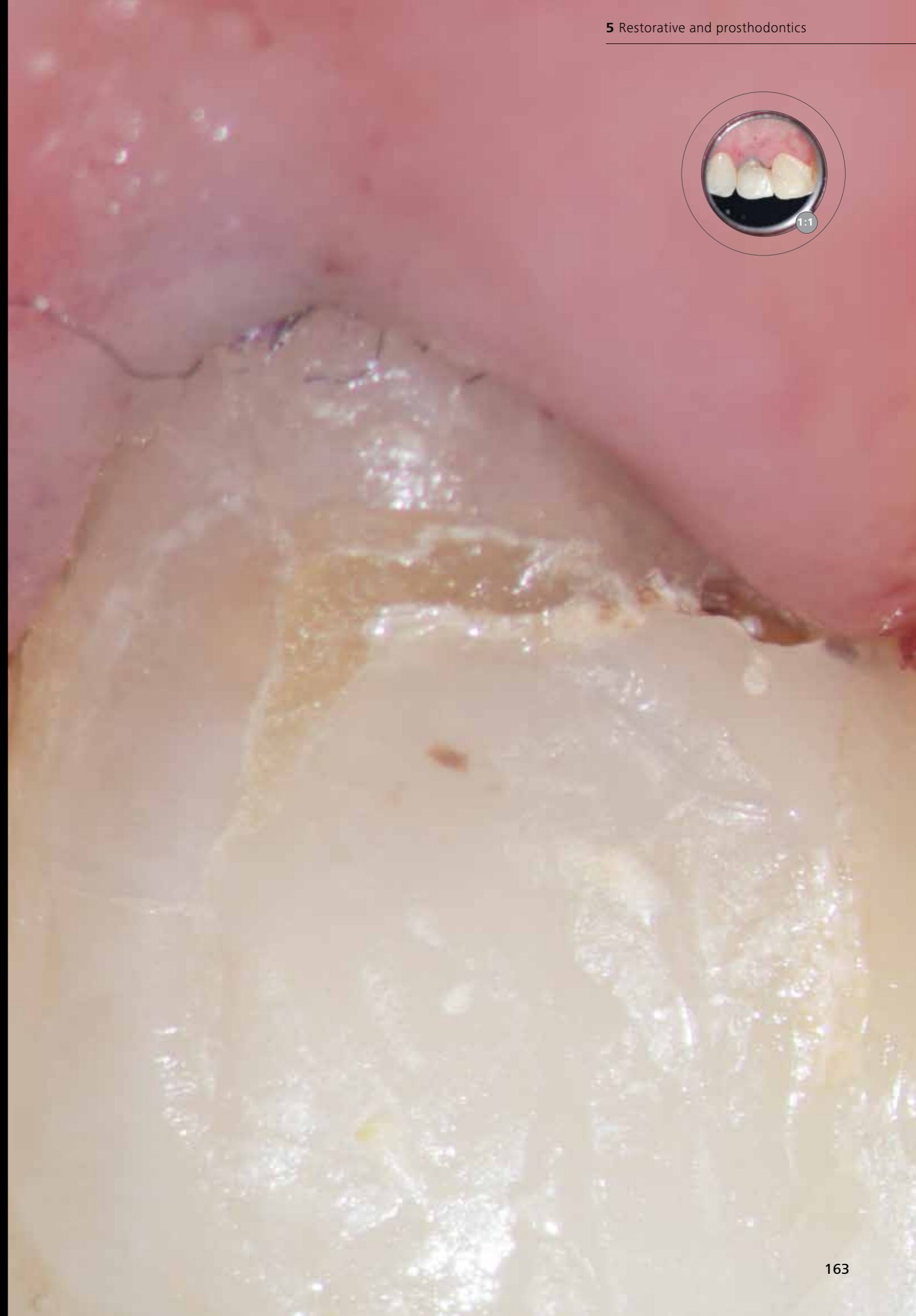


Figure 5.43c

Figures 5.43a, 5.43b and 5.43c:  
Surgical field at low, medium and high magnifications

## Replacements - avoiding impairment

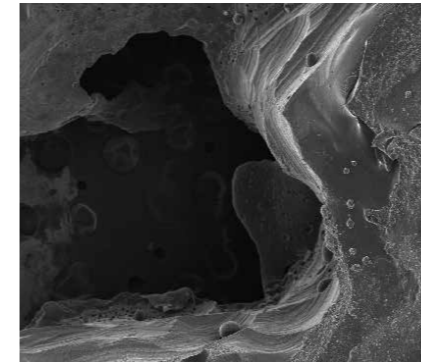
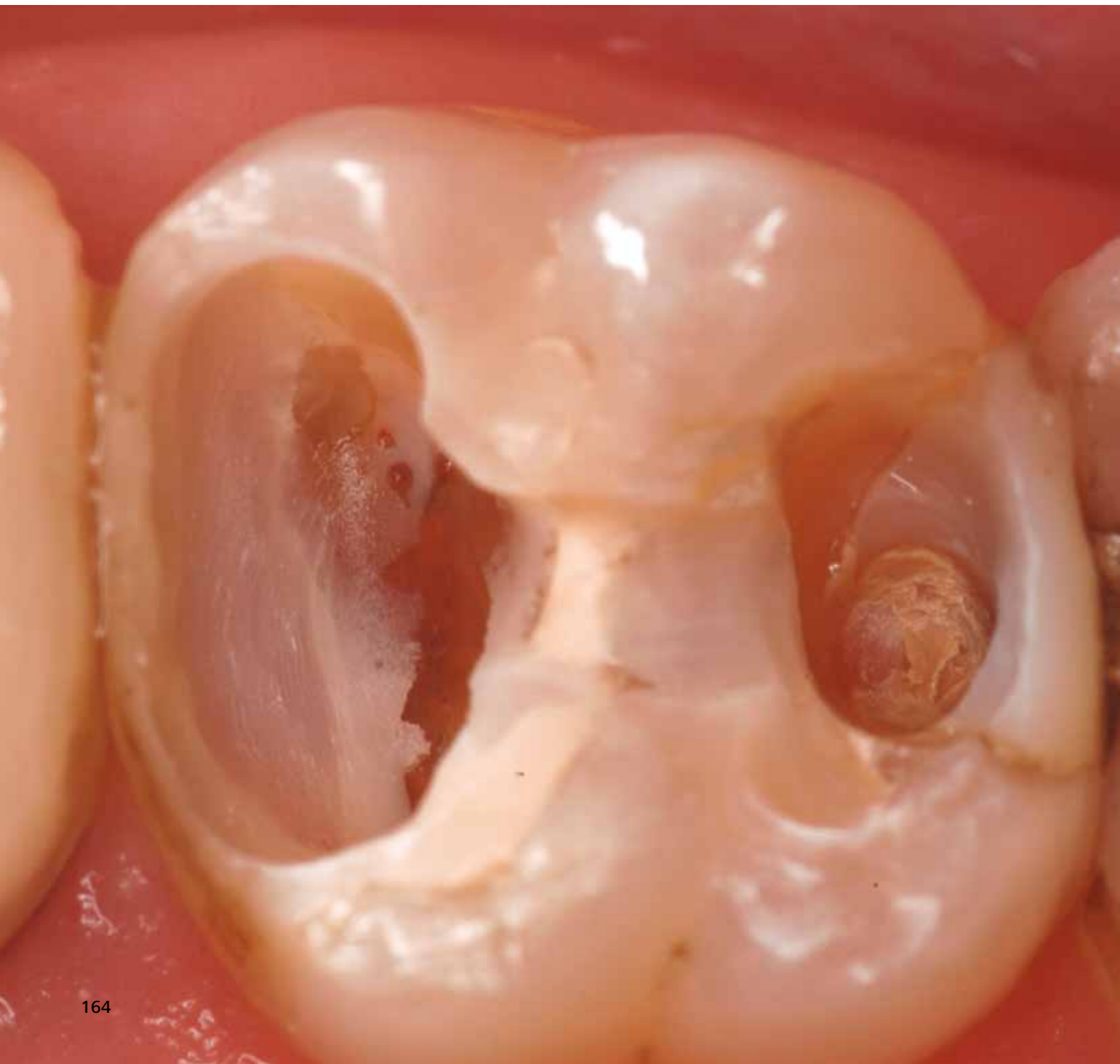


Figure 5.45

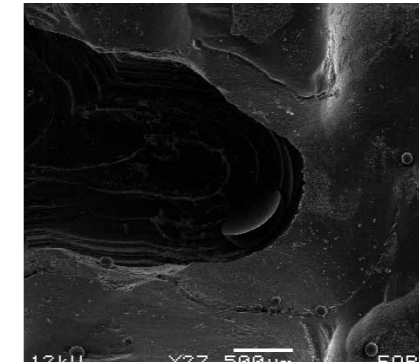


Figure 5.46

Figure 5.44 - 5.46: captured with an OPMI and scanning electron microscope exemplify the most common occurrence during restoration replacement without any kind of magnification

When we replace restorations (aesthetic or non-aesthetic) due to a recurrent carious lesion, or because of superficial or intrinsic discolorations of resin which damage the aesthetic restoration's quality, healthy tooth material is often also removed at the same time. Recognizing the limits between teeth and restorations, seeing these structures with magnification and high quality light, means greater preservation of tooth tissue. (Figures 5.44 - 5.46.)

Improved lighting coupled with magnification provide a clear distinction between surfaces that may look similar in color or texture under traditional working conditions, but look very different under the OPMI. Decay, dentine, enamel, composite, and porcelain are easily discernible from one another and can be viewed with unprecedented detail under the scrutiny of the OPMI.

The images above exemplify how an amount of resin that can remain around the cavity preparation if dentists cannot see the boundaries of the preparation in detail. Conversely, teeth may be over prepared by the removal of healthy tooth tissue at the margins of the restoration.

The replacement of an amalgam or aesthetic restoration often leads to ever larger restorations that have shorter life spans than their predecessors, and the replacement procedures themselves may often cause damage to adjacent healthy teeth.

Figure 5.44

Adhesive restoration eliminates the need for more extensive and retentive preparations. Enamel - like composites offer long-lasting replacement of tooth structure with minimum requirements for restorative bulk; little or no healthy tooth material needs to be removed simply to allow for an adequate thickness of the filling materials. Aesthetic and cosmetic procedures calling for invisible margins and tooth / restorative interface transitions are far easier and less stressful when size enhanced visualization is available.

## The Tunnel preparation technique

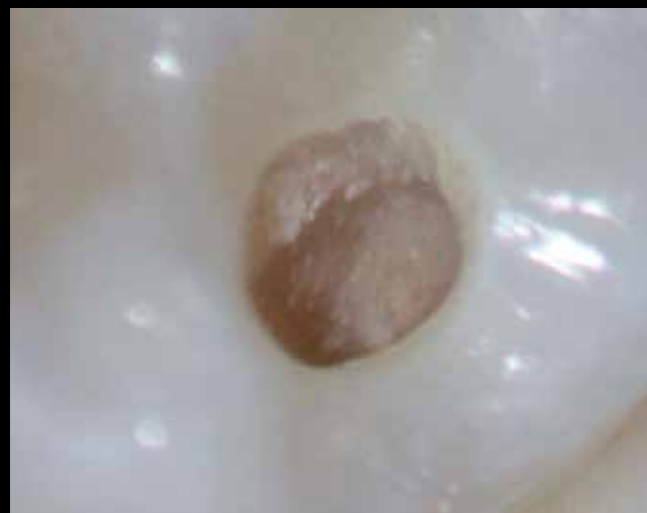

Figure 5.47a Initial access to the decay

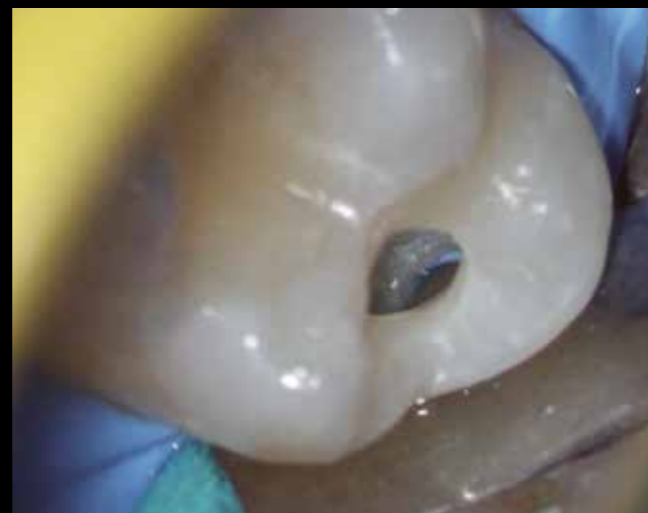

Figure 5.47b Initial view of the tunnel preparation and removal of decay

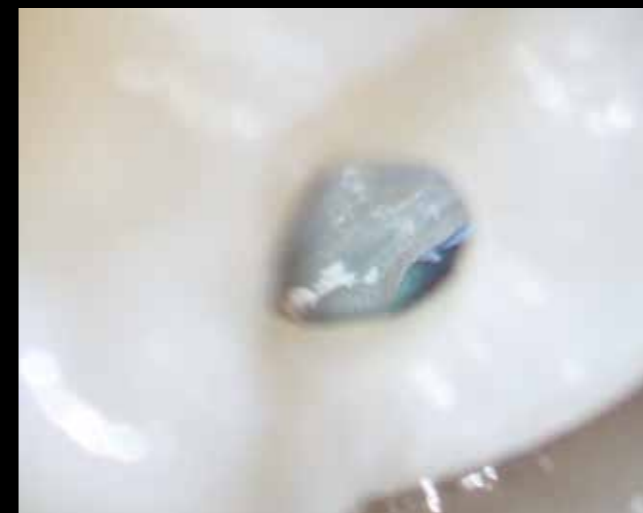

Figure 5.47c Detailed view of the tunnel preparation and inspection of the marginal ridge for cracks

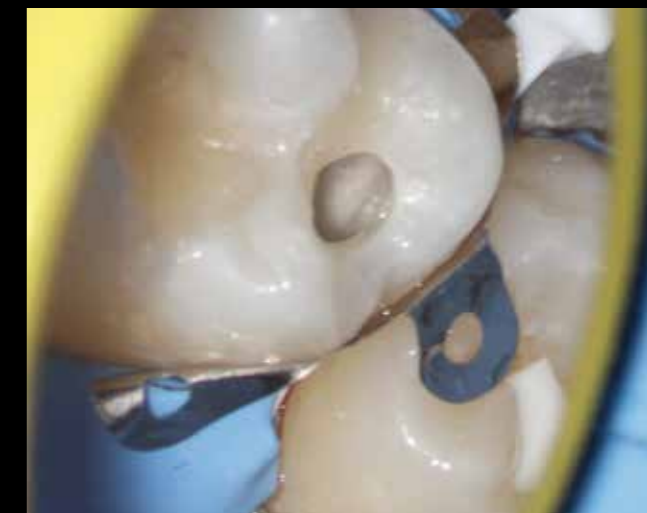

Figure 5.47d Inserted matrix to seal the tunnel

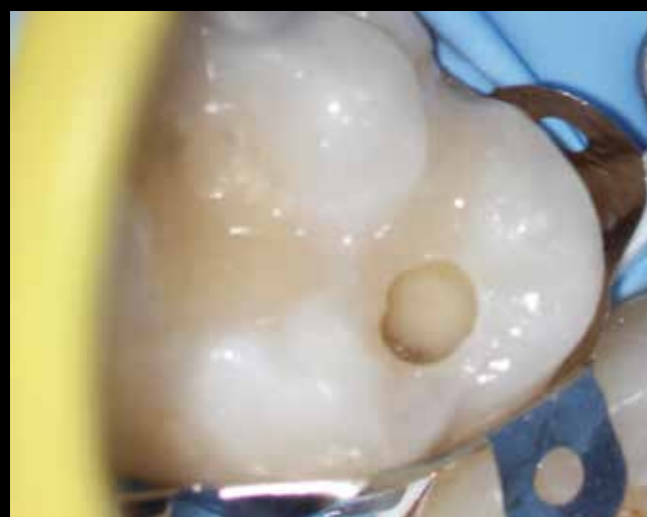

Figure 5.47e 1st layer of flowable composite to seal the tunnel under visual control and transformation of the class II cavity into a class I cavity

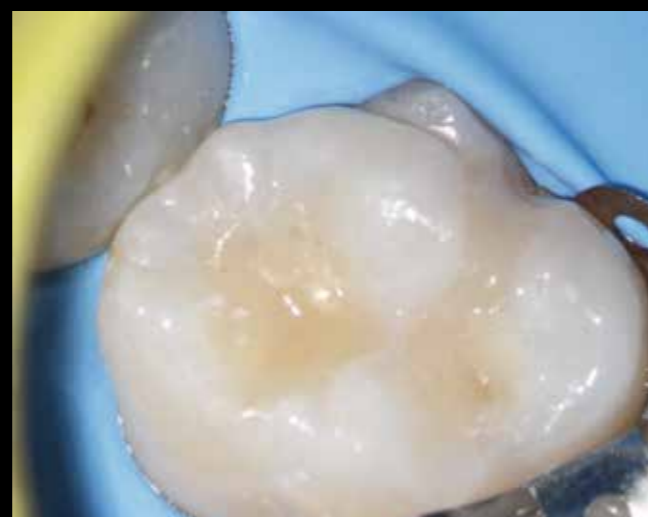

Figure 5.47f Completed restoration

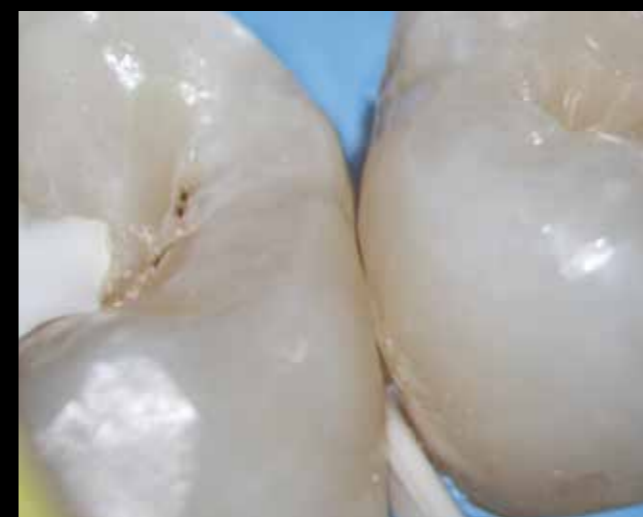

Figure 5.47g Detailed view of the finished restoration and the marginal ridge

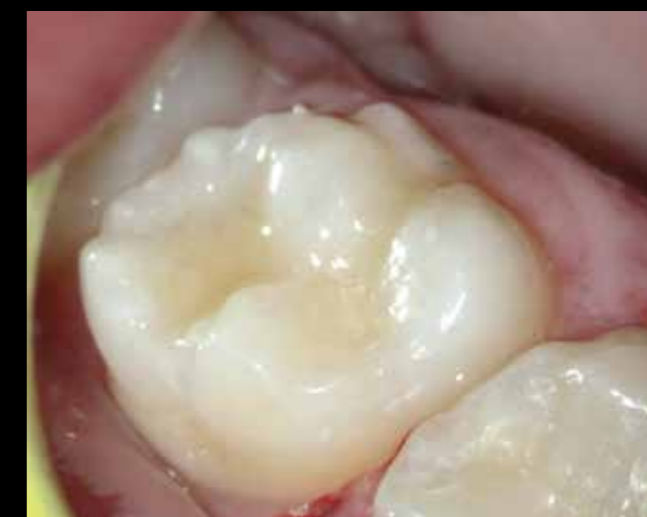

Figure 5.47h After polishing the restoration and rewetting of the tooth

The Tunnel preparation technique is a method in which approximal caries is accessed and prepared through the occlusal surface preserving the marginal ridge intact with occlusal centric contacts. This method allows less removal of enamel and dentine compared to a traditional class II cavity. This minimally invasive approach to approximal decay is indicated in cases of approximal lesions and intact occlusal surface, or a pre-existing occlusal restoration which is removed to gain the access. In the teeth with an intact occlusal surface the ideal position of entry is the fossa next to the marginal ridge.

Contraindicaton of this technique is where the marginal ridge is undermined with decay or demonstrates cracks. It is advisable to maintain at least 2.5 mm of tooth tissue between the crest of the marginal ridge and the cavity margin. The efficacy of caries removal is the main problem. It is limited by the size of the occlusal access – it may be too small to see all the undermined areas. Combination of higher magnification, caries detector dye and transillumination techniques improves the effectiveness of caries removal. Cavity design varies from the tunnel in which the approximal enamel is maintained to a partial or total tunnel where

approximal demineralised enamel is partially or completely removed and then smoothed.

The failure risks include fracture of the marginal ridge, incomplete removal of caries and secondary caries. These risks are reduced by the control given by the OPMI.

## Indirect restorations

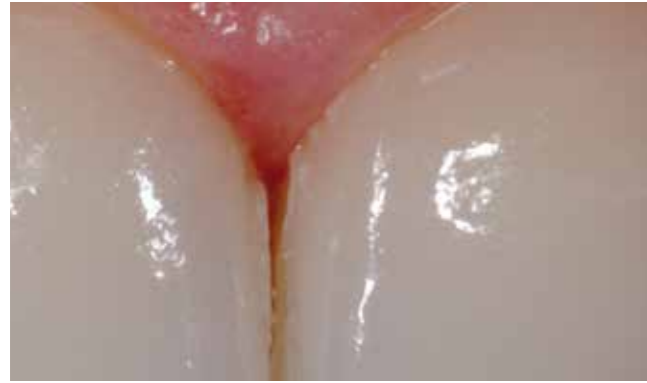

Figure 5.48

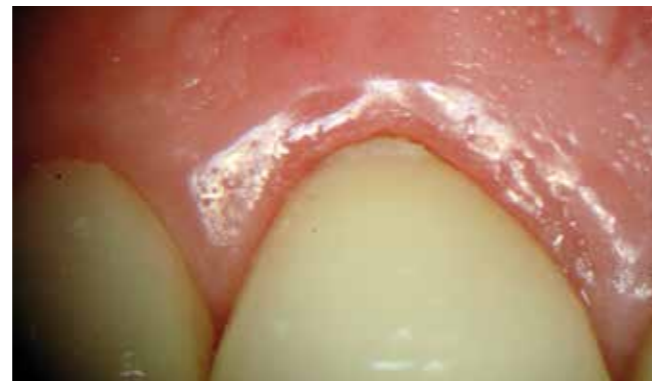

Figure 5.49

Figures 5.48 and 5.49: Note the excess of resin cement, after cementation. This kind of material can damage the surrounding soft tissue and should therefore be removed

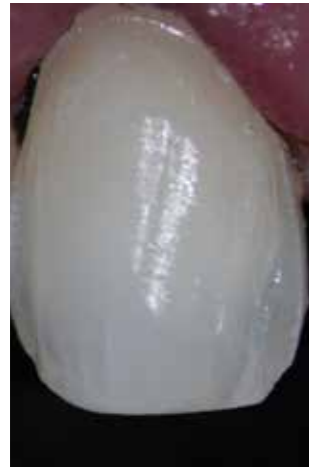

Figure 5.50

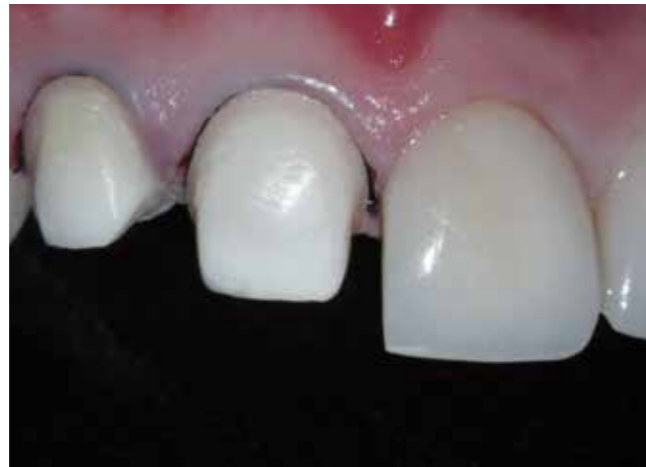

Figure 5.51

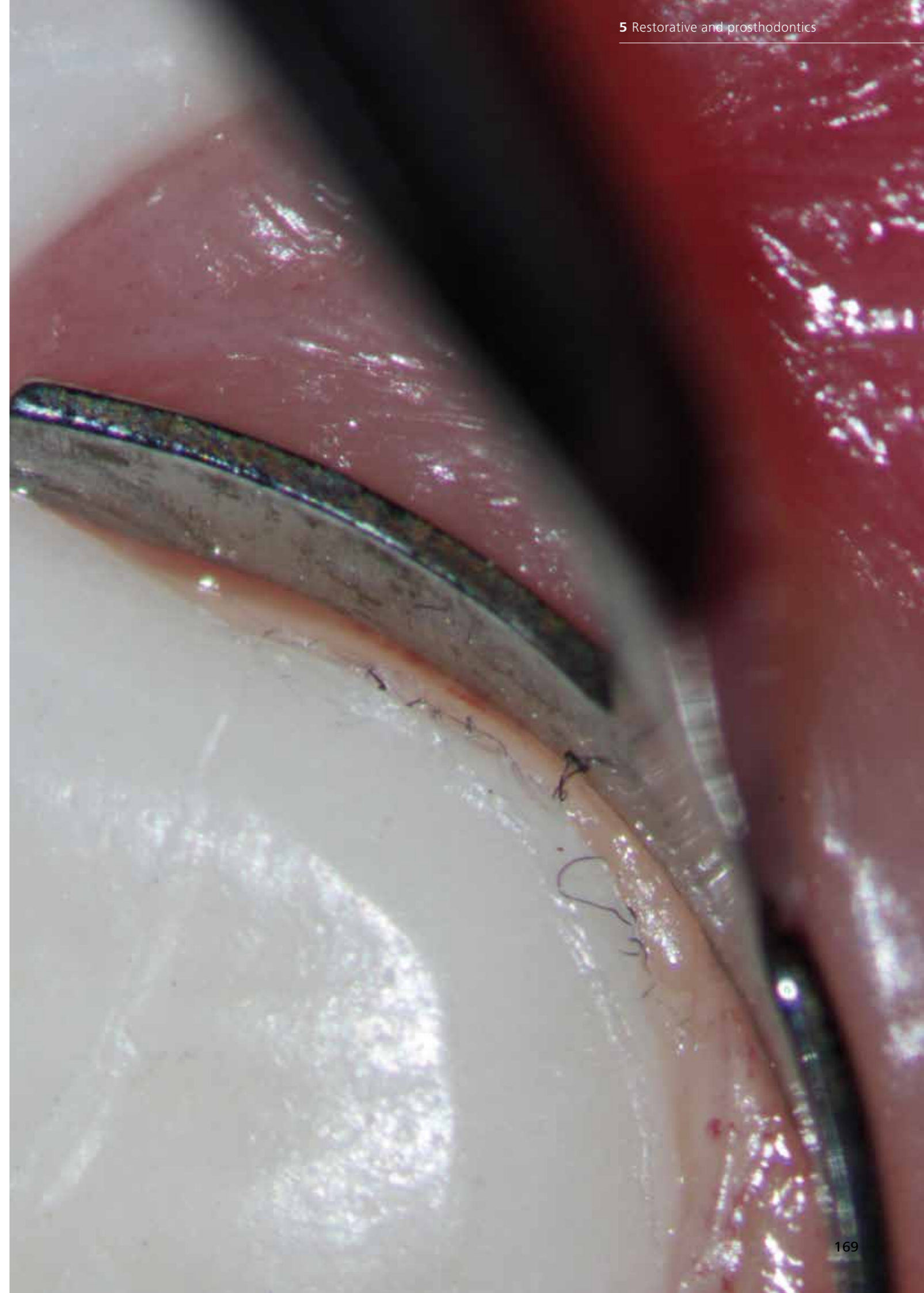Figures 5.50 and 5.51 Note the exact definition of preparation on the cervical area through the use of magnification. At low magnification it is also possible to check the smoothness of preparation in each tooth involved in the restorative procedure

Note the excess of cement in the boundary between the tooth and the ceramic restoration. Without any magnification this is difficult to see and remove adequately. These OPMI images show us the exact point where finishing and polishing must be done. See Figures 5.48 - 5.49.

In order to avoid overhangs during ceramic bonding, marginal adjustments are made using small burs and rubbers. The smoother and more regular they are, the better the adaptation of the indirect restoration. See Figures 5.50 and 5.51.

Other important considerations include the correct removal of the retraction cord after cementation of laminates. Parts of the cord often remain in the cervical area. If the dentist does not use either magnification or clear light, these residues cannot be seen (Figure 5.52).

Figure 5.52: Thanks to the high magnification and clear light provided by the OPMI, it is possible to see residues of the retractor cord used during cementation procedure. These residues must be removed to prevent plaque retention and gingival recession



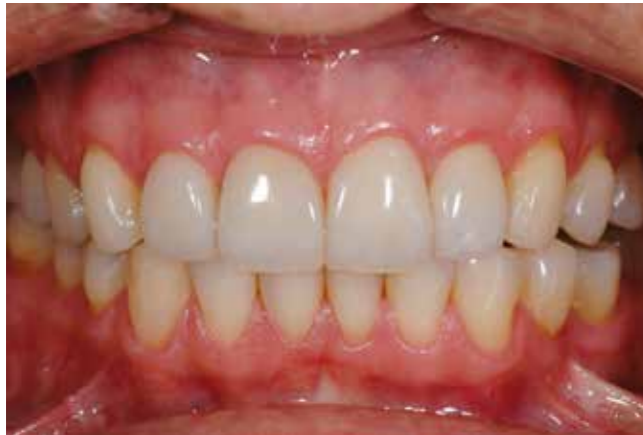

Figure 5.53a

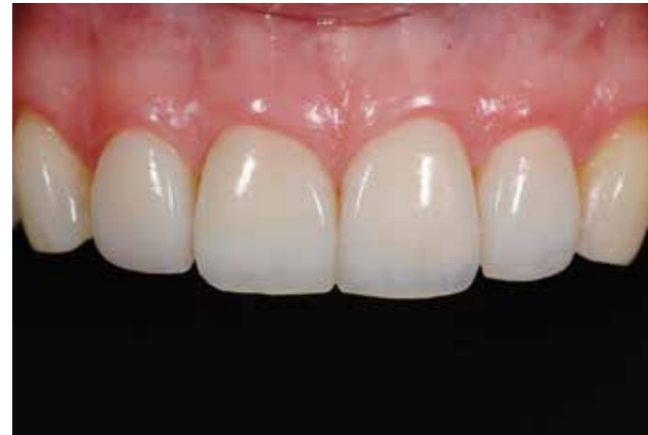

Figure 5.53b

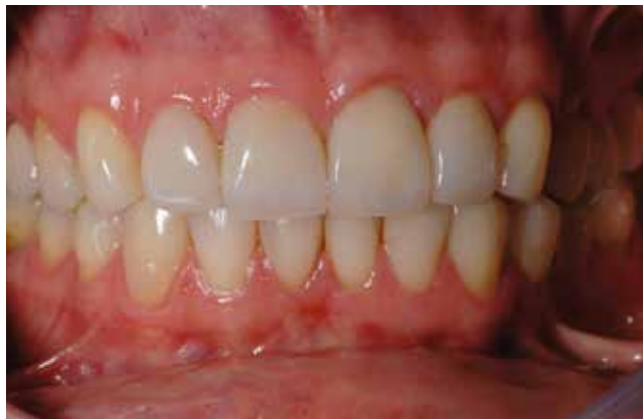

Figure 5.54a

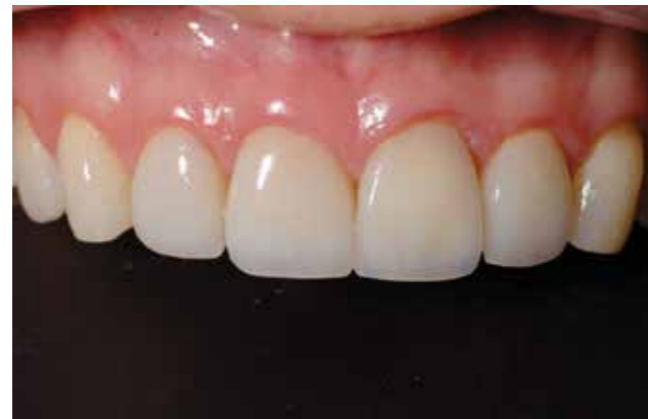

Figure 5.54b

The aim of clinicians and technicians is to achieve excellent margins and perfect adaptation. Clear visibility of the surgical field and high magnification are very important to reach that goal. If excellence is achieved the results are highly satisfying for both the patient and the clinician and also longlasting. See images 5.53a, 5.53b and 5.54a and 5.54b.

*Figures 5.53a and 5.53b: Note the perfect adaptation of ceramic microlaminates when treatment is carried out with the aid of the operating microscope... The ceramic microlaminates were made by Marcos Celestrino TPD – BRAZIL*

*Figures 5.54a and 5.54b: Note the excellent tissue response to the ceramic microlaminates after 5 years in the mouth.*

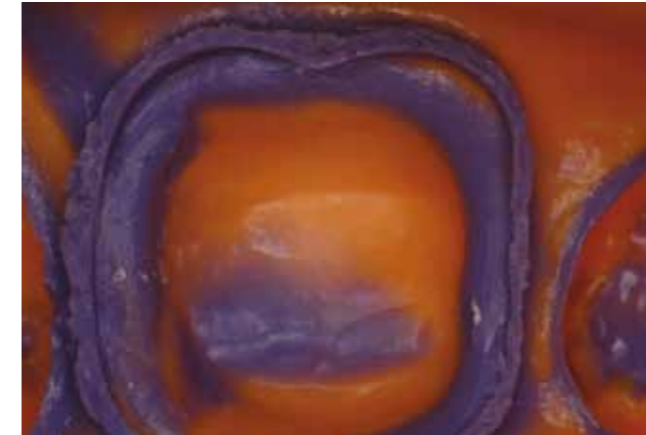


Figure 5.55: Note the accurate impression of the preparation

Another important aspect concerning indirect restorations is the visualization of impressions, and not only the visualization of the impression material, but also the adaptation of the material to the teeth. See Figures 5.55, 5.56a and 5.56b.

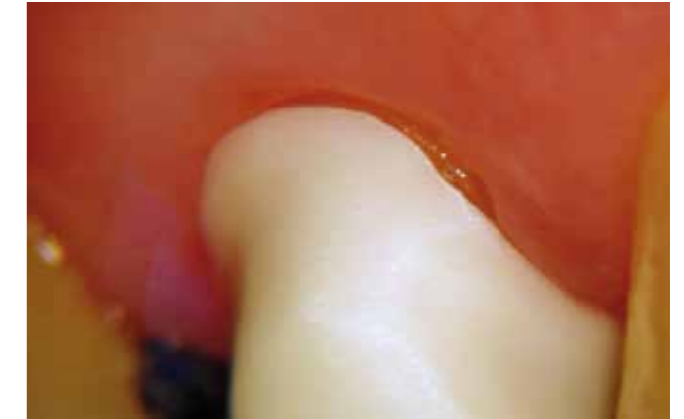

Figure 5.56a

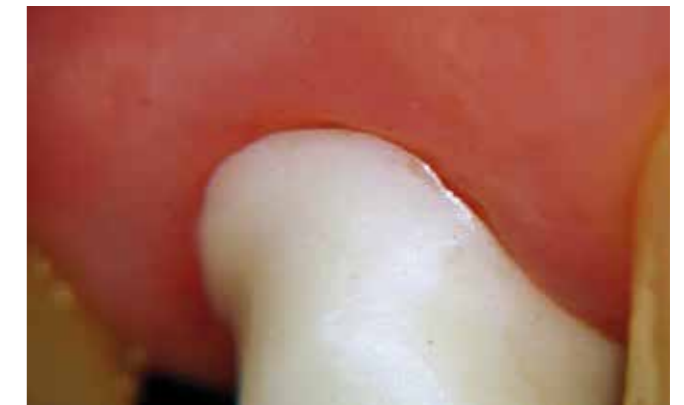

Figure 5.56b

*Figures 5.56a and 5.56b: There is perfect adaptation of the coping to the papilla margin; however, there is incorrect adaptation through the cervical contour*

## Instruments



Figure 5.57



Figure 5.58



Figure 5.59



Figure 5.60

Restorative dentistry under the microscope requires modified instrumentation to take full advantage of this treatment modality. Micro-burs, micro-mirrors and flexible mirrors are available for this type of high precision clinical work. The high quality illumination only 200-300 mm from the mouth provides vastly superior light than the overhead operating light used by most clinicians. See Figures 5.57, 5.58, 5.59, 5.60 and 5.61.



Figure 5.61

Figures 5.57 - 5.61: Note the differences between these instruments. Working under magnification requires delicate instruments, small mirrors, small burs and brushes.



## Excellence in operative and prosthodontic dentistry with regard to communication with patients



Figure 5.62 The use of video and still photography enable documentation of clinical cases. The images can be used to explain findings to patients in perfect detail

The ease of communication with the patient is, without doubt, another great benefit inherent in the use of the OPMI. All clinical images can be recorded by cameras or camcorders and all the details of each clinical case can be shown at the same time for the patient. The OPMI accessories provide exact recording of the images, with high quality and sharpness. See Figures 5.62 - 5.66.

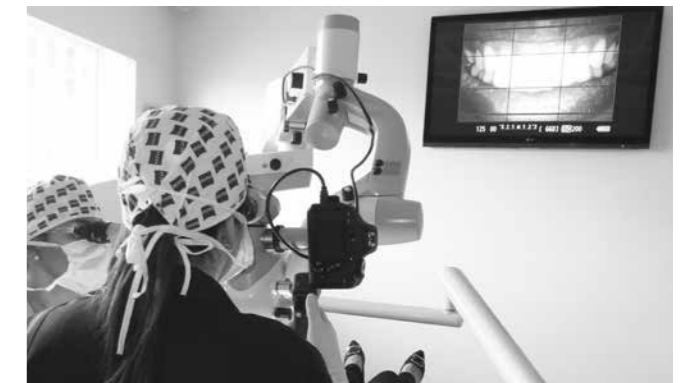

Figure 64: Dentist and assistant working in perfect harmony using the OPMI and shooting and recording images at the same time




Figure 5.63

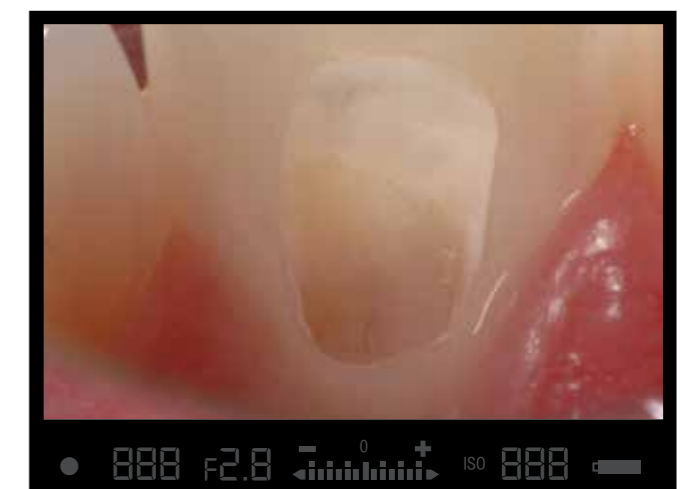

Figure 5.64

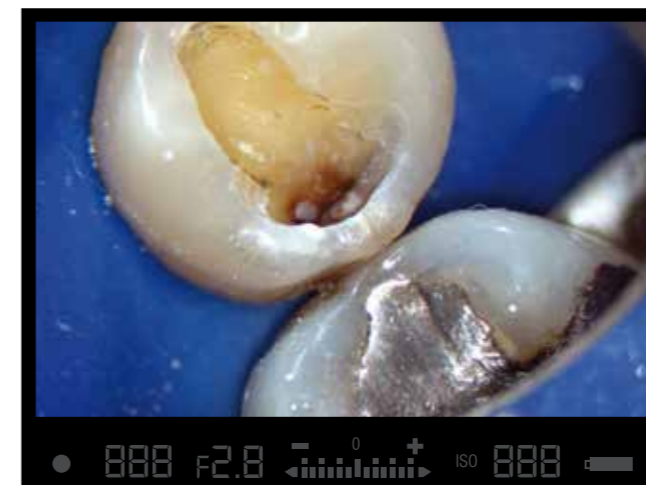

Figure 5.65

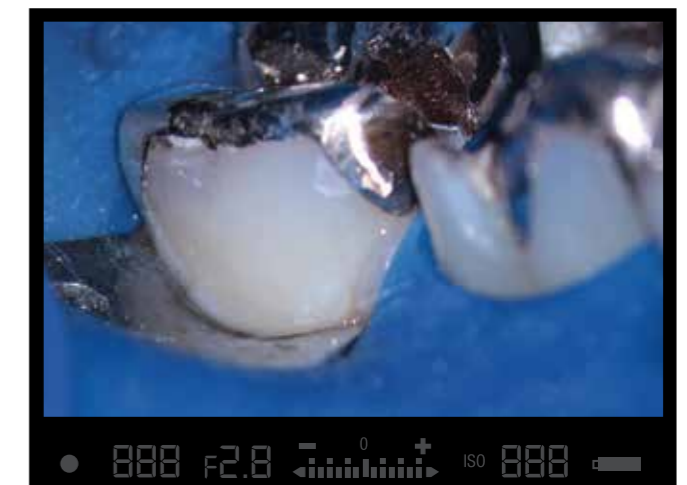


Figure 5.66



## References

- WORSCHCECH CC et al: *Micro-operative dentistry: Why do it?* QDT 2007, 199-205
- Diagnosis of secondary caries in esthetic restorations: influence of the incidence vertical angle of X-ray beam. *Braz Dent J.* 2011;22(2): 129-33
- BRAGA MM, CHIAROTTI AP, IMPARATO JC, MENDES FM. *Braz Oral Res*, 2010 Jan-Mar; 24(1): 102-7
- SHEETS CG: *The periodontal-restorative interface: enhancement through magnification.* *Pract periodont Aesthet Dent* 1999; 11(8): 925-931
- FRIEDMAN M, MORA A, SCHMIDT R *Microscope-assisted precision dentistry. Compend Contin Educ Dent* 1999; 20:723-735
- DALLI M, ÇOLAK H, MUSTAFA HAMIDI *Minimal intervention concept: a new paradigm for operative dentistry. J. Invest Clin Dent* 2012 Aug; 3(3): 167-175. doi: 10.1111/j
- 2041-1626.2012.00117.x. *Epub* 2012 Feb 8.
- LAEGREID T, GJERDET NR, VULT VON STEYERN P, JOHANSSON AK. *Class II composite restorations: importance of cervical enamel in vitro*
- SHEETS CG: *The periodontal-restorative interface: enhancement through magnification.* *Pract periodont Aesthet Dent* 1999; 11(8):925-931
- PERES CR, GONZALEZ MR, PRADO NAS, MIRANDA MSF, MACEDO MA, FERNANDES BMP: *Restoration of noncarious cervical lesions: when, why, and how.* *Int J Dent* 2012;2012: 687058. Published online 2011 December 18. doi: 10.1155/2012/687058
- FRIEDMAN MJ, LANDESMAN HM: *Microscope-assisted precision (MAP) dentistry. A challenge for new knowledge.* *J Calif Dent Assoc* 1998;26:900-905
- WORSCHCECH CC: *Replacement of esthetic restorations: Can we see the limits?* *R. Dental Press Estet, Maringá, v.3, n.4, p.77-90, out/Nov/dez. 2006*
- FREEDMAN G, GOLDSTEP F, SEIF T: *Ultraconservative resin restorations “watch and wait” is not acceptable treatment.* *Dentistry Today, january 2000*
- FRIEDMAN M, MORA A, SCHMIDT R. *Microscope-assisted precision dentistry. Compend Contin Educ Dent* 1999; 20:723-735
- Microscope-assisted precision (MAP) dentistry. A challenge for new knowledge.* *J Calif Dent Assoc* 1998;26:900-905
- FREEDMAN G, GOLDSTEP F, SEIF T: *Ultraconservative resin restorations “watch and wait” is not acceptable treatment.* *Dentistry Today, january 2000*
- CLARK DJ, SHEETS CG, PAQUETTE JM: *Definitive diagnosis of early enamel and dentinal cracks based on microscopic evaluation.* *J. Esthet Restor Dent* 2003;15:391-401
- GARCIA A: *Dental magnification: a clear view of the present and close-up view of the future.* *Compendium, June 2005, 459-453*
- ARENS DE: *Introduction to magnification in endodontics.* *J. Esthet Restor Dent* 15: 426-439, 2003
- RAGAIN J, JOHNSTON WM: *Minimum color differences for discriminating mismatch between composite and tooth color.* *J. Esthet Restor Dent* 13: 41-48, 2001
- BAUMANN RR.: *How may the dentist benefit from the operating microscope?* *Quintessence Int* 1977;5:17-18
- GONDIM E JR, MURGEL CAF, SOUSA FILHO FJ *Microscópio cirurgico: lanueva frontera de la Odontología clínica Del siglo. Fola/ Oral* 1997;3:147-152
- TERRY DA; GELLER W: *Selection defines design.* *J. Esthet Restor Dent*, 2004; 16(4): 213-25; discussion 226
- N – SPEAR F, HOLLOWAY J: *Which all-ceramic system is optimal for anterior esthetics?* *J. Am Dent Assoc, vol 139, No suppl\_4, 19S-24S, 2008*
- HORN HR: *A new lamination: porcelain bonded to enamel.* *NY State Dent J* 1983; 49(6): 401-403
- SIMONSEN RJ, CALAMIA JR: *Tensile bond strengths of etched porcelain.* *Abstract 1099. J.Dent Res, 1983:62*
- CALAMIA JR: *Etched porcelain facial veneers : a new treatment modality based on scientific and clinical evidence.* *N Y J Dent* 1983; 53(6): 255-259
- NAKABAYASHI N, NAKAMURA M, YASUDA N: *Hybrid layer as a dentin-bonding mechanism.* *J Esthet Dent* 1991; 3 (4): 133-138
- POSPIECH P: *All-ceramic crowns : bonding or cementing?* *Clin Oral Investig* 2002; 6(4): 189-197
- N – SPEAR F, HOLLOWAY J: *Which all-ceramic system is optimal for anterior esthetics?* *J. Am Dent Assoc, vol 139, No suppl\_4, 19S-24S, 2008*
- SIMON H, MAGNE P: *Clinically based diagnostic wax up for optimal esthetics: the diagnostic mock up.* *J. Calif Dent Assoc, 2008, May; 36(5): 355-62*
- TERRY DA, MORENO C, GELLER W, ROBERTS M: *The importance of laboratory communication in modern dental practice: stone models without faces.* *Pract Periodontics Aesthet Dent, 1999, NOV-DEC; 112S-32; quiz 1134*
- WORSCHCECH CC, *Microdentistry: A Path to excellence.* QDT 2008, 179-187
- WORSCHCECH CC: *Microscopia Operatoria na Medicina Dentária. Aesthetic&Implant Dentistry Out.* Nov. Dez. 2008
- WORSCHCECH CC: *Microscopia Operatória na Odontologia: Como a magnificação pode aprimorar a habilidade técnica e a comunicação do profissional com o paciente.* *R.Dental Press Estética – Maringá, v.4, n.3, p.24-33, julho/agost/set 2007*
- WORSCHCECH CC, MURGEL CAF: *Micro-odontologia: visão e precisão em tempo real.* Maringá-Dental Press Editora, 2008, 482p
- MAGNE P, VERSLUIS A, DOUGLAS WP: *Effect of luting composite shrinkage and thermal loads on the stress distribution in porcelain laminate veneers.* *J. Prosth Dent* 1999, 81: 335-344
- KINA S, BRUGUERA A: *Invisível: Restaurações estéticas cerâmicas.* Maringá – Dental Press Editora, 2007, 420p
- MAGNE P, PERROUD R, HODGES JS, BELSER UC.: *Clinical performance of novel design porcelain veneers for the recovery of coronal volume and length.* *Int J. Periodontics Restorative. Dent* 2000; 20: 441-457
- LESAGE B: *Finishing and Polishing criteria for minimally invasive composite restorations.* *Gen Dent.* 2011 Nov-Dec; 59 (6): 422-8; quiz 429-30
- HUYSMANS MC, ROETERS FJ, OPDAM NJ: *Cariology and restorative dentistry: old and new risks.* *Ned Tijdschr Tandheelk,* 2009 Jun; 116 (6): 291-7
- PEREIRA AC, EGGERTSSON H, MARTINEZ-MIER EA, MIALHE FL, ECKERT GJ, ZERO DT *Validity of caries detection on occlusal surfaces and treatment decisions based on results from multiple caries detection methods.* *EUR J Oral Sci.* 2009 Feb; 117 (1): 51-7.
- 10.1111/j.1600-0722.2008.00586x.
- SWENSON E, HENNESSY B: *Detection of occlusal carious lesions: an in vitro comparison of clinicians’ diagnostic abilities at varying levels of experience*
- Hunt PR *Microconservative restorations for approximal carious lesions.* *J Am Dent Ass* 1990; 120: 37-40.
- D K Ratledge, E A M Kidd & E T Treasure- *The tunnel restoration, British Dental Journal* 193, (2002)
- Strand GV, Tveit AB *Effectiveness of caries removal by the partial tunnel preparation method.* *Scand J Dent Res* 1993; 101: 270-273.
- Pyk N, Mejäre I *Tunnel restorations. Influence of some of the clinical variables on the success rate.* *Acta Odont Scand* 1999; 57: 149-154.
- Knight GM *The tunnel restoration.* *Dent Outlook* 1984; 10: 53-57
- Nicolaisen S, von der Fehr FR, Lunder N, Thomsen I. *Performance of tunnel restorations at 3-6 years.* *J Dent* 2000; 28: 383-7.
- Kinomoto Y, Inoue Y, Ebisu S. *A two-year comparison of resin-based composite tunnel and class II restorations in a randomized controlled trial.* *Am J Dent* 2004; 17: 253-6.

# 6

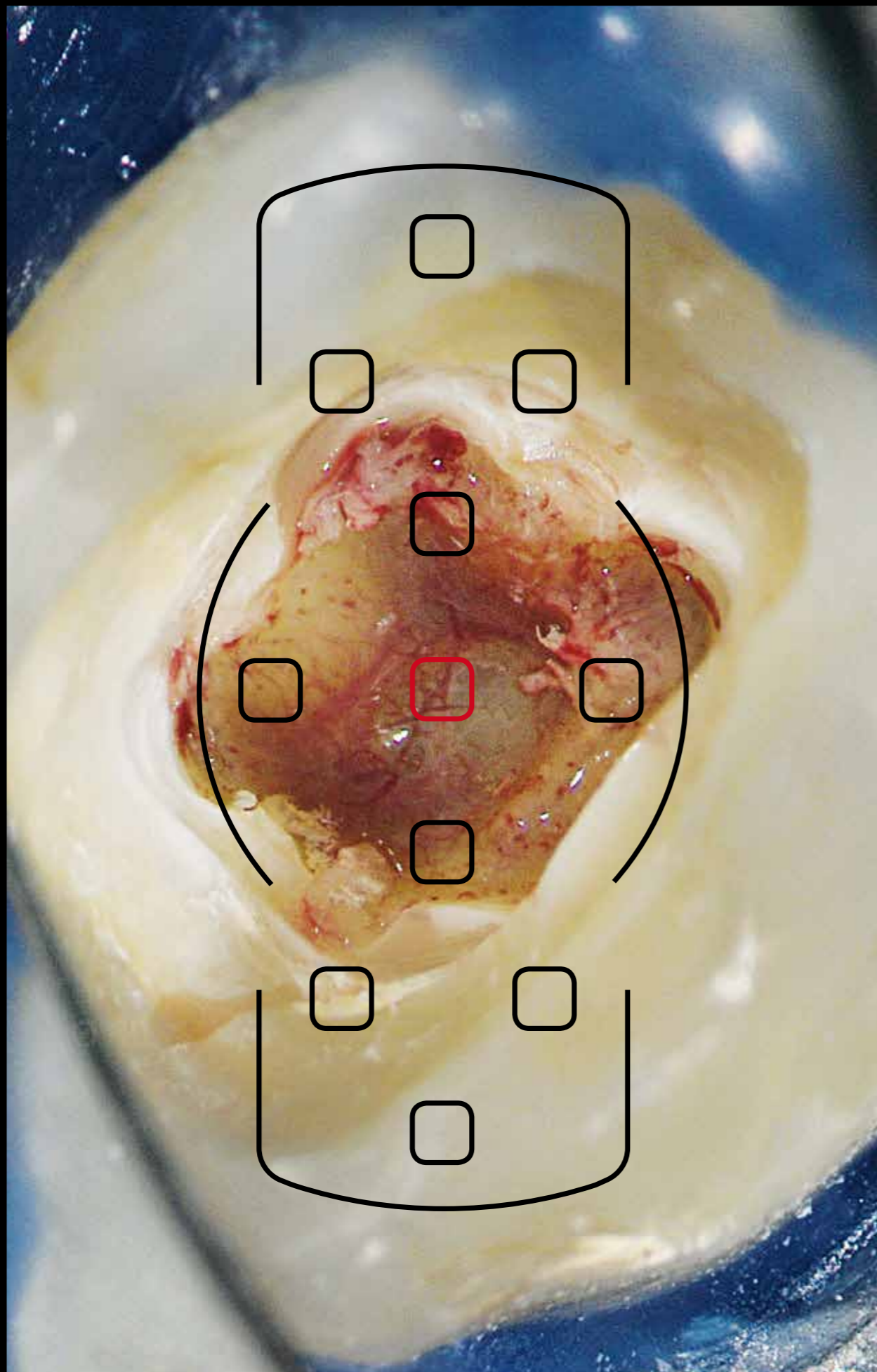
## 6 Documentation

Author: **Oscar Freiherr von Stetten**

181 **Why?**

182 **How?**  
Photo/video

186 **Practical advice**



## Why documentation?

The increasing use of magnifying devices in the dentist's practice is also leading to a need to document the diagnosis and treatment, whether for forensic purposes, for the dentist's own documentation needs, patient education, training or case presentations.

Figure 6.1

## How?



Figure 6.2

Various manufacturers offer different documentation solutions. Unfortunately, it is often the case that the dentist does not realize until after several weeks of use that the usually expensive solution does not fulfill the intended purpose and that the quality is not of the standard normally associated with normal photography or video recordings. It is important to note that the experience gained in everyday photography cannot be transferred one-to-one to documentation with the

OPMI. In addition, the camera hardware used does not play a really decisive role, despite the many beliefs to the contrary that often lead to unnecessary expenditure. Documentation is subject to the laws of physics that cannot be overcome. As impressively shown in Chapter 1, the depth of field of OPMI optics is limited by the principles of physics, as are light conduction and light output. Nevertheless, it is subjective perception that ultimately determines what technology is used. Dentists

should first ask themselves for what purpose the images or videos are to be utilized and then make a decision in favor of one particular solution.

### Photo/video

The optical beam path contains a beam splitter that routes a certain percentage of the incident light to the camera by means of prismatic lenses with defined transmission properties.

### Video

The biggest benefit of the video solution is that very little light is needed (approximately 10%).

In addition, video solutions may be very suitable for generating high-quality photos if high-quality cameras are used for documentation. Consumer cameras may be interesting from the price perspective, but they have drawbacks when it comes to quality. However, their attachment is very simple. ZEISS has developed the FlexioMotion adapter for this purpose. This allows easy, uncomplicated attachment via filter threads that are available in three

different sizes. When purchasing, it is important not to simply choose the model with the lowest price – this reflects the optical quality and of the camera lens – and ensure that a filter thread is present.

A further benefit of the video solution is the weight. The less weight there is on the OPMI head, the less weight also has to be moved when setting the OPMI, making it more stable and less sensitive to vibrations or imbalance. The other class of video cameras with a separate camera head – the medical grade cameras – are more expensive than consumer grade cameras, but feature special benefits. One advantage of the medical grade devices is their standardized interface, the c-mount, which require smaller optics with smaller focal length, which provides better optical quality. This makes it possible



Figure 6.3

to exchange the camera hardware without any immediate need for a new tube. The prefabricated optics of the consumer grade cameras are eliminated, resulting in considerably more light and better optics. In addition, these devices have been optimized to meet the needs of their intended application, i.e. certain parameters have been adapted to usage on the OPMI.

One drawback of video systems is the still enormous file sizes they involve. Considerable time and skill is also required for the editing process, although a few more intuitive solutions have already been established on the market.

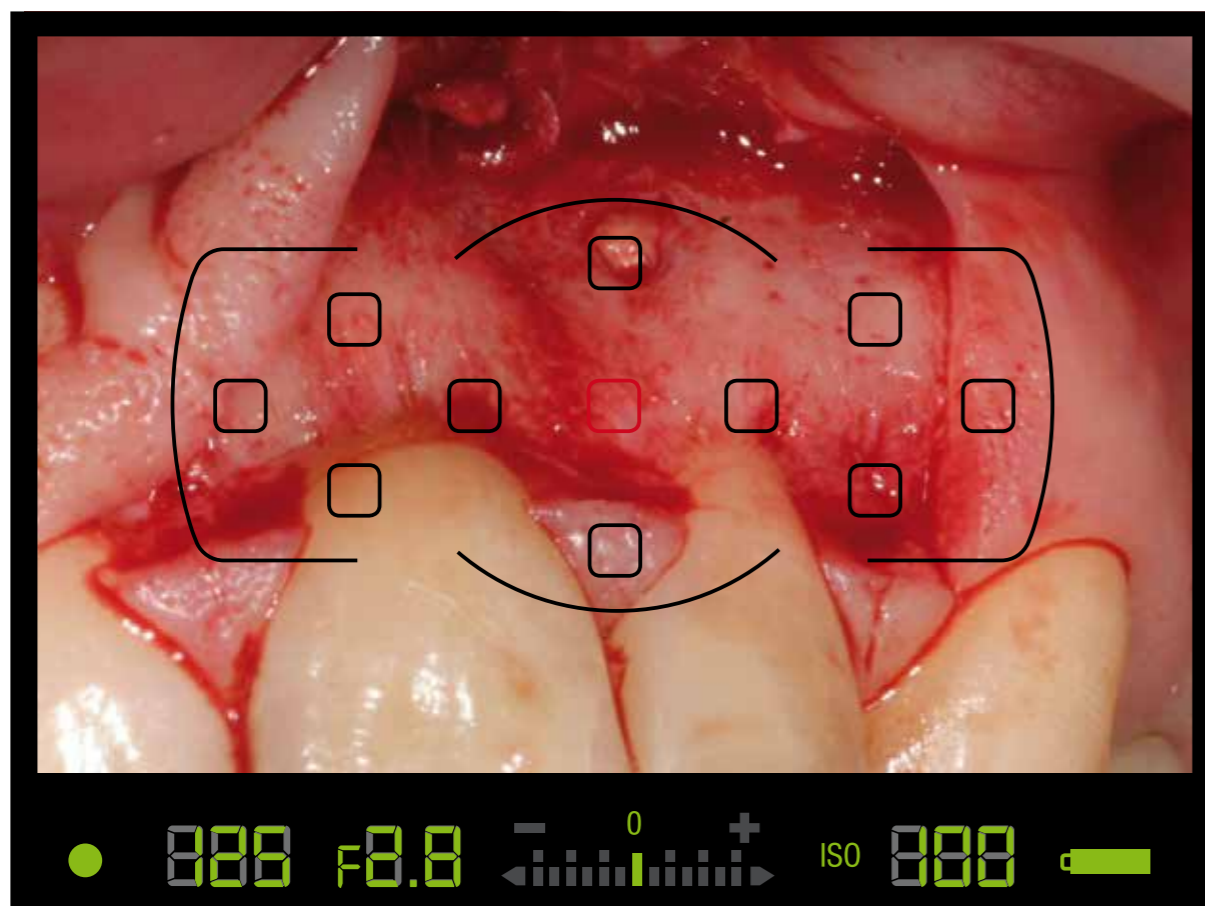


Figure 6.4

At the IDS 2013, ZEISS presented a device showing what such a system could look like. However, the same quality should not be expected from a still frame extracted from a video stream as from a photo taken with a digital single reflex camera (DSLR) camera. 2.1MP is available compared to 10 MP upwards; the resolution alone makes a direct comparison impossible. Nevertheless, the benefits of higher speed combined with low image noise open up new approaches to documentation.

#### Photography

The first question to be asked is what camera type should be selected. Should it be a DSLR, a compact or a mirrorless camera? As we, unlike laboratory microscopy, deal with moving objects (patient movement, vibrations of the OPMI), we must accept a live video image plays a major role in focusing. Only a preview monitor makes it possible to really see whether the

desired image section has been focused sharply and at the right point.

As human beings tend to accommodate with their eyes, it may well be that although we see the image sharply image (transmitted to the camera through the beam splitter) is not sharp. In other words, we perform a readjustment with our eyes, something that the camera cannot do due to the absence of the required possibilities (no objective lens with focusing). It has the further benefit that the preview image does indeed correspond to the mounted on the OPMI was the Canon 300D with 6 MP. Today entry class DSLRs come up with 16 MP. Even the electronics are better and faster than 2004, it makes no sense to get more than 10-14 MP in terms of quality. In 90% of the quality regarding the picture is influenced by the optics, it makes no sense to invest in a very expensive camera, as there will be no significant increase in quality.

#### Full Frame

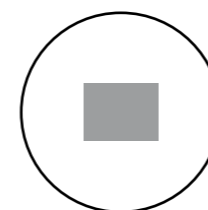
In the past a recommendation for the use of full-frame cameras could not be justified. They were expensive, heavy and too complicated to use on the OPMI.

Now, with the further development of the mirror-less class of camera, Sony offers a mirror-less full-frame camera system which can be fully recommended for the use with the OPMI. It is light weight, easy to use and offers some useful functions like built-in Wi-Fi. Together with the proven Zeiss Phototube f=340 adaptor, it is possible to get high quality pictures with ease. Due to the light weight and the small size of the camera body, the manoeuvrability of the OPMI is not impeded. If using the LED in conjunction with the Varioscope, an external documentation system can not be recommended. For these cases the integrated HD-Recording provides a better suitability.


#### External Camera Adaptation

Recommended for full size chip cameras


- Sensor: Full size 24 x 36mm e.g. Canon EOS 5D Mark II
- Sensor APS ~15 x 22mm e.g. Canon EOS 600D



Camera chip size too small in relation to focal length of photo adapter  
Image looks "cropped"



Camera chip size correct in relation to focal length of photoadapter  
Image has full resolution, no blackcorners



Camera chip size too big in relation to focal length of adapter  
Black corners, fine structures might not be resolved

#### What light?

For photography, it is important that enough light intensity is installed in the OPMI. At the moment (2013) only xenon can be used for photodocumentation. LED technology is not yet advanced enough to replace xenon.

#### Mirrors

Mirrors play a key role in photography. Even the highest light intensity from the illumination apparatus is worthless if the mirror cannot reflect enough light.

In addition, the mirror should be free from scratches and/or spray, but that goes without saying. It is recommended to have a dedicated photo mirror for this purpose.

#### Fine focusing

As the depth of field range continues to decrease as a function of the increasing OPMI magnification, fine focusing becomes necessary to obtain a "sharp" image of the structure to be treated and hence imaged.

To compensate for this, the installation of a co-observation tube is recommended to make it possible to check whether what you want to image really is in focus, or whether the image is in focus or if corrective action has to be taken. The best way is to use the "live-view" function, which allows for a much higher degree of focus control.

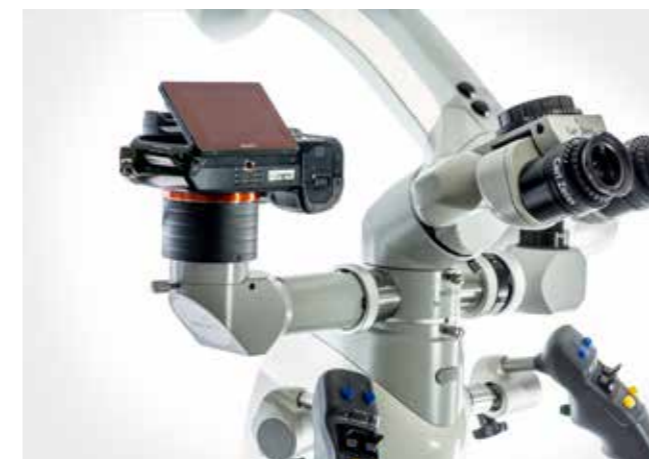

Figure 6.5

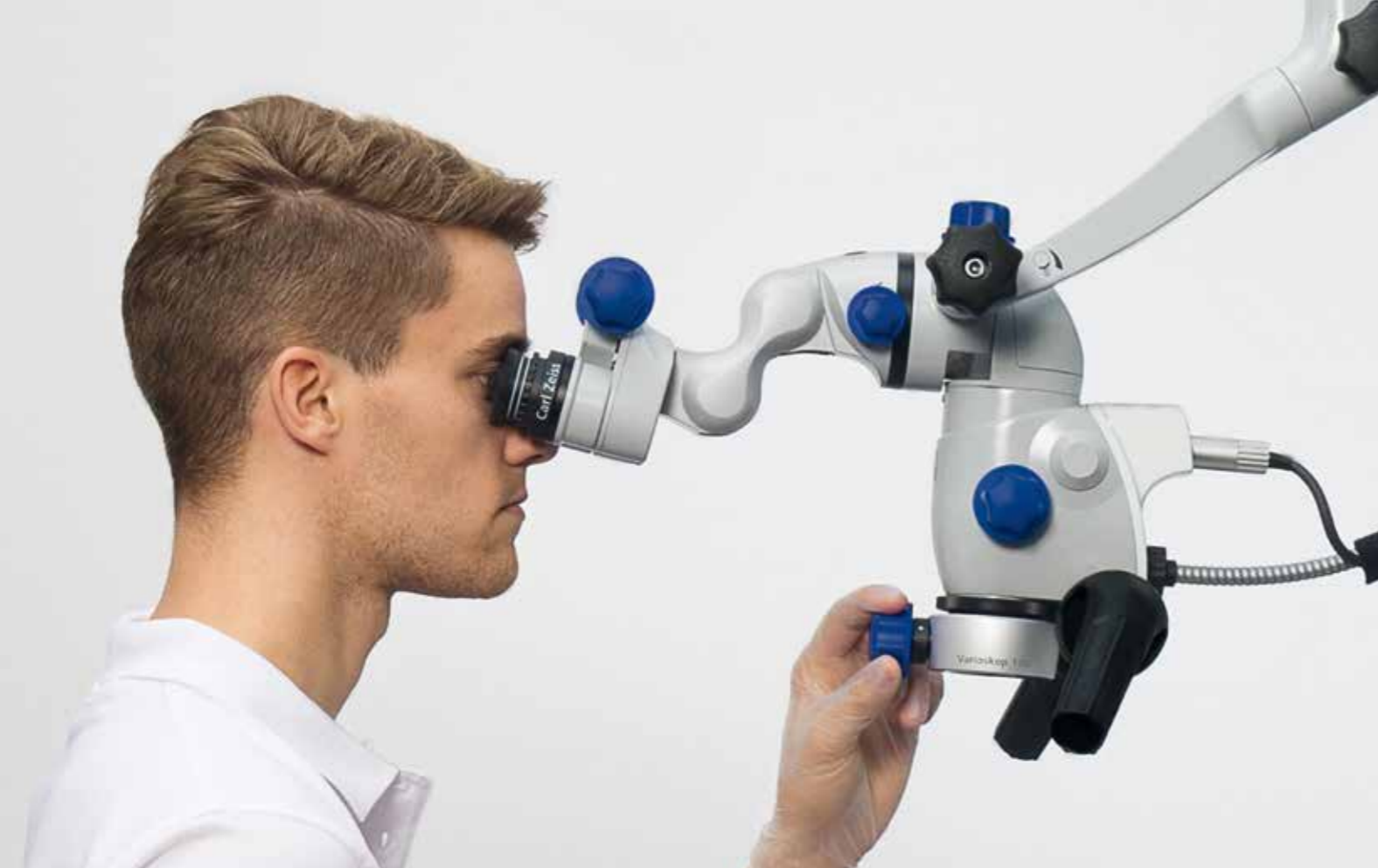

Figure 6.6

### Practical advice

#### Stabilization

In documentation with the OPMI sufficient stabilization is a must. Patients' movement due to breathing, swallowing and muscle tremor are an additional interfering and destabilizing factors. Here it is important to achieve maximum stability in the overall system comprising the dentist, instrument and patient. A direct support should be sought, e.g. a rubber dam on a tooth. It is important that adequate stability is achieved and that the area to be documented must be clearly visible.

#### Pixel size of camera

Another important subject is the sensor or pixel size, not only because it indirectly influences the depth of field, but also because noise increases with decreasing pixel size and the light sensitivity drops. A combination would be desirable: a small sensor size for the depth of field, large pixels for detail and modern sensor and signal processing technology.

#### ISO setting

This is achieved indirectly through amplification of the image signal. Here, both the useful (amplified) data and unwanted data (noise, crosstalk, etc.) are amplified. This in turn leads to digital picture images having a very grainy appearance at high ISO settings, i.e. they display a high level of noise.

#### Depth of field

The term "depth of field" is used to describe the extent that an object that can be seen as "sharp" in the image plane. The maximum depth-of-field ranges are defined by the OPMI optics (Table 1). If we bear in mind that the maximum magnification has a depth-of-field range of only 0.9 mm, it quickly becomes obvious that documenting at maximum magnification does not make any sense.

#### Band of sharpness

Due to the restricted depth-of-field range of the OPMI optics, the term

"band of sharpness" is used. The art is how to bring all important areas of the region to be documented into the image plane. The target eyepiece and the focusing monitor are of excellent assistance here.

#### Remote release

As any instability of the OPMI, combined with involuntary movement of the patient, involve the risk of system tremor, any unnecessary manipulations of the camera should be avoided. Only infrared or radio remote releases are suitable for this.

#### RAW or JPEG?

The discussion about the right file format would appear to be endless. Both have their merits, but also their drawbacks. JPEG is small, and in most cases does not need any editing and is immediately available. One of its drawbacks is the tricky setting of the image parameters and the limited editing possibilities.

RAW images are very big and definitely require post-processing with special software. This means that more time and effort is required to save the file, but also for user familiarization with the RAW workflow. The advantage of the RAW format is the broad spectrum of editing possibilities that it offers. The dynamic potential offered by the sensor can be utilized to the full (an important aspect), and the editing takes place under the full control of the user instead of in the black box of the camera. Here, once again, it is the personal taste and requirements of the user that are decisive.

#### Workflow

Once the picture has been taken, an efficient workflow must be established to take full advantage of the modern documentation systems. In 2014 it seems like an anachronism to remove the memory card from the camera and wait for the computer to import the images. This is time consuming and if

not done regularly, allocating the right images to the right patient can become problematic.

There are several Media-Workflow-Software solutions available. In conjunction with wireless technology like the Eye-Fi-Card a smooth, easy and user-friendly workflow is possible. The Recording-Solution from Zeiss streams live video into the network for viewing through various devices such as computer, iPad or similar. The software record onto shared network or USB devices as well as facilitate easy transfer on still images and HD videos to patient management software, but this software is not usable with external documentation solutions. Depending on the country, there are many solutions available on the market. As an additional benefit, most of the media-administering softwares are able to import literally all media, including CBCT-data. With the further growth of media data available it gets more and more important to have

a reliable archiving solution to hold all the data for the particular patient in one place with easy access. Without a post-processing workflow, documentation with the OPMI can easily become a time consuming and frustrating task.

#### Attachment:

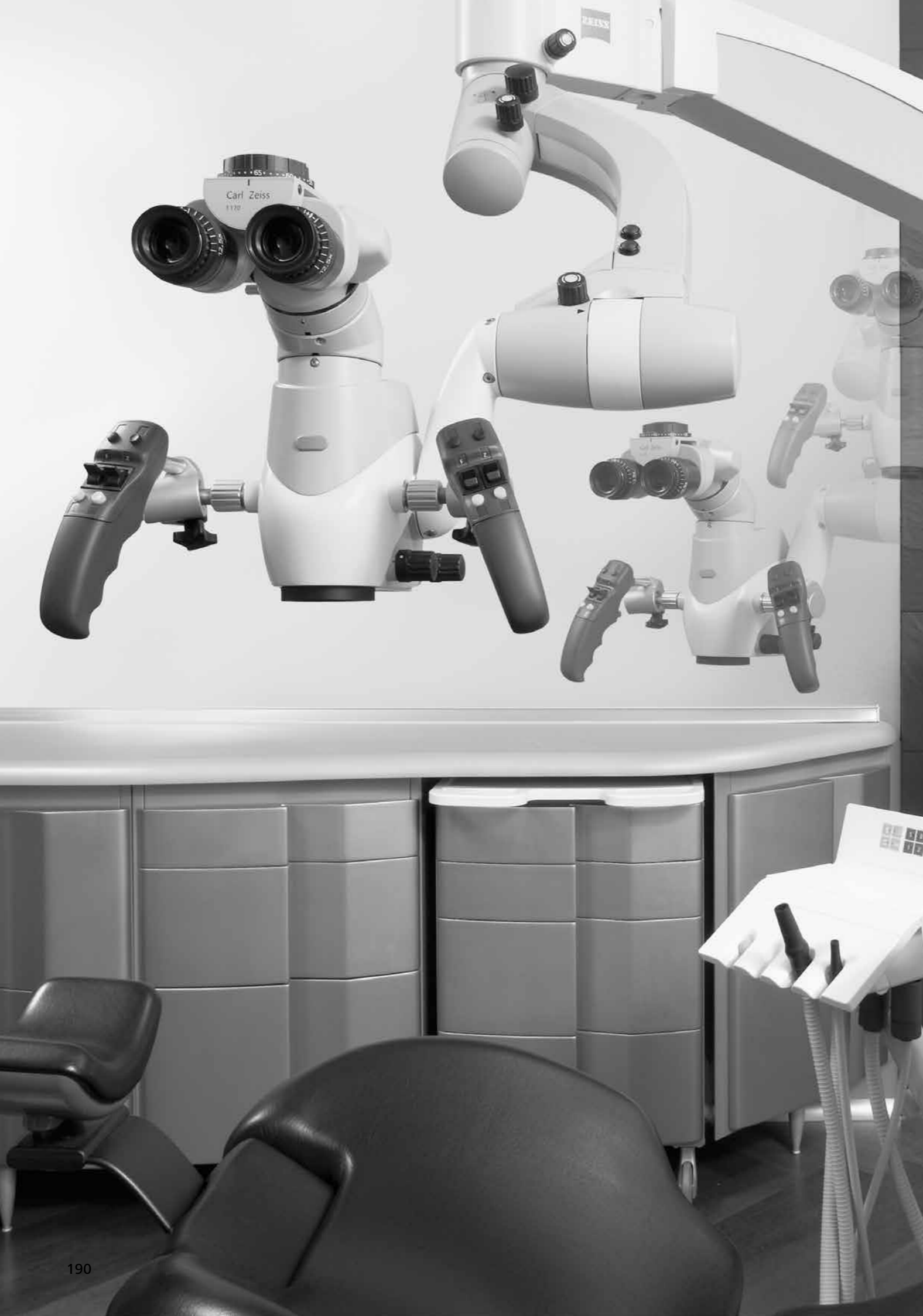For the attachment of a camera, it is important that the adapter is computed for the correct image circle. The most common sensor format in the consumer market is currently APS-C. Full-frame cameras do not offer any real benefit for OPMIs, but can be attached if desired.

# 7

## **7 Practice Management**

Author: **Dr. Manor Haas**

- 191 **The benefits of the OPMI extend far beyond the obvious and well-proven clinical benefits.**
- 192 **Integration into clinical practice**
- 193 **The OPMI as a communication tool**  
Dento-legal aspects
- 194 **Marketing the OPMI**
- 195 **Health benefits to the dentist**
- 196 **Financials of the OPMI**



## The benefits of the OPMI extend far beyond the obvious and well-proven clinical benefits.

As well as the multiple clinical benefits that have been explained in earlier chapters, the OPMI offers enormous potential for growth and ultimately can pay for itself many times over.

Many of the procedures highlighted could not be performed without the OPMI and therefore it enables the clinician to offer many more treatments than would otherwise be possible.

Having more control of the clinical environment can lead to greater efficiency (i.e. reduced time looking for sclerosed canals), less stress and more predictable outcomes.

Patients rapidly come to understand that a dentist using the OPMI is working at the very highest standards of the profession and with the ability to document, this greatly increases acceptance of treatments.

Figure 7.1



## Integration into clinical practice

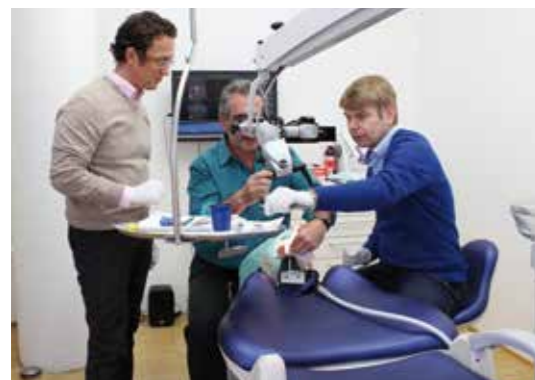

Figure 7.2 Dentist and his assistant getting training in a clinical environment

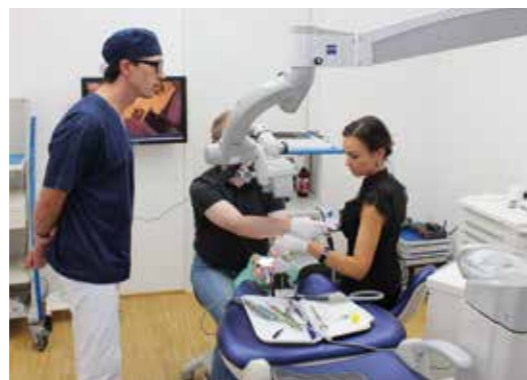

Figure 7.3 Dentist and his assistant trained in four-handed dentistry/assistance

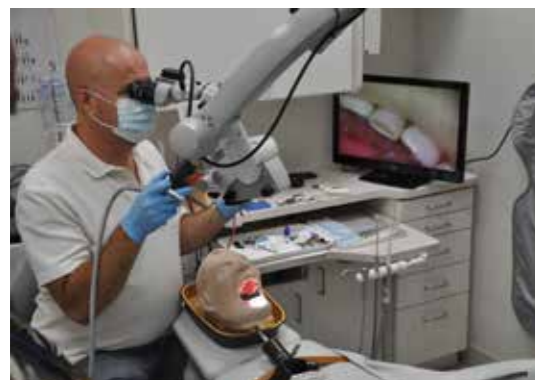

Figure 7.4 Note the low magnification, seen in the monitor, used while this dentist is in training

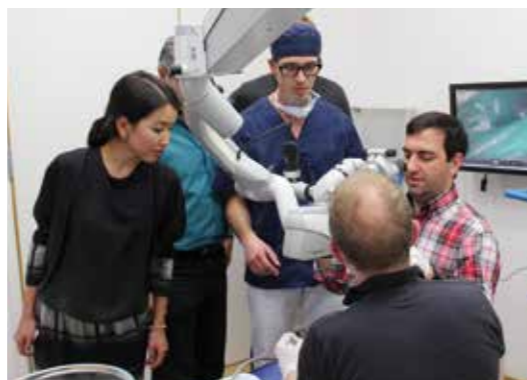

Figure 7.5 Dental assistants who are new to OPMI are receiving instructions from experienced assistants

The dentist and staff need to appreciate the fact that there is a learning curve to using the OPMI. In turn, a little bit of extra time should be set aside for treatments in the initial period until they become proficient in its use.

Dental assistants should be trained in true four (or six)-handed assisting under the OPMI prior to the introduction of the OPMI. This will help the dentist tremendously in practising efficiently and ergonomically.

When first using the OPMI, the dentist should work under low (or lower) magnification. As proficiency and comfort levels improve, magnification could be increased.

## The OPMI as a communication tool

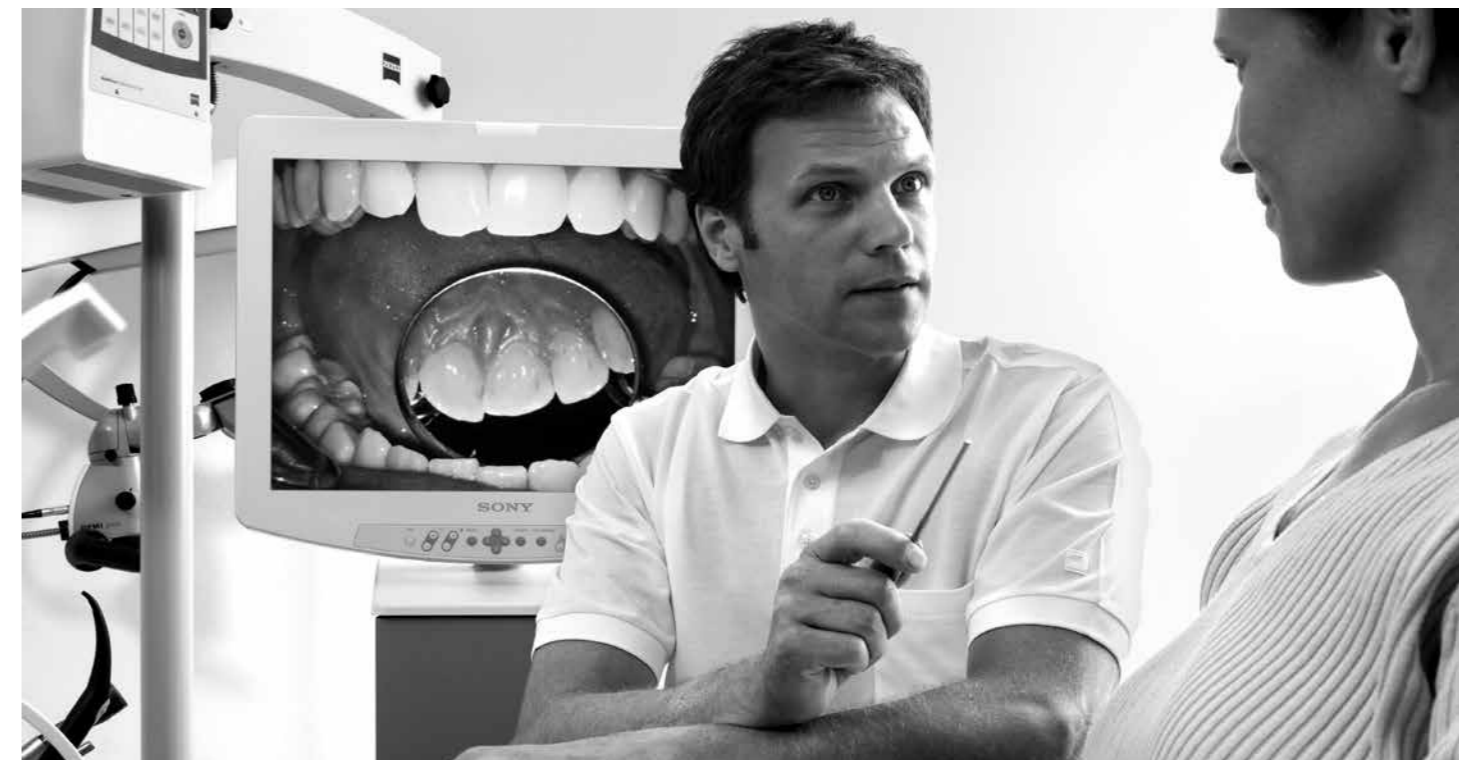

Figure 7.6 The patient's dental condition explained with the aid of the OPMI and camera.

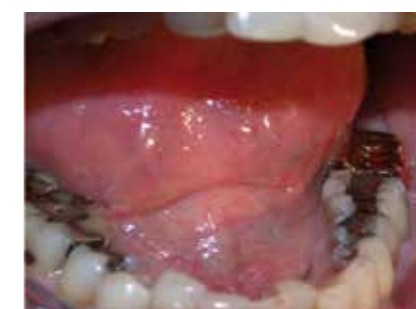

Figure 7.7 This is what patients see looking through a hand-held mirror

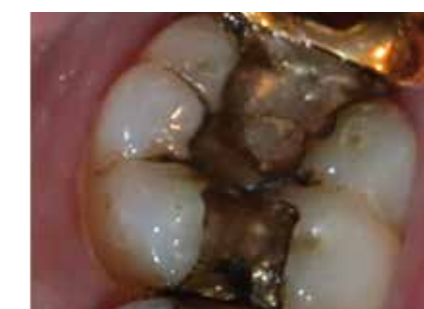

Figure 7.8 What patients see when shown an image captured with the OPMI

The use of the image capturing capabilities of the OPMI provides a powerful communication tool. Whether it is with still or video images, showing patients the state of their oral health makes it easier for them to understand the problem at hand. It is easier for patients to agree to treatment when, for instance, they are shown a close-up of a faulty restoration margin and are recommended to have it replaced. Acceptance of treatment would be reduced if it were only discussed verbally. The OPMI can therefore help to increase acceptance rates and treatment fees.

### Dento-legal aspects

A picture is worth a thousand words and this is very significant when it comes to record keeping. For instance, not only is it easy to diagnose hairline fractures, but it is also easy to record them in the patient's chart. The more documentation, the lower the dento-legal risks to the dentist. The more patients understand their dental condition, the less likely they are to misunderstand and complain.

## Marketing the OPMI

The mere use of the OPMI impresses patients and demonstrates the high level of treatment offered by the dentist. It is beneficial to the dental practice that marketing material includes information on the use of the OPMI. This could be done by means of various media such as paper print (i.e. office brochures and newsletters), a practice website and the social media. Informing patients of the fact the practice uses OPMIs also underlines to them that the practice stands out above and beyond other practices and is very advanced.

For dentists who have taken OPMI training courses, it is recommended that they display any certificates they obtained for patients to see and appreciate their dentist's proficiency in the use of the OPMI.

There is no shame in educating your patients and the general population about the benefits of the OPMI and of the fact that your dental practice uses it. Doing so becomes a win-win situation for patients and dentists: patients get better treatment and practices become more profitable.

## Health benefits to the dentist

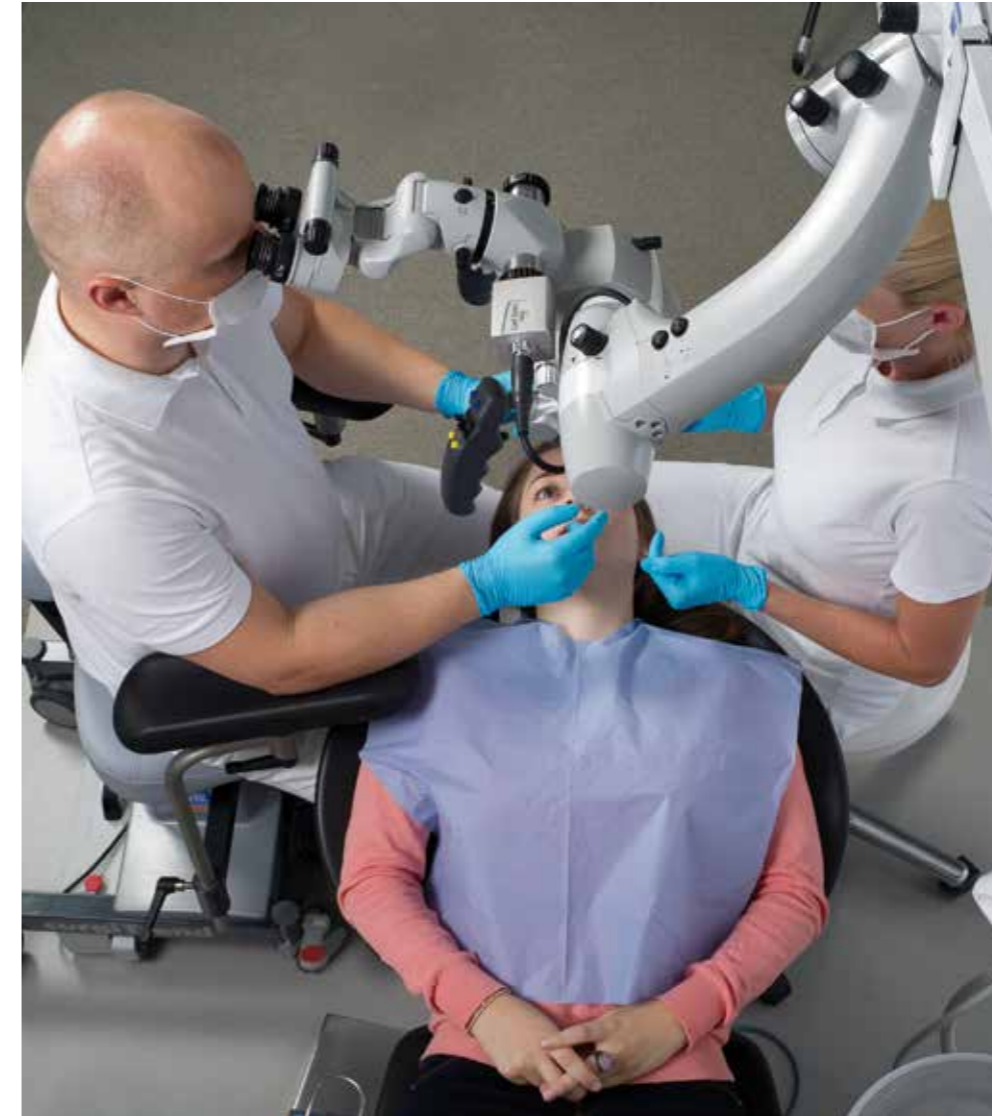

Figure 7.9 A dentist being trained in the use of an OPMI demonstrates good posture.

Improved ergonomics and posture with the OPMI become more obvious as the dentist becomes more proficient in its use. Improved ergonomics also means health benefits for the dentist. This may be in the form of reduced back and neck problems.

Better health results in the following:

- Ability to provide more treatments throughout the day/week. This also means increased patient throughput.
- Reduced downtimes due to injuries that plague many dentists leading to a better quality of life.
- Potentially longer dental career.

Better health makes for better work and better business!!

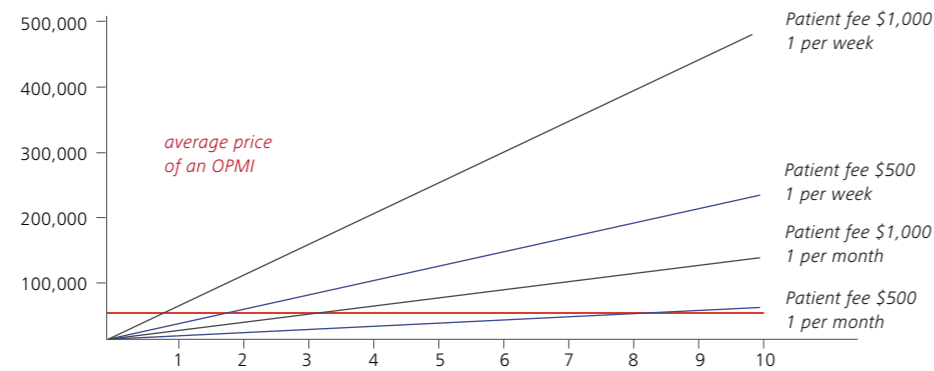
## Financials of the OPMI

### Return on Investment – Example

The increase in acceptance rates, improved quality of treatment, greater efficiency and enhanced reputation that may come with the use of the OPMI can result in financial benefits.

For instance, performing one root canal per month that the dentist is not able to perform without the magnification of an OPMI, may make it possible to pay for the OPMI or the loan of an OPMI in only a few years. This is only one example of how easy it is to justify the financial investment needed to purchase an OPMI.

Patient perception of the dentist, their office and their dental work can be enhanced with the OPMI. With proper patient understanding of the benefits of the OPMI, it is easier to justify an increase to your dental fees.

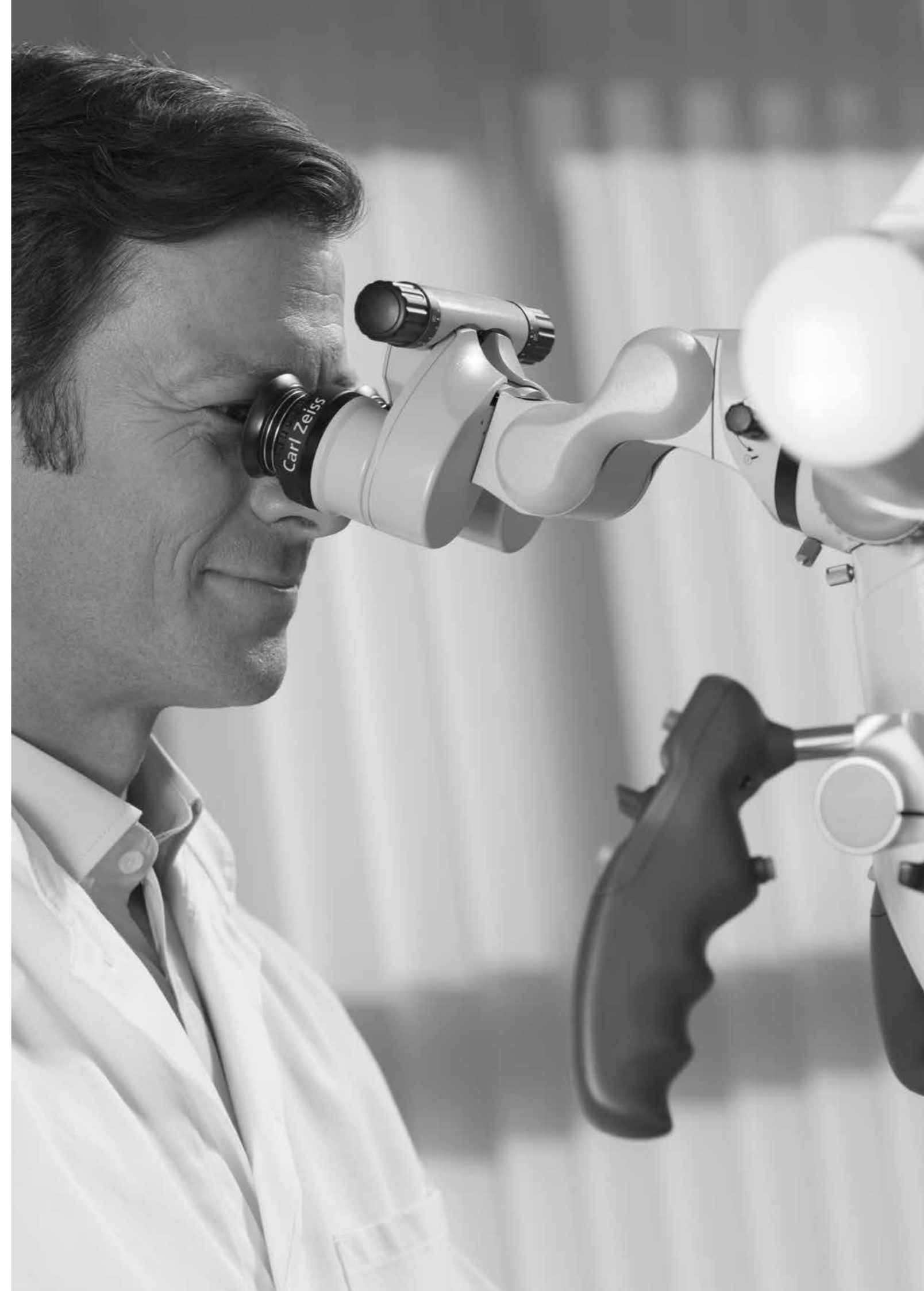

Procedure	Patient fee	Frequency of procedure	Income from procedure in 1 year	Income from procedure over 10 years (more after inflation)
Molar root canal (calcified)	\$500	1 per month	\$6,000	\$60,000 ++
	\$500	1 per week (48 weeks)	\$24,000	\$240,000 ++
	\$1,000	1 per month	\$12,000	\$120,000 ++
	\$1,000	1 per week (48 weeks)	\$48,000	\$480,000 ++

Table 7.1: The table demonstrates the return on investment of one common procedure (example fees), which the dentist may now be able to perform thanks to the OPMI:

Percent increase to dental fees	Increased income in 1 year	Increased income over 10 years (more after inflation)
1 percent (\$400,000)	\$4,000	\$40,000++
((\$800,000))	\$8,000	\$80,000++
2 percent (\$400,000)	\$8,000	\$80,000++
((\$800,000))	\$16,000	\$160,000++
5 percent (\$400,000)	\$20,000	\$200,000++
((\$800,000))	\$40,000	\$400,000++

Table 7.2: The table demonstrating the financial returns of increasing procedure fees in practices that, **for example**, gross \$400,000 and \$800,000 annually. Quite simply, when used regularly, the OPMI pays for itself very easily and quickly.





Dr. José Aranguren Cangas

Associate Professor of Endodontics at the Rey Juan Carlos University in Madrid.

Coordinator Professor of Adult Comprehensive Dentistry UEM (2008-2010).

Professor of the Postgraduate Programme in Endodontics and Restorative Dentistry at the Rey Juan Carlos University.

Title degree in dentistry from the Universidad Europea de Madrid (UEM 1995-2000).

Specialist in endodontics, Specialty Certified in Endodontics, University of Southern Mississippi (USM) (2000-2002). In private practice limited to endodontics in Madrid



Dr. Kristina Badalyan

Graduated from the Yerevan State Medical University, Armenia specializing in Dentistry in 1996. Attended a postgraduate programme in Endodontic Surgery at Central Institute of Scientific Research in Dentistry, Moscow, Russia, where she gained her Ph. D. Continues to work at the Institute and runs private practice in Moscow, where she specializes in implantology and oral surgery.

Has held numerous courses, master classes and congresses in ten largest cities of Russia and internationally. Active Member of NAED (National Academy of Aesthetic Dentistry) and Opinion Leader of Dentsply and Camlog. Also scientific editor of Quintessence Russia.



Dr. Rino Burkhardt

Graduated from University of Zurich and received his doctorate from the Medical Faculty of the same university. EFP (European Federation of Periodontology) certified specialist in periodontology. Received his master's degree from the Medical Faculty of the University of Berne (MAS in Periodontology).

Has maintained a private practice in Zurich limited to periodontology and implantology since 1995.



Dr. Annett Burzlaff

Graduated from the Free University of Berlin in cell biology in 1995. As postdoctoral research fellow, specialized in light and electron microscopy in cell biology at the German Cancer Research Center and managed the Central Laboratory for Microscopy at the University of Stuttgart.

In 2002, started as professional trainer for microscopy and imaging systems at Olympus Life and Material Science and Sirona Dental Services. Manager for training, application and support in dental and ophthalmic microscopy at Carl Zeiss Meditec AG since 2008.



Dr. Maciej Goczewski

Graduated from the Medical University of Gdansk in 1999. Experience working at GKT, King's College, London, UK and Académie Internationale pour Implantologie Orale, Paris, France. He has earned his Ph.D. title in 2010.

For most of his career, he has worked at his private clinic and presided at the Polish Society of Microscopic Dentistry. Main fields of interest are ergonomics and microscopic dentistry; six-handed and four-handed variants in both. Shares his experience organizing numerous courses and attending conferences as a speaker.



Dr. Manor Haas

Graduated from the University of Toronto, Faculty of Dentistry in 1997. Immediately invited to teach at the University of Toronto Restorative and Prosthodontic Departments. Alongside his teaching positions, practiced general dentistry and pursued endodontic research.

Pursued his endodontic and microsurgical specialty training in the Graduate Endodontics Programme at the Albert Einstein Medical Centre in Philadelphia, Pennsylvania.

Has run a private specialty practice in Toronto, limited to dental implantology, microsurgery and endodontics. Gained decade of experience incorporating the OPMI exclusively into his practice.



Oscar Freiherr von Stetten

State examination at the FU Berlin. Own practice since 2001, featuring OPMI support and specialization in endodontics, as well as minimally invasive dentistry. Own endodontics referral practice since 2006.

Numerous lectures and publications on documentation with an OPMI, as well as working ergonomically correct in a team with the OPMI

Key Opinion Leader for multiple dental companies regarding the development of new products. Worked for ZEISS as KOL for documentation with an OPMI.



Dr. Bijan Vahedi

Graduated from University of Leipzig and received doctorate from the Medical Faculty of University of Ulm. Specialist in endodontics of DGET (German Association of Endodontology and Dental Traumatology), certified member of ESE (European Society of Endodontology) and international member of the AAE (American Association of Endodontics) Runs a private practice in Augsburg / Germany limited to endodontics. Currently vice-president of DGET. Speaker at congresses, lectures, courses and master classes nationally and internationally.



Dr. Maxim Stosek

Graduated from the UPJS University in Kosice, Slovakia in 2000. Since 2003, has run own practice limited to microscopic restorative dentistry in Presov, Slovakia, spreading idea of microinvasive treatment successfully not only in patients but also and mainly among dental community in Slovakia.

Lectures and publishes nationally and internationally on composite layering techniques, endodontics and nowadays mainly OPMI based dentistry and dental ergonomics. Parttime teacher at the UPJS University in Kosice, Slovakia.



Dr. Claudia Cia Worschech

Graduated from UNICAMP, where also received her masters, doctorate and postgraduate degrees. Currently President of Brazilian Academy of Microscope Dentistry / ABRAMO from 2014 to 2017

Active member of Editorial Board at ESTETICA, an important journal about aesthetic dentistry in Brazil, published by Dental Press.

Owner and scientific director of GENIO: center of excellence for microdentistry in Brazil. Has held numerous courses, master classes and congresses all over the world, including lectures in Japan, USA, Lithuania, Portugal, Argentina and Brazil.

Has run private practice in Sao Paulo, Brazil, since 1993.



**Dr. Tony Druttman**

1981 Qualified B.Ch.D. Leeds University, 1987 M.Sc. Conservative Dentistry, Eastman Dental Hospital, London University. Since 1999 a registered specialist and practice limited to endodontics. His principal area of interest is non surgical re-treatment.

He has been a member of the British Endodontic Society for over 30 years and was President of the Society in 1994. He is also a Certified Member of the European Society of Endodontology.

He is a visiting specialist teacher at the Eastman Dental Institute, where he teaches endodontics and runs courses with Dr Greg Finn on microscopes in dentistry.

He has lectured both in the UK and at international meetings on endodontics and radiography in endodontics.

He is on the editorial board of Endodontic Practice Journal and is a contributing author.



**Dr. Greg Finn**

Qualified as a dentist in Brisbane in 1982, specialist prosthodontist with a referral practice in London, as well as a clinical lecturer at the UCL Eastman Dental Institute. He runs courses on microscopes in dentistry at EDI with Dr. Tony Druttman



**Slaven Sestic**

Carl Zeiss Meditec AG  
Field Education Manager  
ZEISS ACADEMY



*Our Authors TEAM in Barcelona, Spain in 2013*

Inspiration is one thing and you can't control it, but hard work is what keeps the ship moving. There are no secrets to success. It is the result of preparation, hard work, and learning from failure. We would like to thank you sincerely for all your enthusiasm and hard work, thank you for all good times, days filled with pleasure and great memories.

Your ZEISS Team

# Pictures credits

Page 11,13	Dr. Claudia Cia Worschech	Page 152	5.20 Dr. Maxim Stosek
Page 14-17	Carl Zeiss Meditec AG		5.21, 5.22 Dr. Claudia Cia Worschech
Page 18-19	Dr. Rino Burkhardt	Page 153	5.23, 5.24 Dr. Claudia Cia Worschech
Page 20-21	Carl Zeiss Meditec AG		5.25, 5.26 Dr. Maxim Stosek
Page 24	Carl Zeiss Meditec AG	Page 154-165	Dr. Claudia Cia Worschech
Page 25	Carl Zeiss Meditec AG, Fotolia	Page 166-167	Dr. Maxim Stosek
Page 26-27	Dr. Claudia Cia Worschech	Page 168-172	Dr. Claudia Cia Worschech
Page 28	Fotolia	Page 173	Carl Zeiss Meditec AG
Page 30-36	Carl Zeiss Meditec AG	Page 174-175	Dr. Claudia Cia Worschech
Page 37	1.8 Oscar von Stetten	Page 180	Dr. Bijan Vahedi
Page 38-51	Carl Zeiss Meditec AG	Page 182-183	Oscar von Stetten
Page 54-67	Carl Zeiss Meditec AG	Page 184	Dr. Kristina Badalyan
Page 68	Dr. Maciej Goczewski	Page 185	Oscar von Stetten
Page 69	Oscar von Stetten	Page 186	Carl Zeiss Meditec AG
Page 72-73	Dr. Kristina Badalyan	Page 190	Carl Zeiss Meditec AG
Page 74-75	Dr. José Aranguren Cangas	Page 192	Dr. Manor Haas
Page 76-78	Dr. Tony Druttman	Page 193	7.5 Carl Zeiss Meditec AG, 7.6, 7.7 Dr. Manor Haas
Page 79	3.8a, 3.8b, 3.8c Dr. José Aranguren Cangas	Page 195	Carl Zeiss Meditec AG
	3.10, 3.11 Oscar von Stetten	Page 197	Carl Zeiss Meditec AG
Page 80-81	Dr. Tony Druttman		
Page 82	3.17 Dr. Tony Druttman, 3.18a, 318b Dr. José Aranguren Cangas		
Page 83-85	Dr. Tony Druttman		
Page 86	3.22a, 3.22b, 3.22c Dr. Tony Druttman 3.23 Oscar von Stetten		
Page 87-90	Dr. Tony Druttman		
Page 91	Oscar von Stetten		
Page 92	3.27, 3.28 Dr. José Aranguren Cangas 3.29a, 3.29b Dr. Tony Druttman		
Page 93-94	Dr. Tony Druttman		
Page 95	3.39 Dr. Tony Druttman 3.40 Carl Zeiss Meditec AG		
Page 96-101	Dr. Kristina Badalyan		
Page 104-121	Dr. Rino Burkhardt		
Page 125-127	Dr. Rino Burkhardt		
Page 134-137	Dr. Claudia Cia Worschech		
Page 138-139	5.2; Dr. Claudia Cia Worschech 5.3; 5.4; 5.5; 5.6 Dr. Maxim Stosek		
Page 140-145	Dr. Claudia Cia Worschech		
Page 146	Dr. Maxim Stosek		
Page 147	5.13 Dr. Claudia Cia Worschech 5.14, 5.15a, 5.15b Dr. Maxim Stosek		
Page 148	Dr. Claudia Cia Worschech		
Page 149	Carl Zeiss Meditec AG		
Page 150-151	Dr. Maxim Stosek		

## Carl Zeiss Meditec AG

Goeschwitzer Straße 51-52  
07745 Jena, Germany

Telefon: +49 3641 220-0  
info.meditec@zeiss.com

Copyright©2014 Carl Zeiss Meditec AG

All rights reserved. No part of this book may be reproduced or transmitted in any form by any means, electronic, mechanical, photocopying, recording, or otherwise, without the prior written permission of the publisher.  
For Information, contact Carl Zeiss Meditec AG

Download the Microscopic  
Dentistry Practical Guide under:  
[www.zeiss.com/dental-book](http://www.zeiss.com/dental-book)



**EN\_30\_200\_0149 I** Printed in Germany AW-CZ-VII/2013 Koo International Edition: Not for use in the United States.  
The contents of the brochure may differ from the current status of approval of the product in your country. Please contact our regional representative for more information.  
Subject to change in design and scope of delivery and as a result of ongoing technical development. Printed on elemental chlorine-free bleached paper.  
OPMI, Varioskop and VisionGuard are registered trademarks of ZEISS. PROMAG, FlexoStill and FlexioMotion are trademarks of ZEISS.  
© 2014 by Carl Zeiss Meditec AG. All copyrights reserved.