

THE DMR METHOD

DMR1 STUDY



Disc herniations and listhesis type spinal lesions treated nonsurgically; clinical correlations and observation via upright MRI

Peter L'Allier, DC, Hopkins Health & Wellness Center*

Abstract

Objective: Study the effects of a specific protocol (the DMR Advanced Protocol; see chapter 4) of physical therapy and chiropractic treatment on disc pathology and listhesis-type lesions both clinically and objectively via magnetic resonance imaging (MRI).

Methods: Twenty-three patients with spinal lesions were treated nonsurgically for eight to ten weeks with a specific regimen of treatment (the DMR Advanced Protocol). Objective data regarding the quantity and quality of spinal lesions were obtained through upright MRI study both before and after treatment so results could be compared to baseline data.

Results: Treatment produced significant changes in Oswestry Disability Index scores,, disc herniation size and resolve of neurologic compromise.

Conclusions: The nonsurgical, conservative DMR protocol of treatment provides equally effective treatment for disc herniations and discogenic neurologic compromise in a fraction of the time of traditional medical management and rehabilitation.

Study Type: Practice-based retrospective observational cohort of consecutive patients with lumbar disc herniation, disc bulge, or listhesis.

Key Words: lumbar disc herniation, neurologic compromise, DMR protocol, conservative treatment, magnetic resonance imaging, physical therapy.

**Clinician, Peter L'Allier, DC, Hopkins Health & Wellness Center, Hopkins, MN, USA*

Corresponding Author: Pete L'Allier, PT@hopkinswellness.com

This study was supported by Hopkins Health & Wellness Center. Nothing of value was received from a commercial entity related to this manuscript.

Submit Reprint Requests to: Shannon Jones, Hopkins Health & Wellness Center, 15 8th Avenue N, Hopkins, MN 55343, tel. 952-933-5085, PT@hopkinswellness.com.

Introduction

Lumbar disc herniation is the most common musculoskeletal cause of low-back pain in patients under forty-five years of age.⁶ Treatment for lumbar disc herniation has been a topic of research for nearly fifty years. Surgeries for disc herniation are the most common surgery performed on the spine.¹⁶ Current data suggests residual back pain in 74 percent of lumbar disc herniation surgery patients, 12 percent of who required repeat surgery.²⁴ With the high rate of failed surgery, current research often focuses on the use of conservative treatment in the care of patients with lumbar disc herniation.

With the greater availability of advanced imaging, numerous studies have observed the natural history of herniations. Spontaneous reabsorption is now a well-documented part of the natural clinical progression of this condition.^{1-11,19-21,23} It is now well accepted that, given time and conservative treatment, disc herniations will reduce in size. Conservative care has been demonstrated to be more cost effective and equally as effective as surgery in long-term studies.^{2,6,8,16,21} Most research suggests an average treatment time of thirty-four to forty-three weeks is sufficient to treat disc herniations conservatively.^{2,4-6,9,11,18,23} However, “conservative treatment” is not uniformly defined. The majority of studies researching conservative treatment of lumbar disc herniations utilize such medical procedures as epidural steroid injections, epidural blocks, nerve blocks, analgesics, medications, and bed rest.^{2,3,6,8,11,16,21,23} Few studies have investigated lumbar disc herniations without the use of medical intervention.

In the current study, treatment includes a specific protocol of conservative treatment called the DMR protocol. This study seeks to observe and analyze the effects of the DMR protocol of conservative treatment in the management of lumbar disc herniations, disc bulges, and listhesis type lesions.

Materials and Methods

Twenty-three consecutive patients presenting with low-back pain or leg pain who were treated for disc herniation or lumbar listhesis were selected for the study. These patients each completed paperwork, pre- and post-Oswestry Disability Questionnaires, and two MRI studies. Of the study participants, 60 percent were male and 40 percent were female, with an average overall age of fifty-two. Of these twenty-three patients, 24 percent presented within eight weeks of onset of symptoms and were considered still in the acute phase of injury. The median age of those patients admitted in the acute phase was 47.5, while the median age of those presenting with chronic low-back pain was 54.

Conservative treatment of the twenty-three patients included a specific protocol of physical therapy and chiropractic treatment called the DMR Method protocol. This nonsurgical treatment protocol is a progressive process of manual therapy, specific spinal manipulation, adjunctive therapies, mechanical spinal traction, and an extensive personalized rehabilitative process. The rehabilitative process includes posture, ergonomics, and body mechanics education; stretching and flexibility techniques; and a exercise program that focuses on strength, stability, and spinal balance. Nutritional supplements were also provided to assist soft-tissue healing. Patients were seen in-office for twenty to twenty-four visits over an eight-to-ten-week period. The frequency of care was gradually reduced from three times per week to two.

The twenty-three study participants completed an Oswestry Disability Index Questionnaire to evaluate function and disability due to pain prior to treatment (scored 0 to 100, with a greater score representing a greater degree of disability). The questionnaire was again completed following the completion of eight to ten weeks of conservative treatment. Change in individual scores was calculated as:

$$([initial\ score - final\ score]/initial\ score) \times 100 = percent\ improvement$$

Additionally, t-test statistical analysis was performed to evaluate the significance of the change in scores.

MRI studies were obtained prior to treatment and immediately following treatment. MRI scans were performed on a 0.75T upright scanner. T2 upright neutral, flexion, and extension sagittal images, T1 neutral sagittal and T2-weighted axial images were obtained during each evaluation. Both MRI studies were evaluated by the same radiologist, acting as an independent investigator. The radiologist was to report the presence of any disc bulges, herniations, or listhesis-type lesions and quantify the lesions. Herniations were to be classified as protrusions or extrusions. Listhesis-type lesions were evaluated for dynamic quality on sagittal flexion and extension scans. Data and change in quality and quantity of lesions was recorded and evaluated with t-test analysis. The change in size of lesions was defined as:

$$(1-[lesion\ size\ on\ later\ scan/lesion\ size\ on\ initial\ scan]) \times 100 = percent\ improvement$$

Results

Decreases in pain and disability were found in 100 percent of patients. Patients averaged a 51.1 percent decrease in pain and disability as assessed by

Oswestry Disability Questionnaire. The average initial score decreased from 35 percent to 16.7 percent. This difference was statistically significant, with a p-value of 1.1E-5. Further, 43 percent of patients experienced a decrease in pain and disability greater than 50 percent. The majority of patients (82 percent) achieved an increase in function greater than 25 percent. The greatest changes in pain and disability (66 percent) were noted in those patients presenting in an acute phase of less than eight weeks duration. Those presenting with chronic low-back pain experienced, on average, a decrease of 43.2 percent in pain and disability, which is still significant.

The greatest decrease in pain and disability was noted in those patients presenting in the age group of fifty to fifty-nine. On average, this group experienced a decrease in pain and disability of 60.1 percent. The age group experiencing the least reduction in symptoms and disability were those in the seventy to seventy-nine age group. This is consistent with the pathophysiology of this condition as the degree of disc hydration, and therefore the body's ability to reabsorb, greatly decreases with age.

This study also showed a correlation between gender and degree of functional improvement. Female patients experienced an average 66.6 percent decrease in pain and disability; in comparison, male patients only experienced a 39.2 percent decrease, a statistically significant difference with p-value of 0.019. The women (average age of 50.6) were slightly younger than the men (average age of 54.3). On average, the women completed the protocol in eleven weeks, while the men completed treatment in 10.6 weeks. Neither the differences in age or duration of treatment are statistically significant.

The MRI data revealed a statistically significant difference in the change of both disc herniation and listhesis-type lesion size. The greatest changes in disc herniation size were noted among those presenting in the acute stage (57.1 percent) of injury and women (44 percent), despite the greater number of herniations in men and those presenting with chronic conditions. The average degree of change in herniation size was 42.1 percent among those experiencing a change. Reabsorption occurred in 100 percent of the disc herniations treated within eight weeks of occurrence. Similar to previous studies, the greatest degree of change was noted in larger lesions. Herniations measuring greater than 8mm decreased by an average 76 percent over the course of the eight to ten weeks of treatment.

In addition to the resolution or modification of lesions, neurologic compromise was also evaluated. The treatment utilized in this study produced statistically significant resolution of neurologic compromise, p-value 0.021, via MRI. Overall, 60 percent of those experiencing reduction were women and 60 percent presented in the acute phase of injury.

A correlation between resolution of neurologic compromise and restored function was quite high, with a p-value of 0.0093. Those who experienced a reduction of demonstrable neurologic compromise had an average change in Oswestry Disability Index of 79.1 percent. This is strikingly different from the average 33.8 percent change in Oswestry scores experienced by those without resolution of neurologic compromise.

Discussion

Lumbar lesions such as disc herniations, disc bulges, and listhesis are common occurrences. Herniations are reported to naturally occur in 31 to 33 percent of an asymptomatic population.^{6,17} The natural history of lumbar disc herniations is to spontaneously regress.^{1-11,19-21,23} Though the mechanism is not understood completely, research points to the involvement of macrophages in phagocytosis of discal remnants.^{8,10,19-20,23} This process involves the combination of inflammation and neovascularization for phagocytosis.¹⁰

The use of MRI may provide some clinical indications as to the likelihood of herniations to reabsorb. The herniated disc material is more likely to be reabsorbed if it has violated the posterior longitudinal ligament as the likelihood of neovascularization is greater.^{2,11,23} In addition to disruption of the PLL, the signal of the disc on a T2 weighted scan may be indicative of reabsorption. The greater the intensity of T2 signal, the more likely a disc herniation is to reabsorb.^{8,11} However, the natural healing process of the disc herniation via reabsorption will cause an increase in degenerative disc disease at the level of herniation.^{1,19,22} Thus the greater the initial T2 signal, the greater the level of dehydration and resulting reabsorption of disc material. Finally, the size of the lesion itself may be an indication as to the degree of reabsorption. Numerous studies have demonstrated that the larger the size of the herniation, the greater the degree of reabsorption.^{2,4-5,10-11}

Similar results were demonstrated in this study, as 60 percent of those herniations measuring greater than 8mm had an average 76 percent decrease in size over the course of treatment. Overall, a statistically significant difference was found in regards to the decrease in size of disc herniations following treatment. Furthermore, patients enrolled in treatment experienced an average 23.8 percent decrease in the quantity of neurologic compromise as noted on MRI.

With the increased knowledge of the natural history of disc herniations, more research has been done on the conservative treatment of such conditions. Conservative care, though shown to be cost effective, is not well defined.^{2,6,8,16,21} Spinal steroid injections are one of the most common conserv-

ative care interventions for pain and inflammation control in the research of patients with lumbar disc herniations.^{2-3,6,8,11,16,21} The efficacy of steroid injections, however, has been demonstrated to be limited to inflammation and pain reduction as it does not aid the reabsorption of disc material.¹¹ Memmo, et al., reported that 32 percent of patients who received surgery for lumbar discectomy had previously received an injection.¹⁶

Very little research exists on the nonmedical treatment of disc pathology. Favorable results have been reported with treatment utilizing physical therapy and/or chiropractic manipulations.^{9,19,22} Though both medical and nonmedical treatments report positive results, the average treatment time for nonmedical interventions is drastically less.^{2,4-6,9,11,18,22,24} The average study of nonmedical treatment (chiropractic or physical therapy) consisted of 3.5 weeks of care, whereas the average medical conservative care plan studied averaged thirty-nine to sixty-five weeks. This significant difference in treatment duration may have greater social implications in terms of time away from work caused by pain or decreased function.

In the current study, patients were prescribed eight to ten weeks of conservative treatment, including the DMR protocol of physical therapy and chiropractic treatment. Fully 78 percent of patients completed the prescribed treatment plan and MRI scans within the allotted time; however, five patients took longer than eleven weeks to complete treatment. All patients saw a decrease in clinical symptoms and an increase in function, as determined by Oswestry Disability Questionnaire. On average, those patients that completed the program within ten weeks saw a decrease in Oswestry Scores of 46.7 percent, which is slightly lower than the average 67.1 percent decrease seen by those who took longer than eleven weeks to complete the treatment plan. Of those patients receiving treatment longer than ten weeks, 60 percent were chronic cases. Such data suggests that perhaps a treatment period of greater than ten weeks may be beneficial to the treatment of chronic conditions. The data also supports previous findings that nonmedical treatments can be equally effective while requiring much less time.

Studies have consistently shown the spontaneous reabsorption of disc herniations in 63 to 95 percent of patients.^{1,11,23} Studies have shown continued reabsorption over time, up to 95 percent at seven years post injury. In addition, it is reported that 63 to 78 percent of all herniated discs will reduce in size to some degree over the course of a few years.^{3,5-6,11,21} Reabsorption of more than 50 percent of disc herniation size may be seen in 48 to 50 percent of people with lumbar disc herniations.^{5,23} The greatest results are demonstrated by larger initial herniations.^{8,11} The resolution of disc bulges, however, is much less likely with conservative treatment. Bush K, et al., demonstrated that only 26 percent of disc bulges resolved with conservative treatment.³

The current study revealed a statistically significant difference in the size of herniations following treatment, with a p-value of 0.05. Of those patients, 57.1 percent presenting within the acute stage of injury saw reduction of 50 percent or more of the herniation size of one or more herniations within the treatment time of two months. These results are slightly better than those of previous studies despite the great variation in the duration of treatment in those studies. With follow-up MRI studies being obtained, on average, ten weeks following initial presentation, the duration of the current study was roughly 12 to 20 percent of the average treatment time of other medical studies. It is predicted that follow-up studies performed closer to twelve to eighteen months following initial presentation would demonstrate greater results.

In addition to the statistically significant reabsorption of disc herniations, the resolution of neurologic compromise in patients was also statistically significant in this study, with a p-value of 0.021. Patients experienced an average 23.81 percent reduction in neurologic compromise demonstrated via MRI. Further, 42.86 percent of patients experienced a complete resolution of neurologic compromise at one or more spinal levels following the ten-week nonmedical treatment. Women and those presenting with acute conditions were more likely to experience resolution of neurologic compromise (60 percent).

Though the presence of neurologic compromise is not necessarily indicative of pain, the change in Oswestry scores for those experiencing a reduction in neurologic compromise was 79.1 percent, as compared to the 33.8 percent who experienced no change in neurologic compromise. This statistically significant difference, with p-value of 0.0093, also correlates with the resolution of disc herniations. A statistically significant difference, p-value 0.005, was apparent between the degree of resolution of herniations among those experiencing resolution of neurologic compromise and those who did not. These significant correlations support the idea that herniations causing neurologic compromise are indeed the source of much pain and functional disability. It also suggests that resolution of neural pressure and irritation may significantly improve function and reduce pain.

Similar to previous studies, the resolution of disc bulges was unimpressive. In the ten-week treatment, 22.2 percent of patients with disc bulges experienced resolution of their bulge. This is not a significant difference (p-value 0.17). In addition, of those patients presenting with listhesis-type lesions, only 15.8 percent experienced resolution of the lesion. This is not statistically significant (p-value 0.1). All of the patients experiencing resolution of a disc bulge or listhesis presented with chronic low-back pain.

The conservative care of disc herniations has proved to be highly effective clinically. Studies have reported subjective improvements from 65 to 96 percent with various screening tools.^{1,2,6,8,11,18} For the purpose of this study, the Oswestry Disability Index Questionnaire was used to evaluate pain and functional disability because of its high degree of responsiveness.¹³ The Oswestry Disability Questionnaire is scored 0 to 100 percent (the greater the score, the greater the degree of functional disability). Unlu Z, et al., demonstrated the average base line Oswestry Score for patients with one or more disc herniations as being 19.1 percent.⁹ Following treatment with one physical therapy modality, Unlu demonstrated a decrease in Oswestry score to an average 14.6 percent, an average change of 23.56 percent.⁹

The results of the current study demonstrated far greater clinical improvement than the aforementioned study. The current study resulted in 100 percent of patients seeing some degree of increase in function. The average initial Oswestry score upon presentation was 35 percent disability. The average Oswestry score following the treatment protocol was 16.7 percent—an average 51.1 percent decrease in functional disability, with p-value of 1.12E-5. This change is over two times of that demonstrated by Unlu utilizing one-physical therapy modality.⁹

The greatest restoration of functional ability was noted among those patients who presented in the acute phase. These patients saw a 66 percent increase in function within ten weeks of treatment. 100 percent of the patients presenting for treatment in the acute phase (within eight weeks of disc herniation occurrence) showed disc herniation reabsorption on post-treatment MRI evaluations. Still significant increases of an average 43.2 percent were seen in those who presented with chronic low-back conditions of more than two months in duration. Further, 43 percent of the patients in the study obtained greater than a 50 percent increase in function following ten weeks of treatment. These significant improvements in such a short duration of treatment suggest the high degree of efficacy of nonmedical treatment of disc pathology and listhesis lesions, and that early intervention can improve outcomes..

Complications of this study, like any study, will limit the relevance of conclusions. One complication that arose in this study was the inconsistency of treatment. While the majority of patients completed treatment in the recommended time, a few outliers took longer to complete treatment. In addition, while all patients completed the same protocol, there were some variations within the protocol regarding stretches, exercises, etc. that may have been specifically tailored to the patient's needs. A follow-up study that would control these areas of variability may provide more valid conclusions.

Conclusions

On average, patients experienced a 50.1 percent increase in function within ten weeks of treatment. Disc herniation reabsorption can be improved with treatment. The size of the herniation as well as the time elapsed from disc herniation occurrence and treatment can have an influence on reabsorption rates. The best results were obtained by those presenting within eight weeks of injury, women, and those between the ages of fifty to fifty-nine. Strong correlations exist between the presence of neurologic compromise, functional disability, and pain. Conservative, nonsurgical treatment with the DMR protocol may be highly effective in the treatment of disc herniations and neurologic compromise caused by such pathology. Further, resolution of disc herniations and neurologic compromise with this nonsurgical treatment may be possible to achieve in far less time than with accepted medical interventions.

Acknowledgements

The authors would like to thank William J. Mullin, M.D., Spine Radiologist; Timothy Mick, DC F.I.C.C., D.A.B.C.R.; and Thomas J. Gilbert, M.D., M.P.P. at The Center for Diagnostic Imaging for their assistance in interpretation of the Magnetic Resonance Imaging studies and assisting in selection of imaging sequences. We would also like to thank Jannel P. Kammerer, MPT for helping to develop and administer the initial physical therapy treatment protocol. Finally, we would like to thank the clinical staff of Hopkins Health & Wellness Center for providing excellent healthcare services to all patients in the study. A special thank you to Stephanie E. Musselman, DC, MS, DACB for her hard work in organizing all the case study data and statistical analysis. Without her help and research expertise, this study would not have been possible.

References

1. Masui T, et al. Natural history of patients with lumbar disc herniation observed by magnetic resonance imaging for a minimum of seven years. *J Spinal Disord Tech* 2005;18:121-126.
2. Ito T, Takano Y, Yuasa N. Types of lumbar herniated disc and clinical course. *Spine* 2001;26(6):648-651.
3. Bush K, Cowan N, Katz D, Gishen P. The natural history of sciatica associated with disc pathology: a prospective study with clinical and independent radiologic follow-up. *Spine* 1992;17(10):1205-1212.

4. Yukawa, et al. Serial Magnetic Resonance Imaging follow-up study of lumbar disc herniation conservatively treated for average 30 months: relation between reduction of herniation and degeneration of disc. *J of Spinal Disord* 1996;9(3):251-256.
5. Bozzao A, et al. Lumbar disc herniation: MR imaging assessment of natural history in patients treated without surgery. *Radiology* 1992;185:135-141.
6. Memmo P, Nadler S, Malanga G. Lumbar disc herniations: a review of surgical and nonsurgical indications and outcomes. *J of Back and Msk Rehab* 2000;14:79-88.
7. Saal J, Saal J, Herzog R. The natural history of lumbar intervertebral disc extrusions treated non-operatively. *Spine* 1990;15:683-686.
8. Saal J, Saal J. Lumbar disc extrusions with radiculopathy: natural history of resolution with non-operative management. *Spine* 2003;3:83S.
9. Unlu Z, Tascl S, Tarhan S, Pabuscu Y, Islak S. Comparison of three Physical Therapy modalities for acute pain in lumbar disc herniation measured by clinical evaluation and magnetic resonance imaging. *JMPT* 2008;31(3):191-198.
10. Autio R, et al. Determinants of spontaneous reabsorption of intervertebral disc herniations. *Spine* 2006;31(11):1247-1252.
11. Buttermann G. Lumbar disc herniation regression after successful epidural steroid injection. *J of Spinal Disord &Tech* 2002;15(6):469-476.
12. Khorsan R, Coulter I, Hawk C, Goertz Choate C. Measures in Chiropractic Research: Choosing patient-based outcome assessments. *JMPT* 2008;31(5):355-375.
13. Ferrari, R. Responsiveness of the Short-Form 36 and Oswestry Disability Questionnaire in chronic nonspecific low-back and lower-limb pain treated with customized foot orthotics. *JMPT* 2007;30(6):456-458.
14. Cooley J, Danielson C, Schultz G, Hall T. Posterior disk displacement: morphologic assessment and measurement reliability – lumbar spine. *JMPT* 2001;24(5):317-326.
15. Carragee E, Han M, Suen P, Kim D. Clinical outcomes after lumbar discectomy for sciatica: the effects of fragment type anular competence. *J Bone & Joint Surgery* 2003;85:102-108.
16. Daffner S, Hymanson H, Wang J. Cost and utilization of conservative management of lumbar disc herniation in patients undergoing surgical discectomy. *Spine* 2008;8:94S.
17. Borenstein D, et al. The value of magnetic resonance imaging of the lumbar spine to predict low-back pain in asymptomatic subjects. *J Bone & Joint Surgery* 2001;83:1306-1311.

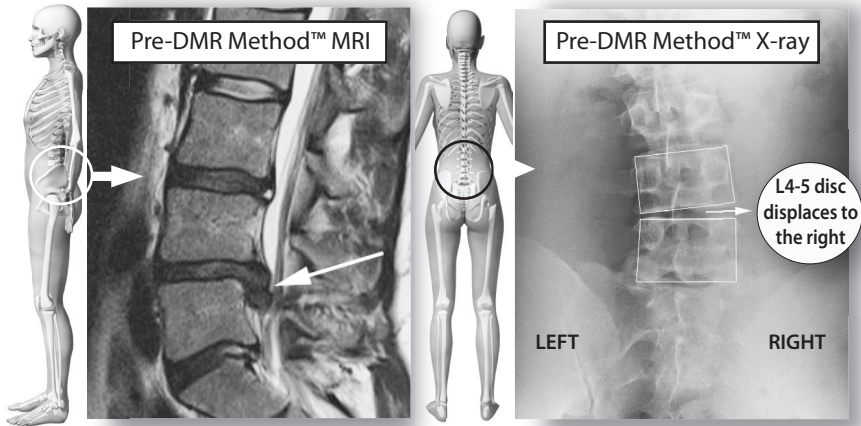
18. Murphy D, Hurwitz E, McGovern E. A nonsurgical approach to the management of patients with lumbar radiculopathy secondary to disc herniation: a prospective observational cohort study with long-term follow-up. *Spine* 2008;8:161S.
19. Iwabuchi S, et al. Low intensity pulsed ultrasound enhances herniated disc reabsorption in a rat culture. *Spine* 2005;5:114S.
20. Tsuru M, et al. Spontaneous remission of intervertebral disk hernia and responses of surrounding macrophages. *Spine* 2003;3:82-83S.
21. Saal JS, Saal JA. Lumbar Stabilizing exercises for the nonoperative treatment of disc lesions. California Medical Association. 432.
22. Santilli V, Beghi E, Finucci S. Chiropractic manipulation in the treatment of acute back pain and sciatica with disc protrusion: a randomized double-blinded clinical trial of active and simulated spinal manipulations. *Spine* 2006;6:131-137.
23. Borota L, Jonasson P, Agolli A. Spontaneous reabsorption of intradural lumbar disc fragments. *Spine* 2008;8:397-403.
24. Postacchini F. Lumbar disc herniation: a new equilibrium is needed between nonoperative and operative treatment. *Spine* 2001;26(6):601.

THE DMIR METHOD

CLINICAL CASE STUDIES



DMR Method™ Case Study



Lumbar Disc Herniation

Andrew was diagnosed with a herniated disc between L4 and L5. It caused local back pain that radiated down his right leg into his calf, which made it difficult for him to stand for long periods of time while he saw patients. He had been trying medical management and rehab therapy for nine months without success.

DIAGNOSIS

An MRI confirmed an L4-5 disc herniation causing irritation to the nerves going into Andrew's right leg (see left photo above). DMR Method Evaluation, including X-rays, revealed immobility and misalignment of the joints in the lower lumbar spine and pelvis that forced the L4-5 disc to herniate to the right side (see right photo above). Note: Surgery would remove the herniation, but do nothing to fix the imbalance in the spine that led to the disc herniation.

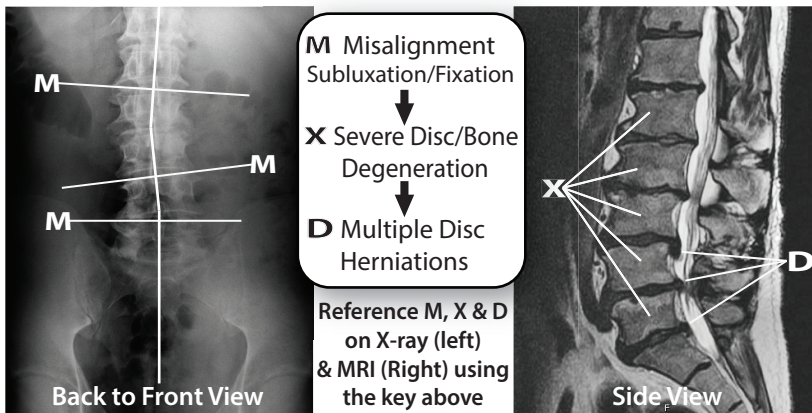
TREATMENT

Andrew completed the Chronic Lumbar DMR Protocol with a focus on restoring mobility, alignment and stability to the lower lumbar spine and pelvis.

OUTCOME

Andrew's symptoms quickly resolved and he was able to resume normal physical activities at home and at work. 5 year follow-up revealed no recurrence of disc herniation. He continues with a self-care stretching program and periodic DMR Method maintenance care.

DMR Method™ Case Study



Multiple Severe Disc Herniations & Degeneration Lumbar Spine

Over the course of seven years, Bruce developed lower back pain that increasingly radiated down his left leg into his foot and eventually became disabling. Medical pain management was unsuccessful and he was referred for an MRI. His doctor subsequently recommended back surgery. Before proceeding with surgery, Bruce decided to have a DMR Method consult based on the recommendation of a friend.

DIAGNOSIS

An MRI done on 12/10/09 revealed a large extruded left-sided disc herniation at L3-L4 causing severe compression of the L4 nerve root. Also noted were disc herniations with nerve compression at L4-5 and L5-S1. DMR Method Evaluation revealed severe fixation and misalignment/subluxation of the lumbar spine with muscle spasm and ligamentous restriction (see X-ray (left) and MRI (right) above).

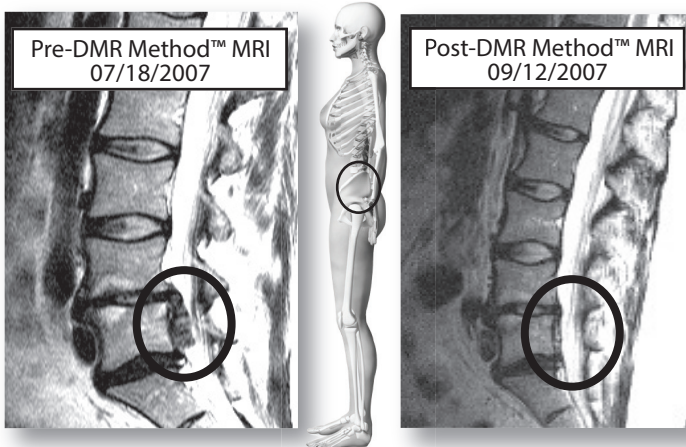
TREATMENT

DMR Method Chronic Protocol for multiple disc herniations, with focus on phase 1 to phase 3 Integrated Dynamic Mobilization (IDM) due to severity of fixation/misalignment/subluxation of the spine.

OUTCOME

Complete resolution of back and leg symptoms. Return to normal physical activities including riding his motorcycle and snowmobiling. His five-year follow-up confirmed continued symptom resolution, and he continues with preventative care.

DMR Method™ Case Study



Severe Disc Herniation Lumbar Spine

Amy was loading her washing machine when she bent over to pick up a laundry basket. She felt something “go out” in her lower back and experienced an intense pain that began radiating down her left leg. Her leg pain soon progressed to numbness and weakness and she began to have difficulty walking. Based on MRI findings, medical radiologists recommended emergency surgery.

DIAGNOSIS

The MRI confirmed a severe extruded disc herniation at L4-5, causing nerve compression. DMR Method Evaluation revealed severe misalignment and immobility in the lower lumbar spine and pelvis, with severe muscle spasm and inflammation.

TREATMENT

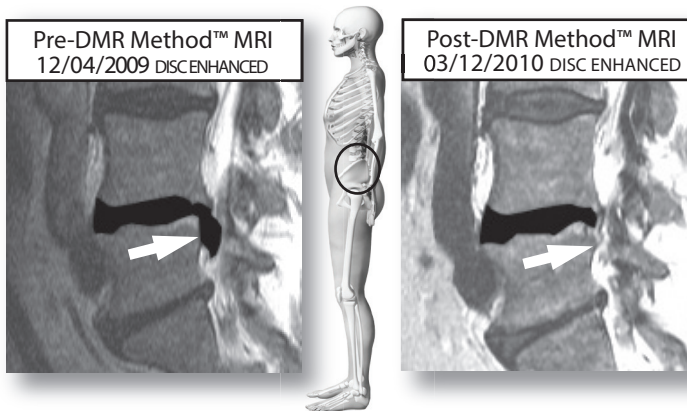
Due to the severity of Amy’s condition, her case was closely monitored. Her treatment following the completion of the Acute Lumbar DMR Protocol was focused on oscillating decompression traction, cold laser therapy and Integrated Progressive Mobilization (IPM).

OUTCOME

Amy experienced a resolution of all symptoms without needing surgery. Her extruded disc was entirely reabsorbed and she has been able to resume normal daily activities without pain. After seven years, Amy reports continued symptoms resolution and normal physical abilities.

NOTE: Amy was the very first DMR Method patient!

DMR Method™ Case Study



L4 Disc Herniation Lumbar Spine

Joe developed a disc herniation in the lower lumbar spine and was referred by his doctor for orthopedic spine surgery. After a difficult recovery, his painful leg symptoms were gone but his back still didn't feel normal. While bending and lifting, he re-herniated the same disc; in addition to lower back pain, he developed disabling left leg pain. Instead of a second surgery, he decided to try the DMR Method.

DIAGNOSIS

MRI confirmed a large L4-5 extruded disc herniation causing left L5 nerve root compression. DMR Method Evaluation revealed misalignment/subluxation of lumbar spine and pelvis. Also noted were severe immobility, muscle spasm and ligament contracture.

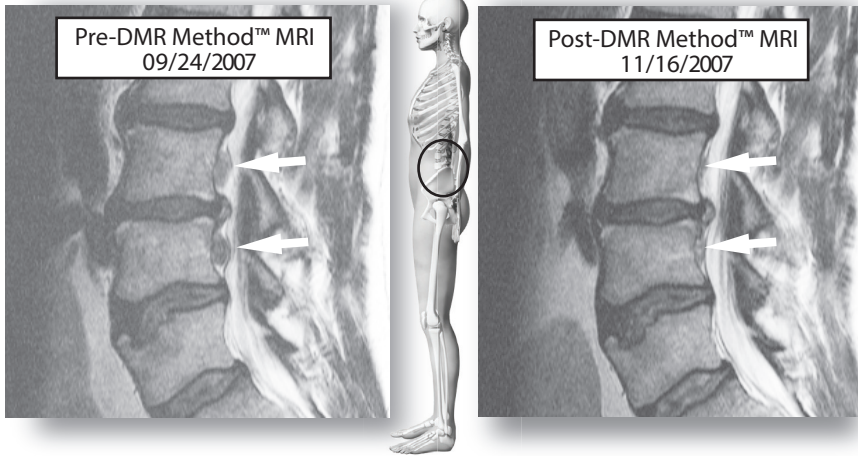
TREATMENT

Joe completed the Acute Lumbar DMR Method Protocol, including restrictions, self-care instructions, a supportive nutrition program, Integrated Progressive Mobilization (IPM) and Dynamic Muscle Technique (DMT) to restore mobility, alignment and stability. He progressed to a self-care exercise and stretching program.

OUTCOME

Resolution of all symptoms, restored functional abilities and restored mobility, alignment and stability. A follow-up MRI revealed complete reabsorption of L4-5 disc herniation (see enhanced pre- and post-MRI images above). After four years, Joe reports continued symptom resolution and normal physical abilities.

DMR Method™ Case Study



Multiple Disc Herniations Lumbar Spine

John developed severe debilitating lower back pain after lifting improperly. His pain continued for weeks and worsened after doing housework, radiating down his left leg. He couldn't stand without leaning forward and his leg felt weak and unstable.

DIAGNOSIS

An MRI scan revealed two large herniations between L4-5 and L3-4 in the lumbar spine causing left-sided nerve root impingement. DMR Method Evaluation revealed severe spinal immobility in the lumbar spine and pelvis, muscle and ligament remodeling and lower back and pelvic misalignment, causing excessive pressure on the lower lumbar discs.

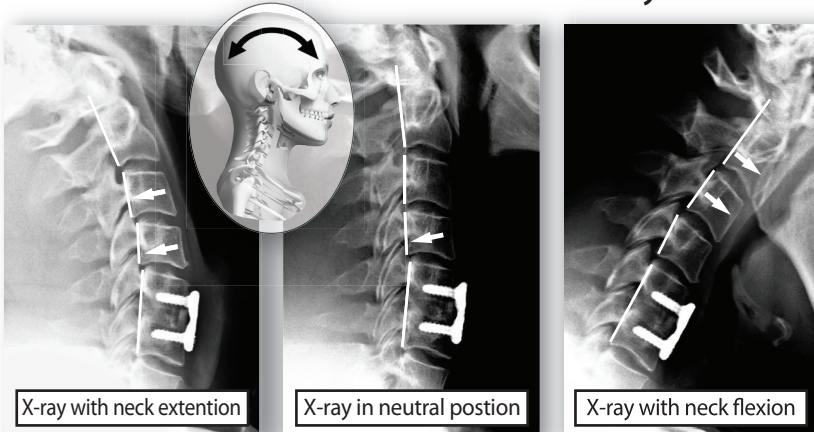
TREATMENT

Acute Lumbar DMR Protocol for multiple herninations that included a lumbar support belt and strict limitations on physical activities to prevent aggravation or re-injury.

OUTCOME

Complete resolution of back and leg symptoms and a return to normal physical activity. A follow-up MRI eight weeks after the initial MRI revealed reabsorption of L4-5 and L3-4 disc herniations. His seven-year follow-up confirmed continued symptom resolution and normal to enhanced physical abilities.

DMR Method™ Case Study



Neck and Arm Pain Before and After Neck Fusion Surgery

Kevin had neck fusion surgery in November 2012. Following the surgery, he continued to have severe neck pain and stiffness. He also developed severe headaches and experienced pain in his arms that steadily escalated. After eight months with no improvement he was told he needed another surgery to fuse more of his neck. He opted to try the DMR Method™ instead.

DIAGNOSIS

X-ray evaluation revealed stable appliance fusion of C5-C6, but unstable motion of the vertebrae above the fusion (see x-rays above). DMR Method Evaluation revealed severe fixation/subluxation of the upper neck and upper thoracic spine with reactive muscle spasm and greater occipital nerve irritation (causing headaches), and brachial plexus nerve irritation (causing arm symptoms).

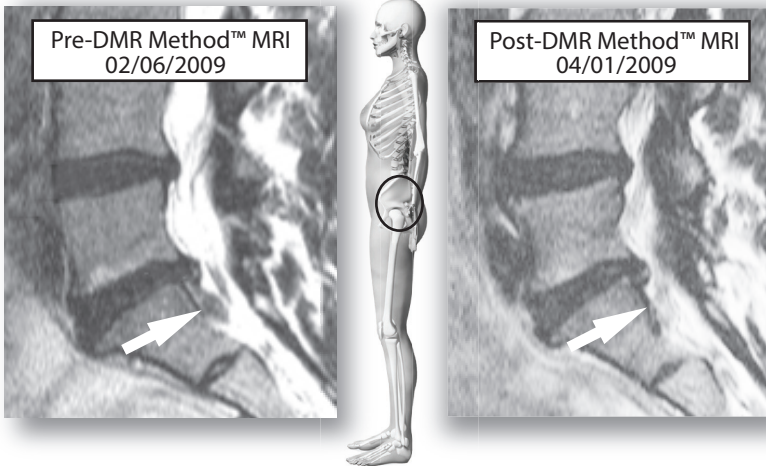
TREATMENT

Post-operative Cervical DMR Protocol with a contraindication to any mobilization of the surgically fused C5-C6 segment.

OUTCOME

Kevin avoided a second neck surgery. All of his symptoms—neck pain and stiffness, headaches and arm symptoms—were resolved. Due to the surgical fusion in his neck, he was educated about and advised to consistently follow home care and proactive DMR maintenance care.

DMR Method™ Case Study



Moderate Disc Herniation Lumbar Spine

Laura, who has a history of rheumatoid arthritis, was in an exercise class when she felt her back give out. The pain worsened over the next few hours and began causing numbness and weakness in her left leg. She couldn't bear weight on her left leg and couldn't sit, stand or walk without severe lower back and leg pain.

DIAGNOSIS

An MRI scan revealed a moderate left-sided L5-S1 disc herniation with nerve root compression. DMR Method Evaluation revealed severe immobility and misalignment of the lower lumbar spine and pelvis, plus muscle spasm, swelling, and remodeling/constriction of the muscles and ligaments in the lower lumbar spine and pelvis.

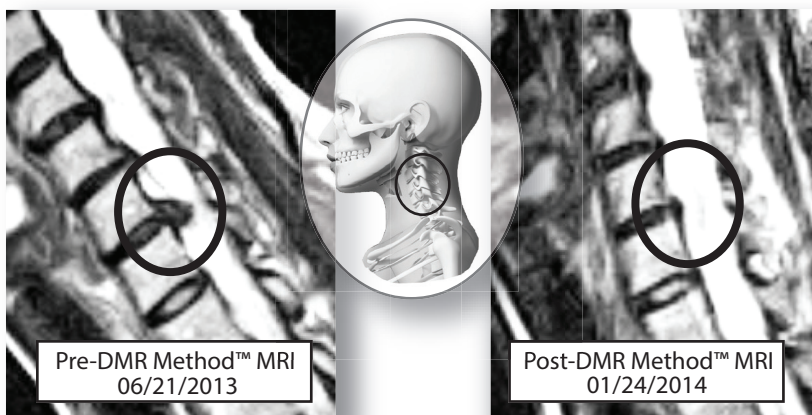
TREATMENT

Acute Lumbar DMR Protocol. Laura was also referred for a lumbar epidural injection to decrease acute pain and inflammation.

OUTCOME

Laura attained complete resolution of back and leg symptoms and returned to aggressive fitness activities. A follow-up MRI eight weeks after her initial MRI revealed complete reabsorption of the disc herniation. Her five-year follow-up revealed continued symptom resolution. Her arthritis-related back pain has been managed with stretching and periodic care. She maintains a very active lifestyle and manages her rheumatoid arthritis well.

DMR Method™ Case Study



Disc Herniation Cervical Spine

Sarah developed severe upper back pain after sleeping the wrong way on a hotel pillow. The pain progressed into her neck; over the next few days she began experiencing severe/constant tingling in her right hand. She had a difficult time sleeping because the pain and numbness worsened when she laid down.

DIAGNOSIS

An MRI scan on 6/21/13 revealed a severe C6-C7 disc herniation causing compression of the right C7 nerve. DMR Method Evaluation revealed severe fixation/subluxation and degeneration in the lower cervical and upper thoracic spine. Sarah also experienced extensive muscle spasm as well as ligament and joint capsule restriction.

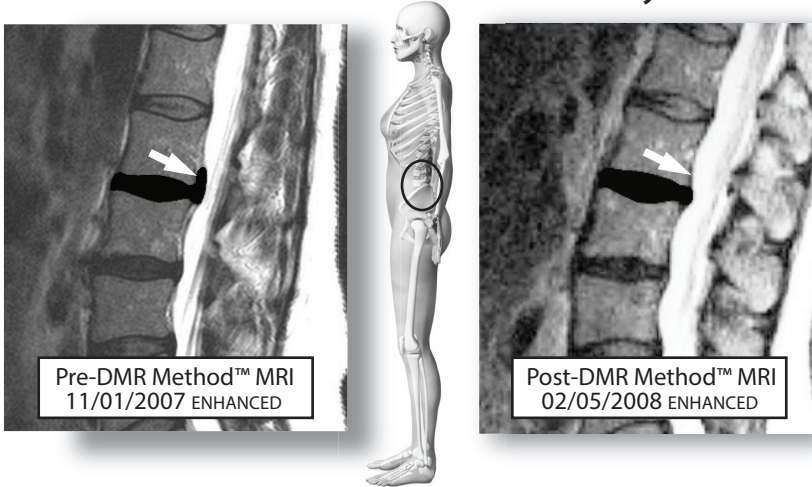
TREATMENT

Acute Cervical DMR Method protocol with medical pain management, including epidural steroid injection to decrease pain and inflammation so Sarah could proceed with the DMR Method Protocol. One of the keys to her progression was the combination of Oscilating Decompression Traction (ODT) and Dynamic Muscle Technique (DMT).

OUTCOME

Sarah's neck, upper back and arm symptoms were completely resolved. A follow-up MRI on 1/24/14 revealed a marked reabsorption of the C6-C7 disc herniation (see enhanced pre- and post-MRI images above). She has resumed normal physical activity, including aggressive fitness training.

DMR Method™ Case Study



Lumbar Disc Herniation with Back Pain

Sandra developed acute severe lower back pain after bending forward to lift a very light object. After failing to improve with standard physical therapy and chiropractic treatment, she had an MRI scan done and came in for a DMR Method Evaluation.

DIAGNOSIS

The MRI scan confirmed a large 14mm x 4mm L2-3 disc herniation that extruded outward and upward (see image above). DMR Method Evaluation revealed joint immobility and misalignment/subluxation in the lumbar spine. Muscle imbalance and spasm was indicative of a structural condition that had been developing over a long period of time.

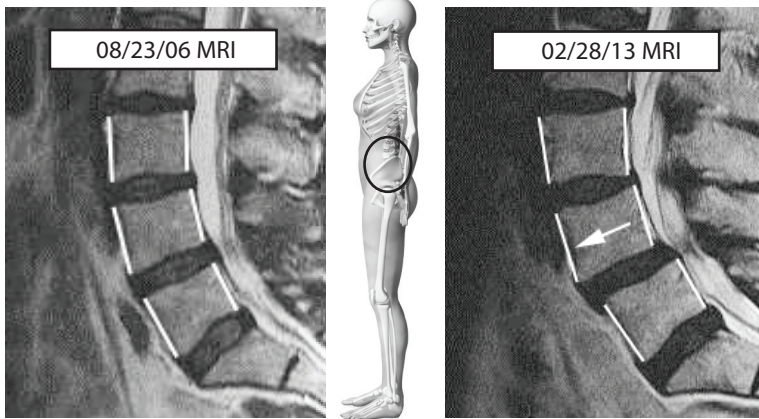
TREATMENT

Because of the new disc herniation, Sandra first completed the acute lumbar DMR Method Protocol with a focus on Integrated Progressive Mobilization (IPM). As her condition improved, her chiropractors and physical therapists transitioned her to a care program that focused on the correction of the long-term joint and muscle imbalance that was the true underlying cause of the new disc herniation.

OUTCOME

Sandra's back and leg pain resolved. A follow-up MRI showed a marked regression of the L2-3 disc herniation with 3mm x 3mm residual. Her six-year follow-up confirmed continued symptom resolution.

DMR Method™ Case Study



Post-Operative Degeneration and Slippage of Spine (Spondylolisthesis)

Sally had surgery on her lower back in 2006 (L4-5 laminectomy). She had recurrent incidental back pain post-surgery, but in 2012 her back pain and right leg pain became constant and severe; she couldn't walk without pain. Her doctor recommended injections and surgery. She was referred by a friend for a DMR Method consult.

DIAGNOSIS

A lumbar MRI done on 2/28/13 revealed post-operative forward slippage of the L4 vertebra with advanced joint degeneration and compression of the nerves in the lumbar spine. DMR Method Evaluation revealed severe restricted motion and compression of the lumbar spine with severe distortion and misalignment causing muscle, ligament, and joint capsule distortion.

TREATMENT

Chronic Lumbar DMR Protocol with a focus on joint mobilization, Decompression, and Progressive Muscle Technique.

OUTCOME

Due to the severity of her condition and her post-operative challenges, Sally's DMR Method progression was more gradual. In time, however, her symptoms resolved and she can now walk and be active without pain, which prevented the need for a second, more invasive back surgery. She prevents recurrence and maintains her pain-free lifestyle with stabilization exercises and periodic preventative care.