



# U.S. Department of Health & Human Services

---

Food and Drug Administration

## SAVE REQUEST

**USER:** (smw)  
**FOLDER:** K121213 - 908 pages  
**COMPANY:** VITAL IMAGES, INC. (VITAIMAG)  
**PRODUCT:** SYSTEM, IMAGE PROCESSING, RADIOLOGICAL (LLZ)  
**SUMMARY:** Product: VITREAADVANCED

**DATE REQUESTED:** Oct 19, 2015

**DATE PRINTED:** Oct 19, 2015

**Note:** Printed



K121213

## 510(k) Summary

This 510(k) summary is submitted in accordance with the requirements by section 807.92.(c)

**Submitter:** Vital Images, Inc.  
5850 Opus Parkway  
Suite 300  
Minnetonka, MN 55343-4414

**Establishment  
Registration:** 2134213

NOV 2 2012

**Contact Person:** Ian Nemerov  
Vice President, General Counsel & Secretary  
Phone: 952-487-9622  
Fax: 952-487-9510  
E-mail: [inemerov@vitalimages.com](mailto:inemerov@vitalimages.com)

**510(k) Type:** Traditional 510(k)

**Summary Date:** October 5, 2012

### Device Name

**Trade Name:** VitreaAdvanced  
**Common Name:** Picture Archiving and Communications System  
**Classification Name:** System, Image Processing, Radiological (21 C.F.R. 892.2050,LLZ)

### Predicate Devices:

Subject Functions	Predicate Devices		
	Manufacturer	Trade Name	510(k) Number
Advanced Image Post-processing	Vital Images, Inc.,	Vitrea <sup>®</sup> , Version 4.0	K071331
Vitrea <sup>®</sup> CT Body Perfusion	Toshiba America Medical System, Inc.,	CSBP-001A Body Perfusion System	K090504
Vitrea <sup>®</sup> CT Liver Analysis	MeVis - Center for Medical Diagnostic Systems and Visualization GmbH	MeVis LiverAnalyser / LiverViewer Software	K051528
	MEDIAN Technologies	LMS-Liver	K071241
Vitrea <sup>®</sup> CT Brain Perfusion	Vital Images, Inc	Vitrea <sup>®</sup> 4DCT	K072821
	Siemens Medical Solutions, Inc.	syngo <sup>®</sup> Volume Perfusion-CT Neuro	K073238

### **Device Description:**

VitreAdvanced is a package of noninvasive post-processing software applications for the Vitrea® software platform. The system is a software only medical device to be installed on common IT hardware. VitreaAdvanced leverages existing Vitrea® functionality for the processing, review, analysis, communication, and media interchange of multi-dimensional digital images acquired from a variety of imaging devices. It provides multi-dimensional visualization of digital images to aid medical professionals in their analysis of anatomy and pathology. VitreaAdvanced can be used with a variety of cleared Vitrea® based software applications. VitreaAdvanced uses the Vitrea® system user interface to follow typical clinical workflow patterns and process, review, and analyze digital images, including:

- Receive DICOM image data from a variety of sources
- Display images using dedicated protocols adapted to exam types
- Select images for closer examination from collection of 2D, 3D or 4D views
- Interactively manipulate an image in real-time to visualize anatomy and pathology
- Annotate, tag, measure, and record selected views
- Output selected views to compatible devices and publishing tools (e.g. printers, DICOM devices, etc.)

In addition, VitreaAdvanced includes three Vitrea® applications:

**Vitre® CT Body Perfusion** is noninvasive post-processing software that has been designed to assess dynamic (time lapsed collections) CT volume scans and provide data related to the volume sets. It displays blood flow parametric maps for single-input and dual-input workflows.

**Vitre® CT Liver Analysis** is noninvasive post-processing software that displays CT image data. It processes image data to segment liver structures and evaluate resection surfaces as well as volumes. Vitre® CT Liver Analysis provides automatic registration and composite views of multiple series, optimized screen layouts and measurement tools. It also generates standardized reports for WHO and RECIST protocols and for percentage change tumor response values.

**Vitre® CT Brain Perfusion** is noninvasive post-processing software that calculates cerebral blood flow (CBF), cerebral blood volume (CBV), local bolus timing (i.e., delay of tissue response, time to peak), and mean transit time (MTT) from dynamic CT image data. It displays time density curves, perfusion characteristics in parametric and summary maps, as well as regions of interest and mirrored regions.

### **Intended Use / Indications for Use:**

VitreAdvanced is a medical diagnostic system for the processing, review, analysis, communication and media interchange of multi-dimensional digital images acquired from a variety of imaging devices. VitreaAdvanced is not meant for primary image interpretation in mammography. It can be used with a variety of cleared Vitrea® based software applications. In addition, VitreaAdvanced includes three Vitrea® applications:

**Vitre® CT Body Perfusion** is a noninvasive post-processing application designed to evaluate perfusion of organs and tumors. The software can calculate perfusion characteristics from dynamic CT image data acquired after the injection of contrast media. The software also allows the separate calculation of the arterial and venous components of perfusion in organs. It supports evaluation of regions of interest and the visual inspection of time density curves. When used by a trained and qualified physician a potential application is to differentiate blood flow between normal and diseased tissue. Determination of the change of perfusion parameters during the course of treatment may be helpful in therapy monitoring.

**Vitreá® CT Liver Analysis** is a noninvasive post-processing application designed to evaluate liver tumors and plan for liver surgery. It displays images for analysis and preoperative liver surgery planning, such as organ segmentation, tumor segmentation and intrahepatic vessels segmentation, as well as the approximation of vascular territories. It supports preoperative evaluation of specific surgery strategies by allowing the user to interactively define virtual resections splitting the liver. It also allows the user to evaluate safety-margins around lesions and to identify affected vascular branches and territories. Vitrea® CT Liver Analysis also provides automatic registration of multiple series and measurement tools for characterization and follow-up of the lesions. When used by a trained and qualified physician a potential application is to assist in the assessment of tumor response to therapy.

**Vitreá® CT Brain Perfusion** is a noninvasive post-processing application designed to evaluate areas of brain perfusion. The software can calculate cerebral blood flow (CBF), cerebral blood volume (CBV), local bolus timing (i.e., delay of tissue response, time to peak), and mean transit time (MTT) from dynamic CT image data acquired after the injection of contrast media. The package also allows the calculation of regions of interest and mirrored regions, as well as the visual inspection of time density curves. Vitrea® CT Brain Perfusion supports the physician in visualizing the apparent blood perfusion in brain tissue affected by acute stroke. Areas of decreased perfusion, as is observed in acute cerebral infarcts, appear as areas of changed signal intensity (lower for both CBF and CBV and higher for time to peak and MTT).

**Comparison with Predicate Devices:**

VitreáAdvanced is a package of noninvasive post-processing software applications for the Vitrea® software platform. It leverages the basic functionality and technology of the existing 510(k) cleared Vitrea® software platform. VitreaAdvanced includes advance applications that extend the functionality of the platform for specific uses. The specific uses are substantially equivalent to the cleared uses of existing post-processing software applications available on other platforms. Also, the software applications use similar technology as existing post-processing software applications.

**Vitreá® CT Body Perfusion:**

Vitreá® CT Body Perfusion (Submission Subject)	Description	Toshiba CSBP-001A Body Perfusion System (K090504)	Explanation of Differences
Analysis Model	Maximum slope (Fick principal)	Includes	<p>The subject and predicate both implement Maximum-slope.</p> <p>The predicate implements additional models: Compartment model and Patlak Plot.</p>

Vitrea® CT Body Perfusion (Submission Subject)	Description	Toshiba CSBP-001A Body Perfusion System (K090504)	Explanation of Differences
Parameters	Blood flow	Includes	<p>The subject and predicate both display blood flow parameters.</p> <p>The predicate includes additional parameters: Blood volume, MTT, HAF (PI), equivalent blood volume using the additional analysis models.</p>
Functions	Single input, dual input, map display and ROI measurement	Same	None

**Vitrea® CT Liver Analysis:**

Vitrea® CT Liver Analysis (Submission Subject)	Description	MeVis Liver Analyser / LiverViewer Software (K051528)	Median LMS-Liver (K071241)	Explanation of Differences
Analysis Model	Rigid and deformable registration, Segmentation and region growing	Same	Same	None
Parameters	Basic measurements, volume, resection plane, RECIST, WHO and comparisons	Partial (volumes, resection planes and comparisons)	Partial (RECIST, WHO and comparisons)	MeVis provides basic measurements for volumes, resection planes and comparisons. LMS-Liver provides RECIST and WHO measurements and comparison.

Vitre <sup>®</sup> CT Liver Analysis (Submission Subject)	Description	MeVis Liver Analyser / LiverViewer Software (K051528)	Median LMS-Liver (K071241)	Explanation of Differences
Functions	Segment: organs, tumors and intrahepatic vessels, Resection planning tool (defines vascular territories), multi-phase fusion and standardized reports	Partial  (segmentation, resection planning and multi-phase fusion)	Partial  (standardized reports)	MeVis provides segmentation, resection planning and multi-phase fusion.  LMS-Liver provides standardized reports.

**Vitre<sup>®</sup> CT Liver Analysis:**

Vitre <sup>®</sup> CT Brain Perfusion (Submission Subject)	Description	Vitre <sup>®</sup> 4DCT (K072821)	Siemens syngo <sup>®</sup> Volume Perfusion-CT Neuro (K073238)	Explanation of Differences
Analysis Model	Deconvolution	Same	Includes	syngo <sup>®</sup> Volume Perfusion-CT Neuro uses both deconvolution and maximum slope.
Parameters	Cerebral blood flow (CBF), cerebral blood volume (CBV), local bolus timing (i.e., delay of tissue response, time to peak), and mean transit time (MTT)	Same	Includes	syngo <sup>®</sup> Volume Perfusion-CT Neuro has all the parameters and vascular permeability

Vitrea® CT Brain Perfusion (Submission Subject)	Description	Vitrea® 4DCT (K072821)	Siemens syngo® Volume Perfusion – CT Neuro (K073238)	Explanation of Differences.
Functions	Display regions of interest, mirrored regions, time density curves and perfusion characteristics in parametric and summary maps	Partial	Same	4DCT does not include summary maps (maps that combine parameters). syngo® Volume Perfusion- CT Neuro includes maps that combine parameters.

**Summary of Non-Clinical Tests:**

VitreaAdvanced was designed, developed, and tested according to written procedures that included applying risk management. Testing included verification, validation, and evaluation of previously acquired medical images.

The following quality assurance measures were applied to the development of VitreaAdvanced:

- Risk analysis
- Requirements reviews
- Design reviews
- Performance testing (Verification)
- Safety testing (Verification)
- Simulated use testing (Validation)

**Software Testing:**

The primary focus of the Verification and Validation team during development was producing, reviewing and executing manual and automated test cases to ensure the product conformed to new and previously defined specifications and also to ensure that risks were properly mitigated during testing. The Requirement Traceability Matrix (RTM) provides a mapping between requirements, risks, test cases, and shows related test results. The RTM confirms that there was a test case authored and executed for all requirements and any applicable risks. In addition, the Verification and Validation Team demonstrated clinical features to several Radiologists and 3D Technologists to gather feedback and formal acceptance.

**Manual Tests:**

Manual tests cases were executed to verify and validate the CT Body Perfusion, CT Liver Analysis and CT Brain Perfusion applications, and to determine the impact of any changes. All manual tests and steps were executed to prove the product conformed to specifications and to mitigate risks.

**Verification:**

The software verification team had a primary goal of assuring that software fully satisfies all expected system requirements and features. Test cases were executed against the system features and requirements. As part of creating the test cases, the verification team reviewed and monitored the Requirements Traceability Matrix ("RTM") to ensure coverage of the items within the RTM.

**Automated Integration Level Build Verification Tests (BVT):**

Automated integration level Build Verification Tests (BVT) were developed to exercise mainstream functionality and provide an assessment of the stability and testability of the VitreaAdvanced software.

(b)(4)

**Validation:**

The software validation team had a primary goal of assuring that software conforms to user needs and intended uses. The result of the validation team's efforts was evidence, produced by workflow testing, that system requirements and features were implemented, reviewed and met.

**Internal Validation:**

The software validation team provided internal validation of VitreaAdvanced. Internal validation included internal beta testing and internal user acceptance testing.

**External Validation:**

**Vitrea® CT Body Perfusion**

(b)(4)

(b)(4)

(b)(4)

Based on the results of the qualitative analysis, and feedback gathered during external validation, the CT Body Perfusion application has passed validation.

**Vitrea® CT Liver Analysis**

(b)(4)

Based on their evaluation, the software passed external validation.

**Vitrea® CT Brain Perfusion**

(b)(4)

(b)(4)

He confirmed that the software has met the intended use and effectively provides a summary image of the data displayed in the perfusion maps as well as when used in conjunction with the perfusion maps, the summary map enables the user to characterize the brain tissue and communicate their findings.



**Summary of Clinical Tests:**

The subject of this traditional 510(k) notification, VitreaAdvanced, did not require clinical studies to support safety and effectiveness of the software.

**Cyber and Information Security:**

- **Confidentiality**  
Vitrea platform relies on built in Windows Login security to limit access to the system. The Vitrea platform can only be installed and configured by an administrator of the Windows machine.
- **Integrity**  
Vitrea platform complies with the DICOM standard for transfer and storage of this data and does not modify the contents of DICOM instances. Vitrea platform identifies the data it produces, marking and encoding the appropriate DICOM fields.
- **Availability**  
Vitrea platform is always available to the logged on user as long as the Windows machine itself is properly maintained.
- **Accountability**  
Vitrea platform includes an audit capability that enables accountability by tracking authenticated and authorized user operations along with information accessed. Vitrea audit logs are time stamped, enabling correlation with Windows system logging to track information accessed by a user.

**Measurement Accuracy:**

Measurements and orientations in VitreaAdvanced were verified using various imaging phantoms

(b)(4)



**Performance Standard:**

No applicable mandatory performance standards or special controls exist for this device. However, the software is designed to meet NEMA PS 3.1 – 3.18 Digital Imaging and Communications in Medicine (DICOM) standard.

**Conclusion:**

The testing reported in this 510(k) establishes that VitreaAdvanced is substantial equivalent to the predicate devices and is safe and effective for its intended use.



DEPARTMENT OF HEALTH & HUMAN SERVICES

Public Health Service

Food and Drug Administration  
10903 New Hampshire Avenue  
Document Control Room – WO66-G609  
Silver Spring, MD 20993-0002

Mr. Daniel Biank  
Regulatory Affairs Manager  
Vital Images, Inc.  
5850 Opus Parkway, Suite 300  
Minnetonka, MN 55343

NOV 2 2012

Re: K121213  
Trade/Device Name: VitreaAdvanced  
Regulation Number: 21 CFR 892.2050  
Regulation Name: Picture archiving and communications system  
Regulatory Class: II  
Product Code: LLZ  
Dated: October 5, 2012  
Received: October 9, 2012

Dear Mr. Biank:

We have reviewed your Section 510(k) premarket notification of intent to market the device referenced above and have determined the device is substantially equivalent (for the indications for use stated in the enclosure) to legally marketed predicate devices marketed in interstate commerce prior to May 28, 1976, the enactment date of the Medical Device Amendments, or to devices that have been reclassified in accordance with the provisions of the Federal Food, Drug, and Cosmetic Act (Act) that do not require approval of a premarket approval application (PMA). You may, therefore, market the device, subject to the general controls provisions of the Act. The general controls provisions of the Act include requirements for annual registration, listing of devices, good manufacturing practice, labeling, and prohibitions against misbranding and adulteration.

If your device is classified (see above) into class II (Special Controls), it may be subject to such additional controls. Existing major regulations affecting your device can be found in Title 21, Code of Federal Regulations (CFR), Parts 800 to 895. In addition, FDA may publish further announcements concerning your device in the Federal Register.


Please be advised that FDA's issuance of a substantial equivalence determination does not mean that FDA has made a determination that your device complies with other requirements of the Act or any Federal statutes and regulations administered by other Federal agencies. You must comply with all the Act's requirements, including, but not limited to: registration and listing (21 CFR Part 807); labeling (21 CFR Parts 801 and 809); medical device reporting (reporting of

medical device-related adverse events) (21 CFR 803); and good manufacturing practice requirements as set forth in the quality systems (QS) regulation (21 CFR Part 820). This letter will allow you to begin marketing your device as described in your Section 510(k) premarket notification. The FDA finding of substantial equivalence of your device to a legally marketed predicate device results in a classification for your device and thus, permits your device to proceed to the market.

If you desire specific advice for your device on our labeling regulation (21 CFR Parts 801 and 809), please contact the Office of *In Vitro* Diagnostic Device Evaluation and Safety at (301) 796-5450. Also, please note the regulation entitled, "Misbranding by reference to premarket notification" (21 CFR Part 807.97). For questions regarding the reporting of adverse events under the MDR regulation (21 CFR Part 803), please go to <http://www.fda.gov/MedicalDevices/Safety/ReportaProblem/default.htm> for the CDRH's Office of Surveillance and Biometrics/Division of Postmarket Surveillance.

You may obtain other general information on your responsibilities under the Act from the Division of Small Manufacturers, International and Consumer Assistance at its toll-free number (800) 638-2041 or (301) 796-7100 or at its Internet address <http://www.fda.gov/cdrh/industry/support/index.html>.

Sincerely Yours,



Janine M. Morris  
Director

Division of Radiological Health  
Office of In Vitro Diagnostics  
and Radiological Health  
Center for Devices and Radiological Health

Enclosure

## Indications for Use

510(k) Number (if known): K121213

Device Name: VitreaAdvanced

### Indications for Use:

VitreaAdvanced is a medical diagnostic system for the processing, review, analysis, communication and media interchange of multi-dimensional digital images acquired from a variety of imaging devices. VitreaAdvanced is not meant for primary image interpretation in mammography. It can be used with a variety of cleared Vitrea® based software applications. In addition, VitreaAdvanced includes three Vitrea® applications:

**Vitrea® CT Body Perfusion** is a noninvasive post-processing application designed to evaluate perfusion of organs and tumors. The software can calculate perfusion characteristics from dynamic CT image data acquired after the injection of contrast media. The software also allows the separate calculation of the arterial and venous components of perfusion in organs. It supports evaluation of regions of interest and the visual inspection of time density curves. When used by a trained and qualified physician a potential application is to differentiate blood flow between normal and diseased tissue. Determination of the change of perfusion parameters during the course of treatment may be helpful in therapy monitoring.

**Vitrea® CT Liver Analysis** is a noninvasive post-processing application designed to evaluate liver tumors and plan for liver surgery. It displays images for analysis and preoperative liver surgery planning, such as organ segmentation, tumor segmentation and intrahepatic vessels segmentation, as well as the approximation of vascular territories. It supports preoperative evaluation of specific surgery strategies by allowing the user to interactively define virtual resections splitting the liver. It also allows the user to evaluate safety-margins around lesions and to identify affected vascular branches and territories. Vitrea® CT Liver Analysis also provides automatic registration of multiple series and measurement tools for characterization and follow-up of the lesions. When used by a trained and qualified physician a potential application is to assist in the assessment of tumor response to therapy.

**Vitrea® CT Brain Perfusion** is a noninvasive post-processing application designed to evaluate areas of brain perfusion. The software can calculate cerebral blood flow (CBF), cerebral blood volume (CBV), local bolus timing (i.e., delay of tissue response, time to peak), and mean transit time (MTT) from dynamic CT image data acquired after the injection of contrast media. The package also allows the calculation of regions of interest and mirrored regions, as well as the visual inspection of time density curves. Vitrea® CT Brain Perfusion supports the physician in visualizing the apparent blood perfusion in brain tissue affected by acute stroke. Areas of decreased perfusion, as is observed in acute cerebral infarcts, appear as areas of changed signal intensity (lower for both CBF and CBV and higher for time to peak and MTT).

Prescription Use  (Part 21 CFR 801 Subpart D)

AND/OR

Over-The-Counter Use \_\_\_\_\_ (21 CFR 807 Subpart C)

  
(Division Sign Off)

Division of Radiological Health

Office of In Vitro Diagnostics and Radiological Health

Questions? Contact FDA/CDRH/OCE/DID at CDRH-FOISTATUS@fda.hhs.gov or 301-796-8118

510(k) K121213



U.S. Food and Drug Administration  
Center for Devices and Radiological Health  
Document Control Center WO66-G609  
10903 New Hampshire Avenue  
Silver Spring, MD 20993-0002

July 17, 2012

VITAL IMAGES, INC.  
5850 OPUS PARKWAY,  
SUITE 300  
MINNETONKA, MINNESOTA 55343-4414  
ATTN: DANIEL BIANK

510k Number: K121213

Product: VITREAADVANCED

Extended Until: 12/19/2012

Based on your recent request, an extension of time has been granted for you to submit the additional information we requested.

If the additional information (AI) is not received by the "Extended Until" date shown above, your premarket notification will be considered withdrawn (21 CFR 807.87(l)). If the submitter does submit a written request for an extension, FDA will permit the 510(k) to remain on hold for up to a maximum of 180 days from the date of the AI request.

If you have procedural questions, please contact the Division of Small Manufacturers International and Consumer Assistance (DSMICA) at (301)796-7100 or at their toll-free number (800)638-2041, or contact the 510k staff at (301)796-5640.

Sincerely yours,

Marjorie Shulman  
Director, 510(k) Program  
Premarket Notification Section  
Office of Device Evaluation  
Center for Devices and Radiological Health

July 13, 2012

K12  
FDA CDRH DMC  
JUL 16 2012  
Received

Jay Vajshnav, Ph.D.  
Physicist and Premarket Reviewer  
c/o Food and Drug Administration  
Center for Devices and Radiological Health  
Division of Radiological Devices (DRAD)  
Document Mail Center - WO66-G609  
10903 New Hampshire Avenue  
Silver Spring, Maryland 20993-0002

Subject: K121213 VitreaAdvanced Telephone Hold Request 180 Days Additional Time

Dear Dr. Vaishnav:

The Vital Images 510(k) pre-market notification for VitreaAdvanced (K121213) was placed on telephone hold by your e-mail dated June 21, 2012. Thank you for your prompt and thorough review of the submission. We would like additional time to assemble the needed information and ensure complete responses to your inquiries.


Please provide us with one hundred and eighty (180) days to respond to the Telephone Hold.

Thank you for your attention to this matter. I look forward to continuing the interactive and collaborative review process. Please contact me with any question regarding this submission or for further information at (952) 487-9622 or via email at inemerov@vitalimages.com.

Sincerely,



Ian Nemerov  
Vice President, General Counsel and Secretary

 Vital Images, Inc. | 5850 Opus Parkway, Suite 300 | Minnetonka, MN 55343 | 866.433.4624  
www.vitalimages.com

**VITAL**  
A Toshiba Medical Systems Group Company



U.S. Food and Drug Administration  
Center for Devices and Radiological Health  
Document Control Center WO66-G609  
10903 New Hampshire Avenue  
Silver Spring, MD 20993-0002

June 25, 2012

VITAL IMAGES, INC.  
5850 OPUS PARKWAY,  
SUITE 300  
MINNETONKA, MINNESOTA 55343-4414  
ATTN: DANIEL BIANK

510k Number: K121213  
Product: VITREAADVANCED  
On Hold As of 6/22/2012

We are holding your above-referenced Premarket Notification (510(k)) for 30 days pending receipt of the additional information that was requested by the Office of Device Evaluation. Please remember that all correspondence concerning your submission MUST cite your 510(k) number and be sent in duplicate to the Document Mail Center at the above letterhead address. Correspondence sent to any address other than the one above will not be considered as part of your official premarket notification submission. Also, please note the new Blue Book Memorandum regarding Fax and E-mail Policy entitled, "Fax and E-Mail Communication with Industry about Premarket Files Under Review. Please refer to this guidance for information on current fax and e-mail practices at <http://www.fda.gov/MedicalDevices/DeviceRegulationandGuidance/GuidanceDocuments/ucm089402.htm>.

The deficiencies identified represent the issues that we believe need to be resolved before our review of your 510(k) submission can be successfully completed. In developing the deficiencies, we carefully considered the statutory criteria as defined in Section 513(i) of the Federal Food, Drug, and Cosmetic Act for determining substantial equivalence of your device. We also considered the burden that may be incurred in your attempt to respond to the deficiencies. We believe that we have considered the least burdensome approach to resolving these issues. If, however, you believe that information is being requested that is not relevant to the regulatory decision or that there is a less burdensome way to resolve the issues, you should follow the procedures outlined in the "A Suggested Approach to Resolving Least Burdensome Issues" document. It is available on our Center web page at: <http://www.fda.gov/MedicalDevices/DeviceRegulationandGuidance/Overview/MedicalDeviceProvisionsofFDAModer nizationAct/ucm136685.htm>.

If after 30 days the additional information (AI), or a request for an extension of time, is not received, we will discontinue review of your submission and proceed to delete your file from our review system (21 CFR 807.87(l)). Please note our guidance document entitled, "Guidance for Industry and FDA Staff, FDA and Industry Actions on Premarket Notification (510(k)) Submissions: Effect on FDA Review Clock and Performance Assessment". If the submitter does submit a written request for an extension, FDA will permit the 510(k) to remain on hold for up to a maximum of 180 days from the date of the AI request. The purpose of this document is to assist agency staff and the device industry in understanding how various FDA and industry actions that may be taken on 510(k)s should affect the review clock for purposes of meeting the Medical Device User Fee and Modernization Act. You may review this document at <http://www.fda.gov/MedicalDevices/DeviceRegulationandGuidance/GuidanceDocuments/ucm089735.htm>. Pursuant to 21 CFR 20.29, a copy of your 510(k) submission will remain in the Office of Device Evaluation. If you then wish to resubmit this 510(k) notification, a new number will be assigned and your submission will be considered a new premarket notification submission.

Records processed under FOIA Request #2014-09977. Released by CDRH on 12-18-2015.  
Please remember that the Safe Medical Devices Act of 1990 states that you may not place a device into commercial distribution until you receive a decision letter from FDA allowing you to do so.

If you have procedural questions, please contact the Division of Small Manufacturers International and Consumer Assistance (DSMICA) at (301)796-7100 or at their toll-free number (800)638-2041, or contact the 510k staff at (301)796-5640.

Sincerely yours,

Marjorie Shulman  
Consumer Safety Officer  
Premarket Notification Section  
Office of Device Evaluation  
Center for Devices and Radiological Health



\* \* \* COMMUNICATION RESULT REPORT ( JUN. 25. 2012 10:44AM ) \* \* \*

FAX HEADER 1:  
FAX HEADER 2:

TRANSMITTED/STORED : JUN. 25. 2012 10:42AM  
MODE OPTION

ADDRESS

RESULT

PAGE

6885 MEMORY TX

Vital Images

OK

2/2

REASON FOR ERROR OR LINE FAIL  
E-1) HANG UP  
E-3) NO ANSWER

E-2) BUSY  
E-4) NO FACSIMILE CONNECTION



DEPARTMENT OF HEALTH & HUMAN SERVICES

Public Health Service

U.S. Food and Drug Administration  
Center for Devices and Radiological Health  
Document Control Center WO66-G609  
10903 New Hampshire Avenue  
Silver Spring, MD 20993-0002

June 25, 2012

VITAL IMAGES, INC.  
5850 OPUS PARKWAY,  
SUITE 300  
MINNETONKA, MINNESOTA 55343-4414  
ATTN: DANIEL BLANK

510k Number: K121213  
Product: VITREAADVANCED  
On Hold As of 6/22/2012

We are holding your above-referenced Premarket Notification (510(k)) for 30 days pending receipt of the additional information that was requested by the Office of Device Evaluation. Please remember that all correspondence concerning your submission MUST cite your 510(k) number and be sent in duplicate to the Document Mail Center at the above letterhead address. Correspondence sent to any address other than the one above will not be considered as part of your official premarket notification submission. Also, please note the new Blue Book Memorandum regarding Fax and E-mail Policy entitled, "Fax and E-Mail Communication with Industry about Premarket Files Under Review. Please refer to this guidance for information on current fax and e-mail practices at <http://www.fda.gov/MedicalDevices/DeviceRegulationandGuidance/GuidanceDocuments/ucm089402.htm>.

The deficiencies identified represent the issues that we believe need to be resolved before our review of your 510(k) submission can be successfully completed. In developing the deficiencies, we carefully considered the statutory criteria as defined in Section 513(l) of the Federal Food, Drug, and Cosmetic Act for determining substantial equivalence of your device. We also considered the burden that may be incurred in your attempt to respond to the deficiencies. We believe that we have considered the least burdensome approach to resolving these issues. If, however, you believe that information is being requested that is not relevant to the regulatory decision or that there is a less burdensome way to resolve the issues, you should follow the procedures outlined in the "A Suggested Approach to Resolving Least Burdensome Issues" document. It is available on our Center web page at: <http://www.fda.gov/MedicalDevices/DeviceRegulationandGuidance/Overview/MedicalDeviceProvisionsofFDAModernizationAct/ucm136685.htm>.

If after 30 days the additional information (AI), or a request for an extension of time, is not received, we will discontinue review of your submission and proceed to delete your file from our review system (21 CFR 807.87(l)). Please note our guidance document entitled, "Guidance for Industry and FDA Staff, FDA and Industry Actions on Premarket Notification (510(k)) Submissions: Effect on FDA Review Clock and Performance Assessment". If the submitter does submit a written request for an extension, FDA will permit the 510(k) to remain on hold for up to a maximum of 180 days from the date of the AI request. The purpose of this document is to assist agency staff and the device industry in understanding how various FDA and industry actions that may be taken on 510(k)s should affect the review clock for purposes of meeting the Medical Device User Fee and Modernization Act. You may review this document at <http://www.fda.gov/MedicalDevices/DeviceRegulationandGuidance/GuidanceDocuments/ucm089735.htm>. Pursuant to 21 CFR 20.29, a copy of your 510(k) submission will remain in the Office of Device Evaluation. If you then wish to resubmit this 510(k) notification, a new number will be assigned and your submission will be considered a new premarket notification submission.



U.S. Food and Drug Administration  
Center for Devices and Radiological Health  
Document Control Center WO66-G609  
10903 New Hampshire Avenue  
Silver Spring, MD 20993-0002

April 23, 2012

VITAL IMAGES, INC.  
5850 OPUS PARKWAY,  
SUITE 300  
MINNETONKA, MINNESOTA 55343-4414  
ATTN: DANIEL BLANK

510k Number: K121213

Received: 4/20/2012

Product: VITREAAADVANCED

The Food and Drug Administration (FDA), Center for Devices and Radiological Health (CDRH), has received the Premarket Notification, (510(k)), you submitted in accordance with Section 510(k) of the Federal Food, Drug, and Cosmetic Act (Act) for the above referenced product and for the above referenced 510(k) submitter. Please note, if the 510(k) submitter is incorrect, please notify the 510(k) Staff immediately. We have assigned your submission a unique 510(k) number that is cited above. Please refer prominently to this 510(k) number in all future correspondence that relates to this submission. We will notify you when the processing of your 510(k) has been completed or if any additional information is required. **YOU MAY NOT PLACE THIS DEVICE INTO COMMERCIAL DISTRIBUTION UNTIL YOU RECEIVE A LETTER FROM FDA ALLOWING YOU TO DO SO.**

Please remember that all correspondence concerning your submission **MUST** be sent to the Document Mail Center (DMC) at the above letterhead address. Correspondence sent to any address other than the one above will not be considered as part of your official 510(k) submission.

On September 27, 2007, the President signed an act reauthorizing medical device user fees for fiscal years 2008 - 2012. The legislation - the Medical Device User Fee Amendments of 2007 is part of a larger bill, the Food and Drug Amendments Act of 2007. Please visit our website at <http://www.fda.gov/MedicalDevices/DeviceRegulationandGuidance/Overview/MedicalDeviceUserFeeandModernizationActMDUFMA/default.htm>

for more information regarding fees and FDA review goals. In addition, effective January 2, 2008, any firm that chooses to use a standard in the review of ANY new 510(k) needs to fill out the new standards form (Form 3654) and submit it with their 510(k). The form may be found at <http://www.fda.gov/AboutFDA/ReportsManualsForms/Forms/default.htm>.

We remind you that Title VIII of the Food and Drug Administration Amendments Act of 2007 (FDAAA) amended the PHS Act by adding new section 402(j) (42 U.S.C. § 282(j)), which expanded the current database known as ClinicalTrials.gov to include mandatory registration and reporting of results for applicable clinical trials of human drugs (including biological products) and devices. Section 402(j) requires that a certification form <http://www.fda.gov/AboutFDA/ReportsManualsForms/Forms/default.htm> accompany 510(k)/HDE/PMA submissions. The agency has issued a draft guidance titled: "Certifications To Accompany Drug, Biological

Product, and Device Applications/Submissions: Compliance with Section 402(j) of The Public Health Service Act, Added By Title VIII of The Food and Drug Administration Amendments Act of 2007”

<http://www.fda.gov/MedicalDevices/DeviceRegulationandGuidance/HowtoMarketYourDevice/PremarketSubmissions/PremarketNotification510k/ucm134034.htm>. According to the draft guidance, 510(k) submissions that do not contain clinical data do not need the certification form.

Please note the following documents as they relate to 510(k) review: 1) Guidance for Industry and FDA Staff entitled, “Interactive Review for Medical Device Submissions: 510(k)s, Original PMAs, PMA Supplements, Original BLAs and BLA Supplements”. This guidance can be found at <http://www.fda.gov/MedicalDevices/DeviceRegulationandGuidance/GuidanceDocuments/ucm089402.htm>. Please refer to this guidance for information on a formalized interactive review process. 2) Guidance for Industry and FDA Staff entitled, "Format for Traditional and Abbreviated 510(k)s". This guidance can be found at <http://www.fda.gov/MedicalDevices/DeviceRegulationandGuidance/GuidanceDocuments/ucm084365.htm>. Please refer to this guidance for assistance on how to format an original submission for a Traditional or Abbreviated 510(k).

In all future premarket submissions, we encourage you to provide an electronic copy of your submission. By doing so, you will save FDA resources and may help reviewers navigate through longer documents more easily. Under CDRH's e-Copy Program, you may replace one paper copy of any premarket submission (e.g., 510(k), IDE, PMA, HDE) with an electronic copy. For more information about the program, including the formatting requirements, please visit our web site at <http://www.fda.gov/MedicalDevices/DeviceRegulationandGuidance/HowtoMarketYourDevice/PremarketSubmissions/ucm134508.html>. In addition, the 510(k) Program Video is now available for viewing on line at <http://www.fda.gov/MedicalDevices/DeviceRegulationandGuidance/HowtoMarketYourDevice/PremarketSubmissions/PremarketNotification510k/ucm070201.htm>.

**Please ensure that whether you submit a 510(k) Summary as per 21 CFR 807.92, or a 510(k) Statement as per 21 CFR 807.93, it meets the content and format regulatory requirements.**

Lastly, you should be familiar with the regulatory requirements for medical devices available at Device Advice <http://www.fda.gov/MedicalDevices/DeviceRegulationandGuidance/default.htm>. If you have questions on the status of your submission, please contact DSMICA at (301)796-7100 or the toll-free number (800)638-2041, or at their internet address <http://www.fda.gov/MedicalDevices/DeviceRegulationandGuidance/default.htm>. If you have procedural questions, please contact the 510(k) Staff at (301)796-5640.

Sincerely,

510(k) Staff

**Grayson, Giovanna \***

---

**From:** Microsoft Outlook  
**To:** 'dbiank@vitalimages.com'  
**Sent:** Monday, April 23, 2012 8:38 AM  
**Subject:** Relayed: ack letter

**Delivery to these recipients or distribution lists is complete, but delivery notification was not sent by the destination:**

'dbiank@vitalimages.com'

Subject: ack letter

---

Sent by Microsoft Exchange Server 2007

**Grayson, Giovanna \***

**From:** Grayson, Giovanna \*  
**Sent:** Monday, April 23, 2012 8:38 AM  
**To:** 'dbiank@vitalimages.com'  
**Subject:** ack letter  
**Attachments:** image002.png

**DEPARTMENT OF HEALTH & HUMAN SERVICES****Public Health Service**

U.S. Food and Drug Administration  
 Center for Devices and Radiological Health  
 Document Control Center W066-0609  
 10903 New Hampshire Avenue  
 Silver Spring, MD 20993-0002

April 23, 2012

BIANK

DANIEL

VITAL IMAGES, INC.  
 5850 OPUS PARKWAY,  
 SUITE 300  
 MINNETONKA, MINNESOTA 55343-4414  
 ATTN: DANIEL BIANK

510k Number: K121213

Received: 4/20/2012

Product: VITREAADVANCED

The Food and Drug Administration (FDA), Center for Devices and Radiological Health (CDRH), has received the Premarket Notification, (510(k)), you submitted in accordance with Section 510(k) of the Federal Food, Drug, and Cosmetic Act (Act) for the above referenced product and for the above referenced 510(k) submitter. Please note, if the 510(k) submitter is incorrect, please notify the 510(k) Staff immediately. We have assigned your submission a unique 510(k) number that is cited above. Please refer prominently to this 510(k) number in all future correspondence that relates to this submission. We will notify you when the processing of your 510(k) has been completed or if any additional information is required. **YOU MAY NOT PLACE THIS DEVICE INTO COMMERCIAL DISTRIBUTION UNTIL YOU RECEIVE A LETTER FROM FDA ALLOWING YOU TO DO SO.**

Please remember that all correspondence concerning your submission **MUST** be sent to the Document Mail Center (DMC) at the above letterhead address. Correspondence sent to any address other than the one above will not be considered as part of your official 510(k) submission.

On September 27, 2007, the President signed an act reauthorizing medical device user fees for fiscal years 2008 – 2012. The legislation – the Medical Device User Fee Amendments of 2007 is part of a larger bill, the Food and Drug Amendments Act of 2007. Please visit our website at <http://www.fda.gov/MedicalDevices/DeviceRegulationandGuidance/Overview/MedicalDeviceUserFeeandModernizationActMDUFMA/default.htm> for more information regarding fees and FDA review goals. In addition, effective January 2, 2008, any firm that chooses to use a standard in the review of ANY new 510(k) needs to fill out the new standards form (Form 3654) and submit it with their 510(k). The form may be found at <http://www.fda.gov/AboutFDA/ReportsManualsForms/Forms/default.htm>.

We remind you that Title VIII of the Food and Drug Administration Amendments Act of 2007 (FDAAA) amended the PHS Act by adding new section 402(j) (42 U.S.C. § 282(j)), which expanded the current database known as ClinicalTrials.gov to include mandatory registration and reporting of results for applicable clinical trials of human drugs (including biological products) and devices. Section 402(j) requires that a certification form <http://www.fda.gov/AboutFDA/ReportsManualsForms/Forms/default.htm> accompany 510(k)/HDE/PMA submissions. The agency has issued a draft guidance titled: "Certifications To Accompany Drug, Biological

Product, and Device Applications/Submissions: Compliance with Section 402(j) of The Public Health Service Act, Added By Title VIII of The Food and Drug Administration Amendments Act of 2007"  
<http://www.fda.gov/MedicalDevices/DeviceRegulationandGuidance/HowtoMarketYourDevice/PremarketSubmissions/PremarketNotification510k/ucm134034.htm>. According to the draft guidance, 510(k) submissions that do not contain clinical data do not need the certification form.

Please note the following documents as they relate to 510(k) review: 1) Guidance for Industry and FDA Staff entitled, "Interactive Review for Medical Device Submissions: 510(k)s, Original PMAs, PMA Supplements, Original BLAs and BLA Supplements". This guidance can be found at <http://www.fda.gov/MedicalDevices/DeviceRegulationandGuidance/GuidanceDocuments/ucm089402.htm>. Please refer to this guidance for information on a formalized interactive review process. 2) Guidance for Industry and FDA Staff entitled, "Format for Traditional and Abbreviated 510(k)s". This guidance can be found at <http://www.fda.gov/MedicalDevices/DeviceRegulationandGuidance/GuidanceDocuments/ucm084365.htm>. Please refer to this guidance for assistance on how to format an original submission for a Traditional or Abbreviated 510(k).

In all future premarket submissions, we encourage you to provide an electronic copy of your submission. By doing so, you will save FDA resources and may help reviewers navigate through longer documents more easily. Under CDRH's e-Copy Program, you may replace one paper copy of any premarket submission (e.g., 510(k), IDE, PMA, HDE) with an electronic copy. For more information about the program, including the formatting requirements, please visit our web site at <http://www.fda.gov/MedicalDevices/DeviceRegulationandGuidance/HowtoMarketYourDevice/PremarketSubmissions/ucm134508.html>. In addition, the 510(k) Program Video is now available for viewing on line at <http://www.fda.gov/MedicalDevices/DeviceRegulationandGuidance/HowtoMarketYourDevice/PremarketSubmissions/PremarketNotification510k/ucm070201.htm>.

**Please ensure that whether you submit a 510(k) Summary as per 21 CFR 807.92, or a 510(k) Statement as per 21 CFR 807.93, it meets the content and format regulatory requirements.**

Lastly, you should be familiar with the regulatory requirements for medical devices available at Device Advice <http://www.fda.gov/MedicalDevices/DeviceRegulationandGuidance/default.htm>. If you have questions on the status of your submission, please contact DSMICA at (301)796-7100 or the toll-free number (800)638-2041, or at their internet address <http://www.fda.gov/MedicalDevices/DeviceRegulationandGuidance/default.htm>. If you have procedural questions, please contact the 510(k) Staff at (301)796-5640.

Sincerely,

510(k) Staff

K121213  
RA / DRAS

FDA CDRH DMC

APR 20 2012

Received *KUR*

Food and Drug Administration  
Center for Devices and Radiological Health  
Document Mail Center - WO66-G609  
10903 New Hampshire Avenue  
Silver Spring, Maryland 20993-0002

17 April 2012

**Subject: Traditional 510(k) Notification for VitreaAdvanced**

To Whom It May Concern:

In accordance with Section 510(k) of the Federal Food, Drug, and Cosmetic Act and in conformance with 21 C.F.R. 807, Vital Images, Inc. submits this 510(k) for VitreaAdvanced software.

Vital Images, Inc. intends to begin marketing this device. This submission is to obtain a determination that the VitreaAdvanced software package is substantially equivalent to the Vitrea<sup>®</sup>, Version 4.0 (K071331) platform with advanced applications for Computed Tomography (CT) Body Perfusion, CT Liver Analysis and CT Brain Perfusion. The advanced applications process the same CT studies and perform the same image review and analysis as previously cleared software applications, specifically:

- Vitrea<sup>®</sup> CT Body Perfusion is substantially equivalent to Toshiba America Medical Systems' CSBP-001A Body Perfusion System (K090504);
- Vitrea<sup>®</sup> CT Liver Analysis is substantially equivalent to MeVis LiverAnalyser / LiverViewer Software (K051528) and Median Technologies LMS-Liver (K071241), and;
- Vitrea<sup>®</sup> CT Brain Perfusion builds on Vital Images' previously cleared Vitrea<sup>®</sup> 4DCT (K072821) and performs the same intended uses as Siemens Medical Solutions' syngo<sup>®</sup> Volume Perfusion-CT Neuro (K073238).

This traditional 510(k) has been prepared in accordance with *Format for Traditional and Abbreviated 510(k)s* issued August 12, 2005, the *Guidance for the Content of Premarket Submissions for Software Contained in Medical Devices* issued May 11, 2005, and the *Guidance for the Submission Of Premarket Notifications for Medical Image Management Devices* issued July 27, 2000. An electronic copy is being provided with this submission and it is an exact duplicate of the original paper submission per the instructions accessed at <http://www.fda.gov/MedicalDevices/DeviceRegulationandGuidance/HowtoMarketYourDevice/PremarketSubmissions/ucm134508.htm>.

The following administrative information is provided as requested in the *Format for Traditional and Abbreviated 510(k)s* Appendix A:

Administrative Information

<b>510(k) Submission Type:</b>	Traditional
<b>Device Name:</b>	VitreaAdvanced
<b>Device Common Name:</b>	Picture Archiving and Communications System
<b>510(K) Submitter:</b>	Vital Images, Inc. 5850 Opus Parkway Suite 300 Minnetonka, MN-55343-4414 Establishment Registration Number: 2134213

# VITAL

A Toshiba Medical Systems Group Company

**Contact Person:** Daniel T. Biank  
 Regulatory Affairs Manager  
 Phone: 952-487-9514  
 Fax: 952-487-9510  
 E-mail: dbiank@vitalimages.com

**Alternate Contact Person:** Ian Nemerov  
 Vice President, General Counsel and Secretary  
 Phone: 952-487-9622  
 Fax: 952-487-9510  
 E-mail: inemerov@vitalimages.com

**Confidentiality Preference:** Keep Confidential  
**Classification Regulation:** 21 CFR 892.2050  
**Classification:** Class II  
**Panel:** Radiology  
**Product Code:** LLZ  
**Prior Related FDA Correspondence:** None

**Basis for Submission**

This Traditional 510(k) is being submitted because this VitreaAdvanced package is a new device.

**Design and Use of the Device**

The following table provides the additional high-level information regarding the design and use of the device:

Question	YES	NO
Is the device intended for prescription use (21 CFR 801 Subpart D)?	X	
Is the device intended for over-the-counter use (21 CFR 807 Subpart C)?		X
Does the device contain components derived from a tissue or other biologic source?		X
Is the device provided sterile?		X
Is the device intended for single use?		X
Is the device a reprocessed single use device?		X
If yes, does this device type require reprocessed validation data?		X
Does the device contain a drug?		X
Does the device contain a biologic?		X
Does the device use software?	X	
Does the submission include clinical information?		X
Is the device implanted?		X

Vital Images, Inc. regards both the content and the existence of this 510(k) submission as confidential commercial information and requests that it be treated as such by the FDA.

Thank you for your attention to this matter. I look forward to an interactive and collaborative review process. Please contact me with any question regarding this submission or for further information at (952) 487-9514 or via email dbiank@vitalimages.com

Sincerely,



Daniel Biank  
 Regulatory Affairs Manager



K121213  
RA / DRAS

FDA CDRH DMC

APR 20 2012

Received *KUB*

Food and Drug Administration  
Center for Devices and Radiological Health  
Document Mail Center - WO66-G609  
10903 New Hampshire Avenue  
Silver Spring, Maryland 20993-0002

17 April 2012

**Subject: Traditional 510(k) Notification for VitreaAdvanced**

To Whom It May Concern:

In accordance with Section 510(k) of the Federal Food, Drug, and Cosmetic Act and in conformance with 21 C.F.R. 807, Vital Images, Inc. submits this 510(k) for VitreaAdvanced software.

Vital Images, Inc. intends to begin marketing this device. This submission is to obtain a determination that the VitreaAdvanced software package is substantially equivalent to the Vitrea<sup>®</sup>, Version 4.0 (K071331) platform with advanced applications for Computed Tomography (CT) Body Perfusion, CT Liver Analysis and CT Brain Perfusion. The advanced applications process the same CT studies and perform the same image review and analysis as previously cleared software applications, specifically:

- Vitrea<sup>®</sup> CT Body Perfusion is substantially equivalent to Toshiba America Medical Systems' CSBP-001A Body Perfusion System (K090504);
- Vitrea<sup>®</sup> CT Liver Analysis is substantially equivalent to MeVis LiverAnalyser / LiverViewer Software (K051528) and Median Technologies LMS-Liver (K071241), and;
- Vitrea<sup>®</sup> CT Brain Perfusion builds on Vital Images' previously cleared Vitrea<sup>®</sup> 4DCT (K072821) and performs the same intended uses as Siemens Medical Solutions' syngo<sup>®</sup> Volume Perfusion-CT Neuro (K073238).

This traditional 510(k) has been prepared in accordance with *Format for Traditional and Abbreviated 510(k)s* issued August 12, 2005, the *Guidance for the Content of Premarket Submissions for Software Contained in Medical Devices* issued May 11, 2005, and the *Guidance for the Submission Of Premarket Notifications for Medical Image Management Devices* issued July 27, 2000. An electronic copy is being provided with this submission and it is an exact duplicate of the original paper submission per the instructions accessed at <http://www.fda.gov/MedicalDevices/DeviceRegulationandGuidance/HowtoMarketYourDevice/PremarketSubmissions/ucm134508.htm>.

The following administrative information is provided as requested in the *Format for Traditional and Abbreviated 510(k)s* Appendix A:

Administrative Information

<b>510(k) Submission Type:</b>	Traditional
<b>Device Name:</b>	VitreaAdvanced
<b>Device Common Name:</b>	Picture Archiving and Communications System
<b>510(K) Submitter:</b>	Vital Images, Inc. 5850 Opus Parkway Suite 300 Minnetonka, MN-55343-4414 Establishment Registration Number: 2134213

# VITAL

A Toshiba Medical Systems Group Company

**Contact Person:** Daniel T. Biank  
 Regulatory Affairs Manager  
 Phone: 952-487-9514  
 Fax: 952-487-9510  
 E-mail: dbiank@vitalimages.com

**Alternate Contact Person:** Ian Nemerov  
 Vice President, General Counsel and Secretary  
 Phone: 952-487-9622  
 Fax: 952-487-9510  
 E-mail: inemerov@vitalimages.com

**Confidentiality Preference:** Keep Confidential  
**Classification Regulation:** 21 CFR 892.2050  
**Classification:** Class II  
**Panel:** Radiology  
**Product Code:** LLZ  
**Prior Related FDA Correspondence:** None

**Basis for Submission**

This Traditional 510(k) is being submitted because this VitreaAdvanced package is a new device.

**Design and Use of the Device**

The following table provides the additional high-level information regarding the design and use of the device:

Question	YES	NO
Is the device intended for prescription use (21 CFR 801 Subpart D)?	X	
Is the device intended for over-the-counter use (21 CFR 807 Subpart C)?		X
Does the device contain components derived from a tissue or other biologic source?		X
Is the device provided sterile?		X
Is the device intended for single use?		X
Is the device a reprocessed single use device?		X
If yes, does this device type require reprocessed validation data?		X
Does the device contain a drug?		X
Does the device contain a biologic?		X
Does the device use software?	X	
Does the submission include clinical information?		X
Is the device implanted?		X

Vital Images, Inc. regards both the content and the existence of this 510(k) submission as confidential commercial information and requests that it be treated as such by the FDA.

Thank you for your attention to this matter. I look forward to an interactive and collaborative review process. Please contact me with any question regarding this submission or for further information at (952) 487-9514 or via email dbiank@vitalimages.com

Sincerely,



Daniel Biank  
 Regulatory Affairs Manager

**V i T A L**

A Toshiba Medical Systems Group Company

## 510(k) Premarket Notification

VitreaAdvanced

Vital Images, Inc.

5850 Opus Parkway, Suite 300

Minnetonka, MN 55343-4414

17 April 2012

**CONFIDENTIAL**

## Contents

1	Medical Device User Fee Cover Sheet.....	7
2	CDRH Premarket Review Submission Cover Sheet.....	9
3	510(k) Cover Letter.....	15
4	Indications for Use Statement.....	18
5	510(k) Summary .....	21
6	Truthful and Accuracy Statement.....	26
7	Class III Summary and Certification.....	28
8	Financial Certification or Disclosure Statement .....	29
9	Declarations of Conformity and Summary Reports .....	30
10	Executive Summary .....	31
11	Device Description.....	35
12	Substantial Equivalence Discussion.....	38
13	Proposed Labeling .....	52
14	Sterilization and Shelf Life .....	54
15	Biocompatibility.....	55
16	Software .....	56
17	Electromagnetic Compatibility and Electrical Safety.....	61
18	Performance Testing – Bench.....	62
19	Performance Testing – Animal .....	64
20	Performance Testing – Clinical .....	65
21	Software Certification.....	66
22	Mapping <i>Guidance for the Submission Of Premarket Notifications for Medical Image Management Devices to Format for Traditional and Abbreviated 510(k)s</i> .....	68

## Attachments

### **Section 12 – Substantial Equivalence**

- 12.1 Vital Images Vitrea<sup>®</sup>, Version 4.0, K071331 510(k) Summary
- 12.2 Vital Images Vitrea<sup>®</sup> 4DCT, K072821 510(k) Summary
- 12.3 Toshiba CSBP-001A Body Perfusion System, K090504 510(k) Summary
- 12.4 Toshiba CSBP-001A Body Perfusion System, Draft Labeling
- 12.5 MeVis LiverAnalyser / LiverViewer Software, K051528 510(k) Summary
- 12.6 MEDIAN Technologies LMS-Liver, K071241 510(k) Summary
- 12.7 Siemens syngo<sup>®</sup> Volume Perfusion-CT Neuro, K073238 510(k) Summary

# Vital Images

VitreAdvanced  
510(k) Pre-market Notification

- 12.8 Morhard, Vasospasm after SAH: Neuro Volume Perfusion CT, SOMATOM Sessions-Siemens Healthcare Magazine (May 2008)
- 12.9 Wintermark, Prognostic Accuracy of Cerebral Blood Flow Measurement by Perfusion Computed Tomography, Annals of Neurology (2002)

## Section 13 – Proposed Labeling

- 13.1 CT Body Perfusion Education and Reference Guide (VPMC-12294)
- 13.2 CT Liver Analysis Education and Reference Guide (VPMC-12295)
- 13.3 CT Brain Perfusion Education and Reference Guide (VPMC-12292)
- 13.4 VitreaAdvanced Promotional Excerpt (M-05545)

## Section 16 – Software

(b)(4)



## Screening Checklist for Traditional/Abbreviated Premarket Notification [510(k)] Submissions

based on

*Guidance for Industry and FDA Staff Format for Traditional and Abbreviated 510(k)s*  
<http://www.fda.gov/MedicalDevices/DeviceRegulationandGuidance/GuidanceDocuments/ucm084365.htm>

Title	Related Information	Present	Inadequate	N/A
MDUFMA Cover Sheet	Medical Device User Fee Cover Sheet <a href="http://www.fda.gov/ForIndustry/UserFees/MedicalDeviceUserFeeandModernizationAct/ucm155274.htm">http://www.fda.gov/ForIndustry/UserFees/MedicalDeviceUserFeeandModernizationAct/ucm155274.htm</a>	Page 7		
CDRH Premarket Review Submission Cover Sheet	CDRH Premarket Review Submission Voluntary Cover Sheet <a href="http://www.fda.gov/downloads/AboutFDA/ReportsManualsForms/Forms/UCM080872.pdf">http://www.fda.gov/downloads/AboutFDA/ReportsManualsForms/Forms/UCM080872.pdf</a>	Page 9		
510(k) Cover Letter	Appendix A of "Guidance for Industry and FDA Staff Format for Traditional and Abbreviated 510(k)s" updated November 17, 2005 <a href="http://www.fda.gov/MedicalDevices/DeviceRegulationandGuidance/GuidanceDocuments/ucm084365.htm">http://www.fda.gov/MedicalDevices/DeviceRegulationandGuidance/GuidanceDocuments/ucm084365.htm</a>	Page 15		
Indications for Use Statement	Device Advice "Content of a 510(k)" Section D <a href="http://www.fda.gov/MedicalDevices/DeviceRegulationandGuidance/GuidanceDocuments/ucm080275.htm">http://www.fda.gov/MedicalDevices/DeviceRegulationandGuidance/GuidanceDocuments/ucm080275.htm</a>	Page 18		
510(k) Summary or 510(k) Statement	Device Advice "Content of a 510(k)" Section E <a href="http://www.fda.gov/MedicalDevices/DeviceRegulationandGuidance/HowtoMarketYourDevice/PremarketSubmissions/PremarketNotification510k/ucm142651.htm">http://www.fda.gov/MedicalDevices/DeviceRegulationandGuidance/HowtoMarketYourDevice/PremarketSubmissions/PremarketNotification510k/ucm142651.htm</a>	Page 21		
Truthful and Accuracy Statement	Device Advice "Content of a 510(k)" Section G <a href="http://www.fda.gov/MedicalDevices/DeviceRegulationandGuidance/HowtoMarketYourDevice/PremarketSubmissions/PremarketNotification510k/ucm142707.htm">http://www.fda.gov/MedicalDevices/DeviceRegulationandGuidance/HowtoMarketYourDevice/PremarketSubmissions/PremarketNotification510k/ucm142707.htm</a>	Page 26		
Class III Summary and Certification	Class III Summary and Certification Form <a href="http://www.fda.gov/MedicalDevices/DeviceRegulationandGuidance/HowtoMarketYourDevice/PremarketSubmissions/PremarketNotification510k/ucm142662.htm">http://www.fda.gov/MedicalDevices/DeviceRegulationandGuidance/HowtoMarketYourDevice/PremarketSubmissions/PremarketNotification510k/ucm142662.htm</a>			NA, not Class III
Financial Certification or Disclosure Statement	FORM FDA 3454, Certification: Financial Interests and Arrangements of Clinical Investigators <a href="http://www.fda.gov/downloads/AboutFDA/ReportsManualsForms/Forms/UCM048304.pdf">http://www.fda.gov/downloads/AboutFDA/ReportsManualsForms/Forms/UCM048304.pdf</a> FORM FDA 3455, Disclosure: Financial Interests and Arrangements of Clinical Investigators <a href="http://www.fda.gov/downloads/AboutFDA/ReportsManualsForms/Forms/UCM048310.pdf">http://www.fda.gov/downloads/AboutFDA/ReportsManualsForms/Forms/UCM048310.pdf</a> Financial Disclosure by Clinical Investigators <a href="http://www.fda.gov/RegulatoryInformation/Guidances/ucm126832.htm">http://www.fda.gov/RegulatoryInformation/Guidances/ucm126832.htm</a>			NA, no clinical trials

## Vital Images

VitreAdvanced  
510(k) Pre-market Notification

Title	Related Information	Present	Inadequate	N/A
Declarations of Conformity and Summary Reports (Abbreviated 510(k)s)	<p>Use of Standards in Substantial Equivalence Determinations  <a href="http://www.fda.gov/MedicalDevices/DeviceRegulationandGuidance/GuidanceDocuments/ucm073752.htm">http://www.fda.gov/MedicalDevices/DeviceRegulationandGuidance/GuidanceDocuments/ucm073752.htm</a></p> <p>FDA Standards program  <a href="http://www.fda.gov/MedicalDevices/DeviceRegulationandGuidance/Standards/default.htm">http://www.fda.gov/MedicalDevices/DeviceRegulationandGuidance/Standards/default.htm</a></p> <p>Declaration of conformity  <a href="http://www.fda.gov/cdrh/devadvice/3145.html#link9">www.fda.gov/cdrh/devadvice/3145.html#link9</a></p> <p>Required Elements for Declaration of Conformity to Recognized Standard  <a href="http://www.fda.gov/MedicalDevices/DeviceRegulationandGuidance/HowtoMarketYourDevice/PremarketSubmissions/PremarketNotification510k/ucm142706.htm">http://www.fda.gov/MedicalDevices/DeviceRegulationandGuidance/HowtoMarketYourDevice/PremarketSubmissions/PremarketNotification510k/ucm142706.htm</a></p>			NA, not Abbreviated 510(k)
Executive Summary	<p>See section 10 in Chapter II of "Guidance for Industry and FDA Staff Format for Traditional and Abbreviated 510(k)s" updated November 17, 2005  <a href="http://www.fda.gov/MedicalDevices/DeviceRegulationandGuidance/GuidanceDocuments/ucm084365.htm">http://www.fda.gov/MedicalDevices/DeviceRegulationandGuidance/GuidanceDocuments/ucm084365.htm</a></p>	Page 31		
Device Description	<p>See section 11 in Chapter II of "Guidance for Industry and FDA Staff Format for Traditional and Abbreviated 510(k)s" updated November 17, 2005  <a href="http://www.fda.gov/MedicalDevices/DeviceRegulationandGuidance/GuidanceDocuments/ucm084365.htm">http://www.fda.gov/MedicalDevices/DeviceRegulationandGuidance/GuidanceDocuments/ucm084365.htm</a></p>	Page 35		
Substantial Equivalence Discussion	<p>Guidance on the CDRH Premarket Notification Review Program 6/30/86 (K86-3),  <a href="http://www.fda.gov/MedicalDevices/DeviceRegulationandGuidance/GuidanceDocuments/ucm081383.htm">http://www.fda.gov/MedicalDevices/DeviceRegulationandGuidance/GuidanceDocuments/ucm081383.htm</a></p>	Page 38		
Proposed Labeling	<p>Device Advice "Content of a 510(k)" Section H  <a href="http://www.fda.gov/MedicalDevices/DeviceRegulationandGuidance/Overview/DeviceLabeling/default.htm">http://www.fda.gov/MedicalDevices/DeviceRegulationandGuidance/Overview/DeviceLabeling/default.htm</a></p>	Page 52		
Sterilization/Shelf Life	<p>Updated 510(k) Sterility Review Guidance (K90-1)  <a href="http://www.fda.gov/MedicalDevices/DeviceRegulationandGuidance/GuidanceDocuments/ucm072783.htm">http://www.fda.gov/MedicalDevices/DeviceRegulationandGuidance/GuidanceDocuments/ucm072783.htm</a></p> <p>For reuse of single use devices, see Guidance for Industry and FDA Staff – Medical Device User Fee and Modernization Act of 2002 Validation Data in Premarket Notification Submissions (510(k)s) for Reprocessed Single-Use Medical Devices  <a href="http://www.fda.gov/MedicalDevices/DeviceRegulationandGuidance/GuidanceDocuments/ucm071434.htm">http://www.fda.gov/MedicalDevices/DeviceRegulationandGuidance/GuidanceDocuments/ucm071434.htm</a></p>			NA, not a sterile device
Biocompatibility	<p>FDA Blue Book Memo, G95-1, Use of International Standard ISO-10993,  <a href="http://www.fda.gov/MedicalDevices/DeviceRegulationandGuidance/GuidanceDocuments/ucm080735.htm">http://www.fda.gov/MedicalDevices/DeviceRegulationandGuidance/GuidanceDocuments/ucm080735.htm</a></p>			NA, no patient contact surfaces

## Vital Images

VitreAdvanced  
510(k) Pre-market Notification

Title	Related Information	Present	Inadequate	N/A
Software	Guidance for the Content of Premarket Submissions for Software Contained in Medical Devices <a href="http://www.fda.gov/MedicalDevices/DeviceRegulationandGuidance/GuidanceDocuments/ucm089543.htm">http://www.fda.gov/MedicalDevices/DeviceRegulationandGuidance/GuidanceDocuments/ucm089543.htm</a>	Page 56		
Electromagnetic Compatibility/Electrical Safety	CDRH Medical Device Electromagnetic Compatibility Program <a href="http://www.fda.gov/Radiation-EmittingProducts/RadiationSafety/ElectromagneticCompatibilityEMC/default.htm">http://www.fda.gov/Radiation-EmittingProducts/RadiationSafety/ElectromagneticCompatibilityEMC/default.htm</a> See also IEC 60601-1-2 Medical Electrical Equipment -- Part 1: General Requirements for Safety; Electromagnetic Compatibility -- Requirements and Tests (Second Edition, 2001)			NA, software-only device
Performance Testing – Bench	See section 18 in Chapter II of “Guidance for Industry and FDA Staff Format for Traditional and Abbreviated 510(k)s” updated November 17, 2005 <a href="http://www.fda.gov/MedicalDevices/DeviceRegulationandGuidance/GuidanceDocuments/ucm084365.htm">http://www.fda.gov/MedicalDevices/DeviceRegulationandGuidance/GuidanceDocuments/ucm084365.htm</a>	Page 62		
Performance Testing – Animal	See section 19 in Chapter II of “Guidance for Industry and FDA Staff Format for Traditional and Abbreviated 510(k)s” updated November 17, 2005 <a href="http://www.fda.gov/MedicalDevices/DeviceRegulationandGuidance/GuidanceDocuments/ucm084365.htm">http://www.fda.gov/MedicalDevices/DeviceRegulationandGuidance/GuidanceDocuments/ucm084365.htm</a>			NA, no animal testing
Performance Testing – Clinical	See section 20 in Chapter II of “Guidance for Industry and FDA Staff Format for Traditional and Abbreviated 510(k)s” updated November 17, 2005 Certification/Disclosure Forms: Financial Interests and Arrangements of Clinical Investigators <a href="http://www.fda.gov/downloads/AboutFDA/ReportsManualsForms/Forms/UCM048304.pdf">http://www.fda.gov/downloads/AboutFDA/ReportsManualsForms/Forms/UCM048304.pdf</a> <a href="http://www.fda.gov/downloads/AboutFDA/ReportsManualsForms/Forms/UCM048310.pdf">http://www.fda.gov/downloads/AboutFDA/ReportsManualsForms/Forms/UCM048310.pdf</a>			NA, no clinical trials
FORM FDA 3654, Standards Data Report for 510(k)s - <a href="http://www.fda.gov/downloads/AboutFDA/ReportsManualsForms/Forms/UCM081667.pdf">http://www.fda.gov/downloads/AboutFDA/ReportsManualsForms/Forms/UCM081667.pdf</a>	<b>Standards Data Report Form – Form 3654</b> 1: No standard used - <b>No Standards Form Required</b> 2: Declaration of Conformity – <b>Yes Standards Form Required</b> 3: Standard but no declaration – <b>Yes Standards Form Required</b>	Page 60		
Kit Certification	Device Advice <a href="http://www.fda.gov/MedicalDevices/DeviceRegulationandGuidance/GuidanceDocuments/ucm080213.htm">http://www.fda.gov/MedicalDevices/DeviceRegulationandGuidance/GuidanceDocuments/ucm080213.htm</a>			NA, not a kit



# 1 Medical Device User Fee Cover Sheet

Records processed under FOIA Request #2014-9977; Released by CDRH on 12-8-2015

Form Approved: OMB No. 0910-511. See Instructions for OMB Statement.

DEPARTMENT OF HEALTH AND HUMAN SERVICES FOOD AND DRUG ADMINISTRATION <b>MEDICAL DEVICE USER FEE COVER SHEET</b>		PAYMENT IDENTIFICATION NUMBER: (b)(4) Write the Payment Identification number on your check.
A completed cover sheet must accompany each original application or supplement subject to fees. If payment is sent by U.S. mail or courier, please include a copy of this completed form with payment. Payment and mailing instructions can be found at: <a href="http://www.fda.gov/oc/mdufma/coversheet.html">http://www.fda.gov/oc/mdufma/coversheet.html</a>		
1. COMPANY NAME AND ADDRESS (include name, street address, city state, country, and post office code)  VITAL IMAGES INC 5850 Opus Parkway Suite 300 Minnetonka MN 55343-4414 US  1.1 EMPLOYER IDENTIFICATION NUMBER (EIN) *****1776	2. CONTACT NAME Daniel Biank  2.1 E-MAIL ADDRESS dbiank@vitalimages.com  2.2 TELEPHONE NUMBER (include Area code) 952-487-9514  2.3 FACSIMILE (FAX) NUMBER (Include Area code)	
3. TYPE OF PREMARKET APPLICATION (Select one of the following in each column; if you are unsure, please refer to the application descriptions at the following web site: <a href="http://www.fda.gov/oc/mdufma">http://www.fda.gov/oc/mdufma</a> ) <u>Select an application type:</u> <input checked="" type="checkbox"/> Premarket notification(510(k)); except for third party <input type="checkbox"/> 513(g) Request for Information <input type="checkbox"/> Biologics License Application (BLA) <input type="checkbox"/> Premarket Approval Application (PMA) <input type="checkbox"/> Modular PMA <input type="checkbox"/> Product Development Protocol (PDP) <input type="checkbox"/> Premarket Report (PMR) <input type="checkbox"/> Annual Fee for Periodic Reporting (APR) <input type="checkbox"/> 30-Day Notice		
3.1 Select a center <input checked="" type="checkbox"/> CDRH <input type="checkbox"/> CBER 3.2 Select one of the types below <input checked="" type="checkbox"/> Original Application <u>Supplement Types:</u> <input type="checkbox"/> Efficacy (BLA) <input type="checkbox"/> Panel Track (PMA, PMR, PDP) <input type="checkbox"/> Real-Time (PMA, PMR, PDP) <input type="checkbox"/> 180-day (PMA, PMR, PDP)		
4. ARE YOU A SMALL BUSINESS? (See the instructions for more information on determining this status) <input type="checkbox"/> YES, I meet the small business criteria and have submitted the required qualifying documents to FDA <input checked="" type="checkbox"/> NO, I am not a small business 4.1 If Yes, please enter your Small Business Decision Number:		
5. FDA WILL NOT ACCEPT YOUR SUBMISSION IF YOUR COMPANY HAS NOT PAID AN ESTABLISHMENT REGISTRATION FEE THAT IS DUE TO FDA. HAS YOUR COMPANY PAID ALL ESTABLISHMENT REGISTRATION FEES THAT ARE DUE TO FDA? <input checked="" type="checkbox"/> YES (All of our establishments have registered and paid the fee, or this is our first device, and we will register and pay the fee within 30 days of FDA's approval/clearance of this device.) <input type="checkbox"/> NO (If "NO," FDA will not accept your submission until you have paid all fees due to FDA. This submission will not be processed; see <a href="http://www.fda.gov/cdrh/mdufma">http://www.fda.gov/cdrh/mdufma</a> for additional information)		
6. IS THIS PREMARKET APPLICATION COVERED BY ANY OF THE FOLLOWING USER FEE EXCEPTIONS? IF SO, CHECK THE APPLICABLE EXCEPTION. <input type="checkbox"/> This application is the first PMA submitted by a qualified small business, including any affiliates <input type="checkbox"/> This biologics application is submitted under section 351 of the Public Health Service Act for a product licensed for further manufacturing use only <input type="checkbox"/> The sole purpose of the application is to support conditions of use for a pediatric population <input type="checkbox"/> The application is submitted by a state or federal government entity for a device that is not to be distributed commercially		
7. IS THIS A SUPPLEMENT TO A PREMARKET APPLICATION FOR WHICH FEES WERE WAIVED DUE TO SOLE USE IN A PEDIATRIC POPULATION THAT NOW PROPOSES CONDITION OF USE FOR ANY ADULT POPULATION? (If so, the application is subject to the fee that applies for an original premarket approval application (PMA). <input type="checkbox"/> YES <input checked="" type="checkbox"/> NO		
PAPERWORK REDUCTION ACT STATEMENT Public reporting burden for this collection of information is estimated to average 18 minutes per response, including the time for reviewing instructions, searching existing data sources, gathering and maintaining the data needed, and completing and reviewing the collection of information. Send comments regarding this burden estimate or any other aspect of this collection of information, including suggestions for reducing this burden, to the address below.  Department of Health and Human Services, Food and Drug Administration, Office of Chief Information Officer, 1350 Piccard Drive, 4th Floor Rockville, MD 20850 [Please do NOT return this form to the above address, except as it pertains to comments on the burden estimate.]		
8. USER FEE PAYMENT AMOUNT SUBMITTED FOR THIS PREMARKET APPLICATION (b)(4)		20-Mar-2012

Form FDA 3601 (01/2007)

["Close Window"](#) [Print Cover sheet](#)

Questions? Contact FDA/CDRH/OCE/DID at CDRH-FOISTATUS@fda.hhs.gov or 301-796-8118

## **2 CDRH Premarket Review Submission Cover Sheet**

DEPARTMENT OF HEALTH AND HUMAN SERVICES  
FOOD AND DRUG ADMINISTRATIONForm Approval  
OMB No. 0910-0120  
Expiration Date: December 31, 2013  
See OMB Statement on page 5.**CDRH PREMARKET REVIEW SUBMISSION COVER SHEET**

Date of Submission April 17, 2012	User Fee Payment ID Number (b)(4)	FDA Submission Document Number (if known) Not known
--------------------------------------	--------------------------------------	--

SECTION A TYPE OF SUBMISSION				
<b>PMA</b> <input type="checkbox"/> Original Submission <input type="checkbox"/> Premarket Report <input type="checkbox"/> Modular Submission <input type="checkbox"/> Amendment <input type="checkbox"/> Report <input type="checkbox"/> Report Amendment <input type="checkbox"/> Licensing Agreement	<b>PMA &amp; HDE Supplement</b> <input type="checkbox"/> Regular (180 day) <input type="checkbox"/> Special <input type="checkbox"/> Panel Track (PMA Only) <input type="checkbox"/> 30-day Supplement <input type="checkbox"/> 30-day Notice <input type="checkbox"/> 135-day Supplement <input type="checkbox"/> Real-time Review <input type="checkbox"/> Amendment to PMA & HDE Supplement <input type="checkbox"/> Other	<b>PDP</b> <input type="checkbox"/> Original PDP <input type="checkbox"/> Notice of Completion <input type="checkbox"/> Amendment to PDP	<b>510(k)</b> <input checked="" type="checkbox"/> Original Submission: <input checked="" type="checkbox"/> Traditional <input type="checkbox"/> Special <input type="checkbox"/> Abbreviated (Complete section I, Page 5) <input type="checkbox"/> Additional Information <input type="checkbox"/> Third Party	<b>Meeting</b> <input type="checkbox"/> Pre-510(K) Meeting <input type="checkbox"/> Pre-IDE Meeting <input type="checkbox"/> Pre-PMA Meeting <input type="checkbox"/> Pre-PDP Meeting <input type="checkbox"/> Day 100 Meeting <input type="checkbox"/> Agreement Meeting <input type="checkbox"/> Determination Meeting <input type="checkbox"/> Other (specify):
<b>IDE</b> <input type="checkbox"/> Original Submission <input type="checkbox"/> Amendment <input type="checkbox"/> Supplement	<b>Humanitarian Device Exemption (HDE)</b> <input type="checkbox"/> Original Submission <input type="checkbox"/> Amendment <input type="checkbox"/> Supplement <input type="checkbox"/> Report <input type="checkbox"/> Report Amendment	<b>Class II Exemption Petition</b> <input type="checkbox"/> Original Submission <input type="checkbox"/> Additional Information	<b>Evaluation of Automatic Class III Designation (De Novo)</b> <input type="checkbox"/> Original Submission <input type="checkbox"/> Additional Information	<b>Other Submission</b> <input type="checkbox"/> 513(g) <input type="checkbox"/> Other (describe submission):

Have you used or cited Standards in your submission?  Yes  No (If Yes, please complete Section I, Page 5)

SECTION B SUBMITTER, APPLICANT OR SPONSOR			
Company / Institution Name Vital Images, Inc.	Establishment Registration Number (if known) 2134213		
Division Name (if applicable) Not Applicable	Phone Number (including area code) 952-487-9514		
Street Address 5850 Opus Parkway, Suite 300	FAX Number (including area code) 952-487-9510		
City Minnetonka	State / Province MN	ZIP/Postal Code 55343	Country USA
Contact Name Daniel Biank			
Contact Title Regulatory Affairs Manager	Contact E-mail Address dbiank@vitalimages.com		

SECTION C APPLICATION CORRESPONDENT (e.g., consultant, if different from above)			
Company / Institution Name Same as above	Phone Number (including area code)		
Division Name (if applicable)	FAX Number (including area code)		
Street Address	FAX Number (including area code)		
City	State / Province	ZIP Code	Country
Contact Name			
Contact Title	Contact E-mail Address		

SECTION D1			REASON FOR APPLICATION - PMA, PDP, OR HDE		
<input type="checkbox"/> New Device <input type="checkbox"/> Withdrawal <input type="checkbox"/> Additional or Expanded Indications <input type="checkbox"/> Request for Extension <input type="checkbox"/> Post-approval Study Protocol <input type="checkbox"/> Request for Applicant Hold <input type="checkbox"/> Request for Removal of Applicant Hold <input type="checkbox"/> Request to Remove or Add Manufacturing Site	<input type="checkbox"/> Change in design, component, or specification: <input type="checkbox"/> Software /Hardware <input type="checkbox"/> Color Additive <input type="checkbox"/> Material <input type="checkbox"/> Specifications <input type="checkbox"/> Other (specify below)	<input type="checkbox"/> Location change: <input type="checkbox"/> Manufacturer <input type="checkbox"/> Sterilizer <input type="checkbox"/> Packager			
<input type="checkbox"/> Process change: <input type="checkbox"/> Manufacturing <input type="checkbox"/> Packaging <input type="checkbox"/> Sterilization <input type="checkbox"/> Other (specify below)	<input type="checkbox"/> Labeling change: <input type="checkbox"/> Indications <input type="checkbox"/> Instructions <input type="checkbox"/> Performance Characteristics <input type="checkbox"/> Shelf Life <input type="checkbox"/> Trade Name <input type="checkbox"/> Other (specify below)	<input type="checkbox"/> Report Submission: <input type="checkbox"/> Annual or Periodic <input type="checkbox"/> Post-approval Study <input type="checkbox"/> Adverse Reaction <input type="checkbox"/> Device Defect <input type="checkbox"/> Amendment			
<input type="checkbox"/> Response to FDA correspondence:	<input type="checkbox"/> Change in Ownership <input type="checkbox"/> Change in Correspondent <input type="checkbox"/> Change of Applicant Address				
<input type="checkbox"/> Other Reason (specify):					

SECTION D2			REASON FOR APPLICATION - IDE		
<input type="checkbox"/> New Device <input type="checkbox"/> New Indication <input type="checkbox"/> Addition of Institution <input type="checkbox"/> Expansion / Extension of Study <input type="checkbox"/> IRB Certification <input type="checkbox"/> Termination of Study <input type="checkbox"/> Withdrawal of Application <input type="checkbox"/> Unanticipated Adverse Effect <input type="checkbox"/> Notification of Emergency Use <input type="checkbox"/> Compassionate Use Request <input type="checkbox"/> Treatment IDE <input type="checkbox"/> Continued Access	<input type="checkbox"/> Change in: <input type="checkbox"/> Correspondent /Applicant <input type="checkbox"/> Design /Device <input type="checkbox"/> Informed Consent <input type="checkbox"/> Manufacturer <input type="checkbox"/> Manufacturing Process <input type="checkbox"/> Protocol - Feasibility <input type="checkbox"/> Protocol - Other <input type="checkbox"/> Sponsor	<input type="checkbox"/> Response to FDA Letter Concerning: <input type="checkbox"/> Conditional Approval <input type="checkbox"/> Deemed Approved <input type="checkbox"/> Deficient Final Report <input type="checkbox"/> Deficient Progress Report <input type="checkbox"/> Deficient Investigator Report <input type="checkbox"/> Disapproval <input type="checkbox"/> Request Extension of Time to Respond to FDA <input type="checkbox"/> Request Meeting <input type="checkbox"/> Request Hearing			
<input type="checkbox"/> Report submission: <input type="checkbox"/> Current Investigator <input type="checkbox"/> Annual Progress Report <input type="checkbox"/> Site Waiver Report <input type="checkbox"/> Final					
<input type="checkbox"/> Other Reason (specify):					

SECTION D3			REASON FOR SUBMISSION - 510(k)		
<input checked="" type="checkbox"/> New Device	<input type="checkbox"/> Additional or Expanded Indications	<input type="checkbox"/> Change in Technology			
<input type="checkbox"/> Other Reason (specify):					

**SECTION E ADDITIONAL INFORMATION ON 510(K) SUBMISSIONS**

Product codes of devices to which substantial equivalence is claimed								Summary of, or statement concerning, safety and effectiveness information <input checked="" type="checkbox"/> 510 (k) summary attached <input type="checkbox"/> 510 (k) statement
1	LLZ	2		3		4		
5		6		7		8		

Information on devices to which substantial equivalence is claimed (if known)

	510(k) Number		Trade or Proprietary or Model Name		Manufacturer
1	K071331	1	VitreA®, Version 4.0	1	Vital Images, Inc., Minnetonka, MN 55343
2	K072821	2	VitreA® 4DCT	2	Vital Images, Inc., Minnetonka, MN 55343
3	K090504	3	CSBP-001A Body Perfusion System	3	Toshiba Medical Systems Corp. Tustin, CA
4	K051528	4	MeVis LiverAnalyser / LiverViewer Software	4	Mevis Technology GMBH & CO. KG Corinth, TX
5	K071241	5	LMS-Liver	5	Median Technologies Sophia Antipolis France
6	K073238	6	syngo® Volume Perfusion-CT Neuro	6	Siemens Medical Solutions, Inc. Malvern, PA

**SECTION F PRODUCT INFORMATION - APPLICATION TO ALL APPLICATIONS**

Common or usual name or classification name  
Picture archiving and communications system

	Trade or Proprietary or Model Name for This Device		Model Number
1	VitreAAdvanced	1	
2		2	
3		3	
4		4	
5		5	

FDA document numbers of all prior related submissions (regardless of outcome)

1	2	3	4	5	6
7	8	9	10	11	12

Data Included in Submission  
 Laboratory Testing   
 Animal Trials   
 Human Trials

**SECTION G PRODUCT CLASSIFICATION - APPLICATION TO ALL APPLICATIONS**

Product Code LLZ	C.F.R. Section (if applicable) 892.2050	Device Class <input type="checkbox"/> Class I <input checked="" type="checkbox"/> Class II <input type="checkbox"/> Class III <input type="checkbox"/> Unclassified
Classification Panel Radiology		

Indications (from labeling)  
VitreAAdvanced is a medical diagnostic system for the processing, review, analysis, communication and media interchange of multi-dimensional digital images acquired from a variety of imaging devices. VitreAAdvanced is not meant for primary image interpretation in mammography. It can be used with a variety of cleared VitreA® based software applications. In addition, VitreAAdvanced includes specific indications for VitreA® CT Body Perfusion, VitreA® CT Liver Analysis and VitreA® CT Brain Perfusion.  
Please see Indications for Use statement for complete indications.

Note: Submission of this information does not affect the need to submit a 2891 or 2891a Device Establishment Registration form.

FDA Document Number (if known)

**SECTION H MANUFACTURING / PACKAGING / STERILIZATION SITES RELATING TO A SUBMISSION**

<input checked="" type="checkbox"/> Original <input type="checkbox"/> Add <input type="checkbox"/> Delete		Facility Establishment Identifier (FEI) Number Not Applicable	<input checked="" type="checkbox"/> Manufacturer <input type="checkbox"/> Contract Sterilizer <input type="checkbox"/> Contract Manufacturer <input type="checkbox"/> Repackager / Relabeler	
Company / Institution Name Vital Images, Inc.		Establishment Registration Number 2134213		
Division Name (if applicable) Not Applicable		Phone Number (including area code) 952-487-9622		
Street Address 5850 Opus Parkway, Suite 300		FAX Number (including area code) 952-487-9510		
City Minnetonka		State / Province MN	ZIP Code 55343	Country USA
Contact Name Ian Nemerov		Contact Title Vice President, General Counsel and Secretary		Contact E-mail Address inemerov@vitalimages.com

<input type="checkbox"/> Original <input type="checkbox"/> Add <input type="checkbox"/> Delete		Facility Establishment Identifier (FEI) Number	<input type="checkbox"/> Manufacturer <input type="checkbox"/> Contract Sterilizer <input type="checkbox"/> Contract Manufacturer <input type="checkbox"/> Repackager / Relabeler	
Company / Institution Name		Establishment Registration Number		
Division Name (if applicable)		Phone Number (including area code)		
Street Address		FAX Number (including area code)		
City		State / Province	ZIP Code	Country
Contact Name		Contact Title		Contact E-mail Address

<input type="checkbox"/> Original <input type="checkbox"/> Add <input type="checkbox"/> Delete		Facility Establishment Identifier (FEI) Number	<input type="checkbox"/> Manufacturer <input type="checkbox"/> Contract Sterilizer <input type="checkbox"/> Contract Manufacturer <input type="checkbox"/> Repackager / Relabeler	
Company / Institution Name		Establishment Registration Number		
Division Name (if applicable)		Phone Number (including area code)		
Street Address		FAX Number (including area code)		
City		State / Province	ZIP Code	Country
Contact Name		Contact Title		Contact E-mail Address

**SECTION I UTILIZATION OF STANDARDS**

**Note:** Complete this section if your application or submission cites standards or includes a "Declaration of Conformity to a Recognized Standard" statement.

	Standards No.	Standards Organization	Standards Title	Version	Date
1	PS 3.1 - 3.18 (2009)  (Recognition Number: 12-218)	NEMA	Digital Imaging and Communications in Medicine (DICOM) Set	3.3	01/01/2008
2					
3					
4					
5					
6					
7					

Please include any additional standards to be cited on a separate page.

**Public reporting burden for this collection of information** is estimated to average 0.5 hour per response, including the time for reviewing instructions, searching existing data sources, gathering and maintaining the data needed, and completing reviewing the collection of information. Send comments regarding this burden estimate or any other aspect of this collection of information, including suggestions for reducing this burden to:

Department of Health and Human Services  
 Food and Drug Administration  
 Office of Chief Information Officer  
 1350 Piccard Drive, Room 400  
 Rockville, MD 20850

*An agency may not conduct or sponsor, and a person is not required to respond to, a collection of information unless it displays a currently valid OMB control number.*



### **3 510(k) Cover Letter**

Food and Drug Administration  
Center for Devices and Radiological Health  
Document Mail Center - WO66-G609  
10903 New Hampshire Avenue  
Silver Spring, Maryland 20993-0002

17 April 2012

Subject: **Traditional 510(k) Notification** for VitreaAdvanced

To Whom It May Concern:

In accordance with Section 510(k) of the Federal Food, Drug, and Cosmetic Act and in conformance with 21 C.F.R. 807, Vital Images, Inc. submits this 510(k) for VitreaAdvanced software.

Vital Images, Inc. intends to begin marketing this device. This submission is to obtain a determination that the VitreaAdvanced software package is substantially equivalent to the Vitrea<sup>®</sup>, Version 4.0 (K071331) platform with advanced applications for Computed Tomography (CT) Body Perfusion, CT Liver Analysis and CT Brain Perfusion. The advanced applications process the same CT studies and perform the same image review and analysis as previously cleared software applications, specifically:

- Vitrea<sup>®</sup> CT Body Perfusion is substantially equivalent to Toshiba America Medical Systems' CSBP-001A Body Perfusion System (K090504);
- Vitrea<sup>®</sup> CT Liver Analysis is substantially equivalent to MeVis LiverAnalyser / LiverViewer Software (K051528) and Median Technologies LMS-Liver (K071241), and;
- Vitrea<sup>®</sup> CT Brain Perfusion builds on Vital Images' previously cleared Vitrea<sup>®</sup> 4DCT (K072821) and performs the same intended uses as Siemens Medical Solutions' syngo<sup>®</sup> Volume Perfusion-CT Neuro (K073238).

This traditional 510(k) has been prepared in accordance with *Format for Traditional and Abbreviated 510(k)s* issued August 12, 2005, the *Guidance for the Content of Premarket Submissions for Software Contained in Medical Devices* issued May 11, 2005, and the *Guidance for the Submission Of Premarket Notifications for Medical Image Management Devices* issued July 27, 2000. An electronic copy is being provided with this submission and it is an exact duplicate of the original paper submission per the instructions accessed at <http://www.fda.gov/MedicalDevices/DeviceRegulationandGuidance/HowtoMarketYourDevice/PremarketSubmissions/ucm134508.htm>.

The following administrative information is provided as requested in the *Format for Traditional and Abbreviated 510(k)s* Appendix A:

Administrative Information

<b>510(k) Submission Type:</b>	Traditional
<b>Device Name:</b>	VitreaAdvanced
<b>Device Common Name:</b>	Picture Archiving and Communications System
<b>510(K) Submitter:</b>	Vital Images, Inc. 5850 Opus Parkway Suite 300 Minnetonka, MN-55343-4414 Establishment Registration Number: 2134213



**Contact Person:** Daniel T. Biank  
 Regulatory Affairs Manager  
 Phone: 952-487-9514  
 Fax: 952-487-9510  
 E-mail: dbiank@vitalimages.com

**Alternate Contact Person:** Ian Nemerov  
 Vice President, General Counsel and Secretary  
 Phone: 952-487-9622  
 Fax: 952-487-9510  
 E-mail: inemerov@vitalimages.com

**Confidentiality Preference:** Keep Confidential  
**Classification Regulation:** 21 CFR 892.2050  
**Classification:** Class II  
**Panel:** Radiology  
**Product Code:** LLZ  
**Prior Related FDA Correspondence:** None

Basis for Submission

This Traditional 510(k) is being submitted because this VitreaAdvanced package is a new device.

Design and Use of the Device

The following table provides the additional high-level information regarding the design and use of the device:

Question	YES	NO
Is the device intended for prescription use (21 CFR 801 Subpart D)?	X	
Is the device intended for over-the-counter use (21 CFR 807 Subpart C)?		X
Does the device contain components derived from a tissue or other biologic source?		X
Is the device provided sterile?		X
Is the device intended for single use?		X
Is the device a reprocessed single use device?		X
If yes, does this device type require reprocessed validation data?		X
Does the device contain a drug?		X
Does the device contain a biologic?		X
Does the device use software?	X	
Does the submission include clinical information?		X
Is the device implanted?		X

Vital Images, Inc. regards both the content and the existence of this 510(k) submission as confidential commercial information and requests that it be treated as such by the FDA.

Thank you for your attention to this matter. I look forward to an interactive and collaborative review process. Please contact me with any question regarding this submission or for further information at (952) 487-9514 or via email dbiank@vitalimages.com

Sincerely,

Daniel Biank  
 Regulatory Affairs Manager

## **4 Indications for Use Statement**

## Indications for Use Form

510(k) Number (if known): \_\_\_\_\_

Device Name: VitreAdvanced

### Indications for Use:

VitreAdvanced is a medical diagnostic system for the processing, review, analysis, communication and media interchange of multi-dimensional digital images acquired from a variety of imaging devices. VitreAdvanced is not meant for primary image interpretation in mammography. It can be used with a variety of cleared Vitrea<sup>®</sup> based software applications. In addition, VitreAdvanced includes the following indications:

**Vitre<sup>®</sup> CT Body Perfusion** is a noninvasive post-processing application designed to evaluate perfusion of organs and tumors. The software can calculate perfusion characteristics from dynamic CT image data acquired after the injection of contrast media. The software also allows the separate calculation of the arterial and venous components of perfusion in organs (e.g., liver, lung and kidney). It supports evaluation of regions of interest and the visual inspection of time density curves. When used by a trained and qualified physician a potential application is to differentiate blood flow between normal and diseased tissue. Determination of the change of perfusion parameters during the course of treatment may be helpful in therapy monitoring.

**Vitre<sup>®</sup> CT Liver Analysis** is a noninvasive post-processing application designed to evaluate liver tumors and plan for liver surgery. It displays images for analysis and preoperative liver surgery planning, such as organ segmentation, tumor segmentation and intrahepatic vessels segmentation, as well as the approximation of vascular territories. It supports preoperative evaluation of specific surgery strategies by allowing the user to interactively define virtual resections splitting the liver. It also allows the user to evaluate safety-margins around lesions and to identify affected vascular branches and territories. Vitrea<sup>®</sup> CT Liver Analysis also provides automatic registration of multiple series and measurement tools for characterization and follow-up of the lesions. When used by a trained and qualified physician a potential application is to assist in the assessment of tumor response to therapy.

**Vitre<sup>®</sup> CT Brain Perfusion** is a noninvasive post-processing application designed to evaluate areas of brain perfusion. The software can calculate cerebral blood flow (CBF), cerebral blood volume (CBV), local bolus timing (i.e., delay of tissue response, time to peak), and mean transit time (MTT) from dynamic CT image data acquired after the injection of contrast media. The package also allows the calculation of regions of interest and mirrored regions, as well as the visual inspection of time density curves. Vitrea<sup>®</sup> CT Brain Perfusion supports the physician in visualizing the apparent blood perfusion in brain tissue affected by acute stroke. Areas of decreased perfusion, as is observed in acute cerebral infarcts, appear as areas of changed signal intensity (lower for both CBF and CBV and higher for time to peak and MTT).

Prescription Use   X    
(Part 21 CFR 801 Subpart D)

AND/OR

Over-The-Counter Use \_\_\_\_\_  
(21 CFR 801 Subpart C)

(PLEASE DO NOT WRITE BELOW THIS LINE-CONTINUE ON ANOTHER PAGE OF NEEDED)

---

Concurrence of CDRH, Office of In Vitro Diagnostic Devices (OIVD)

---

Division Sign-Off  
Office of In Vitro Diagnostic Device  
Evaluation and Safety

510(k)\_\_\_\_\_

Page 1 of \_\_\_\_

## **5 510(k) Summary**

## 510(k) Summary

This 510(k) summary is submitted in accordance with the requirements of 21 C.F.R. Part 807.92.

**Submitter:** Vital Images, Inc.  
5850 Opus Parkway  
Suite 300  
Minnetonka, MN 55343-4414

**Contact Person:** Daniel T. Biank, JD, MEng, PE, RAC  
Regulatory Affairs Manager

**Telephone:** 952 – 487 – 9514

**Fax:** 952 – 487 – 9510

**Email:** dbiank@vitalimages.com

**Date Prepared:** 17 April 2012

### Device Name

**Trade Name:** VitreaAdvanced  
**Common Name:** Picture Archiving and Communications System  
**Classification Name:** System, Image Processing, Radiological (21 C.F.R. 892.2050, LLZ)

### Predicate Devices:

- Vital Images, Inc., Vitrea<sup>®</sup>, Version 4.0 Medical Image Processing Software (K071331)
- Vital Images, Inc., Vitrea<sup>®</sup> 4DCT Medical Image Processing Software (K072821)
- Toshiba America Medical Systems, Inc., CSBP-001A Body Perfusion System (K090504)
- MeVis - Center for Medical Diagnostic Systems and Visualization GmbH, MeVis LiverAnalyser / LiverViewer Software<sup>™</sup> (K051528)
- Median Technologies, LMS-Liver (K071241)
- Siemens Medical Solutions, Inc., syngo<sup>®</sup> Volume Perfusion-CT Neuro (K073238)

### Device Description:

VitreaAdvanced is a package of noninvasive post-processing software applications for the Vitrea<sup>®</sup> software platform. The system is a software-only medical device to be installed on common IT hardware. VitreaAdvanced leverages existing Vitrea<sup>®</sup> functionality for the processing, review, analysis, communication, and media interchange of multi-dimensional digital images acquired from a variety of imaging devices. It provides multi-dimensional visualization of digital images to aid medical professionals in their analysis of anatomy and pathology. VitreaAdvanced can be used with a variety of cleared Vitrea<sup>®</sup> based software applications. VitreaAdvanced uses the Vitrea<sup>®</sup> system user interface to follow typical clinical workflow patterns and process, review, and analyze digital images, including:

- Receive DICOM image data from a variety of sources
- Display images using dedicated protocols adapted to exam types
- Select images for closer examination from collection of 2D, 3D or 4D views
- Interactively manipulate an image in real-time to visualize anatomy and pathology
- Annotate, tag, measure, and record selected views
- Output selected views to compatible devices and publishing tools (e.g. printers, DICOM devices, etc.)

In addition, VitreaAdvanced includes three Vitrea<sup>®</sup> applications:



**Vitreá® CT Body Perfusion** is noninvasive post-processing software that calculates perfusion characteristics from dynamic CT image data. It displays blood flow parametric maps for single-input and dual-input workflows.

**Vitreá® CT Liver Analysis** is noninvasive post-processing software that displays CT image data. It processes image data to segment liver structures and evaluate resection surfaces as well as volumes. Vitreá® CT Liver Analysis provides automatic registration and composite views of multiple series, optimized screen layouts and measurement tools. It also generates standardized reports for WHO and RECIST protocols and for percentage change tumor response values.

**Vitreá® CT Brain Perfusion** is noninvasive post-processing software that calculates cerebral blood flow (CBF), cerebral blood volume (CBV), local bolus timing (i.e., delay of tissue response, time to peak), and mean transit time (MTT) from dynamic CT image data. It displays time density curves, perfusion characteristics in parametric and summary maps, as well as regions of interest and mirrored regions.

#### **Intended Use:**

VitreáAdvanced is a medical diagnostic system for the processing, review, analysis, communication and media interchange of multi-dimensional digital images acquired from a variety of imaging devices. VitreáAdvanced is not meant for primary image interpretation in mammography. It can be used with a variety of cleared Vitreá® based software applications. In addition, VitreáAdvanced includes the following indications:

**Vitreá® CT Body Perfusion** is a noninvasive post-processing application designed to evaluate perfusion of organs and tumors. The software can calculate perfusion characteristics from dynamic CT image data acquired after the injection of contrast media. The software also allows the separate calculation of the arterial and venous components of perfusion in organs (e.g., liver, lung and kidney). It supports evaluation of regions of interest and the visual inspection of time density curves. When used by a trained and qualified physician a potential application is to differentiate blood flow between normal and diseased tissue. Determination of the change of perfusion parameters during the course of treatment may be helpful in therapy monitoring.

**Vitreá® CT Liver Analysis** is a noninvasive post-processing application designed to evaluate liver tumors and plan for liver surgery. It displays images for analysis and preoperative liver surgery planning, such as organ segmentation, tumor segmentation and intrahepatic vessels segmentation, as well as the approximation of vascular territories. It supports preoperative evaluation of specific surgery strategies by allowing the user to interactively define virtual resections splitting the liver. It also allows the user to evaluate safety-margins around lesions and to identify affected vascular branches and territories. Vitreá® CT Liver Analysis also provides automatic registration of multiple series and measurement tools for characterization and follow-up of the lesions. When used by a trained and qualified physician a potential application is to assist in the assessment of tumor response to therapy.

**Vitreá® CT Brain Perfusion** is a noninvasive post-processing application designed to evaluate areas of brain perfusion. The software can calculate cerebral blood flow (CBF), cerebral blood volume (CBV), local bolus timing (i.e., delay of tissue response, time to peak), and mean transit time (MTT) from dynamic CT image data acquired after the injection of contrast media. The package also allows the calculation of regions of interest and mirrored regions, as well as the visual inspection of time density curves. Vitreá® CT Brain Perfusion supports the physician in visualizing the apparent blood perfusion in brain tissue affected by acute stroke. Areas of decreased perfusion, as is observed in acute cerebral infarcts, appear as areas of changed signal intensity (lower for both CBF and CBV and higher for time to peak and MTT).

**Comparison with Predicate Devices:**

VitreAAdvanced is a package of noninvasive post-processing software applications for the Vitrea® software platform. It leverages the basic functionality and technology of the existing 510(k) cleared Vitrea® software platform. VitreaAdvanced includes advance applications that extend the functionality of the platform for specific uses. The specific uses are substantially equivalent to the cleared uses of existing post-processing software applications available on other platforms. Also, the software applications use similar technology as existing post-processing software applications.

VitreA® CT Body Perfusion (Submission Subject)	Description	Toshiba CSBP-001A Body Perfusion System (K090504)	Explanation of Differences
Analysis Model	Maximum slope (Fick principal)	Includes	The subject and predicate both implement Maximum-slope. The predicate implements additional models: Compartment model and Patlak Plot.
Parameters	Blood flow	Includes	The subject and predicate both display blood flow parameters. The predicate includes additional parameters: Blood volume, MTT, HAF(PI), equivalent blood volume using the additional analysis models.
Functions	Single input, dual input, map display and ROI measurement	Same	None

VitreA® CT Liver Analysis (Submission Subject)	Description	MeVis LiverAnalyser / LiverViewer Software (K051528)	Median LMS-Liver (K071241)	Explanation of Differences
Analysis Model	Rigid and deformable registration, Segmentation and region growing	Same	Same	None
Parameters	Basic measurements, volume, resection plane, RECIST, WHO and comparisons	Partial (volumes, resection planes and comparisons)	Partial (RECIST, WHO and comparisons)	MeVis provides basic measurements for volumes, resection planes and comparisons. LMS-Liver provides RECIST and WHO measurements and comparison.
Functions	Segment: organs, tumors and intrahepatic vessels, Resection planning tool (defines vascular territories), multi-phase fusion and standardized reports	Partial (segmentation, resection planning and multi-phase fusion)	Partial (standardized reports)	MeVis provides segmentation, resection planning and multi-phase fusion. LMS-Liver provides standardized reports.

## Vital Images

VitreaAdvanced  
510(k) Pre-market Notification

Vitrea® CT Brain Perfusion (Submission Subject)	Description	Vitrea® 4DCT (K072821)	Siemens syngo® Volume Perfusion-CT Neuro (K073238)	Explanation of Differences
Analysis Model	Deconvolution	Same	Includes	syngo® Volume Perfusion-CT Neuro uses both deconvolution and maximum slope
Parameters	Cerebral blood flow (CBF), cerebral blood volume (CBV), local bolus timing (i.e., delay of tissue response, time to peak), and mean transit time (MTT)	Same	Includes	syngo® Volume Perfusion-CT Neuro has all the parameters and vascular permeability
Functions	Display regions of interest, mirrored regions, time density curves and perfusion characteristics in parametric and summary maps	Partial	Same	4DCT does not include summary maps (maps that combine parameters). syngo® Volume Perfusion-CT Neuro includes maps that combine parameters.

**Summary of Studies:**

The software was designed, developed, and tested according to written procedures and applying risk management. Testing included verification, validation, and evaluating previously acquired diagnostic images. Software testing confirmed that the feature functions according to its requirements without impacting existing functionality. Validation found that users can operate the software and successfully perform the desired function. The software is designed to meet NEMA PS 3.1 - 3.18 Digital Imaging and Communications in Medicine (DICOM).

Testing supports a determination of substantial equivalence.

**Conclusion:**

VitreaAdvanced is substantially equivalent to Vital Images' currently cleared and marketed Vitrea®, Version 4.0 (K071331) with a package of advanced applications substantially equivalent to currently cleared and marketed software applications:

- Vitrea® CT Body Perfusion is substantially equivalent to Toshiba America Medical Systems' CSBP-001A Body Perfusion System (K090504);
- Vitrea® CT Liver Analysis is substantially equivalent to MeVis LiverAnalyser / LiverViewer Software (K051528) and Median Technologies LMS-Liver (K071241), and;
- Vitrea® CT Brain Perfusion builds on Vital Images' previously cleared Vitrea® 4DCT (K072821) and performs the same intended uses as Siemens Medical Solutions' syngo® Volume Perfusion-CT Neuro (K073238).

The included studies support that VitreaAdvanced is substantially equivalent to existing and cleared post-processing software devices.

## **6 Truthful and Accuracy Statement**

**Premarket Notification Truthful and Accurate Statement**  
[As Required by 21 CFR 807.87(k)]

I certify that, in my capacity as Regulatory Affairs Manager of Vital Images, Inc., I believe to the best of my knowledge, that all data and information submitted in the premarket notification are truthful and accurate and that no material fact has been omitted.

Daniel Biank  
(Signature)

Daniel Biank  
(Typed Name)

18 APR 2012  
(Date)

\_\_\_\_\_  
\*(Premarket Notification [510(k)] Number)

\*For a new submission, leave the 510(k) number blank.

## 7 Class III Summary and Certification

**NOT APPLICABLE**

The subject of this 510(k) submission is not a Class III device. Therefore, this section does not apply.

## 8 Financial Certification or Disclosure Statement

**NOT APPLICABLE**

No clinical studies were conducted to support this 510(k) submission. Therefore, this section does not apply.

## 9 Declarations of Conformity and Summary Reports

**NOT APPLICABLE**

This is a Traditional 510(k) submission and not an Abbreviated submission. Therefore, this section does not apply.



## **10 Executive Summary**

## Executive Summary

### 10.1 Concise Device Description

VitreaAdvanced is a package of noninvasive post-processing software applications for the Vitrea<sup>®</sup> software platform. The system is a software-only medical device to be installed on common IT hardware. VitreaAdvanced leverages existing Vitrea<sup>®</sup> functionality for the processing, review, analysis, communication, and media interchange of multi-dimensional digital images acquired from a variety of imaging devices. It provides multi-dimensional visualization of digital images to aid medical professionals in their analysis of anatomy and pathology. VitreaAdvanced can be used with a variety of cleared Vitrea<sup>®</sup> based software applications. VitreaAdvanced uses the Vitrea<sup>®</sup> system user interface to follow typical clinical workflow patterns and process, review, and analyze digital images, including:

- Receive DICOM image data from a variety of sources
- Display images using dedicated protocols adapted to exam types
- Select images for closer examination from collection of 2D, 3D or 4D views
- Interactively manipulate an image in real-time to visualize anatomy and pathology
- Annotate, tag, measure, and record selected views
- Output selected views to compatible devices and publishing tools (e.g. printers, DICOM devices, etc.)

In addition, VitreaAdvanced includes three Vitrea<sup>®</sup> applications:

**Vitrea<sup>®</sup> CT Body Perfusion** is noninvasive post-processing software that calculates perfusion characteristics from dynamic CT image data. It displays blood flow parametric maps for single-input and dual-input workflows.

**Vitrea<sup>®</sup> CT Liver Analysis** is noninvasive post-processing software that displays CT image data. It processes image data to segment liver structures and evaluate resection surfaces as well as volumes. Vitrea<sup>®</sup> CT Liver Analysis provides automatic registration and composite views of multiple series, optimized screen layouts and measurement tools. It also generates standardized reports for WHO and RECIST protocols and for percentage change tumor response values.

**Vitrea<sup>®</sup> CT Brain Perfusion** is noninvasive post-processing software that calculates cerebral blood flow (CBF), cerebral blood volume (CBV), local bolus timing (i.e., delay of tissue response, time to peak), and mean transit time (MTT) from dynamic CT image data. It displays time density curves, perfusion characteristics in parametric and summary maps, as well as regions of interest and mirrored regions.

### 10.2 Device Comparison Table

VitreaAdvanced is a package of noninvasive post-processing software applications for the Vitrea<sup>®</sup> software platform. It leverages the basic functionality and technology of the existing 510(k) cleared Vitrea<sup>®</sup> software platform. VitreaAdvanced includes advance applications that extend the functionality of the platform for specific uses. The specific uses are substantially equivalent to the cleared uses of existing post-processing software applications available on other platforms. Also, the software applications use similar technology as existing post-processing software applications.

# Vital Images

VitreAdvanced  
510(k) Pre-market Notification

Vitre <sup>®</sup> CT Body Perfusion (Submission Subject)	Description	Toshiba CSBP-001A Body Perfusion System (K090504)	Explanation of Differences
Analysis Model	Maximum slope (Fick principal)	Includes	The subject and predicate both implement Maximum-slope. The predicate implements additional models: Compartment model and Patlak Plot.
Parameters	Blood flow	Includes	The subject and predicate both display blood flow parameters. The predicate includes additional parameters: Blood volume, MTT, HAF(PI), equivalent blood volume using the additional analysis models.
Functions	Single input, dual input, map display and ROI measurement	Same	None

Vitre <sup>®</sup> CT Liver Analysis (Submission Subject)	Description	MeVis LiverAnalyser / LiverViewer Software (K051528)	Median LMS-Liver (K071241)	Explanation of Differences
Analysis Model	Rigid and deformable registration, Segmentation and region growing	Same	Same	None
Parameters	Basic measurements, volume, resection plane, RECIST, WHO and comparisons	Partial (volumes, resection planes and comparisons)	Partial (RECIST, WHO and comparisons)	MeVis provides basic measurements for volumes, resection planes and comparisons. LMS-Liver provides RECIST and WHO measurements and comparison.
Functions	Segment: organs, tumors and intrahepatic vessels, Resection planning tool (defines vascular territories), multi-phase fusion and standardized reports	Partial (segmentation, resection planning and multi-phase fusion)	Partial (standardized reports)	MeVis provides segmentation, resection planning and multi-phase fusion. LMS-Liver provides standardized reports.

Vitrea <sup>®</sup> CT Brain Perfusion (Submission Subject)	Description	Vitrea <sup>®</sup> 4DCT (K072821)	Siemens syngo <sup>®</sup> Volume Perfusion- CT Neuro (K073238)	Explanation of Differences
Analysis Model	Deconvolution	Same	Includes	syngo <sup>®</sup> Volume Perfusion-CT Neuro uses both deconvolution and maximum slope
Parameters	Cerebral blood flow (CBF), cerebral blood volume (CBV), local bolus timing (i.e., delay of tissue response, time to peak), and mean transit time (MTT)	Same	Includes	syngo <sup>®</sup> Volume Perfusion-CT Neuro has all the parameters and vascular permeability
Functions	Display regions of interest, mirrored regions, time density curves and perfusion characteristics in parametric and summary maps	Partial	Same	4DCT does not include summary maps (maps that combine parameters). syngo <sup>®</sup> Volume Perfusion-CT Neuro includes maps that combine parameters.

### 10.3 Summary of Performance Testing

The software was designed, developed, and tested according to written procedures and applying risk management. Performance testing for VitreaAdvanced included verification, validation, and evaluation. Validation included evaluating previously acquired CT images. Verification confirmed that the feature functions according to its requirements without impacting existing functionality. Validation found that users could operate the software and successfully visualize anatomy and pathology and perform the specific functions related to CT Body Perfusion, CT Liver Analysis and CT Brain Perfusion.

Verification and validation testing has been performed and is documented in Section 18 *Performance Testing – Bench*. No animal or clinical data was necessary to demonstrate substantial equivalence for this submission. Therefore, testing was not performed for Section 19 *Performance Testing – Animal* and Section 20 *Performance Testing – Clinical Bench*.

The testing supports a determination of substantial equivalence.

## 11 Device Description

## Device Description

### 11.1 Scope and Device Description

VitreaAdvanced is a package of noninvasive post-processing software applications for the Vitrea<sup>®</sup> software platform. The system is a software-only medical device to be installed on common IT hardware. VitreaAdvanced leverages existing Vitrea<sup>®</sup> functionality for the processing, review, analysis, communication, and media interchange of multi-dimensional digital images acquired from a variety of imaging devices. It provides multi-dimensional visualization of digital images to aid medical professionals in their analysis of anatomy and pathology. VitreaAdvanced can be used with a variety of cleared Vitrea<sup>®</sup> based software applications. VitreaAdvanced uses the Vitrea<sup>®</sup> system user interface to follow typical clinical workflow patterns and process, review, and analyze digital images, including:

- Receive DICOM image data from a variety of sources
- Display images using dedicated protocols adapted to exam types
- Select images for closer examination from collection of 2D, 3D or 4D views
- Interactively manipulate an image in real-time to visualize anatomy and pathology
- Annotate, tag, measure, and record selected views
- Output selected views to compatible devices and publishing tools (e.g. printers, DICOM devices, etc.)

In addition, VitreaAdvanced includes three Vitrea<sup>®</sup> applications:

**Vitrea<sup>®</sup> CT Body Perfusion** is noninvasive post-processing software that calculates perfusion characteristics from dynamic CT image data. It displays blood flow parametric maps for single-input and dual-input workflows.

**Vitrea<sup>®</sup> CT Liver Analysis** is noninvasive post-processing software that displays CT image data. It processes image data to segment liver structures and evaluate resection surfaces as well as volumes. Vitrea<sup>®</sup> CT Liver Analysis provides automatic registration and composite views of multiple series, optimized screen layouts and measurement tools. It also generates standardized reports for WHO and RECIST protocols and for percentage change tumor response values.

**Vitrea<sup>®</sup> CT Brain Perfusion** is noninvasive post-processing software that calculates cerebral blood flow (CBF), cerebral blood volume (CBV), local bolus timing (i.e., delay of tissue response, time to peak), and mean transit time (MTT) from dynamic CT image data. It displays time density curves, perfusion characteristics in parametric and summary maps, as well as regions of interest and mirrored regions.

### 11.2 Performance Specifications

There are no new performance requirements specific to VitreaAdvanced or the three applications Vitrea<sup>®</sup> CT Body Perfusion, Vitrea<sup>®</sup> CT Liver Analysis, and Vitrea<sup>®</sup> CT Brain Perfusion. Performance requirements remain the same as Vitrea<sup>®</sup>.

### 11.3 Brief Description of Design Requirements

VitreaAdvanced is a package of noninvasive post-processing software applications for the Vitrea<sup>®</sup> software platform. VitreaAdvanced leverages existing Vitrea<sup>®</sup> functionality for the processing, review, analysis, communication, and media interchange of multi-dimensional digital images acquired from a variety of imaging devices. It provides multi-dimensional visualization of digital images to aid medical professionals in their analysis of anatomy and pathology. VitreaAdvanced can be used with a variety

of cleared Vitrea<sup>®</sup> based software applications. VitreaAdvanced includes three new Vitrea<sup>®</sup> applications with high-level design requirements can be summarized as follows:

**VitreAdvanced<sup>®</sup> CT Body Perfusion**

- Provide adjustable perfusion parameter overlays.
- Provide single-input and dual-input color maps, layouts, and 3D displays.
- Provide deformable registration and automatically correct for motion.
- Provide user graphs of time density curves

**VitreAdvanced<sup>®</sup> CT Liver Analysis**

- Provide segmentation tools for liver and vasculature.
- Provide users the ability to segment and measure liver tumors and manage findings.
- Provide a single fused view of the liver, vessels and tumor(s).
- Provide user workflows for resection planning.

**VitreAdvanced<sup>®</sup> CT Brain Perfusion**

- Provide perfusion parameters.
- Provide summary maps of perfusion parameters.
- Provide motion correction.
- Provide user selection of vasculature (vein and artery).
- Allow users to define the brain midline and mirror regions of interest.
- Provide user graphs of time density curves.

## **11.4 Components and Accessories**

VitreAdvanced can be used with a variety of cleared Vitrea<sup>®</sup> based software applications. Also, VitreaAdvanced may include the following applications: Vitrea<sup>®</sup> CT Body Perfusion, Vitrea<sup>®</sup> CT Liver Analysis and Vitrea<sup>®</sup> CT Brain Perfusion.

## **11.5 Patient Contacting Surfaces**

VitreAdvanced is a software application and has no patient contacting surfaces.

## **12 Substantial Equivalence Discussion**



## Substantial Equivalence

### 12.1 Predicates

VitreaAdvanced is a package of noninvasive post-processing software applications for the Vitrea® software platform. It includes advance applications that extend the functionality of the existing software platform for specific uses similar to other post-processing software packages. The VitreaAdvanced functionality is substantially equivalent to the following software devices:

Function	510(k) Number	Predicate Trade Name	Manufacturer
Advanced image post-processing	K071331	Vitrea®, Version 4.0	Vital Images, Inc.,
Vitrea® CT Body Perfusion	K090504	CSBP-001A Body Perfusion System	Toshiba America Medical Systems, Inc
Vitrea® CT Liver Analysis	K051528	MeVis LiverAnalyser / LiverViewer Software	MeVis - Center for Medical Diagnostic Systems and Visualization GmbH
	K071241	LMS-Liver	MEDIAN Technologies
Vitrea® CT Brain Perfusion	K072821	Vitrea® 4DCT	Vital Images, Inc
	K073238	syngo® Volume Perfusion-CT Neuro	Siemens Medical Solutions, Inc.

The following attachments describe the predicates:

- 12.1 Vital Images Vitrea®, Version 4.0, K071331 510(k) Summary
- 12.2 Vital Images Vitrea® 4DCT, K072821 510(k) Summary
- 12.3 Toshiba CSBP-001A Body Perfusion System, K090504 510(k) Summary
- 12.4 Toshiba CSBP-001A Body Perfusion System, Draft Labeling
- 12.5 MeVis LiverAnalyser / LiverViewer Software, K051528 510(k) Summary
- 12.6 MEDIAN Technologies LMS-Liver, K071241 510(k) Summary
- 12.7 Siemens syngo® Volume Perfusion-CT Neuro, K073238 510(k) Summary
- 12.8 Morhard, Vasospasm after SAH: Neuro Volume Perfusion CT, SOMATOM Sessions-Siemens Healthcare Magazine (May 2008)
- 12.9 Wintermark, Prognostic Accuracy of Cerebral Blood Flow Measurement by Perfusion Computed Tomography, Annals of Neurology (2002)

VitreaAdvanced is a package of noninvasive post-processing software applications for the Vitrea® software platform. It leverages the basic functionality and technology of the existing 510(k) cleared Vitrea® software platform. VitreaAdvanced includes advance applications that extend the functionality of the platform for specific uses. The specific uses are substantially equivalent to the cleared uses of existing post-processing software applications available on other platforms. Also, the software applications use similar technology as existing post-processing software applications. For clarity, the individual advanced applications are separately compared with the relevant predicates in the following sections.

### 12.2 Advanced Image Post-Processing

#### 12.2.1 Regulatory Comparison

Characteristic	VitreaAdvanced (Submission Subject)	Vitrea®, Version 4.0 (K071331)	Explanation of Differences
----------------	--	-----------------------------------	----------------------------

## Vital Images

VitreAdvanced  
510(k) Pre-market Notification

Characteristic	VitreAdvanced (Submission Subject)	Vitre <sup>®</sup> , Version 4.0 (K071331)	Explanation of Differences
Classification Name	System, Image Processing, Radiological	System, Image Processing, Radiological	Same
Regulatory Number	892.2050	892.2050	Same
Product Code	LLZ	LLZ	Same
Classification	Class II	Class II	Same
Committee	Radiology	Radiology	Same
Decision Date	Under Review	May 25, 2007	Predicate cleared earlier

**12.2.2 Indications for Use**

Feature	Indications for Use (Advanced Image Post-Processing Portion)
VitreAdvanced (Submission Subject)	VitreAdvanced is a medical diagnostic system for the processing, review, analysis, communication and media interchange of multi-dimensional digital images acquired from a variety of imaging devices. VitreAdvanced is not meant for primary image interpretation in mammography. It can be used with a variety of cleared Vitre <sup>®</sup> based software applications.
Vitre <sup>®</sup> , Version 4.0 (K071331)	Vitre <sup>®</sup> is a medical diagnostic system that allows the processing, review, analysis, communication and media interchange of multi-dimensional digital images acquired from a variety of imaging devices. Vitre <sup>®</sup> is not meant for primary Image Interpretation in mammography.

**12.2.3 Device Description**

Feature	Device Description (Advanced Image Post-Processing Portion)
VitreAdvanced (Submission Subject)	VitreAdvanced is a package of noninvasive post-processing software applications for the Vitre <sup>®</sup> software platform. The system is a software only medical device to be installed on common IT hardware. VitreAdvanced leverages existing Vitre <sup>®</sup> functionality for the processing, review, analysis, communication, and media interchange of multi-dimensional digital images acquired from a variety of imaging devices. It provides multi-dimensional visualization of digital images to aid medical professionals in their analysis of anatomy and pathology. VitreAdvanced can be used with a variety of cleared Vitre <sup>®</sup> based software applications. VitreAdvanced uses the Vitre <sup>®</sup> system user interface to follow typical clinical workflow patterns and process, review, and analyze digital images, including: <ul style="list-style-type: none"> <li>▪ Receive DICOM image data from a variety of sources</li> <li>▪ Display images using dedicated protocols adapted to exam types</li> <li>▪ Select images for closer examination from collection</li> </ul>

Feature	Device Description (Advanced Image Post-Processing Portion)
	of 2D, 3D or 4D views <ul style="list-style-type: none"> <li>▪ Interactively manipulate an image in real-time to visualize anatomy and pathology</li> <li>▪ Annotate, tag, measure, and record selected views</li> <li>▪ Output selected views to compatible devices and publishing tools (e.g. printers, DICOM devices, etc.)</li> </ul>
Vitre <sup>®</sup> , Version 4.0 (K071331)	<p>The Vitre<sup>®</sup> system is a medical diagnostic device that allows the processing, review, analysis, communication, and media interchange of multi-dimensional digital images acquired from a variety of imaging devices.</p> <p>The Vitre<sup>®</sup> system provides multi-dimensional visualization of digital images to aid clinicians in their analysis of anatomy and pathology. The Vitre<sup>®</sup> system user interface follows typical clinical workflow patterns to process, review, and analyze digital images, including:</p> <ul style="list-style-type: none"> <li>• Retrieve image data over the network via DICOM</li> <li>• Display images that are automatically adapted to exam type via dedicated protocols</li> <li>• Select images for closer examination from a gallery of up to six 2D or 3D views</li> <li>• Interactively manipulate an image in real-time to visualize anatomy and pathology</li> <li>• Annotate, tag, measure, and record selected views</li> <li>• Output selected views to standard film or paper printers, or post a report to an intranet Web server or export views to another DICOM device</li> <li>• Retrieve reports that are archived on a Web server</li> </ul>

#### 12.2.4 Indications and Technology Comparison

VitreAdvanced and Vitre<sup>®</sup> are essentially the same for advanced image processing. The Indications for Use are basically identical with a minor clarification that VitreAdvanced can be used with other cleared Vitre<sup>®</sup> application. The device description is the same with minor edits to simplify and improve clarity. VitreAdvanced is built on the Vitre<sup>®</sup> software. The distinctions in features and functionality are addressed in the individual advanced application sections.

### 12.3 Vitre<sup>®</sup> CT Body Perfusion

#### 12.3.1 Regulatory Comparison

Characteristic	Vitre <sup>®</sup> CT Body Perfusion (Submission Subject)	Toshiba CSBP-001A Body Perfusion System (K090504)	Explanation of Differences
Classification Name	System, Image Processing, Radiological	System, X-ray, Tomography, Computed	Difference explained below.
Regulatory Number	892.2050	892.1750	Difference explained below.
Product Code	LLZ	JAK	Difference

Characteristic	Vitrea <sup>®</sup> CT Body Perfusion (Submission Subject)	Toshiba CSBP-001A Body Perfusion System (K090504)	Explanation of Differences
			explained below.
Classification	Class II	Class II	Same
Committee	Radiology	Radiology	Same
Decision Date	Under Review	March 5, 2009	Predicates cleared earlier

CSBP-001A Body Perfusion System (K090504) uses the JAK product code as accessories to System, X-ray, Tomography, Computed. The VitreaAdvanced submission uses the LLZ product code for System, Image Processing, Radiological. VitreaAdvanced and CSBP-001A Body Perfusion System are both image post-processing software for CT. CSBP-001A Body Perfusion System may be used with a CT scanner or separate computer systems, similar to VitreaAdvanced's Vitrea<sup>®</sup> CT Body Perfusion.

The *Guidance for the Submission of Premarket Notifications for Medical Image Management Devices* issued on July 27, 2000 states:

“In order to apply uniform requirements to all types of medical image management devices, devices designated for use with a single modality are no longer treated as accessories to that modality. They are considered to be medical image management devices and subject to the applicable requirements and exemptions.”

Vitrea<sup>®</sup> CT Body Perfusion post-processes software for CT images. The Guidance states to consider this type of device as a medical image management device. Medical image management devices includes devices classified under 21 C.F.R. §892.2050 for Picture archiving and communications system. The LLZ product code is defined under 21 C.F.R. §892.2050. Therefore, the LLZ code was selected for VitreaAdvanced based on the applicable Guidance. The difference in product codes does not reflect a difference in indications for use or technology.

### 12.3.2 Indications for Use

Feature	Indications for Use
Vitrea <sup>®</sup> CT Body Perfusion (Submission Subject)	Vitrea <sup>®</sup> CT Body Perfusion is a noninvasive post-processing application designed to evaluate perfusion of organs and tumors. The software can calculate perfusion characteristics from dynamic CT image data acquired after the injection of contrast media. The software also allows the separate calculation of the arterial and venous components of perfusion in organs (e.g., liver, lung and kidney). It supports evaluation of regions of interest and the visual inspection of time density curves. When used by a trained and qualified physician a potential application is to differentiate blood flow between normal and diseased tissue. Determination of the change of perfusion parameters during the course of treatment may be helpful in therapy monitoring.
CSBP-001A Body Perfusion System (K090504)	The CSBP-001A Body Perfusion System software package is a noninvasive post-processing package that has been designed to evaluate perfusion of organs and tumors. The software can calculate blood flow, blood volume and permeability from sets of images reconstructed from dynamic

# Vital Images

Feature	Indications for Use
	<p>CT data acquired after the injection of contrast media. The software also allows the separate calculation of the arterial and portal venous component of hepatic perfusion. It supports evaluation of regions of interest and the visual inspection of time density curves.</p> <p>When used by a qualified physician a potential application is to differentiate blood flow between normal and diseased tissue. Determination of the change of perfusion parameters during the course of treatment may be helpful in therapy monitoring.</p> <p>It should be used by a trained and qualified physician.</p>

### 12.3.3 Device Description

Feature	Device Description
Vitre <sup>®</sup> CT Body Perfusion (Submission Subject)	Vitre <sup>®</sup> CT Body Perfusion is noninvasive post-processing software that calculates perfusion characteristics from dynamic CT image data. It displays blood flow parametric maps for single-input and dual-input workflows.
CSBP-001A Body Perfusion System (K090504)	The CSBP-001A is a noninvasive post-processing software that runs on a PC based console of the host CT device. It has been designed to assess dynamic (time lapsed collections) CT volume scans and provide data related to the volume sets.

### 12.3.4 Indications and Technology Comparison

Vitre <sup>®</sup> CT Body Perfusion (Submission Subject)	Description	Toshiba CSBP-001A Body Perfusion System (K090504)	Explanation of Differences
Analysis Model	Maximum slope (Fick principal)	Includes	The subject and predicate both implement Maximum-slope. The predicate implements additional models: Compartment model and Patlak Plot.
Parameters	Blood flow	Includes	The subject and predicate both display blood flow parameters. The predicate includes additional parameters: Blood volume, MTT, HAF(PI), equivalent blood volume using the additional analysis models.
Functions	Single input, dual input, map display and ROI measurement	Same	None

**12.4 Vitrea<sup>®</sup> CT Liver Analysis****12.4.1 Regulatory Comparison**

Characteristic	Vitrea <sup>®</sup> CT Liver Analysis (Submission Subject)	MeVis LiverAnalyser / LiverViewer Software (K051528)	Median LMS-Liver (K071241)	Explanation of Differences
Classification Name	System, Image Processing, Radiological	System, Image Processing, Radiological	System, Image Processing, Radiological	Same
Regulatory Number	892.2050	892.2050	892.2050	Same
Product Code	LLZ	LLZ	LLZ	Same
Classification	Class II	Class II	Class II	Same
Committee	Radiology	Radiology	Radiology	Same
Decision Date	Under Review	July 20, 2005	June 8, 2007	Predicates cleared earlier

**12.4.2 Indications for Use**

Feature	Indications for Use
Vitrea <sup>®</sup> CT Liver Analysis (Submission Subject)	Vitrea <sup>®</sup> CT Liver Analysis is a noninvasive post-processing application designed to evaluate liver tumors and plan for liver surgery. It displays images for analysis and preoperative liver surgery planning, such as organ segmentation, tumor segmentation and intrahepatic vessels segmentation, as well as the approximation of vascular territories. It supports preoperative evaluation of specific surgery strategies by allowing the user to interactively define virtual resections splitting the liver. It also allows the user to evaluate safety-margins around lesions and to identify affected vascular branches and territories. Vitrea <sup>®</sup> CT Liver Analysis also provides automatic registration of multiple series and measurement tools for characterization and follow-up of the lesions. When used by a trained and qualified physician a potential application is to assist in the assessment of tumor response to therapy.
MeVis LiverAnalyser / LiverViewer Software (K051528)	The MeVis LiverAnalyser / LiverViewer Software™ device is intended for preoperative planning in liver surgery. The device is used to analyze data and to display image analysis and risk analysis results for the preoperative planning in liver surgery, e.g. organ segmentation, tumor segmentation, segmentation of intrahepatic vessels as well as the approximation of vascular territories. Preoperative evaluation of specific surgery strategies is supported by the feature to interactively define virtual resections splitting the liver or to calculate safety-margins around lesions identifying affected vascular branches and vascular territories supplied or drained by these branches.  Medical image data is derived from various sources (i.e. CT scanners, MRI scanners). Typical users of this system are

Feature	Indications for Use
	trained professionals, including physicians, nurses, and technicians.
LMS-Liver (K071241)	<p>LMS-Liver is an image analysis software application for evaluating CT images covering the liver area. It is designed to assist radiologists in the evaluation and documentation of lesions. It also provides tools for assessment of lesion evolution over time. LMS-Liver offers measurement tools and 3D registration techniques for characterization and follow-up of the lesions. It also offers reporting capabilities making it possible to generate standardized reports.</p> <p>LMS-Liver is intended to be used by radiologists and other clinicians qualified to interpret CT images.</p> <p>LMS-Liver device is designed to be used with CT images covering the liver area in adult patients.</p>

### 12.4.3 Device Description

Feature	Device Description
Vitrea <sup>®</sup> CT Liver Analysis (Submission Subject)	Vitrea <sup>®</sup> CT Liver Analysis is noninvasive post-processing software that displays CT image data. It processes image data to segment liver structures and evaluate resection surfaces as well as volumes. Vitrea <sup>®</sup> CT Liver Analysis provides automatic registration and composite views of multiple series, optimized screen layouts and measurement tools. It also generates standardized reports for WHO and RECIST protocols and for percentage change tumor response values.
MeVis LiverAnalyser / LiverViewer Software (K051528)	MeVis LiverAnalyser / LiverViewer Software <sup>™</sup> is a PC-based software application that imports medical images (i.e. CT, MRI modalities) in a DICOM format. The MeVis-LiverAnalyser is used to analyze data for preoperative planning in liver surgery. The MeVis-LiverAnalyser contains dedicated methods for organ segmentation, tumor segmentation, and segmentation of intrahepatic vasculature as well as for the approximation of vascular territories. While using the MeVis-LiverAnalyser a number of masks are produced to merge voxels into sets. Each of this set is meant to represent a specific anatomical entity. All volumes calculated by the MeVis-LiverAnalyser are given directly by the number of voxels in one of these sets multiplied by the voxel volume. No direct measure of anatomical entities is Performed.
LMS-Liver (K071241)	LMS-Liver is an image analysis software application for evaluating CT images covering the liver area. It is designed to assist radiologists in the evaluation and documentation of lesions. It also provides tools for assessment of lesion evolution over time. LMS-Liver offers measurement tools and 3D registration techniques for characterization and follow-up of the lesions. It also offers reporting capabilities making it possible to generate standardized reports. LMS-Liver can

Feature	Device Description
	segment hepatic lesions identified by the user with a double click (seed point). Once a lesion is segmented, the software computes its characteristics such as size, volume and intensity. LMVS-Liver can match and compare lesions present in two different datasets of the same patient acquired at different dates and compute their difference of size and volume.

#### 12.4.4 Indications and Technology Comparison

Vitrea <sup>®</sup> CT Liver Analysis (Submission Subject)	Description	MeVis LiverAnalyser / LiverViewer Software (K051528)	Median LMS-Liver (K071241)	Explanation of Differences
Analysis Model	Rigid and deformable registration, Segmentation and region growing	Same	Same	None
Parameters	Basic measurements, volume, resection plane, RECIST, WHO and comparisons	Partial (volumes, resection planes and comparisons)	Partial (RECIST, WHO and comparisons)	MeVis provides basic measurements for volumes, resection planes and comparisons. LMS-Liver provides RECIST and WHO measurements and comparison.
Functions	Segment: organs, tumors and intrahepatic vessels, Resection planning tool (defines vascular territories), multi-phase fusion and standardized reports	Partial (segmentation, resection planning and multi-phase fusion)	Partial (standardized reports)	MeVis provides segmentation, resection planning and multi-phase fusion. LMS-Liver provides standardized reports.

Vitrea<sup>®</sup> CT Liver Analysis essentially packages the existing surgical planning functionality of MeVis LiverAnalyser/LiverViewer Software (K051528) with the standardized measurement and reporting capabilities available in Median LMS-Liver (K071241) in a common software environment. The clinical functionality is substantially equivalent to the existing functionality offered by the existing software package.

## 12.5 Vitrea<sup>®</sup> CT Brain Perfusion

### 12.5.1 Regulatory Comparison



## Vital Images

VitreAdvanced  
510(k) Pre-market Notification

Characteristic	Vitre <sup>®</sup> CT Brain Perfusion (Submission Subject)	Vitre <sup>®</sup> 4DCT (K072821)	Siemens syngo <sup>®</sup> Volume Perfusion-CT Neuro (K073238)	Explanation of Differences
Classification Name	System, Image Processing, Radiological	System, Image Processing, Radiological	System, X-ray, Tomography, Computed	Difference explained below.
Regulatory Number	892.2050	892.2050	892.1750	Difference explained below.
Product Code	LLZ	LLZ	JAK	Difference explained below.
Classification	Class II	Class II	Class II	Same
Committee	Radiology	Radiology	Radiology	Same
Decision Date	Under Review	August 7, 2008	January 3, 2008	Predicates cleared earlier

syngo<sup>®</sup> Volume Perfusion-CT Neuro (K073238) uses the JAK product code as accessories to System, X-ray, Tomography, Computed. The VitreAdvanced submission uses the LLZ product code for System, Image Processing, Radiological. VitreAdvanced and syngo<sup>®</sup> Volume Perfusion-CT Neuro are both image post-processing software for CT. syngo<sup>®</sup> Volume Perfusion-CT Neuro may be used with a CT scanner or separate computer systems, similar to VitreAdvanced's Vitre<sup>®</sup> CT Body Perfusion.

The *Guidance for the Submission of Premarket Notifications for Medical Image Management Devices* issued on July 27, 2000 states:

“In order to apply uniform requirements to all types of medical image management devices, devices designated for use with a single modality are no longer treated as accessories to that modality. They are considered to be medical image management devices and subject to the applicable requirements and exemptions.”

Vitre<sup>®</sup> CT Body Perfusion post-processes software for CT images. The Guidance states to consider this type of device as a medical image management device. Medical image management devices includes devices classified under 21 C.F.R. §892.2050 for Picture archiving and communications system. The LLZ product code is defined under 21 C.F.R. §892.2050. Therefore, the LLZ code was selected for VitreAdvanced based on the applicable Guidance. The difference in product codes does not reflect a difference in indications for use or technology.

### 12.5.2 Indications for Use

Feature	Indications for Use
Vitre <sup>®</sup> CT Brain Perfusion (Submission Subject)	Vitre <sup>®</sup> CT Brain Perfusion is noninvasive post-processing application designed to evaluate areas of brain perfusion. The software can calculate cerebral blood flow (CBF), cerebral blood volume (CBV), local bolus timing (i.e., delay of tissue response, time to peak), and mean transit time (MTT) from dynamic CT image data acquired after the injection of contrast media. The package also allows the calculation of regions of interest and mirrored regions, as well as the visual inspection of time density curves. Vitre <sup>®</sup> CT Brain Perfusion supports the physician in visualizing the apparent blood perfusion in brain tissue affected by acute stroke. Areas of decreased perfusion, as is observed in acute cerebral

Vital Images

Feature	Indications for Use
Vitre <sup>®</sup> 4DCT (K072821)	<p>infarcts, appear as areas of changed signal intensity (lower for both CBF and CBV and higher for time to peak and MTT).</p> <p>Vitre<sup>®</sup> is a medical diagnostic system that allows the processing, review, analysis, communication and media interchange of multi-dimensional digital images acquired from a variety of imaging devices. In addition, Vitrea 4DCT has the following indication:</p> <p style="padding-left: 40px;">The Vitrea<sup>®</sup> 4DCT Brain Perfusion option is intended for post processing based on dynamic CT images continuously acquired during the injection of contrast, for the visualization of apparent blood flow in brain tissue and pictorial illustration of perfusion-related parameters to aid in the assessment of the type and extend of cerebral perfusion disturbances.</p>
syngo <sup>®</sup> Volume Perfusion-CT Neuro (K073238)	<p>syngo<sup>®</sup> Volume Perfusion-CT Neuro is a post-processing software package, which runs on an Intel-based PC platform designed to post-process images acquired with SOMATOM CT scanners, which meet certain minimal requirements (i.e. Siemens Definition, Sensation 64. ). It is a package containing evaluation software that supports the evaluation of Dynamic CT data gathered after the injection of a compact bolus of contrast media, where the contrast media acts as a pure intravascular tracer.</p> <p>The Siemens syngo<sup>®</sup> Volume Perfusion-CT Neuro software package has been designed to evaluate areas of brain perfusion. The software can calculate cerebral blood flow (CBF), cerebral blood volume (CBV), local bolus timing (i.e. time to start, time to peak), mean transit time (MTT), and vascular permeability (blood brain barrier disturbances) from sets of images or volumes reconstructed from continuously acquired CT data after the injection of contrast media. The package also allows the calculation of mirrored regions or volumes of interest and the visual inspection of time attenuation curves.</p> <p>One clinical application is to visualize the apparent blood perfusion in brain tissue affected by acute stroke. Areas of decreased perfusion, as is observed in acute cerebral infarcts, appear as areas of changed signal intensity (lower for CBF and CBV, higher for time to peak and MTT).</p> <p>syngo<sup>®</sup> Volume Perfusion-CT Neuro supports the physician in identifying areas of decreased perfusion which indicate the occurrence of acute stroke during the first 6 hours after onset of symptoms.</p> <p>A second application is the visualization of the permeability. It is used for the modeling of extra-vascular leakage of blood into the interstitial space. This additional capability can display blood brain barrier disturbances and thus may improve the differential diagnosis of brain tumors and be helpful in therapy monitoring.</p>

**12.5.3 Device Description**

Feature	Device Description
Vitrea <sup>®</sup> CT Brain Perfusion (Submission Subject)	Vitrea <sup>®</sup> CT Brain Perfusion is noninvasive post-processing software that calculates cerebral blood flow (CBF), cerebral blood volume (CBV), local bolus timing (i.e., delay of tissue response, time to peak), and mean transit time (MTT) from dynamic CT image data. It displays time density curves, perfusion characteristics in parametric and summary maps, as well as regions of interest and mirrored regions.
Vitrea <sup>®</sup> 4DCT (K072821)	<p>The Vitrea<sup>®</sup> system is a medical diagnostic device that allows the processing, review, analysis, communication, and media interchange of multi-dimensional digital images acquired from a variety of imaging devices.</p> <p>The Vitrea<sup>®</sup> system provides multi-dimensional visualization of digital images to aid clinicians in their analysis of anatomy and pathology. The Vitrea<sup>®</sup> system user interface follows typical clinical workflow patterns to process, review, and analyze digital images, including:</p> <ul style="list-style-type: none"> <li>• Retrieve image data over the network via DICOM</li> <li>• Display images that are automatically adapted to exam type via dedicated protocols</li> <li>• Select images for closer examination from a gallery of up to six 2D or 3D views</li> <li>• Interactively manipulate an image in real-time to visualize anatomy and pathology</li> <li>• Annotate, tag, measure, and record selected views</li> <li>• Output selected views to standard film or paper printers, or post a report to an intranet Web server or export views to another DICOM device</li> <li>• Retrieve reports that are archived on a Web server</li> </ul>
syngo <sup>®</sup> Volume Perfusion-CT Neuro (K073238)	<p>syngo<sup>®</sup> Volume Perfusion-CT Neuro is a post-processing software package, which runs on an Intel-based PC platform designed to post-process images acquired with SOMATOM CT scanners, which meet certain minimal requirements (i.e. Siemens Definition, Sensation 64. ). It is a package containing evaluation software that supports the evaluation of Dynamic CT data gathered after the injection of a compact bolus of contrast media, where the contrast media acts as a pure intravascular tracer.</p> <p>The Siemens syngo<sup>®</sup> Volume Perfusion-CT Neuro software package has been designed to evaluate areas of brain perfusion. The software can calculate cerebral blood flow (CBF), cerebral blood volume (CBV), local bolus timing (i.e. time to start, time to peak), mean transit time (MTT), and vascular permeability (blood brain barrier disturbances) from sets of images or volumes reconstructed from continuously acquired CT data after the injection of contrast media. The package also allows the calculation of mirrored regions or volumes of interest and the visual inspection of time attenuation curves.</p>

Feature	Device Description
	<p>One clinical application is to visualize the apparent blood perfusion in brain tissue affected by acute stroke. Areas of decreased perfusion, as is observed in acute cerebral infarcts, appear as areas of changed signal intensity (lower for CBF and CBV, higher for time to peak and MTT).</p> <p>syngo® Volume Perfusion-CT Neuro supports the physician in identifying areas of decreased perfusion which indicate the occurrence of acute stroke during the first 6 hours after onset of symptoms.</p> <p>A second application is the visualization of the permeability. It is used for the modeling of extra-vascular leakage of blood into the interstitial space. This additional capability can display blood brain barrier disturbances and thus may improve the differential diagnosis of brain tumors and be helpful in therapy monitoring.</p>

**12.5.4 Indications and Technology Comparison**

VitreAdvanced® CT Brain Perfusion (Submission Subject)	Description	VitreAdvanced® 4DCT (K072821)	Siemens syngo® Volume Perfusion-CT Neuro (K073238)	Explanation of Differences
Analysis Model	Deconvolution	Same	Includes	syngo® Volume Perfusion-CT Neuro uses both deconvolution and maximum slope
Parameters	Cerebral blood flow (CBF), cerebral blood volume (CBV), local bolus timing (i.e., delay of tissue response, time to peak), and mean transit time (MTT)	Same	Includes	syngo® Volume Perfusion-CT Neuro has all the parameters and vascular permeability
Functions	Display regions of interest, mirrored regions, time density curves and perfusion characteristics in parametric and summary maps	Partial	Same	4DCT does not include summary maps (maps that combine parameters). syngo® Volume Perfusion-CT Neuro includes maps that combine parameters.

VitreAdvanced® CT Brain Perfusion is substantially equivalent to the previous version of CT brain perfusion software cleared under VitreAdvanced® 4DCT (K072821). It is an enhancement to the VitreAdvanced® 4DCT (K072821) software to include summary maps similar to the Siemens syngo® Volume Perfusion-CT

# Vital Images

VitreAdvanced  
510(k) Pre-market Notification

Neuro (K073238), which are detailed in Attachment 12.8 Morhard, Vasospasm after SAH: Neuro Volume Perfusion CT, SOMATOM Sessions-Siemens Healthcare Magazine (May 2008) figure 2. Summary maps allow medical practitioners to create overlays derived from a combination of perfusion variables.

Additional changes to the intended use were made to align with the Siemens syngo<sup>®</sup> Volume Perfusion-CT Neuro (K073238) predicate. The addition of clinical applications currently supported by CT brain perfusion is described in Attachment 12.9 Wintermark, Prognostic Accuracy of Cerebral Blood Flow Measurement by Perfusion Computed Tomography, Annals of Neurology (2002).

## 12.6 Conclusion

VitreAdvanced is substantially equivalent to Vital Images' currently cleared and marketed Vitrea<sup>®</sup>, Version 4.0 (K071331). VitreaAdvanced is a package of noninvasive post-processing software applications for the Vitrea<sup>®</sup> software platform. VitreaAdvanced includes advanced applications that extend the functionality of the platform for specific uses. The specific uses are substantially equivalent to the cleared uses of existing post-processing software applications available on software platforms from other manufacturers. The specific applications provide functionality substantially equivalent to the following currently cleared and marketed software applications:

- Vitrea<sup>®</sup> CT Body Perfusion is substantially equivalent to Toshiba America Medical Systems' CSBP-001A Body Perfusion System (K090504);
- Vitrea<sup>®</sup> CT Liver Analysis is substantially equivalent to MeVis LiverAnalyser / LiverViewer Software (K051528) and Median Technologies LMS-Liver (K071241), and;
- Vitrea<sup>®</sup> CT Brain Perfusion builds on Vital Images' previously cleared Vitrea<sup>®</sup> 4DCT (K072821) and performs the same intended uses as Siemens Medical Solutions' syngo<sup>®</sup> Volume Perfusion-CT Neuro (K073238).

The VitreaAdvanced software applications use similar technology as existing post-processing software applications. All post-processing software applications extend existing software platforms to provide tools for evaluating CT image data. The combination of post-processing applications with specialized functionality on a single platform or within different packages has been accepted and cleared for both the Vitrea<sup>®</sup> and syngo<sup>®</sup> products. Any differences are not consequential from the standpoint of device operation, safety, effectiveness or intended use.

Vital Images believes the included information supports a finding of substantial equivalence for the VitreaAdvanced.

## 13 Proposed Labeling

## Proposed Labeling

This section includes the proposed labeling for VitreaAdvanced. Labeling is included with Vitrea<sup>®</sup> software platform regarding basic system operation. VitreaAdvanced labeling contains the relevant information unique to the included features.

Please see the following attachments for labeling:

- 13.1 CT Body Perfusion Education and Reference Guide (VPMC-12294)
- 13.2 CT Liver Analysis Education and Reference Guide (VPMC-12295)
- 13.3 CT Brain Perfusion Education and Reference Guide (VPMC-12292)
- 13.4 VitreaAdvanced Promotional Excerpt (M-05545)

## 14 Sterilization and Shelf Life

**NOT APPLICABLE**

This device is software and not sold as sterile. Therefore, this section does not apply.



## 15 Biocompatibility

**NOT APPLICABLE**

This device is software and does not have patient contacting parts. Therefore, this section does not apply.

## 16 Software

## Software

This section has been prepared in accordance with *Guidance for the Content of Premarket Submissions for Software Contained in Medical Devices* issued May 11, 2005.

### 16.1 Summary of Software Documentation

VitreAdvanced is a package of noninvasive post-processing software applications for the Vitrea<sup>®</sup> software platform. The system is a software only medical device to be installed on common IT hardware. VitreAdvanced leverages existing Vitrea<sup>®</sup> functionality for the processing, review, analysis, communication, and media interchange of multi-dimensional digital images acquired from a variety of imaging devices. It provides multi-dimensional visualization of digital images to aid medical professionals in their analysis of anatomy and pathology. VitreAdvanced can be used with a variety of cleared Vitrea<sup>®</sup> based software applications. In addition, VitreAdvanced includes three Vitrea<sup>®</sup> applications:

**Vitre<sup>®</sup> CT Body Perfusion** is noninvasive post-processing software that calculates perfusion characteristics from dynamic CT image data. It displays blood flow parametric maps for single-input and dual-input workflows.

**Vitre<sup>®</sup> CT Liver Analysis** is noninvasive post-processing software that displays CT image data. It processes image data to segment liver structures and evaluate resection surfaces as well as volumes. Vitrea<sup>®</sup> CT Liver Analysis provides automatic registration and composite views of multiple series, optimized screen layouts and measurement tools. It also generates standardized reports for WHO and RECIST protocols and for percentage change tumor response values.

**Vitre<sup>®</sup> CT Brain Perfusion** is noninvasive post-processing software that calculates cerebral blood flow (CBF), cerebral blood volume (CBV), local bolus timing (i.e., delay of tissue response, time to peak), and mean transit time (MTT) from dynamic CT image data. It displays time density curves, perfusion characteristics in parametric and summary maps, as well as regions of interest and mirrored regions.

VitreAdvanced presents a Moderate Level of Concern because a malfunction may lead to an erroneous diagnosis or a delay in delivery of appropriate medical care that may lead to a minor injury. Therefore, the following table includes the suggested content for Moderate Level of Concern software and references the supporting documents.

The following attachments are referenced in this section:

(b)(4)



Vital Images

VitreAdvanced  
510(k) Pre-market Notification

(b)(4)



Software Documentation	Guidance	Supporting Reference
Level of Concern	A statement indicating the Level of Concern and a description of the rationale for that level.	(b)(4)
Software Description	A summary overview of the features and software operating environment.	(b)(4)
Device Hazard Analysis	Tabular description of identified hardware and software hazards, including severity assessment and mitigations.	(b)(4)
Software Requirements Specification (SRS)	The complete SRS document.	(b)(4)
Architecture Design Chart	Detailed depiction of functional units and software modules. May include state diagrams as well as flow charts.	(b)(4)
Software Design Specification (SDS)	Software design specification document.	(b)(4)
Traceability Analysis	Traceability among requirements, specifications, identified hazards and mitigations, and Verification and Validation testing.	(b)(4)
Software Development Environment Description	Summary of software life cycle development plan, including a summary of the configuration management and maintenance activities.	(b)(4)
Verification and Validation Documentation	Description of V&V activities at the unit, integration, and system level. System level test protocol, including pass/fail criteria, and tests results.	(b)(4)

		(b)(4)
Revision Level History	Revision history log, including release version number and date.	
Unresolved Anomalies (Bugs or Defects)	List of remaining software anomalies, annotated with an explanation of the impact on safety or effectiveness, including operator usage and human factors.	

**16.2 Level of Concern**

The Level of Concern is Moderate by applying the method defined in the *Guidance for the Content of Premarket Submissions for Software Contained in Medical Devices, May 11, 2005*.

First, the Major Level of Concern was evaluated and determined to not apply. If the answer to any one of the following questions is “Yes,” the level of concern for the software device is likely to be Major:

Does the software device qualify as blood establishment computer software?

*Answer: No, the software device has no blood establishment functionality.*

Is the software device intended to be used in combination with a drug or biologic?

*Answer: No, the software device has no biologic or drug component.*

Is the software device an accessory to a medical device that has a major level of concern?

*Answer: No, the software device is not an accessory to another medical device with a major level of concern.*

Prior to mitigation of hazards, could a failure of the software device result in death or serious injury, either to a patient or to a user of the device?

*Answer: No.*

*The device does not control a life supporting or sustaining function. The device delivers no harmful energy that could result in death or serious injury such as radiation, defibrillators, and ablation generators. The device does not control the delivery of treatment or therapy such that an error or malfunction would result in death or serious injury. The device does not provide diagnostic information that directly drives a decision regarding treatment or therapy that if misapplied it could result in serious injury or death. The device provides no monitoring of vital signs.*

Therefore, the software device is NOT considered a “Major” Level of Concern.

Second, the Moderate Level of Concern was evaluated and determined to apply. If the answer to any one of the following questions is “Yes,” the level of concern for the software shall be considered Moderate:

Is the software device an accessory to a medical device that has a moderate level of concern?

# Vital Images

VitreAdvanced  
510(k) Pre-market Notification

*Answer: No, the software device is not an accessory to another medical device with a moderate level of concern.*

Prior to mitigation of hazards, could a failure of the software device result in minor injury, either to a patient or to a user of the device?

*Answer: No, the software device is used for post-processing and does not control energy or motion and therefore failure does result in injury.*

Could a malfunction of, or a latent design flaw in, the software device lead to an erroneous diagnosis or a delay in delivery of appropriate medical care that would likely lead to minor injury?

*Answer: Yes, the software device provides imaging information to assist physicians. The software device does not provide a diagnosis or determine recommended medical care.*

Therefore, the Level of Concern is considered Moderate, based on a potential that a malfunction of, or latent design flaw in, the software device could potentially lead to a delay in delivery of appropriate medical care.

## 16.3 DICOM Conformance

VitreAdvanced accepts DICOM images. It uses the Vitrea<sup>®</sup> software platform DICOM infrastructure described in Attachment 16.17 VitreAdvanced DICOM Conformance Statement (VLC-07112). Also included is Attachment 16.18 DICOM Form FDA 3654, Standards Data Report Form for 510(k)s identifying that the submission references the recognized DICOM standard.

## **17 Electromagnetic Compatibility and Electrical Safety**

**NOT APPLICABLE**

This device is software and resides on standard off-the-shelf computer hardware. Therefore, this section does not apply.

## **18 Performance Testing – Bench**



## Performance Testing – Bench

Performance testing for VitreaAdvanced included verification and validation. Validation included evaluating previously acquired CT images. Verification confirmed that the feature functions according to its requirements without impacting existing functionality. Validation found that users could operate the software and successfully visualize anatomy and pathology and perform the specific functions related to CT Body Perfusion, CT Liver Analysis and CT Brain Perfusion.

The testing data and reports support a determination of substantial equivalence. The complete data is included with Section 16 – Software in the following attachments:

(b)(4)



## 19 Performance Testing – Animal

**NOT APPLICABLE**

Animal testing was not necessary or performed to support substantial equivalence or evaluate performance characteristics. Therefore, this section does not apply.

## **20 Performance Testing – Clinical**

**NOT APPLICABLE**

Clinical testing was not necessary or performed to support substantial equivalence or evaluate performance characteristics. Therefore, this section does not apply.

## 21 Software Certification

**Software Certification**

As recommended by Guidance for the Submission Of Premarket Notifications for  
Medical Image Management Devices issued on July 27, 2000

I certify that, in my capacity as Senior Director of Research and Development of Vital Images, Inc., I believe to the best of my knowledge, that all the software information is correct. The Vital Images, Inc. procedures under which this software was developed remain in place and will be utilized for any future software development associated with this product.



\_\_\_\_\_  
Scott Galbari  
Senior Director of Research and Development

*April 17, 2012*

\_\_\_\_\_  
Date

***22 Mapping Guidance for the Submission Of  
Premarket Notifications for Medical Image  
Management Devices to Format for Traditional  
and Abbreviated 510(k)s***

## Vital Images

VitreaAdvanced  
510(k) Pre-market Notification

This section maps the suggested content from *Guidance for the Submission Of Premarket Notifications for Medical Image Management Devices* to the sections defined in *Format for Traditional and Abbreviated 510(k)s*. This is an aid for submission reviewers.

Section	Image Mgmt Content	510(k) Location
<b>A. General Information</b>		
	1. Name and address of manufacturer	Section 3 – Cover Letter
	2. Establishment registration number	Section 3 – Cover Letter
	3. Name, title and phone number of contact	Section 3 – Cover Letter
	4. Tradename and common name of the device	Section 5 – 510(k) Summary
	5. Classification(s) of the device	Section 3 – Cover Letter
	7. Intended use	Section 5 – 510(k) Summary
	8. Substantially Equivalent (predicate) device(s)	Section 3 – Cover Letter
	9. Applicable mandatory and voluntary standards including Declaration of Conformity or certification statement to applicable voluntary standards that are cited for the device.	Section 2 – CDRH Premarket Review Submission Cover Sheet
<b>B. Administrative Information</b>		
	1. 510(k) Summary of Safety and Effectiveness or 510(k) Statement. Submit one or the other, not both. The content and format of these documents are described in 21 CFR 807.92 and 807.93.	Section 5 – 510(k) Summary
	2. FDA Indication for Use Form	Section 4 – Indications for Use Statement
	3. Truthful and Accurate Statement (21 CFR 807.87(k)).	Section 6 – Truthful and Accuracy Statement
<b>C. Device Description</b>		
	1. Summary of functions of the device and its major components	Section 11 – Device Description
	2. Diagram of layout and interconnections	Section 16 – Software (Attachment 16.9 VitreaAdvanced Analysis Architecture Design Chart (VLC-07102))
	3. Technical characteristics and principles of operation	Section 11 – Device Description
	4. Specifications	Section 11 – Device Description
<b>D. Laboratory and Clinical Testing</b>		
	Manufacturers should include a brief description of their test methods and results in the 510(k).	Section 10 – Executive Summary and Section 16 – Software
<b>E. Comparison to Legally Marketed (Predicate) Devices</b>		
	1. Manufacturer and tradename of predicate device(s)	Section 12 – Substantial Equivalence Discussion
	2. Promotional material and specifications for SE devices	Section 12 – Substantial Equivalence Discussion
	3. Tabular comparison of features and specifications of the device and SE device(s)	Section 12 – Substantial Equivalence Discussion
	4. Discussion of similarities and differences and an explanation of important differences	Section 12 – Substantial Equivalence Discussion

# Vital Images

VitreAdvanced  
510(k) Pre-market Notification

F. Labeling		
	1. Labeling and promotional material	Section 13 – Proposed Labeling (13.4 VitreaAdvanced Promotional Excerpt (M-05545))
	2. User’s Manuals (drafts are acceptable) including	Section 13 – Proposed Labeling (Attachments 13.1 CT Body Perfusion Education and Reference Guide (VLC-07108), 13.2 CT Liver Analysis Education and Reference Guide (VLC-07110), 13.3 CT Brain Perfusion Education and Reference Guide (VPMC-07111))
	3. Images	Section 13 – Proposed Labeling (13.4 VitreaAdvanced Promotional Excerpt (M-05545))

G. Software Information		
-------------------------	--	--

	1. A list and a brief description of the functions performed by the software.	(b)(4)
	2. A description of the manufacturer’s software development methods.	
	3. A list of hazards related to the functions performed by the software, and the means taken to mitigate each of these hazards.	
	4. A description of the software test procedures.	
	5. A certification by a responsible company official that the software information provided in this notification is correct, and that the same procedures will be used to retest and revalidate the software when it is revised.	



**V i T A L**

A Toshiba Medical Systems Group Company

510(k) Premarket Notification  
VitreaAdvanced  
Attachments

Vital Images, Inc.

5850 Opus Parkway, Suite 300

Minnetonka, MN 55343-4414

18 April 2012

**CONFIDENTIAL**

## Attachments

### **Section 12 – Substantial Equivalence**

- 12.1 Vital Images Vitrea<sup>®</sup>, Version 4.0, K071331 510(k) Summary
- 12.2 Vital Images Vitrea<sup>®</sup> 4DCT, K072821 510(k) Summary
- 12.3 Toshiba CSBP-001A Body Perfusion System, K090504 510(k) Summary
- 12.4 Toshiba CSBP-001A Body Perfusion System, Draft Labeling
- 12.5 MeVis LiverAnalyser / LiverViewer Software, K051528 510(k) Summary
- 12.6 MEDIAN Technologies LMS-Liver, K071241 510(k) Summary
- 12.7 Siemens syngo<sup>®</sup> Volume Perfusion-CT Neuro, K073238 510(k) Summary
- 12.8 Morhard, Vasospasm after SAH: Neuro Volume Perfusion CT, SOMATOM Sessions-Siemens Healthcare Magazine (May 2008)
- 12.9 Wintermark, Prognostic Accuracy of Cerebral Blood Flow Measurement by Perfusion Computed Tomography, Annals of Neurology (2002)

### **Section 13 – Proposed Labeling**

- 13.1 CT Body Perfusion Education and Reference Guide (VPMC-12294)
- 13.2 CT Liver Analysis Education and Reference Guide (VPMC-12295)
- 13.3 CT Brain Perfusion Education and Reference Guide (VPMC-12292)
- 13.4 VitreaAdvanced Promotional Excerpt (M-05545)

### **Section 16 – Software**

(b)(4)



## **12 Substantial Equivalence Attachments**

## **12.1 Vital Images Vitrea®, Version 4.0, K071331 510(k) Summary**

## 6.0 510(k) Summary

### Submitter's Name / Contact Person

MAY 25 2007

Timothy J. Kappers, MBA, RAC  
 Director, Quality Systems, Regulatory & Clinical Affairs  
 Vital Images, Inc.  
 5850 Opus Parkway, Suite 300  
 Minnetonka, MN 55343

### General Information

<b>Trade Name</b>	Vitrea <sup>®</sup> , Version 4.0 Medical Image Processing Software
<b>Common / Usual Name</b>	System, Image Processing, Radiological
<b>Classification Name</b>	LLZ, Class II, CFR 21 892.2050
<b>Predicate Devices</b>	<ul style="list-style-type: none"> <li>• Vitrea<sup>®</sup>, Version 3.9 (K061624) Vital Images, Inc.</li> <li>• EnSite Verismo™ (K051840) St. Jude, Inc.</li> <li>• CARD EP (K031261) GE Medical Systems</li> <li>• SUREPlaque™ (K043111) Toshiba America Medical Systems, Inc.</li> </ul>

### Device Description

The Vitrea system is a medical diagnostic device that allows the processing, review, analysis, communication, and media interchange of multi-dimensional digital images acquired from a variety of imaging devices.

The Vitrea system provides multi-dimensional visualization of digital images to aid clinicians in their analysis of anatomy and pathology. The Vitrea system user interface follows typical clinical workflow patterns to process, review, and analyze digital images, including:

- Retrieve image data over the network via DICOM
- Display images that are automatically adapted to exam type via dedicated protocols
- Select images for closer examination from a gallery of up to six 2D or 3D views
- Interactively manipulate an image in real-time to visualize anatomy and pathology

Vital Images, Inc.  
Vitrea™, Version 4.0

- Annotate, tag, measure, and record selected views
- Output selected views to standard film or paper printers, or post a report to an intranet Web server or export views to another DICOM device
- Retrieve reports that are archived on a Web server

### **Intended Use**

Vitrea is a medical diagnostic system that allows the processing, review, analysis, communication and media interchange of multi-dimensional digital images acquired from a variety of imaging devices. Vitrea is not meant for primary image interpretation in mammography. In addition, Vitrea Version 4.0 has the following additional indications:

Cardiac EP Planning is a post-processing advanced visualization application that is intended to be used for the analysis and assessment of the heart including the atria, pulmonary veins, and coronary sinus. The application provides analysis tools which include a number of display, quantitative measurement and 3D model export capabilities for use with the St. Jude Ensite® System. The application can be used to aid trained physicians in the visualization and assessment of cardiac anatomy.

The SUREPlaque™ software application is intended to assist trained physicians in the stratification of patients identified to have atherosclerosis. This software post processes images obtained using a multidetector CT. The package provides tools for the measurement and visualization (color coded maps) of arterial vessels.

The Vessel Probe option is intended for viewing the anatomy and pathology of a patient's peripheral arteries. Clinicians can select any artery to view the following anatomical references: the highlighted vessel in 3D, two rotate-able curved MPR vessel views displayed at angles orthogonal to each other, and cross sections of the vessel. Cross-sectional measurements can be obtained using standard Vitrea software measuring tools. Clinicians can semi-automatically determine contrasted lumen boundaries, stenosis measurements, and maximum and minimum lumen diameters. In addition, clinicians can edit lumen boundaries and examine Hounsfield unit or signal intensity statistics. Clinicians can also manually measure vessel length along the centerline in standard curved MPR views.

### **Predicate Device Comparison**

The Vitrea, Version 4.0 system and its predicate devices allow for the analysis, communication and media interchange of digital images acquired from a variety of acquisition devices. All devices support the DICOM protocol for communication of images with other medical imaging devices.

## **Summary of Studies**

The software utilized was designed, developed, tested, and validated according to written procedures. These procedures specify individuals within the organization responsible for developing and approving product specifications, coding, testing, validating, and maintenance.

The Vitrea, Version 4.0 system will successfully complete integration testing/verification testing prior to Beta validation. Software Beta testing/validation will be successfully completed prior to release. In addition, potential hazards have been studied and controlled by a Risk Management Plan.

## **Conclusion**

The Vitrea, Version 4.0 system has similar intended uses as the predicate devices and has very similar technological characteristics. Minor technological differences do not raise any new questions regarding safety or effectiveness of the device. Thus, the Vitrea, Version 4.0 system is substantially equivalent to the predicate devices.



Food and Drug Administration  
9200 Corporate Blvd.  
Rockville MD 20850

Vital Images, Inc.  
% Mr. Mark Job  
Responsible Third Party Official  
Regulatory Technology Services LLC  
1394 25<sup>th</sup> Street NW  
BUFFALO MN 55313

MAY 25 2007

Re: K071331

Trade/Device Name: Vitrea<sup>®</sup>, Version 4.0 Medical Image Processing Software  
Regulation Number: 21 CFR 892.2050  
Regulation Name: Picture archiving and communications system  
Regulatory Class: II  
Product Code: LLZ  
Dated: May 10, 2007  
Received: May 11, 2007

Dear Mr. Job:

We have reviewed your Section 510(k) premarket notification of intent to market the device referenced above and have determined the device is substantially equivalent (for the indications for use stated in the enclosure) to legally marketed predicate devices marketed in interstate commerce prior to May 28, 1976, the enactment date of the Medical Device Amendments, or to devices that have been reclassified in accordance with the provisions of the Federal Food, Drug, and Cosmetic Act (Act) that do not require approval of a premarket approval application (PMA). You may, therefore, market the device, subject to the general controls provisions of the Act. The general controls provisions of the Act include requirements for annual registration, listing of devices, good manufacturing practice, labeling, and prohibitions against misbranding and adulteration.

If your device is classified (see above) into either class II (Special Controls) or class III (Premarket Approval), it may be subject to such additional controls. Existing major regulations affecting your device can be found in the Code of Federal Regulations, Title 21, Parts 800 to 898. In addition, FDA may publish further announcements concerning your device in the Federal Register.



*Protecting and Promoting Public Health*



Page 2 --

Please be advised that FDA's issuance of a substantial equivalence determination does not mean that FDA has made a determination that your device complies with other requirements of the Act or any Federal statutes and regulations administered by other Federal agencies. You must comply with all the Act's requirements, including, but not limited to: registration and listing (21 CFR Part 807); labeling (21 CFR Part 801); good manufacturing practice requirements as set forth in the quality systems (QS) regulation (21 CFR Part 820); and if applicable, the electronic product radiation control provisions (Sections 531-542 of the Act); 21 CFR 1000-1050.


This letter will allow you to begin marketing your device as described in your Section 510(k) premarket notification. The FDA finding of substantial equivalence of your device to a legally marketed predicate device results in a classification for your device and thus, permits your device to proceed to the market.

If you desire specific advice for your device on our labeling regulation (21 CFR Part 801), please contact the Office of Compliance at one of the following numbers, based on the regulation number at the top of this letter:

21 CFR 876.xxx	(Gastroenterology/Renal/Urology)	240-276-0115
21 CFR 884.xxx	(Obstetrics/Gynecology)	240-276-0115
21 CFR 894.xxx	(Radiology)	240-276-0120
Other		240-276-0100

Also, please note the regulation entitled, "Misbranding by reference to premarket notification" (21CFR Part 807.97). You may obtain other general information on your responsibilities under the Act from the Division of Small Manufacturers, International and Consumer Assistance at its toll-free number (800) 638-2041 or (240) 276-3150 or at its Internet address <http://www.fda.gov/cdrh/industry/support/index.html>.

Sincerely yours,



Nancy C. Brogdon  
Director, Division of Reproductive,  
Abdominal, and Radiological Devices  
Office of Device Evaluation  
Center for Devices and Radiological Health

Enclosure

Vital Images, Inc.  
Vitrea™, Version 4.0

3.0 Intended Use Statement

510(k) Number (if known): K071331

Device Name: Vitrea®, Version 4.0 Medical Image Processing Software

Vitrea is a medical diagnostic system that allows the processing, review, analysis, communication and media interchange of multi-dimensional digital images acquired from a variety of imaging devices. Vitrea is not meant for primary image interpretation in mammography. In addition, Vitrea Version 4.0 has the following additional indication:

Cardiac EP Planning is a post processing advanced visualization application that is intended to be used for the analysis and assessment of the heart including the atria, pulmonary veins, and coronary sinus. The application provides analysis tools which include a number of display, quantitative measurement and 3D model export capabilities for use with the St. Jude Ensite® System. The application can be used to aid trained physicians in the visualization and assessment of cardiac anatomy.

The SUREPlaque™ software application is intended to assist trained physicians in the stratification of patients identified to have atherosclerosis. This software post processes images obtained using a multidetector CT. The package provides tools for the measurement and visualization (color coded maps) of arterial vessels.

The Vessel Probe option is intended for viewing the anatomy and pathology of a patient's peripheral arteries. Clinicians can select any artery to view the following anatomical references: the highlighted vessel in 3D, two rotate-able curved MPR vessel views displayed at angles orthogonal to each other, and cross sections of the vessel. Cross-sectional measurements can be obtained using standard Vitrea software measuring tools. Clinicians can semi-automatically determine contrasted lumen boundaries, stenosis measurements, and maximum and minimum lumen diameters. In addition, clinicians can edit lumen boundaries and examine Hounsfield unit or signal intensity statistics. Clinicians can also manually measure vessel length along the centerline in standard curved MPR views.

Prescription Use   X    
(Part 21 CFR 801 Subpart D)

AND/OR

Over-The-Counter Use \_\_\_\_\_  
(21 CFR 801 Subpart C)

(PLEASE DO NOT WRITE BELOW THIS LINE-CONTINUE ON ANOTHER PAGE OF NEEDED)

Concurrence of CDRH, Office of Device Evaluation (ODE)

Nancy C. Brogdon  
(Division Sign-Off)  
Division of Reproductive, Abdominal,  
and Radiological Devices  
510(k) Number K071331

Page \_\_\_ of \_\_\_

## **12.2 Vital Images Vitrea® 4DCT, K072821 510(k) Summary**

K072821  
pg 1 of 2

## 6.0 510(k) Summary

### Submitter's Name / Contact Person

Timothy J. Kappers, MBA, RAC  
Director, Quality Systems, Regulatory & Clinical Affairs  
Vital Images, Inc.  
5850 Opus Parkway, Suite 300  
Minnetonka, MN 55343

Page 20

### General Information

<b>Trade Name</b>	Vitrea <sup>®</sup> 4DCT Medical Image Processing Software
<b>Common / Usual Name</b>	System, Image Processing, Radiological
<b>Classification Name</b>	LLZ, Class II, CFR 21 892.2050
<b>Predicate Device</b>	Vitrea, Version 4.0 (K071331)

### Device Description

The Vitrea system is a medical diagnostic device that allows the processing, review, analysis, communication, and media interchange of multi-dimensional digital images acquired from a variety of imaging devices.

The Vitrea system provides multi-dimensional visualization of digital images to aid clinicians in their analysis of anatomy and pathology. The Vitrea system user interface follows typical clinical workflow patterns to process, review, and analyze digital images, including:

- Retrieve image data over the network via DICOM
- Display images that are automatically adapted to exam type via dedicated protocols
- Select images for closer examination from a gallery of up to six 2D or 3D views
- Interactively manipulate an image in real-time to visualize anatomy and pathology
- Annotate, tag, measure, and record selected views
- Output selected views to standard film or paper printers, or post a report to an intranet Web server or export views to another DICOM device
- Retrieve reports that are archived on a Web server

K072821  
Pg. 2 of 2

## Intended Use

Vitrea is a medical diagnostic system that allows the processing, review, analysis, communication and media interchange of multi-dimensional digital images acquired from a variety of imaging devices. In addition, Vitrea 4DCT has the following indication:

The Vitrea 4DCT Brain Perfusion option is intended for post processing based on dynamic CT images continuously acquired during the injection of contrast, for the visualization of apparent blood flow in brain tissue and pictorial illustration of perfusion-related parameters to aid in the assessment of the type and extend of cerebral perfusion disturbances.

## Predicate Device Comparison

The Vitrea 4DCT system and its predicate device allow for the analysis, communication and media interchange of digital images acquired from a variety of acquisition devices. All devices support the DICOM protocol for communication of images with other medical imaging devices.



Food and Drug Administration  
9200 Corporate Boulevard  
Rockville MD 20850

**'AUG 7 2008**

Vital Images, Inc.  
% Mr. Mark Job  
Responsible Third Party Official  
Regulatory Technology Services LLC  
1394 25th Street NW  
BUFFALO MN 55313

Re: K072821

Trade/Device Name: Vitrea® 4DCT Medical Image Processing Software  
Regulation Number: 21 CFR 892.2050  
Regulation Name: Picture archiving and communications system  
Regulatory Class: II  
Product Code: LLZ  
Dated: January 19, 2008  
Received: January 22, 2008

Dear Mr. Job:

This letter corrects our substantially equivalent letter of February 20, 2008.

We have reviewed your Section 510(k) premarket notification of intent to market the device referenced above and have determined the device is substantially equivalent (for the indications for use stated in the enclosure) to legally marketed predicate devices marketed in interstate commerce prior to May 28, 1976, the enactment date of the Medical Device Amendments or to devices that have been reclassified in accordance with the provisions of the Federal Food, Drug, and Cosmetic Act (Act) that do not require approval of a premarket approval (PMA). You may, therefore, market the device, subject to the general controls provisions of the Act. The general controls provisions of the Act include requirements for annual registration, listing of devices, good manufacturing practice, labeling, and prohibitions against misbranding and adulteration.

If your device is classified (see above) into either class II (Special Controls) or class III (PMA), it may be subject to additional controls. Existing major regulations affecting your device can be found in the Code of Federal Regulations, Title 21, Parts 800 to 898. In addition, FDA may publish further announcements concerning your device in the Federal Register.


Please be advised that FDA's issuance of a substantial equivalence determination does not mean that FDA has made a determination that your device complies with other requirements of the Act or any Federal statutes and regulations administered by other Federal agencies. You must comply with all the Act's requirements, including, but not limited to: registration and listing (21

CFR Part 807); labeling (21 CFR Part 801); good manufacturing practice requirements as set forth in the quality systems (QS) regulation (21 CFR Part 820); and if applicable, the electronic product radiation control provisions (sections 531-542 of the Act); 21 CFR 1000-1050.

This letter will allow you to continue marketing your device as described in your Section 510(k) premarket notification. The FDA finding of substantial equivalence of your device to a legally marketed predicate device results in a classification for your device and thus, permits your device to proceed to the market.

If you desire specific advice for your device on our labeling regulation (21 CFR Part 801), please contact the Office of Compliance at (240) 276-0120. Also, please note the regulation entitled, "Misbranding by reference to premarket notification" (21CFR Part 807.97). You may obtain other general information on your responsibilities under the Act from the Division of Small Manufacturers, International and Consumer Assistance at its toll-free number (800) 638-2041 or (240) 276-3150 or at its Internet address <http://www.fda.gov/cdrh/dsma/dsmamain.html>

Sincerely yours,

A handwritten signature in black ink, appearing to read "Nancy C. Brogdon", with a small "for" written to the left of the signature.

Nancy C. Brogdon  
Director, Division of Reproductive,  
Abdominal, and Radiological Devices  
Office of Device Evaluation  
Center for Devices and Radiological Health

## Indications for Use

510(k) Number (if known): K072821

Device Name: Vitrea® 4DCT Medical Image Processing Software

### Indications For Use:

Vitrea is a medical diagnostic system that allows the processing, review, analysis, communication and media interchange of multi-dimensional digital images acquired from a variety of imaging devices. In addition, Vitrea 4DCT has the following indication:

The Vitrea 4DCT Brain Perfusion option is intended for post processing based on dynamic CT images continuously acquired during the injection of contrast, for the visualization of apparent blood flow in brain tissue and pictorial illustration of perfusion-related parameters to aid in the assessment of the type and extent of cerebral perfusion disturbances.

Prescription Use   X  

AND/OR

Over-The-Counter Use


(Part 21 CFR 801 Subpart D)

(21 CFR 801 Subpart C)

(PLEASE DO NOT WRITE BELOW THIS LINE-CONTINUE ON ANOTHER PAGE IF NEEDED)

---

Concurrence of CDRH, Office of Device Evaluation (ODE)

  
\_\_\_\_\_  
(Division Sign-Off)  
Division of Reproductive, Abdominal and  
Radiological Devices  
510(k) Number   K072821



## **12.3 Toshiba CSBP-001A Body Perfusion System, K090504 510(k) Summary**

K090504

Toshiba America Medical Systems, Inc.  
Premarket Notification Body Organ Perfusion System, CSBP-001A

**Section 5. 510(k) Summary**

MAR 5 2009

**Date:** February 18, 2009

**Manufacturer:** Toshiba Medical Systems Corporation  
1385 Shimoishigami, Otawara-shi,  
Tochigi-ken, 324-8550, Japan

**Initial Importer/Distributor:** Toshiba America Medical Systems, Inc.  
**Address:** P.O. Box 2068, 2441 Michelle Drive,  
Tustin, CA 92781-2068

**Contact:** Paul Biggins, Director Regulatory Affairs  
(714)730-5000

**Establishment Registration Number:** 2020563

**Device Proprietary Name:** CSBP-001A; Body Perfusion System

**Common Name:** Scanner, Computed Tomography, X-Ray

**Classification:** 90-JAK

**Regulatory Class:** II (per 21 CFR 892.1750)

**Performance Standard:** None

**Predicate Device(s):** General Electric CT Perfusion 4 (k052839)  
Siemens syngo Perfusion (k073373)

**Reason For Submission** New software device

**Description of this Device:**

The CSBP-001A is a noninvasive post-processing software that runs on a PC based console of the host CT device. It has been designed to assess dynamic (time lapsed collections) CT volume scans and provide data related to the volume sets.

**Summary of Intended Uses:**

The Body Perfusion System software package is a noninvasive post-processing package that has been designed to evaluate perfusion of organs and tumors. The software can calculate blood flow, blood volume and permeability from sets of images reconstructed from dynamic CT data acquired after the injection of contrast media. The software also allows the separate calculation of the arterial and portal venous component of hepatic

Toshiba America Medical Systems, Inc.

Premarket Notification Body Organ Perfusion System, CSBP-001A

perfusion. It supports evaluation of regions of interest and the visual inspection of time density curves.

When used by a qualified physician a potential application is to differentiate blood flow between normal and diseased tissue. Determination of the change of perfusion parameters during the course of treatment may be helpful in therapy monitoring.

It should be used by a trained and qualified physician.

**Safety and Effectiveness Concerns:**

This device is designed and manufactured under the Quality System Regulations as outlined in 21 CFR § 820. Additionally, risk management is employed through hazard analysis which identifies potential hazards. These hazards are mitigated through labeling and software development.

**Substantial Equivalence:**

This device is substantially equivalent to the predicate devices which are commercially available at this time.

GE CT Perfusion 4	k052839	March 10, 2006
Siemens syngo Volume Perfusion CT Body	k073373	December 18, 2007



Food and Drug Administration  
9200 Corporate Boulevard  
Rockville MD 20850

MAR 5 2009

Toshiba America Medical Systems, Inc.  
% Mr. Mark Job  
Responsible Third Party Official  
Regulatory Technology Services LLC  
1394 25<sup>th</sup> Street NW  
BUFFALO MN 55313

Re: K090504

Trade/Device Name: Body Perfusion System, CSBP-001A  
Regulation Number: 21 CFR 892.1750  
Regulation Name: Computed tomography x-ray system  
Regulatory Class: II  
Product Code: JAK  
Dated: February 25, 2009  
Received: February 26, 2009

Dear Mr. Job:

We have reviewed your Section 510(k) premarket notification of intent to market the device referenced above and have determined the device is substantially equivalent (for the indications for use stated in the enclosure) to legally marketed predicate devices marketed in interstate commerce prior to May 28, 1976, the enactment date of the Medical Device Amendments, or to devices that have been reclassified in accordance with the provisions of the Federal Food, Drug, and Cosmetic act (Act) that do not require approval of a premarket approval application (PMA). You may, therefore, market the device, subject to the general controls provisions of the Act. The general controls provisions of the Act include requirements for annual registration, listing of devices, good manufacturing practice, labeling, and prohibitions against misbranding and adulteration.

If your device is classified (see above) into either class II (Special Controls) or class III (PMA), it may be subject to such additional controls. Existing major regulations affecting your device can be found in the Code of Federal Regulations, Title 21, Parts 800 to 898. In addition, FDA may publish further announcements concerning your device in the Federal Register.

Please be advised that FDA's issuance of a substantial equivalence determination does not mean that FDA has made a determination that your device complies with other requirements of the Act or any Federal statutes and regulations administered by other Federal agencies. You must comply with all the Act's requirements, including but not limited to: registration and listing (21 CFR Part 807); labeling (21 CFR Part 801); good manufacturing practice requirements as set forth in the quality systems (QS) regulation (21 CFR Part 820); and if applicable, the electronic product radiation control provisions (Sections 531-542 of the Act); 21 CFR 1000-1050.


This letter will allow you to begin marketing your device as described in your Section 510(k) premarket notification. The FDA finding of substantial equivalence of your device to a legally marketed predicate device results in a classification for your device and thus, permits your device to proceed to the market.

If you desire specific advice for your device on our labeling regulation (21 CFR Part 801), please contact the Office of Compliance at one of the following numbers, based on the regulation number at the top of this letter.

21 CFR 876.xxx	(Gastroenterology/Renal/Urology)	(240) 276-0115
21 CFR 884.xxx	(Obstetrics/Gynecology)	(240) 276-0115
21 CFR 892.xxx	(Radiology)	(240) 276-0120
Other		(240) 276-0100

Also, please note the regulation entitled, "Misbranding by reference to premarket notification" (21 CFR Part 807.97). For questions regarding postmarket surveillance, please contact CDRH's Office of Surveillance and Biometrics' (OSB's) Division of Postmarket Surveillance at 240-276-3474. For questions regarding the reporting of device adverse events (Medical Device Reporting (MDR)), please contact the Division of Surveillance Systems at 240-276-3464. You may obtain other general information on your responsibilities under the Act from the Division of Small Manufacturers, International and Consumer Assistance at its toll-free number (800) 638-2041 or (240) 276-3150 or at its Internet address <http://www.fda.gov/cdrh/industry.support/index.html>.

Sincerely yours,



Janine M. Morris  
Acting Director, Division of Reproductive,  
Abdominal, and Radiological Devices  
Office of Device Evaluation  
Center for Devices and Radiological Health

Enclosure

## Indications for Use

510(k) Number (if known): K090504

Device Name: Body Perfusion System, CSBP-001A

### Indications for Use:

The Body Perfusion System software package is a noninvasive post-processing package that has been designed to evaluate perfusion of organs and tumors. The software can calculate blood flow, blood volume and permeability from sets of images reconstructed from dynamic CT data acquired after the injection of contrast media. The software also allows the separate calculation of the arterial and portal venous component of hepatic perfusion. It supports evaluation of regions of interest and the visual inspection of time density curves.


When used by a qualified physician a potential application is to differentiate blood flow between normal and diseased tissue. Determination of the change of perfusion parameters during the course of treatment may be helpful in therapy monitoring.

It should be used by a trained and qualified physician.

Prescription Use  X  AND/OR Over-The-Counter Use \_\_\_\_\_  
(Part 21 CFR 801 Subpart D) (21 CFR 801 Subpart C)

(PLEASE DO NOT WRITE BELOW THIS LINE-CONTINUE ON ANOTHER PAGE OF NEEDED)

Concurrence of CDRH, Office of Device Evaluation (ODE)

  
\_\_\_\_\_  
(Division Sign-Off)  
Division of Reproductive, Abdominal and  
Radiological Devices  
510(k) Number K090504

Page 1 of 1

## **12.4 Toshiba CSBP-001A Body Perfusion System, Draft Labeling**

# BODY ORGAN PERFUSION **CSBP-001A**

Product Data  
 No. MPDCT0307EAA

## APPLICATION

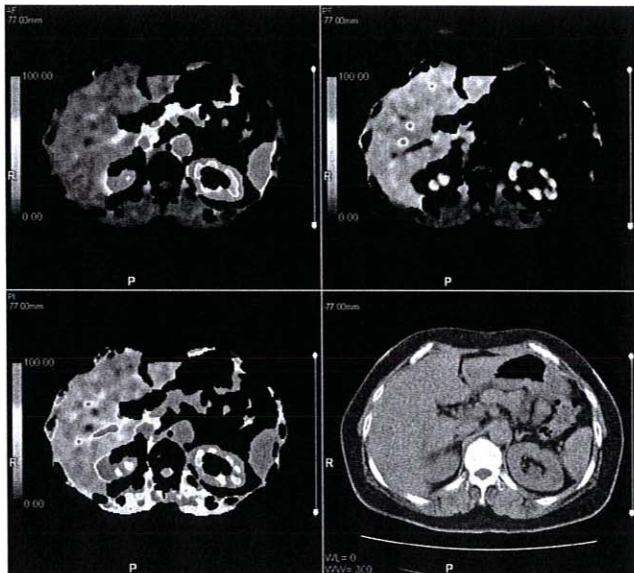
This software is an application system that analyzes blood perfusion in the peripheral vessels of a body organ based on the time-sequential images obtained by performing a CT examination for the same anatomical region over time using iodinated contrast medium as a tracer, and displays the analysis results as functional images. This software is applicable to the following Aquilion™ systems.

Aquilion	32-slice systems	TSX-101A/I, /K
	64-slice systems	TSX-101A/H, /J

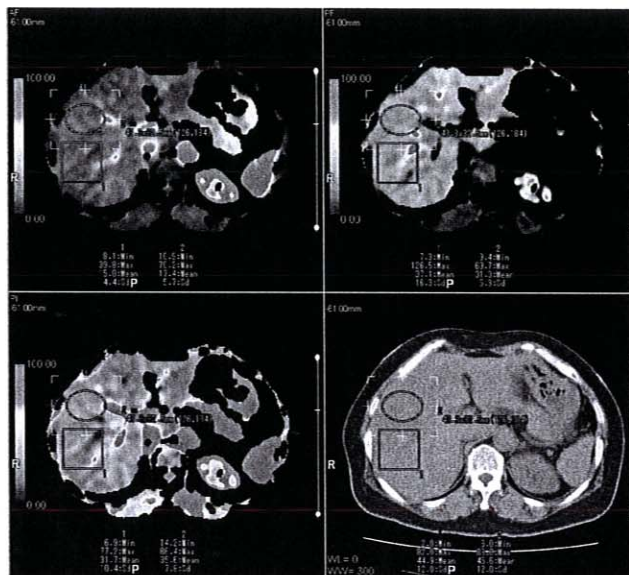
Note: System software version must be V4.4 or later. For CT systems with system software earlier than V4.4, an additional software upgrade kit must be purchased.

## FEATURES

- Blood perfusion in the peripheral vessels of a body organ is analyzed and displayed as a map.



- ROIs can be set on the generated map, and the average CT number in the set ROI can be calculated.



## COMPOSITION

- Software disk ..... 1
- Manuals ..... 1 set

## TERMINOLOGY

Map: Images in which the calculated blood perfusion information is visualized.

TDC curve: Time-density curve indicating the variation in the CT number with time.

## FUNCTIONS

- This software mainly has the following two functions.
- Map generation and display
  - Calculation of the average CT number within an ROI on the map

## Input/Output Data

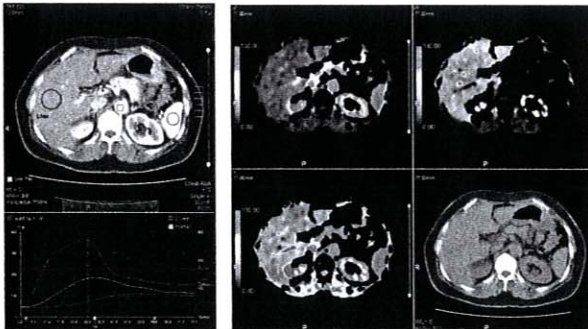
- Input data  
 Time-sequential images obtained by performing a CT examination for the same anatomical region over time using iodinated contrast medium as a tracer.



- Output data
  - Maps
  - Parameters: AF, PF, PI, Flow, Equiv. BV
  - AF: Artery blood flow [mL/min/100 mL]
  - PF: Portal blood flow [mL/min/100 mL]
  - PI: Perfusion index:  $AF/(AF + PF)$  [%]
  - Flow: Equivalent flow value
  - Equiv. BV: Equivalent blood volume
- \* For the organ that does not have a blood supply by the portal vein, the PF and PI values are not calculated.
- Screen save images

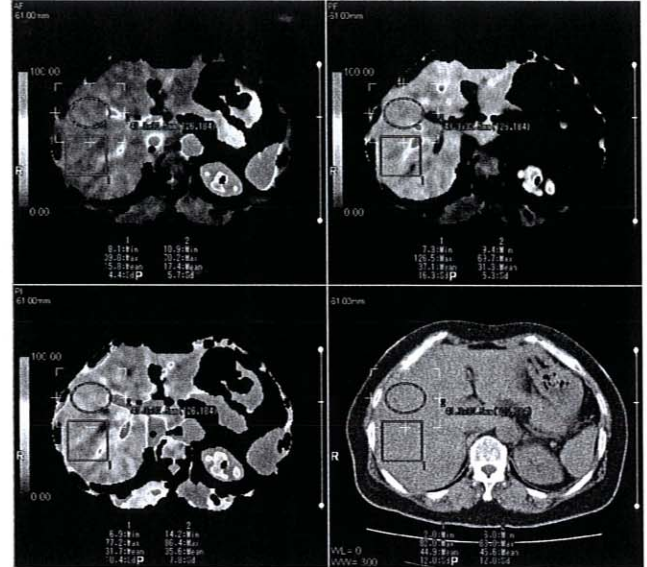
**Map Generation and Display**

- Time-sequential images are displayed.
  - The TDC curves of the artery and the portal vein are generated and displayed by setting ROIs on the target image.
  - Perfusion analysis is performed based on the TDC curves of the artery and the portal vein as input parameters.
  - The analysis results are generated, saved, and displayed as maps.
- Display method: 2D display (axial)  
 Color display of the generated maps is possible.



**Calculation of the Average CT Number Within an ROI on the Map**

- ROIs can be set on the generated map to calculate the average CT number in the set ROI.
- ROIs: Elliptical, rectangular, free, polygonal ROIs



**MASS**

- Mass: 0.1 kg (0.2 lb)

**POWER REQUIREMENTS**

The ratings of the CT system are not changed.

**AMBIENT CONDITIONS**

Same as those for the CT system.



**TOSHIBA MEDICAL SYSTEMS CORPORATION**

<http://www.toshibamedicalsystems.com>

©Toshiba Medical Systems Corporation 2007-2009 all rights reserved.  
 Design and specifications subject to change without notice.

Toshiba Medical Systems Corporation meets internationally recognized standards for Quality Management System ISO 9001, ISO 13485.

Toshiba Medical Systems Corporation Nasu Operations meets the Environmental Management System standard, ISO 14001.

Made for Life and Aquilion are trademarks of Toshiba Medical Systems Corporation.

This document may include trademarks and registered trademarks of

## **12.5 MeVis LiverAnalyser / LiverViewer Software, K051528 510(k) Summary**

K051528



**JUL 20 2005**

510(k) Summary of Safety and Effectiveness

This 510(k) summary of safety and effectiveness information is being submitted in accordance with the requirements of SMDA 1990.

Date Prepared:  
June 5, 2005

Submitter's Information: 21 CFR 807.92(a)(1)  
 Dr. Markus Lang  
 MeVis - Center for Medical Diagnostic Systems and Visualization GmbH  
 Universitätsallee 29  
 D-28359 Bremen, Germany  
 Phone: +49-421-218-2439  
 Fax : +49-421-218-4236  
 E-mail: office@mevis.de

Trade Name, Common Name and Classification: 21 CFR 807.92(a)(2)  
 Trade Name: MeVis LiverAnalyser / LiverViewer Software™  
 Common Name: Picture Archiving Communications System  
 Device Classification: 892.2050 LLZ  
 Name: System, Image Processing

Predicate Device: 21 CFR 807.92(a)(3)

Device Classification Name	System, Image Processing, Radiological	System, Image Processing, Radiological
Regulation Number	892.2050	892.2050
510(k) Number	K022692	K040852
Device Name	VoxelPlus PACS	Preview Treatment Planning Software
Applicant	Mevisys Co. Ltd.	Medical Media Systems, Inc.
Product Code	LLZ	LLZ

Device Description: 21 CFR 807.92(a)(4)  
 MeVis LiverAnalyser / LiverViewer Software™ is a PC-based software application that imports medical images (i.e. CT, MRI modalities) in a DICOM format. The MeVis-LiverAnalyser is used to analyze data for preoperative planning in liver surgery. The MeVis-LiverAnalyser contains dedicated methods for organ segmentation, tumor segmentation, and segmentation of intrahepatic vasculature as well as for the approximation of vascular territories. While using the MeVis-LiverAnalyser a number of masks are produced to merge voxels into sets. Each of this set is meant to represent a specific anatomical entity. All volumes calculated by the MeVis-LiverAnalyser are given directly by the number of voxels in one of these sets multiplied by the voxel volume. No direct measure of anatomical entities is performed.



Indications for Use: 21 CFR 807 92(a)(5)

The MeVis LiverAnalyser / LiverViewer Software™ device is intended for preoperative planning in liver surgery. The device is used to analyze data and to display image analysis and risk analysis results for the preoperative planning in liver surgery, e.g. organ segmentation, tumor segmentation, segmentation of intrahepatic vessels as well as the approximation of vascular territories. Preoperative evaluation of specific surgery strategies is supported by the feature to interactively define virtual resections splitting the liver or to calculate safety-margins around lesions identifying affected vascular branches and vascular territories supplied or drained by these branches.

Medical image data is derived from various sources (i.e. CT scanners, MRI scanners). Typical users of this system are trained professionals, including physicians, nurses, and technicians.

Technological Characteristics: 21 CFR 807 92(a)(6)

MeVis LiverAnalyser / LiverViewer Software™ is a software product that assists surgeons when doing preoperative planning and post-operative follow-up. MeVis LiverAnalyser / LiverViewer Software™ is a PC-based software application that imports medical images (i.e. CT, MRI modalities) in a DICOM format.

The device does not contact the patient, nor does it control any life sustaining devices. A physician, providing ample opportunity for competent human intervention interprets images and information being displayed and printed.

Conclusion: 21 CFR 807 92(b)(1)

The 510 (k) Pre-Market Notification for MeVis LiverAnalyser / LiverViewer Software™ device contains adequate information and data to enable FDA - CDRH to determine substantial equivalence to the predicate device.

MeVis LiverAnalyser / LiverViewer Software™ device has been and will be manufactured in accordance with the voluntary standards listed in the enclosed voluntary standard survey. The submission contains the results of a hazard analysis and the "Level of Concern for potential hazards has been classified as "minor".



Food and Drug Administration  
9200 Corporate Boulevard  
Rockville MD 20850

JUL 20 2005

MeVis – Center for Medical Diagnostic  
Systems and Visualizations GmbH  
% Mr. Carl Alletto  
1600 Manchester Way  
CORINTH TX 76210

Re: K051528  
Trade/Device Name: MeVis LiverAnalyser/  
LiverViewer Software  
Regulation Number: 21 CFR 892.2050  
Regulation Name: Picture archiving and  
communications system  
Regulatory Class: II  
Product Code: LLZ  
Dated: May 11, 2005  
Received: June 15, 2005

Dear Mr. Alletto:

We have reviewed your Section 510(k) premarket notification of intent to market the device referenced above and have determined the device is substantially equivalent (for the indications for use stated in the enclosure) to legally marketed predicate devices marketed in interstate commerce prior to May 28, 1976, the enactment date of the Medical Device Amendments, or to devices that have been reclassified in accordance with the provisions of the Federal Food, Drug, and Cosmetic Act (Act) that do not require approval of a premarket approval application (PMA). You may, therefore, market the device, subject to the general controls provisions of the Act. The general controls provisions of the Act include requirements for annual registration, listing of devices, good manufacturing practice, labeling, and prohibitions against misbranding and adulteration.

If your device is classified (see above) into either class II (Special Controls) or class III (Premarket Approval), it may be subject to such additional controls. Existing major regulations affecting your device can be found in the Code of Federal Regulations, Title 21, Parts 800 to 898. In addition, FDA may publish further announcements concerning your device in the Federal Register.

Please be advised that FDA's issuance of a substantial equivalence determination does not mean that FDA has made a determination that your device complies with other requirements of the Act or any Federal statutes and regulations administered by other Federal agencies. You must comply with all the Act's requirements, including, but not limited to registration and listing (21 CFR Part 807); labeling (21 CFR Part 801); good manufacturing practice requirements as set forth in the quality systems (QS) regulation (21 CFR Part 820); and if applicable, the electronic product radiation control provisions (Sections 531-542 of the Act); 21 CFR 1000-1050.

This letter will allow you to begin marketing your device as described in your Section 510(k) premarket notification. The FDA finding of substantial equivalence of your device to a legally marketed predicate device results in a classification for your device and thus, permits your device to proceed to the market.

If you desire specific advice for your device on our labeling regulation (21 CFR Part 801), please contact the Office of Compliance at one of the following numbers, based on the regulation number at the top of this letter:

21 CFR 876.xxxx	(Gastroenterology/Renal/Urology)	240-276-0115
21 CFR 884.xxxx	(Obstetrics/Gynecology)	240-276-0115
21 CFR 892.xxxx	(Radiology)	240-276-0120
Other		240-276-0100

Also, please note the regulation entitled, "Misbranding by reference to premarket notification" (21 CFR 807.97). You may obtain other general information on your responsibilities under the Act from the Division of Small Manufacturers, International and Consumer Assistance at its toll-free number (800) 638-2041 or (301) 443-6597 or at its Internet address <http://www.fda.gov/cdrh/industry/support/index.html>.

Sincerely yours,



Nancy C. Brogdon  
Director, Division of Reproductive,  
Abdominal, and Radiological Devices  
Office of Device Evaluation  
Center for Devices and Radiological Health

Enclosure

## Indications for Use

510(k) Number (if known): K051528

Device Name: MeVis LiverAnalyzer / LiverViewer Software™ device

### Indications for Use:

The MeVis LiverAnalyzer / LiverViewer Software™ device is intended for preoperative planning in liver surgery. The device is used to analyze data and to display image analysis and risk analysis results for the preoperative planning in liver surgery, e.g. organ segmentation, tumor segmentation, segmentation of intrahepatic vessels as well as the approximation of vascular territories. Preoperative evaluation of specific surgery strategies is supported by the feature to interactively define virtual resections splitting the liver or to calculate safety-margins around lesions identifying affected vascular branches and vascular territories supplied or drained by these branches. Medical image data is derived from various sources (i.e. CT scanners, MRI scanners).

Typical users of this system are trained professionals, including physicians, nurses, and technicians.


Prescription Use    
 (Part 21 CFR 801 Subpart D)

AND/OR

Over-The-Counter Use    
 (21 CFR 807 Subpart C)

(PLEASE DO NOT WRITE BELOW THIS LINE-CONTINUE ON ANOTHER PAGE IF NEEDED)

Concurrence of CDRH, Office of Device Evaluation (ODE)

  
\_\_\_\_\_  
(Division Sign-Off)  
Division of Reproductive, Abdominal,  
and Radiological Devices

## **12.6 MEDIAN Technologies LMS-Liver, K071241 510(k) Summary**



K071241

## 510(k) Summary

### Submitter's Information

JUN - 8 2007

Submitted by MEDIAN Technologies  
 Le Solaris  
 120 rue Albert Caquot  
 06560 Sophia Antipolis France  
 Fax: +33 93 333 777

Contact: Fredrik Brag, CEO  
 Fredrik.brag@mediantechnologies.com  
 Tel: +33 93 333 777

Questions or requests for further information should be addressed to:  
 Michael Auffret, VP Product Management  
 Michael.auffret@mediantechnologies.com  
 Tel: +33 4 92 90 65 84

Date summary was prepared: May 14, 2007

### Name of Device

Proprietary name: LMS-Liver  
 Common name: Image visualization and analysis software package  
 Classification Name: Class II 21 CFR 892.2050 LLZ

### Predicate Devices

<b>Manufacturer:</b>	SIEMENS	CEDARA
<b>Common Name:</b>	Accessory to Computed Tomography X-ray System /II/ 90	Accessory to Computed Tomography X-ray System /II/ 90
<b>Trade Name:</b>	Syngo TrueD software	Cedara I-Response; Cedara PET/CT
<b>510(k) Number:</b>	K061671	K053301

### Device Description

LMS-Liver is an image analysis software application for evaluating CT images covering the liver area. It is designed to assist radiologists in the evaluation and documentation of lesions. It also provides tools for assessment of lesion evolution over time. LMS-Liver offers measurement tools and 3D registration techniques for characterization and follow-up of the lesions. It also offers reporting capabilities making it possible to generate standardized reports. LMS-Liver can segment hepatic lesions identified by the user with a double click (seed point). Once a lesion is segmented, the software computes its characteristics such as size, volume and intensity.

LMS-Liver can match and compare lesions present in two different datasets of the same patient acquired at different dates and compute their difference of size and volume.

**Indication for use**

LMS-Liver is an image analysis software application for evaluating CT images covering the liver area. It is designed to assist radiologists in the evaluation and documentation of lesions. It also provides tools for assessment of lesion evolution over time. LMS-Liver offers measurement tools and 3D registration techniques for characterization and follow-up of the lesions. It also offers reporting capabilities making it possible to generate standardized reports.

LMS-Liver is intended to be used by radiologists and other clinicians qualified to interpret CT images.

LMS-Liver device is designed to be used with CT images covering the liver area in adult patients.

**Substantial Equivalence Comparison Chart**

Manufacturer	Siemens	Cedara	MEDIAN
Product Name	Syngo TrueD software	Cedara I-Response; Cedara PET/CT	LMS-Liver
510(k)	K061671	K053301	
Software only solution	√	√	√
Windows XP operating system	√	√	√
CT scans as Input	√	√	√
Support the oncological workflow by helping the user assess and document morphological changes in therapy follow-up examinations	√	√	√
Compare medical imaging data from different time points	√	√	√
Landmark matching and visual alignment	√	√	√
Lesion comparison over time	√	√	√
Report Generator	√	√	√

## **Safety**

A comprehensive hazard analysis was carried out on MEDIAN Technologies' LMS-Liver software. It concluded that residual risks are acceptable when weighed against the intended benefits of the system.

## **Conclusion**

LMS-Liver software does not raise new safety risks and is equivalent in function to existing legally marketed devices. LMS-Liver software is therefore substantially equivalent with respect to safety and effectiveness to the predicate devices.



Food and Drug Administration  
9200 Corporate Blvd.  
Rockville MD 20850

Median Technologies  
% Mr. Chas Burr  
President  
Chas Burr Q/R Services, Inc.  
11 Mystic Avenue  
WINCHESTER MA 01890-2920

JUN - 8 2007

Re: K071241  
Trade/Device Name: LMS-Liver  
Regulation Number: 21 CFR 892.2050  
Regulation Name: Picture archiving and communications system  
Regulatory Class: II  
Product Code: LLZ  
Dated: April 30, 2007  
Received: May 3, 2007

Dear Mr. Burr:

We have reviewed your Section 510(k) premarket notification of intent to market the device referenced above and have determined the device is substantially equivalent (for the indications for use stated in the enclosure) to legally marketed predicate devices marketed in interstate commerce prior to May 28, 1976, the enactment date of the Medical Device Amendments, or to devices that have been reclassified in accordance with the provisions of the Federal Food, Drug, and Cosmetic Act (Act) that do not require approval of a premarket approval application (PMA). You may, therefore, market the device, subject to the general controls provisions of the Act. The general controls provisions of the Act include requirements for annual registration, listing of devices, good manufacturing practice, labeling, and prohibitions against misbranding and adulteration.

If your device is classified (see above) into either class II (Special Controls) or class III (Premarket Approval), it may be subject to such additional controls. Existing major regulations affecting your device can be found in the Code of Federal Regulations, Title 21, Parts 800 to 898. In addition, FDA may publish further announcements concerning your device in the Federal Register.



Page 2 -

Please be advised that FDA's issuance of a substantial equivalence determination does not mean that FDA has made a determination that your device complies with other requirements of the Act or any Federal statutes and regulations administered by other Federal agencies. You must comply with all the Act's requirements, including, but not limited to: registration and listing (21 CFR Part 807); labeling (21 CFR Part 801); good manufacturing practice requirements as set forth in the quality systems (QS) regulation (21 CFR Part 820); and if applicable, the electronic product radiation control provisions (Sections 531-542 of the Act); 21 CFR 1000-1050.


This letter will allow you to begin marketing your device as described in your Section 510(k) premarket notification. The FDA finding of substantial equivalence of your device to a legally marketed predicate device results in a classification for your device and thus, permits your device to proceed to the market.

If you desire specific advice for your device on our labeling regulation (21 CFR Part 801), please contact the Office of Compliance at one of the following numbers, based on the regulation number at the top of this letter:

21 CFR 876.xxx	(Gastroenterology/Renal/Urology)	240-276-0115
21 CFR 884.xxx	(Obstetrics/Gynecology)	240-276-0115
21 CFR 894.xxx	(Radiology)	240-276-0120
Other		240-276-0100

Also, please note the regulation entitled, "Misbranding by reference to premarket notification" (21CFR Part 807.97). You may obtain other general information on your responsibilities under the Act from the Division of Small Manufacturers, International and Consumer Assistance at its toll-free number (800) 638-2041 or (240) 276-3150 or at its Internet address <http://www.fda.gov/cdrh/industry/support/index.html>.

Sincerely yours,



Nancy C. Brogdon  
Director, Division of Reproductive,  
Abdominal, and Radiological Devices  
Office of Device Evaluation  
Center for Devices and Radiological Health

Enclosure

## Indications for Use

510(k) Number (if known): K071241

Device Name: LMS-Liver

### Indications for Use:

LMS-Liver is an image analysis software application for evaluating CT images covering the liver area. It is designed to assist radiologists in the evaluation and documentation of lesions. It also provides tools for assessment of lesion evolution over time. LMS-Liver offers measurement tools and 3D registration techniques for characterization and follow-up of the lesions. It also offers reporting capabilities making it possible to generate standardized reports.

LMS-Liver is intended to be used by radiologists and other clinicians qualified to interpret CT images.

LMS-Liver device is designed to be used with CT images covering the liver area in adult patients.


Prescription Use X  
(Part 21 CFR 801 Subpart D)

AND/OR

Over-The-Counter Use \_\_\_\_\_  
(21 CFR 801 Subpart C)

(PLEASE DO NOT WRITE BELOW THIS LINE-CONTINUE ON ANOTHER PAGE  
OF NEEDED)

Concurrence of CDRH, Office of Device Evaluation (ODE)

  
\_\_\_\_\_  
(Division Sign-Off)  
Division of Reproductive, Abdominal, and  
Radiological Devices  
510(k) Number K071241

## **12.7 Siemens syngo® Volume Perfusion-CT Neuro, K073238 510(k) Summary**

**SIEMENS**

510(k)

K073238  
Section 8  
Pg. 1 of 3

**510(k) - Summary**

This summary of 510(k) safety and effectiveness information is being submitted in accordance with the requirements of SMDA 1990 and 21 CFR §807.92.

**I. GENERAL INFORMATION**

JAN - 3 2006

**1. Device Name and Classification**

Product Name: **syngo® Volume Perfusion-CT Neuro**  
Classification Name: Accessory to Computed Tomography System  
Classification Panel: Radiology  
CFR Section: 21 CFR §892.1750  
Device Class: Class II  
Product Code: 90 JAK

**2. Importer/Distributor Establishment:**

**Registration Number:** 2240869

Siemens Medical Solutions, Inc.  
51 Valley Stream Pkwy  
Malvern, PA 19355

**3. Manufacturing Facility:**

Siemens AG  
Medical Solutions  
Henkestrasse 127  
D-91052 Erlangen, Germany

**4. Contact Person:**

Mr. Ralf Hofmann  
Regulatory Affairs Specialist  
Siemensstr.1; D-91301 Forchheim  
Phone: +49 9191 18-8170  
Fax: +49 9191 18-9782

**5. Date of Preparation of Summary:** Oct 12<sup>th</sup> 2007





**II. SAFETY AND EFFECTIVENESS INFORMATION SUPPORTING THE SUBSTANTIAL EQUIVALENCE DETERMINATION**

**6. General Safety and Effectiveness Concerns:**

The device labeling contains instructions for use and any necessary cautions and warnings, to provide for safe and effective use of the device.

Risk management is ensured via a hazard analysis, which is used to identify potential hazards. These potential hazards are controlled via software development, verification and validation testing. To minimize electrical, mechanical, and radiation hazards, Siemens adheres to recognized and established industry practice and standards.

**7. Substantial Equivalence:**

The **syngo<sup>®</sup> Volume Perfusion-CT Neuro** software package that is addressed in this premarket notification, is substantially equivalent to the following commercially available software package

<u>Manufacturer</u>	<u>Product</u>	<u>510(k)</u>	<u>Clearance date</u>
1. Siemens	syngo Perfusion-CT	K033832	12/23/2003
2. Siemens	syngo Perf. CT Body	K050867	04/14/2005
3. General Electric	CT Perfusion 4	K052839	03/10/2006

**8. Device Description and Intended Use:**

*syngo<sup>®</sup> Volume Perfusion-CT Neuro* is a post-processing software package, which runs on an Intel-based PC platform designed to post-process images acquired with SOMATOM CT scanners, which meet certain minimal requirements (i.e. Siemens Definition, Sensation 64, ...). It is a package containing evaluation software that supports the evaluation of Dynamic CT data gathered after the injection of a compact bolus of contrast media, where the contrast media acts as a pure intravascular tracer.

The Siemens *syngo<sup>®</sup> Volume Perfusion-CT Neuro* software package has been designed to evaluate areas of brain perfusion. The software can calculate cerebral blood flow (CBF), cerebral blood volume (CBV), local bolus timing (i.e. time to start, time to peak), mean transit time (MTT), and vascular permeability (blood brain barrier disturbances) from sets of images or volumes reconstructed from continuously acquired CT data after the injection of contrast media. The package also allows the calculation of mirrored regions or volumes of interest and the visual inspection of time attenuation curves.

K073238  
Pg. 3 of 3  
510(k)

# SIEMENS

One clinical application is to visualize the apparent blood perfusion in brain tissue affected by acute stroke. Areas of decreased perfusion, as is observed in acute cerebral infarcts, appear as areas of changed signal intensity (lower for CBF and CBV, higher for time to peak and MTT).

*Syngo*<sup>®</sup> Volume Perfusion-CT Neuro supports the physician in identifying areas of decreased perfusion which indicate the occurrence of acute stroke during the first 6 hours after onset of symptoms.

A second application is the visualization of the permeability. It is used for the modeling of extra-vascular leakage of blood into the interstitial space. This additional capability can display blood brain barrier disturbances and thus may improve the differential diagnosis of brain tumors and be helpful in therapy monitoring.



Food and Drug Administration  
9200 Corporate Boulevard  
Rockville MD 20850

JAN - 3 2008

Siemens AG Medical Solutions  
% Mr. Olaf Teichert  
Responsible Third Party Official  
TÜV SÜD America  
1775 Old Hwy 8 NW, Ste 104  
NEW BRIGHTON MN 55112-1891

Re: K073238

Trade/Device Name: syngo<sup>®</sup> Volume Perfusion-CT Neuro  
Regulation Number: 21 CFR 892.1750  
Regulation Name: Computed tomography x-ray system  
Regulatory Class: II  
Product Code: JAK  
Dated: December 10, 2007  
Received: December 14, 2007

Dear Mr. Teichert:

We have reviewed your Section 510(k) premarket notification of intent to market the device referenced above and have determined the device is substantially equivalent (for the indications for use stated in the enclosure) to legally marketed predicate devices marketed in interstate commerce prior to May 28, 1976, the enactment date of the Medical Device Amendments, or to devices that have been reclassified in accordance with the provisions of the Federal Food, Drug, and Cosmetic act (Act) that do not require approval of a premarket approval application (PMA). You may, therefore, market the device, subject to the general controls provisions of the Act. The general controls provisions of the Act include requirements for annual registration, listing of devices, good manufacturing practice, labeling, and prohibitions against misbranding and adulteration.

If your device is classified (see above) into either class II (Special Controls) or class III (PMA), it may be subject to such additional controls. Existing major regulations affecting your device can be found in the Code of Federal Regulations, Title 21, Parts 800 to 898. In addition, FDA may publish further announcements concerning your device in the Federal Register.

Please be advised that FDA's issuance of a substantial equivalence determination does not mean that FDA has made a determination that your device complies with other requirements of the Act or any Federal statutes and regulations administered by other Federal agencies. You must comply with all the Act's requirements, including, but not limited to: registration and listing (21 CFR Part 807); labeling (21 CFR Part 801); good manufacturing practice requirements as set forth in the quality systems (QS) regulation (21 CFR Part 820); and if applicable, the electronic product radiation control provisions (Sections 531-542 of the Act); 21 CFR 1000-1050.

This letter will allow you to begin marketing your device as described in your Section 510(k) premarket notification. The FDA finding of substantial equivalence of your device to a legally marketed predicate device results in a classification for your device and thus, permits your device to proceed to the market.

If you desire specific advice for your device on our labeling regulation (21 CFR Part 801), please contact the Center for Devices and Radiological Health's (CDRH's) Office of Compliance at one of the following numbers, based on the regulation number at the top of this letter.

21 CFR 876.xxxx	(Gastroenterology/Renal/Urology)	240-276-0115
21 CFR 884.xxxx	(Obstetrics/Gynecology)	240-276-0115
21 CFR 892.xxxx	(Radiology)	240-276-0120
Other		240-276-0100

Also, please note the regulation entitled, "Misbranding by reference to premarket notification" (21CFR Part 807.97). For questions regarding postmarket surveillance, please contact CDRH's Office of Surveillance and Biometric's (OSB's) Division of Postmarket Surveillance at 240-276-3474. For questions regarding the reporting of device adverse events (Medical Device Reporting (MDR)), please contact the Division of Surveillance Systems at 240-276-3464. You may obtain other general information on your responsibilities under the Act from the Division of Small Manufacturers, International and Consumer Assistance at its toll-free number (800) 638-2041 or (240) 276-3150 or at its Internet address <http://www.fda.gov/cdrh/industry/support/index.html>.

Sincerely yours,



Nancy C. Brogdon  
Director, Division of Reproductive,  
Abdominal, and Radiological Devices  
Office of Device Evaluation  
Center for Devices and Radiological Health

Enclosure

# SIEMENS

Section 2

Indication for use

510(k) Number (if known): K073238

Device Name: **syngo® Volume Perfusion-CT Neuro**

The Siemens *syngo*® Volume Perfusion-CT Neuro software package has been designed to evaluate areas of brain perfusion. The software can calculate cerebral blood flow (CBF), cerebral blood volume (CBV), local bolus timing (i.e. time to start, time to peak), mean transit time (MTT), and vascular permeability (blood brain barrier disturbances) from sets of images or volumes reconstructed from continuously acquired CT data after the injection of contrast media. The package also allows the calculation of mirrored regions or volumes of interest and the visual inspection of time attenuation curves.

One clinical application is to visualize the apparent blood perfusion in brain tissue affected by acute stroke. Areas of decreased perfusion, as is observed in acute cerebral infarcts, appear as areas of changed signal intensity (lower for CBF and CBV, higher for time to peak and MTT).

*Syngo*® Volume Perfusion-CT Neuro supports the physician in identifying areas of decreased perfusion which indicate the occurrence of acute stroke during the first 6 hours after onset of symptoms.

A second application is the visualization of the permeability. It is used for the modeling of extra-vascular leakage of blood into the interstitial space. This additional capability can display blood brain barrier disturbances and thus may improve the differential diagnosis of brain tumors and be helpful in therapy monitoring.

Prescription Use   X   AND/OR Over-The-Counter Use \_\_\_\_\_  
(Part 21 CFR 801 Subpart D) (21 CFR 801 Subpart C)

(PLEASE DO NOT WRITE BELOW THIS LINE-CONTINUE ON ANOTHER PAGE OF NEEDED)

Concurrence of CDRH, Office of Device Evaluation (ODE)

Nancy C Brogdon  
(Division Sign-Off)  
Division of Reproductive, Abdominal, and  
Radiological Devices

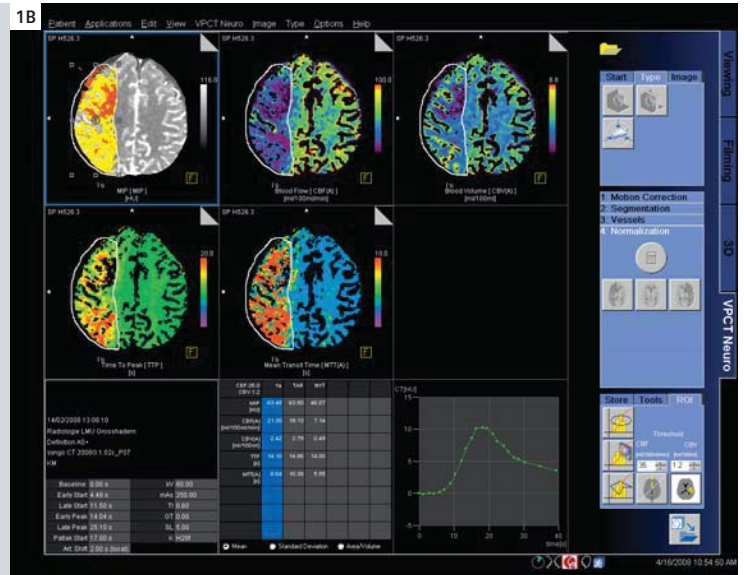
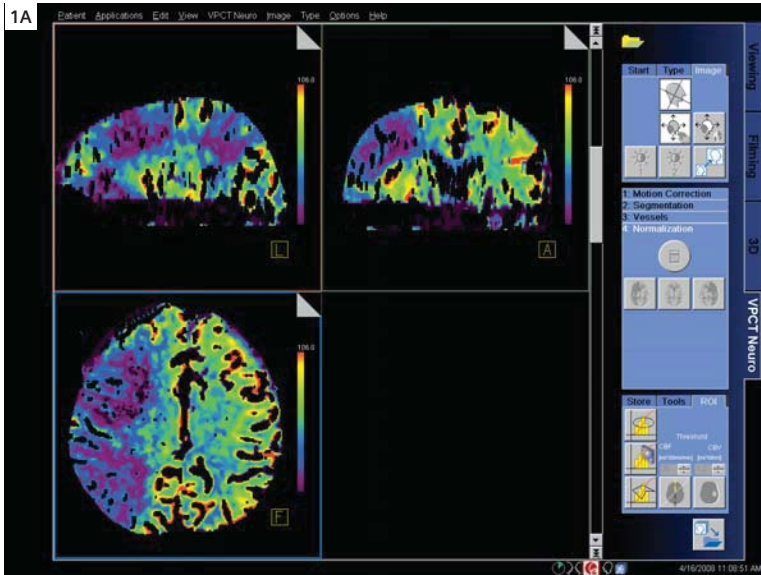
**12.8 Morhard, Vasospasm after SAH: Neuro Volume  
Perfusion CT, SOMATOM Sessions-Siemens  
Healthcare Magazine (May 2008)**

# Case 7

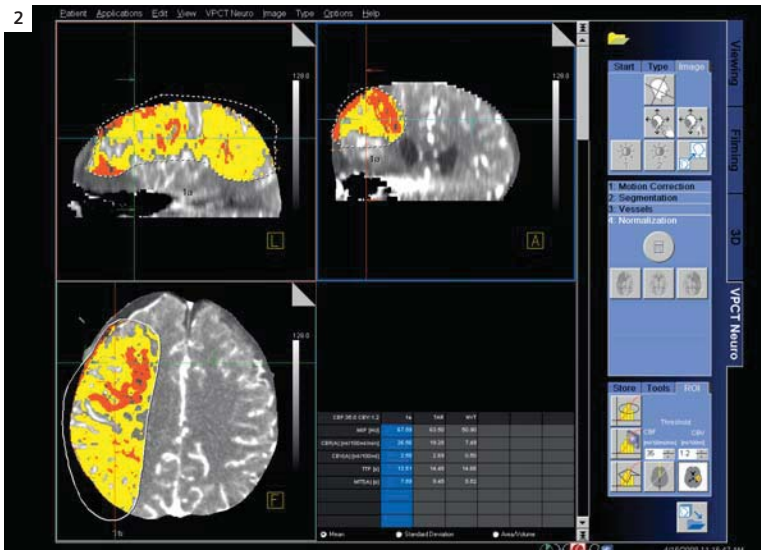
## Vasospasm After SAH: Neuro Volume Perfusion CT

By Dominik Morhard, MD

Department of Clinical Radiology, University of Munich, Campus Grosshadern, Munich, Germany



1 3D view of cerebral blood flow (CBF) of the entire brain\* (Fig. 1A). VPCT-Neuro post-processing visualizing maximum intensity projections (MIP, top left), cerebral blood flow (CBF top middle), cerebral blood volume (CBV, top right), time to peak (TTP, lower left), mean transit time (MTT, lower middle) color-coded parameter maps (Fig. 1B).



2 syngo Volume Perfusion CT - Neuro allows for 3 dimensional evaluation of tissue at risk, mapping infarcted tissue (core infarct) as red, and penumbra as yellow, colored overlays.

### EXAMINATION PROTOCOL

<b>Scanner</b>	SOMATOM Definition AS+
<b>Scan area</b>	Head
<b>Scan length</b>	100 mm (VPCT)
<b>Scan time</b>	40 s, one scan every 1.5 s (26 scans)
<b>Scan direction</b>	Adaptive 4D Spiral
<b>Tube voltage</b>	80 kV
<b>Tube current</b>	200 eff. mAs
<b>Rotation time</b>	0.3 s
<b>Spatial resolution</b>	0.33 mm
<b>Slice collimation</b>	128 x 0.6 mm
<b>Slice width</b>	1.0 mm
<b>CTDI<sub>vol</sub></b>	189.63 mGy (VPCT) 54, 34 mGy (Head)
<b>Reconstruction kernel</b>	H20f
<b>Contrast</b>	
<b>Volume</b>	50 ml Enhance / 50 ml NaCl
<b>Start delay</b>	5 s
<b>Postprocessing</b>	syngo Volume Perfusion CT – Neuro (VPCT-Neuro)

\*requires Adaptive 4D Spiral technology

## HISTORY

A 70-year-old female patient was admitted to the emergency room with a suspected subarachnoidal hemorrhage (SAH). Initial non-enhanced cranial CT (NECT) noted a small subarachnoidal bleeding in the sylvian fissure on the right side. On intracranial CT-angiography (CTA) a giant aneurysm (17 x 11 mm) of the right middle cerebral artery (MCA) was detected. The patient was transferred to the neurosurgery department for aneurysm clipping therapy. Due to massive calcifications at the neck of the aneurysm, no appropriate position of the aneurysm clip could be achieved. Two days later the patient underwent endovascular coil embolization of the MCA aneurysm. On the sixth day after SAH, duplex sonography revealed high flow rates of the intracranial arteries and the patient was referred to the radiology department for comprehensive stroke imaging, including NECT and Volume-Perfusion-CT (VPCT) of the brain to rule out vasospasm.

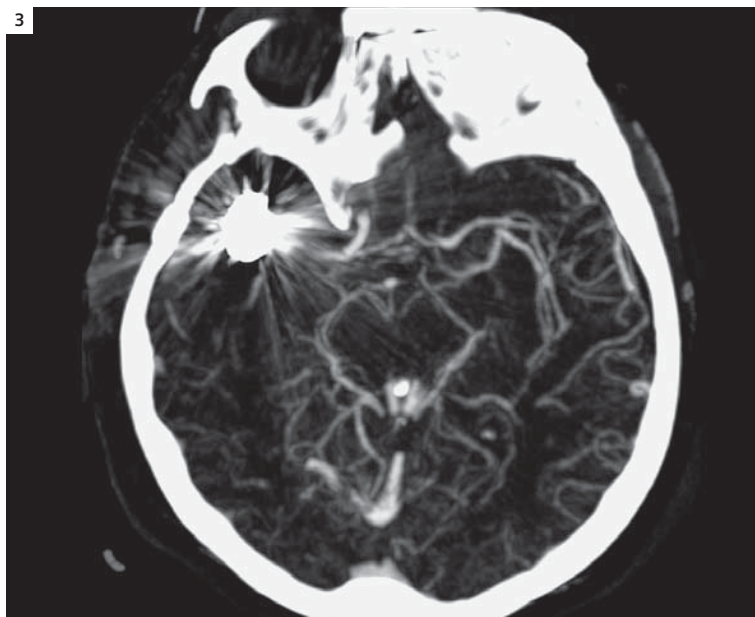
## DIAGNOSIS

On NECT, small subterritorial infarctions could be delineated on the right hemisphere. VPCT demonstrated an impaired brain perfusion of large parts of the right hemisphere with prolonged mean transit time (MTT), lowered cerebral blood flow (CBF) and lowered cerebral blood volume (CBV). 2dimensional (D) and 3D quantitative assessment of the perfusion parameter maps (Figs. 1 and 2) showed small irreversible infarcted and large potential reversible ischemic parts (penumbra) of the brain parenchyma. Cerebral vasospasm six days after subarachnoidal hemorrhage have been detected. Anti vasospasm therapy was immediately intensified. NECT and VPCT on the next day revealed no additional infarctions and a normalization of the brain perfusion values could be detected.

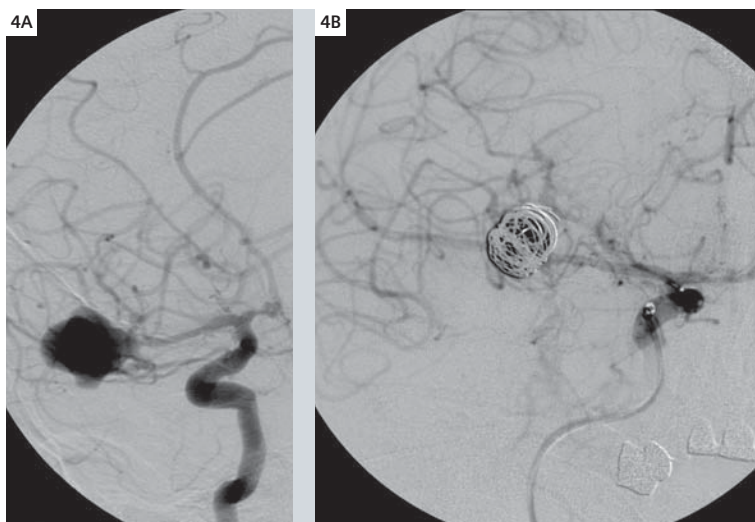
## COMMENT

VPCT – Neuro offers dynamic perfusion analysis of the entire brain. In contrast to standard perfusion CT in which only small volumes of 1-4 cm width – traditionally at the base of skull – can be investigated, now subsegmental and sub-

cortical infarctions can be visualized at nearly every location of the brain, and we were able to show for the first time 3 dimensional tissue at risk (penumbra) evaluation indicating the full impact of stroke in the whole brain.



**3** MIP at the circulus of willis: Artifacts due to aneurysm coils at the MCA bifurcation.



**4** DSA: Before endovascular coil embolisation (Fig. 4A) and after embolisation (Fig. 4B). DSA-Images courtesy of Department of Neuroradiology, University of Munich, Germany.



**12.9 Wintermark, Prognostic Accuracy of Cerebral Blood Flow Measurement by Perfusion Computed Tomography, Annals of Neurology (2002)**

# Prognostic Accuracy of Cerebral Blood Flow Measurement by Perfusion Computed Tomography, at the Time of Emergency Room Admission, in Acute Stroke Patients

Max Wintermark, MD,<sup>1</sup> Marc Reichhart, MD,<sup>2</sup> Jean-Philippe Thiran, PhD,<sup>3</sup> Philippe Maeder, MD,<sup>1</sup> Marc Chalaron, MD,<sup>1</sup> Pierre Schnyder, MD,<sup>1</sup> Julien Bogousslavsky, MD,<sup>2</sup> and Reto Meuli, MD, PhD<sup>1</sup>

The purpose of this study was to determine the prognostic accuracy of perfusion computed tomography (CT), performed at the time of emergency room admission, in acute stroke patients. Accuracy was determined by comparison of perfusion CT with delayed magnetic resonance (MR) and by monitoring the evolution of each patient's clinical condition. Twenty-two acute stroke patients underwent perfusion CT covering four contiguous 10mm slices on admission, as well as delayed MR, performed after a median interval of 3 days after emergency room admission. Eight were treated with thrombolytic agents. Infarct size on the admission perfusion CT was compared with that on the delayed diffusion-weighted (DWI)-MR, chosen as the gold standard. Delayed magnetic resonance angiography and perfusion-weighted MR were used to detect recanalization. A potential recuperation ratio, defined as  $PRR = \text{penumbra size} / (\text{penumbra size} + \text{infarct size})$  on the admission perfusion CT, was compared with the evolution in each patient's clinical condition, defined by the National Institutes of Health Stroke Scale (NIHSS). In the 8 cases with arterial recanalization, the size of the cerebral infarct on the delayed DWI-MR was larger than or equal to that of the infarct on the admission perfusion CT, but smaller than or equal to that of the ischemic lesion on the admission perfusion CT; and the observed improvement in the NIHSS correlated with the PRR (correlation coefficient = 0.833). In the 14 cases with persistent arterial occlusion, infarct size on the delayed DWI-MR correlated with ischemic lesion size on the admission perfusion CT ( $r = 0.958$ ). In all 22 patients, the admission NIHSS correlated with the size of the ischemic area on the admission perfusion CT ( $r = 0.627$ ). Based on these findings, we conclude that perfusion CT allows the accurate prediction of the final infarct size and the evaluation of clinical prognosis for acute stroke patients at the time of emergency evaluation. It may also provide information about the extent of the penumbra. Perfusion CT could therefore be a valuable tool in the early management of acute stroke patients.

Ann Neurol 2002;51:417-432

Stroke is the third-leading cause of death in the United States, after cardiovascular disease and cancer. Each year in the United States, it affects 730,000 to 760,000 patients, a third of whom will be permanently disabled, and thus represents the leading cause of disability in the country.<sup>1,2</sup> Thrombolysis has been introduced as a new therapy for acute stroke,<sup>3</sup> but present indications for intravenous thrombolytic therapy depend on the time interval since the onset of symptoms (less than 3 hours) and noncontrast cerebral computed tomography (CT) findings (absence of cerebral hemorrhage and extent of the cerebral hypodensity).<sup>1,3,4</sup> Evaluation of brain perfusion prior to thrombolysis has been suggested as a possible selection criterion for treatment,

since extensive infarct and little salvageable penumbra in the territory of an occluded middle cerebral artery (MCA) seem to be linked to an unfavorable risk-benefit ratio.<sup>4-9</sup> The aim of thrombolysis is to save ischemic but still-viable cerebral parenchyma.<sup>10</sup>

Viability of the cerebral parenchyma depends on the cerebral blood flow (CBF).<sup>11-13</sup> Multiple thresholds describing the progressive inhibition of the electrical and metabolic activity of neurons have been defined in various animal species.<sup>13-15</sup> Soon after cerebral arterial occlusion, reversible inhibition or penumbra occurs in the cerebral parenchyma territory that is usually perfused by this artery; then, starting from the center of the arterial territory, infarct progressively replaces pen-

From the Departments of <sup>1</sup>Diagnostic and Interventional Radiology and <sup>2</sup>Neurology, CHUV, Lausanne, Switzerland, and the <sup>3</sup>Signal Processing Laboratory, Swiss Federal Institute of Technology, Lausanne, Switzerland.

Received Mar 12, 2001, and in revised form Jul 30 and Nov 26. Accepted for publication Nov 29, 2001.

Address correspondence to Dr Bogousslavsky, Department of Neurology, CHUV-BH10, 1011 Lausanne, Switzerland.  
E-mail: Julien.Bogousslavsky@chuv.hospvd.ch

umbra at a rate that depends on the degree of collateral circulation.<sup>13-18</sup>

An additional major difference between cerebral penumbra and infarct relates to cerebral perfusion autoregulation. Complex autoregulation processes ensure both the adjustment of regional cerebral blood flows (rCBF) to local neuronal activity and CBF stability, despite changes in systemic arterial pressure. Vascular autoregulation in the brain causes vascular dilatation when the systemic pressure falls, thus maintaining a constant CBF. This vascular dilatation leads, in turn, to an increased regional cerebral blood volume (rCBV), which some authors equate with penumbra.<sup>19-23</sup> In infarcted cerebral parenchyma, the autoregulation mechanisms are altered, and both the rCBF and rCBV are usually decreased.<sup>8,9</sup> Penumbra and infarct maps can thus be inferred from rCBV and rCBF maps and could perhaps be used as an additional criterion to decide whether an acute stroke patient should be included in a thrombolysis protocol, since thrombolysis performed on patients with extensive cerebral infarct and a limited penumbra would not only be of little benefit, but also increase the risk of intracranial bleeding.<sup>8-10</sup>

#### *Perfusion Computed Tomography Technology*

Various imaging techniques are now available to evaluate brain perfusion; these include perfusion CT.

Perfusion CT is a modern imaging technique that allows accurate quantitative assessment of rCBF and rCBV.<sup>24-26</sup> It can be performed on acute stroke patients, since it involves only the sequential acquisition of cerebral CT images performed in cine mode during the intravenous administration of iodinated contrast material. It is well tolerated and not time-consuming, and can be integrated into the cerebral CT survey undergone by all stroke patients.<sup>24-27</sup> Except for dedicated software, no special equipment is required. Perfusion CT data consist of contrast enhancement profiles obtained in each pixel; these profiles are linearly related to the time-concentration curves for the contrast material. Analysis of these curves is performed according to the central volume principle, which is reported to give the most accurate results for low injection rates of iodinated contrast material.<sup>28-33</sup> The rCBV map is calculated from a quantitative estimation of the partial size averaging effect, which is completely absent in a reference pixel at the center of the large superior sagittal venous sinus.<sup>34-38</sup> The impulse function and the related mean transit time (MTT) maps result from a deconvolution of the parenchymal time-concentration curves by a reference arterial curve. Finally, the rCBF value can be calculated from the rCBV and MTT values for each pixel using the following simple equation:<sup>31,32</sup>

$$rCBF = \frac{rCBV}{MTT}$$

#### *Hypotheses*

Our purpose was to perform perfusion CT on acute stroke patients at the time of emergency room admission; to define rCBV, MTT, and rCBF maps; and to calculate penumbra and infarct maps according to the above-described principles. Assuming that thrombolysis can salvage the penumbra but not the infarct,<sup>10</sup> we tried to answer two questions:

- (1) *What is the accuracy of admission perfusion CT in predicting infarcted cerebral areas?* We tried to answer this question by comparing the admission perfusion CT results with the final size of the cerebral infarct defined by delayed diffusion-weighted magnetic resonance (DWI-MR). DWI-MR does not provide information on the rCBF, but rather on the functional condition of cerebral neurons (microscopic proton diffusion, altered, for example, by cytotoxic edema), and has been shown to be accurate in the delineation of the nature and size of brain ischemia and in the quantification of tissue in the moderate-to-advanced stages of injury.<sup>8</sup> In order to avoid pitfalls related to biphasic phenomena,<sup>39,40</sup> DWI-MR performed a few days after the stroke was chosen as the reference for the final cerebral infarct size.
- (2) *What is the potential predictive value of the relative sizes of the penumbra and infarct in terms of clinical improvement?* Clinical improvement was evaluated on admission and a median of 1 month later (interquartile range, 0.825-1.625 months) using the National Institutes of Health Stroke Scale (NIHSS), which has been proven to provide an accurate assessment of stroke severity.<sup>41-43</sup> We hypothesize that, in a patient with an extensive infarct and a relatively small penumbra, thrombolysis would salvage little and clinical improvement would be poor. On the other hand, in a patient with an extensive penumbra and a small infarct, recanalization of the occluded cerebral artery would lead to greater clinical improvement.

## **Patients and Methods**

### *Patients*

Our series consisted of 22 adults (13 men and 9 women; average age, 63 years; age range, 31-85 years) with an acute ischemic stroke diagnosed on the basis of clinical and non-contrast CT data. These patients were prospectively identified in the Emergency Department of our institution during the period of March to December 2000. The patients' char-

acteristics, the exact location of the ischemic stroke, use of thrombolysis, and recanalization of the occluded cerebral artery are summarized in Table 1.

In all 22 patients, noncontrast baseline cerebral CT was immediately followed by perfusion CT, this being part of the initial routine survey of acute stroke patients at our institution. Twelve of the patients also underwent a cerebral and cervical angio-CT. Eight of the 22 patients were eligible for intravenous thrombolytic therapy. Thrombolysis was begun at a median of 3 hours (interquartile range, 2.625–3 hours) after the stroke onset. No complications, particularly no hemorrhages, occurred in the 8 thrombolized patients; but 15 days after the stroke onset, 1 patient died of septicemia following pulmonary infection.

After a median of 3 days (interquartile range, 3–4 days; median [interquartile range], 3 [3–4.75] days for the thrombolysis group and 3 [2.25–3] days for the nonthrombolysis group;  $p = 0.209$ ) after admission, an MR examination, including T2 and DWI series, as well as cerebral and cervical angio-MR, were performed on each of the 22 patients.

In addition to the admission CT and delayed MR, two patients underwent a second cerebral CT survey before the MR. These sequential perfusion CT and MR examinations demonstrated the evolution of the penumbra over time, with and without arterial recanalization (Figs 1 and 2).

The time intervals between stroke onset and admission to the emergency room, perfusion CT, beginning of thrombolysis, and delayed MR were recorded. The permeability of the cerebral and cervical vessels was assessed from the admission angio-CT and delayed angio-MR.

In the surviving 21 patients, the NIHSS, Barthel index,

and modified Rankin scale were used to evaluate clinical condition both at the time of admission and after a median of 1 month (interquartile range, 0.825–2.625 months) (median [interquartile range], 1.4 [1.075–2.875] months for the thrombolysis group and 1 [0.475–1.325] month for the nonthrombolysis group;  $p = 0.298$ ). The improvement in the NIHSS between admission and at a median of 1 month (interquartile range, 0.825–2.625 months) was used to evaluate clinical improvement.

For the patient who died of septicemia 15 days after stroke onset, a delayed MR was performed on day 5 and was included in the comparison with admission perfusion CT. The patient was assigned delayed Barthel and modified Rankin indices of 0 and 6, respectively. However, this patient was not included in the comparison of NIHSS improvement, which would have given a negative value (19 on admission and 42 in the final function outcome analysis).

### Imaging Techniques

The perfusion CT examination consisted of two 40-second series separated by 5 minutes, each series consisting of one image per second in cine mode during intravenous administration of iodinated contrast material. The acquisition parameters for both series were 80kVp and 100mA.<sup>44</sup> For each series, CT scanning was initiated 7 seconds after injection of 50ml of iohexol (300mg/ml of iodine; Accupaque 300, Nycomed, Oslo, Norway) at a rate of 5ml per second into an antecubital vein using a power injector (CT9000; Libel-Flarsheim Company, Cincinnati, OH). The delay before the arrival of the contrast material allowed baseline images with-

Table 1. Characteristics of the 22 Patients with Acute Stroke Who Underwent Both Admission Perfusion CT and Delayed MR

Patient no.	Age (yrs)	Gender	Location of the Ischemic Stroke on the DWI-MR	Thrombolysis	Recanalization of the Occluded Cerebral Artery
1	68	M	Superficial posterior left MCA	No	Yes
2	54	M	Left MCA	Yes	Yes
3(†)	84	F	Superficial and deep left MCA	Yes	Yes
4	51	F	Superficial left MCA	No	Yes
5	51	F	Deep posterior right MCA	No	Yes
6	76	F	Superficial anterior right MCA	No	Yes
7	46	F	Posterior right MCA	No	No
8	78	M	Basilar artery	Yes	Yes
9	71	M	Superficial posterior left MCA	Yes	Yes
10	71	M	Posterior left MCA	Yes	Yes
11	61	M	Superficial right MCA	Yes	No
12	43	F	Left MCA	No	No
13	31	M	Anterior right MCA	No	No
14	50	M	Posterior left MCA	No	Yes
15 (see Fig. 1)	74	F	Anterior right MCA	No	Yes
16	85	F	Superficial anterior left MCA	No	No
17	68	M	Superficial left MCA	Yes	Yes
18	75	M	Right MCA	Yes	No
19	33	M	Right MCA	No	No
20	80	F	Right MCA	No	Yes
21	61	M	Posterior right MCA	No	Yes
22 (see Fig. 2)	83	M	Left MCA	No	No

†Deceased.

CT = computed tomography; DWI-MR = diffusion-weighted magnetic resonance; MCA = middle cerebral artery.

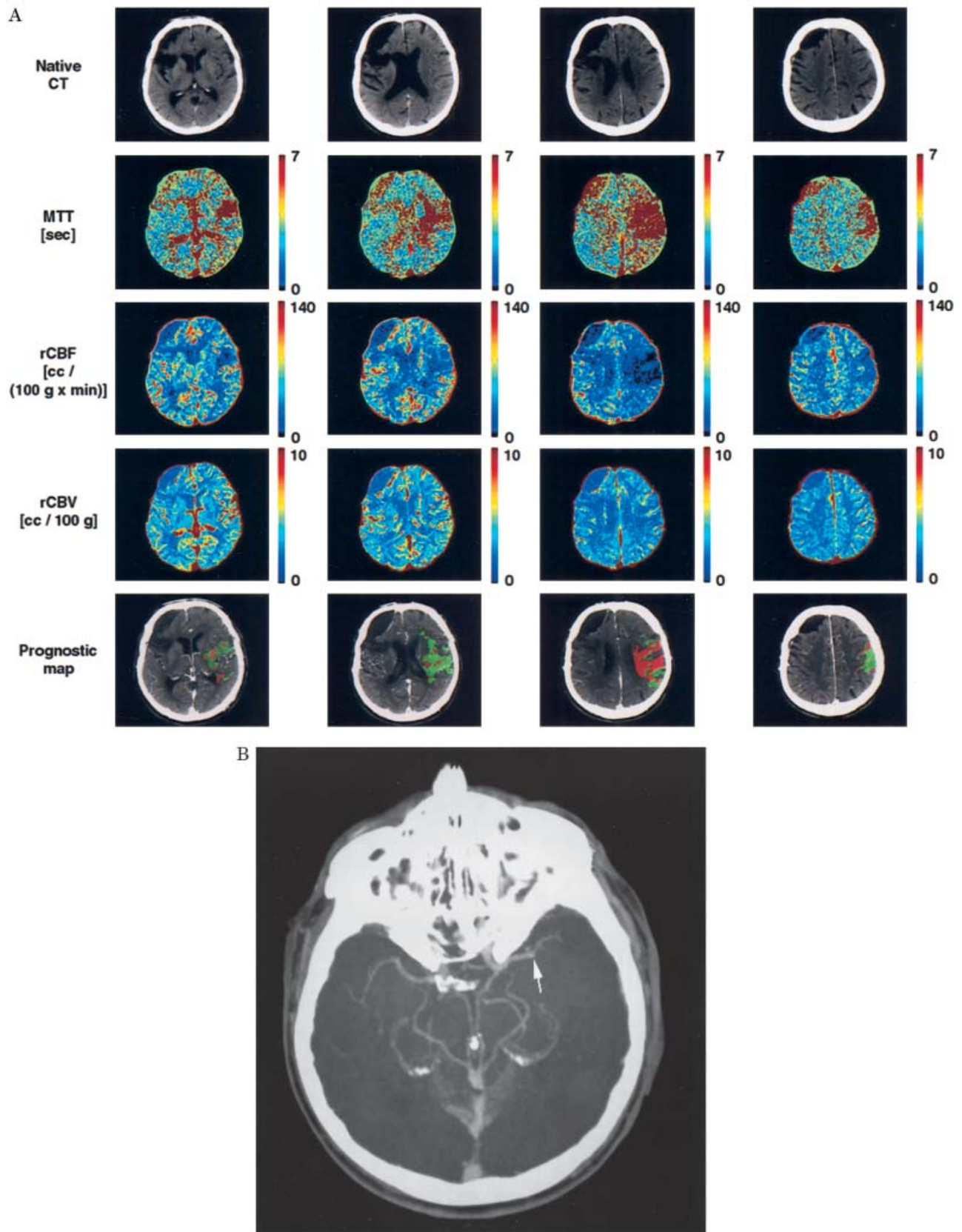


Figure 1

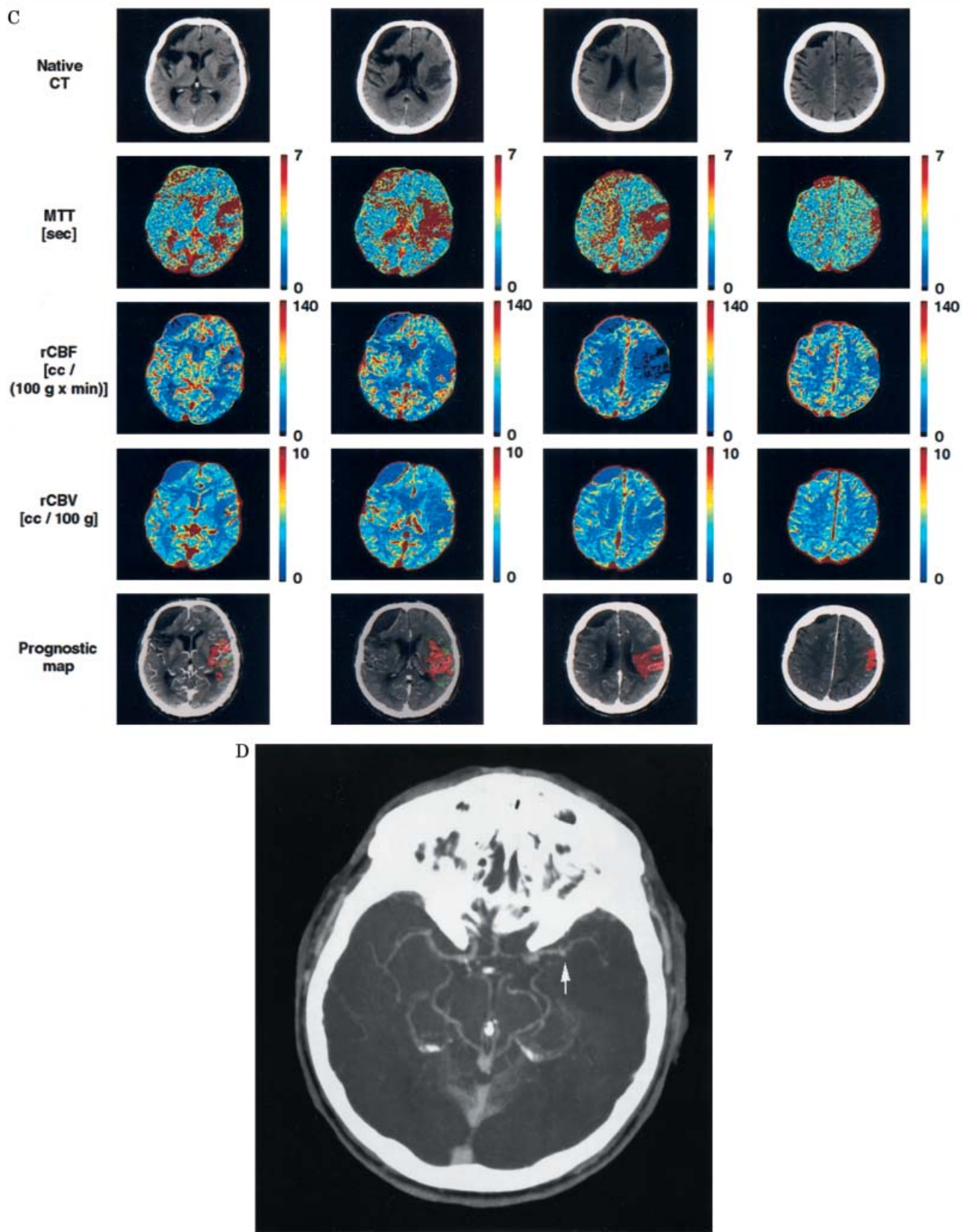
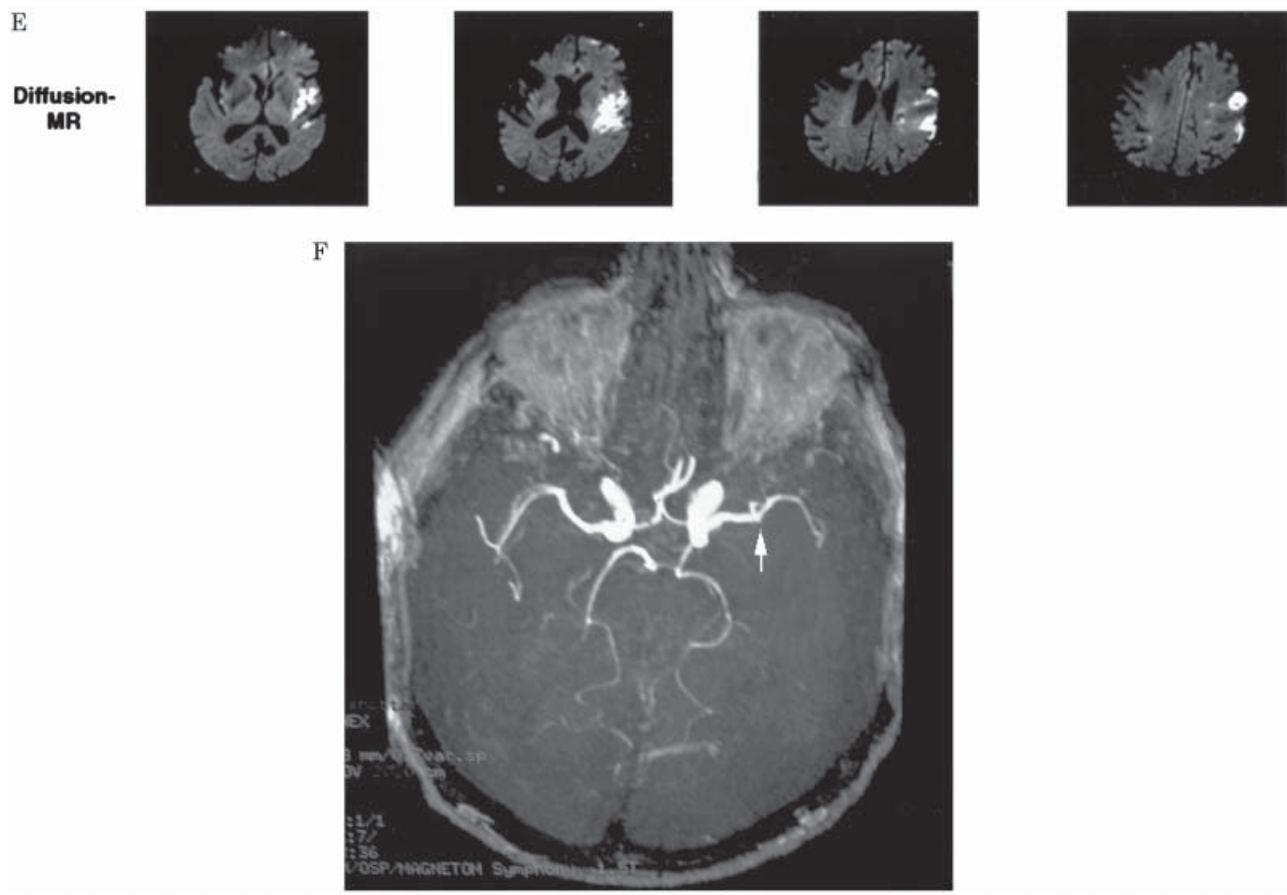


Figure 1 (Continued)



*Fig 1. (Continued) Progression of the infarct over the penumbra in a case of persistent cerebral arterial occlusion. The patient was a male age 83 years with suspected anterior left sylvian artery stroke. (A) The noncontrast cerebral computed tomography (CT) (first line) obtained at the time of emergency room admission, 7 hours after stroke onset, showed an old right frontal lesion and slight left insula ribbon sign, whereas the more sensitive perfusion CT prognostic map (fifth line) identified a deep left middle cerebral artery (MCA) ischemia, with an infarct (red) component located on the left semioval center and a penumbra (green) lying on the left internal capsula, insula, and parietal operculum. The mean transit time (MTT) (second line) and regional cerebral blood flow (rCBF) (third line) were increased and decreased, respectively, in both the infarct and penumbra, whereas the regional cerebral blood volume (rCBV) (fourth line) was decreased in the infarct and either preserved or increased in the penumbra, due to autoregulation processes. (B) The admission angio-CT maximum intensity projection (MIP) displayed the occluded left MCA responsible for the reported cerebral ischemia. No thrombolysis was performed due to the time delay. (C) Worsening of the clinical condition justified the performance of a second CT 28 hours after the first. The noncontrast cerebral CT (first line) demonstrated a cerebral infarct in the exact location reported on the first perfusion CT. The perfusion CT prognostic map (fifth line) disclosed almost complete replacement of the first perfusion CT penumbra (green) by infarct (red). (D) The second angio-CT explained these findings by persistent occlusion of the left MCA. (E) Six days after admission, diffusion-weighted magnetic resonance (DWI-MR) demonstrated the cerebral infarct, which closely correlated with that described on the second perfusion CT prognostic map. (F) The persistent occlusion of the left MCA was confirmed by angio-MR.*

out contrast enhancement to be acquired. Multidetector-array technology (Lightspeed CT unit; General Electrics, Milwaukee, WI) allowed the acquisition of data from two adjacent 10mm sections for each series. The two perfusion CT series thus allowed the acquisition of data for four adjacent 10mm cerebral CT sections. The four studied cerebral sections were chosen above the orbits to protect the lenses, passing through the basal nuclei, then towards the vertex.

The cerebral and cervical angio-CT were performed using the parameters 120kVp, 240mAs, slice thickness 2.5mm,

slice acquisition interval 2mm, pitch 1.5:1, HS mode, intravenous administration of 50ml of iodinated contrast material at a rate of 3ml per second, and an acquisition delay of 10 seconds. Data acquisition was performed from the origin of the aortic arch branch vessels to the circle of Willis.

After a median of 3 days (interquartile range, 3–4 days) (median [interquartile range], 3.5 [3–4.75] days for the thrombolysis group and 3 [2.25–3] days for the nonthrombolysis group;  $p = 0.209$ ) after admission, an MR examination was performed on all 22 patients using a 1.5T MR unit

(Symphony MR unit; Siemens, Erlangen, Germany). This included spin-echo T2-weighted series and DWI series (echoplanar spin-echo, TR = 5,000msec, TE = 100msec, b = 1,000, 20 5mm thick slices with a 1.5mm gap, matrix size = 128 × 128). Angio-MR was performed using a time-of-flight multislab 3-D FLASH technique for cerebral and cervical vessels. A 3-D FISP technique during the intravenous administration of a bolus of gadolinium was also used for cervical vessels.

This study protocol was approved by our review board, and institutional informed consent guidelines were followed.

### Data Processing

The perfusion CT data were transferred to an SG1 Onyx workstation (Silicon Graphics, Mountain View, CA) and analyzed using perfusion analysis software to create parametric maps of rCBV, MTT, and rCBF. The penumbra and infarct maps calculated as follows: An ischemic cerebral area (penumbra + infarct) was defined as including cerebral pixels with a greater than 34% decrease in rCBF compared with the corresponding region in the cerebral hemisphere, defined as healthy on the basis of clinical symptomatology. In this selected area, 2.5ml per 100g was chosen as the rCBV threshold, in agreement with published data suggesting that cerebral parenchyma below this rCBV level is highly likely to die.<sup>13,19,20,49-51</sup> Again, within this selected area, pixels with rCBV values higher or lower than 2.5ml per 100g were attributed, respectively, to the penumbra or the infarct. The resultant cerebral penumbra and infarct maps were combined and graphically displayed as a prognostic map, with the infarct shown in red and the penumbra in green (see Figs 1 and 2). Four cerebral sections in the DWI-MR sequence were selected as corresponding most closely to the chosen perfusion CT sections. The infarcted cerebral area on the DWI-MR images was defined as including all pixels above an intensity threshold, in order to exclude the contralateral hemisphere and choroidal plexi from the infarcted area, since the stroke was unilateral in all 22 patients.

### Data Analysis

For each patient, the final results included four perfusion CT penumbra maps, four perfusion CT infarct maps, and four

DWI-MR infarct maps (see Figs 1 and 2). The DWI-MR sections examined were selected at approximately the same level as the perfusion CT sections. Analysis of perfusion CT infarct and penumbra maps was performed in two ways:

- (1) The perfusion CT infarct and penumbra maps were first used to measure the size of the predicted infarcted area in cm<sup>2</sup>. The size of the final infarcted area was measured on the corresponding sections of the DWI-MR, regarded as the gold standard for statistical analysis. Linear regression analysis and bilateral T-tests for matched variables were used to compare infarct sizes on the corresponding sections of the perfusion CT and DWI-MR. Statistically significant *p* values were lower than 0.05.
- (2) The perfusion CT penumbra and infarct maps were used to calculate a potential recuperation ratio (PRR), using the following equation;

$$\text{PRR} = \frac{\text{penumbra size}}{\text{penumbra size} + \text{infarct size}}$$

A PRR was determined for each of the four slices and a mean PRR calculated for each patient.

Correlations between the admission NIHSS and the size of the ischemic cerebral area on the admission perfusion CT; among the infarct sizes on the delayed DWI-MR and the delayed NIHSS, Barthel index, and modified Rankin score; and between the NIHSS improvement and the PRR were evaluated by linear regression analysis, with calculation of Pearson's linear correlation coefficients.

## Results

### Time Delays

The median time from stroke onset to emergency room admission was 1.875 (interquartile range, 1.5–4.875) hours (median [interquartile range], 1.5 [1.5–1.5] hours for the thrombolysis group and 4.5 [2.875–6] hours for the nonthrombolysis group; *p* = 0.009),

*Fig 2. Recovery of the penumbra in a case of cerebral arterial recanalization. The patient was a female age 74 years with anterior right sylvian artery stroke suspected on the basis of the physical examination 5 hours after symptomatology onset. (A) The noncontrast cerebral computed tomography (CT) obtained at the same time (first line) demonstrated a subtle corticomedullary dedifferentiation on the head of the right caudate nucleus, whereas the more sensitive perfusion CT prognostic map (second line) clearly identified a deep right middle cerebral artery (MCA) ischemia, with an infarct (red) component located on the head of the right caudate nucleus and a penumbra (green) lying on the right internal capsula and lenticulate nucleus. (B) Admission angio-CT maximum intensity projection displayed the occluded right MCA responsible for the reported cerebral ischemia. No thrombolysis was performed due to the time delay. The evolution of the clinical condition was favorable, but a generalized seizure occurred 7 hours after the first CT, which justified the performance of a second CT (C) to rule out a reperfusion hemorrhage. The noncontrast cerebral CT (first line) did not display any extension of the ischemic territory depicted in (A). The perfusion CT prognostic map (second line) showed limited progression of the infarct (red) over the first perfusion CT penumbra, whereas the penumbra (green) had mostly resolved. (D) The second angio-CT explained these findings by right MCA recanalization, which occurred some time after the first CT; this time delay allowed for the observed progression of the infarct. Immediately after recanalization, infarct progression over the penumbra was stopped and the residual penumbra recovered. (E) Three days after admission, diffusion-weighted magnetic resonance (DWI-MR) demonstrated the residual infarct, which closely correlated with that described on the second perfusion CT prognostic map. (F) Right MCA recanalization was again demonstrated by delayed angio-MR.*



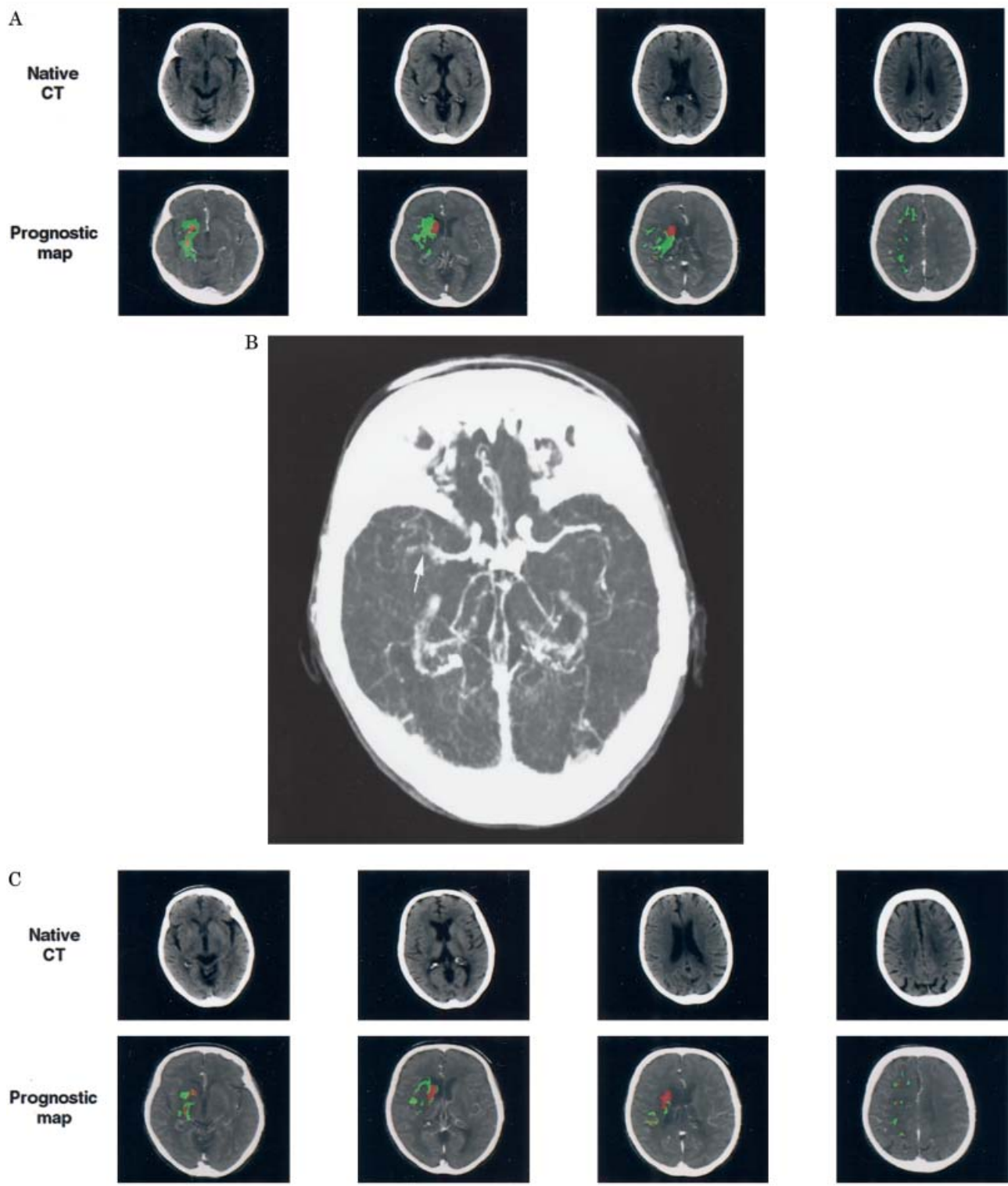


Figure 2

while the median time from stroke onset to perfusion CT scanning was 3.25 (2–6) hours (median [interquartile range], 2 [2–2] hours for the thrombolysis group and 6 [3.25–8] hours for the nonthrombolysis

group;  $p = 0.010$ ). The perfusion CT examinations were well tolerated by all 22 patients and added only 10 minutes to the time required for the admission cerebral CT survey.

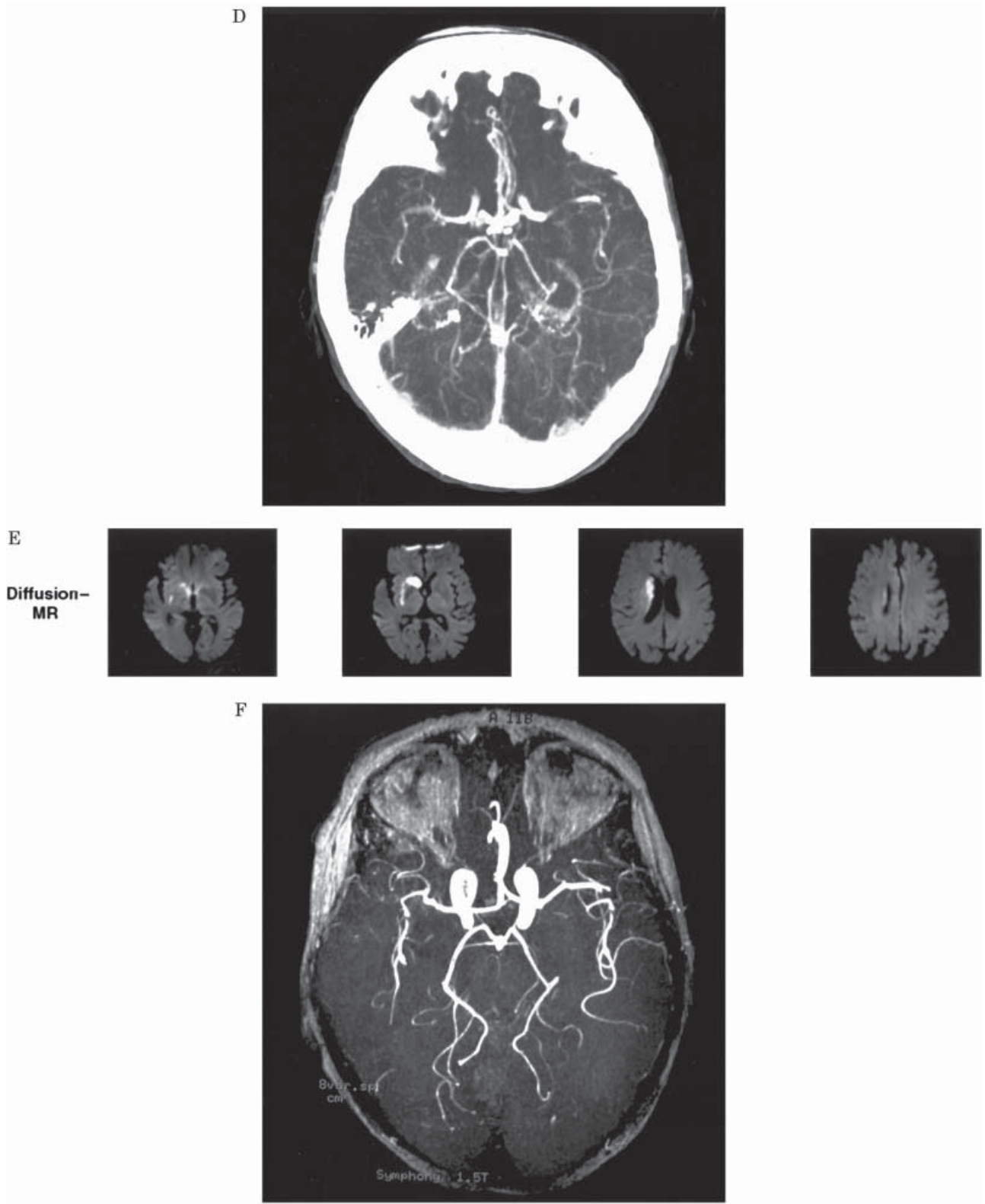


Table 2. Overview of NIHSS Evolution Over a Median of 1 Month (Interquartile Range, 0.825–1.625 Months) and of the Potential Recuperation Ratio in 22 Patients

Arterial Recanalization Status	Thrombolysis	No Thrombolysis
Arterial recanalization	5 patients (+ 1 death) Time to hospital admission = 1.5 (1.125–1.5) hours <sup>a</sup> Time to thrombolysis = 3 (2.75–3) hours <sup>a</sup> PRR = 81% ± 16% <sup>b</sup> NIHSS improvement = 74% ± 20% <sup>b</sup>	8 patients Time to hospital admission = 3.75 (2.25–4.875) hours <sup>a</sup> PRR = 71% ± 11% <sup>b</sup> NIHSS improvement = 62% ± 20% <sup>b</sup>
No arterial recanalization	2 patients Time to hospital admission = 2 (2–2) hours <sup>a</sup> Time to thrombolysis = 2.725 (2.625–2.825) hours <sup>a</sup> PRR = 69% ± 15% <sup>b</sup> NIHSS improvement = 55% ± 19% <sup>b</sup>	6 patients Time to hospital admission = 6 (4–7.5) hours <sup>a</sup> PRR = 60% ± 12% <sup>b</sup> NIHSS improvement = 42% ± 12% <sup>b</sup>

<sup>a</sup>Time delays are expressed as the median and interquartile range.

<sup>b</sup>Percentages are expressed as the mean ± standard deviation.

PRR = potential recuperation ratio; NIHSS = clinical condition of patients, measured with the National Institutes of Health Stroke Scale.

*Arterial Recanalization or Persistent Arterial Occlusion*

In the 8 patients who underwent admission angio-CT, the procedure demonstrated an occluded cerebral artery. The delayed angio-MR, performed on all 22 patients, allowed evaluation of potential recanalization of the occluded cerebral artery, which occurred either spontaneously or as a result of thrombolytic therapy (Table 2). In 8 patients (2 patients in the thrombolysis group and 6 in the nonthrombolysis group), angio-MR demonstrated persistence of arterial occlusion. Of the 8

patients with an occluded artery on the admission angio-CT, 5 showed recanalization on the delayed angio-MR, whereas 3 showed persistent occlusion.

*Correlation between Admission Perfusion Computed Tomography and Delayed Diffusion-Weighted Magnetic Resonance Results*

In patients with a persistent occluded cerebral artery on the delayed angio-MR (Figs 1 and 3), the mean size of the ischemic lesion (infarct + penumbra) on the admission perfusion CT was 37.8 ± 15.5 cm<sup>2</sup> (mean ±

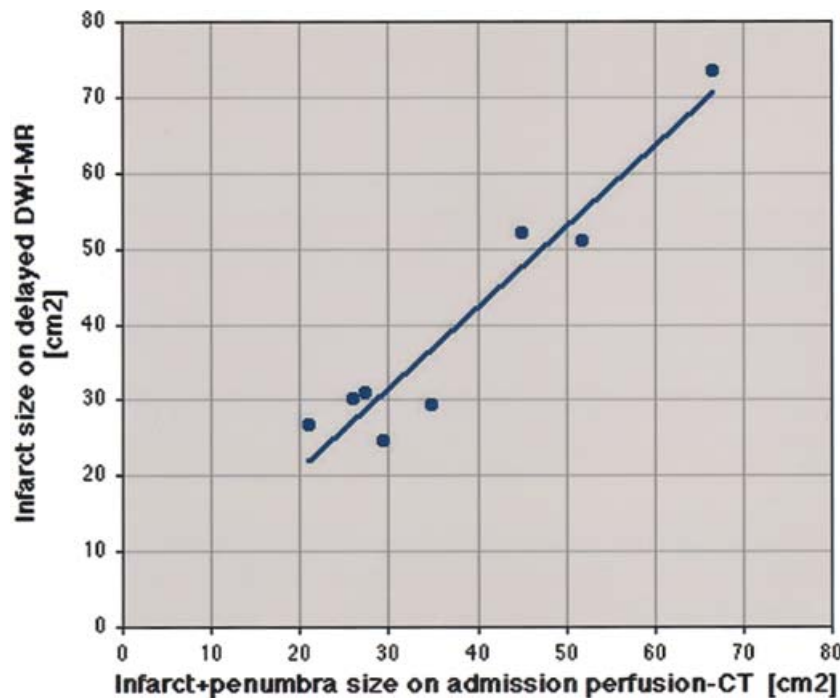


Fig 3. Relationship between ischemic lesion sizes on the perfusion computed tomography (CT) performed at the time of emergency room admission and delayed diffusion-weighted magnetic resonance (DWI-MR) in acute stroke patients without arterial recanalization. In patients with persistent arterial occlusion, the size of the cerebral infarct on the delayed DWI-MR strongly correlated ( $DWI-MR^{infarct} = 3.659 + 0.861 \times_{perfusion\ CT}^{infarct + penumbra}$ ;  $r = 0.958$ ,  $p < 0.001$ ) and showed no statistically significant difference ( $p = 0.332$ ) with the size of the total ischemic area on the admission perfusion CT. In these patients, the penumbra defined on the admission perfusion CT gradually evolved towards infarct, with the entire cerebral ischemic area gradually becoming infarct, due to the prolongation of the arterial occlusion, thus explaining the observed distribution.

standard deviation), whereas the mean size of the infarct on the delayed DWI-MR series was  $39.7 \pm 17.3 \text{ cm}^2$ . No significant difference was seen between these significantly correlated values ( $_{\text{DWI-MR}}\text{infarct} = 3.659 + 0.861 \times \text{perfusion}_{\text{CT}}\text{infarct} + \text{penumbra}$ ; correlation coefficient = 0.958;  $p < 0.001$ ).

In all patients with a recanalized cerebral artery on the delayed angio-MR (Figs 2 and 4), the cerebral infarct on the delayed DWI-MR (mean  $\pm$  standard deviation,  $21.3 \pm 18.6 \text{ cm}^2$ ) was larger than or the same size as the infarct on the admission perfusion CT ( $12.0 \pm 11.1 \text{ cm}^2$ ), but smaller than or the same size as the ischemic lesion on the admission perfusion CT ( $41.3 \pm 12.7 \text{ cm}^2$ ). Infarct size on the delayed DWI-MR was, on average, 22.6% of the range defined by the admission perfusion CT. Infarct sizes on the admission perfusion CT and on the delayed DWI-MR were significantly correlated ( $_{\text{DWI-MR}}\text{infarct} = -0.568 \pm 0.753 \times \text{perfusion}_{\text{CT}}\text{infarct}$ ;  $r = 0.926$ ;  $p < 0.001$ ).

In patients with either arterial recanalization or persistent occlusion, the shape of the infarct or infarct-penumbra areas was similar on perfusion CT and DWI-MR images, as demonstrated in Figures 1 and 2.

*Correlation between Perfusion Computed Tomography Results and Clinical Condition*

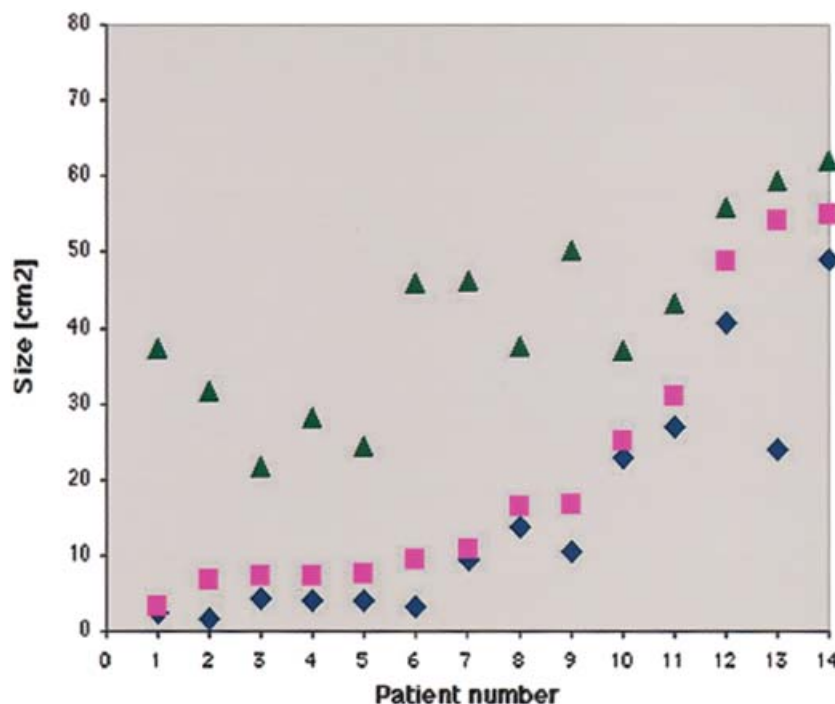
The admission NIHSS increased with the initial size of the combined infarct and penumbra areas on the admission perfusion CT ( $_{\text{admission}}\text{NIHSS} = 5.953 + 0.222 \times \text{perfusion}_{\text{CT}}\text{infarct} + \text{penumbra}$ ;  $r = 0.627$ ;

$p = 0.002$ ) (Fig 5). However, there was no significant correlation between the size of the final cerebral infarct, as defined on the delayed DWI-MR, and the delayed NIHSS ( $r = 0.587$ ;  $p = 0.054$ ), Barthel index ( $r = 0.302$ ;  $p = 0.171$ ), or modified Rankin score ( $r = 0.538$ ;  $p = 0.114$ ).

Finally, the PRR was distributed as follows (see Table 2): In 6 patients in whom thrombolysis was not performed and the delayed angio-MR revealed a persistent occluded cerebral artery, the NIHSS improvement was  $42 \pm 12\%$  (mean  $\pm$  standard deviation) and the PRR  $60 \pm 12\%$ . In 8 patients in whom thrombolysis was not performed and arterial recanalization was diagnosed on the delayed angio-MR, the NIHSS improvement was  $62 \pm 20\%$  and the PRR  $71 \pm 11\%$ . In 5 patients in whom thrombolysis was performed and resulted in recanalization, the NIHSS improvement was  $74 \pm 20\%$  and the PRR  $81 \pm 16\%$ . In 2 patients in whom thrombolysis was performed but did not result in arterial recanalization, the NIHSS improvement was  $55 \pm 19\%$  and the PRR amounted to  $69 \pm 15\%$ .

Of the patients who underwent thrombolysis, a lower but nonsignificant NIHSS improvement of  $55\% \pm 19\%$  was seen in those with a persistent occluded cerebral artery compared with those with recanalization ( $74\% \pm 20\%$ ) ( $p = 0.354$ ). This was associated with a lower but nonsignificant PRR ( $p = 0.297$ ).

In patients with recanalization of the occluded cerebral artery, either spontaneous or consecutive to thrombolysis, there was a strong correlation between



*Fig 4. Correlation between ischemic lesion sizes on the admission perfusion computed tomography (CT) and delayed diffusion-weighted magnetic resonance (DWI-MR) in acute stroke patients with arterial recanalization. In all patients with a recanalized cerebral artery on the delayed angio-MR, the size of the final cerebral infarct defined on the delayed DWI-MR was larger than or the same size as the infarct on the admission perfusion CT, but smaller than or the same size as the ischemic lesion on the admission perfusion CT. This was probably related to the evolution of the infarct over the penumbra as defined on the admission perfusion CT until arterial recanalization occurred, followed by recovery of the remaining penumbra. ◆ Infarct on admission perfusion CT; ■ infarct on delayed DWI-MR; ▲ infarct + penumbra on admission perfusion-CT.*

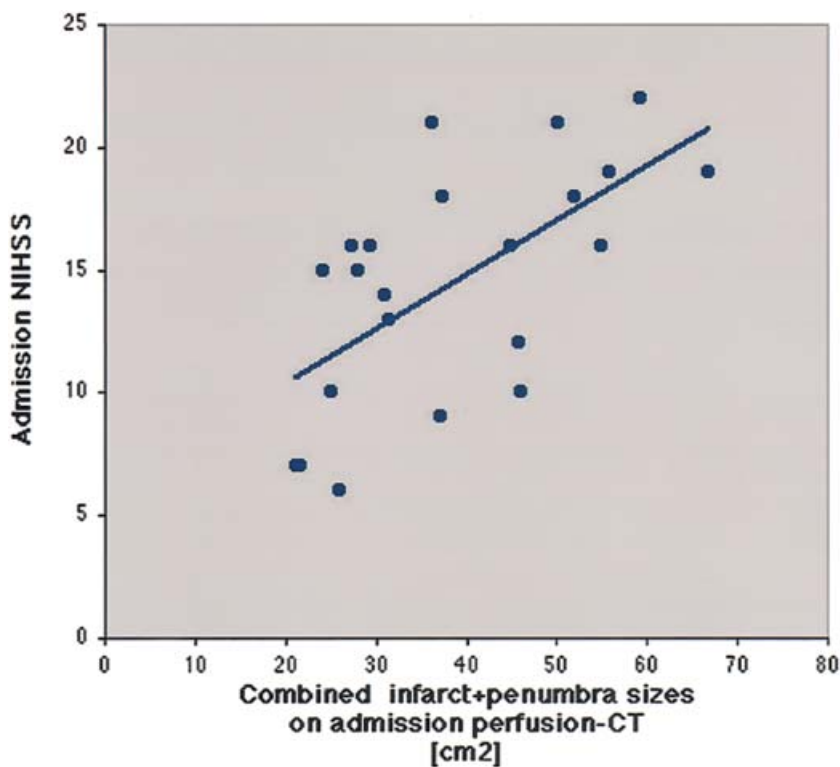


Fig 5. Correlation between the clinical condition of patients at the time of emergency room admission, measured with the National Institutes of Health Stroke Scale (NIHSS), and combined infarct-penumbra size on the admission perfusion computed tomography (CT) ( $r = 0.627$ ,  $p = 0.002$ ). The admission NIHSS increased concomitantly with the initial size of the combined infarct and penumbra areas on the admission perfusion CT ( $_{admission}NIHSS = 5.953 + 0.222 \times \text{perfusion-CT infarct} + \text{penumbra}$ ); the more extensive the initial ischemic cerebral area, the worse the clinical condition, especially on admission. At later clinical time points, neural repair and neuroplasticity allowed various degrees of improvement to occur in different patients, explaining the poorer correlation between the size of the cerebral infarct by delayed diffusion-weighted magnetic resonance (DWI-MR) and the clinical scores.

the PRR and the improvement in the NIHSS evaluated on admission and after a median of 1 month (interquartile range, 0.825–1.625 months) (NIHSS im-

provement =  $0.108 + 0.863 \times \text{perfusion CT-PRR}$ ;  $r = 0.833$ ;  $p = 0.001$ ; Fig 6).

In patients with a persistent occluded cerebral artery,

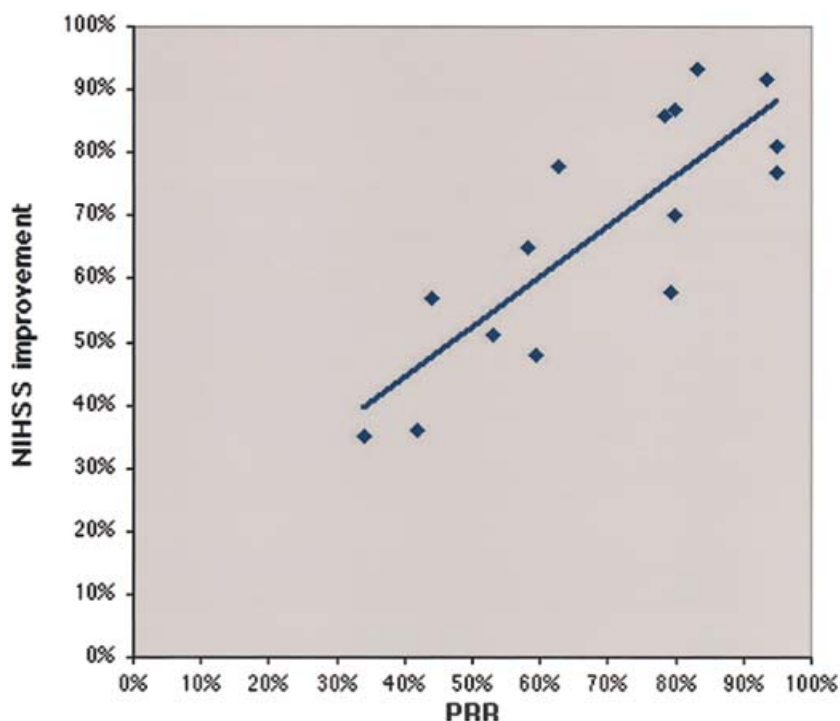


Fig 6. Correlation between the potential recuperation ratio (PRR) and improvement in clinical condition measured with the National Institutes of Health Stroke Scale (NIHSS) in acute stroke patients with arterial recanalization. In patients with recanalization of the occluded cerebral artery, there was a strong correlation between the PRR and improvement in the NIHSS evaluated on admission and after a median delay of 1 (interquartile range, 0.825–2.625 months) (NIHSS improvement =  $0.108 + 0.863 \times \text{perfusion CT-PRR}$ ;  $r = 0.833$ ,  $p = 0.001$ ). In these patients, recanalization, whether spontaneous or after thrombolysis, allowed the penumbra to be salvaged, with subsequent proportional improvement in the patients' clinical condition.

the NIHSS improvement was globally poorer ( $45 \pm 15\%$ ; mean  $\pm$  standard deviation) than in the recanalization group ( $67 \pm 20\%$ ) ( $p = 0.059$ ), and the PRR significantly lower ( $60 \pm 12\%$  vs  $71 \pm 11\%$ ;  $p = 0.005$ ). In the persistent occlusion group, there was no correlation between NIHSS improvement and PRR (NIHSS improvement =  $0.769 - 0.106 \times$  perfusion CT-PRR;  $r = 0.111$ ;  $p = 0.859$ ).

### Discussion

Perfusion CT examinations are not time-consuming, since they can be integrated into the cerebral CT survey performed on every stroke patient, and are well tolerated.<sup>24</sup> In most hospitals, CT units are available 24 hours a day, 7 days a week. The intravenous administration of nonionic iodinated contrast material involved is easily performed, even in acute stroke patients.<sup>45</sup>

The radiation dose in a perfusion CT study is equivalent to that in a standard cerebral CT examination. For the acquisition of four adjacent 10mm sections at 80kVp, the measured normalized and weighted CT dose index (nCTDIw) amounts to 0.112mGy/mAs. For a perfusion CT protocol of 40 successive slices performed in cine mode at 100mA and with the geometry of radiation delivery on the Lightspeed CT unit (dose efficiency of 86%), the radiation dose amounts to 368mGy. To estimate the stochastic effect of the radiation, these doses must be distributed over the entire brain. Since a 40mm thickness ( $4 \times 10$ mm sections) is approximately equal to one-fifth of the whole cerebral size, the absorbed dose to the brain is 77mGy. Using a weighting factor of 0.0023mSv/(mGy  $\times$  cm) for the brain, the cerebral effective dose is 3.4mSv, which is quite similar to the dose level for a standard cerebral CT examination (2.5mSv).<sup>44,46,47</sup>

Perfusion CT examination with data analysis according to the central volume principle<sup>48</sup> allows accurate quantitative assessment of both the rCBF and the rCBV<sup>24</sup> as well as definition of the cerebral infarct and penumbra, as described above. Our proposed method for the calculation of cerebral penumbra and infarct maps from the rCBF and rCBV maps provided by perfusion CT data analysis relies on (1) the reported rCBF threshold of ischemia and (2) preserved (penumbra) or altered (infarct) autoregulatory mechanisms. In the penumbra, the rCBV is greater than 2.5ml per 100g, whereas in the infarcted area it is less. In agreement with the values most frequently reported in the literature,<sup>13,19,20,49-51</sup> we arbitrarily chose a relative rCBF cutoff of 34% and an absolute rCBV cutoff of 2.5ml per 100g as indicative of ischemic brain and of cerebral parenchyma highly likely to die, respectively.

Although the MTT is affected at an earlier stage by cerebral ischemia, it is less specific and we therefore chose an rCBF threshold, rather than an MTT thresh-

old, to determine the total ischemic area (infarct and penumbra). Indeed, soon after the onset of ischemia, the MTT is prolonged and the rCBV is increased as a result of cerebral vascular autoregulation. If both increase by the same proportion, the rCBF, which is equal to the rCBV divided by the MTT, is unchanged, and thus there is no real cerebral parenchymal damage.

### *Correlation between Admission Perfusion Computed Tomography and Delayed Diffusion-Weighted Magnetic Resonance Results*

In terms of the comparison between admission perfusion CT and delayed DWI-MR, our results underscore the excellent prognostic value of admission perfusion CT as regards the final size of the cerebral infarct, defined by reference DWI-MR sequences. As explained above, DWI-MR has been shown to accurately delineate the cerebral infarct.<sup>5,8,52</sup> In order to avoid pitfalls related to biphasic phenomena,<sup>39,40</sup> we chose to use the DWI-MR results obtained at a median of 3 days (interquartile range, 3-4 days) after stroke as a reference.

Eight of the 22 acute stroke patients showed persistent arterial occlusion, and in 2 of them thrombolytic therapy was unsuccessful. In these patients with persistent arterial occlusion, the penumbra defined on the admission perfusion CT gradually evolved towards infarct; due to prolongation of the arterial occlusion, the entire cerebral ischemic area became infarcted with time (see Fig 2). Thus, the size of the combined cerebral infarct and penumbra on the admission perfusion CT and the size of the cerebral infarct on the delayed MR were closely correlated and not statistically different (see Fig 4).

Fourteen of our 22 acute stroke patients showed recanalization of the occluded cerebral artery; 6 of them had received thrombolytic therapy, while recanalization was spontaneous in the other 8 patients. In patients with recanalization of the occluded cerebral artery (see Fig 3), the cerebral infarct on the delayed DWI-MR was larger than or the same size as the infarct on the admission perfusion CT, but smaller than or the same size as the ischemic lesion on the admission perfusion CT. More precisely, its average was located at 22.6% of the range defined by the sizes of the cerebral infarct and ischemia on the admission perfusion CT. This was probably due to the gradual replacement of the penumbra by infarct (particularly marked in Patient 13; see Fig 4) until arterial recanalization, followed by recovery of the remaining penumbra (see Fig 1). Significant correlation was identified between the infarct sizes on the admission perfusion CT and on the delayed DWI-MR, in agreement with a previous report of patients with documented recanalization during intra-arterial thrombolysis.<sup>53</sup>

Two objections could be raised to our study proto-

col. First, the four examined cerebral slices were not exactly the same in the perfusion CT and DWI-MR, as there was an interval of several days between the two examinations. However, for each patient, we performed an averaging of the ischemic areas calculated on four adjacent slices, thus decreasing the inaccuracy due to the same slices not being used. Second, the precise moment of recanalization of the occluded cerebral artery could not be accurately determined from the admission perfusion CT and delayed DWI-MR. However, it was impossible to repeat the imaging examinations of all the acute stroke patients, the exceptions being those cases in which clinical evolution made it mandatory (see Figs 1 and 2).

Finally, our choice of cerebral DWI-MR as the reference for the final infarct size is justified by reports of its accuracy in the delineation of the nature and size of brain ischemia and the quantification of tissue in moderate-to-advanced stages of injury.<sup>5,8,52,54-57</sup> We decided to use delayed DWI-MR in order to avoid controversy related to biphasic phenomena, which were reported during the early phase after stroke.<sup>39,40</sup> We did not evaluate the use of perfusion MR, which only allows semiquantitative assessment of rCBF,<sup>58</sup> preventing the use of thresholds.

#### *Correlation between Perfusion Computed Tomography Results and Patients' Clinical Condition*

In the first part of the study, we demonstrated a correlation between the ischemic cerebral areas estimated by two imaging techniques, the reference method (DWI-MR) and the method to be validated (perfusion-CT). In the second part, we wished to evaluate the clinical relevance of perfusion CT examinations performed on admission in acute stroke patients. Three clinical scores, the NIHSS, Barthel index, and modified Rankin scale, all proven to give an assessments of clinical condition,<sup>41-42</sup> were used. In addition, we examined the evolution of the NIHSS between admission and a median of 1 month (interquartile range, 0.825–1.625 months) later.

A good correlation was found between the admission NIHSS and the initial size of the combined cerebral infarct and penumbra defined on the admission perfusion CT (see Fig 5), while a poor correlation was found between the delayed DWI-MR size of the cerebral infarct and the various clinical scores. The most likely explanation for this poorer correlation between DWI-MR lesion size and delayed clinical score is that the results of an MR examination on day 3 (interquartile range, 3–4 days) were compared with the clinical scores at a median of 1 month (interquartile range, 0.825–1.625 months), rather than with the clinical scores on day 3, neural repair and neuroplasticity allowing variable amounts of improvement in different patients at the later clinical time points.

Finally, we evaluated a new parameter, PRR, which is the ratio of the size of the penumbra to the size of the penumbra plus infarct, as a means of predicting improvement in the NIHSS between admission and after a median of 1 month (interquartile range, 0.825–1.625 months) (see Table 2 and Fig 6).

In 14 patients, thrombolysis was not performed. In 8 of these, spontaneous fragmentation of the thrombus with recanalization of the occluded cerebral artery occurred, as demonstrated by the delayed angio-MR, while in 6 no arterial recanalization occurred. In the latter group, clinical evolution was not as good, reflected by the lower NIHSS improvement and PRR.

Thrombolysis was performed on 8 patients, allowing recanalization of the arterial thrombus and salvaging the penumbra in 6,<sup>10</sup> this being reflected by the high NIHSS improvement of  $74 \pm 20\%$  (mean  $\pm$  standard deviation). In the remaining 2 patients, thrombolysis was unsuccessful, as reflected by the NIHSS improvement of only  $55 \pm 19\%$  and the lower PRR of  $69 \pm 15\%$ .

In patients with recanalization of the occluded cerebral artery, whether spontaneous or with thrombolysis, there was a strong correlation between the PRR and the improvement in the NIHSS evaluated on admission and after a median of 1 month (interquartile range, 0.875–1.625 months) (see Fig 6). In these patients, recanalization allowed the penumbra to be salvaged, with a subsequent and proportional improvement in clinical condition.

In patients with a persistent occluded cerebral artery, the cerebral infarct gradually evolved over the penumbra and finally completely replaced it, as reflected by a globally poorer NIHSS improvement. Since the PRR is calculated from the sizes of the penumbra and infarct on admission, it is significant when the penumbra recovers (as with arterial recanalization) and allows clinical improvement. On the other hand, it showed no correlation with NIHSS improvement in the persistent occlusion group.

Since the PRR is computed based on the admission imaging survey, it should be independent of whether arterial recanalization occurs or not. Our data showing a substantially lower PRR in the persistent occlusion group suggests that infarcts were more mature in this group. This could be among the reasons why patients without arterial recanalization did not improve and showed globally poorer NIHSS improvement.

#### **Conclusions**

Perfusion CT examinations were performed on four adjacent 10mm cerebral sections in 22 patients with acute stroke in the cerebral artery territory. This procedure allowed accurate prediction of the final cerebral infarct size in acute stroke patients at the time of emergency evaluation and provided information about the

extent of the penumbra. The relationship between the perfusion CT abnormality and the final infarct size was shown to vary in a predictable fashion, depending upon whether arterial recanalization occurred. Perfusion CT accuracy was demonstrated by comparison with the results of delayed DWI-MR examinations.

Perfusion CT results correlate with the patients' clinical condition, the admission NIHSS being directly related to the size of the ischemic cerebral area on the admission perfusion CT. On the other hand, the delayed clinical scores are strongly influenced by neural repair and neuroplasticity, which allow various extents of improvement in different patients. Perfusion CT can be used to estimate a PRR, which is an indicator of the maturity of arterial occlusion and cerebral infarct and which correlates with evolution of the NIHSS in patients with arterial recanalization.

Even if these conclusions need to be confirmed in larger series, this article shows perfusion CT examination to be a valuable tool in the early evaluation of acute stroke patients and possibly in the selection of the therapeutic strategy.

---

We thank Mrs M Rousselle and Mr T Barkas for their help in editing this manuscript.

---

## References

- National Institute of Neurological Disorders and Stroke (NINDS) rt-PA Stroke Study Group. Tissue plasminogen activator for acute ischaemic stroke. *N Engl J Med* 1995;33:1581-1587.
- Bogousslavsky J, Van Melle G, Regli F. The Lausanne stroke registry: analysis of 1,000 consecutive patients with first stroke. *Stroke* 1988;19:1083-1092.
- Hennerici M. Improving the outcome of acute stroke management. *Hosp Med* 1999;60:44-49.
- Hacke W, Kaste M, Fieschi C. Randomised double-blind trial placebo-controlled trial of thrombolytic therapy with intravenous therapy with intravenous alteplase in acute ischaemic stroke (ECASS II). *Lancet* 1998;352:1245-1251.
- Oppenheim C, Samson Y, Manai R, et al. Prediction of malignant middle cerebral artery infarction by diffusion-weighted imaging. *Stroke* 2000;31:2175-2185.
- Rubin G, Firlik AD, Levy EI, et al. Relationship between cerebral blood flow and clinical outcome in acute stroke. *Cerebrovasc Dis* 2000;10:298-306.
- Karonen JO, Nuutinen J, Kuikka JT, et al. Combined SPECT and diffusion-weighted MRI as predictor of infarct growth in acute ischemic stroke. *J Nucl Med* 2000;41:788-794.
- Sorensen AG, Copen WA, Ostergaard L, et al. Hyperacute stroke: simultaneous measurement of relative cerebral blood volume, relative cerebral blood flow, and mean tissue transit time. *Radiology* 1999;210:519-527.
- Ezura M, Takahashi A, Yoshimoto T. Evaluation of regional cerebral blood flow using single photon emission tomography for the selection of patients for local fibrinolytic therapy of acute cerebral embolism. *Neurosurg Rev* 1996;19:231-236.
- Heiss WD, Grond M, Thiel A, et al. Ischemic brain tissue salvaged from infarction with alteplase. *Lancet* 1997;349:1599-1600.
- Reivich M. Blood flow metabolism couple in brain. *Res Pub Assoc Res Nerv Ment Dis* 1974;53:125-140.
- Lassen NA. Cerebral blood flow and oxygen consumption in man. *Physiol Rev* 1959;39:183-238.
- Hossmann KA. Viability thresholds and the penumbra of focal ischemia. *Ann Neurol* 1994;36:557-565.
- Symon L, Branston NM, Strong AJ, Hope TD. The concepts of thresholds of ischaemia in relation to brain structure and function. *J Clin Pathol* 1977;30(Suppl):149-154.
- Astrup J, Symon L, Siesjö BK. Thresholds in cerebral ischemia: the ischemic penumbra. *Stroke* 1981;12:723-725.
- Hakim AM. The cerebral ischemic penumbra. *Can J Neurol Sci* 1987;14:557-559.
- Hossmann KA. Neuronal survival and revival during and after cerebral ischemia. *Am J Emerg Med* 1994;1:191-197.
- Heiss WD. Ischemic penumbra: evidence from functional imaging in man. *J Cereb Blood Flow Metab* 2000;20:1276-93.
- Harper AM. Autoregulation of cerebral blood flow: influence of the arterial blood pressure on the blood flow through the cerebral cortex. *J Neurol Neurosurg Psychiatry* 1966;29:398-403.
- Wood JH. Cerebral blood flow: physiologic and clinical aspects. New York: McGraw-Hill, 1987.
- Symon L, Ganz JC, Dorsch NWC. Experimental studies of hyperaemic phenomena in the cerebral circulation of primates. *Brain* 1972;95:265-278.
- Gourley JK, Heistad DD. Characteristics of reactive hyperemia in the cerebral circulation. *Am J Physiol* 1984;246 (Heart Circ Physiol 15):H52-H58.
- Todd NV, Picozzi P, Crockard HA. Quantitative measurement of cerebral blood flow and cerebral blood volume after cerebral ischemia. *J Cereb Blood Flow Metab* 1986;6:338-341.
- Wintermark M, Maeder P, Thiran J-Ph, et al. Simultaneous measurements of regional cerebral blood flows by perfusion-CT and stable xenon-CT: a validation study. *AJNR* 2001;22:905-914.
- Nabavi DG, Cenic A, Craen RA, et al. CT assessment of cerebral perfusion: experimental validation and initial clinical experience. *Radiology* 1999;213:141-149.
- Cenic A, Nabavi DG, Craen RA, et al. Dynamic CT measurement of cerebral blood flow: a validation study. *AJNR Am J Neuroradiol* 1999;20:63-73.
- König M, Klotz E, Luka B, et al. Perfusion CT of the brain: diagnostic approach for early detection of ischemic stroke. *Radiology* 1998;209:85-93.
- Meier P, Zierler KL. On the theory of the indicator-dilution method for measurement of blood flow and size. *J Appl Physiol* 1954;12:731-744.
- Zierler KL. Theoretical basis of indicator-dilution methods for measuring flow and size. *Circ Res* 1962;10:393-407.
- Zierler KL. Equations for measuring blood flow by external monitoring of radioisotopes. *Circ Res* 1965;16:309-321.
- Axel L. Cerebral blood flow determination by rapid-sequence computed tomography. *Radiology* 1980;137:679-686.
- Axel L. A method of calculating brain blood flow with a CT dynamic scanner. *Adv Neurol* 1981;30:67-71.
- Axel L. Tissue mean transit time from dynamic computed tomography by a simple deconvolution technique. *Invest Radiol* 1983;18:94-99.
- Ladurner G, Zilkha E, Iliff LD, et al. Measurement of regional cerebral blood volume by computerized axial tomography. *J Neurol Neurosurg Psychiatry* 1976;39:152-155.
- Zilkha E, Ladurner G, Linette D, et al. Computer subtraction in regional cerebral blood-size measurements using the EMI-scanner. *Br J Radiol* 1976;49:330-334.
- Ladurner G, Zilkha E, Sager WD, et al. Measurement of regional cerebral blood volume using the EMI 1010 scanner. *Br J Radiol* 1979;52:371-374.



37. Larson OA, Lassen NA. Cerebral hematocrit in normal man. *J Appl Physiol* 1964;19:571-574.
38. Sakai F, Kakazawa K, Tazaki Y, et al. Regional cerebral blood volume and hematocrit measured in human volunteers by single-photon emission tomography. *J Cereb Blood Flow Metab* 1985;5:207-213.
39. Miyasaka N, Nagaoka T, Kuroiwa T, et al. Histopathologic correlates of temporal diffusion changes in a rat model of cerebral hypoxia/ischemia. *AJNR Am J Neuroradiol* 2000;21:60-66.
40. Oppenheim C, Stanescu R, Dormont D, et al. False-negative diffusion-weighted MR findings in acute ischemic stroke. *AJNR Am J Neuroradiol* 2000;21:1434-1440.
41. Williams LS, Yilmaz EY, Lopez-Yunez AM. Retrospective assessment of initial stroke severity with the NIH Stroke Scale. *Stroke* 2000;31:858-862.
42. Adams HP Jr, Davis PH, Leira EC, et al. Baseline NIH Stroke Scale score strongly predicts outcome after stroke: a report of the Trial of Org 10172 in Acute Stroke Treatment (TOAST). *Neurology* 1999;53:126-131.
43. DeGraba TJ, Hallenbeck JM, Pettigrew KD, et al. Progression in acute stroke: value of the initial NIH stroke scale score on patient stratification in future trials. *Stroke* 1999;20:1208-1212.
44. Wintermark M, Maeder P, Verdun FR, et al. Using 80 kVp versus 120 kVp in perfusion CT measurement of regional cerebral blood flows. *AJNR Am J Neuroradiol* 2000;21:1881-1884.
45. Doerfler A, Engelhorn T, von Kummer R, et al. Are iodinated contrast agents detrimental in acute cerebral ischemia? An experimental study in rats. *Radiology* 1998;206:211-217.
46. Commission of the European Communities. European guidelines on quality criteria for computed tomography. EUR 16262 EN, 1999. Available from: URL:<http://www.drs.dk/guidelines/ct/quality/>
47. Hidajat N, Mäurer J, Schröder RJ, et al. Relationships between physical dose quantities and patient dose in CT. *Br J Radiol* 1999;72:556-561.
48. Wintermark M, Maeder P, Thiran J-Ph, Schnyder P, Meuli R. Quantitative assessment of regional cerebral blood flows by perfusion CT studies at low injection rates: a critical review of the underlying theoretical models. *Eur Radiol* 2001;11:1220-1230.
49. Mayer TE, Hamann GF, Baranczyk J, et al. Dynamic CT perfusion imaging of acute stroke. *AJNR Am J Neuroradiol* 2000;21:1441-1449.
50. Hunter GJ, Hamberg LM, Ponzio JA, et al. Assessment of cerebral perfusion and arterial anatomy in hyperacute stroke with three-dimensional functional CT: early clinical results. *AJNR Am J Neuroradiol* 1998;19:29-37.
51. Lee KH, Soo-Jin C, Byun HS, et al. Triphasic perfusion computed tomography in acute middle cerebral artery stroke: a correlation with angiographic findings. *Arch Neurol* 2000;57:990-999.
52. Gonzales RG, Schaefer PW, Buonanno FS, et al. Diffusion-weighted MR imaging: accuracy in patients imaged within 6 hours of stroke symptom onset. *Radiology* 1999;210:155-162.
53. Lev MH, Segal AZ, Farkas J, et al. Utility of perfusion-weighted CT imaging in acute middle cerebral artery stroke treated with intra-arterial thrombolysis: prediction of final infarct volume and clinical outcome. *Stroke* 2001;32:2021-2028.
54. Kluytmans M, Van Everdingen KJ, Kappelle LJ, et al. Prognostic value of perfusion- and diffusion-weighted MR imaging in first 3 days of stroke. *Eur Radiol* 2000;10:1434-1441.
55. Kim JH, Lee SJ, Kang KH, et al. Correlative assessment of hemodynamic parameters obtained with T2\*-weighted perfusion MR imaging and SPECT in symptomatic carotid artery occlusion. *AJNR Am J Neuroradiol* 2000;21:1450-1456.
56. Smith AM, Grandin CB, Duprez T, et al. Whole brain quantitative CBF, CBV, MTT measurements using MRI bolus tracking: implementation and application to data acquired from hyperacute stroke patients. *J Magn Reson Imag* 2000;12:400-410.
57. Lythgoe MF, Thomas DL, Calamante F, et al. Acute changes in MRI diffusion, perfusion, T1, and T2 in a rat model of oligemia produced by partial occlusion of the middle cerebral artery. *Magn Reson Med* 2000;44:706-712.
58. Sorensen AG, Reimer P. Cerebral MR perfusion imaging: principles and current applications. Stuttgart: Thieme Verlag, 2000.

## **13 Proposed Labeling Attachments**

## **13.1 Vitrea<sup>®</sup> CT Body Perfusion Education and Reference Guide (VPMC-12294)**

# **VitreAdvanced - Vitre<sup>®</sup> CT Body Perfusion Education and Reference Guide**

**For Vitrea fX Only.**

---

VITALU<sup>®</sup>

VPMC-12294A

Questions? Contact FDA/CDRH/OCE/DID at [CDRH-FOISTATUS@fda.hhs.gov](mailto:CDRH-FOISTATUS@fda.hhs.gov) or 301-796-8118



















































































































## **13.2 Vitrea<sup>®</sup> CT Liver Analysis Education and Reference Guide (VPMC-12295)**



# **VitreAAdvanced**

## **VitreA<sup>®</sup> CT Liver Analysis - Education and Reference Guide**

---

VITALU<sup>®</sup>

VPMC-12295A

Questions? Contact FDA/CDRH/OCE/DID at [CDRH-FOISTATUS@fda.hhs.gov](mailto:CDRH-FOISTATUS@fda.hhs.gov) or 301-796-8118







































































### **13.3 Vitrea<sup>®</sup> CT Brain Perfusion Education and Reference Guide (VPMC-12292)**

**VitreAAdvanced**

**VitreA<sup>®</sup> CT Brain**

**Perfusion Education**

**and Reference**

**Guide**

---

VITALU<sup>®</sup>

VPMC-12292A

Questions? Contact FDA/CDRH/OCE/DID at [CDRH-FOISTATUS@fda.hhs.gov](mailto:CDRH-FOISTATUS@fda.hhs.gov) or 301-796-8118











































































## **13.4 VitreaAdvanced Promotional Excerpt (M-05545)**

VitreAdvanced delivers comprehensive advanced visualization solutions that are accessible from any Web-enabled PC. Intuitive applications and automated workflows speed diagnosis, communication and collaboration for efficient and confident decision making. Vitrea® Enterprise Suites' (VES) unique modular architecture delivers an optimal user experience and can be virtualized to increase productivity. Backed by Vital's first-class service and education programs, VES is an advanced visualization solution that delivers both performance and value to meet the growing, changing needs of healthcare institutions.

### **CT Brain Perfusion**

CT Brain Perfusion is a noninvasive post-processing application designed to evaluate areas of brain perfusion. The software can calculate cerebral blood flow (CBF), cerebral blood volume (CBV), local bolus timing (i.e., delay of tissue response, time to peak), and mean transit time (MTT) from dynamic CT image data acquired after the injection of contrast media. The package also allows the calculation of regions of interest and mirrored regions, as well as the visual inspection of time density curves. Vitrea® CT Brain Perfusion supports the physician in visualizing the apparent blood perfusion in brain tissue affected by acute stroke. Areas of decreased perfusion, as is observed in acute cerebral infarcts, appear as areas of changed signal intensity (lower for both CBF and CBV and higher for time to peak and MTT).

### **CT Liver Analysis**

CT Liver Analysis is a noninvasive post-processing application designed to evaluate liver tumors and plan for liver surgery. It displays images for analysis and preoperative liver surgery planning, such as organ segmentation, tumor segmentation and intrahepatic vessels segmentation, as well as the approximation of vascular territories. CT Liver Analysis supports preoperative evaluation of specific surgery strategies by allowing the user to interactively define virtual resections splitting the liver. It also allows the user to evaluate safety-margins around lesions and to identify affected vascular branches and territories. Vitrea® CT Liver Analysis also provides automatic registration of multiple series and measurement tools for characterization and follow-up of the lesions.

### **CT Body Perfusion**

CT Body Perfusion is a noninvasive post-processing application designed to evaluate perfusion of organs and tumors. The software can calculate perfusion characteristics from dynamic CT image data acquired after the injection of contrast media. The software also allows the separate calculation of the arterial and venous components of perfusion in organs. CT Body Perfusion supports the evaluation of regions of interest and the visual inspection of time.

## 16 Software Attachments



































































































































































































































































































































































































































































































































































































































































































































































































































































































































## **16.18 DICOM Form FDA 3654, Standards Data Report Form for 510(k)s**

Department of Health and Human Services Food and Drug Administration <b>STANDARDS DATA REPORT FOR 510(k)s</b> <i>(To be filled in by applicant)</i>	
This report and the Summary Report Table are to be completed by the applicant when submitting a 510(k) that references a national or international standard. A separate report is required for each standard referenced in the 510(k).	
TYPE OF 510(K) SUBMISSION <input checked="" type="checkbox"/> Traditional <input type="checkbox"/> Special <input type="checkbox"/> Abbreviated	
STANDARD TITLE <sup>1</sup>	
<b>Please answer the following questions</b>	
	Yes      No
Is this standard recognized by FDA <sup>2</sup> ? .....	<input checked="" type="checkbox"/> <input type="checkbox"/>
FDA Recognition number <sup>3</sup> ..... # <u>12-218</u>	
Was a third party laboratory responsible for testing conformity of the device to this standard identified in the 510(k)? .....	<input type="checkbox"/> <input checked="" type="checkbox"/>
Is a summary report <sup>4</sup> describing the extent of conformance of the standard used included in the 510(k)? ..... If no, complete a summary report table.	<input checked="" type="checkbox"/> <input type="checkbox"/>
Does the test data for this device demonstrate conformity to the requirements of this standard as it pertains to this device? .....	<input checked="" type="checkbox"/> <input type="checkbox"/>
Does this standard include acceptance criteria? ..... If no, include the results of testing in the 510(k).	<input checked="" type="checkbox"/> <input type="checkbox"/>
Does this standard include more than one option or selection of tests? ..... If yes, report options selected in the summary report table.	<input type="checkbox"/> <input checked="" type="checkbox"/>
Were there any deviations or adaptations made in the use of the standard? ..... If yes, were deviations in accordance with the FDA supplemental information sheet (SIS) <sup>5</sup> ? .....	<input type="checkbox"/> <input checked="" type="checkbox"/> <input type="checkbox"/> <input type="checkbox"/>
Were deviations or adaptations made beyond what is specified in the FDA SIS? ..... If yes, report these deviations or adaptations in the summary report table.	<input type="checkbox"/> <input checked="" type="checkbox"/>
Were there any exclusions from the standard? ..... If yes, report these exclusions in the summary report table.	<input type="checkbox"/> <input checked="" type="checkbox"/>
Is there an FDA guidance <sup>6</sup> that is associated with this standard? ..... If yes, was the guidance document followed in preparation of this 510k? .....	<input checked="" type="checkbox"/> <input type="checkbox"/> <input type="checkbox"/> <input type="checkbox"/>
Title of guidance: <u>Guidance for the Submission of Premarket Notifications for Medical Image Management Devices</u>	
<sup>1</sup> The formatting convention for the title is: [SDO] [numeric identifier] [title of standard] [date of publication] <sup>2</sup> Authority [21 U.S.C. 360d], <a href="http://www.fda.gov/cdrh/stdsprog.html">www.fda.gov/cdrh/stdsprog.html</a> <sup>3</sup> <a href="http://www.accessdata.fda.gov/scripts/cdrh/cfdocs/cfStandards/search.cfm">http://www.accessdata.fda.gov/scripts/cdrh/cfdocs/cfStandards/search.cfm</a> <sup>4</sup> The summary report should include: any adaptations used to adapt to the device under review (for example, alternative test methods); choices made when options or a selection of methods are described; deviations from the standard; requirements not applicable to the device; and the name and address of the test laboratory or	certification body involved in conformance assessment to this standard. The summary report includes information on all standards utilized during the development of the device. <sup>5</sup> The supplemental information sheet (SIS) is additional information which is necessary before FDA recognizes the standard. Found at <a href="http://www.accessdata.fda.gov/scripts/cdrh/cfdocs/cfStandards/search.cfm">http://www.accessdata.fda.gov/scripts/cdrh/cfdocs/cfStandards/search.cfm</a> <sup>6</sup> The online search for CDRH Guidance Documents can be found at <a href="http://www.fda.gov/cdrh/guidance.html">www.fda.gov/cdrh/guidance.html</a>

EXTENT OF STANDARD CONFORMANCE SUMMARY REPORT TABLE		
STANDARD TITLE NEMA PS 3.1 - 3.18 (2009), Digital Imaging and Communications in Medicine (DICOM) Set.		
CONFORMANCE WITH STANDARD SECTIONS*		
SECTION NUMBER	SECTION TITLE	CONFORMANCE? <input type="checkbox"/> Yes <input type="checkbox"/> No <input type="checkbox"/> N/A
TYPE OF DEVIATION OR OPTION SELECTED *		
DESCRIPTION		
JUSTIFICATION		
SECTION NUMBER	SECTION TITLE	CONFORMANCE? <input type="checkbox"/> Yes <input type="checkbox"/> No <input type="checkbox"/> N/A
TYPE OF DEVIATION OR OPTION SELECTED *		
DESCRIPTION		
JUSTIFICATION		
SECTION NUMBER	SECTION TITLE	CONFORMANCE? <input type="checkbox"/> Yes <input type="checkbox"/> No <input type="checkbox"/> N/A
TYPE OF DEVIATION OR OPTION SELECTED *		
DESCRIPTION		
JUSTIFICATION		
SECTION NUMBER	SECTION TITLE	CONFORMANCE? <input type="checkbox"/> Yes <input type="checkbox"/> No <input type="checkbox"/> N/A
TYPE OF DEVIATION OR OPTION SELECTED *		
DESCRIPTION		
JUSTIFICATION		
<p>* For completeness list all sections of the standard and indicate whether conformance is met. If a section is not applicable (N/A) an explanation is needed under "justification." Some standards include options, so similar to deviations, the option chosen needs to be described and adequately justified as appropriate for the subject device. Explanation of all deviations or description of options selected when following a standard is required under "type of deviation or option selected," "description" and "justification" on the report. More than one page may be necessary.</p> <p>* Types of deviations can include an exclusion of a section in the standard, a deviation brought out by the FDA supplemental information sheet (SIS), a deviation to adapt the standard to the device, or any adaptation of a section.</p>		
Paperwork Reduction Act Statement		
<p>Public reporting burden for this collection of information is estimated to average 1 hour per response, including the time for reviewing instructions, searching existing data sources, gathering and maintaining the data needed, and completing and reviewing the collection of information. Send comments regarding this burden estimate or any other aspect of this collection of information, including suggestions for reducing this burden, to:</p> <p style="text-align: center;">Center for Devices and Radiological Health 1350 Piccard Drive Rockville, MD 20850</p> <p style="text-align: center;"><i>An agency may not conduct or sponsor, and a person is not required to respond to, a collection of information unless it displays a currently valid OMB control number.</i></p>		





Food and Drug Administration  
Office of Device Evaluation &  
Office of In Vitro Diagnostics

**COVER SHEET MEMORANDUM**

From: Reviewer Name Jay Vaishnav  
Subject: 510(k) Number K121213  
To: The Record TH

- Please list CTS decision code TH
- Refused to accept (Note: this is considered the first review cycle, See Screening Checklist [http://eroom.fda.gov/eRoomReq/Files/CDRH3/CDRHPremarketNotification510kProgram/0\\_5631/Screening%20Checklist%207%202%2007.doc](http://eroom.fda.gov/eRoomReq/Files/CDRH3/CDRHPremarketNotification510kProgram/0_5631/Screening%20Checklist%207%202%2007.doc))
  - Hold (Additional Information or Telephone Hold).
  - Final Decision (SE, SE with Limitations, NSE (select code below), Withdrawn, etc.).

Not Substantially Equivalent (NSE) Codes

- NO NSE for lack of predicate
- NI NSE for new intended use
- NQ NSE for new technology that raises new questions of safety and effectiveness
- NU NSE for new intended use AND new technology raising new questions of safety and effectiveness
- NP NSE for lack of performance data
- NS NSE no response
- NL NSE for lack of performance data AND no response
- NM NSE pre-amendment device call for PMAs (515i)
- NC NSE post-amendment device requires PMAs
- NH NSE for new molecular entity requires PMA
- TR NSE for transitional device

Please complete the following for a final clearance decision (i.e., SE, SE with Limitations, etc.):	YES	NO
Indications for Use Page <i>Attach IFU</i>		
510(k) Summary /510(k) Statement <i>Attach Summary</i>		
Truthful and Accurate Statement. <i>Must be present for a Final Decision</i>		
Is the device Class III? If yes, does firm include Class III Summary? <i>Must be present for a Final Decision</i>		
Does firm reference standards? (If yes, please attach form from <a href="http://www.fda.gov/opacom/morechoices/fdaforms/FDA-3654.pdf">http://www.fda.gov/opacom/morechoices/fdaforms/FDA-3654.pdf</a> )		
Is this a combination product? (Please specify category _____ see <a href="http://eroom.fda.gov/eRoomReq/Files/CDRH3/CDRHPremarketNotification510kProgram/0_413b/COMBINATION%20PRODUCT%20ALGORITHM%20(REVISED%203-12-03).DOC">http://eroom.fda.gov/eRoomReq/Files/CDRH3/CDRHPremarketNotification510kProgram/0_413b/COMBINATION%20PRODUCT%20ALGORITHM%20(REVISED%203-12-03).DOC</a> )		
Is this a reprocessed single use device? (Guidance for Industry and FDA Staff – MDUFMA - Validation Data in 510(k)s for Reprocessed Single-Use Medical Devices, <a href="http://www.fda.gov/cdrh/ode/guidance/1216.html">http://www.fda.gov/cdrh/ode/guidance/1216.html</a> )		
Is this device intended for pediatric use only?		
Is this a prescription device? (If both prescription & OTC, check both boxes.)		
Did the application include a completed FORM FDA 3674, Certification with Requirements of ClinicalTrials.gov Data Bank?		
Is clinical data necessary to support the review of this 510(k)? For United States-based clinical studies only: Did the application include a completed FORM FDA 3674, Certification with Requirements of ClinicalTrials.gov Data Bank? (If study was		

conducted in the United States, and FORM FDA 3674 was not included or incomplete, then applicant must be contacted to obtain completed form.)

Does this device include an Animal Tissue Source?

All Pediatric Patients age <= 21

Neonate/Newborn (Birth to 28 days)

Infant (29 days - < 2 years old)

Child (2 years - < 12 years old)

Adolescent (12 years - < 18 years old)

Transitional Adolescent A (18 - < 21 years old) Special considerations are being given to this group, different from adults age ≥ 21 (different device design or testing, different protocol procedures, etc.)

Transitional Adolescent B (18 - <= 21; No special considerations compared to adults => 21 years old)

Nanotechnology

Is this device subject to the Tracking Regulation? (Medical Device Tracking Guidance, <http://www.fda.gov/cdrh/comp/guidance/169.html>) Contact OC.

<b>Regulation Number</b>	<b>Class*</b>	<b>Product Code</b>
--------------------------	---------------	---------------------

21 CFR 892.2050

II

LLZ

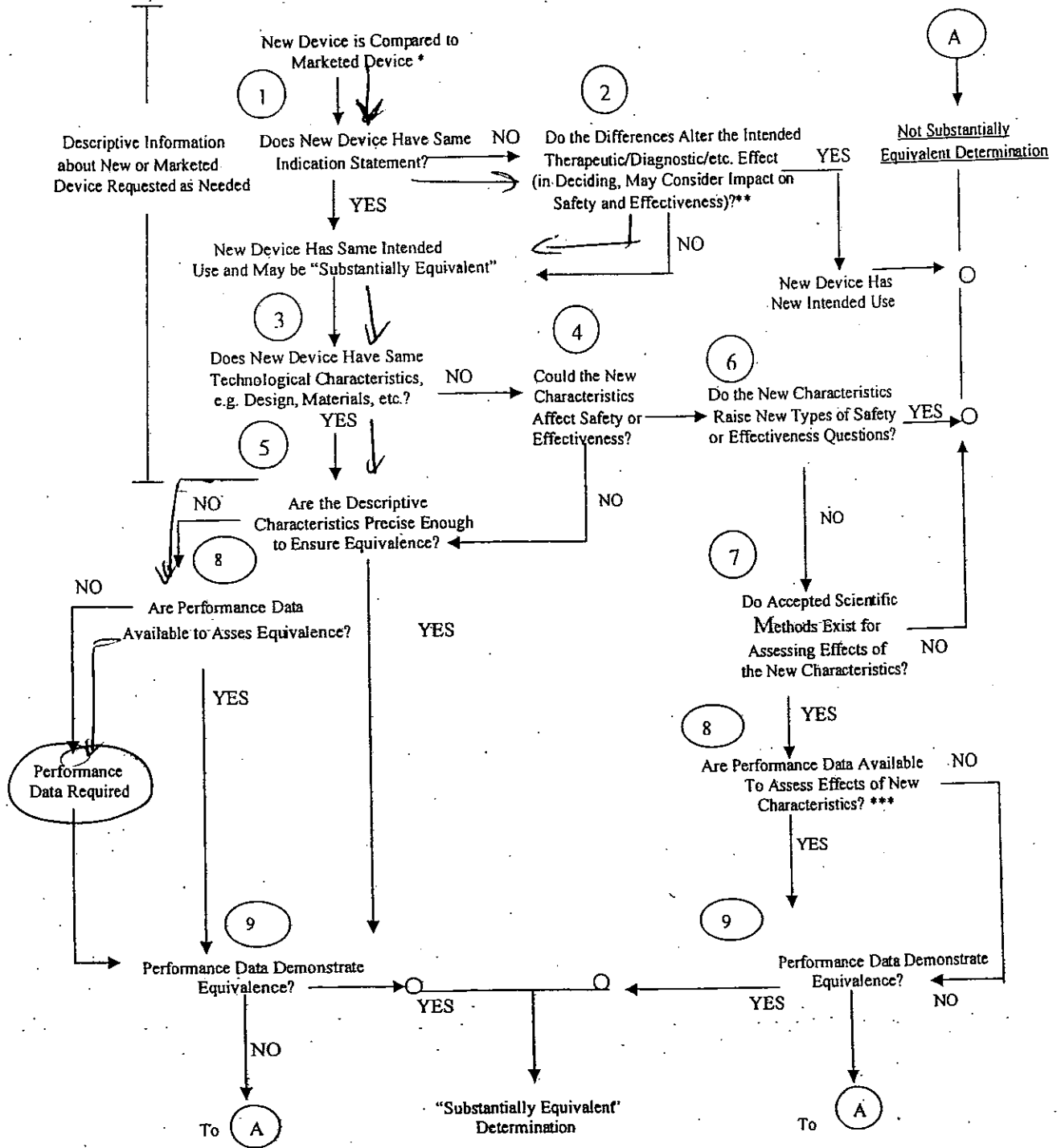
(\*If unclassified, see 510(k) Staff)

Additional Product Codes: \_\_\_\_\_

Review: \_\_\_\_\_  
 (Branch Chief) DRA D 6/22/12  
 (Branch Code) (Date)

Final Review: \_\_\_\_\_  
 (Division Director) (Date)

### 510(k) "SUBSTANTIAL EQUIVALENCE" DECISION-MAKING PROCESS



\* 510(k) Submissions compare new devices to marketed devices. FDA requests additional information if the relationship between marketed and "predicate" (pre-Amendments or reclassified post-Amendments) devices is unclear.

\*\* This decision is normally based on descriptive information alone, but limited testing information is sometimes required.

\*\*\* Data maybe in the 510(k), other 510(k)s, the Center's classification files, or the literature. Questions? Contact FDA/CDRH/OCE/DID at CDRH-FOISTATUS@fda.hhs.gov or 301-796-8118



**Premarket Notification [510(k)] Review  
 Traditional/Abbreviated**

**K121213**

Date: June 21, 2012  
 To: The Record Office: OIVD  
 From: Jay Y. Vaishnav, Ph.D. Division: DRAD

510(k) Holder: Vital Images, Inc.  
 Device Name: VitreaAdvanced  
 Contact: Daniel Biank  
 Vital Images, Inc.  
 5850 Opus Parkway, Suite 300  
 Minnetonka, MN 55343-4414

Phone: 952-487-9514  
 Email: [dbiank@vitalimages.com](mailto:dbiank@vitalimages.com)

**I. Purpose and Submission Summary**

Vital Images, Inc. is submitting a Traditional 510(k) for the VitreaAdvanced software. This submission is essentially a bundled submission.

The sponsor is claiming substantial equivalence to the following legally marketed predicate devices:

- K071331 – Vitrea v 4.0 (Vital Images)
- K072821 – Vitrea 4DCT (Vital Images)
- K090504 – CSBP-001A Body Perfusion System (Toshiba)
- K051528 – MeVis LiverAnalyser/Liver Viewer (Mevis Technology GMBH & Co.)
- K071241 – LMS-Liver (Median Technologies)
- K073238 – syngo Volume Perfusion-CT Neuro (Siemens)

The sponsor intends to demonstrate that the software is substantially equivalent to K071331 (Vitrea, v. 4.0, K071331), and includes other applications for Computed Tomography (CT) Body Perfusion, CT Liver Analysis and CT Brain Perfusion that are equivalent to other legally marketed devices.

In particular, the sponsor will claim substantial equivalence between

Vitrea CT Body Perfusion and Toshiba's CSBP-001A Body Perfusion System (K090504)

Vitrea CT Liver Analysis and the MeVis Liver Analyser/LiverViewer (K051528) and Median Technologies' LMS-Liver (K071241 ),

Vitrea CT Brain Perfusion and Vital Images' previously cleared Vitrea 4DCT package (K072821) as well as Siemens Medical Solutions' syngo Volume Perfusion-CT Neuro (K073238).

**Differences from Predicate Device**

This device adds three new modules to the primary predicate device. These modules analyze images from brain, body, and liver perfusion respectively.

The sponsor has added additional predicates which overlap the function of each module.

The labeling claims in this device seem to be expanded over some of these predicates. There are also some claims that do appear in the predicate IFUs, but are condition and disease specific. I am requesting additional data in support of those claims. Please see Section XVI of this memorandum ("Deficiencies") for further details.

Recommendation: Telephone hold

**II. Administrative Requirements**

	Sufficient	
	Yes	No
CDRH Premarket Review Submission Cover Sheet (Form FDA 3514)	✓	
510(k) Cover Letter	✓	
Indications for Use	Rx	
510(k) Summary	✓	
(a) 510(k) Summary is in sufficient detail to provide an understanding of the basis for a determination of substantial equivalence (21 CFR §807.92)	✓	
(1) Submitter's Contact Information	✓	
(2) Device Name	✓	
(3) Predicate Identification	✓	
(4) Device Description	✓	
(5) Intended Use Statement	✓	
(6) Technological Characteristics Comparison	✓	
(b) Performance Data	✓	
(1) Brief Discussion of Nonclinical Tests	✓	
(2) Brief Discussion of Clinical Tests		N/A
(3) Test Conclusions	✓	
Truthful and Accuracy Statement	✓	
Class III Summary		N/A
Financial Certification or Disclosure Statement		N/A
Standards Form (FDA 3654)		✓
• DICOM - Digital Imaging and Communications in Medicine v. 3		
Clinical Trials Form (FDA 3674)		N/A

**Deficiency #1:** In your submission, you provided a 510(k) summary that was administratively complete. However, we would like your 510(k) summary to contain somewhat more detail. Please provide a 510(k) summary for this submission that includes more detail regarding the performance testing that you provided in order to support substantial equivalence.

**III. Indications for Use**

The device is correctly indicated as being for prescription use. The IFU statement for the subject device follows:

<b>K121213, VitreaAdvanced (Vital Images, Inc.)</b>	<b>LLZ (21 CFR §892.2050)</b>
<p>VitreaAdvanced is a medical diagnostic system for the processing, review, analysis, communication and media interchange of multi-dimensional digital images acquired from a variety of imaging devices. VitreaAdvanced is not meant for primary image interpretation in mammography. It can be used with a variety of cleared Vitrea® based software applications. In addition, VitreaAdvanced includes the following indications:</p> <p><b>Vitrea CT Body Perfusion</b> is a noninvasive post-processing application designed to evaluate perfusion of organs and tumors. The software can calculate perfusion characteristics from dynamic CT image data acquired after the injection of contrast media. The software also allows the separate calculation of the arterial and venous components of perfusion in organs (e.g., liver, lung and kidney). It supports evaluation of regions of interest and the visual inspection of time density curves. When used by a trained and qualified physician a potential application is to differentiate blood flow between normal and diseased tissue. Determination of the change of perfusion parameters during the course of treatment may be helpful in therapy monitoring.</p> <p><b>Vitrea CT Liver Analysis</b> is a noninvasive post-processing application designed to evaluate liver tumors and plan for liver surgery. It displays images for analysis and preoperative liver surgery planning, such as organ segmentation, tumor segmentation and intrahepatic vessels segmentation, as well as the approximation of vascular territories. It supports preoperative evaluation of specific surgery strategies by allowing the user to interactively define virtual resections splitting the liver. It also allows the user to evaluate safety-margins around lesions and to identify affected vascular branches and territories. Vitrea® CT Liver Analysis also provides automatic registration of multiple series and measurement tools for characterization and follow-up of the lesions. When used by a trained and qualified physician a potential application is to assist in the assessment of tumor response to therapy.</p> <p><b>Vitrea CT Brain Perfusion</b> is a noninvasive post-processing application designed to evaluate areas of brain perfusion. The software can calculate cerebral blood flow (CBF), cerebral blood volume (CBV), local bolus timing (i.e., delay of tissue response, time to peak), and mean transit time (MTT) from dynamic CT image data acquired after the injection of contrast media. The package also allows the calculation of regions of interest and mirrored regions, as well as the visual inspection of time density curves. Vitrea® CT Brain Perfusion supports the physician in visualizing the apparent blood perfusion in brain tissue affected by acute stroke. Areas of decreased perfusion, as is observed in acute cerebral infarcts, appear as areas of changed signal intensity (lower for both CBF and CBV and higher for time to peak and MTT).</p>	

The sponsor claims substantial equivalence to the following legally marketed predicate devices. The primary predicate device is this one:

<b>K072821, Vitrea 4DCT Medical Image Processing Software (Vital Images)</b>	<b>JAK (21 CFR §892.1750)</b>
<p>Vitrea is a medical diagnostic system that allows the processing, review, analysis, communication and media interchange of multi-dimensional digital images acquired from a variety of imaging devices. In addition, Vitrea 4DCT has the following indication: The Vitrea 4DCT Brain Perfusion option is intended for post processing based on dynamic CT images</p>	

continuously acquired during the injection of contrast, for the visualization of apparent blood flow in brain tissue and pictorial illustration of perfusion-related parameters to aid in the assessment of the type and extent of cerebral perfusion disturbances.

Comparing the first paragraph of this IFU to the first paragraph of the IFU statement of the subject device, there are no concerns.

**K090504, Body Perfusion System, CSBP-001A (Toshiba)**

**JAK (21 CFR §892.1750)**

The Body Perfusion System software package is a noninvasive post-processing package that has been designed to evaluate perfusion of organs and tumors. The software can calculate blood flow, blood volume and permeability from sets of images reconstructed from dynamic CT data acquired after the injection of contrast media. The software also allows the separate calculation of the arterial and portal venous component of hepatic perfusion. It supports evaluation of regions of interest and the visual inspection of time density curves.

When used by a qualified physician a potential application is to differentiate blood flow between normal and diseased tissue. Determination of the change of perfusion parameters during the course of treatment may be helpful in therapy monitoring.

It should be used by a trained and qualified physician.

The above IFU statement should be compared to the relevant portion of the subject device's IFU statement, which states

"Vitrea CT Body Perfusion is a noninvasive post-processing application designed to evaluate perfusion of organs and tumors. The software can calculate perfusion characteristics from dynamic CT image data acquired after the injection of contrast media. The software also allows the separate calculation of the arterial and venous components of perfusion in organs (e.g., liver, lung and kidney). It supports evaluation of regions of interest and the visual inspection of time density curves. When used by a trained and qualified physician a potential application is to differentiate blood flow between normal and diseased tissue. Determination of the change of perfusion parameters during the course of treatment may be helpful in therapy monitoring."

**Reviewer Note:** The subject device adds to the predicate indication an intended use for performing perfusion calculations on lung and kidney images.

**K051528, MeVis LiverAnalyser / LiverViewer Software (MeVis)**

**LLZ (21 CFR §892.2050)**

The MeVis LiverAnalyser / LiverViewer Software™ device is intended for preoperative planning in liver surgery. The device is used to analyze data and to display image analysis and risk analysis results for the preoperative planning in liver surgery, e.g. organ segmentation, tumor segmentation, segmentation of intrahepatic vessels as well as the approximation of vascular territories. Preoperative evaluation of specific surgery strategies is supported by the feature to interactively define virtual resections splitting the liver or to calculate safety-margins around lesions identifying affected vascular branches and vascular territories supplied or drained by these branches. Medical image data is derived from various sources (i.e. CT scanners, MRI scanners). Typical users of this system are trained professionals, including physicians, nurses, and technicians.

**K071241, LMVS-Liver (MEDIAN Technologies)**

**LLZ (21 CFR §892.2050)**

LMVS-Liver is an image analysis software application for evaluating CT images covering the liver area. It is designed to assist radiologists in the evaluation and documentation of lesions. It also provides tools for assessment of lesion evolution overtime. LMVS-Liver offers measurement tools and 3D registration techniques for characterization and follow-up of the lesions. It also offers reporting

12

capabilities making it possible to generate standardized reports. LMVS-Liver is intended to be used by radiologists and other clinicians qualified to interpret CT images. LMVS-Liver device is designed to be used with CT images covering the liver area in adult patients.

Comparing both of the above to the relevant portion of the subject IFU,

**Vitreæ CT Liver Analysis** is a noninvasive post-processing application designed to evaluate liver tumors and plan for liver surgery. It displays images for analysis and preoperative liver surgery planning, such as organ segmentation, tumor segmentation and intrahepatic vessels segmentation, as well as the approximation of vascular territories. It supports preoperative evaluation of specific surgery strategies by allowing the user to interactively define virtual resections splitting the liver. It also allows the user to evaluate safety-margins around lesions and to identify affected vascular branches and territories. Vitreæ CT Liver Analysis also provides automatic registration of multiple series and measurement tools for characterization and follow-up of the lesions. **When used by a trained and qualified physician a potential application is to assist in the assessment of tumor response to therapy.**

The subject device contains a new tool claim stating that the device is intended for use in tumor therapy.

**K072821, syngo® Volume Perfusion-CT Neuro**

**JAK (21 CFR §892.1750)**

The Siemens syngo® Volume Perfusion-CT Neuro software package has been designed to evaluate areas of brain perfusion. The software can calculate cerebral blood flow (CBF), cerebral blood volume (CBV), local bolus timing (i.e. time to start, time to peak), mean transit time (MTT), and vascular permeability (blood brain barrier disturbances) from sets of images or volumes reconstructed from continuously acquired CT data after the injection of contrast media. The package also allows the calculation of mirrored regions or volumes of interest and the visual inspection of time attenuation curves. One clinical application is to visualize the apparent blood perfusion in brain tissue affected by acute stroke. Areas of decreased perfusion, as is observed in acute cerebral infarcts, appear as areas of changed signal intensity (lower for CBF and CBV, higher for time to peak and MTT). Syngo® Volume Perfusion-CT Neuro supports the physician in identifying areas of decreased perfusion which indicate the occurrence of acute stroke during the first 6 hours after onset of symptoms. A second application is the visualization of the permeability. It is used for the modeling of extra-vascular leakage of blood into the interstitial space. This additional capability can display blood brain barrier disturbances and thus may improve the differential diagnosis of brain tumors and be helpful in therapy monitoring.

The sponsor makes the following claim:

“Vitreæ CT Brain Perfusion supports the physician in visualizing the apparent blood perfusion in brain tissue affected by acute stroke. Areas of decreased perfusion, as is observed in acute cerebral infarcts, appear as areas of changed signal intensity (lower for both CBF and CBV and higher for time to peak and MTT).”

This is a tool claim that the device assists a physician in identifying stroke. The claim was cleared after extensive discussion in predicate K072821 as well as the predicate of that device, which includes data in support of the claim. This submission does not appear to include such data. **Please see Deficiency #4.**

**Reviewer Note:** Some of the predicates are under a different regulation and procode (21CFR892.1750, JAK) than the subject device. This is because the 2000 PACS guidance stated that devices designated for use with a single modality are no longer treated as accessories to that modality, but rather considered to be medical image management devices and subject to the applicable requirements and exemptions. The different regulations are not an issue.



**Deficiency #2:** The IFU statement of your chosen predicate device K090504 includes indications for operation on hepatic perfusion. Your device adds to the predicate indication a specific indication for performing perfusion calculations on liver, lung and kidney images. We are not clear whether the extra language you have added indicates extra device functionality. Please either explain why the new indication does not constitute a new intended use, or provide data in support of this new intended use. Alternately, please remove the added indication.

**Deficiency #3:** As compared to predicate K071241, you add the claim "when used by a trained and qualified physician a potential application is to assist in the assessment of tumor response to therapy." This claim is not present in the predicate devices' labeling, and could potentially constitute a new intended use for your device. Please provide data substantiating this claim. This data could possibly include clinical data. Alternately, please remove the claim.

Please note that you name one of your software workflows "Tumor Response." If you cannot provide data supporting the use of your application in support of this function, please modify this phrase in your software and labeling.

**Deficiency #4:** Your IFU statement includes the following claim: "Vitrea® CT Brain Perfusion supports the physician in visualizing the apparent blood perfusion in brain tissue affected by acute stroke." Although this claim appears in the predicate IFU, we were unable to locate data in your submission that substantiates the efficacy of your device for disease-specific claims. This data may include clinical data. Please either substantiate the claim, or remove it from your IFU statement.

**IV. Device Description**

Component	Material(s)	Attributes	Acceptable	
			Yes	No
Software	Software	Reusable Patient contact Implant Biocompatibility Testing Sterilization Cleaning Instructions Electrical/Magnetic/Thermal Compatibility Imaging Contrast Required Life Supporting or Life Sustaining	✓	
The device is software only.				

VitreaAdvanced is a package of post-processing software applications. This package of applications is intended for use with the Vitrea software platform.

The device has the standard features to receive DICOM data, display images, manipulate images, annotate images, perform measurements, and output views to other devices.

The device also includes three advanced applications. A description of these applications (taken from p. 23/662 of the submission) follows:

**Vitrea® CT Body Perfusion** is noninvasive post-processing software that calculates perfusion characteristics from dynamic CT image data. It displays blood flow parametric maps for single-input and dual-input workflows.

**Vitrea® CT Liver Analysis** is noninvasive post-processing software that displays CT image data. It processes image data to segment liver structures and evaluate resection surfaces as well as volumes. Vitrea® CT Liver Analysis provides automatic registration and composite views of multiple series, optimized screen layouts and measurement tools. It also generates

standardized reports for WHO and RECIST protocols and for percentage change tumor response values.

**Vitreac<sup>®</sup> CT Brain Perfusion** is noninvasive post-processing software that calculates cerebral blood flow (CBF), cerebral blood volume (CBV), local bolus timing (i.e., delay of tissue response, time to peak), and mean transit time (MTT) from dynamic CT image data. It displays time density curves, perfusion characteristics in parametric and summary maps, as well as regions of interest and mirrored regions.

**V. Predicate Device Comparison**

As compared to the primary predicate device K072821, the device adds three new modules for analysis of body perfusion images, liver perfusion images, and brain perfusion images.

On p. 24/662 of the submission, the sponsor provides a substantial equivalence discussion. This discussion consists of three tables:

- The sponsor compares the calculations performed by the Body Perfusion module with those performed by K090504. Both devices measure parameters including blood volume mean transit time, etc. The sponsor notes that K090504 has some extra analysis tools including the ability to generate compartment models and Patlak plots.
- The sponsor compares the calculations performed by the Liver Analysis module with those performed by K051528 and K071241. All three devices perform image registration, segmentation, and other basic features. The subject device generates RECIST and WHO reports. This features is not available in K051528 but is available in K071241. The subject device appears to have functionality similar to K051528 but generates data reports in the same manner as K071241.
- The sponsor compares the calculations performed by the Brain Perfusion module with those performed by K072821 and K073238. All three devices calculate standard perfusion parameters such as cerebral blood flow, cerebral blood volume, local bolus timing, and mean transit time. The sponsor notes the following difference from K072821:

[K072821] does not include summary maps (maps that combine parameters).

The other predicate device does combine these maps.

Based on the substantial equivalence comparison, I do not detect issues. The differences between each module and its primary predicate include either the deletion of features (which is not an issue) or the addition of features for which another predicate exists.

FDA has previously cleared software that makes body, brain, and liver perfusion calculations on both MR and CT images, including the predicate devices. I do not see this device as serving a function that is particularly different from all of the other previously cleared devices.

**VI. Labeling**

	Sufficient	
	Yes	No
Manufacturer's Contact Information	✓	
Prescription use statement	✓	
Intended Use / Indications for Use	✓	
Relevant notes, cautions, warnings, and/or contraindications	✓	

Symbols (with description)		N/A
Device Description	✓	
Hardware Requirements (for software)	✓	
Accessories		N/A
Directions for Use	✓	
Performance Specifications		N/A
Description of quality assurance tests (and action limits)		N/A
Marketing brochures/flyers/claims		N/A

The principal labeling deficiency was raised in **Deficiency #3**. Please refer to that deficiency in Section XVI of this memorandum.

### IX. Software

Version: 6.2.2044.

	Sufficient	
	Yes	No
"Guidance for the Content of Premarket Submissions for Software Contained in Medical Devices" <a href="http://www.fda.gov/MedicalDevices/DeviceRegulationandGuidance/GuidanceDocuments/ucm089543.htm">http://www.fda.gov/MedicalDevices/DeviceRegulationandGuidance/GuidanceDocuments/ucm089543.htm</a>		
<u>Level of Concern</u> : [Section 16.2] We agree with the sponsor's identification of the software's level of concern as "Moderate."	✓	
<u>Software Description</u> : [Attachment 16.1] The sponsor provided an acceptable description of the application for image processing, review, and analysis.	✓	
<u>Device Hazard Analysis</u> : [Begins on p. 276/662] For each of the three modules of the device, the sponsor provided a summary of their risk management process, including each hazard, the severity of that hazard, and the ways in which they mitigated each hazard. The sponsor lists primary hazards of this device as occurring from the user's inability to interpret the images due to lack of training or professional expertise.	✓	
<u>Software Requirements Specifications</u> : [p. 283/662] The sponsor listed the functional, performance, interface, design and development requirements for the software.	✓	
<u>Architecture Design Chart</u> : [Section 16.9] The sponsor provided an architecture design chart.	✓	
<u>Design Specifications</u> : [Sections 16.6-16.9]: The sponsor provided three Software Design Specification (SDS) documents, one for each additional module of the software.	✓	
<u>Traceability Analysis/Matrix</u> : [Section 16.10] The sponsor has provided a matrix of traceability between design input and the SRS, the SRS and test cases, and risk reduction methods and test cases. The device has failed some of the tests but the sponsor has provided sufficient explanation (see e.g. pp. 359/662, 361/662).	✓	
<u>Development Environment</u> : [Section 16.11] The sponsor provided a sufficient description of their software development process.	✓	
<u>Verification &amp; Validation Testing</u> : [Section 18] The sponsor describes unit, integration, and system testing on the software.	✓	
<u>Revision Level History</u> : [Section 16.15]. The sponsor provides a list of all versions of the software through the present version, v. 6.2.2044.	✓	
<u>Unresolved Anomalies</u> : [Section 16.16] The sponsor lists unresolved anomalies and explains why the anomalies are not safety issues.	✓	
<u>Off-the-Shelf Software</u> : The software description contains a description of all OTS software. The OTS software includes standard components like Microsoft Windows, etc.		✓
<u>Cyber security</u> : <b>Missing</b> . The hazard analysis included a discussion of how the device would ensure information security (e.g., passwords, firewalls, USB keys, VPN access).		✓

The sponsor provided a DICOM conformance statement in Section 16.3.

**Please see Deficiency #4.**

**XI. Performance Testing – Bench/Animal/Clinical**

The sponsor referred the reviewer to their verification and validation testing documentation; however, the documentation was poorly organized and was not possible to follow. The sponsor should provide clarification of their performance testing.

**Deficiency:** You discussed the performance testing performed on your device by referring to your validation test document VLC-07107. However, this document was difficult to follow, printed in an extremely small font, and contained too much information for us to determine the general approach you took to test the device's safety and effectiveness for the intended uses you describe. Please provide a clear and concise summary of the performance tests you performed to verify and validate the operation of your device. Where your device calculates numerical quantities or makes measurements, please explain how you validated the results of the calculation. Please also summarize any testing performed by external clinicians. In providing us your performance testing data, please pay particular attention to Deficiencies #2 and #3.

**XII. Use of Imaging Agents**

**Deficiency #5:** We were unable to determine which functions of your device required contrast-enhanced images for operation. Please provide a list of applications of your device that require contrast-enhanced images in order to operate. For each application, please indicate which of the predicate devices performed this function and whether they also required contrast-enhanced images for operation.

**XV. Substantial Equivalence Discussion**

	Yes	No	
1. Same Indications for Use statement?		✓	If YES = Go To 3
2. Do differences alter the effect or raise new issues of safety or effectiveness?		✓	If YES = Stop NSE
3. Same technological characteristics?	✓		If YES = Go To 5
4. Could the new characteristics affect safety or effectiveness?			If YES = Go To 6
5. Descriptive characteristics precise enough?		✓	If NO = Go To 8 If YES = Stop SE
6. New types of safety or effectiveness questions?		✓	If YES = Stop NSE
7. Accepted scientific methods exist?		✓	If NO = Stop NSE
8. Performance data available?		✓	If NO = Request Data
9. Data demonstrate equivalence?			Final Decision: SE

1. Explain how the new indication differs from the predicate device's indication:  
The indication adds some language that may or may not reflect new intended uses. See Section XVI (Deficiencies) for details.
2. Explain why there is or is not a new effect or safety or effectiveness issue:

We are trying to establish whether this is the case. We are requesting the sponsor to modify their IFU statement.

3. Describe the new technological characteristics:  
The subject device does not appear to have any significantly new technological characteristics compared to the predicate. The labeling is different.
4. Explain how the new characteristics could or could not affect safety or effectiveness: N/A
5. Explain how descriptive characteristics are not precise enough:  
In general, for postprocessing devices, some performance testing is required in order to assess the device's safety and efficacy.
6. Explain new types of safety or effectiveness question(s) raised or why the question(s) are not new:  
FDA routinely reviews software devices that analyze perfusion images. There are no new questions.
7. Explain why existing scientific methods can not be used: N/A
8. Explain what performance data is needed:  
The sponsor has not clearly explained what performance testing they have performed. We can better answer this question once we understand the data.
9. Explain how the performance data demonstrates that the device is or is not substantially equivalent:  
N/A—recommending telephone hold.

#### **XVI. Deficiencies**

1. In your submission, you provided a 510(k) summary that was administratively complete. However, we would like your 510(k) summary to contain somewhat more detail. Please provide a 510(k) summary for this submission that includes more detail regarding the performance testing that you provided in order to support substantial equivalence.
2. The IFU statement of your chosen predicate device K090504 includes indications for operation on hepatic perfusion. Your device adds a specific indication for performing perfusion calculations on liver, lung and kidney images. We are not clear whether the extra organ-specific language you have added indicates extra device functionality. Please either explain why the new indication does not constitute a new intended use, or provide data in support of this new intended use. Alternately, please remove the added indication.
3. As compared to predicate K071241, you add the claim "when used by a trained and qualified physician a potential application is to assist in the assessment of tumor response to therapy." This claim is not present in the predicate devices' labeling, and could potentially constitute a new intended use for your device. Please provide data substantiating this claim, noting that data required to support condition and disease-specific claims can possibly include clinical data. Alternately, please remove the claim.
4. Your IFU statement includes the following claim: "Vitrea CT Brain Perfusion supports the physician in visualizing the apparent blood perfusion in brain tissue affected by acute stroke." Although this claim appears in the predicate IFU, we were unable to locate data in your submission that substantiates the efficacy of your device for disease-specific claims. As noted in Paragraph 3, the data required to support disease or condition-specific claims may include clinical data. Please either substantiate the claim, or remove it from your IFU statement.
5. You discussed the performance testing performed on your device by referring to your validation test document VLC-07107. However, this document was difficult to follow, containing a very large

amount of information printed in an extremely small font. Based on this document, we had difficulty determining the general approach you took to test the device's safety and effectiveness for the intended uses you describe. Please provide a clear and concise summary of the performance testing you performed to verify and validate the operation of your device. For numerical quantities that your device calculates (e.g. CBV), please explain how you validated the results of the calculation and established substantial equivalence to the predicate. Please also summarize any testing of your device performed by external clinicians. In providing us your performance testing data, please note Paragraphs #2-4 of this letter.

6. We were unable to locate the following software documentation in your submission. If you have already provided these elements of software documentation, please indicate their location in the submission. If you have not provided these elements of software documentation, please provide them:

#### **Cyber and Information security**

Please provide information, as appropriate, on the Cybersecurity aspects of your device, including, but not limited to, the following facets of information security with respect to communications features of your device and associated software: Confidentiality, integrity, availability and accountability.

**Confidentiality** assures that no unauthorized users have access to the information.

**Integrity** is the assurance that the information is correct - that is, it has not been improperly modified.

**Availability** suggests that the information will be available when needed.

**Accountability** is the application of identification and authentication to assure that the prescribed access process is being done by an authorized user.

Please refer to the following guidance document

"Guidance for the Content of Premarket Submissions for Software Contained in Medical Devices"  
<http://www.fda.gov/MedicalDevices/DeviceRegulationandGuidance/GuidanceDocuments/ucm089543.htm>

for further information.

7. We were unable to determine which functions of your device required contrast-enhanced images for operation. Please provide a list of applications of your device that require contrast-enhanced images in order to operate. For each item on this list, please indicate which of the predicate devices performed this function and whether they also required contrast-enhanced images for operation.

#### **XVIII. Recommendation:** Telephone hold

Regulation Number: 21 CFR §892.2050  
Regulation Name: Picture archiving and communications system  
Regulatory Class: Class II  
Product Code: LLZ

*J. Vaishnav*

\_\_\_\_\_  
Jay Vaishnav, PhD

June 21, 2012

\_\_\_\_\_  
Date

*Michael D. O'Keefe*

\_\_\_\_\_  
Supervisor

*6/22/12*

\_\_\_\_\_  
Date

**Vaishnav, Jay**

---

**From:** Morris, Janine M.  
**Sent:** Thursday, June 21, 2012 3:43 PM  
**To:** Vaishnav, Jay; O'Hara, Michael D  
**Subject:** RE: K121213 telephone hold concurrence

Sorry Jay too many distractions. I concur

**Janine M. Morris, Acting Division Director**  
Division of Radiological Devices  
Office of In Vitro Diagnostic Device Evaluation and Safety  
Center for Devices and Radiological Health  
WO66 Room G208  
10903 New Hampshire Ave.  
Silver Spring, MD 20993-0002  
office phone: (301) 796-5706  
blackberry: (301) 318-9659  
janine.morris@fda.hhs.gov

---

**From:** Vaishnav, Jay  
**Sent:** Thursday, June 21, 2012 2:58 PM  
**To:** Morris, Janine M.; O'Hara, Michael D  
**Subject:** RE: K121213 telephone hold concurrence

Hello Mike and Janine. If possible, I would like to put this on hold by the end of today; I'd appreciate it if you could take a look. I can come by and discuss if that would be useful. Thanks!

-Jay

---

**From:** Vaishnav, Jay  
**Sent:** Wednesday, June 20, 2012 5:18 PM  
**To:** Morris, Janine M.; O'Hara, Michael D  
**Subject:** K121213 telephone hold concurrence

Hello Mike and Janine. I discussed this submission with Mike today; it is the Vitrea software (Vital Images, Inc.) that analyzes brain, liver, and body perfusion images. This is the list of deficiencies I would like to send them. Please review—thank you!

It would be helpful if we could get this on hold tomorrow.

Jay

- 
1. In your submission, you provided a 510(k) summary that was administratively complete. However, we would like your 510(k) summary to contain somewhat more detail. Please provide a 510(k) summary for this



Records processed under FOIA Request #2014-9977; Released by CDRH on 12-8-2015  
submission that includes more detail regarding the performance testing that you provided in order to support substantial equivalence.

2. The IFU statement of your chosen predicate device K090504 includes indications for operation on hepatic perfusion. Your device adds a specific indication for performing perfusion calculations on liver, lung and kidney images. We are not clear whether the extra organ-specific language you have added indicates extra device functionality. Please either explain why the new indication does not constitute a new intended use, or provide data in support of this new intended use. Alternately, please remove the added indication.
3. As compared to predicate K071241, you add the claim "when used by a trained and qualified physician a potential application is to assist in the assessment of tumor response to therapy." This claim is not present in the predicate devices' labeling, and could potentially constitute a new intended use for your device. Please provide data substantiating this claim, noting that data required to support condition and disease-specific claims can possibly include clinical data. Alternately, please remove the claim.
4. Your IFU statement includes the following claim: "Vitrea•CT Brain Perfusion supports the physician in visualizing the apparent blood perfusion in brain tissue affected by acute stroke." Although this claim appears in the predicate IFU, we were unable to locate data in your submission that substantiates the efficacy of your device for disease-specific claims. As noted in Paragraph 3, the data required to support disease or condition-specific claims may include clinical data. Please either substantiate the claim, or remove it from your IFU statement.
5. You discussed the performance testing performed on your device by referring to your validation test document VLC-07107. However, this document was difficult to follow, containing a very large amount of information printed in an extremely small font. Based on this document, we had difficulty determining the general approach you took to test the device's safety and effectiveness for the intended uses you describe. Please provide a clear and concise summary of the performance testing you performed to verify and validate the operation of your device. For numerical quantities that your device calculates (e.g. CBV), please explain how you validated the results of the calculation and established substantial equivalence to the predicate. Please also summarize any testing of your device performed by external clinicians. In providing us your performance testing data, please note Paragraphs #2-4 of this letter.
6. We were unable to locate the following software documentation in your submission. If you have already provided these elements of software documentation, please indicate their location in the submission. If you have not provided these elements of software documentation, please provide them:

#### **Cyber and Information security**

Please provide information, as appropriate, on the Cybersecurity aspects of your device, including, but not limited to, the following facets of information security with respect to communications features of your device and associated software: Confidentiality, integrity, availability and accountability.

**Confidentiality** assures that no unauthorized users have access to the information.

**Integrity** is the assurance that the information is correct - that is, it has not been improperly modified.

**Availability** suggests that the information will be available when needed.

**Accountability** is the application of identification and authentication to assure that the prescribed access process is being done by an authorized user.

Please refer to the following guidance document

"Guidance for the Content of Premarket Submissions for Software Contained in Medical Devices"

for further information.

7. We were unable to determine which functions of your device required contrast-enhanced images for operation. Please provide a list of applications of your device that require contrast-enhanced images in order to operate. For each item on this list, please indicate which of the predicate devices performed this function and whether they also required contrast-enhanced images for operation.

**Vaishnav, Jay**

---

**m:** Vaishnav, Jay  
**sent:** Thursday, June 21, 2012 4:59 PM  
**To:** 'dbiank@vitalimages.com'  
**Cc:** O'Hara, Michael D  
**Subject:** K121213 telephone hold

Dear Mr. Biank:

Thank you for submitting the VitreaAdvanced system (K121213) to FDA for 510(k) clearance. As you know, 510(k) clearance requires a finding of substantial equivalence between the submitted device and an appropriate predicate device.

In your submission, you submitted information that you felt demonstrated your device's substantial equivalence to six predicate devices:

- K071331 – Vitrea v 4.0 (Vital Images)
- K072821 – Vitrea 4DCT (Vital Images)
- K090504 – CSBP-001A Body Perfusion System (Toshiba)
- K051528 – MeVis LiverAnalyser/Liver Viewer (Mevis Technology GMBH & Co.)
- K071241 – LMS-Liver (Median Technologies)
- K073238 – syngo Volume Perfusion-CT Neuro (Siemens)

However, we find that there is insufficient information in your submission for us to make a clear determination of the equivalence of your device to the designated predicate devices.

We would therefore appreciate your providing the following additional information:

1. In your submission, you provided a 510(k) summary that was administratively complete. However, we would like your 510(k) summary to contain somewhat more detail. Please provide a 510(k) summary for this submission that includes more detail regarding the performance testing that you provided in order to support substantial equivalence.
2. The IFU statement of your chosen predicate device K090504 includes indications for operation on hepatic perfusion. Your device adds a specific indication for performing perfusion calculations on liver, lung and kidney images. We are not clear whether the extra organ-specific language you have added indicates extra device functionality. Please either explain why the new indication does not constitute a new intended use, or provide data in support of this new intended use. Alternately, please remove the added indication.
3. As compared to predicate K071241, you add the claim "when used by a trained and qualified physician a potential application is to assist in the assessment of tumor response to therapy." This claim is not present in the predicate devices' labeling, and could potentially constitute a new intended use for your device. Please provide data substantiating this claim, noting that data required to support condition and disease-specific claims can possibly include clinical data. Alternately, please remove the claim.
4. Your IFU statement includes the following claim: "Vitrea CT Brain Perfusion supports the physician in visualizing the apparent blood perfusion in brain tissue affected by acute stroke." Although this claim appears in the predicate IFU, we were unable to locate data in your submission that substantiates the efficacy of your device

for disease-specific claims. As noted in Paragraph 3, the data required to support disease or condition-specific claims may include clinical data. Please either substantiate the claim, or remove it from your IFU statement.

5. You discussed the performance testing performed on your device by referring to your validation test document VLC-07107. However, this document was difficult to follow, containing a very large amount of information printed in an extremely small font. Based on this document, we had difficulty determining the general approach you took to test the device's safety and effectiveness for the intended uses you describe. Please provide a clear and concise summary of the performance testing you performed to verify and validate the operation of your device. For numerical quantities that your device calculates (e.g. CBV), please explain how you validated the results of the calculation and established substantial equivalence to the predicate. Please also summarize any testing of your device performed by external clinicians. In providing us your performance testing data, please note Paragraphs #2-4 of this letter.
6. We were unable to locate the following software documentation in your submission. If you have already provided these elements of software documentation, please indicate their location in the submission. If you have not provided these elements of software documentation, please provide them:

### **Cyber and Information security**

Please provide information, as appropriate, on the Cybersecurity aspects of your device, including, but not limited to, the following facets of information security with respect to communications features of your device and associated software: Confidentiality, integrity, availability and accountability.

**Confidentiality** assures that no unauthorized users have access to the information.

**Integrity** is the assurance that the information is correct - that is, it has not been improperly modified.

**Availability** suggests that the information will be available when needed.

**Accountability** is the application of identification and authentication to assure that the prescribed access process is being done by an authorized user.

Please refer to the following guidance document

"Guidance for the Content of Premarket Submissions for Software Contained in Medical Devices"  
<http://www.fda.gov/MedicalDevices/DeviceRegulationandGuidance/GuidanceDocuments/ucm089543.htm>

for further information.

7. We were unable to determine which functions of your device required contrast-enhanced images for operation. Please provide a list of applications of your device that require contrast-enhanced images in order to operate. For each item on this list, please indicate which of the predicate devices performed this function and whether they also required contrast-enhanced images for operation.

At this time, I am recommending that your submission be placed on telephone hold to allow you time to assemble the information we have requested. Please note that telephone hold is not an indication of the quality of your submission or on the likely outcome of the review. Please submit your official response and any additional information you provide to the FDA Document and Mail Center (WO66-G609, 10903 New Hampshire Avenue, Silver Spring, MD 20993-0002) within thirty days. Should you require more than thirty days to assemble the requested materials, please submit a request for additional time to the FDA Document and Mail Center.

Should you have any questions about the additional information required, please contact me; my contact information is below.

Thank you for your attention; I look forward to your prompt response and to continuing my review.

Vaishnav, Ph.D.  
Physicist and Premarket Reviewer  
Division of Radiological Devices (DRAD)  
Food and Drug Administration  
301-796-9580



DEPARTMENT OF HEALTH & HUMAN SERVICES

K 121213/S1  
V.1  
Food and Drug Administration  
10903 New Hampshire Avenue  
Document Control Room – WO66-G609  
Silver Spring, MD 20993-0002

Mr. Daniel Biank  
Regulatory Affairs Manager  
Vital Images, Inc.  
5850 Opus Parkway, Suite 300  
Minnetonka, MN 55343

NOV 2 2012

Re: K121213  
Trade/Device Name: VitreaAdvanced  
Regulation Number: 21 CFR 892.2050  
Regulation Name: Picture archiving and communications system  
Regulatory Class: II  
Product Code: LLZ  
Dated: October 5, 2012  
Received: October 9, 2012

Dear Mr. Biank:

We have reviewed your Section 510(k) premarket notification of intent to market the device referenced above and have determined the device is substantially equivalent (for the indications for use stated in the enclosure) to legally marketed predicate devices marketed in interstate commerce prior to May 28, 1976, the enactment date of the Medical Device Amendments, or to devices that have been reclassified in accordance with the provisions of the Federal Food, Drug, and Cosmetic Act (Act) that do not require approval of a premarket approval application (PMA). You may, therefore, market the device, subject to the general controls provisions of the Act. The general controls provisions of the Act include requirements for annual registration, listing of devices, good manufacturing practice, labeling, and prohibitions against misbranding and adulteration.

If your device is classified (see above) into class II (Special Controls), it may be subject to such additional controls. Existing major regulations affecting your device can be found in Title 21, Code of Federal Regulations (CFR), Parts 800 to 895. In addition, FDA may publish further announcements concerning your device in the Federal Register.


Please be advised that FDA's issuance of a substantial equivalence determination does not mean that FDA has made a determination that your device complies with other requirements of the Act or any Federal statutes and regulations administered by other Federal agencies. You must comply with all the Act's requirements, including, but not limited to: registration and listing (21 CFR Part 807); labeling (21 CFR Parts 801 and 809); medical device reporting (reporting of

medical device-related adverse events) (21 CFR 803); and good manufacturing practice requirements as set forth in the quality systems (QS) regulation (21 CFR Part 820). This letter will allow you to begin marketing your device as described in your Section 510(k) premarket notification. The FDA finding of substantial equivalence of your device to a legally marketed predicate device results in a classification for your device and thus, permits your device to proceed to the market.

If you desire specific advice for your device on our labeling regulation (21 CFR Parts 801 and 809), please contact the Office of *In Vitro* Diagnostic Device Evaluation and Safety at (301) 796-5450. Also, please note the regulation entitled, "Misbranding by reference to premarket notification" (21 CFR Part 807.97). For questions regarding the reporting of adverse events under the MDR regulation (21 CFR Part 803), please go to <http://www.fda.gov/MedicalDevices/Safety/ReportaProblem/default.htm> for the CDRH's Office of Surveillance and Biometrics/Division of Postmarket Surveillance.

You may obtain other general information on your responsibilities under the Act from the Division of Small Manufacturers, International and Consumer Assistance at its toll-free number (800) 638-2041 or (301) 796-7100 or at its Internet address <http://www.fda.gov/cdrh/industry/support/index.html>.

Sincerely Yours,



Janine M. Morris  
Director

Division of Radiological Health  
Office of In Vitro Diagnostics  
and Radiological Health  
Center for Devices and Radiological Health

Enclosure

## Indications for Use

510(k) Number (if known): **K121213**

Device Name: VitreAdvanced

### Indications for Use:

VitreAdvanced is a medical diagnostic system for the processing, review, analysis, communication and media interchange of multi-dimensional digital images acquired from a variety of imaging devices. VitreAdvanced is not meant for primary image interpretation in mammography. It can be used with a variety of cleared Vitrea<sup>®</sup> based software applications. In addition, VitreAdvanced includes three Vitrea<sup>®</sup> applications:

**Vitre<sup>®</sup> CT Body Perfusion** is a noninvasive post-processing application designed to evaluate perfusion of organs and tumors. The software can calculate perfusion characteristics from dynamic CT image data acquired after the injection of contrast media. The software also allows the separate calculation of the arterial and venous components of perfusion in organs. It supports evaluation of regions of interest and the visual inspection of time density curves. When used by a trained and qualified physician a potential application is to differentiate blood flow between normal and diseased tissue. Determination of the change of perfusion parameters during the course of treatment may be helpful in therapy monitoring.

**Vitre<sup>®</sup> CT Liver Analysis** is a noninvasive post-processing application designed to evaluate liver tumors and plan for liver surgery. It displays images for analysis and preoperative liver surgery planning, such as organ segmentation, tumor segmentation and intrahepatic vessels segmentation, as well as the approximation of vascular territories. It supports preoperative evaluation of specific surgery strategies by allowing the user to interactively define virtual resections splitting the liver. It also allows the user to evaluate safety-margins around lesions and to identify affected vascular branches and territories. Vitrea<sup>®</sup> CT Liver Analysis also provides automatic registration of multiple series and measurement tools for characterization and follow-up of the lesions. When used by a trained and qualified physician a potential application is to assist in the assessment of tumor response to therapy.

**Vitre<sup>®</sup> CT Brain Perfusion** is a noninvasive post-processing application designed to evaluate areas of brain perfusion. The software can calculate cerebral blood flow (CBF), cerebral blood volume (CBV), local bolus timing (i.e., delay of tissue response, time to peak), and mean transit time (MTT) from dynamic CT image data acquired after the injection of contrast media. The package also allows the calculation of regions of interest and mirrored regions, as well as the visual inspection of time density curves. Vitrea<sup>®</sup> CT Brain Perfusion supports the physician in visualizing the apparent blood perfusion in brain tissue affected by acute stroke. Areas of decreased perfusion, as is observed in acute cerebral infarcts, appear as areas of changed signal intensity (lower for both CBF and CBV and higher for time to peak and MTT).

Prescription Use X  
(Part 21 CFR 801 Subpart D)

AND/OR

Over-The-Counter Use \_\_\_\_\_  
(21 CFR 807 Subpart C)

  
(Division Sign Off)

Division of Radiological Health

Office of In Vitro Diagnostics and Radiological Health

Questions? Contact FDA/CDRH/OCE/DDI at CDRH-FOISTATUS@fda.hhs.gov or 301-796-8118

510(k) K121213



\* \* \* COMMUNICATION RESULT REPORT ( NOV. 5. 2012 11:59AM ) \* \* \*

FAX HEADER 1:  
FAX HEADER 2:

TRANSMITTED/STORED : NOV. 5. 2012 11:57AM  
FILE MODE OPTION

ADDRESS

RESULT

PAGE

0725 MEMORY TX

Vital Images

OK

3/3

REASON FOR ERROR  
E-1) HANG UP OR LINE FAIL  
E-3) NO ANSWER

E-2) BUSY  
E-4) NO FACSIMILE CONNECTION



**DEPARTMENT OF HEALTH & HUMAN SERVICES**

Public Health Service

Food and Drug Administration  
10903 New Hampshire Avenue  
Document Control Room - WO66-G609  
Silver Spring, MD 20993-0002

Mr. Daniel Biank  
Regulatory Affairs Manager  
Vital Images, Inc.  
5850 Opus Parkway, Suite 300  
Minnetonka, MN 55343

NOV 2 2012

Re: K121213  
Trade/Device Name: VitreaAdvanced  
Regulation Number: 21 CFR 892.2050  
Regulation Name: Picture archiving and communications system  
Regulatory Class: II  
Product Code: LLZ  
Dated: October 5, 2012  
Received: October 9, 2012

Dear Mr. Biank:

We have reviewed your Section 510(k) premarket notification of intent to market the device referenced above and have determined the device is substantially equivalent (for the indications for use stated in the enclosure) to legally marketed predicate devices marketed in interstate commerce prior to May 28, 1976, the enactment date of the Medical Device Amendments, or to devices that have been reclassified in accordance with the provisions of the Federal Food, Drug, and Cosmetic Act (Act) that do not require approval of a premarket approval application (PMA). You may, therefore, market the device, subject to the general controls provisions of the Act. The general controls provisions of the Act include requirements for annual registration, listing of devices, good manufacturing practice, labeling, and prohibitions against misbranding and adulteration.

If your device is classified (see above) into class II (Special Controls), it may be subject to such additional controls. Existing major regulations affecting your device can be found in Title 21, Code of Federal Regulations (CFR), Parts 800 to 895. In addition, FDA may publish further announcements concerning your device in the Federal Register.

Please be advised that FDA's issuance of a substantial equivalence determination does not mean that FDA has made a determination that your device complies with other requirements of the Act or any Federal statutes and regulations administered by other Federal agencies. You must comply with all the Act's requirements, including, but not limited to: registration and listing (21 CFR Part 807); labeling (21 CFR Parts 801 and 809); medical device reporting (reporting of



# COVER SHEET MEMORANDUM

**From:** Reviewer Name Jay Vaishnav  
**Subject:** 510(k) Number R12/Z18/S1  
**To:** The Record

Please list CTS decision code SE

- Refused to accept (Note: this is considered the first review cycle, See Screening Checklist [http://eroom.fda.gov/eRoomReg/Files/CDRH3/CDRHPremarketNotification510kProgram/0\\_5631/Screening%20Checklist%207%202%2007.doc](http://eroom.fda.gov/eRoomReg/Files/CDRH3/CDRHPremarketNotification510kProgram/0_5631/Screening%20Checklist%207%202%2007.doc))
- Hold (Additional Information or Telephone Hold).
- Final Decision (SE, SE with Limitations, NSE (select code below), Withdrawn, etc.).

### Not Substantially Equivalent (NSE) Codes

- NO NSE for lack of predicate
- NI NSE for new intended use
- NQ NSE for new technology that raises new questions of safety and effectiveness
- NU NSE for new intended use AND new technology raising new questions of safety and effectiveness
- NP NSE for lack of performance data
- NS NSE no response
- NL NSE for lack of performance data AND no response
- NM NSE pre-amendment device call for PMAs (515i)
- NC NSE post-amendment device requires PMAs
- NH NSE for new molecular entity requires PMA
- TR NSE for transitional device

Please complete the following for a final clearance decision (i.e., SE, SE with Limitations, etc.):		YES	NO
Indications for Use Page	Attach IFU	✓	
510(k) Summary /510(k) Statement	Attach Summary	✓	
Truthful and Accurate Statement.	Must be present for a Final Decision	✓	
Is the device Class III?			✓
If yes, does firm include Class III Summary?	Must be present for a Final Decision		✓
Does firm reference standards? (If yes, please attach form from <a href="http://www.fda.gov/opacom/morechoices/fdaforms/FDA-3654.pdf">http://www.fda.gov/opacom/morechoices/fdaforms/FDA-3654.pdf</a> )		✓	✓
Is this a combination product? (Please specify category _____, see <a href="http://eroom.fda.gov/eRoomReg/Files/CDRH3/CDRHPremarketNotification510kProgram/0_413b/COMBINATION%20PRODUCT%20ALGORITHM%20(REVISED%203-12-03).DOC">http://eroom.fda.gov/eRoomReg/Files/CDRH3/CDRHPremarketNotification510kProgram/0_413b/COMBINATION%20PRODUCT%20ALGORITHM%20(REVISED%203-12-03).DOC</a> )			✓
Is this a reprocessed single use device? (Guidance for Industry and FDA Staff – MDUFMA - Validation Data in 510(k)s for Reprocessed Single-Use Medical Devices, <a href="http://www.fda.gov/cdrh/ode/guidance/1216.html">http://www.fda.gov/cdrh/ode/guidance/1216.html</a> )			✓
Is this device intended for pediatric use only?		✓	
Is this a prescription device? (If both prescription & OTC, check both boxes.)		✓	
Did the application include a completed FORM FDA 3674, Certification with Requirements of ClinicalTrials.gov Data Bank?			✓
Is clinical data necessary to support the review of this 510(k)?			✓
For United States-based clinical studies only: Did the application include a completed FORM FDA 3674, Certification with Requirements of ClinicalTrials.gov Data Bank? (If study was			

conducted in the United States, and FORM FDA 3674 was not included or incomplete, then applicant must be contacted to obtain completed form.)

Does this device include an Animal Tissue Source? ✓

All Pediatric Patients age <= 21 ✓

Neonate/Newborn (Birth to 28 days)

Infant (29 days - < 2 years old)

Child (2 years - < 12 years old)

Adolescent (12 years - < 18 years old)

Transitional Adolescent A (18 - < 21 years old) Special considerations are being given to this group, different from adults age ≥ 21 (different device design or testing, different protocol procedures, etc.)

Transitional Adolescent B (18 - <= 21; No special considerations compared to adults => 21 years old)

Nanotechnology ✓

Is this device subject to the Tracking Regulation? (Medical Device Tracking Guidance, <http://www.fda.gov/cdrh/comp/guidance/169.html>)

Contact OC. ✓

Regulation Number	Class*	Product Code
21 CFR 892.2050	II	LL2

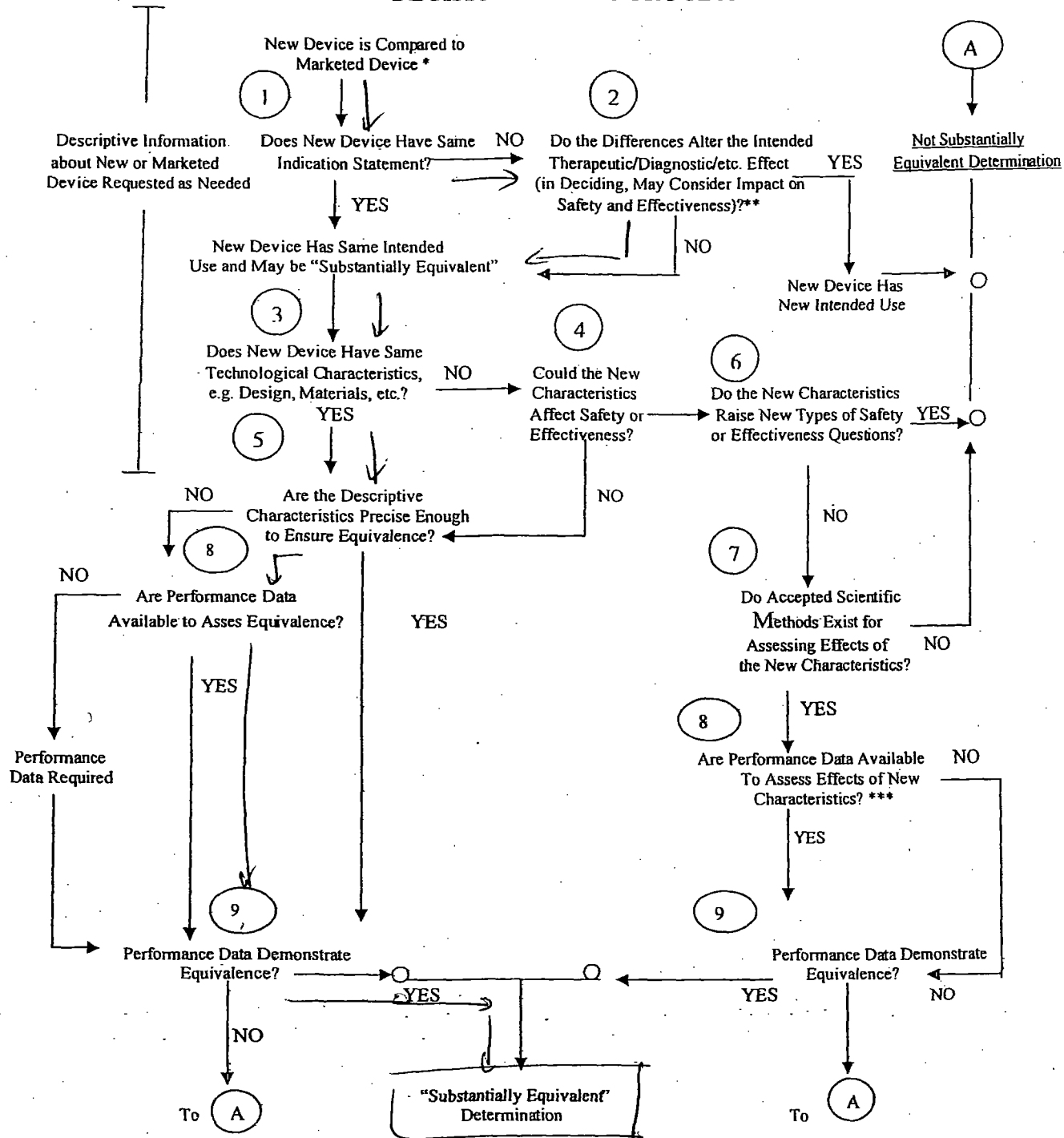
(\*If unclassified, see 510(k) Staff)

Additional Product Codes: \_\_\_\_\_

Review: \_\_\_\_\_  
(Branch Chief) EPMR (Branch Code) \_\_\_\_\_ (Date)

Final Review: [Signature] \_\_\_\_\_  
(Division Director) 11/2/12 (Date)

## 510(k) "SUBSTANTIAL EQUIVALENCE" DECISION-MAKING PROCESS



\* 510(k) Submissions compare new devices to marketed devices. FDA requests additional information if the relationship between marketed and "predicate" (pre-Amendments or reclassified post-Amendments) devices is unclear.

\*\* This decision is normally based on descriptive information alone, but limited testing information is sometimes required.

\*\*\* Data may be in the 510(k), other 510(k)s, the Center's classification files, or the literature.



**Premarket Notification [510(k)] Review  
Traditional/Abbreviated**

**K121213**

Date: November 1, 2012  
To: The Record Office: OIVD  
From: Jay Y. Vaishnav, Ph.D. Division: DRAD

510(k) Holder: Vital Images, Inc.  
Device Name: VitreaAdvanced  
Contact: Daniel Biank  
Vital Images, Inc.  
5850 Opus Parkway, Suite 300  
Minnetonka, MN 55343-4414  
Phone: 952-487-9514  
Email: [dbiank@vitalimages.com](mailto:dbiank@vitalimages.com)

**I. Purpose and Submission Summary**

Vital Images, Inc. is submitting a Traditional 510(k) for the VitreaAdvanced software. This submission is essentially a bundled submission. This review is the second review of this submission.

The sponsor is claiming substantial equivalence to the following legally marketed predicate devices:

- K071331 – Vitrea v 4.0 (Vital Images)
- K072821 – Vitrea 4DCT (Vital Images)
- K090504 – CSBP-001A Body Perfusion System (Toshiba)
- K051528 – MeVis LiverAnalyser/Liver Viewer (Mevis Technology GMBH & Co.)
- K071241 – LMS-Liver (Median Technologies)
- K073238 – syngo Volume Perfusion-CT Neuro (Siemens)

The sponsor intends to demonstrate that the software is substantially equivalent to K071331 (Vitrea, v. 4.0, K071331), and includes other applications for Computed Tomography (CT) Body Perfusion, CT Liver Analysis and CT Brain Perfusion that the sponsor claims are equivalent to other legally marketed devices.

In particular, the sponsor will claim substantial equivalence between

Vitrea CT Body Perfusion and Toshiba's CSBP-001A Body Perfusion System (K090504)

Vitrea CT Liver Analysis and the MeVis Liver Analyser/LiverViewer (K051528) and Median Technologies' LMS-Liver (K071241 ),

Vitrea CT Brain Perfusion and Vital Images' previously cleared Vitrea 4DCT package (K072821) as well as Siemens Medical Solutions' syngo Volume Perfusion-CT Neuro (K073238).

**Differences from Predicate Device**

This device adds three new modules to the primary predicate device. These modules analyze

images from brain, body, and liver perfusion respectively.

The sponsor has added additional predicates which overlap the function of each module.

**S000:** The labeling claims in this device appeared to be expanded over some of these predicates. There are also some claims that do appear in the predicate IFUs, but are condition and disease specific. I am requesting additional data in support of those claims. Please see Section XVI of this memorandum ("Deficiencies") for further details.

**S001:** In response to deficiencies issued in S000, the sponsor has reduced the scope of some of the labeling claims and provided supporting evidence for some of the others. I do not identify remaining deficiencies.

Recommendation: Substantially Equivalent

**II. Administrative Requirements**

	Sufficient	
	Yes	No
CDRH Premarket Review Submission Cover Sheet (Form FDA 3514)	✓	
510(k) Cover Letter	✓	
Indications for Use	Rx	
510(k) Summary	✓	
(a) 510(k) Summary is in sufficient detail to provide an understanding of the basis for a determination of substantial equivalence (21 CFR §807.92)	✓	
(1) Submitter's Contact Information	✓	
(2) Device Name	✓	
(3) Predicate Identification	✓	
(4) Device Description	✓	
(5) Intended Use Statement	✓	
(6) Technological Characteristics Comparison	✓	
(b) Performance Data	✓	
(1) Brief Discussion of Nonclinical Tests	✓	
(2) Brief Discussion of Clinical Tests		N/A
(3) Test Conclusions	✓	
Truthful and Accuracy Statement	✓	
Class III Summary		N/A
Financial Certification or Disclosure Statement		N/A
Standards Form (FDA 3654)		✓
• DICOM - Digital Imaging and Communications in Medicine v. 3		
Clinical Trials Form (FDA 3674)		N/A

**Deficiency #1:** In your submission, you provided a 510(k) summary that was administratively complete. However, we would like your 510(k) summary to contain somewhat more detail. Please provide a 510(k) summary for this submission that includes more detail regarding the performance testing that you provided in order to support substantial equivalence.

**Closed (S001).** The sponsor provided a new 510(k) summary. Please see Section XVI of this memorandum for further information.

### **III. Indications for Use**

The device is correctly indicated as being for prescription use. The IFU statement for the subject device follows:

**K121213, VitreaAdvanced (Vital Images, Inc.)**

**LLZ (21 CFR §892.2050)**

VitreaAdvanced is a medical diagnostic system for the processing, review, analysis, communication and media interchange of multi-dimensional digital images acquired from a variety of imaging devices. VitreaAdvanced is not meant for primary image interpretation in mammography. It can be used with a variety of cleared Vitrea® based software applications. In addition, VitreaAdvanced includes the following indications:

**Vitrea CT Body Perfusion** is a noninvasive post-processing application designed to evaluate perfusion of organs and tumors. The software can calculate perfusion characteristics from dynamic CT image data acquired after the injection of contrast media. The software also allows the separate calculation of the arterial and venous components of perfusion in organs (e.g., liver, lung and kidney). It supports evaluation of regions of interest and the visual inspection of time density curves. When used by a trained and qualified physician a potential application is to differentiate blood flow between normal and diseased tissue. Determination of the change of perfusion parameters during the course of treatment may be helpful in therapy monitoring.

**Vitrea CT Liver Analysis** is a noninvasive post-processing application designed to evaluate liver tumors and plan for liver surgery. It displays images for analysis and preoperative liver surgery planning, such as organ segmentation, tumor segmentation and intrahepatic vessels segmentation, as well as the approximation of vascular territories. It supports preoperative evaluation of specific surgery strategies by allowing the user to interactively define virtual resections splitting the liver. It also allows the user to evaluate safety-margins around lesions and to identify affected vascular branches and territories. Vitrea® CT Liver Analysis also provides automatic registration of multiple series and measurement tools for characterization and follow-up of the lesions. When used by a trained and qualified physician a potential application is to assist in the assessment of tumor response to therapy.

**Vitrea CT Brain Perfusion** is a noninvasive post-processing application designed to evaluate areas of brain perfusion. The software can calculate cerebral blood flow (CBF), cerebral blood volume (CBV), local bolus timing (i.e., delay of tissue response, time to peak), and mean transit time (MTT) from dynamic CT image data acquired after the injection of contrast media. The package also allows the calculation of regions of interest and mirrored regions, as well as the visual inspection of time density curves. Vitrea® CT Brain Perfusion supports the physician in visualizing the apparent blood perfusion in brain tissue affected by acute stroke. Areas of decreased perfusion, as is observed in acute cerebral infarcts, appear as areas of changed signal intensity (lower for both CBF and CBV and higher for time to peak and MTT).

The sponsor claims substantial equivalence to the following legally marketed predicate devices. The primary predicate device is this one:

**K072821, Vitrea 4DCT Medical Image Processing Software (Vital Images)**

**JAK (21 CFR §892.1750)**

Vitrea is a medical diagnostic system that allows the processing, review, analysis, communication and

media interchange of multi-dimensional digital images acquired from a variety of imaging devices. In addition, Vitrea 4DCT has the following indication:  
The Vitrea 4DCT Brain Perfusion option is intended for post processing based on dynamic CT images continuously acquired during the injection of contrast, for the visualization of apparent blood flow in brain tissue and pictorial illustration of perfusion-related parameters to aid in the assessment of the type and extent of cerebral perfusion disturbances.

Comparing the first paragraph of this IFU to the first paragraph of the IFU statement of the subject device, there are no concerns.

**K090504, Body Perfusion System, CSBP-OO1A (Toshiba)**

**JAK (21 CFR §892.1750)**

The Body Perfusion System software package is a noninvasive post-processing package that has been designed to evaluate perfusion of organs and tumors. The software can calculate blood flow, blood volume and permeability from sets of images reconstructed from dynamic CT data acquired after the injection of contrast media. The software also allows the separate calculation of the arterial and portal venous component of hepatic perfusion. It supports evaluation of regions of interest and the visual inspection of time density curves.

When used by a qualified physician a potential application is to differentiate blood flow between normal and diseased tissue. Determination of the change of perfusion parameters during the course of treatment may be helpful in therapy monitoring.

It should be used by a trained and qualified physician.

The above IFU statement should be compared to the relevant portion of the subject device's IFU statement, which states

"Vitrea CT Body Perfusion is a noninvasive post-processing application designed to evaluate perfusion of organs and tumors. The software can calculate perfusion characteristics from dynamic CT image data acquired after the injection of contrast media. The software also allows the separate calculation of the arterial and venous components of perfusion in organs (e.g., liver, **lung and kidney**). It supports evaluation of regions of interest and the visual inspection of time density curves. When used by a trained and qualified physician a potential application is to differentiate blood flow between normal and diseased tissue. Determination of the change of perfusion parameters during the course of treatment may be helpful in therapy monitoring."

**Reviewer Note:** The subject device adds to the predicate indication an intended use for performing perfusion calculations on lung and kidney images.

**K051528, MeVis LiverAnalyzer / LiverViewer Software (MeVis)**

**LLZ (21 CFR §892.2050)**

The MeVis LiverAnalyzer / LiverViewer Software™ device is intended for preoperative planning in liver surgery. The device is used to analyze data and to display image analysis and risk analysis results for the preoperative planning in liver surgery, e.g. organ segmentation, tumor segmentation, segmentation of intrahepatic vessels as well as the approximation of vascular territories. Preoperative evaluation of specific surgery strategies is supported by the feature to interactively define virtual resections splitting the liver or to calculate safety-margins around lesions identifying affected vascular branches and vascular territories supplied or drained by these branches. Medical image data is derived from various sources (i.e. CT scanners, MRI scanners). Typical users of this system are trained professionals, including physicians, nurses, and technicians.

**K071241, LMVS-Liver (MEDIAN Technologies)**

**LLZ (21 CFR §892.2050)**

LMVS-Liver is an image analysis software application for evaluating CT images covering the liver area. It is designed to assist radiologists in the evaluation and documentation of lesions. It also



provides tools for assessment of lesion evolution overtime. LMVS-Liver offers measurement tools and 3D registration techniques for characterization and follow-up of the lesions. It also offers reporting capabilities making it possible to generate standardized reports. LMVS-Liver is intended to be used by radiologists and other clinicians qualified to interpret CT images. LMVS-Liver device is designed to be used with CT images covering the liver area in adult patients.

Comparing both of the above to the relevant portion of the subject IFU,

**Vitreac<sup>®</sup> CT Liver Analysis** is a noninvasive post-processing application designed to evaluate liver tumors and plan for liver surgery. It displays images for analysis and preoperative liver surgery planning, such as organ segmentation, tumor segmentation and intrahepatic vessels segmentation, as well as the approximation of vascular territories. It supports preoperative evaluation of specific surgery strategies by allowing the user to interactively define virtual resections splitting the liver. It also allows the user to evaluate safety-margins around lesions and to identify affected vascular branches and territories. Vitreac<sup>®</sup> CT Liver Analysis also provides automatic registration of multiple series and measurement tools for characterization and follow-up of the lesions. **When used by a trained and qualified physician a potential application is to assist in the assessment of tumor response to therapy.**

The subject device contains a new tool claim stating that the device is intended for use in tumor therapy.

**K072821, syngo<sup>®</sup> Volume Perfusion-CT Neuro**

**JAK (21 CFR §892.1750)**

The Siemens syngo<sup>®</sup> Volume Perfusion-CT Neuro software package has been designed to evaluate areas of brain perfusion. The software can calculate cerebral blood flow (CBF), cerebral blood volume (CBV), local bolus timing (i.e. time to start, time to peak), mean transit time (MTT), and vascular permeability (blood brain barrier disturbances) from sets of images or volumes reconstructed from continuously acquired CT data after the injection of contrast media. The package also allows the calculation of mirrored regions or volumes of interest and the visual inspection of time attenuation curves. One clinical application is to visualize the apparent blood perfusion in brain tissue affected by acute stroke. Areas of decreased perfusion, as is observed in acute cerebral infarcts, appear as areas of changed signal intensity (lower for CBF and CBV, higher for time to peak and MTT). Syngo<sup>®</sup> Volume Perfusion-CT Neuro supports the physician in identifying areas of decreased perfusion which indicate the occurrence of acute stroke during the first 6 hours after onset of symptoms. A second application is the visualization of the permeability. It is used for the modeling of extravascular leakage of blood into the interstitial space. This additional capability can display blood brain barrier disturbances and thus may improve the differential diagnosis of brain tumors and be helpful in therapy monitoring.

The sponsor makes the following claim:

"Vitreac<sup>®</sup> CT Brain Perfusion supports the physician in visualizing the apparent blood perfusion in brain tissue affected by acute stroke. Areas of decreased perfusion, as is observed in acute cerebral infarcts, appear as areas of changed signal intensity (lower for both CBF and CBV and higher for time to peak and MTT)."

This is a tool claim that the device assists a physician in identifying stroke. The claim was cleared after extensive discussion in predicate K072821 as well as the predicate of that device, which includes data in support of the claim. This submission does not appear to include such data. **Please see Deficiency #4.**

**Reviewer Note:** Some of the predicates are under a different regulation and procode (21CFR892.1750, JAK) than the subject device. This is because the 2000 PACS guidance stated that devices designated for use with a single modality are no longer treated as accessories to that modality, but rather considered to be medical image management devices and subject to the applicable requirements and exemptions. The different regulations are not an issue.

**Deficiency #2:** The IFU statement of your chosen predicate device K090504 includes indications for operation on hepatic perfusion. Your device adds to the predicate indication a specific indication for performing perfusion calculations on liver, lung and kidney images. We are not clear whether the extra language you have added indicates extra device functionality. Please either explain why the new indication does not constitute a new intended use, or provide data in support of this new intended use. Alternately, please remove the added indication.

**Closed (S001).** The sponsor has removed the indication. Please see Section XVI of this memorandum for further information.

**Deficiency #3:** As compared to predicate K071241, you add the claim "when used by a trained and qualified physician a potential application is to assist in the assessment of tumor response to therapy." This claim is not present in the predicate devices' labeling, and could potentially constitute a new intended use for your device. Please provide data substantiating this claim. This data could possibly include clinical data. Alternately, please remove the claim.

Please note that you name one of your software workflows "Tumor Response." If you cannot provide data supporting the use of your application in support of this function, please modify this phrase in your software and labeling.

**Closed (S001).** The sponsor notes that labeling indicating that the device measures tumor response is in fact present throughout the predicate K071241's labeling, and that the predicate device also has a workflow called "tumor response." The reviewer was not aware of this and is satisfied with the resolution of the deficiency. Please see Section XVI of this memorandum.

**Deficiency #4:** Your IFU statement includes the following claim: "Vitrea® CT Brain Perfusion supports the physician in visualizing the apparent blood perfusion in brain tissue affected by acute stroke." Although this claim appears in the predicate IFU, we were unable to locate data in your submission that substantiates the efficacy of your device for disease-specific claims. This data may include clinical data. Please either substantiate the claim, or remove it from your IFU statement.

**Closed (S001).** In Appendix A-2 of the supplement, the sponsor has provided supporting evidence including literature using the Vitrea device that has been used to visualize blood perfusion in brain tissue. The lead reviewer has, furthermore concluded that this is a tool claim and not a condition-specific diagnostic claim. The lead reviewer is willing to accept the claim. Please see Section XVI of this memorandum.

**IV. Device Description**

Component	Material(s)	Attributes	Acceptable	
			Yes	No
Software	Software	Reusable Patient contact Implant Biocompatibility Testing Sterilization Cleaning Instructions Electrical/Magnetic/Thermal Compatibility Imaging Contrast Required Life-Supporting or Life-Sustaining	✓	
The device is software only.				

VitreaAdvanced is a package of post-processing software applications. This package of applications is intended for use with the Vitrea software platform.

The device has the standard features to receive DICOM data, display images, manipulate images, annotate images, perform measurements, and output views to other devices.

The device also includes three advanced applications. A description of these applications (taken from p. 23/662 of the submission) follows:

**Vitreac<sup>®</sup> CT Body Perfusion** is noninvasive post-processing software that calculates perfusion characteristics from dynamic CT image data. It displays blood flow parametric maps for single-input and dual-input workflows.

**Vitreac<sup>®</sup> CT Liver Analysis** is noninvasive post-processing software that displays CT image data. It processes image data to segment liver structures and evaluate resection surfaces as well as volumes. Vitreac<sup>®</sup> CT Liver Analysis provides automatic registration and composite views of multiple series, optimized screen layouts and measurement tools. It also generates standardized reports for WHO and RECIST protocols and for percentage change tumor response values.

**Vitreac<sup>®</sup> CT Brain Perfusion** is noninvasive post-processing software that calculates cerebral blood flow (CBF), cerebral blood volume (CBV), local bolus timing (i.e., delay of tissue response, time to peak), and mean transit time (MTT) from dynamic CT image data. It displays time density curves, perfusion characteristics in parametric and summary maps, as well as regions of interest and mirrored regions.

#### **V. Predicate Device Comparison**

As compared to the primary predicate device K072821, the device adds three new modules for analysis of body perfusion images, liver perfusion images, and brain perfusion images.

On p. 24/662 of the submission, the sponsor provides a substantial equivalence discussion. This discussion consists of three tables:

- The sponsor compares the calculations performed by the Body Perfusion module with those performed by K090504. Both devices measure parameters including blood volume mean transit time, etc. The sponsor notes that K090504 has some extra analysis tools including the ability to generate compartment models and Patlak plots.
- The sponsor compares the calculations performed by the Liver Analysis module with those performed by K051528 and K071241. All three devices perform image registration, segmentation, and other basic features. The subject device generates RECIST and WHO reports. This features is not available in K051528 but is available in K071241. The subject device appears to have functionality similar to K051528 but generates data reports in the same manner as K071241.
- The sponsor compares the calculations performed by the Brain Perfusion module with those performed by K072821 and K073238. All three devices calculate standard perfusion parameters such as cerebral blood flow, cerebral blood volume, local bolus timing, and mean transit time. The sponsor notes the following difference from K072821:

[K072821] does not include summary maps (maps that combine parameters).

The other predicate device does combine these maps.

Based on the substantial equivalence comparison, I do not detect issues. The differences between each module and its primary predicate include either the deletion of features (which is not an issue) or the addition of features for which another predicate exists.

FDA has previously cleared software that makes body, brain, and liver perfusion calculations on both MR and CT images, including the predicate devices. I do not see this device as serving a function that is particularly different from all of the other previously cleared devices.

**VI. Labeling**

	Sufficient	
	Yes	No
Manufacturer's Contact Information	✓	
Prescription use statement	✓	
Intended Use / Indications for Use	✓	
Relevant notes, cautions, warnings, and/or contraindications	✓	
Symbols ( <i>with description</i> )		N/A
Device Description	✓	
Hardware Requirements (for software)	✓	
Accessories		N/A
Directions for Use	✓	
Performance Specifications		N/A
Description of quality assurance tests (and action limits)		N/A
Marketing brochures/flyers/claims		N/A

The principal labeling deficiency was raised in **Deficiency #3 (closed in S001)**. Please refer to that deficiency and its resolution in Section XVI of this memorandum.

**IX. Software**

Version: 6.2.2044.

	Sufficient	
	Yes	No
"Guidance for the Content of Premarket Submissions for Software Contained in Medical Devices" <a href="http://www.fda.gov/MedicalDevices/DeviceRegulationandGuidance/GuidanceDocuments/ucm089543.htm">http://www.fda.gov/MedicalDevices/DeviceRegulationandGuidance/GuidanceDocuments/ucm089543.htm</a>		
<u>Level of Concern:</u> [Section 16.2] We agree with the sponsor's identification of the software's level of concern as "Moderate."	✓	
<u>Software Description:</u> [Attachment 16.1] The sponsor provided an acceptable description of the application for image processing, review, and analysis.	✓	
<u>Device Hazard Analysis:</u> [Begins on p. 276/662] For each of the three modules of the device, the sponsor provided a summary of their risk management process, including each hazard, the severity of that hazard, and the ways in which they mitigated each hazard. The sponsor lists primary hazards of this device as occurring from the user's inability to interpret the images due to lack of training or professional expertise.	✓	
<u>Software Requirements Specifications:</u> [p. 283/662] The sponsor listed the functional, performance, interface, design and development requirements for the software.	✓	
<u>Architecture Design Chart:</u> [Section 16.9] The sponsor provided an architecture design chart.	✓	
<u>Design Specifications:</u> [Sections 16.6-16.9]: The sponsor provided three Software Design Specification (SDS) documents, one for each additional module of the software.	✓	
<u>Traceability Analysis/Matrix:</u> [Section 16.10] The sponsor has provided a matrix of traceability between design input and the SRS, the SRS and test cases, and risk reduction methods and test cases. The device has failed some of the tests but the sponsor has provided sufficient explanation (see e.g. pp. 359/662, 361/662).	✓	

"Guidance for the Content of Premarket Submissions for Software Contained in Medical Devices" <a href="http://www.fda.gov/MedicalDevices/DeviceRegulationandGuidance/GuidanceDocuments/ucm089543.htm">http://www.fda.gov/MedicalDevices/DeviceRegulationandGuidance/GuidanceDocuments/ucm089543.htm</a>	Sufficient	
	Yes	No
<u>Development Environment</u> : [Section 16.11] The sponsor provided a sufficient description of their software development process.	✓	
<u>Verification &amp; Validation Testing</u> : [Section 18] The sponsor describes unit, integration, and system testing on the software.	✓	
<u>Revision Level History</u> : [Section 16.15]. The sponsor provides a list of all versions of the software through the present version, v. 6.2.2044.	✓	
<u>Unresolved Anomalies</u> : [Section 16.16] The sponsor lists unresolved anomalies and explains why the anomalies are not safety issues.	✓	
<u>Off-the-Shelf Software</u> : The software description contains a description of all OTS software. The OTS software includes standard components like Microsoft Windows, etc.		✓
<u>Cyber security</u> : <b>[Additional Information]</b> . The hazard analysis included a discussion of how the device would ensure information security (e.g., passwords, firewalls, USB keys, VPN access).		✓

The sponsor provided a DICOM conformance statement in Section 16.3.

**Deficiency #4:** Information about Cyber Security is missing. Please see Section XVI of this memorandum.

**Closed (S001).** The sponsor provided information about cyber security.

#### **XI. Performance Testing – Bench/Animal/Clinical**

The sponsor referred the reviewer to their verification and validation testing documentation; however, the documentation was poorly organized and was not possible to follow. The sponsor should provide clarification of their performance testing.

**Deficiency:** You discussed the performance testing performed on your device by referring to your validation test document VLC-07107. However, this document was difficult to follow, printed in an extremely small font, and contained too much information for us to determine the general approach you took to test the device's safety and effectiveness for the intended uses you describe. Please provide a clear and concise summary of the performance tests you performed to verify and validate the operation of your device. Where your device calculates numerical quantities or makes measurements, please explain how you validated the results of the calculation. Please also summarize any testing performed by external clinicians. In providing us your performance testing data, please pay particular attention to Deficiencies #2 and #3.

**Closed (S001):** The sponsor provided a summary of performance test data in the supplement. Performance data has been provided for validation of CT Brain Perfusion, Body Perfusion, and Liver Analysis modules.

For the Body Perfusion module, the sponsor performed studies using numerical phantoms, as well as direct comparisons of the results of numerical outputs of the subject device to images generated by predicate devices such as Vitrea 4DCT (K072821), Vitrea (K032748, K071331), as well as the Toshiba scanner console (K090504). The imaging phantoms contained markers at known positions, distances, and angles and these phantoms were used for verification and validation of the registration algorithm. The results were reviewed by an external cardiologist.

Automated rendering tests were validated by comparing images with images produced by from Vitrea (K032748, K071331) and Vitrea 4DCT (K072821). Automated Algorithm tests similarly compared results of algorithms with previously verified results from Vitrea (K032748, K071331) or from Vitrea 4DCT

(K072821). Images generated from VitreaAdvanced were compared with images generated by the Toshiba scanner console (K090504).

The results of validation were reviewed by two radiologists.

CT Liver Analysis performs measurement and segmentation functions that were tested by two radiological technicians at the Mallinckrodt Institute of Radiology. Data from the validation tests is provided in Questions 16-22 of the V&V section of the document (in test case 52167, the sponsor provides data on tumor response).

For the brain perfusion module, verification and validation was performed on quantities like the MTT, CBV, etc. versus the results were reviewed by an external radiologist at Mount Sinai hospital.

All automated tests and external validation tests passed. Four of the manual test cases failed testing, however all known outstanding defects were reviewed and the software was found to be safe and effective with all known issues. The Unresolved Anomalies Report contains the list of known unresolved defects that are included in the VitreaAdvanced software and the reasons why the software is safe and effective with known issues.

**XII. Use of Imaging Agents**

**Deficiency #5:** We were unable to determine which functions of your device required contrast-enhanced images for operation. Please provide a list of applications of your device that require contrast-enhanced images in order to operate. For each application, please indicate which of the predicate devices performed this function and whether they also required contrast-enhanced images for operation.

**Closed (S001):** The sponsor has provided this list in S001. The list confirms to the lead reviewer's satisfaction that all of the postprocessing software applications that can potentially use contrast are also performed by the predicate devices.

**XV. Substantial Equivalence Discussion**

	Yes	No	
1. Same Indications for Use statement?		✓	If YES = Go To 3
2. Do differences alter the effect or raise new issues of safety or effectiveness?		✓	If YES = Stop NSE
3. Same technological characteristics?	✓		If YES = Go To 5
4. Could the new characteristics affect safety or effectiveness?			If YES = Go To 6
5. Descriptive characteristics precise enough?		✓	If NO = Go To 8 If YES = Stop SE
6. New types of safety or effectiveness questions?		✓	If YES = Stop NSE
7. Accepted scientific methods exist?		✓	If NO = Stop NSE
8. Performance data available?		✓	If NO = Request Data
9. Data demonstrate equivalence?			Final Decision: SE

1. Explain how the new indication differs from the predicate device's indication:  
The indication adds some language that may or may not reflect new intended uses. See Section XVI (Deficiencies) for details.

2. Explain why there is or is not a new effect or safety or effectiveness issue:  
We are trying to establish whether this is the case. We are requesting the sponsor to modify their IFU statement.
3. Describe the new technological characteristics:  
The subject device does not appear to have any significantly new technological characteristics compared to the predicate. The labeling is different.
4. Explain how the new characteristics could or could not affect safety or effectiveness: N/A
5. Explain how descriptive characteristics are not precise enough:  
In general, for postprocessing devices, some performance testing is required in order to assess the device's safety and efficacy.
6. Explain new types of safety or effectiveness question(s) raised or why the question(s) are not new:  
FDA routinely reviews software devices that analyze perfusion images. There are no new questions.
7. Explain why existing scientific methods can not be used: N/A
8. Explain what performance data is needed:  
N/A
9. Explain how the performance data demonstrates that the device is or is not substantially equivalent:  
The sponsor has provided additional explanation of their verification and validation that addresses the deficiencies issued in S000.

#### **XVI. Previous Deficiencies**

1. In your submission, you provided a 510(k) summary that was administratively complete. However, we would like your 510(k) summary to contain somewhat more detail. Please provide a 510(k) summary for this submission that includes more detail regarding the performance testing that you provided in order to support substantial equivalence.

**S001: Closed.** The sponsor has provided an updated 510(k) summary.

2. The IFU statement of your chosen predicate device K090504 includes indications for operation on hepatic perfusion. Your device adds a specific indication for performing perfusion calculations on liver, lung and kidney images. We are not clear whether the extra organ-specific language you have added indicates extra device functionality. Please either explain why the new indication does not constitute a new intended use, or provide data in support of this new intended use. Alternately, please remove the added indication.

**S001: Closed.** The sponsor has removed the extra indications.

3. As compared to predicate K071241, you add the claim "when used by a trained and qualified physician a potential application is to assist in the assessment of tumor response to therapy." This claim is not present in the predicate devices' labeling, and could potentially constitute a new intended use for your device. Please provide data substantiating this claim, noting that data required to support condition and disease-specific claims can possibly include clinical data. Alternately, please remove the claim.

**S001: Closed.** The sponsor has provided additional material in support of the claim, and the lead reviewer is satisfied, as the claim is not a strong diagnostic claim.

4. Your IFU statement includes the following claim: "Vitrea CT Brain Perfusion supports the physician in visualizing the apparent blood perfusion in brain tissue affected by acute stroke." Although this claim appears in the predicate IFU, we were unable to locate data in your submission that substantiates the efficacy of your device for disease-specific claims. As noted in Paragraph 3, the data required to support disease or condition-specific claims may include clinical data. Please either substantiate the claim, or remove it from your IFU statement.

**S001: Closed.** The sponsor has pointed out numerous clinical studies in the literature using the Vitrea device for this intended use. Additionally, upon further examination the claim is not a claim of stroke diagnosis. It is a tool claim that the device assists in visualization of blood perfusion for stroke patients. The lead reviewer concludes that restricting the intended use population to stroke patients is not the same as making a clinical claim, and does not have issue with clearing the claim.

5. You discussed the performance testing performed on your device by referring to your validation test document VLC-07107. However, this document was difficult to follow, containing a very large amount of information printed in an extremely small font. Based on this document, we had difficulty determining the general approach you took to test the device's safety and effectiveness for the intended uses you describe. Please provide a clear and concise summary of the performance testing you performed to verify and validate the operation of your device. For numerical quantities that your device calculates (e.g. CBV), please explain how you validated the results of the calculation and established substantial equivalence to the predicate. Please also summarize any testing of your device performed by external clinicians. In providing us your performance testing data, please note Paragraphs #2-4 of this letter.

**S001: Closed.** Please see Section XI (Performance Testing) of this document for details on the sponsor's response.

6. We were unable to locate the following software documentation in your submission. If you have already provided these elements of software documentation, please indicate their location in the submission. If you have not provided these elements of software documentation, please provide them:

#### **Cyber and Information security**

Please provide information, as appropriate, on the Cybersecurity aspects of your device, including, but not limited to, the following facets of information security with respect to communications features of your device and associated software: Confidentiality, integrity, availability and accountability.

**Confidentiality** assures that no unauthorized users have access to the information.

**Integrity** is the assurance that the information is correct - that is, it has not been improperly modified.

**Availability** suggests that the information will be available when needed.

**Accountability** is the application of identification and authentication to assure that the prescribed access process is being done by an authorized user.

Please refer to the following guidance document

"Guidance for the Content of Premarket Submissions for Software Contained in Medical Devices"  
<http://www.fda.gov/MedicalDevices/DeviceRegulationandGuidance/GuidanceDocuments/ucm089543.htm>



for further information.


**S001: Closed.** The sponsor has provided additional information on cyber security in the supplement.

7. We were unable to determine which functions of your device required contrast-enhanced images for operation. Please provide a list of applications of your device that require contrast-enhanced images in order to operate. For each item on this list, please indicate which of the predicate devices performed this function and whether they also required contrast-enhanced images for operation.

**S001: Closed.** The sponsor has provided this list in S001. The list confirms that all of the CT postprocessing software applications of this device that require, or can potentially use, contrast are also performed by the predicate devices.

**XVIII. Recommendation:** Telephone hold


Regulation Number: 21 CFR §892.2050  
Regulation Name: Picture archiving and communications system  
Regulatory Class: Class II  
Product Code: LLZ



\_\_\_\_\_  
Jay Vaishnav, PhD

November 1, 2012

\_\_\_\_\_  
Date



\_\_\_\_\_  
Supervisor

11/2/12  
\_\_\_\_\_  
Date



U.S. Food and Drug Administration  
Center for Devices and Radiological Health  
Document Control Center WO66-G609  
10903 New Hampshire Avenue  
Silver Spring, MD 20993-0002

October 10, 2012

VITAL IMAGES, INC.  
5850 OPUS PARKWAY,  
SUITE 300  
MINNETONKA, MINNESOTA 55343-4414  
ATTN: DANIEL BIANK

510k Number: K121213

Product: VITREAADVANCED

The additional information you have submitted has been received.

We will notify you when the processing of this submission has been completed or if any additional information is required. Please remember that all correspondence concerning your submission MUST be sent to the Document Mail Center at the above letterhead address. Correspondence sent to any address other than the one above will not be considered as part of your official premarket notification submission. Also, please note the new Blue Book Memorandum regarding Fax and E-mail Policy entitled, "Fax and E-Mail Communication with Industry about Premarket Files Under Review. Please refer to this guidance for information on current fax and e-mail practices at <http://www.fda.gov/MedicalDevices/DeviceRegulationandGuidance/GuidanceDocuments/ucm089402.htm>. On August 12, 2005 CDRH issued the Guidance for Industry and FDA Staff: Format for Traditional and Abbreviated 510(k)s. This guidance can be found at <http://www.fda.gov/MedicalDevices/DeviceRegulationandGuidance/GuidanceDocuments/ucm084365.htm>. Please refer to this guidance for assistance on how to format an original submission for a Traditional or Abbreviated 510(k).

The Safe Medical Devices Act of 1990, signed on November 28, states that you may not place this device into commercial distribution until you receive a letter from FDA allowing you to do so. As in the past, we intend to complete our review as quickly as possible. Generally we do so in 90 days. However, the complexity of a submission or a requirement for additional information may occasionally cause the review to extend beyond 90 days. Thus, if you have not received a written decision or been contacted within 90 days of our receipt date you may want to check with FDA to determine the status of your submission.

**Please ensure that whether you submit a 510(k) Summary as per 21 CFR 807.92, or a 510(k) Statement as per 21 CFR 807.93, it meets the content and format regulatory requirements.**

If you have procedural questions, please contact the Division of Small Manufacturers International and Consumer Assistance (DSMICA) at (301)796-7100 or at their toll-free number (800)638-2041, or contact the 510k staff at (301)796-5640.

Sincerely,

510(k) Staff

**Mcdonald, Lisa \***

---

**From:** Microsoft Outlook  
**To:** dbiank@vitalimages.com  
**Sent:** Wednesday, October 10, 2012 5:01 PM  
**Subject:** Relayed: K121213 Ecopy/ AI Letter

**Delivery to these recipients or groups is complete, but no delivery notification was sent by the destination server:**

[dbiank@vitalimages.com](mailto:dbiank@vitalimages.com) (dbiank@vitalimages.com)

Subject: K121213 Ecopy/ AI Letter

K121213/S1

October 5, 2012

K36

Food and Drug Administration  
Division of Radiological Devices  
Document Mail Center – WO66-G609  
10903 New Hampshire Avenue  
Silver Spring, Maryland 20993-0002  
Attn: Dr. Jay Vaishnav, Ph.D.  
Physicist and Premarket Reviewer

FDA CD/EDMC  
OCT 9 2012  
Received

RE: **Response to Telephone Hold for Traditional 510(k) for VitreaAdvanced (K121213/S001)**

Dear Dr. Vaishnav,

On June 21, 2012, you asked Vital Images to provide additional information regarding the above-referenced submission. On July 17, 2012, FDA granted Vital Images a total of 180 days from the date of the AI request to provide its response. With this letter, please find the response of Vital Images to the AI request of June 21, 2012. We appreciate your attention to this submission and wish to continue working with you in a collaborative manner. For each item below, the FDA question appears first, in boldface, and the response of Vital Images follows, in regular type face.

1. **In your submission, you provided a 510(k) summary that was administratively complete. However, we would like your 510(k) summary to contain somewhat more detail. Please provide a 510(k) summary for this submission that includes more detail regarding the performance testing that you provided in order to support substantial equivalence.**

Response of Vital Images:

Please see Exhibit A-1 to this response letter, in which Vital Images provides a revised 510(k) summary that includes more detail regarding the performance testing that we performed in order to support substantial equivalence.

2. **The IFU statement of your chosen predicate device K090504 includes indications for operation on hepatic perfusion. Your device adds a specific indication for performing perfusion calculations on liver, lung and kidney images. We are not clear whether the extra organ-specific language you have added indicates extra device functionality. Please either explain why the new indication does not constitute a new intended use, or provide data in support of this new intended use. Alternately, please remove the added indication.**

**VITAL**

A Toshiba Medical Systems Group Company

Response of Vital Images:

Vital Images requests to remove the added indication. The revised indications for use shall read as follows:

**“Vitrea® CT Body Perfusion is a noninvasive post-processing application designed to evaluate perfusion of organs and tumors. The software can calculate perfusion characteristics from dynamic CT image data acquired after the injection of contrast media. The software also allows the separate calculation of the arterial and venous components of perfusion in organs. It supports evaluation of regions of interest and the visual inspection of time density curves. When used by a trained and qualified physician a potential application is to differentiate blood flow between normal and diseased tissue. Determination of the change of perfusion parameters during the course of treatment may be helpful in therapy monitoring.”**

This revised language omits the extra organ-specific language that differs from the indications for use for the predicate device.

3. **As compared to predicate K071241, you add the claim “when used by a trained and qualified physician a potential application is to assist in the assessment of tumor response to therapy.” This claim is not present in the predicate devices’ labeling, and could potentially constitute a new intended use for your device. Please provide data substantiating this claim, noting that data required to support condition and disease-specific claims can possibly include clinical data. Alternately, please remove the claim.**

Response of Vital Images:

Typical uses of the CT Liver Analysis product will be to assist in the determination of whether treatment is needed and whether the treatment was effective. Therefore, to match these typical uses, Vital Images included in the indications for use the statement, **“When used by a trained and qualified physician a potential application is to assist in the assessment of tumor response to therapy.”** This statement is similar to a section of the indications for use for the predicate device, Median Technologies, LMS-Liver (K071241), which states, among other things, “It is designed to assist radiologists in the evaluation and documentation of lesions. It also provides tools for *assessment of lesion evolution over time.*”

Vital Images established requirements and performed verification and validation for the product to determine whether it was safe and effective for this use. For example, as stated on page 7 of the Leo4 CT Liver Analysis Software Requirements Specification (VLC-07097), the product included the following requirement: “A tumor response Gallery preset will be available targeted toward tumor tracking.” The effectiveness of this preset was determined through various test

**VITAL**

A Toshiba Medical Systems Group Company

cases, such as test case 52427 (“Create a Liver Snap - Matched Tumors”) and test case 52167 (“Tumor Response – Segmented Tumors”), and test case 52167 (“Tumor Response – Segmented Tumors”), both of which passed testing, as shown on page 15 of the Leo4 Verification and Validation Summary (VLC-07113). Please note that test case 52167 reviewed a workflow a user might follow when processing two or more studies (baseline and follow-up(s)) for tumor response using segmented tumors.

The effectiveness of the tool for assessing tumor response was further validated through internal and external validation procedures, such as Question 16 (“Can you measure tumors using simple rulers (RECIST or WHO)?”) and Question 20 (“After utilizing the Liver software, in your opinion, does the software solve the intended clinical needs and purpose (to enable users to perform routine liver diagnosis, treatment, and follow-up activities)?”, as well as other validation procedures, all of which passed, as shown on page 9 of the Leo4 Verification and Validation Summary (VLC-07113). “RECIST” stands for Response Evaluation Criteria in Solid Tumors, which is a set of criteria published in February, 2000 by an international group that included the European Organisation for Research and Treatment of Cancer (EORTC), National Cancer Institute of the United States, and the National Cancer Institute of Canada Clinical Trials Group. According to the National Cancer Institute,

“RECIST criteria offer a simplified, conservative, extraction of imaging data for wide application in clinical trials. They presume that linear measures are an adequate substitute for 2-D methods and register four *response categories*:

- CR (*complete response*) = disappearance of all target lesions
- PR (*partial response*) = 30% decrease in the sum of the longest diameter of target lesions
- PD (*progressive disease*) = 20% increase in the sum of the longest diameter of target lesions
- SD (*stable disease*) = small changes that do not meet above criteria”

The CT Liver Analysis product was designed to support these criteria and passed verification and validation for its performance. In combination with those results, Vital Images also recognized the claim in the indications for use of the predicate device, which provides tools for assessment of lesion evolution over time, and therefore included in its indications for use the claim that the product may “assist in the assessment of tumor response to therapy.”

4. **Your IFU statement includes the following claim: “Vitrea CT Brain Perfusion supports the physician in visualizing the apparent blood perfusion in brain tissue affected by acute stroke.” Although this claim appears in the predicate IFU, we were unable to locate data in your submission that substantiates the efficacy of your device for disease-specific claims. As noted**

**VITAL**

A Toshiba Medical Systems Group Company

**in Paragraph 3, the data required to support disease or condition-specific claims may include clinical data. Please either substantiate the claim, or remove it from your IFU statement.**

Response of Vital Images:

Please see Exhibit A-2 to this response letter, which includes a summary of clinical studies that have been performed using the Vital Images brain perfusion product to visualize apparent blood perfusion in brain tissue affected by acute stroke.

- 5. You discussed the performance testing performed on your device by referring to your validation test document VLC-07107. However, this document was difficult to follow, containing a very large amount of information printed in an extremely small font. Based on this document, we had difficulty determining the general approach you took to test the device's safety and effectiveness for the intended uses you describe. Please provide a clear and concise summary of the performance testing you performed to verify and validate the operation of your device. For numerical quantities that your device calculates (e.g. CBV),**

**Please explain how you validated the results of the calculation and established substantial equivalence to the predicate. Please also summarize any testing of your device performed by external clinicians. In providing us your performance testing data, please note Paragraphs #2-4 of this letter.**

Response of Vital Images:

Please see Exhibit A-3 to this response letter, which summarizes the performance testing performed by Vital Images to verify and validate the operation of our device.

- 6. We were unable to locate the following software documentation in your submission. If you have already provided these elements of software documentation, please indicate their location in the submission. If you have not provided these elements of software documentation, please provide them:**

**Cyber and Information security**

Please provide information, as appropriate, on the Cyber security aspects of your device, including, but not limited to, the following facets of information security with respect to communications features of your device and associated software: Confidentiality, integrity, availability and accountability.

**Confidentiality** assures that no unauthorized users have access to the information.

**Integrity** is the assurance that the information is correct - that is, it has not been improperly modified.

**VITAL**

A Toshiba Medical Systems Group Company

**Availability** suggests that the information will be available when needed.

**Accountability** is the application of identification and authentication to assure that the prescribed access process is being done by an authorized user.

Please refer to the following guidance document

“Guidance for the Content of Premarket Submissions for Software Contained in Medical Devices”

<http://www.fda.gov/MedicalDevices/DeviceRegulationandGuidance/GuidanceDocuments/ucm089543.htm>

for further information.

Response of Vital Images:

Please see Exhibit A-4 to this response letter, which describes the cyber and information security aspects of VitreaAdvanced.

- 7. We were unable to determine which functions of your device required contrast-enhanced images for operation. Please provide a list of applications of your device that require contrast-enhanced images in order to operate. For each item on this list, please indicate which of the predicate devices performed this function and whether they also required contrast-enhanced images for operation.**

Response of Vital Images:

Please see Exhibit A-5 to this response letter, which lists the functions within VitreaAdvanced that require contrast-enhanced images for operation and indicates which of the predicate devices perform this function and also require contrast-enhanced images for operation.

Vital Images, Inc. regards both the content and the existence of this letter response as confidential commercial information and requests that it be treated as such by the FDA.



**VITAL**

A Toshiba Medical Systems Group Company

Thank you for your continued attention to this matter. We look forward to continuing the interactive and collaborative review process. Please contact me with any questions regarding this submission or for further information at (952) 487-9622 or via email at [inemerov@vitalimages.com](mailto:inemerov@vitalimages.com).

Best regards,



Ian Nemerov  
Vice President, General Counsel and Secretary

Page 6 of 6

**Parthiv Shah**

---

**From:** Vaishnav, Jay [Jay.Vaishnav@fda.hhs.gov]  
**Sent:** Thursday, June 21, 2012 3:59 PM  
**To:** Daniel Biank  
**Cc:** O'Hara, Michael D  
**Subject:** K121213 telephone hold

Dear Mr. Biank:

Thank you for submitting the VitreaAdvanced system (K121213) to FDA for 510(k) clearance. As you know, 510(k) clearance requires a finding of substantial equivalence between the submitted device and an appropriate predicate device.

In your submission, you submitted information that you felt demonstrated your device's substantial equivalence to six predicate devices:

- K071331 – Vitrea v 4.0 (Vital Images)
- K072821 – Vitrea 4DCT (Vital Images)
- K090504 – CSBP-001A Body Perfusion System (Toshiba)
- K051528 – MeVis LiverAnalyser/Liver Viewer (Mevis Technology GMBH & Co.)
- K071241 – LMS-Liver (Median Technologies)
- K073238 – syngo Volume Perfusion-CT Neuro (Siemens)

However, we find that there is insufficient information in your submission for us to make a clear determination of the equivalence of your device to the designated predicate devices.

We would therefore appreciate your providing the following additional information:

1. In your submission, you provided a 510(k) summary that was administratively complete. However, we would like your 510(k) summary to contain somewhat more detail. Please provide a 510(k) summary for this submission that includes more detail regarding the performance testing that you provided in order to support substantial equivalence.
2. The IFU statement of your chosen predicate device K090504 includes indications for operation on hepatic perfusion. Your device adds a specific indication for performing perfusion calculations on liver, lung and kidney images. We are not clear whether the extra organ-specific language you have added indicates extra device functionality. Please either explain why the new indication does not constitute a new intended use, or provide data in support of this new intended use. Alternately, please remove the added indication.
3. As compared to predicate K071241, you add the claim “when used by a trained and qualified physician a potential application is to assist in the assessment of tumor response to therapy.” This claim is not present in the predicate devices’ labeling, and could potentially constitute a new intended use for your device. Please provide data substantiating this claim, noting that data required to support condition and disease-specific claims can possibly include clinical data. Alternately, please remove the claim.
4. Your IFU statement includes the following claim: “Vitrea CT Brain Perfusion supports the physician in visualizing the apparent blood perfusion in brain tissue affected by acute stroke.” Although this claim appears in the predicate IFU, we were unable to locate data in your submission that substantiates the efficacy of your device for disease-specific claims. As noted in Paragraph 3, the data required to support disease or condition-specific claims may include clinical data. Please either substantiate the claim, or remove it from your IFU statement.

5. You discussed the performance testing performed on your device by referring to your validation test document VLC-07107. However, this document was difficult to follow, containing a very large amount of information printed in an extremely small font. Based on this document, we had difficulty determining the general approach you took to test the device's safety and effectiveness for the intended uses you describe. Please provide a clear and concise summary of the performance testing you performed to verify and validate the operation of your device. For numerical quantities that your device calculates (e.g. CBV), please explain how you validated the results of the calculation and established substantial equivalence to the predicate. Please also summarize any testing of your device performed by external clinicians. In providing us your performance testing data, please note Paragraphs #2-4 of this letter.
6. We were unable to locate the following software documentation in your submission. If you have already provided these elements of software documentation, please indicate their location in the submission. If you have not provided these elements of software documentation, please provide them:

### **Cyber and Information security**

Please provide information, as appropriate, on the Cybersecurity aspects of your device, including, but not limited to, the following facets of information security with respect to communications features of your device and associated software: Confidentiality, integrity, availability and accountability.

**Confidentiality** assures that no unauthorized users have access to the information.

**Integrity** is the assurance that the information is correct - that is, it has not been improperly modified.

**Availability** suggests that the information will be available when needed.

**Accountability** is the application of identification and authentication to assure that the prescribed access process is being done by an authorized user.

Please refer to the following guidance document

"Guidance for the Content of Premarket Submissions for Software Contained in Medical Devices"

<http://www.fda.gov/MedicalDevices/DeviceRegulationandGuidance/GuidanceDocuments/ucm089543.htm>

for further information.

7. We were unable to determine which functions of your device required contrast-enhanced images for operation. Please provide a list of applications of your device that require contrast-enhanced images in order to operate. For each item on this list, please indicate which of the predicate devices performed this function and whether they also required contrast-enhanced images for operation.

At this time, I am recommending that your submission be placed on telephone hold to allow you time to assemble the information we have requested. Please note that telephone hold is not an indication of the quality of your submission or on the likely outcome of the review. Please submit your official response and any additional information you provide to the FDA Document and Mail Center (WO66-G609, 10903 New Hampshire Avenue, Silver Spring, MD 20993-0002) within thirty days. Should you require more than thirty days to assemble the requested materials, please submit a request for additional time to the FDA Document and Mail Center.

Should you have any questions about the additional information required, please contact me; my contact information is below.

Thank you for your attention; I look forward to your prompt response and to continuing my review.

Jay Vaishnav, Ph.D.  
Physicist and Premarket Reviewer  
Division of Radiological Devices (DRAD)  
Food and Drug Administration  
301-796-9580

---

This email has been scanned for all viruses and found to be virus free. If you have questions regarding this scanning please visit the Information Services area of <http://home.vitalimages.com>

---

**Parthiv Shah**

---

**From:** Daniel Biank  
**ent:** Tuesday, July 17, 2012 2:36 PM  
**To:** Ian Nemerov; Parthiv Shah  
**Subject:** Fwd: K121213- Extension Letter

Begin forwarded message:

**From:** "Nichols, Karl \*" <Karl.Nichols@fda.hhs.gov>  
**Date:** July 17, 2012 11:32:43 AM CDT  
**To:** Daniel Biank <dbiank@vitalimages.com>  
**Subject:** K121213- Extension Letter

---

**DEPARTMENT OF HEALTH & HUMAN SERVICES**  
**Public Health Service**



U.S. Food and Drug Administration  
Center for Devices and Radiological Health  
Document Control Center WO66-G609  
10903 New Hampshire Avenue  
Silver Spring, MD 20993-0002  
July 17, 2012

VITAL IMAGES, INC.  
5850 OPUS PARKWAY,  
SUITE 300  
MINNETONKA, MINNESOTA 55343-4414  
ATTN: DANIEL BIANK  
510k Number: K121213  
Product: VITREAADVANCED

12/19/2012

Extended Until:

Based on your recent request, an extension of time has been granted for you to submit the additional information we requested.

If the additional information (AI) is not received by the "Extended Until" date shown above, your premarket notification will be considered withdrawn (21 CFR 807.87(l)). If the submitter does submit a written request for an extension, FDA will permit the 510(k) to remain on hold for up to a maximum of 180 days from the date of the AI request.

If you have procedural questions, please contact the Division of Small Manufacturers International and Consumer Assistance (DSMICA) at (301)796-7100 or at their toll-free number (800)638-2041, or contact the 510k staff at (301)796-5640.

Sincerely yours,

Marjorie Shulman  
Director, 510(k) Program  
Premarket Notification Section  
Office of Device Evaluation  
Center for Devices and Radiological Health

---

This email has been scanned for all viruses and found to be virus free. If you have questions regarding this scanning please visit the Information Services area of <http://home.vitalimages.com>

---

**A-1**  
**510(k) Summary**

## 510(k) Summary

This 510(k) summary is submitted in accordance with the requirements by section 807.92.(c)

**Submitter:** Vital Images, Inc.  
5850 Opus Parkway  
Suite 300  
Minnetonka, MN 55343-4414

**Establishment  
Registration:** 2134213

**Contact Person:** Ian Nemerov  
Vice President, General Counsel & Secretary  
Phone: 952-487-9622  
Fax: 952-487-9510  
E-mail: [inemerov@vitalimages.com](mailto:inemerov@vitalimages.com)

**510(k) Type:** Traditional 510(k)

**Summary Date:** October 5, 2012

**Device Name**

**Trade Name:** VitreaAdvanced  
**Common Name:** Picture Archiving and Communications System  
**Classification Name:** System, Image Processing, Radiological (21 C.F.R. 892.2050,LLZ)

**Predicate Devices:**

Subject Functions	Predicate Devices		
	Manufacturer	Trade Name	510(k) Number
Advanced Image Post-processing	Vital Images, Inc.,	Vitrea <sup>®</sup> , Version 4.0	K071331
Vitrea <sup>®</sup> CT Body Perfusion	Toshiba America Medical System, Inc.,	CSBP-001A Body Perfusion System	K090504
Vitrea <sup>®</sup> CT Liver Analysis	MeVis - Center for Medical Diagnostic Systems and Visualization GmbH	MeVis LiverAnalyser / LiverViewer Software	K051528
	MEDIAN Technologies	LMS-Liver	K071241
Vitrea <sup>®</sup> CT Brain Perfusion	Vital Images, Inc	Vitrea <sup>®</sup> 4DCT	K072821
	Siemens Medical Solutions, Inc.	syngo <sup>®</sup> Volume Perfusion-CT Neuro	K073238



### **Device Description:**

VitreaAdvanced is a package of noninvasive post-processing software applications for the Vitrea® software platform. The system is a software only medical device to be installed on common IT hardware. VitreaAdvanced leverages existing Vitrea® functionality for the processing, review, analysis, communication, and media interchange of multi-dimensional digital images acquired from a variety of imaging devices. It provides multi-dimensional visualization of digital images to aid medical professionals in their analysis of anatomy and pathology. VitreaAdvanced can be used with a variety of cleared Vitrea® based software applications. VitreaAdvanced uses the Vitrea® system user interface to follow typical clinical workflow patterns and process, review, and analyze digital images, including:

- Receive DICOM image data from a variety of sources
- Display images using dedicated protocols adapted to exam types
- Select images for closer examination from collection of 2D, 3D or 4D views
- Interactively manipulate an image in real-time to visualize anatomy and pathology
- Annotate, tag, measure, and record selected views
- Output selected views to compatible devices and publishing tools (e.g. printers, DICOM devices, etc.)

In addition, VitreaAdvanced includes three Vitrea® applications:

**Vitrea® CT Body Perfusion** is noninvasive post-processing software that has been designed to assess dynamic (time lapsed collections) CT volume scans and provide data related to the volume sets. It displays blood flow parametric maps for single-input and dual-input workflows.

**Vitrea® CT Liver Analysis** is noninvasive post-processing software that displays CT image data. It processes image data to segment liver structures and evaluate resection surfaces as well as volumes. Vitrea® CT Liver Analysis provides automatic registration and composite views of multiple series, optimized screen layouts and measurement tools. It also generates standardized reports for WHO and RECIST protocols and for percentage change tumor response values.

**Vitrea® CT Brain Perfusion** is noninvasive post-processing software that calculates cerebral blood flow (CBF), cerebral blood volume (CBV), local bolus timing (i.e., delay of tissue response, time to peak), and mean transit time (MTT) from dynamic CT image data. It displays time density curves, perfusion characteristics in parametric and summary maps, as well as regions of interest and mirrored regions.

### **Intended Use / Indications for Use:**

VitreaAdvanced is a medical diagnostic system for the processing, review, analysis, communication and media interchange of multi-dimensional digital images acquired from a variety of imaging devices. VitreaAdvanced is not meant for primary image interpretation in mammography. It can be used with a variety of cleared Vitrea® based software applications. In addition, VitreaAdvanced includes three Vitrea® applications:

**Vitrea® CT Body Perfusion** is a noninvasive post-processing application designed to evaluate perfusion of organs and tumors. The software can calculate perfusion characteristics from dynamic CT image data acquired after the injection of contrast media. The software also allows the separate calculation of the arterial and venous components of perfusion in organs. It supports evaluation of regions of interest and the visual inspection of time density curves. When used by a trained and qualified physician a potential application is to differentiate blood flow between normal and diseased tissue. Determination of the change of perfusion parameters during the course of treatment may be helpful in therapy monitoring.

**Vitrear<sup>®</sup> CT Liver Analysis** is a noninvasive post-processing application designed to evaluate liver tumors and plan for liver surgery. It displays images for analysis and preoperative liver surgery planning, such as organ segmentation, tumor segmentation and intrahepatic vessels segmentation, as well as the approximation of vascular territories. It supports preoperative evaluation of specific surgery strategies by allowing the user to interactively define virtual resections splitting the liver. It also allows the user to evaluate safety-margins around lesions and to identify affected vascular branches and territories. Vitrea<sup>®</sup> CT Liver Analysis also provides automatic registration of multiple series and measurement tools for characterization and follow-up of the lesions. When used by a trained and qualified physician a potential application is to assist in the assessment of tumor response to therapy.

**Vitrear<sup>®</sup> CT Brain Perfusion** is a noninvasive post-processing application designed to evaluate areas of brain perfusion. The software can calculate cerebral blood flow (CBF), cerebral blood volume (CBV), local bolus timing (i.e., delay of tissue response, time to peak), and mean transit time (MTT) from dynamic CT image data acquired after the injection of contrast media. The package also allows the calculation of regions of interest and mirrored regions, as well as the visual inspection of time density curves. Vitrea<sup>®</sup> CT Brain Perfusion supports the physician in visualizing the apparent blood perfusion in brain tissue affected by acute stroke. Areas of decreased perfusion, as is observed in acute cerebral infarcts, appear as areas of changed signal intensity (lower for both CBF and CBV and higher for time to peak and MTT).

**Comparison with Predicate Devices:**

VitrearAdvanced is a package of noninvasive post-processing software applications for the Vitrea<sup>®</sup> software platform. It leverages the basic functionality and technology of the existing 510(k) cleared Vitrea<sup>®</sup> software platform. VitreaAdvanced includes advance applications that extend the functionality of the platform for specific uses. The specific uses are substantially equivalent to the cleared uses of existing post-processing software applications available on other platforms. Also, the software applications use similar technology as existing post-processing software applications.

**Vitrear<sup>®</sup> CT Body Perfusion:**

<b>Vitrear<sup>®</sup> CT Body Perfusion (Submission Subject)</b>	<b>Description</b>	<b>Toshiba CSBP-001A Body Perfusion System (K090504)</b>	<b>Explanation of Differences</b>
Analysis Model	Maximum slope (Fick principal)	Includes	The subject and predicate both implement Maximum-slope.  The predicate implements additional models: Compartment model and Patlak Plot.

Vitrea® CT Body Perfusion (Submission Subject)	Description	Toshiba CSBP-001A Body Perfusion System (K090504)	Explanation of Differences
Parameters	Blood flow	Includes	<p>The subject and predicate both display blood flow parameters.</p> <p>The predicate includes additional parameters: Blood volume, MTT, HAF (PI), equivalent blood volume using the additional analysis models.</p>
Functions	Single input, dual input, map display and ROI measurement	Same	None

**Vitrea® CT Liver Analysis:**

Vitrea® CT Liver Analysis (Submission Subject)	Description	MeVis Liver Analyser / LiverViewer Software (K051528)	Median LMS-Liver (K071241)	Explanation of Differences
Analysis Model	Rigid and deformable registration, Segmentation and region growing	Same	Same	None
Parameters	Basic measurements, volume, resection plane, RECIST, WHO and comparisons	Partial (volumes, resection planes and comparisons)	Partial (RECIST, WHO and comparisons)	MeVis provides basic measurements for volumes, resection planes and comparisons. LMS-Liver provides RECIST and WHO measurements and comparison.

Vitrea® CT Liver Analysis (Submission Subject)	Description	MeVis Liver Analyser / LiverViewer Software (K051528)	Median LMS-Liver (K071241)	Explanation of Differences
Functions	Segment: organs, tumors and intrahepatic vessels, Resection planning tool (defines vascular territories), multi-phase fusion and standardized reports	Partial  (segmentation, resection planning and multi-phase fusion)	Partial  (standardized reports)	MeVis provides segmentation, resection planning and multi-phase fusion.  LMS-Liver provides standardized reports.

**Vitrea® CT Liver Analysis:**

Vitrea® CT Brain Perfusion (Submission Subject)	Description	Vitrea® 4DCT (K072821)	Siemens syngo® Volume Perfusion - CT Neuro (K073238)	Explanation of Differences
Analysis Model	Deconvolution	Same	Includes	syngo® Volume Perfusion-CT Neuro uses both deconvolution and maximum slope.
Parameters	Cerebral blood flow (CBF), cerebral blood volume (CBV), local bolus timing (i.e., delay of tissue response, time to peak), and mean transit time (MTT)	Same	Includes	syngo® Volume Perfusion-CT Neuro has all the parameters and vascular permeability

Vitreia® CT Brain Perfusion (Submission Subject)	Description	Vitreia® 4DCT (K072821)	Siemens syngo® Volume Perfusion – CT Neuro (K073238)	Explanation of Differences
Functions	Display regions of interest, mirrored regions, time density curves and perfusion characteristics in parametric and summary maps	Partial	Same	4DCT does not include summary maps (maps that combine parameters). syngo® Volume Perfusion- CT Neuro includes maps that combine parameters.

**Summary of Non-Clinical Tests:**

VitreiaAdvanced was designed, developed, and tested according to written procedures that included applying risk management. Testing included verification, validation, and evaluation of previously acquired medical images.

The following quality assurance measures were applied to the development of VitreaAdvanced:

- Risk analysis
- Requirements reviews
- Design reviews
- Performance testing (Verification)
- Safety testing (Verification)
- Simulated use testing (Validation)

**Software Testing:**

The primary focus of the Verification and Validation team during development was producing, reviewing and executing manual and automated test cases to ensure the product conformed to new and previously defined specifications and also to ensure that risks were properly mitigated during testing. The Requirement Traceability Matrix (RTM) provides a mapping between requirements, risks, test cases, and shows related test results. The RTM confirms that there was a test case authored and executed for all requirements and any applicable risks. In addition, the Verification and Validation Team demonstrated clinical features to several Radiologists and 3D Technologists to gather feedback and formal acceptance.

**Manual Tests:**

Manual tests cases were executed to verify and validate the CT Body Perfusion, CT Liver Analysis and CT Brain Perfusion applications, and to determine the impact of any changes. All manual tests and steps were executed to prove the product conformed to specifications and to mitigate risks.

***Verification:***

The software verification team had a primary goal of assuring that software fully satisfies all expected system requirements and features. Test cases were executed against the system features and requirements. As part of creating the test cases, the verification team reviewed and monitored the Requirements Traceability Matrix ("RTM") to ensure coverage of the items within the RTM.

***Automated Integration Level Build Verification Tests (BVT):***

Automated integration level Build Verification Tests (BVT) were developed to exercise mainstream functionality and provide an assessment of the stability and testability of the VitreaAdvanced software. Automated software rendering tests were used to verify correctness of images generated by the rendering engine. Automated algorithm smoke tests and automated algorithm regression tests were executed. Automated performance tests were used to verify that response times and throughput were acceptable. Automated regressions tests were used to verify correctness of measurements, orientation markers, and other core features of VitreaAdvanced.

***Validation:***

The software validation team had a primary goal of assuring that software conforms to user needs and intended uses. The result of the validation team's efforts was evidence, produced by workflow testing, that system requirements and features were implemented, reviewed and met.

***Internal Validation:***

The software validation team provided internal validation of VitreaAdvanced. Internal validation included internal beta testing and internal user acceptance testing.

***External Validation:***

***Vitrea® CT Body Perfusion***

During external validation of CT Body Perfusion application of VitreaAdvanced, an external cardiologist confirmed that the CT Body Perfusion application's deformable (non-rigid) registration for dynamically scanned organs produces similar results to what is available on the scanner console. It was also confirmed that it takes the same amount of time or less to complete registration.

The results of the qualitative analysis (visual verification), performed as part of validation, support the feedback received from the cardiologist during external validation regarding the visual similarity of images produced by the VitreaAdvanced registration to the registration applied at the scanner. In addition, a cardiologist also confirmed the measurements produced were clinically acceptable and that the software was ready for general release. Based on the results of the qualitative analysis, and feedback gathered during external validation, the CT Body Perfusion application has passed validation.

***Vitrea® CT Liver Analysis***

During external validation of CT Liver Analysis application of VitreaAdvanced, two external 3D Technicians evaluated the functionality, usability and performance of the CT Liver Analysis application. Based on their evaluation, the software passed external validation.

***Vitrea® CT Brain Perfusion***

During external validation of CT Brain Perfusion of VitreaAdvanced, an external radiologist evaluated the functionality and performance of the summary map feature and the correlation of each summary map with his interpretation of that summary map's associated perfusion maps. He confirmed that the software has met the intended use and effectively provides a summary image of the data displayed in the perfusion maps as well as when used in conjunction with the perfusion maps, the summary map enables the user to characterize the brain tissue and communicate their findings.

**Summary of Clinical Tests:**

The subject of this traditional 510(k) notification, VitreaAdvanced, did not require clinical studies to support safety and effectiveness of the software.

**Cyber and Information Security:**

- **Confidentiality**  
Vitrea platform relies on built in Windows Login security to limit access to the system. The Vitrea platform can only be installed and configured by an administrator of the Windows machine.
- **Integrity**  
Vitrea platform complies with the DICOM standard for transfer and storage of this data and does not modify the contents of DICOM instances. Vitrea platform identifies the data it produces, marking and encoding the appropriate DICOM fields.
- **Availability**  
Vitrea platform is always available to the logged on user as long as the Windows machine itself is properly maintained.
- **Accountability**  
Vitrea platform includes an audit capability that enables accountability by tracking authenticated and authorized user operations along with information accessed. Vitrea audit logs are time stamped, enabling correlation with Windows system logging to track information accessed by a user.

**Measurement Accuracy:**

Measurements and orientations in VitreaAdvanced were verified using various imaging phantoms. These imaging phantoms contain markers at known positions, distances, and angles from one another. The known positions, distances, and angles were used as input into expected results for verification tests that verified the spatial accuracy of image rendering of 2D and 3D images, the accuracy of distance, angular measurement, and navigational tools, as well as the accuracy of orientation markers within VitreaAdvanced.

**Performance Standard:**

No applicable mandatory performance standards or special controls exist for this device. However, the software is designed to meet NEMA PS 3.1 – 3.18 Digital Imaging and Communications in Medicine (DICOM) standard.

**Conclusion:**

The testing reported in this 510(k) establishes that VitreaAdvanced is substantial equivalent to the predicate devices and is safe and effective for its intended use.

A-2

**A-2**  
**Clinical Research Published Papers**  
**for Vitrea® CT Brain Perfusion –**  
**Conducted by Independent**  
**Researchers**



# Studies using Vitrea that show CT Perfusion is effective for visualizing the apparent blood perfusion abnormalities in the brain tissue affected by an acute stroke

---

## Why using CT Perfusion for acute ischemic stroke?

Perfusion CT imaging (PCI) of the brain is the modality of choice for assessing the extent of the existing damaged area (the infarct core) and the tissue at risk (the penumbra) in the early phase of an acute stroke occurring in any emergency situation. In effect, CT perfusion imaging is a fast imaging technique showing reasonably high sensitivity and specificity for evaluating both the tissue at risk and the tissue already infarcted.[2b] [3b] [4b] [5b][6b]. Moreover, the recent evolution of the CT perfusion techniques allows a full brain coverage [12] and X-Ray dose reduction [15] thereby reducing the previous limitations of the computed tomography (CT) compared to the magnetic resonance imaging (MRI).

See for example [4b]: Schaefer PW, Barak ER, Kamalian S, Gharai LR, et Al. Quantitative assessment of core/penumbra mismatch in acute stroke: CT and MR perfusion imaging are strongly correlated when sufficient brain volume is imaged. *Stroke*. 2008;39:2986 –2992.

These authors conclude: “Advanced MR and CT perfusion imaging measurements of core/penumbra mismatch for patient selection in stroke trials are highly correlated when CT perfusion coverage is sufficient to include most of the ischemic region. Although MR is currently the preferred imaging method for determining core and penumbra, CT perfusion is comparable and potentially more available” (p. 2986).

See also [6b]: Wintermark M, Meuli R, Browaeys P, Reichhart M, et al: Comparison of CT perfusion and angiography and MRI in selecting stroke patients for acute treatment. *Neurology*. 2007; 68:694–697.

These authors write: “Correlation between PCT/CTA and MRI was excellent for infarct size, cortical involvement, and internal cerebral artery occlusion and substantial for penumbra/infarct ratio. Relying on MRI or PCT/CTA would have led to the same treatment decisions in all cases but one” (p. 694).

And [5b]: M Wintermark et al: Comparative Overview of Brain Perfusion Imaging Techniques”. *Stroke*. 2005; 36: e83-e99.

Commonly, a radiologist assesses the penumbra and the infarct core in reviewing in parallel several 2D or 3D brain tissue maps with perfusion parameters such as the regional cerebral blood flow (rCBF), the cerebral blood volume (CBV), the Mean Transit Time (MTT), the Time-To-peak (TTP) and the delay. The

radiologist interprets these maps to identify different brain tissue types such as the infarct core, the ischemic area at risk and the normal brain tissue in order to select the most appropriate patient treatment. Typically, a large infarct and a comparatively small ischemic region will generally not be treated using reperfusion therapies, while a smaller infarct surrounded with a large salvageable ischemic area is generally a good candidate to these reperfusion therapies [11] [13]. Various rules with thresholds on perfusion values involving multiple maps have been proposed to assess the extent of the infarct core and the penumbra [5b]. For example, a region of depressed CBV is generally accepted as a strong indication of an infarct while a low relative rCBF or a high relative MTT is suggestive of an ischemic or a hypoperfused area at risk.

### **Vitrea references: Summary**

Vitrea CT Brain Perfusion has been shown effective in clinical publications regarding the **visualization of cerebral blood volume (CBV) abnormalities and cerebral blood flow (CBF) abnormalities in brain tissue affected by an acute stroke.**

See, for example [11]: Natarajan SK, Snyder KV, Siddiqui AH, Ionita CC et al. : Safety and effectiveness of endovascular therapy after 8 hours of acute ischemic stroke onset and wake-up strokes. *Stroke*. 2009;40:3269-3274. The authors write: *"CT perfusion scans were analyzed to evaluate for salvageable brain tissue. Endovascular therapy was only implemented on those patients in whom CT perfusion volume maps demonstrated the presence of clinically significant salvageable brain tissue as compared with established core infarct"* (p. 3270).

Further, the authors concluded: *"There is a moderate improvement in outcome at 3 months in these patients [in using endovascular therapy for late onset patients] when they are carefully selected with perfusion imaging, without an increase in morbidity or mortality"* (p 3272-3273).

See also [13]: Rai A T, Raghuram K, Domico Jet al.: Pre-intervention triage incorporating perfusion imaging improves outcomes in patients undergoing endovascular stroke therapy: a comparison with the device trials. *J NeuroIntervent Surg* (2012). The goal of the authors is to evaluate on 99 patients a triage methodology that incorporates CT perfusion imaging against previous device trials that treated all patients within a certain time frame. The authors write: *"A small cerebral blood volume (CBV) abnormality ( $p < 0.0001$ ) and large mean transit time-CBV mismatch ( $p < 0.0001$ ) were strong predictors of a good outcome. (p.1) /.../ The endpoint of any stroke intervention is not just re-establishing blood flow but to achieve better functional outcomes as a consequence of restoring blood flow. Therefore, adding cerebral perfusion information to other clinical predictors of outcome may increase the confidence with which an intervention is decided upon"* (p.7).

The first list of references below contains exclusively papers using Vitrea CT Perfusion.

### **Vitrea references: Delay sensitive and delay invariant deconvolution methods**

Vitrea computes the brain perfusion maps from the dynamic CT scan acquisition covering either a part of the brain, using a multi-slice spiral CT scanner (usually a 64-slice CT) or covering the whole brain using a volumetric scanner such as the 320-slice CT scanner. The references [1] [3] [4] [6] [7] [8] [9] [10] [13][18] [19] refer to classic spiral CT scanners studies. The references [2] [5] [12] [14] [15] [16] [17] refer to whole brain 320-slice CT scanner studies. Reference [11] uses both spiral 64-slices CT and 320-slice scanner.

The computation of the perfusion maps such as CBF, MTT or delay is based on a deconvolution algorithm such as a singular-value deconvolution (SVD). An important issue in recent neuroradiology research was to assess the comparative performances of various deconvolution algorithms in brain CT perfusion. In particular, studies compared the new generation of algorithms described as delay invariant SVD+ with former delay sensitive algorithms SVD [1b].

Vitreia currently applies in the Brain perfusion for classic spiral CT scan brain perfusion datasets either the classic delay-sensitive SVD algorithm or the new delay-invariant SVD+ algorithm. For 320-slice whole brain scans, Vitrea currently applies only the new delay insensitive SVD+ algorithm. A comparison of the results between SVD and SVD+ techniques appears in the reference [2] & [5]. Studies [2] [5] [11] [14] [15] [16] explicitly use Vitrea delay-invariant SVD+ algorithm. The studies [5] [9] [11] explicitly refer to Vitrea classic delay-sensitive SVD algorithm.

### **Vitreia references: the clinical indications**

All studies presented in the list below investigate the Brain CT perfusion in the context of the *acute ischemic stroke with Vitrea*. Only studies [12] & [16] extend their case review to other pathologies beyond the acute stroke such as the brain tumor, the arteriovenous malformation, etc. While several papers refer to the acute ischemic stroke (AIS), the papers [6] [9] & [10] address specific cerebrovascular conditions such as the luxury perfusion which are related to a minority of AIS. Similarly, paper [14] addresses a specific unusual condition following the acute stroke (crossed cerebellar diaschisis) suggesting the role of CT perfusion with Vitrea beyond the acute phase of the stroke.

### **References using Vitrea CT Brain perfusion**

[1] Bhatt A, Vora NA, Thomas AJ, Majid A, et Al: Lower pretreatment cerebral blood volume affects hemorrhagic risks after intra-arterial revascularization in acute stroke. *Neurosurgery*. 2008 Nov;63(5):874-8; discussion 878-9.

*Site: Dpt. of Neurology, Michigan State Univ., East Lansing, Michigan, USA.*

*Goal: assess the pre-treatment CT perfusion parameters as predictors of developing intracranial hemorrhage.*

*Method: 57 patients. Retrospective study. CT perfusion before intra-arterial thrombolysis. Regression modeling.*

*Result-conclusion: reduced pretreatment CBV is the only variable predictive of the post treatment hemorrhage.*

[2] Dababneh H, Guerrero W, Wilson K, Hoh BL, Mocco JD, et al. (2011): Observation of mean transit time (MTT) perfusion maps on a 320-Detector row CT scanner and its potential application in acute ischemic stroke. *J Neurol Neurophysiol* 2:115.

*Site: Departments of Neurology, University of Florida, College of Medicine, Gainesville, FL USA*

*Goal: Assess delay invariant (SVD+) MTT map as predictors of ischemic penumbra and infarct Core on 320-slice whole brain CT scanner.*

*Method: 320-slice CT scanner. 3 patients. Vitrea fX version 1.3. SVD+ deconvolution algorithm.*

*Results - Conclusion: Utilization of the SVD+ MTT map may allow for a more accurate assessment of the infarct core and surrounding salvageable tissue as compared to cerebral blood flow/cerebral blood volume (CBF/CBV) mismatch though further studies are required to validate this observation.*

**[3]** Chaudhry SA, Miley JT, Khatri R, Hassan SA, et al. : Microcatheter to recanalization (procedure time) predicts outcomes in endovascular treatment in patients with acute ischemic stroke: when do we stop? *AJNR Am J Neuroradiol.* 2012 Jul 19.

*Goal: determine the relationship among procedure time, recanalization, and clinical outcomes in patients with acute ischemic stroke undergoing endovascular treatment.*

*Method: Retrospective study 209 patients. Analyze data from consecutive patients with acute ischemic stroke who underwent endovascular treatment during a 6-year period.*

*Result- conclusion: Procedure time in patients with acute ischemic stroke appears to be a critical determinant of outcomes following endovascular treatment.*

**[4]** Hassan AE, Zacharatos H, Rodriguez GJ, Vazquez G, et al.: A comparison of Computed Tomography perfusion-guided and time-guided endovascular treatments for patients with acute ischemic stroke. *Stroke.* 2010 Aug;41(8):1673-8.

*Site: Zeenat Qureshi Stroke Research Center, Univ. Minnesota. Goal: to determine whether CTP-guided endovascular treatment improves clinical outcomes compared with standard endovascular treatment based on the time interval between symptom onset and presentation and noncontrast cranial CT imaging.*

*Method: Retrospective study. 61 patients. Comparison of the clinical characteristics, complications, and clinical outcomes of patients with acute ischemic stroke treated using endovascular modalities based on either CT-P imaging (CT-P-guided) or time interval between symptom onset and presentation and absence of intracerebral hemorrhage or extensive ischemic changes on noncontrast cranial CT scan (time-guided).*

*Result-conclusion: CT-P-guided endovascular treatment did not increase the rate of short-term favorable outcomes among patients with acute ischemic stroke. Prospective studies are required to validate the CT-P criteria and protocols currently in use before incorporating CT-P as a routine modality for patient selection for endovascular treatment.*

**[5]** Heiberger, P T: "Protocol variation analysis of whole brain CT perfusion in acute ischemic stroke" (2010). *Master of Science dissertation.* University of Nevada Las Vegas. UNLV Theses/ Dissertations/Professional Papers/Capstones. Paper 740.

<http://digitalscholarship.unlv.edu/thesesdissertations/740>

*Site: University of Nevada. Department of Health Physics and Diagnostic Sciences. USA*

*Goal: Assess the effect of two CT perfusion protocols: delay sensitive (SVD) and delay insensitive (SVD+) deconvolution algorithms on the CTP parametric maps.*

*Method: 320-slice CT scanner. 7 patients. Vitrea fX version 1.2. Colometric image analysis in Matlab.*

*Results - Conclusion: SVD+ produced more consistent CTP values with less variation than the SVD deconvolution algorithm.*

**[6]** Karagulle Kendi AT, Miley JT, McKinney AM, Truwit CL et al.: Luxury perfusion masking subacute infarcts on dynamic CT perfusion. *ASNR Poster. ASNR 2007, June 111-14, 2007 Chicago, IL.*

*Site: University of Minnesota and Hennepin County Medical Center, Minneapolis, MN.*

*Goal: Describe the hyperperfusion phenomenon occurring in the subacute phase on dynamic CT perfusion (CTP), potentially obscuring the extent of infarction, and to propose tools to avoid this pitfall.*

*Method: CTP 6 patients. 64-slice CT. Processed with Vitrea 2. Comparison DWI.*

*Results - Conclusion: Hyperemia (increased CBF and CBV) rather than Oligemia in a territory of subacute phase infarction is likely related to the concept of luxury perfusion from capillary dysfunction, based on recent literature.*

**[7]** Khatri K, Rodriguez GJ, Suri MF, Vazquez G Et al. : Leptomeningeal Collateral Response and Computed Tomographic Perfusion Mismatch in Acute Middle Cerebral Artery Occlusion. *Journal of Vascular and Interventional Neurology* 2011;4(1):1-4

*Site: Zeenat Qureshi Stroke Research Center, Department of Neurology, University of Minnesota, Minneapolis, MN, USA*

*Goal: Study the relationship between the extent of leptomeningeal collaterals (LMC) seen on DSA and regional cerebral blood volume (rCBV)/regional cerebral blood flow (rCBF) mismatch visible on CTP.*

*Method: Retrospective study on 16 patients. CTP perfusion using Vitrea 2 and scoring collateral flow prior to treatment on DSA images. Assess rCBV/rCBF mismatch on perfusion maps.*

*Results - Conclusion: There was no association between the magnitude of LMC on DSA and the severity of rCBV/rCBF mismatch on CTP.*

**[8]** McKinney A, Truwit CL and S Kieffer: Reversibility of an "Apparent" Infarct on Dynamic Perfusion CT after Lytic Therapy: Comment regarding cerebral blood flow and blood volume thresholds. *AJNR Am J Neuroradiol* 2006. 27:1391–95.

*Site: Department of Radiology University of Minnesota Medical School and Hennepin County Medical Center Minneapolis, MN.USA*

*Goal: Answer to the paper: "Schaefer PW, Roccatagliata L, Ledezma C, et al.: First-pass quantitative CT perfusion identifies thresholds for salvageable penumbra in acute stroke patients treated with intra-arterial therapy. AJNR Am J Neuroradiol 2006;27: 20–25".*

**[9]** Nagar VA, Karagulle Kendi AT, McKinney AM, Truwit CL. Detection of luxury perfusion via utilization of time-to-peak, delay, transit time, and blood volume maps in patients initially suspected to have acute infarction. *ASNR poster*. 2008. May 31 – June 5, 2008. New Orleans, LA.

*Site: Division of Neuroradiology, University of Minnesota Medical Center & Department of Radiology, Hennepin County Medical Center, Minneapolis, MN, USA*

*Goal: evaluate the use of time to peak (TTP), Delay, cerebral blood volume (CBV), and mean transit time (MTT) maps via dynamic CTP in detecting infarcts with suspected reperfusion or hyperperfusion.*

*Method: 10 patients. CTP in subacute and acute phases using Vitrea 2 – SVD algorithm. ROIs with Time to Peak (TTP), Delay, Mean transit time (MTT), CBF and CBV. Comparison DWI.*

*Result – Conclusion: In patients with irreversible cerebral infarction who demonstrate normal CBF and mildly elevated CBV on CTP, a combination of the MTT, and Delay maps may aid in detecting the uncommon state of "luxury perfusion."*

**[10]** Nagar VA., McKinney AM, Karagulle AT, Truwit CL: Reperfusion phenomenon masking acute and subacute infarcts at dynamic perfusion CT: confirmation by fusion of CT and diffusion-weighted MR images. *AJR* 2009; 193:1629–1638.

*Site: Department of Radiology, University of Minnesota and Hennepin County Medical Center MN.USA*

*Goal: Evaluate cerebral blood flow, cerebral blood volume, mean transit time, time to peak, and delay in a selected sample of patients with visually normal or increased cerebral blood volume to facilitate detection of a post-ischemic CT perfusion hyperperfusion–reperfusion phenomenon.*

*Method: 10 patients. Comparison CTP on 64-slice CT in subacute and acute phase. MR DWI with image fusion.*

*Results - Conclusion: Different pattern of MTT, TTP, CBV and CBF related to reperfused or hyperperfused infarct in subacute or acute phase.*

**[11]** Natarajan SK, Snyder KV, Siddiqui AH, Ionita CC et al. : Safety and Effectiveness of Endovascular Therapy After 8 Hours of Acute Ischemic Stroke. Onset and Wake-Up Strokes. *Stroke*. 2009;40:3269-3274.

*Site: Department of Neurosurgery, Millard Fillmore Gates Hospital, Kaleida Health, Buffalo N, USA*

*Goal: Evaluate the safety, effectiveness, and feasibility of endovascular therapy for patients presenting after 8 hours of stroke symptom onset and woke up stroke.*

*Method: Retrospective study based on 30 patients. 64-slice scans and few 320-slices CT scans. Review of perfusion maps TTP, MTT, rCBF, and CBV using SVD algorithm (64-slice datasets) and both SVD & SVD+ delay invariant algorithm (320 slice scanner). Assessment of effective recanalization with angiograms. Analysis of immediate and 3-month outcomes.*

*Results - Conclusion: moderate improvement in outcome at 3 months in these patients when they are carefully selected with perfusion imaging.*

**[12]** W.W. Orrison, K.V. Snyder, L.N. Hopkins, C.J. Roach, et al.: Whole-brain dynamic CT angiography and perfusion imaging. *Clinical Radiology*, 66 (6) 2011. Pages 566-574

*Site: CHW Nevada Imaging Company, Spring Valley, Las Vegas, NV, USA.*

*Goal: Examples demonstrating the clinical utility of whole-brain CT perfusion imaging in selected acute and chronic ischemic arterial neurovascular conditions are presented.*

**[13]** Rai A T, Raghuram K, Domico Jet al.: Pre-intervention triage incorporating perfusion imaging improves outcomes in patients undergoing endovascular stroke therapy: a comparison with the device trials. *J NeuroIntervent Surg* (2012). doi:10.1136/neurintsurg-2011-010189

*Site: Interventional Neuroradiology, West Virginia University Hospital, Morgantown, West Virginia, USA.*  
*Goal: to evaluate a triage methodology that incorporates CT perfusion imaging against previous device trials that treated all patients within a certain time frame.*

*Method: Retrospective study based on 99 patients. ROI comparison on perfusion maps.*

*Results - Conclusion: A small cerebral blood volume (CBV) abnormality ( $p < 0.0001$ ) and large mean transit time-CBV mismatch ( $p < 0.0001$ ) were strong predictors of a good outcome. Adding cerebral perfusion information to other clinical predictors of outcome may increase the confidence with which an intervention is decided upon.*

**[14]** Shankar and J Lum C: Crossed cerebellar diaschisis: assessment with dynamic contrast imaging on whole brain perfusion on 320 slice CT scanner. *SNIS Annual Meeting poster abstracts* (25). *J NeuroIntervent Surg* 2009 1: 97-98.

*Site: Diagnostic Imaging, The Ottawa Hospital, Ottawa, Ontario, Canada*

*Goal: investigate the feasibility of the whole brain perfusion using a 320-slice CT scanner to depict crossed cerebellar diaschisis.*

*Method: 11 patients. 320-slice CT scanner. Vitrea fx v. 1.0. SVD+ delay insensitive algorithm. CBV and CBF maps.*

*Results – Conclusion: The relative regional cerebellar blood volume map obtained with whole brain perfusion on 320-slice CT scanner depicted findings compatible with crossed cerebellar diaschisis in patients with supratentorial stroke.*

**[15]** Shiva Shankar J J, Lum C, Sharma M: Whole-Brain Perfusion Imaging with 320-MDCT Scanner: reducing Radiation Dose by increasing sampling interval. *AJR* 2010; 195:1183–1186

*Site: Neuroradiology Section, Department of Medical Imaging, QE II Hospital, Halifax, NS, Canada.*

*Goal: investigate whether perfusion CT values obtained with a reduced-dose imaging protocol on a 320-MDCT scanner are similar to those obtained with a standard protocol.*

*Method: 19 patients. Reduced dose protocol simulated in selecting fewer phases in the original datasets (sampling interval: 4s instead of the usual 2s). Processed with Vitrea fx v.1.0. Delay invariant SVD+ deconvolution algorithm. Draw ROIs.*

*Results - Conclusion: Similar perfusion values at one-half the radiation dose can be obtained with the alternative algorithm used in this study*

**[16]** Shankar. Whole brain CT perfusion on a 320-slice CT scanner. *Indian J Radiol Imaging*. 2011 Jul-Sep; 21(3): 209–214.

*Goal: Review of neuroradiological applications of whole brain CT perfusion: Acute stroke, chronic ischemia, arteriovenous malformations, brain tumors, Intracerebral hematomas.*

*Method: Retrospective study with 81 patients undergoing whole brain CT perfusion. Vitrea fx 1.0. Computation of CBF, CBV, MTT and TTP using SVD+ deconvolution method.*

*Results-Conclusion: This paper highlighted the advantages and new implications of whole brain coverage CT perfusion using the 320-CT scanner, compared to the limited-slice CT perfusion with classic CT scanners. Web access: <http://www.ijri.org/article.asp?issn=0971-3026;year=2011;volume=21;issue=3;spage=209;epage=214;aurlast=Shiva>*

**[17]** Siebert E, Bohner G, Dewey M, Mashur F, Hoffmann K T et al: 320-slice CT neuroimaging: initial clinical experience and image quality evaluation. *The British Journal of Radiology*, 82 (2009), 561–570.

*Site: Departments of Neuroradiology Radiology and Neurology, Charite' University Medicine, Berlin, Germany.*

*Goal: Report initial clinical experience and image quality in 320-slice CT perfusion and CTA.*

*Method: 26 patients. 4D CTA and 4D CTP acquisitions. Qualitative image quality assessment with 2 readers.*

*Results - Conclusion: CT is a feasible and robust neuroimaging method for the comprehensive assessment of cerebrovascular pathology. Lower image quality of 320-slice CT compared to 64-slice CT in this early clinical evaluation.*

**[18]** Tekşam M, Çakır B, Coşkun M: CT perfusion imaging in the early diagnosis of acute stroke. *Diagn. Interv. Radiol* 2005; 11:202-205.

*Site: Department of Radiology, Başkent University School of Medicine, Ankara, Turkey.*

*Goal: Assess the capability of the CT Perfusion to provide valuable information about the hemodynamic status of ischemic brain tissue, with comparison using DWI MR and unenhanced CT.*

*Method: 2 cases. CTP with Vitrea 2, review rCBF, CBV and MTT maps. Comparison with non contrast CT and MR DWI.*

*Results – Conclusion: CT perfusion imaging demonstrated significant perfusion defects in the middle cerebral artery territory in both cases. DW-MR imaging confirmed acute infarctions, which were smaller than the perfusion defect areas in the CT perfusion imaging in both cases.*

**[19]** Zussman BM, Boghosian G, Gorniak RJ, Olszewski ME et al.: The Relative Effect of Vendor Variability in CT Perfusion Results: A Method Comparison Study. *AJR* 2011; 197:468–473.

*Site: Dept. of Radiology, Thomas Jefferson University Hospital, Philadelphia, MD.*

*Method: 11 patients. Comparison of absolute CBF, CBV and MTT maps using 2 methods, 4 vendors including Vitrea, 3 readers.*

*Results, conclusion: Intervendor difference is, by far, the largest cause of variability in perfusion results relative to interoperator and intraoperator difference.*

## **Other references (CT Perfusion Imaging & Stroke)**

**[1B]** Konstas AA & M E Lev: CT perfusion imaging of acute stroke: the need for arrival time, delay insensitive, and standardized postprocessing algorithms? *Radiology* 2010; 254:22–25

**[2b]** Love A, Siemund R, Andsberg G, Cronqvist M, et al.: Comprehensive CT evaluation in acute ischemic stroke: Impact on diagnosis and treatment decisions. *Stroke Research and Treatment*. 2011, 10 pages.

**[3b]** Murphy BD, Fox AJ, Lee DH, et al. Identification of penumbra and infarct in acute ischemic stroke using computed tomography perfusion-derived blood flow and blood volume measurements. *Stroke* 2006;37:1771-1777.

**[4b]** Schaefer PW, Barak ER, Kamalian S, Gharai LR, et al.: Quantitative assessment of core/penumbra mismatch in acute stroke: CT and MR perfusion imaging are strongly correlated when sufficient brain volume is imaged. *Stroke*. 2008; 39:2986 –2992.

**[5b]** Wintermark M et Al.: Perfusion-CT assessment of infarct core and penumbra receiver operating characteristic curve analysis in 130 patients suspected of acute hemispheric stroke. *Stroke*. 2006. 979-986.

**[6b]** Wintermark M, Meuli R, Browaeys P, Reichhart M, et al.: Comparison of CT perfusion and angiography and MRI in selecting stroke patients for acute treatment. *Neurology*. 2007; 68:694–697.



**Paper-1:**

**Bhatt A, Vora NA, Thomas AJ, Majid A, et Al:**  
**Lower pretreatment cerebral blood volume**  
**affects hemorrhagic risks after intra-arterial**  
**revascularization in acute stroke.**  
*Neurosurgery.* 2008 Nov; 63(5):874-8;  
discussion 878-9.

**Archit Bhatt, M.D.**

Department of Neurology,  
Division of Cerebrovascular Diseases,  
Michigan State University,  
East Lansing, Michigan

**Nirav A. Vora, M.D.**

Department of Neurology,  
Stroke Institute,  
University of Pittsburgh  
Medical Center,  
Pittsburgh, Pennsylvania

**Ajith J. Thomas, M.D.**

Department of Neurology,  
Stroke Institute,  
University of Pittsburgh  
Medical Center,  
Pittsburgh, Pennsylvania

**Arshad Majid, M.D.**

Department of Neurology,  
Division of Cerebrovascular Diseases,  
Michigan State University,  
East Lansing, Michigan

**Mounzer Kassab, M.D.**

Department of Neurology,  
Division of Cerebrovascular Diseases,  
Michigan State University,  
East Lansing, Michigan

**Maxim D. Hammer, M.D.**

Department of Neurology,  
Stroke Institute,  
University of Pittsburgh  
Medical Center,  
Pittsburgh, Pennsylvania

**Ken Uchino, M.D.**

Department of Neurology,  
Stroke Institute,  
University of Pittsburgh  
Medical Center,  
Pittsburgh, Pennsylvania

**Lawrence Wechsler, M.D.**

Department of Neurology,  
Stroke Institute,  
University of Pittsburgh  
Medical Center,  
Pittsburgh, Pennsylvania

**Tudor G. Jovin, M.D.**

Department of Neurology,  
Stroke Institute,  
University of Pittsburgh  
Medical Center,  
Pittsburgh, Pennsylvania

**Rishi Gupta, M.D.**

Department of Neurology,  
Division of Cerebrovascular Diseases,  
Michigan State University,  
East Lansing, Michigan, and  
Cerebrovascular Center,  
The Cleveland Clinic Foundation,  
Cleveland, Ohio

**Reprint requests:**

Rishi Gupta, M.D.,  
Cerebrovascular Center,  
The Cleveland Clinic Foundation,  
9500 Euclid Avenue, S80,  
Cleveland, OH 44195.  
Email: guptar@ccf.org

**Received,** November 25, 2007.

**Accepted,** June 4, 2008.

**CLINICAL STUDIES**

## LOWER PRETREATMENT CEREBRAL BLOOD VOLUME AFFECTS HEMORRHAGIC RISKS AFTER INTRA-ARTERIAL REVASCULARIZATION IN ACUTE STROKE

**OBJECTIVE:** Intra-arterial therapies are being used more frequently in patients presenting with acute cerebral occlusions, but they have been limited by the potential for hemorrhage. We sought to determine whether pretreatment computed tomography perfusion parameters might help to identify patients at a higher risk of developing intracranial hemorrhage after intra-arterial stroke revascularization treatment.

**METHODS:** We retrospectively reviewed all patients at the University of Pittsburgh Medical Center and Michigan State University who underwent computed tomography perfusion imaging of the brain before intra-arterial thrombolysis between January 2006 and June 2007. Demographic information, angiographic variables, and types of endovascular interventions were recorded. The mean transit time and cerebral blood volumes were recorded for the ipsilateral and contralateral middle cerebral artery territories. A binary logistic regression model was constructed to determine the independent predictors of developing intracranial hemorrhage.

**RESULTS:** A total of 57 patients (33 from the University of Pittsburgh and 24 from Michigan State University) with a mean age of  $66 \pm 13$  years and mean National Institutes of Health Stroke Scale scores of  $16 \pm 5$  were studied. The overall recanalization (Thrombolysis in Myocardial Infarction Trial scale 2 or 3 flow) was 72% for the cohort, and the overall rate of parenchymal hemorrhage was 5 of 57 (9%) patients. The overall hemorrhage rate was 19 of 57 (33%) patients. The only variable found to be predictive of the development of hemorrhage after intervention was reduced pretreatment cerebral blood volume (odds ratio, 0.49; 95% confidence interval, 0.35–0.91;  $P < 0.022$ ).

**CONCLUSION:** A reduced pretreatment ipsilateral cerebral blood volume value before endovascular revascularization of an acute middle cerebral artery or internal carotid artery occlusion significantly increases the risk of an intracranial hemorrhage.

**KEY WORDS:** Acute stroke, Computed tomography perfusion, Thrombolysis

Neurosurgery 63:874–879, 2008

DOI: 10.1227/01.NEU.000033259.11739.AD

www.neurosurgery-online.com

Endovascular treatment modalities for acute ischemic strokes are increasingly used in patients with acute arterial occlusions. Mechanical, local thrombolysis, and multimodal approaches have all been described with varying success rates at revascularizing occluded cerebral arteries (4, 5, 8). These therapies have been limited by the small number of patients presenting within the therapeutic window, as well as hemorrhagic complications

associated with treatments. Computed tomography perfusion (CTP) has been described and studied to help determine potentially suitable candidates for acute stroke interventions (7, 12). The focus of these studies has been to validate that this imaging modality can estimate salvageable tissue (penumbra). Lower cerebral blood volume (CBV) values and cerebral blood flow (CBF) have been shown to correlate with irreversibly injured tissue (7, 12). CTP has not

**ABBREVIATIONS:** CBF, cerebral blood flow; CBV, cerebral blood volume; CT, computed tomographic; CTP, computed tomography perfusion; MCA, middle cerebral artery.

## CEREBRAL BLOOD VOLUME AFFECTS HEMORRHAGIC RISKS

been extensively studied as a potential predictor for determining patients at risk of hemorrhage after intra-arterial therapies for acute stroke. We hypothesized that patients who presented with lower hemispheric CBV values before revascularization were at a higher risk of developing an intracranial hemorrhage.

### PATIENTS AND METHODS

After approval from the Institutional Review Boards at each respective university, we retrospectively reviewed all patients who underwent CTP imaging before endovascular therapy for an occlusion of the extracranial or intracranial portion of the internal carotid artery and/or middle cerebral artery (MCA) at Michigan State University and the University of Pittsburgh Medical Center between January 2006 and June 2007. A total of 60 patients were identified. Three were excluded because of CTP maps that were not interpretable because of excessive patient movement artifact ( $n = 2$ ), and 1 patient with a poor ejection fraction in whom the contrast bolus was poorly timed was excluded. Thus, a total of 57 patients (33 from Pittsburgh and 24 from Michigan State University) were identified for this study.

Demographic information was collected and recorded. Angiographic studies and reports were reviewed to determine the modalities of treatment used. Computed tomographic (CT) scans were obtained for all patients within 24 hours of intra-arterial therapy. Hemorrhage was distinguished from poor contrast clearance by persistence of hyperattenuation on a follow-up CT scan (11). Hemorrhage was classified as parenchymal hematoma or hemorrhagic infarction based on previously published guidelines (2).

#### CT Perfusion Maps

An initial CT scan of the head was obtained before the CTP acquisition. A 20-gauge cannula was placed in the right antecubital vein in each patient. The CTP examination was performed as follows: 45-second cine scanning (80 kilovolt [peak] [kVP], 190 mA) with a 7-second delay and an injection of 40 mL of ioversol (OPTIRAY 350; Covidien, Mansfield, MA). A total of 4 slices were identified 5 mm apart, with the first slice at the level of the third ventricle and basal ganglia. Arterial and venous output functions were obtained using the ipsilateral anterior cerebral artery and the torcula (confluence of the venous sinuses). Postprocessing of images using the Vitrea workstation allowed for generation of the mean transit time maps, CBV, and CBF.

#### Image Analysis

The color-coded CTP maps were assessed by 3 of the authors (AB, NAV, AJT) by drawing a region-of-interest circle around the MCA territory in the ipsilateral and contralateral images for the 4 cuts obtained. This was performed for the CBV, mean transit time, and CBF maps and was averaged over the 4 slices to obtain a mean value for each patient. Two of the authors analyzed each CT perfusion map together. Follow-up non-contrast CT imaging was obtained for each patient within 24 hours of endovascular intervention. Patients with hyperdensity on CT imaging after intervention were noted to have an intracranial hemorrhage. Patients were classified as having parenchymal hematoma and hemorrhagic infarction, but hemorrhages were grouped together for analysis in a binary fashion.

#### Interventional Procedure

Patients were brought to the angiography suite, and a 6-French sheath was placed in the right common femoral artery. A 5-French diagnostic catheter was used to perform the angiography. In patients

with occlusions of the internal carotid artery, angiography of the contralateral carotid artery and 1 vertebral artery was performed to assess the collateral patterns, whereas patients with isolated MCA occlusions were treated without selecting other vessels. After the location of the occlusion was noted, a 6-French guide catheter or 8-French balloon guide catheter was placed in the ipsilateral internal carotid artery. The microcatheter and microwire were used to traverse the intracranial occlusion, and delivery of thrombolytics was performed using the pulse-spray technique. In patients treated with mechanical thrombectomy, the Merci Retrieval System (Concentric Medical, Mountain View, CA) was placed in the thrombus, and a gradual pullback was performed. Patients who failed thrombectomy and pharmacological lysis were treated with placement of a balloon-mounted coronary stent across the occlusion. The stents were undersized by 10% of the proximal vessel diameter.

In patients with an extracranial carotid total occlusion ( $n = 15$ ), a 7-French shuttle sheath was placed in the proximal common carotid artery. Patients with extracranial carotid artery occlusions were treated with placement of 0.014-inch microwire across the occlusion with a microcatheter. A microcatheter injection was performed to determine whether the proximal occlusion was focal. An exchange-length, 300-cm, 0.014-inch microwire was then placed through the microcatheter, which was removed. An Acculink self-expanding stent (Guidant Corp., Indianapolis, IN) was then placed across the occlusion, and this was postdilated with an appropriately sized balloon. The guide catheter was then advanced through the stent and the distal occlusion was treated as described above.

Patients who were treated with stents were given a bolus of eptifibatid of 180  $\mu\text{g}/\text{kg}$  after stent deployment. Clopidogrel and aspirin were given if the 24-hour head CT scan was negative for intracranial hemorrhage.

#### Statistics

Statistical analysis was performed using SPSS software (version 15; SPSS, Inc., Chicago, IL). A univariate analysis was performed to determine predictors of hemorrhage. Categorical variables were assessed using Fisher's exact test and continuous variables with Student's *t* test. Variables with a *P* value of less than 0.10 were entered into a binary logistic regression model using the Enter method to determine the independent predictors of the development of hemorrhage after intervention.

## RESULTS

A total of 57 patients (33 from the University of Pittsburgh and 24 from Michigan State University) with a mean age of  $66 \pm 13$  years and mean National Institutes of Health Stroke Scale score of  $16 \pm 5$  were studied. The overall mean time to completion of treatment with endovascular therapy was  $335 \pm 165$  minutes, without any difference between the hemorrhage and nonhemorrhage groups. Forty-five patients were found to have an isolated M1 segment of the MCA or carotid terminus occlusion, whereas 12 presented with tandem occlusions (extracranial internal carotid artery and MCA). Mechanical intervention with a retrieval device was performed in 30 (53%) patients, and a stent was placed in 22 (39%) patients. The overall recanalization (Thrombolysis in Myocardial Infarction Trial scale 2 or 3 flow) was 72% for the cohort, and the overall rate of parenchymal hematomas was 5 of 57 (9%) patients. The overall hemorrhage rate, including hemorrhagic infarction, was 19 of 57 (33%) patients. The mean CBF for patients who developed

BHATT ET AL.

**TABLE 1. Univariate analysis for predictors of intracranial hemorrhage after endovascular therapy for anterior circulation arterial occlusion\***

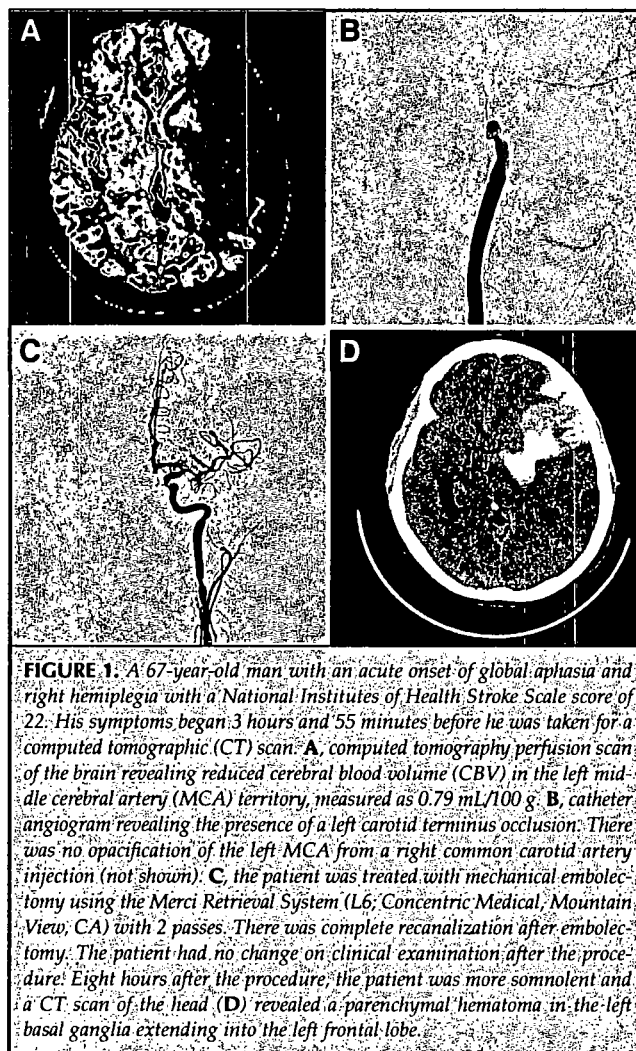
	No hemorrhage, no. (%) (n = 38)	Hemorrhage, no. (%) (n = 19)	P value
<b>Demographics</b>			
Age (years $\pm$ SD)	66.5 $\pm$ 13.8	63.6 $\pm$ 13.4	0.45
Female	19 (50)	7 (37)	0.26
Hypertension	11 (29)	8 (42)	0.38
Diabetes	18 (44)	6 (32)	0.48
A Fib	13 (34)	6 (32)	0.78
Hyperlipidemia	13 (34)	6 (32)	0.78
NIHSS admission (points $\pm$ SD)	15 $\pm$ 5	16 $\pm$ 4	0.46
<b>Thrombus Location</b>			
Carotid terminus	13 (34)	7 (37)	0.72
M1 MCA	15 (38)	10 (53)	0.39
Tandem occlusion	7 (18)	5 (26)	0.51
<b>Therapy</b>			
IV tPA + IA therapy	9 (24)	7 (36)	0.25
Mechanical only	20 (52)	6 (31)	0.19
Mechanical + IA thrombolysis	12 (32)	8 (42)	0.56
<b>CT Perfusion</b>			
Ipsilateral MTT (s $\pm$ SD)	7.9 $\pm$ 2.6	8.0 $\pm$ 2.1	0.82
Contralateral MTT (s $\pm$ SD)	4.4 $\pm$ 1.1	4.2 $\pm$ 0.8	0.35
Ipsilateral CBV (mL/100 g $\pm$ SD)	2.2 $\pm$ 1.1	1.5 $\pm$ 0.9	0.02
Contralateral CBV (mL/100 g $\pm$ SD)	3.1 $\pm$ 0.9	3.0 $\pm$ 0.7	0.62

\* SD, standard deviation; A fib, atrial fibrillation; NIHSS, National Institutes of Health Stroke Scale; MCA, middle cerebral artery; IV, intravenous; tPA, tissue plasminogen activator; IA, intra-arterial; MTT, mean transit time; s, seconds; CBV, cerebral blood volume.

hemorrhage was  $11.5 \pm 6.5$  mL/100 g/min, compared with  $18.5 \pm 6.2$  mL/100 g/min ( $P < 0.005$ ) for patients without hemorrhage. As expected, there was significant interaction between CBF and CBV, but CBV was found to be a better predictor of developing hemorrhage. Table 1 summarizes the univariate analysis for predictors of hemorrhage.

The only variable found to be predictive of the development of any hemorrhage after intervention in binary logistic regression modeling was a reduced pretreatment CBV (odds ratio, 0.49; 95% confidence interval, 0.35–0.91;  $P < 0.022$ ).

Of the 19 patients who developed a hemorrhage, 16 (84%) patients were found to have a CBV value of less than 1.8



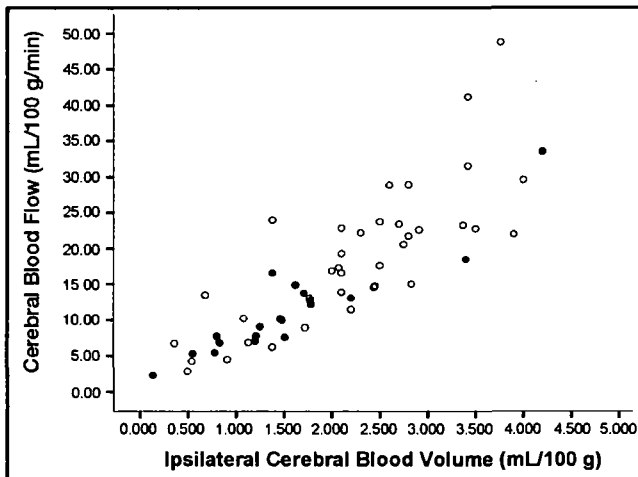
**FIGURE 1.** A 67-year-old man with an acute onset of global aphasia and right hemiplegia with a National Institutes of Health Stroke Scale score of 22. His symptoms began 3 hours and 55 minutes before he was taken for a computed tomographic (CT) scan. **A**, computed tomography perfusion scan of the brain revealing reduced cerebral blood volume (CBV) in the left middle cerebral artery (MCA) territory, measured as 0.79 mL/100 g. **B**, catheter angiogram revealing the presence of a left carotid terminus occlusion. There was no opacification of the left MCA from a right common carotid artery injection (not shown). **C**, the patient was treated with mechanical thrombectomy using the Merci Retrieval System (L6; Concentric Medical, Mountain View, CA) with 2 passes. There was complete recanalization after thrombectomy. The patient had no change on clinical examination after the procedure. Eight hours after the procedure, the patient was more somnolent and a CT scan of the head (**D**) revealed a parenchymal hematoma in the left basal ganglia extending into the left frontal lobe.

mL/100 g, and 14 (74%) were found to have a CBF of less than 13 mL/100 g/min. Figure 1 shows an example of a patient who developed a parenchymal hematoma after endovascular intervention in the setting of a low CBV. In contrast to the 38 patients without hemorrhage, only 12 (31%) patients were found to have a CBV value of less than 1.8 mL/100 g, and 11 (29%) had a CBF of less than 13 mL/100 g/min. Figure 2 illustrates the distribution of all patients with and without hemorrhage relative to their CBV and CBF values.

## DISCUSSION

This study reveals that patients who present with lower hemispheric CBV values are more likely to develop intracranial hemorrhage after endovascular therapy for acute ischemic stroke. The CBV parameter of CTP has predominantly been used to determine the viability of tissue at risk for undergoing irreversible infarction (7, 12). In the setting of an acute arterial occlusion,

## CEREBRAL BLOOD VOLUME AFFECTS HEMORRHAGIC RISKS



**FIGURE 2.** Scatter plot showing that patients with development of intracranial hemorrhage (dark circles) after intervention were more likely to have lower CBV and cerebral blood flow values before treatment compared with patients who did not develop hemorrhage (open circles).

sion, a CBV value of less than 2.0 mL/100 g may represent irreversibly injured tissue (12). The current study shows that patients with reduced CBV are at a higher risk of hemorrhage, likely because of the larger areas of irreversibly injured tissue.

Two types of hemorrhage have been identified after thrombolysis: hemorrhagic infarction that is a result of petechial bleeding without mass effect, and parenchymal hematoma as a result of a confluent hemorrhage with mass effect (2). We did not distinguish between these 2 types of bleeds in this study because it is not clear that petechial bleeds are truly asymptomatic (3). Others have found that patients are at a higher risk of developing hemorrhagic infarctions in the setting of larger territories of infarction pretreatment, whereas parenchymal hematomas develop as a result of the use of thrombolytics (9, 10). There were too few patients to analyze separately for variables associated with developing parenchymal hematomas in our current study, but our findings corroborate the fact that patients were at a higher risk of hemorrhage because of larger regions of infarcted tissue, based on CBV parameters.

Interpretation of CTP variables may be somewhat limited, as this approach has not been validated in the acute setting of studies such as positron emission tomography or xenon computed tomography. A recent study showed on xenon CT scans that patients with reduced CBF to the affected MCA territory were at a significantly higher risk of developing hemorrhage after intra-arterial tissue plasminogen activator (6). CTP is more pragmatic in the setting of an acute stroke, as it can be obtained from the emergency room, and interpretation can be performed in a timely manner. Thus, identifying CTP thresholds may be of clinical use for patients being considered for aggressive interventions. In the current cohort, patients with a CBV value of less than 1.8 mL/100 g were found to be at a higher risk of developing a hemorrhage. Additionally, patients with a CBF

value of less than 13 mL/100 g/min appeared to be at a higher risk of developing hemorrhage. These thresholds are similar to what has been described with xenon CT imaging for acute stroke interventions and are intriguing because the value is at the lower end of the threshold for penumbra and the upper end of threshold for irreversible injury (1, 6).

There are limitations to this study, given its retrospective nature. Additionally, there was no standard protocol for acute stroke interventions at either institution; thus, the type of intervention may also contribute to the development of hemorrhage. We analyzed the various modalities used, but, given the small sample sizes for each group, the analysis may not detect differences seen in large groups of patients. Thirdly, this was not a consecutive series of all patients undergoing endovascular intervention; thus, there may be a component of selection bias in this group of patients. It is unlikely that this would lead to a significant difference, as the patients selected for treatment were standardized at both institutions based on the time of symptom onset.

In conclusion, we found that patients who present with a low pretreatment CBV on CTP were at a significantly higher risk for developing an intracranial hemorrhage. Further study is required in a prospective manner with standardized endovascular treatment paradigms to identify whether a threshold exists where the risk of hemorrhage is too high to warrant aggressive intervention.

### Disclosure

Lawrence Wechsler, M.D., has received compensation from Abbott Laboratories and Bristol Meyer Squibb. Tudor G. Jovin, M.D., is on the Scientific Advisory Board for Concentric Medical, a consultant for EV3, and a consultant for CoAxia Medical. Rishi Gupta, M.D., is on the Scientific Advisory Board for Concentric Medical.

### REFERENCES

1. Astrup J, Siesjö BK, Symon I: Thresholds in cerebral ischemia - the ischemic penumbra. *Stroke* 12:723-725, 1981.
2. Berger C, Fiorelli M, Steiner T, Schätzl WR, Bozzao L, Bluhmki E, Hacke W, von Kummer R: Hemorrhagic transformation of ischemic brain tissue: Asymptomatic or symptomatic? *Stroke* 32:1330-1335, 2001.
3. Dzialowski I, Pexman JH, Barber PA, Demchuk AM, Buchan AM, Hill MD; CASES Investigators: Asymptomatic hemorrhage after thrombolysis may not be benign: Prognosis by hemorrhage type in the Canadian alteplase for stroke effectiveness study registry. *Stroke* 38:75-79, 2007.
4. Furlan A, Higashida R, Wechsler L, Gent M, Rowley H, Kase C, Pessin M, Ahuja A, Callahan F, Clark WM, Silver F, Rivera F: Intra-arterial prourokinase for acute ischemic stroke. The PROACT II study: A randomized controlled trial. *Prolyse in Acute Cerebral Thromboembolism. JAMA* 282:2003-2011, 1999.
5. Gupta R, Vora NA, Horowitz MB, Tayal AH, Hammer MD, Uchino K, Levy EI, Wechsler LR, Jovin TG: Multimodal reperfusion therapy for acute ischemic stroke: factors predicting vessel recanalization. *Stroke* 37:986-990, 2006.
6. Gupta R, Yonas H, Gebel J, Goldstein S, Horowitz M, Grahovac SZ, Wechsler LR, Hammer MD, Uchino K, Jovin TG: Reduced pretreatment ipsilateral middle cerebral artery cerebral blood flow is predictive of symptomatic hemorrhage post-intra-artery thrombolysis in patients with middle cerebral artery occlusion. *Stroke* 37:2526-2530, 2006.
7. Murphy BD, Fox AJ, Lee DH, Sahlas DJ, Black SE, Hogan MJ, Coutts SB, Demchuk AM, Goyal M, Aviv RI, Symons S, Gulka IB, Beletsky V, Pelz D, Hachinski V, Chan R, Lee TY: Identification of penumbra and infarct in acute ischemic stroke using computed tomography perfusion-derived blood flow and blood volume measurements. *Stroke* 37:1771-1777, 2006.

**BHATT ET AL.**

8. Smith WS, Sung G, Starkman S, Saver JL, Kidwell CS, Gobin YP, Lutsep HL, Nesbit GM, Grobelny T, Rymer MM, Silverman IE, Higashida RT, Budzik RF, Marks MP; MERCI Trial Investigators: Safety and efficacy of mechanical embolectomy in acute ischemic stroke: Results of the MERCI trial. *Stroke* 36:1432-1438, 2005.
9. Thomalla G, Sobesky J, Köhrmann M, Fiebich JB, Fiehler J, Zaro Weber O, Kruezelmann A, Kucinski T, Rosenkranz M, Röther J, Schellinger PD: Two tales: Hemorrhagic transformation but not parenchymal hemorrhage after thrombolysis is related to severity and duration of ischemia: MRI study of acute stroke patients treated with intravenous tissue plasminogen activator within six hours. *Stroke* 38:313-318, 2007.
10. Vora NA, Gupta R, Thomas AJ, Horowitz MB, Tayal AH, Hamner MD, Uchino K, Wechsler LR, Jovin TG: Factors predicting hemorrhagic complications after multimodal reperfusion therapy for acute ischemic stroke. *AJNR Am J Neuroradiol* 28:1391-1394, 2007.
11. Wildenhain SL, Jungreis CA, Barr J, Mathis J, Wechsler L, Horton JA: CT after intracranial intra-arterial thrombolysis for acute stroke. *AJNR Am J Neuroradiol* 15:487-492, 1994.
12. Wintermark M, Flanders AE, Velthuis B, Meuli R, van Leeuwen M, Goldsher D, Pineda C, Serena J, van der Schaaf I, Waaijer A, Anderson J, Nesbit G, Gabriely I, Medina V, Quiles A, Pohlman S, Quist M, Schnyder P, Bogousslavsky J, Dillon WP, Pedraza S: Perfusion-CT assessment of infarct core and penumbra: receiver operating characteristic curve analysis in 130 patients suspected of acute hemispheric stroke. *Stroke* 37:979-985, 2006.

**COMMENTS**

Intra-arterial revascularization after acute stroke has significant appeal, but the risk of hemorrhagic complications limits its overall effectiveness. Bhatt et al. have provided a retrospective review of their experience at 2 major academic medical centers in using pretreatment computed tomographic (CT) perfusion parameters in an attempt to identify patients at high risk of developing hemorrhagic complications after intra-arterial revascularization therapy. On the basis of the presumption that infarction may have already occurred or is threatened in patients with lower cerebral blood volume (CBV) and cerebral blood flow (CBF), the authors postulate that low pretreatment CBV may increase the risk of hemorrhagic stroke. Their data clearly indicate significant interaction between CBF and CBV, but CBV was found to be a better predictor of developing hemorrhagic complications after endovascular revascularization. This is a potentially important finding, because CT perfusion studies are readily available at most medical centers and may provide a simple and reliable method for stratifying patients into high- and low-risk groups for hemorrhagic complications of acute revascularization. This study suggests that patients with reduced CBV are at a higher risk of hemorrhage, probably because of having larger areas of irreversibly injured brain tissue.

The authors are cautious in discussing this retrospective study's limitations, which include the fact that no standard protocol for acute stroke interventions was used and that this was not a consecutive series of all patients undergoing endovascular intervention. Despite these detractors, this is a potentially important observation and should be verified by larger prospective studies.

**Alexander Mason**  
**C. Michael Cawley**  
**Daniel L. Barrow**  
*Atlanta, Georgia*

**B**hatt et al. investigated whether pretreatment CT perfusion parameters may predict the risk of developing intracranial hemorrhage

after intra-arterial stroke revascularization. After retrospectively reviewing a total of 57 patients, the overall recanalization rate was 72% for the cohort, and the overall rate of symptomatic hemorrhage was 9% (5 of 57 patients). The overall hemorrhage rate including asymptomatic hemorrhage was 33% (19 of 57 patients). The only variable found to be predictive of the development of any hemorrhage postintervention was a reduced pretreatment CBV. On the basis of these findings, the authors concluded that a reduced pretreatment ipsilateral CBV value before endovascular revascularization of an acute middle cerebral artery (MCA) or internal carotid artery (ICA) occlusion significantly increases the risk of intracranial hemorrhage.

Recognition of such CT perfusion thresholds may help exclude patients being considered for acute stroke therapy secondary to unacceptably high risk. In the study at hand, CBV values of less than 1.8 mL/100 g and CBF values of less than 13 mL/100 g/min correlated with a higher risk of developing a hemorrhage. Considering the current limitations in acute stroke management, prospective studies with standardized endovascular treatment paradigms are clearly needed before widely applying these specific cutoffs.

**Ricardo J. Komotar**  
**E. Sander Connolly, Jr.**  
*New York, New York*

In this article, the authors have presented evidence that a lower pretreatment blood volume (CBV <1.8 mL/100 g) was a good predictor of hemorrhage after intra-arterial revascularization for ICA or MCA occlusion. CBV was a better predictor than a lower pretreatment CBF. The recanalization rate was very high at 72%, compared with some other studies, partly related to the use of intravascular stents when revascularization failed. However, similar recanalization rates are being achieved now with the Penumbra device (Penumbra System; Penumbra, Inc., San Leandro, CA), unfortunately, with similar rebleeding rates.

The major limitations of the study have been summarized by the authors themselves: This was not a consecutive series of patients. There was no standardization of endovascular treatments, and there was a wide range in the timing of revascularizations. The data on CBF and CBV using CT perfusion have not been validated by another accepted technique such as positron emission tomographic scanning.

Although patients with a lower pretreatment blood volume (<1.8 mL/100 g) and lower CBF (<13 mL/100 g/min) were much more likely to incur a hemorrhage, there were a number of patients who did not. The timing of the revascularization may also play an important role in the occurrence of posttreatment hemorrhage. This study offers some important leads for further investigation; however, further studies are required before we can decide to withhold endovascular revascularization in a patient on the basis of low CBV by CT perfusion.

**Laligam N. Sekhar**  
*Seattle, Washington*

**T**he authors performed a retrospective case-controlled investigation of the relationship between CT perfusion parameters and the risk of developing "any cerebral hemorrhage." Owing to the power of their study, they were unable to focus on symptomatic hemorrhage or frank parenchymal hematomas. Their simplified method of measuring quantitative CBF and CBV, averaged over an entire MCA territory over the 2-cm CT range, should provide somewhat reproducible results across different centers. They found that a mean CBV of less than 1.8 mL/100 g carries a statistically significant increased risk of parenchymal

## CEREBRAL BLOOD VOLUME AFFECTS HEMORRHAGIC RISKS

hemorrhage, with only 3 of 19 hemorrhages occurring in patients with CBV levels above this threshold. Some reports indicate that a CBV that is this low is representative of infarct core (1), and this correlates with the appearance of the CBV map in the example case. With such evidence of massive MCA infarction, one could argue that the potential benefit of thrombolysis is minimal, and the consequent prevalence of hemorrhage is unsurprising.

The utility of perfusion imaging in acute ischemic stroke therapy continues to be refined. It is possible that, in the near future, perfusion imaging may become more important than time parameters for determining whether patients should receive reperfusion therapies and with which techniques.

**Michael C. Hurley**  
**Bernard R. Bendok**  
*Chicago, Illinois*

1. Wintermark M, Flanders AE, Velthuis B, Meuli R, van Leeuwen M, Goldsher D, Pineda C, Serena J, van der Schaaf I, Waaijer A, Anderson J, Nesbit G, Gabriely I, Medina V, Quiles A, Pohlman S, Quist M, Schnyder P,

Bogousslavsky J, Dillon WP, Pedraza S: Perfusion-CT assessment of infarct core and penumbra: Receiver operating characteristic curve analysis in 130 patients suspected of acute hemispheric stroke. *Stroke* 37:979-985, 2006.

This study examined 57 patients with ICA or MCA occlusions that received endovascular therapy for acute ischemic stroke, consisting of thrombolytics, mechanical clot retrieval, or both. Overall, 72% of occluded arteries were reopened, and 33% of patients experienced intracerebral hemorrhages. Pretreatment CT perfusion data were analyzed for predictors of hemorrhagic complications, and low CBV (<1.8 mL/100 g) was the most predictive. More than low CBF, low CBV indicates irreversible ischemic injury and brain susceptible to reperfusion hemorrhage. This study demonstrates that CT perfusion studies can provide a quick, coarse assessment of posttreatment hemorrhage risk before embarking on endovascular therapy for acute ischemic stroke. A finding of low CBV values would not contraindicate treatment, but might inform family discussions before interventions and clinical management after interventions.

**Michael T. Lawton**  
*San Francisco, California*



Mount Everest. Courtesy of Tashi Tenzing and Everest Speaker's Bureau, 2003.

**Paper-2:**

**Dababneh H, Guerrero W, Wilson K, Hoh BL, Mocco JD, et al. (2011): Observation of mean transit time (MTT) perfusion maps on a 320-Detector row CT scanner and its potential application in acute ischemic stroke. *J Neurol Neurophysiol* 2:115**





## Observation of Mean Transit Time (Mtt) Perfusion Maps on a 320-Detector Row Ct Scanner and its Potential Application in Acute Ischemic Stroke

Haitham Dababneh<sup>1</sup>, Waldo Guerrero<sup>1</sup>, Kelvin Wilson<sup>2</sup>, Brian L. Hoh<sup>2</sup>, J Duffy Mocco<sup>2</sup>, Jeffery Bennett<sup>3</sup> and Michael F. Waters<sup>1,4\*</sup>

<sup>1</sup>Departments of Neurology, University of Florida, College of Medicine, Gainesville, FL 32610

<sup>2</sup>Neurosurgery, University of Florida, College of Medicine, Gainesville, FL 32610

<sup>3</sup>Radiology, University of Florida, College of Medicine, Gainesville, FL 32610

<sup>4</sup>Neuroscience, University of Florida, College of Medicine, Gainesville, FL 32610

### Abstract

**Background and Purpose:** We present three patients with acute ischemic stroke who underwent computed tomography perfusion (CTP) imaging utilizing an Aquilion ONE (Toshiba Medical Systems, Nasu, Japan) 320-detector row CT scanner using a Singular Value Decomposition Plus (SVD+) algorithm to generate perfusion maps. These MTT maps may prove to be a sensitive and specific predictor of ischemic penumbra (IP) and infarct core (IC).

**Methods:** Patients, who presented with an acute ischemic stroke, received high quality whole-brain CTP scans and a follow up MRI or non-contrast CT (NCCT) scan, and underwent successful pharmacological and/or interventional reperfusion procedures were selected for evaluation. A neuroradiologist utilizing Vitrea FX 3.1 software reviewed images, and the IC volumes were calculated.

**Results:** A comparison was made between the volumes of infarct core utilizing SVD+ MTT maps and DWI MR sequences or a sub-acute NCCT. There was a correlation between the infarct core volume measured on MTT and final infarct volume on follow up imaging. However due to limitations associated with a small sample size, a statistical correlation cannot be definitively calculated from this data set.

**Conclusions:** Utilization of the SVD+ MTT map may allow for a more accurate assessment of the infarct core and surrounding salvageable tissue as compared to cerebral blood flow/cerebral blood volume (CBF/CBV) mismatch though further studies are required to validate this observation.

**Keywords:** Mean transit time; Ischemic penumbra; Infarct core; CT Perfusion; Singular Value Decomposition plus; Deconvolution; Interventional endovascular procedures

### Introduction

Ischemic penumbra (IP) was first proposed by Astrup in 1981 [1] referencing regions of brain tissue where blood flow is sufficiently reduced to result in hypoxia and dysfunction of physiologic function, but not severe enough to cause irreversible damage and necrosis in an acute ischemic stroke [2,3]. Identifying the mismatch between IC and IP allows the possibility of identifying patients who may have a higher likelihood of benefiting from aggressive interventional therapies. The current medical standard for rescue of the IP is intravenously administered tissue plasminogen activator within 4.5 hours of symptom onset. Select studies have suggested that systemic thrombolysis is safe up to 9 hours postictus [4,8]. Further, new advances in interventional procedures such as Penumbra and Merci have expanded the time window for acute stroke treatment. Recently, CTP has become more available in emergency rooms for assessment of IC and IP [9]. Studies utilizing older, primarily 64-multi-detector dynamic CT scanner (MDCT), CT perfusion have defined IP as the area of brain with diminished CBF but normal or increased CBV [10-12]. IC has been defined as the region with CBV less than 2mL/100g brain tissue with the IP considered the surrounding tissue with a greater than 145% decrement in CBF and increased mean transit time as compared to the contralateral hemisphere [13,14]. Until recently, CTP was confined to imaging discreet tissue slices. However, introduction of the Aquilion ONE has changed the dynamics of perfusion scanning permitting imaging of the entire brain with isophasic and physiologic

uniformity. It utilizes whole head volumetric coverage and delay insensitive SVD+ brain perfusion software allowing for more accurate and complete analysis of cerebral perfusion. MTT maps have become more reactive to flow changes with the introduction of the SVD+ perfusion algorithm. We have observed that areas of decreased mean transit time on MTT maps correlate with areas of restricted diffusion on MR imaging.

### Materials and Methods

We selected three acute, large vessel stroke patients presenting to the emergency department between the dates of November 2010 and May 2011 who: 1) experienced a unilateral large vessel stroke, 2) underwent both whole-brain CTP as part of our acute stroke protocol and a follow up MRI or NCCT scan as a part of their standard work up all of technically adequate quality, and 3) had successful pharmacological

\*Corresponding author: Michael F. Waters, MD, PhD, Departments of Neurology and Neuroscience, University of Florida College of Medicine, HSC Box 100236 Gainesville, FL, E-mail: mwaters@neurology.ufl.edu

Received June 15, 2011; Accepted July 20, 2011; Published July 28, 2011

**Citation:** Dababneh H, Guerrero W, Wilson K, Hoh BL, Mocco JD, et al. (2011) Observation of Mean Transit Time (Mtt) Perfusion Maps on a 320-Detector Row Ct Scanner and its Potential Application in Acute Ischemic Stroke. J Neurol Neurophysiol 2:115. doi:10.4172/2155-9562.1000115

**Copyright:** © 2011 Dababneh H, et al. This is an open-access article distributed under the terms of the Creative Commons Attribution License, which permits unrestricted use, distribution, and reproduction in any medium, provided the original author and source are credited.

**Citation:** Dababneh H, Guerrero W, Wilson K, Hoh BL, Mocco JD, et al. (2011) Observation of Mean Transit Time (Mtt) Perfusion Maps on a 320-Detector Row Ct Scanner and its Potential Application in Acute Ischemic Stroke. *J Neurol Neurophysiol* 2:115. doi:10.4172/2155-9562.1000115

and/or interventional reperfusion procedures. None of the patients had evidence of hemorrhage on initial or follow-up non-contrast CT. (Table 1) provides detailed summaries of patient demographics. Images were reviewed by a neuroradiologist utilizing Vitrea FX 3.1 (Vital, Toshiba America Medical System) software including CTP, MRI, and NCCT. 5mm slices were evaluated. The time to peak (TTP) was first used to identify areas of brain tissue with delayed perfusion. In our experience, the average value of MTT in the presumed infarct core is less than 3 seconds. This value was chosen to select the presumed infarct core area on each slice within the corresponding area of increased TTP. Vitrea FX 3.1 calculated the area for each slice based on our selection of decreased MTT. The MTT volume was calculated by adding all the areas multiplied by the thickness of each slice. For comparison to final infarct, areas with hyperintense signal on diffusion weighted MRI were selected. The area for each slice was measured, then the total volume of diffusion abnormality was calculated by adding all the areas multiplied by the total thickness of each slice. For the NCCT, the neuroradiologist chose the region of hypodensity believed to represent the infarct core. Then the area of hypodensity was calculated and the total volume was obtained by calculating the area of each slice multiplied by its thickness.

**Mr image acquisition**

MR imaging was performed on either a 1.5 or 3 Tesla (Siemens, USA) whole-body scanner with echo planar capabilities. Diffusion weighted images were obtained using single-shot, spin echo echoplanar imaging with sampling of the entire diffusion tensor. Three high b-value images corresponding to diffusion measurements in different gradient directions were acquired. Double inversion pulses were used to help reduce eddy current effects. The high b-value was 1000 sec/mm<sup>2</sup> and the low b-value was 0 sec/mm<sup>2</sup>. A repetition time of 7300mS was used. The echo time for each scan was 89mS. Other parameters were FoV (field of view) read of 200mm, image matrix of 1.5x1.5 voxels, slice thickness of 4 mm with 1mm gap, and 2 signals averaging. Isotropic DWI images were reviewed.

**Ct perfusion acquisition**

The CTP study was performed using the Aquilion ONE. Image acquisition was performed as a dynamic contrast material enhanced scan covering the entire brain with 0.5mm section thickness, 512x512 matrix, and 160mm axial field of view. Omnipaque (50 ml, Iohexol 350, GE healthcare, Shanghai, China) was injected by a power injector at a flow rate of 5 mL/s. Contrast material was injected 7 seconds prior to the start of the dynamic scan. The scanning protocol was: first scan at 7 seconds, followed by continuous intermittent scans at 2-second intervals beginning at 11 seconds. Scans were performed before contrast material bolus arrival (80 kV tube voltage, 150 mA tube current). During the expected period of arterial peak between 18-28 seconds, tube current was increased (80 kV tube voltage, 300 mA

tube current). Arterial phase scanning ceased at 36 seconds. During the venous phase, intermittent scans were performed every 5 seconds starting at 40 seconds and ending at 60 seconds (80 kV tube voltage, 150 mA tube current). The scanning speed was 1 second per rotation, and total scanning time was 60 seconds. CT dose index (CTDI) and dose length product (DLP) [15] data were collected from the console for each scan. Effective dose was estimated for each patient by multiplying the DLP by a region specific dose conversion factor for adult head of 0.0021 mSv•mGy<sup>-1</sup>•cm<sup>-1</sup> [16]. Computed tomography perfusion data were analysed using Vitrea FX 3.1. A region of interest (ROI) of the arterial input function (AIF) was automatically applied on a single branch of the insular segment of the middle cerebral artery (MCA) at the side contralateral to the affected hemisphere. An ROI of the venous output function was also established on the superior sagittal sinus. To minimize the conspicuity of vasculature, vascular-pixel elimination (VPE) was applied to dynamic CT images before smoothing and subsequent deconvolution analysis. The MTT was calculated after determination of residue function using the delay-compensated SVD+, which is theoretically delay-insensitive and equal to the block-circulant SVD method. CBV values were obtained by dividing the area under the curve of the brain tissue by the area under the curve of the venous output function after automatic pixel-by-pixel determination of the start point and discard of the second bolus. Subsequently, CBF values were calculated by dividing the CBV by the MTT in accordance to the central volume principle.

**Results**

All patients in this study were imaged using the same acquisition protocol and thus the reported dose was equivalent. CTDI for each of the 19 intermittent gantry rotations was 16mGy leading to a cumulative CTDI of 239.7mGy for each patient. Effective dose for each patient was estimated to be 8mSv.

Imaging of patient 1 revealed a left M1 segmental thrombosis. Whole brain perfusion studies revealed an increased TTP in the entire left MCA distribution. MTT was also elevated in the majority of the left MCA territory indicating a large area of potential ischemic penumbra (Figure 1). Re-canalization of the left MCA thrombus was established with Penumbra retrieval device (Penumbra Inc., Alameda, CA, USA). Patient underwent a NCCT of the head 6 days later, which revealed infarct in the area of decreased MTT on initial perfusion studies (Figure 2).

Imaging of patient 2 demonstrated an abrupt cut-off of the right P1 segment of the PCA. Patient received systemic thrombolysis. Follow-up brain MRI (Figure 3A) showed a right PCA infarct, which matched the area of decreased MTT on CT perfusion (Figure 3B).

Imaging of patient 3 revealed an intraluminal clot in the right MCA. MTT was principally increased in the right MCA territory consistent

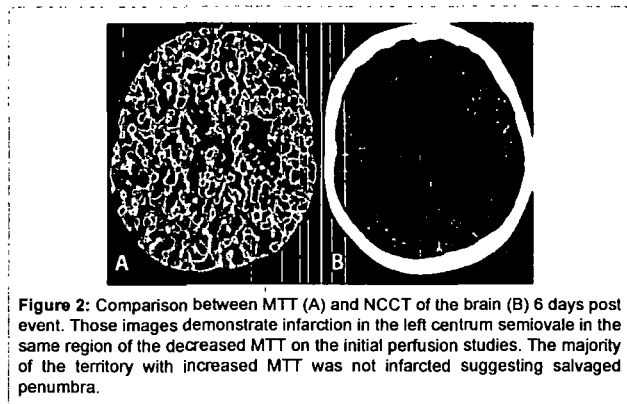
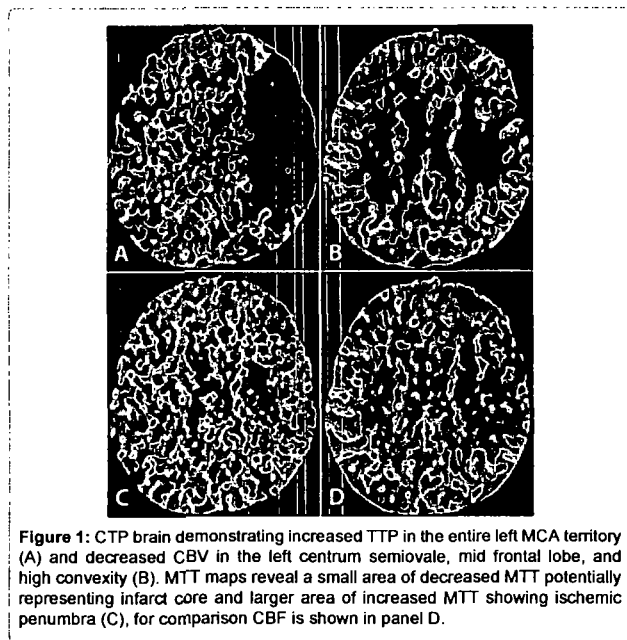
Patient	Age	Gender	Onset to imaging	Admission NIHSS	t-PA	Mechanical recanalization	Recanalization at 24 hours
1	65	F	Unknown	20	No	Yes	Complete
2	76	M	<2 hours	7	Yes	No	Partial
3	10	F	<1 hour	15	Yes	Yes	Complete

Table 1: Summary of patient information.

Patient	MTT value (seconds)	MTT infarct core volume (cm <sup>3</sup> )	CT infarct core volume (cm <sup>3</sup> )	HU	MRI infarct core volume (cm <sup>3</sup> )	MTT infarct volume as % of final
1	2.91	16.75	16.33	19.97	N/A	102
2	2.78	32.7	36.17	22.18	41.2	79
3	2.49	4.55	N/A	N/A	5.76	79

Table 2: Comparison of MTT infarct volume with follow up imaging.

**Citation:** Dababneh H, Guerrero W, Wilson K, Hoh BL, Mocco JD, et al. (2011) Observation of Mean Transit Time (Mtt) Perfusion Maps on a 320-Detector Row Ct Scanner and its Potential Application in Acute Ischemic Stroke. *J Neurol Neurophysiol* 2:115. doi:10.4172/2155-9562.1000115

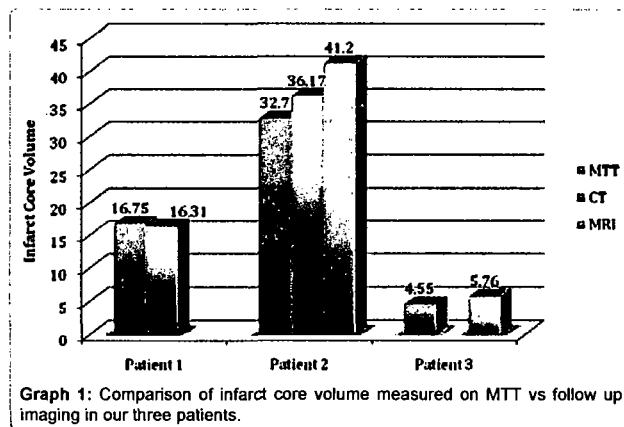
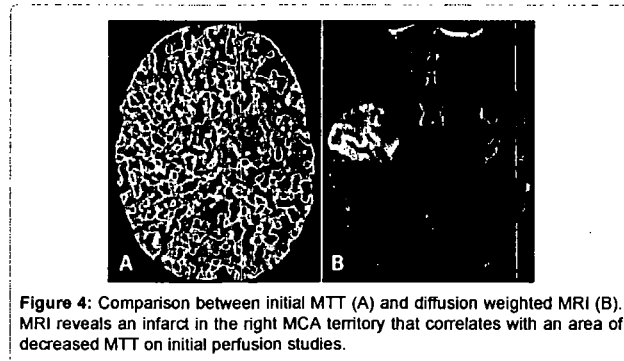
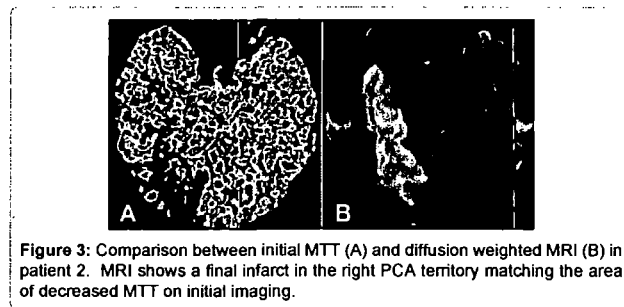


with ischemic penumbra, though there was a smaller area of decreased MTT suggestive of infarct core. Patient received systemic thrombolysis and re-canalization with Penumbra retrieval device. Follow up MRI examination (Figure 4A) revealed a correlation between the area of decreased MTT on the perfusion study and DWI hyperintensity on MR imaging (Figure 4B).

The mean MTT value for infarcted tissue was 2.72 seconds. For patient 1, the volume of infarct on MTT was 102% of the volume of infarct on follow-up NCCT. Images for patient 2 demonstrated a volume of infarct on MTT that was approximately 90% of the total infarct volume observed on follow-up CT and 79% as detected on diffusion weighted MRI. Similarly, patient 3 had a volume of infarct on MTT which was 79% of the infarcted volume observed on follow-up diffusion weighed MRI. The mean MTT lesion volume was 18 cm<sup>3</sup>. Using CT for patient 1 and diffusion MRI for patients 2 and 3, the mean infarct volume on follow-up imaging was determined to be 21 cm<sup>3</sup>. Thus, the MTT infarct core volume represented 85% of the final infarct volume on follow-up imaging (Table 2 & Graph 1).

**Discussion**

To our knowledge, studies assessing the efficacy of MTT maps in determination of IC or IP on Aquilion ONE utilizing SVD+ perfusion algorithm have not been published. We have observed that with this technology, MTT maps appear to identify both IC and IP in the evaluation of acute large vessel strokes. However, this observation requires further validation. When evaluating imaging studies in these cases it was noted that the area of final infarct on follow-up corresponded to decreased MTT on the acute CTP study, whereas areas immediately surrounding the presumed infarct core demonstrated increased MTT. The areas delineated by increased MTT may represent the ischemic penumbra. There was consistent overlap between the infarct core volume measured on MTT and final infarct volume on follow up imaging. However, due to small sample size, a statistical correlation could not be definitively calculated.



**Citation:** Dababneh H, Guerrero W, Wilson K, Hoh BL, Mocco JD, et al. (2011) Observation of Mean Transit Time (Mtt) Perfusion Maps on a 320-Detector Row Ct Scanner and its Potential Application in Acute Ischemic Stroke. *J Neurol Neurophysiol* 2:115. doi:10.4172/2155-9562.1000115

In the evaluation of patients with acute stroke, discriminating IC from IP is of critical importance for differentiating patients who may benefit from revascularization from those who are at high risk for hemorrhagic complications or may not benefit from aggressive intervention. The ischemic penumbra is the area surrounding the infarct core that is physiologically stunned, but potentially salvageable whereas tissue within the infarct core displays necrosis of neuronal and glial elements secondary to severe hypoperfusion at <10-12 ml/100g/min. Tissue within the surrounding ischemic penumbra while still hypoperfused at approximately 50-60 ml/100 g/min, remains viable if reperfused [17]. The salvagability of tissue in the ischemic penumbra is secondary to the preservation of autoregulatory mechanisms i.e. vasodilatation and collateral flow. When this vasodilatation occurs there is a decrease in velocity across the capillary bed [18]. Inversely, in the infarct core there is capillary lumen obstruction resulting in a relative vasoconstriction [19]. Cells within the ischemic region of dysfunctional yet potentially salvageable tissue are the target of thrombolytic therapy [20-22].

According to literature describing previous MDCT scanners, MTT maps were found to be a more reliable predictor of ischemia than CBF because the MTT values of normal gray and white matter are not significantly different as they are for CBF [14]. However, Wintermark et al, reported that CBF is more specific than MTT in ischemic stroke because MTT values can be prolonged in TIA as well as stroke [23]. Furthermore, various other reports have stated that although MTT is the most sensitive marker for early ischemic lesion, it cannot differentiate between infarct core and ischemic penumbra [24]. Currently the most widely accepted technique for the evaluation of IC and IP on CTP is assessment of CBF/CBV mismatch, where penumbra is defined as the area of decreased CBF but relatively preserved CBV [13,14].

The ability of the MTT maps to detect and accurately display alterations in MTT (i.e. infarct core or penumbra) is both a product of the Aquilion ONE itself and the deconvolution SVD+ algorithm it utilizes to calculate the perfusion maps. SVD+ is a delay insensitive algorithm that uses calculations to account for delayed blood flow, minimize noise, and perform calculations with fast computation, thus ensuring delay insensitivity of MTT. With a single arterial input, each part of the brain will have a different delay due to its distance from the arterial input. This delay using the standard SVD algorithms can potentially display normal brain as having prolonged MTT values at points far from the input [25]. Other sources of delay may be abnormal vasculature or collateral vasculature. This results in MTT maps displaying delayed flow as opposed to reduced travel time through brain tissue. With SVD+, the sensitivity of the MTT map to ischemia is visible in the TTP and delay maps whereas the MTT map is reserved for the capillary velocity [22]. The sensitivity to delayed flow is measured in the TTP and delay maps, thus ensuring that MTT actually represents the time travel through the capillaries (capillary velocity) and not delayed flow [25].

This pilot study demonstrates that MTT maps on the Aquilion ONE 320 detector row CT scanner using SVD+ algorithm software may be useful in differentiating IC from IP. This study is limited by several factors including: 1) CTP and follow-up scans were separated in time and thus susceptible to dynamic changes in the vascular response to ischemia. This may have altered the size of the IC more substantially than what was seen on follow up imaging. The time lag between initial and follow up imaging may have accounted for the volume difference between average MTT and average final infarct volume. This may be overcome in a prospective study in which patients receive an MRI immediately following CTP. 2) Small sample size with an insufficient

quantity of patients to statistically support our observation. 3) Definition of IC has yet to be systematically delineated and proven. Based on our observations, an MTT of less than 3 seconds was selected as an indication of IC. In this study, the approximate value for infarct core on MTT was 2.72. This cannot be ideally defined in this study and would require a prospective study to further validate. 4) Resolution of CT images limits exact delineation of IC borders. This can be seen with patient 2 above; infarct core on MTT is judged to be slightly larger than on follow up NCCT.

## Conclusion

We believe that the MTT maps produced by the Aquilion ONE 320 detector row CT scanner and calculated with SVD+ algorithm may be a sensitive and specific marker for capillary velocity in acute stroke. Thus, in IC where capillary velocity is increased there is a corresponding decrease in the MTT. In IP where capillary velocity is decreased the MTT is increased. If this observation holds true in further studies, MTT maps generated in this fashion may prove to be a valuable imaging modality in differentiating between penumbra and infarct core, potentially allowing for greater extension of the thrombolytic treatment window in instances when the IC remains relatively small in the presence of a large IP. This would be particularly valuable in identifying salvageable brain tissue in patients with unknown time of symptom onset where brain physiology may be more valuable criteria than the clock in treatment decision making.

## Acknowledgements

The authors thank Dr. Erin Angel (Toshiba America Medical Systems, USA), who provided support with regard to the technical terms related to the scanning system.

## References

1. Astrup J, Siesjo BK, Symon L (1981) Thresholds in cerebral ischemia – the ischemic penumbra. *Stroke* 12: 723–725.
2. Hossmann KA (1994) Viability thresholds and the penumbra of focal ischemia. *Ann Neurol* 36: 557–565.
3. Ginsberg MD (2003) Adventures in the pathophysiology of brain ischemia: penumbra, gene expression, neuroprotection: the 2002 Thomas Willis Lecture. *Stroke* 34: 214–223.
4. Hacke W, Albers G, Al-Rawi Y, Bogousslavsky J, Davalos A, et al. (2005) The Desmoteplase in Acute Ischemic Stroke Trial (DIAS): a phase II MRI-based 9-hour window acute stroke thrombolysis trial with intravenous desmoteplase. *Stroke* 36: 66–73.
5. Furlan AJ, Eyding D, Albers GW, Al-Rawi Y, Lees KR, et al. (2006) Dose Escalation of Desmoteplase for Acute Ischemic Stroke (DEDAS): evidence of safety and efficacy 3 to 9 hours after stroke onset. *Stroke* 37: 1227–1231.
6. Albers GW, Thijs VN, Wechsler L, Kemp S, Schlaug G, et al. (2006) Magnetic resonance imaging profiles predict clinical response to early reperfusion: the diffusion and perfusion imaging evaluation for understanding stroke evolution (DEFUSE) study. *Ann Neurol* 60: 508–517.
7. Thomalla G, Schwark C, Sobesky J, Bluhmki E, Fiebach JB, et al. (2006) Outcome and symptomatic bleeding complications of intravenous thrombolysis within 6 hours in MRI- selected stroke patients: comparison of a German multicenter study with the pooled data of ATLANTIS, ECASS, and NINDS tPA trials. *Stroke* 37: 852–858.
8. Kohrmann M, Juttler E, Fiebach JB, Huttner HB, Siebert S, et al. (2006) MRI versus CT-based thrombolysis treatment within and beyond the 3 h time window after stroke onset: a cohort study. *Lancet Neurol* 5: 661–667.
9. Wintermark M, Bogousslavsky J (2003) Imaging of acute ischemic brain injury: the return of computed tomography. *Curr Opin Neurol* 16: 59–63.
10. Muir K, Baird-Gunning J, Walker L, Baird T, McCormick M (2007) Coultts S. Can the ischemic penumbra be identified on noncontrast CT of acute stroke. *Stroke* 38: 2485–2490.

**Citation:** Dababneh H, Guerrero W, Wilson K, Hoh BL, Mocco JD, et al. (2011) Observation of Mean Transit Time (Mtt) Perfusion Maps on a 320-Detector Row Ct Scanner and its Potential Application in Acute Ischemic Stroke. *J Neurol Neurophysiol* 2:115. doi:10.4172/2155-9562.1000115

11. Parsons MW, Pepper EM, Bateman GA, Wang Y, Levi CR (2007) Identification of the penumbra and infarct core on hyperacutenoncontrast and perfusion CT. *Neurology* 68: 730–736.
12. Soares BP, Dankbaar JW, Bredno J, Cheng S, Bhogal S, et al. (2009) Automated versus manual post-processing of perfusion-CT data in patients with acute cerebral ischemia: influence on interobserver variability. *Neuroradiology* 51: 445–451.
13. Tan JC, Dillon WP, Liu S, Adler F, Smith WS et al. (2007) Systematic comparison of perfusion-CT and CT-angiography in acute stroke patients. *Ann Neurol* 61: 533–543.
14. Wintermark M, Flanders AE, Velthuis B, Meuli R, Leeuwen MV, et al. (2006) Perfusion-CT assessment of infarct core and penumbra: receiver operating characteristic curve analysis in 130 patients suspected of acute hemispheric stroke. *Stroke* 37: 979–985.
15. International Electrotechnical Commission (2009) Medical electrical equipment: particular requirements for the basic safety and essential performance of x-ray equipment for computed tomography. International Standard IEC, Geneva, Switzerland.
16. McCollough C, Cody D, Edyvean S, Geise R, Gould B, Keat N, et al. (2008) The Measurement, Reporting, and Management of Radiation Dose in CT, Report of AAPM Task Group 23: CT Dosimetry, AAPM.
17. Deb P, Sharma S, Hassan KM (2010) Pathophysiologic mechanisms of acute ischemic stroke: An overview. *Pathophysiology* 17: 197-218.
18. Moncada S, Radomski MW, Palmer RMJ (1998) Endothelium-derived relaxing factor: identification as nitric oxide and role in the control of vascular tone and platelet function. *BiochemPharmacol* 37: 2495–2502.
19. Mori E, del Zoppo GJ, Chambers JD, Copeland BR, Arfors KE (1992) Inhibition of polymorphonuclear leukocyte adherence suppresses no-reflow after focal cerebral ischemia in baboons. *Stroke* 23: 712-718.
20. Hakim AM (1998) Ischemic penumbra—the therapeutic window. *Neurology* 51: S44–S46.
21. Warach S, Latour LL (2004) Evidence of reperfusion injury, exacerbated by thrombolytic therapy, in human focal brain ischemia using a novel imaging marker of early blood-brain barrier disruption. *Stroke* 11: 2659–2661.
22. Ebinger M, De Silva DA, Christensen S, Parsons MW, Markus R, et al. (2009) Imaging the penumbra—strategies to detect tissue at risk after ischemic stroke. *J ClinNeurosci* 16: 178–187.
23. Wintermark M, Fischbein NJ, Smith WS, Ko NU, Quist M, et al. (2005) Accuracy of dynamic perfusion CT with deconvolution in detecting acute hemispheric stroke. *AJNR* 26:104–112.
24. Sun Z, Zhang X, Zhang Y, Guo H, Zhang J, et al. (2010) Estimation of the ischemic penumbra based on CT perfusion a pilot study. *AcadRadiol* 12:1535-1542.
25. Angel E (2010) SVD+ Dynamic Volume CT: Delay insensitive Brain Perfusion Analysis. White Paper Toshiba America Medical Systems, Inc.

**Submit your next manuscript and get advantages of OMICS Group submissions**

**Unique features:**

- User friendly/feasible website-transition of your paper to 50 world's leading languages
- Audio Version of published paper
- Digital articles to share and explore

**Special features:**

- 100 Open Access Journals
- 10,000 editorial team
- 21 days rapid review process
- Quality and quick editorial, review and publication processing
- Indexing at PubMed (partial), Scopus, DOAJ, EBSCO, Index Copernicus and Google Scholar etc
- Sharing Option: Social Networking Enabled
- Authors, Reviewers and Editors rewarded with online Scientific Credits
- Better discount for your subsequent articles

Submit your manuscript at <http://www.omicsonline.org/submission>



U.S. Food & Drug Administration  
Center for Devices and Radiological Controls  
10155  
10155

**Paper-3:**

**Chaudhry SA, Miley JT, Khatri R, Hassan SA, et al. : Microcatheter to recanalization (procedure time) predicts outcomes in endovascular treatment in patients with acute ischemic stroke: when do we stop? *AJNR Am J Neuroradiol.* 2012 Jul 19**

# Microcatheter to Recanalization (Procedure Time) Predicts Outcomes in Endovascular Treatment in Patients with Acute Ischemic Stroke: When Do We Stop?

## ORIGINAL RESEARCH

A.E. Hassan  
S.A. Chaudhry  
J.T. Miley  
R. Khatri  
S.A. Hassan  
M.F.K. Suri  
A.I. Qureshi



**BACKGROUND AND PURPOSE:** Endovascular treatment for acute ischemic stroke consists of various mechanical and pharmacologic modalities used for recanalization of arterial occlusions. We performed this study to determine the relationship among procedure time, recanalization, and clinical outcomes in patients with acute ischemic stroke undergoing endovascular treatment.

**MATERIALS AND METHODS:** We analyzed data from consecutive patients with acute ischemic stroke who underwent endovascular treatment during a 6-year period. Demographic characteristics, NIHSS score before and 24 hours after the procedure, and discharge mRS score were ascertained. Procedure time was defined by the time interval between microcatheter placement and recanalization or completion of the procedure. We estimated the procedure time after which favorable clinical outcome was unlikely, even after adjustment for age, time from symptom onset, and admission NIHSS scores.

**RESULTS:** We analyzed 209 patients undergoing endovascular treatment (mean age, 65 ± 16 years; 109 [52%] men; mean admission/preprocedural NIHSS score, 15.3 ± 6.8). Complete or partial recanalization was observed in 176 (84.2%) patients, while unfavorable outcome (mRS 3–6) was observed in 138 (66%) patients at discharge. In univariate analysis, patients with procedure time ≤30 minutes had lower rates of unfavorable outcome at discharge compared with patients with procedure time ≥30 minutes (52.3% versus 72.2%, *P* = .0049). In our analysis, the rates of favorable outcomes in endovascularly treated patients after 60 minutes were lower than rates observed with placebo treatment in the Prourokinase for Acute Ischemic Stroke Trial. In logistic regression analysis, unfavorable outcome was positively associated with age (*P* = .0012), admission NIHSS strata (*P* = .0017), and longer procedure times (*P* = .0379).

**CONCLUSIONS:** Procedure time in patients with acute ischemic stroke appears to be a critical determinant of outcomes following endovascular treatment. This highlights the need for procedure time guidelines for patients being considered for endovascular treatment in acute ischemic stroke.

**ABBREVIATIONS:** CI = confidence interval; ICH = intracerebral hemorrhage; mRS = modified Rankin Scale; OR = odds ratio; PROACT = Prourokinase for Acute Ischemic Stroke Trial.

INTERVENTIONAL ORIGINAL RESEARCH

The Brain Attack Coalition guidelines require a stroke team member at the patient's bedside within 15 minutes, initial head CT scan performed and interpreted in <45 minutes, and IV rtPA given within 60 minutes of arrival.<sup>1,2</sup> Although endovascular treatment is a widely used option for recanalization in patients not eligible for IV rtPA, there are limited data and no current performance guidelines for endovascular treatment of acute ischemic stroke. The only recommendation states that

personnel responsible for conventional angiography must arrive at the institution within 60 minutes of being notified.<sup>1-3</sup>

Recent studies have introduced the idea of "futile recanalization" after endovascular treatment of acute ischemic stroke, defined as recanalization with no improvement in outcome.<sup>4</sup> Since then, greater emphasis has been placed on reducing the time delays in endovascular treatment to reduce the rate of futile recanalization with particular emphasis on "time to microcatheter." A recently published study identified a wide variability in time to microcatheter and delay among different institutions and concluded that there needs to be time recommendations for comprehensive stroke centers to improve acute stroke outcomes.<sup>5</sup> However, the study was unable to demonstrate a relationship between the time interval between symptom onset and microcatheter placement and clinical outcomes. After a microcatheter is placed in a thrombus, the recanalization time varies considerably, but the clinical significance of such variations remains unclear. However, the current and proposed guidelines do not recognize the significance of the procedure time incurred after "time to microcatheter." The goal of our study was to determine the relationship of the time interval between microcatheter placement and recanalization (procedure time) and clinical outcomes among

Received January 8, 2012; accepted after revision April 3.

From the Zeenat Qureshi Stroke Research Center, University of Minnesota, Minneapolis, Minnesota.

All authors have read and approved submission of the manuscript.

This study was performed independent of any financial support. None of the authors have any conflict of interest or financial conflicts to disclose.

Dr Qureshi has received funding from National Institutes of Health RO-1-NS44976-01A2 (medication provided by ESP Pharma), the American Heart Association Established Investigator Award 0840053N, and the Minnesota Medical Foundation, Minneapolis, Minnesota.

Please address correspondence to Ameer E. Hassan, DO, Department of Neurology, Zeenat Qureshi Stroke Research Center, University of Minnesota, 12-100 PWB, 516 Delaware St SE, Minneapolis, MN 55455; e-mail: ameerhassan@gmail.com



Indicates open access to non-subscribers at www.ajnr.org



Indicates article with supplemental on-line tables.

<http://dx.doi.org/10.3174/ajnr.A3202>

patients with acute ischemic stroke undergoing endovascular treatment.

### Materials and Methods

A retrospective study of consecutive patients with acute ischemic stroke who underwent endovascular treatment was performed between January 1, 2007 to June 1, 2010 at the University of Minnesota and Hennepin County Medical Centers and from May 2005 to July 2007 at the University of Medicine and Dentistry of New Jersey. The 3 institutions maintained a prospective endovascular procedure data base, which records information regarding the procedural components, devices used, and intraprocedural medication with doses. The protocol for collecting data was reviewed and approved by the institutional review board at each institution as part of a standardized data base.

### Data Collected

We recorded the presence of cardiovascular risk factors (active smoking history, hypertension, atrial fibrillation, coronary artery disease, hyperlipidemia, diabetes mellitus, prior TIA or ischemic stroke, time interval between symptom onset and endovascular intervention, and use of IV rtPA). "Procedure time" was defined by the interval between the time of positioning the microcatheter proximal to the thrombus and the time to partial or complete recanalization (based on modified Thrombolysis in Myocardial Infarction 2 or 3) or procedure termination. The times were identified by 2 authors (A.E.H. and J.T.M.) individually reviewing the angiographic images and recording the times of microcatheter placement and recanalization or completion of the procedure. We also recorded admission, 24-hour posttreatment, and discharge NIHSS scores. Outcome at the time of discharge was assessed by using the mRS, ascertained from hospital discharge summaries by the vascular neurology team and occupational, speech, and physical therapists. The principal safety end points were ICH and in-hospital mortality. Symptomatic ICH was defined as noncontrast CT–documented ICH resulting in neurologic deterioration ( $\geq 4$ -point worsening on an NIHSS score compared with previous clinical assessment). Favorable functional outcome at discharge was defined by an mRS score of 0–2 at discharge.

### Technical Description for Endovascular Treatment

In a typical procedure, patients are brought to the neuroangiography room, and through a 6F introducer sheath in the common femoral artery, a 6F multipurpose device-guide catheter is advanced into the internal carotid artery or vertebral artery. Once the arterial occlusion is identified, a microcatheter ranging in diameter from 1.4F to 2.3F is advanced over a 0.014-inch microwire into the vessel of interest, in close proximity to the thrombus. At this given moment, arterial recanalization therapy is initiated. The techniques for endovascular treatment have been described in detail in previous publications.<sup>6–10</sup> Briefly, a combination of pharmacologic agents and/or mechanical thrombus disruption and/or retrieval is used in varying paradigms.

### Patient Selection

The patient-selection criteria for endovascular treatment are described in detail in previous publications.<sup>7,11,12</sup> Briefly, at the University of Medicine and Dentistry of New Jersey, all patients were selected for endovascular treatment on the basis of the time interval between symptom onset and emergency department presentation and the findings of noncontrast cranial CT scan. Patients with ICH or cerebral edema, sulcal effacement, and/or focal parenchymal hypoattenuation

exceeding one-third of the MCA vascular territory (in those presenting after 3 hours) were excluded. At the University of Minnesota and Hennepin County Medical Centers, the patients were selected on the basis of findings of CTA and CTP scans, in addition to the noncontrast CT. The CTP protocol follows the noncontrast cranial CT scan and is discontinued if ICH is identified. Maps obtained from data acquired by the Brilliance 64 (Philips Healthcare, Best, the Netherlands) were generated by using Vitrea software (Vital Images, Minnetonka, Minnesota), yielding the following perfusion parameters: time to peak, mean transit time, relative CBF, and relative CBV. In the case of an MCA vascular territory infarction, the patient was excluded from endovascular treatment if the infarct burden was greater than or equal to one-third of the vascular territory on qualitative analysis of the relative CBV map acquired from the CTP study.<sup>12</sup>

### Statistical Analysis

All data were presented by using mean  $\pm$  SD for continuous data and frequencies for categorical data. The frequency of baseline demographic and clinical characteristics, admission NIHSS score, time interval between symptom onset and endovascular treatment, and the interval between hospital presentation and endovascular treatment (time to microcatheter) were compared among patients with endovascularly treated acute ischemic stroke. We analyzed the effect of different time strata on discharge outcomes by using the receiver operating curve and goodness-of-fit model. We chose the smallest time interval that had an adequate number of patients resulting in a good precision estimate. We divided the patients into 2 strata based on endovascular procedure time of  $\leq 30$  and  $> 30$  minutes. The choice of 30 minutes as the cutoff for procedure time was also supported by visual analysis of scatterplots depicting recanalization response to incremental doses in 2 of our previous dose-escalating studies.<sup>13,14</sup> In both studies, at least half of the patients demonstrated partial or complete recanalization after administration of 4 doses of intra-arterial thrombolytics (each administered for 5 minutes) and 4 angiographic images obtained in the interim (estimated 10 minutes between each image). Therefore, there is reason to believe that 30 minutes is the earliest time to assess the procedural success.

We performed univariate analysis followed by a multivariate logistic regression model to determine the effect of procedure time on clinical outcomes at discharge. Statistical association was assessed with a *t* test or median 2-sample test according to normality for continuous data and the  $\chi^2$  test for categorical data. The rates of partial and complete angiographic recanalization, symptomatic and asymptomatic ICH, early neurologic improvement, favorable discharge outcome, and in-hospital mortality were compared between strata defined by procedure time. We performed multivariate logistic regression analysis, adjusting for admission NIHSS score, age, recanalization status, and the time interval between symptom onset and microcatheter placement, to determine the independent effect of procedure time strata and clinical outcomes. We estimated the procedure time after which favorable clinical outcome was unlikely (no greater than expected by the natural history of untreated ischemic stroke). Subsequently in a separate analysis, we compared rates of favorable outcome by using various cutoff values of total procedure time by using favorable rates observed in the placebo group in PROACT II as a reference as used in previous exploratory analysis (Mechanical Embolus Removal in Cerebral Ischemia trial).<sup>15</sup> Our goal was to identify a procedure time cutoff after which the rate of favorable outcomes is not greater than what could be expected with a placebo infusion via a microcatheter placed within the thrombus. A *P* value  $< .05$  was con-



**Table. Multivariate analysis determining the predictors of unfavorable outcome (mRS 3-6) among patients who underwent endovascular treatment<sup>a</sup>**

Variable	Odds Ratio (95% CI)	P Value for Trend
<b>Age</b>		
≤45 years	Reference	.0012
46-65 years	0.8 (0.3-2.6)	
>65 years	3.6 (1.2-11.3)	
<b>NIHSS score strata</b>		
0-9	Reference	.0017
10-19	3.3 (1.3-8.3)	
≥20	8.5 (2.6-28.2)	
<b>Total procedure time (min)</b>		
<30	Reference	.0379
31-60	1.3 (0.6-3.3)	
61-90	3.7 (1.1-12.6)	
>90	5.4 (1.4-20.9)	

<sup>a</sup> Model adjusts for time interval between symptom onset and microcatheter placement, and recanalization status

sidered significant. All analyses were performed by using SAS statistical software (SAS, Cary, North Carolina).

**Results**

We analyzed 209 patients who underwent endovascular treatment (mean age, 65 ± 16 years; 109 [52%] men; mean admission NIHSS score, 15.3 ± 6.8; and mean time to recanalization, 50 ± 33.5 minutes). Complete or partial recanalization was observed in 176 (84.2%) patients, while unfavorable outcome was observed in 138 (66%) patients at discharge. Mean time from symptom onset to microcatheter was 299 ± 110.9 minutes.

Patients with favorable outcome had a procedure time and average time from symptom onset to recanalization that was shorter compared with patients with unfavorable outcome (41.8 minutes versus 54.3 minutes, *P* = .0067 and 330.4 minutes versus 358.8 minutes, *P* = .3179, respectively). Patients who had a procedure within 30 minutes were less likely to be

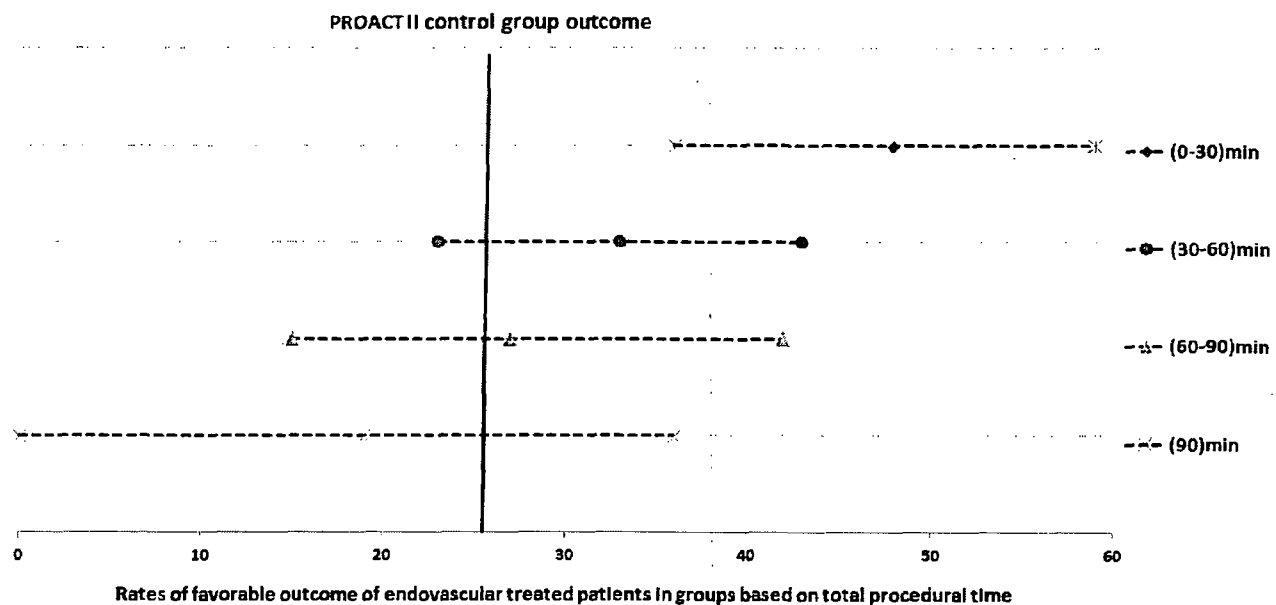
women compared with those patients with a time of >30 minutes (36.9% versus 52.7%, *P* = .03). In univariate analysis, there were no statistical differences for patients with a procedure time of ≤30 minutes and those with a time of >30 minutes in regard to demographics, time interval between symptom onset and start of procedure, location of arterial occlusion, and admission NIHSS score (Table 1). There was no statistical difference in the rate of symptomatic and asymptomatic ICHs between the 2 groups. Patients with procedure times of ≤30 minutes had a lower rate of unfavorable outcome at discharge, defined by an mRS ≥3 compared with patients with a procedure time of ≥30 minutes (52.3% versus 72.2%, *P* = .0049).

After we adjusted for age, admission NIHSS score, recanalization status, and time interval between the onset of symptoms and microcatheter placement, the longer procedure times of 61-90 minutes (OR, 3.7; 95% CI, 1.1-12.6) and >90 minutes (OR, 5.4; 95% CI, 1.4-20.9) were associated with higher rates of unfavorable outcome compared with microcatheter-to-recanalization time of ≤30 minutes with a *P* value for trend (*P* = .0379) (Table). Increased age (*P* = .0012) and NIHSS score (*P* = .0017) at admission were independent predictors of unfavorable outcome.

In our analysis, favorable outcomes in endovascularly treated patients after 60 minutes were comparable with those in the PROACT-II control group (Fig 1). To explore the relationship between clinical outcome recanalization, and time, we plotted the rate of angiographic recanalization and time strata (Fig 2), and plotted the unfavorable outcomes and time strata (Fig 3). The rate of unfavorable outcome was much higher in the 60-90 and >90 minute strata.

**Discussion**

This study highlights the relationship between microcatheter placement and recanalization (procedure time) and clinical outcomes among patients with acute ischemic stroke undergoing endovascular treatment. To our knowledge, procedure



**Fig 1.** Rates of favorable outcome of endovascularly treated patients in groups based on total procedure time in comparison with rates observed in placebo-treated PROACT II patients.

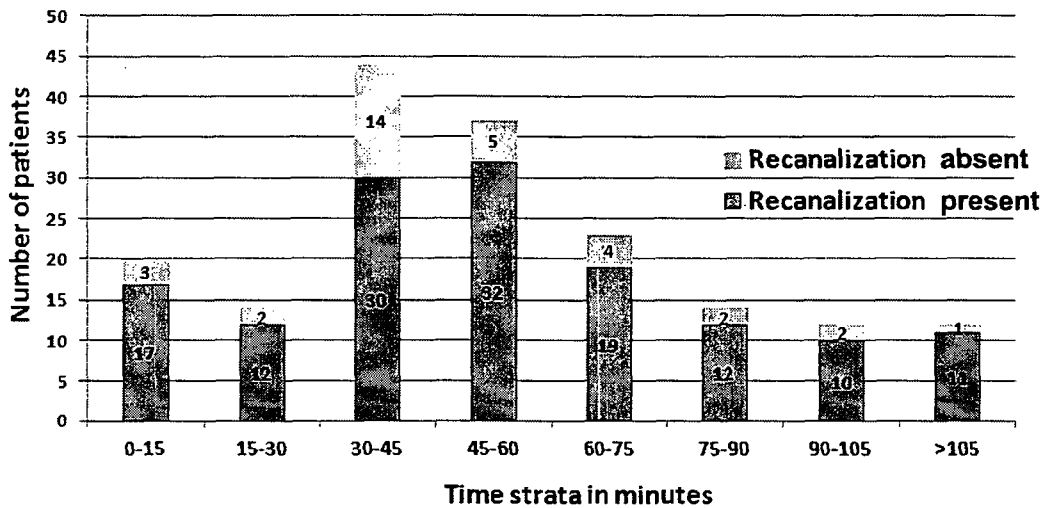


Fig 2. Rates of angiographic recanalization in endovascularly treated patients in groups based on total procedure time.

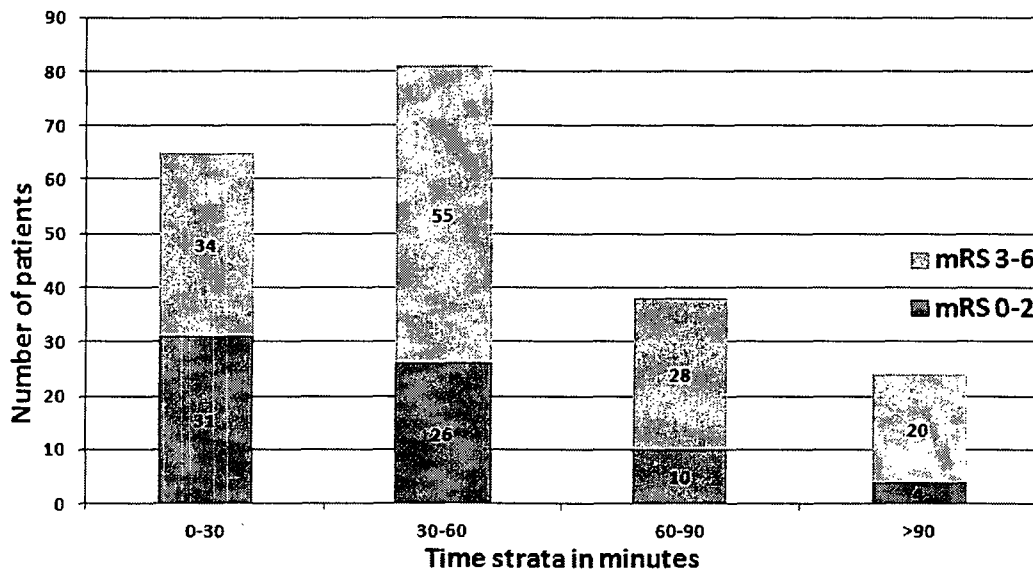


Fig 3. The relationship between the endovascular procedure time and clinical outcome at discharge.

time (as defined by time from microcatheter to recanalization/procedure completion) had not been previously studied. Procedure time in patients undergoing endovascular treatment demonstrates considerable variation within procedures, and such variations directly impact clinical outcome.

There are multiple factors that determine the outcome of endovascular treatment in patients with acute ischemic stroke. Previous studies have focused heavily on achieving recanalization and using recanalization as a measure of treatment success.<sup>4</sup> However, the recognition of futile recanalization has shifted the focus of treatment to time-efficient protocol implementation. In a recently published multicenter study of consecutive patients with acute ischemic stroke who underwent endovascular treatment, the authors compared the clinical outcomes based on recanalization.<sup>4</sup> A large proportion (49%) of patients who had successful recanalization did not achieve favorable outcomes, presumably due to irreversible ischemic injury not detected by noncontrast CT scan. Presumably, early recanalization by reducing the delays in treat-

ment could reduce the rate of futile recanalization. The Interventional Management of Stroke investigators found that time to angiographic reperfusion and age predicted good clinical outcome in those patients who had angiographic reperfusion.<sup>16</sup> The probability of good clinical outcome decreased as the time to reperfusion increased and then approached that of patients without angiographic reperfusion. After analyzing our data and adjusting for age, NIHSS score, and time interval between onset and microcatheter placement, we found that procedure time was still a predictor of unfavorable outcome in patients who had recanalization.

In the acute ischemic stroke setting, centers follow the Brain Attack Coalition guidelines for time-efficient administration of IV rtPA. Stroke centers continuously monitor door to CT scan and door to needle as quality parameters and implement strategies to improve performance. In theory, the same principles should apply to endovascular treatment. However, the basic elements necessary for recognition and improvement have not been identified either through the con-

sensus of experts or clinical studies. The comprehensive stroke center metrics<sup>17</sup> identify “time to microcatheter” as a recommended metric to monitor but did not specify the thresholds for acceptable performance. The selection of time to microcatheter was based on a similar performance metric, “door to balloon,” in patients with acute myocardial infarction. The American College of Cardiology and the American Heart Association guidelines for the management of ST-elevation myocardial infarction state that percutaneous coronary intervention should be performed as quickly as possible, preferably within 90 minutes from the moment of first medical contact.<sup>18</sup> Although there are similarities between stroke and myocardial infarction treatment, procedure times in stroke have much larger variations due to considerable variability in tortuosity, vessel location, and the nature of the occlusion.<sup>14,16</sup> Such variability in procedure time in patients with acute stroke, unlike those with myocardial infarction, increases the likelihood of a prominent relationship to outcomes.

The effect of shorter procedure time on patient clinical outcome is provocative, but it needs to be interpreted with caution. Although we found that 42 minutes was our mean procedure time in patients with favorable outcomes, the evidence does not support aborting procedures after that timeframe. Every endovascular procedure needs to be looked at individually, incorporating patient- and treatment-related factors in the decision-making. Centers should begin monitoring procedure times, and guidelines need to be provided to standardize treatment protocols if procedure time exceeds 60 minutes. Endovascular treatments that might restore blood flow more rapidly, such as mechanical intervention, flow-diversion devices, or the combination of thrombolytics, should be incorporated into treatment paradigms. However, aggressive manipulation may lead to unfortunate complications including dissection, perforation,<sup>19</sup> vessel rupture,<sup>20</sup> and conversion of distal emboli to more proximal larger artery occlusions.<sup>21</sup> There have been discussions about procedure time as a marker of extensive occlusions, but studies have shown that clot volume in acute ischemic stroke is not related to recanalization.<sup>20-22</sup>

The retrospective nonrandomized nature of the study is a limitation. IV rtPA was not withheld in any patients, consistent with current guidelines. There are limitations to the use of the NIHSS score and mRS in describing patient deficits and disabilities. The NIHSS score, in particular, provides limited information in patients with deficits referable to the posterior circulation. The bias introduced may be more pronounced in our and other studies that include posterior circulation ischemic events unlike studies such as PROACT I and II, which only included patients with anterior circulation ischemic events.<sup>15</sup> There are also differences in time points of mRS ascertainment. Comparison of outcomes between our study and placebo-treated patients in the PROACT trial may be further limited by improvements in poststroke medical management since PROACT II was completed. Therefore, the comparison between the findings of our study and PROACT II is only exploratory. Prestroke mRS or NIHSS scores were not documented consistently, potentially undermining the benefit of treatment among patients with prestroke neurologic deficits by inclusion of patients with pre-existing disability and poor mRS scores.<sup>3-5</sup> We used mRS and NIHSS scores that were doc-

umented for 7 days or at discharge but did not have 3-month functional outcomes or mortality rates. Broderick et al<sup>23</sup> found that a given level or amount of change in the NIHSS score during the first 24 hours and the NIHSS score at 7–10 days following treatment was the most sensitive measure for detecting differences in the effectiveness of thrombolytic treatment during the first 3 months after an ischemic stroke. The prognostic value of 24-hour and 7-day data in that analysis validates the outcomes used in our study.

## Conclusions

Our observations highlight the need for specific time guidelines to reduce the delays in endovascular treatment among patients with acute ischemic stroke. Procedure time in patients undergoing endovascular treatment for acute ischemic stroke appears to be a critical determinant of outcomes following treatment. Although we recommend procedure times of <60 minutes, every endovascular procedure needs to be looked at individually, incorporating patient- and treatment-related factors in the decision-making. Comprehensive stroke centers should begin monitoring procedure times, and special considerations may be required if procedure time exceeds 60 minutes. Further studies need to standardize the definition of procedure time and determine the effect of various thresholds to improve outcomes of patients with acute ischemic stroke.

## References

1. Alberts MJ, Hademenos G, Latchaw RE, et al. Recommendations for the establishment of primary stroke centers: Brain Attack Coalition. *JAMA* 2000;283:3102–09
2. Alberts MJ, Latchaw RE, Selman WR, et al. Recommendations for comprehensive stroke centers: a consensus statement from the Brain Attack Coalition. *Stroke* 2005;36:1597–616
3. Schriger DL, Kalafut M, Starkman S, et al. Cranial computed tomography interpretation in acute stroke: physician accuracy in determining eligibility for thrombolytic therapy. *JAMA* 1998;279:1293–97
4. Hussein HM, Georgiadis AL, Vazquez G, et al. Occurrence and predictors of futile recanalization following endovascular treatment among patients with acute ischemic stroke: a multicenter study. *AJNR Am J Neuroradiol* 2010;31:454–58
5. Miley JT, Memon MZ, Hussein HM, et al. A multicenter analysis of “time to microcatheter” for endovascular therapy in acute ischemic stroke. *J Neuroimaging* 2011;21:159–64
6. Burns TC, Rodriguez GJ, Patel S, et al. Endovascular interventions following intravenous thrombolysis may improve survival and recovery in patients with acute ischemic stroke: a case-control study. *AJNR Am J Neuroradiol* 2008;29:1918–24
7. Qureshi AI, Janjua N, Kirmani JF, et al. Mechanical disruption of thrombus following intravenous tissue plasminogen activator for ischemic stroke. *J Neuroimaging* 2007;17:124–30
8. Qureshi AI, Harris-Lane P, Kirmani JF, et al. Intra-arterial reteplase and intravenous abciximab in patients with acute ischemic stroke: an open-label, dose-ranging, phase I study. *Neurosurgery* 2006;59:789–96, discussion 96–97
9. Qureshi AI, Siddiqui AM, Kim SH, et al. Reocclusion of recanalized arteries during intra-arterial thrombolysis for acute ischemic stroke. *AJNR Am J Neuroradiol* 2004;25:322–28
10. Qureshi AI, Hussein HM, Abdelmoula M, et al. Subacute recanalization and reocclusion in patients with acute ischemic stroke following endovascular treatment. *Neurocrit Care* 2009;10:195–203
11. Qureshi AI, Suri MF, Ali Z, et al. Intraarterial reteplase and intravenous abciximab for treatment of acute ischemic stroke: a preliminary feasibility and safety study in a non-human primate model. *Neuroradiology* 2005;47:845–54.
12. Hassan AE, Zacharatos H, Rodriguez GJ, et al. A comparison of computed tomography perfusion-guided and time-guided endovascular treatments for patients with acute ischemic stroke. *Stroke* 2010;41:1673–78
13. Qureshi AI, Suri MF, Shatla AA, et al. Intraarterial recombinant tissue plasminogen activator for ischemic stroke: an accelerating dosing regimen. *Neurosurgery* 2000;47:473–76, discussion 477–79
14. Qureshi AI, Ali Z, Suri MF, et al. Intra-arterial third-generation recombinant tissue plasminogen activator (reteplase) for acute ischemic stroke. *Neurosurgery* 2001;49:41–48, discussion 48–50

15. Furlan A, Higashida R, Wechsler L, et al. Intra-arterial prourokinase for acute ischemic stroke: the PROACT II study—a randomized controlled trial. *Prolyse in Acute Cerebral Thromboembolism. JAMA* 1999;282:2003–11
16. Khatri P, Abruzzo T, Yeatts SD, et al. Good clinical outcome after ischemic stroke with successful revascularization is time-dependent. *Neurology* 2009; 73:1066–72
17. Leifer D, Bravata DM, Connors JJ 3rd, et al. Metrics for measuring quality of care in comprehensive stroke centers: detailed follow-up to Brain Attack Coalition comprehensive stroke center recommendations—a statement for healthcare professionals from the American Heart Association/American Stroke Association. *Stroke* 2011;42:849–77
18. Derex L, Adeleine P, Nighoghossian N, et al. Factors influencing early admission in a French stroke unit. *Stroke* 2002;33:153–59
19. Nguyen TN, Lanthier S, Roy D. Iatrogenic arterial perforation during acute stroke interventions. *AJNR Am J Neuroradiol* 2008;29:974–75
20. Shi ZS, Liebeskind DS, Loh Y, et al. Predictors of subarachnoid hemorrhage in acute ischemic stroke with endovascular therapy. *Stroke* 2010;41: 2775–81
21. Nguyen TN, Babikian VL, Romero R, et al. Intra-arterial treatment methods in acute stroke therapy. *Front Neurol* 2011;2:9
22. Qureshi AI, Alkawi A, Hussein HM, et al. Angiographic analysis of intravascular thrombus volume in patients with acute ischemic stroke. *J Endovasc Ther* 2007;14:475–82
23. Broderick JP, Lu M, Kothari R, et al. Finding the most powerful measures of the effectiveness of tissue plasminogen activator in the NINDS tPA stroke trial. *Stroke* 2000;31:2335–41

**Paper-4:**

Hassan AE, Zacharatos H, Rodriguez GJ, Vazquez G, et al.: A comparison of Computed Tomography perfusion-guided and time-guided endovascular treatments for patients with acute ischemic stroke. *Stroke*. 2010 Aug;41(8):1673-8

# Stroke

JOURNAL OF THE AMERICAN HEART ASSOCIATION



American Heart Association | American Stroke Association

## A Comparison of Computed Tomography Perfusion-Guided and Time-Guided Endovascular Treatments for Patients With Acute Ischemic Stroke

Ameer E. Hassan, Haralabos Zacharatos, Gustavo J. Rodriguez, Gabriela Vazquez, Jefferson T. Miley, Ramachandra P. Tummala, M. Fareed K. Suri, Robert A. Taylor and Adnan I. Qureshi

*Stroke*. 2010;41:1673-1678; originally published online July 8, 2010;

doi: 10.1161/STROKEAHA.110.586685

*Stroke* is published by the American Heart Association, 7272 Greenville Avenue, Dallas, TX 75231

Copyright © 2010 American Heart Association, Inc. All rights reserved.

Print ISSN: 0039-2499. Online ISSN: 1524-4628

The online version of this article, along with updated information and services, is located on the World Wide Web at:

<http://stroke.ahajournals.org/content/41/8/1673>

**Permissions:** Requests for permissions to reproduce figures, tables, or portions of articles originally published in *Stroke* can be obtained via RightsLink, a service of the Copyright Clearance Center, not the Editorial Office. Once the online version of the published article for which permission is being requested is located, click Request Permissions in the middle column of the Web page under Services. Further information about this process is available in the Permissions and Rights Question and Answer document.

**Reprints:** Information about reprints can be found online at:

<http://www.lww.com/reprints>

**Subscriptions:** Information about subscribing to *Stroke* is online at:

<http://stroke.ahajournals.org/subscriptions/>

# A Comparison of Computed Tomography Perfusion-Guided and Time-Guided Endovascular Treatments for Patients With Acute Ischemic Stroke

Ameer E. Hassan, DO; Haralabos Zacharatos, DO; Gustavo J. Rodriguez, MD; Gabriela Vazquez, PhD; Jefferson T. Miley, MD; Ramachandra P. Tummala, MD; M. Fareed K. Suri, MD; Robert A. Taylor, MD; Adnan I. Qureshi, MD

**Background and Purpose**—The role of CT perfusion (CT-P) imaging for the selection of patients with acute ischemic stroke who may benefit from endovascular treatment is not defined. The objective of this study was to determine whether CT-P-guided endovascular treatment improves clinical outcomes compared with standard endovascular treatment based on the time interval between symptom onset and presentation and noncontrast cranial CT imaging.

**Methods**—A retrospective study was performed comparing the clinical characteristics, complications, and clinical outcomes of patients with acute ischemic stroke who were treated using endovascular modalities based on either CT-P imaging (CT-P-guided) or time interval between symptom onset and presentation and absence of intracerebral hemorrhage or extensive ischemic changes on noncontrast cranial CT scan (time-guided).

**Results**—The rates of partial and complete recanalization were similar between the CT-P- and time-guided treatment groups (n=61 [88%] versus n=103 [81%];  $P=0.52$ ) regardless of whether they received intravenous recombinant tissue plasminogen activator before endovascular treatment. Comparing the CT-P-guided with the time-guided patients, favorable discharge outcome (modified Rankin Scale 0 to 2) was observed in 23 (32%) versus 41 (33%) of the patients, respectively ( $P=0.9$ ). In-hospital mortality was observed in 15 (21%) of CT-P- and 29 (23%) of time-guided patients ( $P=0.74$ ).

**Conclusion**—CT-P-guided endovascular treatment did not increase the rate of short-term favorable outcomes among patients with acute ischemic stroke. Prospective studies are required to validate the CT-P criteria and protocols currently in use before incorporating CT-P as a routine modality for patient selection for endovascular treatment. (*Stroke*. 2010; 41:1673-1678.)

**Key Words:** acute ischemic stroke ■ computed tomographic perfusion ■ endovascular treatment ■ thrombectomy ■ thrombolysis

Noncontrast cranial CT scan findings in patients with acute ischemic stroke have been classically used to select patients for intravenous and endovascular thrombolysis therapy in the European Cooperative Acute Stroke Study (ECASS) I,<sup>1</sup> II,<sup>2</sup> and III,<sup>3</sup> Interventional Management of Stroke (IMS) I,<sup>4</sup> II,<sup>5</sup> and III,<sup>6</sup> Prolyse in Acute Cerebral Thromboembolism (PROACT) II,<sup>7</sup> and Mechanical Embolus Removal in Cerebral Ischemia (MERCII)<sup>8</sup> trials. Ezzeddine et al<sup>9</sup> found that CT perfusion (CT-P) imaging was more sensitive (100%) and specific (92%) than noncontrast CT (93% sensitive and 67% specific) for the detection of large ischemic infarcts (affecting greater than one third of the affected lobe). Similarly, Wintermark et al<sup>10</sup> found that dynamic CT-P images were more accurate than nonenhanced cranial CT in the detection of ischemic stroke in patients presenting with symptoms <12 hours in duration. Subsequently, new emphasis has been placed on using CT-P

imaging to select patients with acute ischemic stroke who can benefit from endovascular treatment. Selection is based on identification of hypoperfused, hypoxic tissue that is structurally intact and at risk of infarction but potentially salvageable with early reperfusion (penumbra). The presence of ischemic penumbra on CT-P can be identified based on increased mean transit time (MTT), decreased regional cerebral blood flow (rCBF), and normal or increased regional cerebral blood volume (rCBV)<sup>11</sup> and potentially used to select patients with acute ischemic stroke for intravenous<sup>12</sup> or endovascular treatment.<sup>13</sup>

The 2009 American Heart Association Scientific Statement<sup>14</sup> recommends that a vascular imaging study should not delay the start of intravenous thrombolysis in patients with ischemic stroke presenting within 3 hours of symptom onset. The American Heart Association statement suggests that CT-P may be used to select patients for intravenous

Received April 12, 2010; accepted April 27, 2010.

From the Zeenat Qureshi Stroke Research Center, University of Minnesota, Minneapolis, Minn.

Correspondence to Ameer E. Hassan, DO, Zeenat Qureshi Stroke Research Center, Department of Neurology, University of Minnesota, 12-100 PWB, 516 Delaware Street SE, Minneapolis, MN 55455. E-mail ameerhassan@gmail.com

© 2010 American Heart Association, Inc.

Stroke is available at <http://stroke.ahajournals.org>

DOI: 10.1161/STROKEAHA.110.586685

thrombolysis treatment beyond a strict 3-hour time window.<sup>14</sup> However, CT-P has not been validated for use in the diagnosis of penumbra and identification of patients appropriate for endovascular treatment. The goal of our study was to determine if there is an incremental clinical benefit to CT-P-guided selection compared with standard time-guided selection of patients with acute ischemic stroke undergoing endovascular treatment.

## Materials and Methods

A retrospective study of consecutive endovascularly treated acute ischemic stroke patients was performed between January 1, 2007, to July 1, 2009, at the University of Minnesota and Hennepin County Medical Centers and from May 2005 to July 2007 at the University of Medicine and Dentistry of New Jersey. The 3 institutions maintained a prospective endovascular procedure database. The protocol for collecting data was reviewed and approved by the Institutional Review Board at each institution as part of a standardized database.

### Patient Selection

At the University of Medicine and Dentistry of New Jersey, all patients were selected for endovascular treatment based on time interval between symptom onset and hospital presentation and noncontrast cranial CT scan findings. Every patient had a noncontrast CT scan to identify intracranial hemorrhage (ICH), cerebral edema, sulcal effacement, dense vessel sign, focal parenchymal hypoattenuation, or an obvious infarction of greater than one third of the middle cerebral artery vascular territory.

At the University of Minnesota and Hennepin County Medical Centers, the majority of endovascularly treated patients were selected after undergoing CT angiogram and CT-P scans. The CT-P protocol started with a noncontrast cranial CT scan and was discontinued if ICH was identified. Most perfusion scans were performed on the Phillips 64-slice CT scanner. Maps obtained by the Phillips 64 (Phillips Medical Systems, Cleveland, OH) were generated using both Gaussian fit and single value deconvolution methods using Vitrea software (Vital Images), yielding the following perfusion parameters: time to peak, MTT, rCBF, and rCBV. Patients were selected for endovascular treatment based on qualitative and quantitative analysis demonstrating preserved rCBV, decreased rCBF, and increased MTT in  $\geq 20\%$  of the affected region and involving the cortex. Automated quantitative values for rCBF, rCBV, and MTT in predefined regions of interest were infrequently used as supplementary data to enhance the identification of mismatch based on the previously published parameters by Wintermark et al<sup>15,16</sup>: MTT  $> 145\%$  of the contralateral side values and rCBV  $> 2$  mL/100 g.<sup>15,16</sup> In the case of a middle cerebral artery vascular territory infarction, the patient was excluded from endovascular treatment if the infarct burden was greater than or equal to one third of the vascular territory on qualitative analysis of the rCBV map acquired from CT-P studies. These parameters are based on previous studies that have been used to identify patients for intravenous thrombolysis<sup>17,18</sup> and other studies that have identified a large rCBV deficit (one third of the middle cerebral artery vascular territory or greater) correlating with poor recovery potential.<sup>19</sup>

### Data Collected

We recorded the presence of cardiovascular risk factors (active smoking history, hypertension, atrial fibrillation, coronary artery disease, hyperlipidemia, diabetes mellitus, prior transient ischemic attack or ischemic stroke), time interval between symptom onset and endovascular intervention, and use of intravenous recombinant tissue plasminogen activator. We also recorded admission, 24-hour post-treatment, and discharge National Institutes of Health Stroke Scale (NIHSS) scores, and discharge modified Rankin Scale scores. The principal safety end points were ICH and in-hospital mortality. Symptomatic ICH was defined as noncontrast CT scan-documented

ICH either in the area of the qualifying stroke and related to neurological deterioration ( $\geq 2$ -point worsening on a NIHSS score compared with previous clinical assessment) or in a different vascular territory and associated with new neurological deficits within 24 hours of treatment. Early neurological improvement was documented as an improvement in NIHSS score  $\geq 4$  or a NIHSS score of 0 at 24 hours posttreatment. Favorable functional outcome was defined by modified Rankin Scale score of 0 to 2 at discharge.

### Angiographic Recanalization

Arterial occlusion on pre- and posttreatment cerebral angiogram was classified by the Qureshi Grading Scale, a previously validated grading scheme based on the occlusion location and collateral supply to the affected region.<sup>20,21</sup> The Qureshi Grading Scale has 6 grades with Grade 0 denoting no occlusion and Grade 5 representing complete occlusion of either the internal carotid artery or the basilar artery. Recanalization was defined by a reduction in  $\geq 1$  grade from baseline in the Qureshi Grading Scale consistent with previous studies.<sup>22-24</sup>

### Statistical Analysis

All data were descriptively presented using mean  $\pm$  SD for continuous data and frequencies for categorical data. The frequency of baseline demographic and clinical characteristics, admission NIHSS score, time interval between symptom onset and endovascular treatment, and the interval between hospital presentation and endovascular treatment were compared between acute ischemic stroke patients treated using CT-P- and time-guided selection criteria. Statistical association was assessed with *t* test or median 2-sample test according to normality for continuous data and  $\chi^2$  test for categorical data. The rates of partial and complete angiographic recanalization, symptomatic and asymptomatic ICHs, early neurological improvement, favorable discharge outcome, and in-hospital mortality were compared. Multivariable analysis was not performed because all potential confounding factors were similar between the 2 groups.

### Results

A total of 69 patients (mean age  $\pm$  SD  $68 \pm 15$  years;  $n=36$  [52%] men) underwent CT-P-guided and 127 patients (mean age  $\pm$  SD  $65 \pm 15$  years;  $n=65$  [51%] men) underwent time-guided endovascular treatment. The clinical characteristics and mean NIHSS score on admission were similar between the 2 groups (Table 1). There was no difference with regard to the median time interval between symptom onset and endovascular treatment between the CT-P- and time-guided treatment groups: 308 minutes (range, 140 to 1120,  $n=65$  of 69) versus 301 minutes (range, 116 to 1109,  $n=107$  of 127;  $P=0.87$ ).

The rates of various endovascular treatments used are presented in Table 1. The rate of postprocedural partial and complete recanalization was similar between the patients treated using CT-P- and time-guided selection ( $n=61$  [88%] versus  $n=103$  [81%];  $P=0.52$ ). Before endovascular treatment, intravenous recombinant tissue plasminogen activator was administered to 32 (44%) of the CT-P-guided patients compared with 47 (37%) of the time-guided patients ( $P=0.3$ ). Intravenous recombinant tissue plasminogen activator administration was not associated with a higher rate of recanalization ( $P=0.29$ ) or favorable outcome at discharge ( $P=0.53$ ).

Favorable outcome was observed in 23 (32%) CT-P-guided and 41 (33%) time-guided treatment patients ( $P=0.9$ ; Table 2). Early neurological improvement was observed in 46 (64%) of the CT-P-guided and 69 (64%) of 108 time-guided endovascularly treated patients ( $P=0.94$ ). In-hospital mortal-



**Table 1. Demographic and Clinical Characteristics of Patients Treated Using CT-P-Guided and Time Guided Endovascular Treatments**

Demographics	Patients Undergoing CT-P-Guided Treatment	Patients Undergoing Time-Guided Treatment	P
No. of patients	69	127	
Men	36 (52%)	65 (51%)	1.0
Mean age $\pm$ SD	68 $\pm$ 15	65 $\pm$ 15	0.26
Mean admission NIHSS score $\pm$ SD	15 $\pm$ 6	17 $\pm$ 7	0.16
Risk factors			
Cigarette smoking	16 (23%)	9/73 (12%)	0.12
Hypertension	47 (68%)	93 (73%)	0.51
Atrial fibrillation	25 (36%)	33 (26%)	0.14
Coronary artery disease	13 (19%)	31 (24%)	0.47
Hyperlipidemia	27 (39%)	34 (27%)	0.08
Diabetes mellitus	14 (20%)	36 (28%)	0.23
Prior stroke/transient ischemic attack	16 (23%)	21 (17%)	0.26
Endovascular characteristics			
Wake-up strokes	4 (6%)	20 (16%)	0.19
Median time interval between symptom onset and endovascular treatment (minutes [range], no.)*	308 [140–1120], 65	301 [116–1109], 107	0.87
Median time interval between hospital arrival and endovascular treatment (minutes [range], no.)	201 [100–511]	194 [68–859], 108	0.31
IV rtPA	32 (46%)	47 (37%)	0.30
Endovascular treatment $\leq$ 6 hours of symptom onset	36 (52%)	75 (59%)	0.37
Endovascular thrombolytics	50 (72%)	84 (66%)	0.42
Mechanical thrombectomy	27 (39%)	41 (32%)	0.35
Angioplasty	26 (38%)	37 (29%)	0.26

\*Not estimated if time of symptom onset was not known and time last known intact was used.

IV rtPA indicates intravenous recombinant tissue plasminogen activator.

ity rates among CT-P-guided and time-guided treatment patients were similar: 15 (21%) versus 29 (23%;  $P=0.74$ ; Table 2). Among patients with acute ischemic stroke undergoing CT-P- or time-guided treatment, there was no difference in the rates of symptomatic ( $n=6$  [8%] versus  $n=8$  [6%];  $P=0.59$ ) or asymptomatic ICHs ( $n=11$  [15%] versus  $n=13$  [10%];  $P=0.29$ ; Table 2). There were no differences observed in the rates of partial or complete recanalization, favorable outcome at discharge, neurological improvement, or symptomatic or asymptomatic ICHs in patient strata based on time interval between symptom onset and treatment ( $\leq 6$  and  $>6$  hours) between the 2 groups (Table 2).

### Discussion

We compared the clinical outcomes of patients with acute ischemic stroke selected for endovascular intervention based on either CT-P- or time-guided paradigms. There was no difference in the proportion of factors that could obscure any differential rates of outcomes between the 2 groups, including admission NIHSS score, median time interval between symptom onset and endovascular treatment, or rates of partial or complete recanalization. When compared with the time-guided endovascularly treated patients, CT-P-guided patients were not found to have an increased clinical benefit with respect to functional outcome, early neurological improvement, ICH, and in-hospital mortality. Furthermore, no differ-

ence was observed in patients presenting to the hospital within or after 6 hours of symptom onset.

Although the primary purpose of the noncontrast cranial CT scan is to exclude any ICH,<sup>4,5</sup> findings of early ischemic injury such as sulcal effacement, obscuration of junction between gray and white matter, and focal parenchymal low attenuation have been used to identify patients at risk for poor outcomes after thrombolysis.<sup>25</sup> The extent of early ischemic changes on noncontrast CT scan has been quantified using the Alberta Stroke Program Early CT<sup>26</sup> scoring system (ASPECTS). The ASPECTS score is a 10-point scale that rates the presence or absence of ischemia in 10 regions of the brain. In a post hoc analysis of the PROACT-II<sup>7</sup> study, patients with ischemic stroke with a baseline ASPECTS  $>7$  were 3 times more likely to have an independent functional outcome with thrombolytic treatment compared with control subjects.<sup>27</sup> Experienced endovascular physicians may be able to use the findings on noncontrast CT scan supplanted by information regarding time interval between symptom onset and presentation and other unmeasured variables such as the mismatch between clinical deficits and CT scan findings to appropriately identify patients with ischemic stroke who may benefit from endovascular treatment. Such selection criteria may limit the value of CT-P-guided selection of patients for thrombolytic treatment, particularly endovascular treatment.

**Table 2. Rates of Various Outcomes Among Patients Treated Using CT-P-Guided and Time-Guided Endovascular Treatments**

Outcomes	Patients Undergoing CT-P-Guided Treatment (n=69)	Patients Undergoing Time-Guided Treatment (n=127)	P
Favorable outcome at discharge, no.	23 (32%)	41 (33%), 125	0.90
Early neurological improvement, no.	46 (64%)	69 (64%), 108	0.94
In-hospital mortality	15 (21%)	29 (23%)	0.74
Symptomatic ICH	6 (8%)	8 (6%)	0.59
Asymptomatic ICH	11 (15%)	13 (10%)	0.29
Partial or complete recanalization	61 (88%)	103 (81%)	0.52
Endovascular treatment ≤6 hours of symptom onset (n=36)		(n=75)	
Favorable outcome at discharge	15 (42%)	27 (36%)	0.68
Early neurological improvement, no.	25 (69%)	50 (74%), 67	0.65
In-hospital mortality	6 (17%)	15 (20%)	0.79
Symptomatic ICH	3 (8%)	7 (9%)	1.0
Asymptomatic ICH	4 (11%)	8 (11%)	1.0
Partial or complete recanalization	30 (83%)	68 (91%)	0.26
Endovascular treatment >6 hours of symptom onset (n=33)		(n=52)	
Favorable outcome at discharge	7 (21%)	14 (27%)	0.61
Early neurological improvement, no.	19 (58%)	19 (46%), 41	0.36
In-hospital mortality	9 (27%)	14 (27%)	1.0
Symptomatic ICH	3 (9%)	1 (2%)	0.29
Asymptomatic ICH	6 (18%)	5 (10%)	0.32
Partial or complete recanalization	28 (85%)	35 (67%)	0.61

The concept is similar to the selection of patients for thrombolytic therapy based on mismatch between deficits observed in diffusion- and perfusion-weighted MRI.<sup>17</sup> Previous studies of patients with acute ischemic stroke demonstrated CT-P measurements of MTT, rCBF, and rCBV correlate well with concurrent assessment using perfusion-weighted MRI.<sup>28</sup> However, the information regarding viability of regional tissue provided by diffusion-weighted MRI is not directly available by CT-P. Wintermark et al<sup>15</sup> studied 42 patients with ischemic stroke who successively underwent CT angiogram and CT-P and MRI examinations within 3 to 9 hours of symptom onset and found that there was an excellent interobserver agreement for CT-P ( $\alpha=0.90$ ) with respect to infarct size, cortical involvement, arterial occlusion site, and magnitude of mismatch denoting penumbra to infarct ratio.

CT-P evaluation of patients with ischemic stroke, beyond the initial 6 hours of symptom onset, has been used to select patients appropriate for endovascular treatment. Natarajan et al<sup>29</sup> reported the results of endovascular therapy in 30 patients selected based on the presence of clinically significant salvageable brain tissue as compared with the established core infarct (less than one third of the middle cerebral artery territory) that was at high risk for hemorrhagic conversion as demonstrated by CT-P after a minimum of 8 hours from symptom onset. Symptomatic or asymptomatic ICH was observed in 10% and 33.3% of patients, respectively, with a total in-hospital mortality of 23.3%.<sup>29</sup> Although the low rates of ICH have been used as a measure of safety in such reports,

no definitive comments can be made regarding efficacy due to the absence of a comparison group.

There are limitations to acquisition and interpretation of CT-P imaging in the current study. Multislice CT scanners provide 2 to 4 cm of coverage per acquisition, which do not always allow the evaluation of the exact perfusion deficit volumes if they exceed the volume studied.<sup>12</sup> The variation in reconstruction of CT-P images and qualitative interpretation of salvageable tissue may lead to selection of a relatively heterogeneous population, leading to the inclusion of patients with limited salvageable tissue, which may obscure the benefit of endovascular treatment. False-negatives and uninterpretable imaging can be obtained when using CT-P imaging largely due to a patient's low cardiac output, inappropriate slow rate of bolus administration, contrast extravasation in the subcutaneous tissue, patient movement, and operator inexperience.<sup>11</sup>

The mismatch between rCBV and rCBF deficits on CT-P may not represent salvageable tissue. Animal models studying the pathophysiology of ischemic and infarcted brain tissue have demonstrated that irreversible stereotypical biochemical, molecular, and electrophysiological changes occur as rCBF is reduced for a prolonged period of time.<sup>30</sup> In contrast to infarcted tissue, the penumbra retains its biochemical, molecular, and electrophysiological function despite decreased cerebral perfusion. The presence of collateral circulation may contribute to the maintenance of the cerebral perfusion and rCBV within the affected brain region; unfortunately, collateral circulation is variable and may not always be present.<sup>31</sup>

This was a retrospective study with a sample size that was not adequate to establish a noninferiority of CT-P- over time-guided selection of patients appropriate for endovascular therapy. Due to the fact that this was not a randomized study, there may be unmeasured differences between the 2 treatment groups. We did not document the number of patients who were excluded from endovascular treatment based on either the CT-P or noncontrast cranial CT findings in either of the treatment paradigms. Although the magnitude of this selection bias is not known, preferential selection of the best possible candidates would have favored better outcomes among the CT-P-guided group. It should be noted that intravenous recombinant tissue plasminogen activator was not withheld in study sites based on CT-P findings consistent with current guidelines<sup>14</sup> and may have obscured the potential differences in outcomes between the 2 groups. Because the CT-P-guided treatments occurred more recently than the time-guided treatment, evolution in both endovascular technology and standardization of postprocedural medical care would also have favored the CT-P-guided treatment group. However, the lack of standardized and validated criteria based on CT-P confounded by interpretation by multiple physicians may have undermined the value of CT-P-guided treatment. There may also have been some patients with pre-existing deficits and modified Rankin Scale scores of 3 to 5 who could not have demonstrated a favorable discharge modified Rankin Scale score of 0 to 2 despite treatment. However, the proportion of patients with a history of prior strokes was similar between the 2 patient groups.

### Conclusion

CT-P-guided endovascular treatment (compared with conventional time-guided endovascular treatment) was not associated with improved short-term outcomes among patients with acute ischemic stroke. There are currently no randomized controlled trials that demonstrate incremental benefit using CT-P-guided selection of patients for endovascular treatment. Prospective studies are required to validate the CT-P criteria and protocols currently in use before incorporating CT-P as a routine patient selection modality for endovascular treatment.

### Sources of Funding

A.I.Q. has received funding from National Institutes of Health RO-1-NS44976-1A2 (medication provided by ESP Pharma), American Heart Association Established Investigator Award 0840053N, and Minnesota Medical Foundation, Minneapolis, Minn.

### Disclosures

None.

### References

- Hacke W, Kaste M, Fieschi C, Toni D, Lesaffre E, von Kummer R, Boysen G, Bluhmki E, Höxter G, Mahagne MH, et al. Intravenous thrombolysis with recombinant tissue plasminogen activator for acute hemispheric stroke. The European Cooperative Acute Stroke Study (ECASS). *JAMA*. 1995;274:1017-1025.
- Hacke W, Kaste M, Fieschi C, von Kummer R, Davalos A, Meier D, Larrue V, Bluhmki E, Davis S, Donnan G, Schneider D, Diez-Tejedor E, Trouillas P. Randomised double-blind placebo-controlled trial of thrombolytic therapy with intravenous alteplase in acute ischaemic stroke

- (ECASS II). Second European-Australasian Acute Stroke Study Investigators. *Lancet*. 1998;352:1245-1251.
- Hacke W, Kaste M, Bluhmki E, Brozman M, Davalos A, Guidetti D, Larrue V, Lees KR, Medeghri Z, Machnig T, Schneider D, von Kummer R, Wahlgren N, Toni D: ECASS Investigators. Thrombolysis with alteplase 3 to 4.5 hours after acute ischemic stroke. *N Engl J Med*. 2008;359:1317-1329.
- IMS Study Investigators. Combined intravenous and intra-arterial recanalization for acute ischemic stroke: the Interventional Management of Stroke Study. *Stroke*. 2004;35:904-911.
- IMS II Trial Investigators. The Interventional Management of Stroke (IMS) II Study. *Stroke*. 2007;38:2127-2135.
- Khatri P, Hill MD, Palesch YY, Spilker J, Jauch EC, Carrozzella JA, Demchuk AM, Martin R, Mauldin P, Dillon C, Ryckborst KJ, Janis S, Tomsick TA, Broderick JP; International Management of Stroke III Investigators. Methodology of the Interventional Management of Stroke III Trial. *Int J Stroke*. 2008;3:130-137.
- Furlan A, Higashida R, Wechsler L, Gent M, Rowley H, Kase C, Pessin M, Ahuja A, Callahan F, Clark WM, Silver F, Rivera R. Intra-arterial prourokinase for acute ischemic stroke. The PROACT II study: a randomized controlled trial. *Prolyse in Acute Cerebral Thromboembolism*. *JAMA*. 1999;282:2003-2011.
- Smith WS, Sung G, Starkman S, Saver JL, Kidwell CS, Gobin YP, Lutsep HL, Nesbit GM, Grobelny T, Rymer MM, Silverman IE, Higashida RT, Budzik RF, Marks MP; MERCI Trial Investigators. Safety and efficacy of mechanical embolectomy in acute ischemic stroke: results of the MERCI trial. *Stroke*. 2005;36:1432-1438.
- Ezzeddine MA, Lev MH, McDonald CT, Rordorf G, Oliveira-Filho J, Aksoy FG, Farkas J, Segal AZ, Schwamm LH, Gonzalez RG, Koroshetz WJ. CT angiography with whole brain perfused blood volume imaging: added clinical value in the assessment of acute stroke. *Stroke*. 2002;33:959-966.
- Wintermark M, Fischbein NJ, Smith WS, Ko NU, Quist M, Dillon WP. Accuracy of dynamic perfusion CT with deconvolution in detecting acute hemispheric stroke. *AJNR Am J Neuroradiol*. 2005;26:104-112.
- Lovblad KO, Baird AE. Computed tomography in acute ischemic stroke. *Neuroradiology*. 2010;52:175-187.
- Wintermark M, Reichhart M, Cuisenaire O, Maeder P, Thiran JP, Schnyder P, Bogousslavsky J, Meuli R. Comparison of admission perfusion computed tomography and qualitative diffusion- and perfusion-weighted magnetic resonance imaging in acute stroke patients. *Stroke*. 2002;33:2025-2031.
- Wintermark M, Bogousslavsky J. Imaging of acute ischemic brain injury: the return of computed tomography. *Curr Opin Neurol*. 2003;16:59-63.
- Laichaw RE, Alberts MJ, Lev MH, Connors JJ, Harbaugh RE, Higashida RT, Hobson R, Kidwell CS, Koroshetz WJ, Mathews V, Villablanca P, Warach S, Walters B; American Heart Association Council on Cardiovascular Radiology and Intervention, Stroke Council, and the Interdisciplinary Council on Peripheral Vascular Disease. Recommendations for imaging of acute ischemic stroke: a scientific statement from the American Heart Association. *Stroke*. 2009;40:3646-3478.
- Wintermark M, Meuli R, Browaeys P, Reichhart M, Bogousslavsky J, Schnyder P, Michel P. Comparison of CT perfusion and angiography and MRI in selecting stroke patients for acute treatment. *Neurology*. 2007;68:694-697.
- Wintermark M, Flanders AE, Velthuis B, Meuli R, van Leeuwen M, Goldsher D, Pineda C, Serena J, van der Schaaf I, Waaijer A, Anderson J, Nesbit G, Gabriely I, Medina V, Quiles A, Pohlman S, Quist M, Schnyder P, Bogousslavsky J, Dillon WP, Pedraza S. Perfusion-CT assessment of infarct core and penumbra: receiver operating characteristic curve analysis in 130 patients suspected of acute hemispheric stroke. *Stroke*. 2006;37:979-985.
- Hacke W, Albers G, Al-Rawi Y, Bogousslavsky J, Davalos A, Eliasziw M, Fischer M, Furlan A, Kaste M, Lees KR, Soehngen M, Warach S; DIAS Study Group. The Desmoteplase in Acute Ischemic Stroke Trial (DIAS): a phase II MRI-based 9-hour window acute stroke thrombolysis trial with intravenous desmoteplase. *Stroke*. 2005;36:66-73.
- Wintermark M, Reichhart M, Thiran JP, Maeder P, Chalaron M, Schnyder P, Bogousslavsky J, Meuli R. Prognostic accuracy of cerebral blood flow measurement by perfusion computed tomography, at the time of emergency room admission, in acute stroke patients. *Ann Neurol*. 2002;51:417-432.
- Lev MH, Segal AZ, Farkas J, Hossain ST, Putman C, Hunter GJ, Budzik R, Harris GJ, Buonanno FS, Ezzeddine MA, Chang Y, Koroshetz WJ, Gonzalez RG, Schwamm LH. Utility of perfusion-weighted CT imaging in acute middle cerebral artery stroke treated with intra-arterial

- thrombolysis: prediction of final infarct volume and clinical outcome. *Stroke*. 2001;32:2021-2028.
20. Qureshi AI. New grading system for angiographic evaluation of arterial occlusions and recanalization response to intra-arterial thrombolysis in acute ischemic stroke. *Neurosurgery*. 2002;50:1405-1414, discussion 1414-1415.
  21. Qureshi AI. Endovascular treatment of cerebrovascular diseases and intracranial neoplasms. *Lancet*. 2004;363:804-813.
  22. Mohammad YM CG, Bourekas EC, Slivka AP, Qureshi grading scheme predicts subsequent volume of brain infarction following intra-arterial thrombolysis in patients with acute anterior circulation ischemic stroke. *J Neuroimaging*. 2008;18:262-267.
  23. Hussein HM GA, Vazquez G, Miley JT, Memon MZ, Mohanmad YM, Christoforidis GA, Tariq N, Qureshi AI. Occurrence and predictors of futile recanalization following endovascular treatment among patients with acute ischemic stroke: a multicenter study. *AJNR Am J Neuroradiol*. 2010;31:454-458.
  24. Qureshi AI AA, Hussein HM, Divani AA. Angiographic analysis of intravascular thrombus volume in patients with acute ischemic stroke. *J Endovasc Ther*. 2007;14:475-482.
  25. von Kummer R, Allen KL, Holle R, Bozzao L, Bastianello S, Manelfe C, Bluhmki E, Ringleb P, Meier DH, Hacke W. Acute stroke: usefulness of early CT findings before thrombolytic therapy. *Radiology*. 1997;205:327-333.
  26. Barber PA, Demchuk AM, Zhang J, Buchan AM. Validity and reliability of a quantitative computed tomography score in predicting outcome of hyperacute stroke before thrombolytic therapy. ASPECTS Study Group. Alberta Stroke Programme Early CT score. *Lancet*. 2000;355:1670-1674.
  27. Hill MD, Rowley HA, Adler F, Eliasziw M, Furlan A, Higashida RT, Wechsler LR, Roberts HC, Dillon WP, Fischbein NJ, Firszt CM, Schulz GA, Buchan AM; PROACT-II Investigators. Selection of acute ischemic stroke patients for intra-arterial thrombolysis with pro-urokinase by using ASPECTS. *Stroke*. 2003;34:1925-1931.
  28. Eastwood JD, Lev MH, Wintermark M, Fitzek C, Barboriak DP, Delong DM, Lee TY, Azhari T, Herzau M, Chilukuri VR, Provenzale JM. Correlation of early dynamic CT perfusion imaging with whole-brain MR diffusion and perfusion imaging in acute hemispheric stroke. *AJNR Am J Neuroradiol*. 2003;24:1869-1875.
  29. Natarajan SK, Snyder KV, Siddiqui AH, Ionita CC, Hopkins LN, Levy EI. Safety and effectiveness of endovascular therapy after 8 hours of acute ischemic stroke onset and wake-up strokes. *Stroke*. 2009;40:3269-3274.
  30. Ginsberg MD. Adventures in the pathophysiology of brain ischemia: penumbra, gene expression, neuroprotection: the 2002 Thomas Willis Lecture. *Stroke*. 2003;34:214-223.
  31. Maas MB, Lev MH, Ay H, Singhal AB, Greer DM, Smith WS, Harris GJ, Halpern E, Kemmling A, Koroshetz WJ, Furie KL. Collateral vessels on CT angiography predict outcome in acute ischemic stroke. *Stroke*. 2009;40:3001-3005.

**Paper-5:**

**Heiberger, P T: "Protocol variation analysis of whole brain CT perfusion in acute ischemic stroke" (2010). Master of Science dissertation. University of Nevada Las Vegas. UNLV Theses/ Dissertations/Professional Papers/Capstones. Paper 740**



---

UNLV Theses/Dissertations/Professional Papers/Capstones

---

12-1-2010

# Protocol variation analysis of whole brain CT perfusion in acute ischemic stroke

Peter T. Heiberger  
*University of Nevada, Las Vegas*

---

## Repository Citation

Heiberger, Peter T., "Protocol variation analysis of whole brain CT perfusion in acute ischemic stroke" (2010). *UNLV Theses/Dissertations/Professional Papers/Capstones*. Paper 740.  
<http://digitalscholarship.unlv.edu/thesesdissertations/740>

This Thesis is brought to you for free and open access by Digital Scholarship@UNLV. It has been accepted for inclusion in UNLV Theses/Dissertations/Professional Papers/Capstones by an authorized administrator of Digital Scholarship@UNLV. For more information, please contact [marianne.buehler@unlv.edu](mailto:marianne.buehler@unlv.edu).

PROTOCOL VARIATION ANALYSIS OF WHOLE BRAIN CT PERFUSION IN  
ACUTE ISCHEMIC STROKE

by

Peter T. Heiberger

Bachelor of Science  
University of Wisconsin, Eau Claire  
2006

A thesis submitted in partial fulfillment of  
the requirements for the

**Master of Science in Health Physics**  
**Department of Health Physics and Diagnostic Sciences**  
**School of Allied Health Sciences**  
**Division of Health Sciences**

**Graduate College**  
**University of Nevada, Las Vegas**  
**December 2010**

## CHAPTER 1

### INTRODUCTION

#### 1.1 Computed Tomography (CT)

Computed Tomography is a radiographic or medical imaging method used for the visualization of patient anatomy in two-dimensional and three-dimensional view. Planar cross-sectional x-rays are used for the creation of anatomical structures through the use of computer algorithms incorporating filtered back projection reconstruction. The x-ray source and corresponding detector make a complete 360-degree rotation around the patient to obtain a complete set of x-ray data for image reconstruction.<sup>1</sup> In order to increase the visibility of the organs and structures imaged during a CT scan, a contrast agent can be injected intravenously. This contrast will be taken up into the organs of interest and allow for a more defined and enhanced image of that anatomy. Some common contrast agents are barium, iodine, and water. These agents are effective as they have different x-ray absorption characteristics than soft tissue resulting in better contrast resolution density. The differences in attenuation of bodily organs due to their densities define the differences in Hounsfield Units. The Hounsfield Unit is calculated by using Eq. 1<sup>1</sup>.

$$HU = 1000 \left( \frac{\mu(x,y) - \mu_{\text{water}}}{\mu_{\text{water}}} \right) \quad \text{Eq. 1}$$

where  $\mu(x,y)$  is the linear attenuation coefficient of the  $(x,y)$  pixel and  $\mu_{\text{water}}$  is the attenuation coefficient of water. The CT numbers range from about -1000 to +3000, where -1000 corresponds to air, soft tissues range from -300 to -100, water is 0, and dense bone and areas filled with contrast agent range up to +3000.



Multiple detector array CT scanners acquire multiple slices per rotation. The slice thickness is dependent on the number of active individual detectors or those detectors “binned” together. The use of a multiple detector array can decrease the slice width, which in turn can decrease the contrast resolution, but increases the spatial resolution for the depiction of finer detail. In the case of identification of AIS within the vasculature and tissue of the brain, spatial resolution is more important than contrast resolution. The reduction in contrast resolution can be compensated for by post-processing the acquired images through windowing and leveling.

Computed Tomography Perfusion (CTP) is the process of taking a CT of the vasculature of the brain, with the injection of a contrast agent. As the contrast agent travels through the vasculature, the CT imaging is initiated in order to acquire the scan simultaneously with the movement of the contrast agent. This allows for the visualization of the contrast through the vasculature to identify any form of blockage or thrombosis. In the case of AIS patients, the CT scan is acquired during the simultaneous entrance of the contrast into the brain. This method allows for the diagnosis and prognosis of stroke to a particular area of the brain.

CTP is possible due to the advent of multi-slice CT, along with the high resolution and high speed of the current scanners. Typical CT-angiography and perfusion have been done using a 64-slice (detector row) CT scanner allowing for a larger volume of acquisition. However, the limitation of field size with the 64-slice CT makes whole brain perfusion analysis difficult. With the introduction of Toshiba’s Aquilion ONE 320-detector row CT, whole brain perfusion analysis is now possible.<sup>2,8,9</sup>

## 1.2 Acute Ischemic Stroke

This protocol analysis focused entirely on patients suffering from acute ischemic stroke. A stroke is a decrease or cease of blood to any particular area of the brain. This interruption of blood to the brain causes deprivation of oxygen to the brain tissue causing eminent necrosis of brain tissue.<sup>3</sup> Immediate medical care is to be sought at the onset of a stroke in order to spare and save as much brain tissue and brain function as possible.<sup>4,5</sup> The approach utilized to try and save tissue after the onset of stroke is to reopen the vasculature where the clotting has occurred. Some FDA approved drugs, such as tPA, are capable of revascularization.<sup>6</sup>

Ischemic describes a decrease in blood flow due to narrowing or blockage of an artery.<sup>3,4</sup> Ischemic includes both thrombotic and embolic stroke. Thrombotic occurs when one of the immediate arteries supplying blood to the brain is clotted causing a decrease or total blockage of blood flow. This is typically due to plaque build-up called atherosclerosis. Embolic stroke is due to the clotting of an artery elsewhere in the body and the clot dislodging itself only to clot in an artery feeding the brain. Therefore, acute ischemic stroke is defined as a sudden decrease or cease of blood flow to the brain due to a clot of the immediate blood supplying arteries to the brain.

The artery that clots the most frequently is the middle cerebral artery (MCA). This artery is one of two branches of the internal carotid artery and divides into three branches. It originates off of the internal carotid artery near the brain midline and branches bilaterally distal. The branches of the middle cerebral artery supply the extremities of the brain and engross a large volume of the brain. The posterior cerebral artery (PCA) may clot as well, although less frequently than the MCA. The posterior cerebral artery arises from the basilar artery and supplies oxygenated blood to the posterior portion of the brain

or the occipital lobe. Other arteries which clot less frequently but still result in a stroke are the basilar artery, internal carotid artery (ICA), and distal branches of both the PCA and MCA.

### 1.3 Research Goal

The goal of this comprehensive study was to identify the premier protocol for CTP analysis using the Aquilion ONE CT scanner (Toshiba Medical Systems, Nasu, Japan) along with the corresponding analysis software, Vitrea *fX* version 2.1 (Vital Images, Minnetonka, MN, USA). Identification of the most accurate and tested protocol can lead to a standard in the field of radiology in regards to analysis of AIS. CTP imaging is capable of providing physiological information leading to a rapid diagnosis and treatment of AIS. This immediate analysis via CTP of the patient anatomy allows for the identification of the infarcted core and the ischemic penumbra.<sup>2</sup> Thrombolytic drugs are available to reduce and ultimately remove the clot, but according to current FDA standards, must be administered within a three-hour window following the onset of the acute ischemic stroke.<sup>3,7</sup> These imaging tools allow for individual diagnosis and prognosis and can tailor the treatment plan accordingly. Due to the individual patient's condition, the window for administering thrombolytic agents may be extended for increased tissue salvage.<sup>8</sup>

### 1.4 Brain CTP Analysis

AIS analysis for affected patients involves both the CT scanner and the Vitrea software consisting of dedicated convolution/ deconvolution algorithms for image recreation and manipulation. Understanding of the necessary inputs and variables of the software are also vital for understanding of the AIS analysis. In CTP imaging, the

contrast agent is injected intravenously and is scanned repeatedly (19 times for these patients) as the contrast travels through the brain tissue and vasculature. The Hounsfield Units are defined for each particular voxel, creating tissue-specific time density graphs.<sup>10,11</sup>

The current standard protocol for the Vitrea *fX* version 2.1 consists of a singular value decomposition deconvolution (SVD) algorithm. This algorithm consists of a delay-sensitive component for CT-Perfusion (CTP). Another algorithm that is being supplemented in place of the SVD algorithm is termed singular value decomposition plus deconvolution (SVD+). The SVD+ deconvolution algorithm consists of a delay-insensitive component for CTP. Vascular pixel elimination (VPE) is an option in the Vitrea *fX* program that is a mathematical tool used for pixel-smoothing. This allows for an averaging of neighboring pixels of varying values for a smoother value identification.

Singular value decomposition (SVD) is a non-iterative deconvolution method based on the central volume principle. This method solves convolution equations to determine a contrast residue function for each volume of interest.<sup>10,12</sup> The contrast residue function of the tissue is derived by deconvolution. Mean transit time (MTT) is determined from the width of the contrast residue curve. Imaging modalities such as magnetic resonance imaging (MRI), positron emission tomography (PET) and CT have adapted various forms of SVD-based deconvolution algorithms to calculate brain perfusion parameters. The SVD deconvolution algorithm, is capable and is utilized for deconvolving the tissue responses from the first pass of contrast to provide underlying vascular structure.<sup>14</sup> However, due to the high sensitivity to dispersion and delay in the arterial input curve, SVD may not accurately depict the true physiological changes that

are present in the individual patient.<sup>13,21</sup> This sensitivity to dispersion and delay will deconvolve perfusion maps that may not represent the true anatomical physiology, leading to a misdiagnosis of AIS. As the time to peak (TTP) and MTT are highly sensitive to hemodynamic changes in cerebral circulation, increased values of these parameters with normal CBF and CBV will not accurately identify infarction.<sup>14,19</sup> For example, an increase in TTP or MTT will be depicted with greater perfusion values on the perfusion maps, indicating to the reader that this is an area of possible infarction. This increase in perfusion values may just be a result of the high sensitivity to delay and dispersion, representing an inaccurate reading.<sup>22,23</sup>

To overcome the high sensitivity to delay and dispersion of the SVD deconvolution algorithm and the corresponding potential biological inaccuracies, the SVD+ deconvolution algorithm has been implemented.<sup>15,18</sup> This tracer delay insensitive method integrates an adjustment in which the arterial input function (AIF) is shifted and a preconditioning technique has been applied to make calculated perfusion parameters independent of the time of arrival of the bolus.<sup>16,17</sup> The bolus arrival time is set to zero at the first sign of arrival in the brain to avoid potential delay effects. The SVD+ algorithm provides the delay or the time in seconds when the calculated tissue residue function reaches the maximum. This CTP parameter of delay represents the difference in time of contrast arrival in the brain tissue and the arterial input function. This allows the SVD+ algorithm to avoid miscalculations due to dispersion and delay.

#### 1.5 Variation of AIF and VIF Selections

The deconvolution methods of both SVD and SVD+ are directly responsive to the location selection of the arterial input function (AIF) and venous input function (VIF).

These locations allow for the creation of the corresponding arterial and venous bell curves in relation to the intensity of blood/ contrast versus time in seconds. Due to this relationship, CTP maps can vary drastically depending on the location of both the AIF and VIF. The location is indicative of the left or right hemisphere, the 'x' and 'y' coordinates within the 'z' axis and in which artery and vein the functions are placed. Unfortunately, due to the brevity of the technology used and the research within this field, there is no accepted standard for the selection of the AIF and VIF locations. Additionally, there is not an accepted standard for the selection site for particular neurological abnormalities and disease.

One must measure the accuracy and reproducibility of different selection sites to identify a premier approach for each individual AIS case analysis. As each reader approaches a case somewhat differently and has varying years of reading experience, variations will occur and need to be minimized as much as possible in order to create a standard. Several studies have shown that in comparison to the automatic AIF/VIF selection, the manual selection sites have a substantially lower variation percentage of perfusion values between multiple case analyses.<sup>24</sup> It is necessary to realize how much of an impact the deconvolution protocol and AIF/VIF factors have on individual cases in the clinical interpretation of the results.

#### 1.6 Parameters Affecting Procedural Analysis

It is important to understand the CTP parameters that are used in each case analysis within the Vitrea fX software version 2.1. *Cerebral blood volume (CBV)* is the area under the computed residue function, adjusted by the brain concentration of contrast and the hematocrit constant. This is the volume of blood per 100 grams of brain tissue

(mL/ 100g). *Cerebral blood flow (CBF)* is the volume of blood flow per minute per 100 grams of brain tissue (mL/ min/ 100 g) and is calculated by  $CBV/ MTT$ . *Time to peak (TTP)* is the time in seconds between the start of the scan acquisition and the attenuation peak on the time-intensity graph. *Mean transit time (MTT)* is the average time in seconds for a bolus of blood to cross the capillary network in a given amount of tissue. *Delay* is the difference in time of contrast arrival in the brain tissue and the AIF. It is independent of the scan start time and contrast injection time or rate. It is measured as the time in seconds for the computed residue function to reach a maximum and is available in SVD+ and SVD software, but is not reported in SVD literature.<sup>26</sup>

In order to measure the response of the selection variability of the AIF and VIF, a product map of the CBV and CBF parameters is created. Lee et al<sup>25</sup> found that the CBF x CBV product map created a qualitative CTP map that enhanced the differences between the penumbra and infarct core better than the CBV or CBF threshold alone. The CBF x CBV product map was created by multiplying the value of a gray matter (GM) and white matter (WM) pixel on the CBV map by the value of the corresponding pixel on the CBF map.

**Paper-6:**

**Karagulle Kendi AT, Miley JT, McKinney AM,  
Truwit CL et al.: Luxury perfusion masking sub  
acute infarcts on dynamic CT perfusion. ASNR  
Poster. ASNR 2007, June 11-14, 2007  
Chicago, IL**



Table 1.

	No-statin Median Infarct Volume cm <sup>3</sup>	Statin Median Infarct Volume cm <sup>3</sup>	p- value
Total Whole Group	1.96	1.44	.484
Whole Group minus subcortical only	3.11	1.98	.541
Whole Group minus subcortical only minus vol <1.5	13.90	15.05	.655
Whole group diabetes	2.27	1.02	.039
Diabetes minus subcortical only	4.23	1.08	.032
Diabetes minus subcortical <1.5	14.56	13.02	.783

**CONCLUSION**

Results of this study indicate that statin pretreatment is associated with a reduction in infarct volume in ischemic stroke patients. Additionally, the potential effect of statins on infarct volume may be particularly pronounced among patients with diabetes. Unlike Shook, et al., when we excluded small (< 1.5 cm<sup>3</sup>) and single subcortical infarcts, the observed difference between the groups was lost. Larger prospective studies are needed to confirm and characterize any potential neuroprotective effect of statins.

**REFERENCES**

1. Shook, SJ. *J. Neuroimag* 2006;16:341-346

**KEY WORDS:** Stroke, statin, infarct

*Partial support for this project was provided by Pfizer grant #2004-0361*

**Poster 4**

### How Reasonable Is Immediately Performed CCT Imaging in Patients Presenting with Clinical Symptoms of TIA Lasting Less than an Hour?

Wiese, C.<sup>1</sup> · Koch, C.<sup>1</sup> · Seidel, G.<sup>1</sup> · Jansen, O.<sup>2</sup> · Ulmer, S.<sup>2</sup>

<sup>1</sup>University Hospital of Schleswig-Holstein, Luebeck, GERMANY, <sup>2</sup>University Hospital of Schleswig-Holstein, Kiel, GERMANY

**PURPOSE**

Transient ischemic attack (TIA) is defined by neurologic symptoms lasting less than 24 hours without evidence of infarction. Recent publications discussed a timeframe of neurologic symptoms lasting less than an hour (1). Patients with a recent TIA have an increased risk to develop a major stroke most likely within the first week after symptom onset therefore requiring an extensive work-up for prevention (2). Recent recommendations for prevention of strokes do not discriminate TIA from stroke independent of the underlying cause (3). Cranial CT (CCT) as widely available imaging modality of choice is usually initially performed to rule out other causes of neurologic deterioration. According to the current literature there is no systematically performed study analyzing the possible underlying causes in patients presenting with TIA lasting less than an hour. Furthermore to justify radiation exposure CT should be sensitive enough to depict intracranial lesions.

**MATERIALS & METHODS**

Within one year we reviewed all CCT-requests of patients presenting with transient neurologic symptoms at our university hospital. CT scans, emergency notes, charts and other performed imaging modalities were reviewed. Cases with

Todd paralysis due to seizure and other causes that would require immediate emergency imaging (i.e. anticoagulated patients with head trauma or acute hypertensive dysregulation) were excluded.

**RESULTS**

We reviewed 3580 requests for a cranial CT including 350 requests (9.8%) because of transient neurologic symptoms. Of these 112 with symptoms that lasted longer than an hour were excluded for further analyzes. From the remaining group 20 were excluded because of reasons requiring emergency imaging as described above, and 13 had to be excluded for other reasons. 205 patients (5.7%) presented with a transient neurologic deterioration lasting less than one hour. From these patients 5 cases (2.4%) had a pathological finding in the initial CT. One case of infarction on initial CCT turned out to be artificial in the follow up imaging. Two infarctions were found one of which showed hemorrhagic transformation. One case of metastasis (lung cancer) and one meningioma with parenchymal edema were diagnosed respectively. From the remaining CCTs without pathological findings, 4 cases showed infarction on follow-up MRI.

**CONCLUSION**

Overall 8 cases (3.9%) with TIA had pathological findings, of which only 50% were detected by initial CCT. Both patients with tumor lesions as well as the patient with hemorrhagic infarction did not receive anticoagulation. Four strokes presenting as TIA were missed on initial CCT. Strokes can present as TIA especially when they affect clinically "silent" regions. Even though we found a small number of pathological findings, none of the patients required any immediate emergency treatment. In none of our cases an intracranial bleeding was detected. 50% of pathological findings were completely missed on CCT. Emergency imaging with CT in TIA lasting less than an hour remains questionable with regard to the benefit for the patient, costs and radiation exposure without significant improvement or changes in the treatment.

**KEY WORDS:** TIA, CCT, stroke

**Poster 5**

### Luxury Perfusion Masking Subacute Infarcts on Dynamic CT Perfusion

Karagulle Kendi, A. T.<sup>1</sup> · Miley, J. T.<sup>2</sup> · McKinney, A. M.<sup>1</sup> · Truwit, C. L.<sup>1</sup> · Kieffer, S. A.<sup>1</sup>

<sup>1</sup>University of Minnesota and Hennepin County Medical Center, Minneapolis, MN, <sup>2</sup>University of Minnesota, Minneapolis, MN

**PURPOSE**

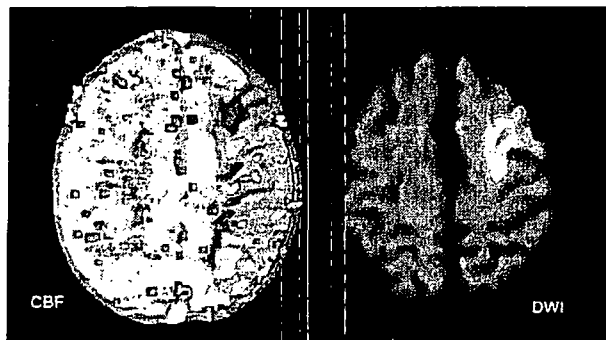
Preliminary literature based on single photon emission computed tomography (SPECT) and positron emission tomography have noted that SPECT imaging can be misleading in subacute cerebral infarcts, due to mildly increased cerebral blood volume (CBV), and slightly decreased cerebral blood flow (CBF) (1). Our purpose is to describe this hyperperfusion phenomenon occurring in the subacute phase on dynamic CT perfusion (CTP), potentially obscuring the extent of infarction, and to propose tools to avoid this pitfall.

**MATERIALS & METHODS**

Dynamic perfusion CT was performed in 6 patients in the subacute phase (range 3-8 days, one with unknown exact infarct age, but deemed subacute based on progression and contrast enhancement). Three were performed to rule out progression of a known stroke due to worsening symptoms, and three to rule out acute stroke, but later found to be subacute insults based on further clinical history and imaging. Mean transit time (MTT), CBF and CBV were calculated in >2cm regions of interest in the area of infarction, and the contralateral unaffected hemisphere, using post-processing software.

**RESULTS**

In 5 of the 6 patients, diffusion-weighted imaging (DWI) MRI was performed in under 3 days relative to the CTP; one could not undergo MRI due to pacemaker and was followed by CT. In all 6 patients, compared to the nonaffected side, the CBV's were mildly elevated (mean increase 42%) and the CBF's were mildly decreased (mean decrease 34%), while MTT's were severely elevated (mean increase >200%) in all but one case where the transit time was only mildly elevated. Hence, CBF and CBV were only mildly abnormal rather than being near zero in areas later shown to progress to infarction on DWI ( $n=5$ ) or followup CT ( $n=1$ ). Hence, MTT was the only measurement that corresponded well with the extent of DWI infarction in 5 of the 6 cases of subacute infarction (threshold >9 seconds).

**CONCLUSION**

Hyperemia (increased CBF and CBV) rather than oligemia in a territory of subacute phase infarction is likely related to the concept of luxury perfusion from capillary dysfunction, based on recent literature. Use of MTT measurements, DWI MRI, and appropriate clinical histories can prevent misinterpretation when this misleading imaging appearance occurs.

**REFERENCES**

1. Cho I, Hayashida K, Imakita S, Kume N, Fukuchi K. Hemodynamic and metabolic state of hyperfixation with  $^{99m}\text{Tc}$ -HMPAO brain SPECT in subacute stroke. *Ann Nucl Med*. 2000 Jun;14(3):159-63.

**KEY WORDS:** CT perfusion, luxury perfusion, cerebral infarction

**Poster 6****Vertebral Stump Syndrome**

Nguyen, T. N. · Mahmoud Gamal El Din, M. · Roy, D. · Weill, A. · Raymond, J. · Guilbert, F.

CHUM Notre Dame Hospital  
Montreal, PQ, CANADA

The role of the carotid artery stump as an embolic source for cerebral ischemia has been well described. When there is occlusion of flow in an artery, further ischemic episodes are not expected because of lack of a flow conduit to carry the embolus. However, in the carotid stump syndrome, ongoing ischemic events may continue due to collateral flow via the external carotid artery branches. To our knowledge, there have been no reports of a parallel syndrome causing stroke in the posterior circulation after documented proximal arterial occlusion. Vertebral artery anastomoses are numerous in the neck. Collaterals often preserve antegrade flow distal to a vertebral artery occlusion and may serve as a path for persistent emboli. We report two patients who presented with posterior circulation strokes after documented vertebral artery occlusion, despite optimal medical therapy (antiplatelet and anticoagulation therapy). Due to failed medical therapy, an endovascular approach via the deep cervical artery collateral to the vertebral artery was undertaken to exclude the embolic source. We describe their histories, the anatomy of the cervical-vertebral anastomotic collaterals as a pathway for ongoing ischemia, and implications for management.

**KEY WORDS:** Vertebral stump, stroke, anatomy

**Poster 7****Diffusion Tensor Imaging of Normal Appearing White Matter in Late-Life Depression**

Shimony, J. S. · Epstein, A. A. · Snyder, A. Z. · McKinstry, R. C. · Mintun, M. A. · Price, J. L. · Christenson, J. · Moinuddin, A. · Sheline, Y. I.

Washington University School of Medicine  
St. Louis, MO

**PURPOSE**

Diffusion tensor imaging (DTI) can be used to evaluate white matter (WM) integrity and structural abnormalities in normal appearing white matter (NAWM). WM disruption in frontal emotional regulatory areas may be a contributing factor to late-life depression. The purpose of this study was to use DTI to assess the integrity of frontal subcortical and deep WM of depressed patients versus controls.

**MATERIALS & METHODS**

Structural imaging was performed in a sample of late life depressed (LLD) subjects ( $n=73$ ) compared with controls ( $n=23$ ). The groups were matched according to gender, age, and vascular risk factors. Anatomical imaging was performed using T1- and T2-weighted images. DTI was obtained on a 1.5T Sonata (Siemens, Erlangen, Germany) with 6 encoding directions and multiple b values ( $b = 0, 400, 800, 1200 \text{ s/mm}^2$ ) using 2mm isotropic voxels. DTI parameters were computed from the raw data using linear least

**Paper-7:**

**Khatri K, Rodriguez GJ, Suri MF, Vazquez G Et al.:  
Leptomeningeal Collateral Response and  
Computed Tomographic Perfusion Mismatch in  
Acute Middle Cerebral Artery Occlusion. Journal  
of Vascular and Interventional Neurology  
2011;4(1):1-4**

ORIGINAL CONTRIBUTION

## Leptomeningeal Collateral Response and Computed Tomographic Perfusion Mismatch in Acute Middle Cerebral Artery Occlusion

### Abstract

**Objective:** To identify the relationship between the magnitude of leptomeningeal collaterals (LMC) on digital subtraction angiography (DSA) and regional cerebral blood volume (rCBV)/regional cerebral blood flow (rCBF) mismatch on computed tomography perfusion (CTP) in patients with acute middle cerebral artery (MCA) occlusion.

Rakesh Khatri, MD  
Gustavo J Rodriguez, MD  
M. Fareed K Suri, MD  
Gabriela Vazquez, PhD  
Mustapha A Ezzeddine, MD

Address Correspondence to:  
Rakesh Khatri, MD

**Design/Methods:** We reviewed the clinical records, and neuroimaging studies in consecutive patients with proximal MCA (M1-segment) and proximal branch (M2-segment) occlusion undergoing endovascular treatment following the demonstration of mismatch on CTP. DSA images acquired prior to the treatment were used to grade collateral flow from the anterior cerebral artery to the MCA on a scale ranging from 1 to 5, based on retrograde reconstitution of MCA segments in the late arterial phase. CTP images were reviewed and rCBV/rCBF mismatch was categorized as minor ( $\leq 1/3$  of MCA territory), moderate ( $1/3$ - $2/3$  of MCA territory), or severe ( $> 2/3$  to complete territory). Statistical association was assessed using Pearson exact test.

**Results:** A total of sixteen patients were studied (10 were men; mean age of 69 years). Mean time from symptom onset to CTP was 146 minutes. Patients with M1-segment occlusion (n=10) had more severe rCBV/rCBF mismatch compared to patients with M2-segment occlusion (p=0.016). There was no association between the magnitude of LMC and severity of rCBV/rCBF mismatch on CTP.

**Conclusions/Relevance:** The magnitude of LMC on DSA does not correlate with the severity of rCBV/rCBF mismatch in patients with MCA occlusion. This result suggests that additional factors, such as micro vascular failure, may contribute to altered cerebral perfusion.

*Journal of Vascular and Interventional Neurology* 2011;4(1):1-4

### Introduction

In acute ischemic stroke (AIS), the collateral circulation reduces ischemic injury to tissue and may maintain the tissue in a state of vulnerability but potentially salvable (penumbra). The absence of angiographic evidence of cerebral collateral circulation is considered a prognostic sign of poor outcome.<sup>1,2,3</sup> CT perfusion (CTP) has been used for selecting patients with AIS for endovascular treatments.<sup>4</sup> Patients also undergo digital subtraction angiography (DSA) prior to endovascular treatments. In dynamic CTP, areas with prolonged mean transit time (MTT) are suspected to be hemodynamically compromised. In these area of increased MTT, the regions with increased regional cerebral blood volume (rCBV) represent "tissue at risk", where as regions with decreased rCBV correspond to the infarct core. This increase in rCBV is believed to be a result from vasodilatation and collaterals recruitment including communicating segments of the circle of Willis (primary collaterals) supplemented by collaterals from external carotid artery branches, and leptomeningeal vessels (secondary collaterals).<sup>4,7</sup> Our intent was to study the relationship between the extent of leptomeningeal collaterals seen on DSA and regional cerebral blood volume (rCBV)/regional cerebral blood flow (rCBF) mismatch visible on CTP. We included only acute middle cerebral artery (MCA) occlusion patients to ensure a homogenous population. Our hypothesis was that if LMCs are adequate then rCBV may be preserved and rCBV/ rCBF mismatch may be present. Since this mismatch is usually treated as a surrogate marker of penumbra, an angiographic correlate of such mismatch may be valuable for selecting patients for endovascular treatment in acute ischemic stroke.

### Materials and Methods

We conducted a retrospective analysis of consecutive patients with AIS who met our study inclusion criteria at two centers.

Zeenat Qureshi Stroke Research Center, Department of Neurology, University of Minnesota, Minneapolis, MN.

*Journal of Vascular and Interventional Neurology*, Volume 4, Number 1, January 2011

1

Table 1: Pial Collateral Classification: (modified from Christoforidis et al.)<sup>9</sup>

1	Collaterals reconstituted the distal portion of the occluded vessel segment (reconstitution of distal M1 segment)
2	Collaterals reconstituted the proximal portion of the segment adjacent to occluded vessel (reconstitution of proximal M2 segments)
3	Collaterals reconstituted the distal portion of the segment adjacent to occluded vessel (reconstitution of distal portions of M2 segments)
4	Collaterals reconstituted 2 segments distal to the occluded vessel (reconstitution M3 segments)
5	There was little or no significant reconstitution of the territory of the occluded vessel.

### Patient selection

We screened consecutive patients admitted with AIS who presented with acute occlusion of M1 or M2 segment of the middle cerebral artery (n= 53) from November 2006 to July 2008. In all patients, non-contrast baseline cerebral CT scan was immediately followed by CT perfusion (CTP) along with CT angiogram (CTA), which is included in the initial routine survey of AIS patients at our institution (see Figures 1-3). We excluded patients with critical stenosis or occlusion of either internal carotid artery (ICA), remote or acute ischemic stroke in anterior cerebral artery (ACA), or posterior cerebral artery (PCA) territory. None of the patient had hypotension, defined by systolic blood pressure less than 90 mmHg at the time of CTP.

### Imaging Techniques and data processing

#### CT Perfusion:

The CTP examination consisted of two 55-second series at an interval of two minutes, each series consisting of 1 image per second during intravenous administration of iodinated contrast material. The acquisition parameters for both series were 120 kilovolt (peak; kVp) and 150 mAs (300 mA at 0.5 seconds). For each series, CT scanning was initiated immediately after injection of 36 mL iodinated contrast material, Omnipaque, 350 mg/mL iodine, at a rate of 6 mL/s into an antecubital vein with a power injector (Stellant, Medred Co). Multidetector-array technology allowed data acquisition from 4 adjacent 10-mm sections for each series. The two perfusion CT series thus allowed data acquisition in 8 adjacent 10-mm cerebral CT sections. The four studied cerebral sections were selected above the orbits to protect the lenses, running through the basal nuclei and then toward the vertex.

Perfusion CT data consist of time-contrast enhancement curves registered in each pixel, with the curves linearly related to the time-concentration curves for the iodinated contrast material. The perfusion CT data were analyzed by perfusion CT software

(Vitrea 2). Images of rCBF, rCBV, and MTT were interpreted together on a workstation permitting the use of visual assessment. MCA territory ischemia was divided on CT perfusion images as minor deficit ( $\leq 1/3$  of MCA vascular territory), moderate deficit ( $1/3$ - $2/3$  territory) and severe deficit ( $2/3$  to complete territory) by one of the investigators (RK).

#### DSA and leptomenigeal collaterals:

Leptomeningeal collaterals (LMC) are best studied by conventional digital subtraction angiography (DSA) in emergent setting.<sup>8</sup> After initial evaluation and initiation of IV rt-PA therapy in eligible patients; patients were transported immediately to the neuro-angiographic suite. Transfemoral approach was used to access the target artery. Contrast injection using Visipaque 320 in the internal carotid artery was used to visualize and assess leptomenigeal collaterals and site of occlusion. DSA images acquired prior to treatment were used to grade collateral flow from the anterior cerebral artery to the MCA on a scale ranging from 1 to 5, based on retrograde reconstitution of MCA segments in the late arterial phase. This scoring system was adopted from leptomenigeal collaterals classification as described by Christoforidis et al.<sup>9</sup> (see Table 1)

#### Statistical analysis

We assessed the association between LMC score on digital subtraction angiography (DSA) with various categories of rCBV/ rCBF mismatch on CTP in patients with acute occlusion of M1 or M2 segments. We tested this association using Pearson exact test.

#### Results

We included 16 patients with mean age of 69 years who met our criteria; 10 were men. Ten patients had M1 segment occlusion; with National Institutes of Health Stroke Scale (NIHSS) score ranging from 6-21 (Median NIHSS score 14). Six patients had M2 segment occlusion with NIHSS score ranging from 9-20. Mean

Table 2: Regional cerebral blood flow/ regional cerebral blood volume mismatch and leptomeningeal collateral score in middle cerebral artery occlusion

LMC Score	rCBV/rCBV mismatch		
	Minor	Moderate	Severe
1	1	None	None
2	None	4	1
3	None	5	3
4	1	1	None
M1 segment	None	6	4
M2 segment	2	4	None

time from symptom onset to CTP acquisition was 146 minutes. Time interval between the first angiographic image acquisition and symptom onset among thirteen patients with known time of symptom onset ranged from 144-525 minutes; remaining three patients had unknown time of symptom onset and received endovascular interventions based on CTP mismatch. Five patients received intravenous recombinant tissue plasminogen activator (rt-PA) within 3-hours of symptom onset, prior to endovascular intervention (intra-arterial thrombolytic and/or mechanical thrombectomy).

A total of five patients were found to have early evidence of infarction in the MCA territory on head CT scan prior to the procedure however all changes were less than 1/3rd of MCA territory and each patient had significant rCBV/rCBF mismatch noted on the CTP. Three out of these five patients with evidence of infarction on head CT scan had unknown time of onset, one event was after 3 hours and another one event was less than 2 hours from the symptom onset. Patients with M1-segment occlusion (n=10) had more severe rCBV/rCBF mismatch compared to patients with M2-segment occlusion (p=0.016). LMC score of 1 had minor mismatch compared to moderate to severe deficit mismatch with LMC score of 2 and 4. However LMC score of 4 (n=1) did not have severe mismatch as would be expected but had minor to moderate mismatch. Overall there was no clear association between the extent of leptomeningeal collaterals and severity of rCBV/rCBF mismatch on CTP. (see Table 2)

## Discussion

Astrup et al<sup>10</sup> tried to differentiate between the areas of severe ischemia (state of energy failure, high extra-cellular potassium, and developing infarction) and areas with less severe ischemia "penumbra" (state of electrical failure but sustained energy metabolism and low extra-cellular potassium) in the animal model. In our series of patients with middle cerebral artery occlusion, residual flow in the MCA territory would be mainly dependent on LMC<sup>11</sup> with no contribution from anterior cerebral artery via anterior communicating artery, posterior

cerebral artery via posterior communicating artery or external carotid artery collaterals. Our results suggest that the magnitude of LMCs on DSA does not correlate with the severity of rCBV/rCBF mismatch in patients with MCA occlusion. There may be several explanations for this observation including the technical limitations of resolution in both DSA and CTP. rCBF is dependent on both macrovasculature and microvasculature circulation. DSA typically demonstrates arteries with diameter larger than 100  $\mu$ m. The arterioles that arise from the leptomeningeal arteries are less than 100  $\mu$ m in diameter and supply the capillary bed of the cerebrum. This extensive microcirculation (< 100  $\mu$ m) networks provide the actual blood supply to the brain parenchyma and has been proven to be a potential collateral pathway in patients with ischemic cerebrovascular disease may be relatively invisible on DSA.<sup>12</sup> The lack of visualization of smaller arteriolar networks may explain the discrepancy between CTP mismatch and LMC score. CTP also has limitations in studying penumbra in brain. Currently, CTP only allows the estimation of rCBF, rCBV, and MTT in a limited volume of brain tissue. Other limitations of our analysis include the inability to study the hemodynamic fluctuations which may influence the magnitude of collaterals, possibly rCBF deficits. Presence of LMC may be only a marker of impaired hemodynamic status<sup>8</sup> and not compensatory status. We did not study this factor in detail in our analysis, however none of our patients had hypotension (systolic blood pressure < 90 mmHg). There was also a time lag between the CTP and DSA during which distal embolism of a thrombus within the parent vessel lead to further occlusion of distal branches, compromising the LMC as well as microcirculation. Moreover, it is not merely the presence of LMC but also efficiency of these vessels that need to be taken into account. The efficiency of collateral vessels depends on age, duration of ischemia, and associated co-morbidities.<sup>8</sup>

Despite all the technical and procedural limitations, our analysis suggests that the extent of leptomeningeal collaterals per se on DSA does not explain the extent of mismatch noted on CTP and additional factors need to be accounted for and studied in future.

---

References:

1. Gado M, Marshall J. Clinico-radiological study of collateral circulation after internal carotid and middle cerebral occlusion. *J Neurol Neurosurg Psychiatry*. 1971;34:163-170.
2. Zhu M, Dai J, Li S. Cerebral angiography and MR perfusion images in patients with ischemic cerebral vascular disease. *Chin Med J (Engl)*. 2002;115:1687-1691.
3. Wintermark M, Reichhart M, Thiran J-P, et. al. Prognostic accuracy of cerebral blood flow measurement by perfusion computed tomography, at the time of emergency room admission, in acute stroke patients. *Ann Neurol*. 2002;51:417-432.
4. Wintermark M, Reichhart M, Cuisenaire O, et. al. Comparison of admission perfusion computed tomography and qualitative diffusion – and perfusion-weighted magnetic resonance imaging in acute stroke patients. *Stroke*. 2002;33:2025-2031.
5. Wintermark M, Fischbein NJ, Smith WS, et. al. Accuracy of dynamic perfusion CT with deconvolution in detecting acute hemispheric stroke. *AJNR Am J Neuroradiol*. 2005;26:104-112.
6. Masdeu JC, Irimia P, Asenbaum S, et. al. EFNS guideline on neuroimaging in acute stroke. Report of an EFNS task force. *Eur J Neurol*. 2006;13:1271-1283.
7. Wintermark M, Sesay M, Barbier E, et. al. Comparative overview of brain perfusion imaging techniques. *Stroke*. 2005;36:e83-99.
8. Liebeskind DS. Collateral circulation. *Stroke*. 2003;34:2279-2284.
9. Christoforidis GA, Karakasis C, Mohammad Y, et. al. Predictors of hemorrhage following intra-arterial thrombolysis for acute ischemic stroke: the role of pial collateral formation. *AJNR Am J Neuroradiol*. 2009;30:165-170.
10. Astrup J, Siesjo BK, Symon L. Thresholds in cerebral ischemia – the ischemic penumbra. *Stroke*. 1981;12:723-725.
11. Olsen TS, Larsen B, Herning M, Skriver EB, Lassen NA. Blood flow and vascular reactivity in collaterally perfused brain tissue. Evidence of an ischemic penumbra in patients with acute stroke. *Stroke*. 1983;14:332-341.
12. Moody DM, Bell MA, Challa VR. Features of the cerebral vascular pattern that predict vulnerability to perfusion or oxygenation deficiency: an anatomic study. *AJNR Am J Neuroradiol*. 1990;11:431-439.

**Paper-8:**

**McKinney A, Truwit CL and S Kieffer:  
Reversibility of an "Apparent" Infarct on  
Dynamic Perfusion CT after Lytic Therapy:  
Comment regarding cerebral blood flow and  
blood volume thresholds. AJNR Am J  
Neuroradiol 2006. 27:1391-95**



### Reversibility of an "Apparent" Infarct on Dynamic Perfusion CT after Lytic Therapy: Comment Regarding Cerebral Blood Flow and Blood Volume Thresholds

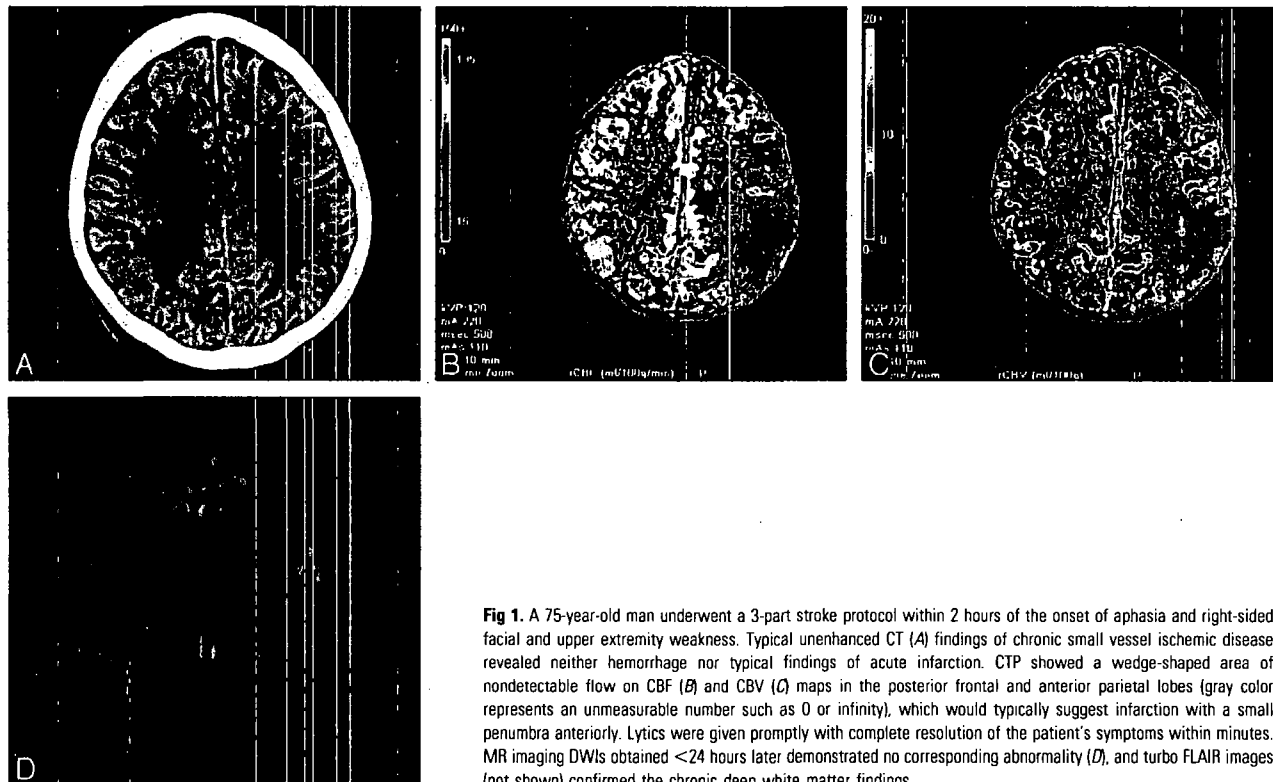
We read with considerable interest the article by Schaefer et al regarding dynamic CT perfusion (CTP) in evaluation of the salvageable ischemic penumbra.<sup>1</sup> The authors of that study, as well as other recent studies,<sup>1-3</sup> refer to the usage of various thresholds and ratios relative to the contralateral side, obtained via dynamic CTP, to evaluate acutely which lesions are likely to progress to infarction in comparison to those that are potentially reversible ischemic lesions. The authors suggest that below a threshold for the cerebral blood volume (CBV) of 2.2 mL/100 g, a threshold for the cerebral blood flow (CBF) of 12.7 mL/100 g/min, a CBV ratio to the opposite side of  $<0.68$ , or CBF ratio of  $<0.32$  leads to irreversible infarction. They state that no patients in whom CBV and/or CBF dropped below these thresholds had normal values and findings seen on follow-up examinations.

We respectfully submit that, despite the experience of these investigators, we have in fact encountered patients whose CTP studies clearly demonstrate focally or regionally absent CBF or CBV—ie, nearly 0—but have a normal appearance on diffusion-weighted imaging (DWI) performed in the acute phase. One such patient is illustrated here, a 75-year-old man presenting with acute onset of right upper extremity weakness, right facial weakness, and aphasia. Unenhanced CT, dynamic CTP, and CT angiography of the brain were performed as part of a 3-step protocol immediately in the same sitting within 2 hours of the onset of symptoms. Neither hemorrhage nor significant low attenuation was noted on the unenhanced CT scan (Fig 1A). The dynamic CTP examination was performed with a multi-section scanner during 2 sequential 40-second dynamic scans (5-minute delay between the 2). This demonstrated a moderate-sized perfusion defect with no detectable CBV in the left posterior frontal and precentral and postcentral regions, consistent with the patient's symptoms (Fig 1B, CBF images; Fig 1C, CBV). CT angiography (not

shown) demonstrated a possible small M3 branch occlusion but no evidence of internal carotid or M1 branch occlusion. Immediately after completion of the stroke protocol and interpretation of the images, intravenous tissue plasminogen activator (tPA) was administered in the emergency department. It was interesting that the patient's symptoms resolved within 2–3 minutes of administration of the tPA bolus. Follow-up MR images obtained just less than 24 hours after onset of symptoms demonstrated the typical findings of chronic small vessel ischemic disease on fluid-attenuated inversion recovery (FLAIR) imaging, with no abnormality on DWI imaging (Fig 1D) in the region of the CBV/CBF abnormality seen on CT perfusion. A tiny, punctuate, potential lesion on DWI (not shown) was noted in the contralateral, right parietal lobe, too small to visualize on the ADC maps, and presumed to be a tiny infarct superimposed on a large amount of leukoariosis. The patient's neurologic status remained baseline (ie, normal) without neurologic sequelae on sequential clinical visits.

Although the etiology is unclear, but presumed to be thromboembolic, this may be related to a complete block of perfusion with no detectable circulating blood volume in the region of abnormality but not long enough to result in infarction. Artifacts can also simulate this abnormality, but in this case no such artifact or motion was noted. Moreover, re-evaluation of the CTP study confirmed that it was performed appropriately and that the contrast bolus appeared adequate. We note that an area of gray depicts an unmeasurable number on our software (Vitrea, Vital Images, Plymouth, Minn), either 0 or infinity (ie, either 0 CBF/CBV or infinity), whereas it seems there may be much variability among different software related to the color scheme used by the software implemented.<sup>1-6</sup>

An earlier article, by Wintermark et al, described false-positive cases of CT perfusion without abnormalities on follow-up imaging<sup>4</sup> but stated that these cases had an element of ischemia with regard to CBF, with elevated mean transit time, but actually had a slightly ele-



**Fig 1.** A 75-year-old man underwent a 3-part stroke protocol within 2 hours of the onset of aphasia and right-sided facial and upper extremity weakness. Typical unenhanced CT (A) findings of chronic small vessel ischemic disease revealed neither hemorrhage nor typical findings of acute infarction. CTP showed a wedge-shaped area of nondetectable flow on CBF (B) and CBV (C) maps in the posterior frontal and anterior parietal lobes (gray color represents an unmeasurable number such as 0 or infinity), which would typically suggest infarction with a small penumbra anteriorly. Lytics were given promptly with complete resolution of the patient's symptoms within minutes. MR imaging DWIs obtained  $<24$  hours later demonstrated no corresponding abnormality (D), and turbo FLAIR images (not shown) confirmed the chronic deep white matter findings.

vated CBV (in contrast to our case), and symptom resolution was considered to be consistent with transient ischemic attacks. In our case, surrounding the complete (or near-complete) perfusion block and near-zero CBV was an area of mildly elevated CBV (Fig 1).

The significance of this observation is that, although the article by Schaefer et al illustrates the utility of CBV and CBF and ratios of these parameters in evaluating the extent of what is likely to infarct, the findings should always be carefully placed in perspective when affecting emergent clinical decision making, in particular with regard to administration of lytic therapy. This study and other recent studies comparing CT perfusion with MR DWI or MR perfusion<sup>2,3,5</sup> are well designed but based on relatively small numbers (<20 with initial CTP and follow-up MR imaging) in light of the overall incidence of acute stroke. Another series by Mayer et al<sup>6</sup> does postulate that this circumstance may occur, where flow rates less than approximately 5 mL/100 g/min might not be discerned from truly zero-flow states in CT-CBF maps, because the noise of the time-attenuation curve may obscure a very low level of flow. Presumably in our case a very minimal amount of CBF and very low CBV was present, but not detectable. Mayer et al urge less emphasis on exact thresholds, stating that these measurements are a marker of a point in time and do not reflect the state of perfusion before and after the perfusion examination. Those authors describe that a decrease of CBV down to 0 is likely not because of true lack of blood-containing capillary attenuation in that region, but rather a failure of contrast enhancement in the region of no detectable flow. Hence, the severity of the CBV defect may not be as relevant as the temporal extension and delay before the tissue is reperfused.<sup>6,7</sup> Therefore, it is plausible that the rare case of a complete discrepancy between CT perfusion CBV and MR DW may exist, particularly if a hyperacute defect is immediately alleviated, whether spontaneously or from lytic therapy. Hence, in light of the occasional "near-zero-flow" situation described here, CBF or CBV values below the threshold should not necessarily drive whether to administer tPA. In a case of a moderate-sized or smaller "complete" perfusion deficit (in other words, no detectable cerebral perfusion or blood volume), intravenous tPA may still be a primary consideration as long as there is no evidence of hemorrhage or significant low attenuation is present on the noncontrast CT scan, and symptoms are clearly within the appropriate time window for intravenous tPA. These patients may occasionally completely reperfuse, with dramatic improvement, and no significant longstanding neurologic sequelae.

A. McKinney

C.L. Truwit

S. Kieffer

Department of Radiology

University of Minnesota Medical School and

Hennepin County Medical Center

Minneapolis, Minn

## References

- Schaefer PW, Roccatagliata L, Ledezma C, et al. First-pass quantitative CT perfusion identifies thresholds for salvageable penumbra in acute stroke patients treated with intra-arterial therapy. *AJNR Am J Neuroradiol* 2006;27:20–25
- Wintermark M, Reichhart M, Cuisenaire O, et al. Comparison of admission perfusion computed tomography and qualitative diffusion- and perfusion-weighted magnetic resonance imaging in acute stroke patients. *Stroke* 2002;33:2025–31
- Galvez M, York GE 2nd, Eastwood JD. CT perfusion parameter values in regions of diffusion abnormalities. *AJNR Am J Neuroradiol* 2004;25:1205–10
- Wintermark M, Fischbein NJ, Smith WS, et al. Accuracy of dynamic perfusion CT with deconvolution in detecting acute hemispheric stroke. *AJNR Am J Neuroradiol* 2005;26:104–12

- Eastwood JD, Lev MH, Wintermark M, et al. Correlation of early dynamic CT perfusion imaging with whole-brain MR diffusion and perfusion imaging in acute hemispheric stroke. *AJNR Am J Neuroradiol* 2003;24:1869–75
- Mayer TE, Hamann GF, Baranczyk J, et al. Dynamic CT perfusion imaging of acute stroke. *AJNR Am J Neuroradiol* 2000;21:1441–49
- Heiss WD, Grond M, Thiel A, et al. Tissue at risk of infarction rescued by early reperfusion: a positron emission tomography study in systemic recombinant tissue plasminogen activator thrombolysis of acute stroke. *J Cereb Blood Flow Metab* 1998;18:1298–307

## Reply:

We thank Drs. McKinney et al for their interest in our manuscript<sup>1</sup> and for their thoughtful comments regarding the potential role of CT perfusion imaging (CTP) in the triage of acute stroke patients. Their case, of a patient imaged within 3 hours of stroke onset, with an apparent ischemic lesion on both CT-cerebral blood volume (CBV) and CT-cerebral blood flow (CBF) maps, but with normal diffusion-weighted MR imaging (DWI) at 24 hours, raises a number of important issues. Explanations for this discordance between the suggestion of infarct on the admission CBV maps and the absence of infarct on the follow-up DWI scan could be either physiologic or technical.

First, we emphasize that an implicit goal of "advanced" stroke imaging, whether using DWI/perfusion-weighted MR imaging (PWI) or CT CBV/CBF mismatch, is to extend the time window for treatment so that it can be applied to patients beyond a narrow 3-hour period. We are not aware of any paper, including our own, that advocates exclusion from intravenous thrombolysis based only on early (less than 3 hours) MR imaging or CTP findings. Indeed, there are rare but well-documented examples in the literature of true DWI reversibility in the setting of early, complete reperfusion of ischemic regions.<sup>2–4</sup> We have occasionally observed a similar phenomenon with CT angiography source images (which are blood volume weighted), though no CBV reversibility occurred in our study cohort (none of whom recanalized within 3 hours of stroke onset).<sup>1</sup>

Perfusion thresholds for tissue viability likely depend on the timing of reperfusion and are likely significantly lower at very early time points following vascular occlusion. For example, Jones et al<sup>5</sup> demonstrated in a primate model that the CBF threshold for viability associated with only 2–3 hours of middle cerebral artery (MCA) occlusion was 10–12 mL/100 g/min, whereas this threshold rose to 17–18 mL/100 g/min when the MCA was permanently occluded. The case presented by McKinney et al might be explained by recanalization of the occluded MCA branch just after the CT examination. Such early complete reperfusion has the potential to reverse the acute CT-CBV lesion, with subsequent normalization of the apparent diffusion coefficient (ADC) at 24 hours. This ADC normalization could reflect either truly normal or "pseudonormal" tissue, with the latter being brain parenchyma that remains destined to infarct, despite a transient restoration of energy metabolism and hence normal proton diffusion at early follow-up. In fact, most patients in Dr Kidwell's paper<sup>2</sup> who had reversal of restricted diffusion immediately following intraarterial thrombolysis, showed encephalomalacic change in the initially ischemic regions at 1-week follow-up.

The discrepancy between the initial CBV and the subsequent DWI images could also have occurred for technical reasons. A neck CTA was not obtained in this case. If there had been a proximal internal carotid artery occlusion or severe stenosis, contrast filling of the ischemic territory could have been delayed. This, in combination with the authors' short CTP acquisition time of 40 seconds and a possible M3 occlusion, could have resulted in a falsely low CT-CBV measurement, overestimating the degree of potentially infarcted tissue. We therefore recommend a CTP acquisition time of at least 50–60 seconds to re-

duce this problem of “perfusion weighting” of the blood volume maps. Even without an internal carotid artery stenosis or occlusion, the matched CBV-CBF lesion shown in this case could have resulted in part from poor filling distal to the M3 lesion described on the CTA (not shown). Had the acquisition time been longer, additional contrast may have reached the territory of the CBV lesion via collateral flow.

Poor signal intensity-to-noise ratio on the CTP source images could also lead to false-positive perfusion maps. We recommend that at least 45–50 mL of contrast with 300 mg iodine/mL (or its equivalent) be administered when performing CTP to achieve adequate signal intensity. In addition, we have found that thicker CTP map sections (10 mm rather than 5 mm) have an improved signal intensity-to-noise ratio.<sup>6</sup> Also, accurate quantification of both CBF and mean transit time is optimized with a software package capable of deconvolution. Finally, other factors, such as streak and motion artifact, could result in false-positive CBV images. Careful review of the CTP source images, as well as the arterial and tissue time-course curves, is mandatory.

In summary, there are a number of possible explanations, both physiologic and technical, for the discrepancy between the CBV and DWI findings in the case presented. We again are grateful to Drs. McKinney et al for calling these potential pitfalls of CTP acquisition and interpretation to the attention of *AJNR* readers.

## References

- Schaefer PW, Roccatagliata L, Ledezma C, et al. First-pass quantitative CT perfusion identifies thresholds for salvageable penumbra in acute stroke patients treated with intra-arterial therapy. *AJNR Am J Neuroradiol* 2006;27:20–5
- Kidwell CS, Saver JL, Starkman S, et al. Late secondary ischemic injury in patients receiving intraarterial thrombolysis. *Ann Neurol* 2002;52:698–703
- Schaefer PW, Hassankhani A, Putman C, et al. Characterization and evolution of diffusion MR imaging abnormalities in stroke patients undergoing intra-arterial thrombolysis. *AJNR Am J Neuroradiol* 2004;25:951–7
- Grant PE, He J, Halpern EF, et al. Frequency and clinical context of decreased apparent diffusion coefficient reversal in the human brain. *Radiology* 2001;221:43–50
- Jones TH, Morawetz RB, Crowell RM, et al. Thresholds of focal cerebral ischemia in awake monkeys. *J Neurosurg* 1981;54:773–82
- Hamedanchi R, Camargo EC, Gulick SM, et al. Improved signal-to-noise ratio in thick versus thin slice CT perfusion maps. In: *Stroke* 2006;37:647–745. Proceedings of the 31st International Stroke Conference, Kissimmee, FL, 2006

P.W. Schaefer, R.G. Gonzalez, and M.H. Lev  
*Department of Radiology, Neuroradiology Division*  
 W.J. Koroshetz  
*Department of Neurology*  
*Massachusetts General Hospital*  
*Boston, Mass*

## Hyrtl's Fissure

The authors of “Hyrtl's Fissure: A Case of Spontaneous CSF Otorrhea” claim the first documented case of a CSF leak via abnormal persistence of Hyrtl's (tympaenomeningeal) fissure.<sup>1</sup> I was surprised to read this because in 2002 my coauthors and I reported on a child presenting with meningitis and found during surgery to have a CSF leak from Hyrtl's fissure.<sup>2</sup> We included a CT image almost identical to the single case in Jegoux et al's paper in addition to 3 other illustrated examples resulting in clinical complications of one sort or another. We also reviewed developmental anatomy and the historical provenance of the eponym.

I am not sure how Jegoux et al missed our paper—titled “Hyrtl's Fissure”—during their literature review. Searching PubMed for “Hyrtl's fissure” produces only 3 responses: their paper, ours, and one

by Gacek et al that we both quoted.<sup>3</sup> Try the same on Google, and our paper is the first result.

Had they read our paper Jegoux et al would have learned, as I did, that Hyrtl might not have been responsible for describing “his” fissure. Jegoux et al write about “the second accessory canal described by Hyrtl in 1936” and quote a supporting reference from an Austrian medical journal<sup>4</sup> that is also cited in other articles that refer to Hyrtl's fissure. That paper, however, may not exist.

First, Hyrtl died 42 years earlier, in 1894. Furthermore, a search of Viennese medical archives on our behalf failed to unearth this or any similar article by Hyrtl referring to the fissure. Schuknecht, quoted by Spector, had concluded some years earlier that Hyrtl probably did not describe the fissure and that the 1936 reference was a misquote.<sup>5</sup> He was also unsuccessful in trying to unearth the paper in Vienna or find evidence for Hyrtl's description in any of his other articles. I searched major medical libraries in London without success and read the nineteenth-century English-language articles by Hyrtl quoted in our paper. They do not mention the fissure.

Jegoux et al quote Spector: “Anton and Bast renamed Hyrtl's fissure ‘the tympanomeningeal fissure or hiatus.’”<sup>6</sup> Again, it may be true, but we were unable to find evidence that it is so. Spector referred to 3 textbooks, 2 of which do not state explicitly that Anson and Bast were responsible for renaming Hyrtl's fissure, and the third was a histopathology text published in 1947 that I was unable to find in any London library (including the on-line catalogue of the British Library). A review of papers by Anson and Bast was similarly unrewarding.

The historical debate is incidental, but it illustrates an important lesson that I learned during the preparation of our paper. A reference should not be transposed from one article to another without reading the original paper to confirm that it says what you think it does.

P.M. Rich  
*Department of Neuroradiology*  
*Atkinson Morley Wing*  
*St. George's Hospital*  
*London, UK*

## References

- Jegoux F, Malard O, Gayet-Delacroix M, et al. Hyrtl's fissure: a case of spontaneous cerebrospinal fluid otorrhea. *AJNR Am J Neuroradiol* 2005;26:963–66
- Rich PM, Graham J, Phelps PD. Hyrtl's fissure. *Otol Neurotol* 2002;23:476–82
- Gacek RR, Leipzig B. Congenital cerebrospinal otorrhea. *Ann Otol Rhinol Laryngol* 1979;88:358–65
- Hyrtl J. Neue Beobachtungen aus dem gebiete der Menschlichen und Vergleichenden: Anatomie Medizinische Jahrbucher des. *Oestr Reich Staates* 1936;10:457–66
- Spector GJ. Developmental temporal bone anatomy and its clinical significance: variations on themes by H F Schuknecht. *Ann Otol Rhinol Laryngol Suppl* 1984;112:101–09
- Spector GJ, Lee D, Carr C, et al. Later stages of development of the periotic duct and its adjacent area in the human fetus: *Laryngoscope* 1990;90:1–31

## Reply:

I must first apologize for having forgotten to cite Rich et al<sup>1</sup> in our references. Because Hyrtl's fissure is still obviously a rare entity, there are several good reasons for this article to be cited. Their article is of interest, so the omission was more a mistake than a voluntary exclusion. Between publication of Rich et al and the date we submitted our manuscript for the first time, several months passed, during which time our bibliography had not been updated. Case reports are valuable for a number of different reasons, because they provide a unique look at less common disorders or diseases and are also more consistent with the practical demands of nonacademics. They are an excel-

**papers:**

**Nagar VA, Karagulle Kendi AT, McKinney AM, Truwit CL. Detection of luxury perfusion via utilization of time-to-peak, delay, transit time, and blood volume maps in patients initially suspected to have acute infarction. *ASNR poster*. 2008. May 31 – June 5, 2008.**



# Detection of Luxury Perfusion via Utilization of Time-To-Peak, Delay, Transit Time, and Blood Volume Maps in Patients Initially Suspected to Have Acute Infarction

Nagar V.A., M.D., Karagulle Kendi A.T., M.D., McKinney A.M., M.D., Truwit C.L., M.D.

Division of Neuroradiology, University of Minnesota Medical Center & Department of Radiology, Hennepin County Medical Center, Minneapolis, MN, USA

## ABSTRACT

**Purpose**  
This preliminary study addresses the hyperperfusion phenomenon in cerebral infarcts on CT perfusion (CTP) that occasionally may mask subacute (and rarely) acute infarcts. We evaluate the use of time to peak (TTP), Delay, cerebral blood volume (CBV), and mean transit time (MTT) maps via dynamic CTP in detecting these infarcts.

## Materials & Methods

We retrospectively reviewed the neuroradiology imaging data base from 2005-2007 for CTP exams performed in patients who presented with stroke or stroke-like symptoms. Of the 370 examinations, there were 10 patients in which the CBV and CBF were not visually decreased; with clearly hypodense infarct on CT or restricted diffusion on MRI > 2 cm size (so it could be measurable on CTP). Internal review board approval was obtained. Using CTP software (VITREA, Minnetonka, MN), MTT, TTP, Delay, CBF and CBV were calculated in areas of infarction and (via an "automirror" function) in the contralateral, unaffected hemisphere. The region of interest was drawn in the affected area seen on CT or diffusion MRI. Two neuroradiologists reviewed these CTP maps in consensus. Means were obtained for each parameter; a paired student t-test was applied.

The time to presentation was 7.7 days (18 hours-105 hours) or symptom onset. Two patients presented in the acute (but not hyperacute) phase of stroke (18 and 24 hours). There were five males and five females (mean age 58.7 years). Infarcts were in the following distributions: MCA (5), ACA (3), PCA (1) and PCA (1). The difference between the mean values of TTP, MTT, and CBV on the affected versus the contralateral hemisphere was statistically significant at 95% confidence interval ( $p=0.005, 0.027, 0.03$ ; respectively). Difference in the mean Delay was probably significant ( $p=0.077$ ), but not at the 95% confidence interval. The difference between the mean values of CBF was not statistically significant ( $p=0.76$ ). The TTP, MTT, CBV, and Delay values increased by a mean of 10%, 38.1%, 26.7% and 57.9%, respectively.

## INTRODUCTION

CT Perfusion (CTP) has become a routine examination at some centers in the evaluation for acute stroke, as the sensitivity and specificity of its markers in the hyperacute stage has been shown to be >90% and the abnormalities on CTP have been shown to correlate with final infarct volume on diffusion-weighted imaging (DWI) (1,2). The use of CTP to identify "tissue at risk" has been shown to alter decision-making for intravenous thrombolysis and affect outcomes (3,4). Dynamic scanning via CT perfusion is a relatively rapid and widely available imaging method that can be used in the hyperacute or acute phase (traditionally <6 hours) to accurately differentiate between the penumbra of ischemic versus infarcted tissue (5,6).

Typically, CTP demonstrates the following findings in acutely ischemic cerebrum: elevated mean transit time (MTT), elevated time to peak (TTP), decreased cerebral blood flow (CBF, 10-20cc/100g/min), and normal or increased cerebral blood volume (CBV). In acute infarction, CTP typically demonstrates increased MTT, markedly reduced CBF (<10-13cc/100g/min) and moderately reduced CBV (5,6,7).

Following acute ischemic stroke, the return of CBF in excess of metabolic requirement has been termed "luxury perfusion." It is believed that the excess CBF may relate to dysfunctional autoregulation. PET and SPECT studies have demonstrated that areas of hyperperfusion with high CBV correlate with high rates of cerebral oxygen utilization (8,9). Although defined in the PET literature, luxury perfusion is only briefly mentioned in the available literature on CT perfusion, and without distinct criteria for recognizing this imaging appearance (2,8). Recognition of this pattern of luxury perfusion is important to avoid, as the appearance of falsely preserved CBF or CBV could potentially lead to misinterpretation as a false negative. However, as luxury perfusion could potentially mask acute or subacute stage infarcts, one potential indicator in the setting of nearly normal CBV/CBF could be the MTT, as this has been shown to be the most sensitive for acute infarcts, but far less specific (10). Additionally, TTP, or another yet to be developed algorithm/measurement could also be employed to detect this situation. The purpose of this study was to develop criteria for detecting the phenomenon of luxury perfusion via CTP. Our hypothesis was that the CBF and CBV would be near normal, but that the MTT, TTP, and a vendor-specific map termed "delay" images would be more sensitive indicators of this phenomenon on CTP.

## MATERIALS AND METHODS

This retrospective evaluation was approved by an IRB. Over a 3 year period (1/2005-1/2008), 370 CTP exams for this study were retrospectively collected from the PACS database, and reviewed for "false negatives," based on the appearance and measurements of CBF and CBV maps. The criteria for inclusion were a visually nearly normal CBF and CBV, with either DWI MRI or serial CT scans clearly demonstrating an infarct >2cm size. Excluded were patients with brainstem infarction, CNS involvement by meningitis, tumor, inflammatory disorder, or radiation. Ultimately, 10 were included.

**Technique:** The CTP examination consisted of a dynamic, first-pass acquisition, of 2 sequential 55-sec dynamic scans (no delay between the two scans). The two separate acquisitions yielded four contiguous 10 mm thick slices (32x 1.25 mm collimation) of the area of interest. A bolus of 36 ml of nonionic contrast medium was administered via the antecubital vein for each acquisition. All patients underwent a follow up examination with either DWI MRI or NECT 1-10 days after the initial examination to confirm the infarct.

### Analysis of scans:

**Non-contrast CT scans:** NECT images were reviewed by signs of acute infarction, areas of decreased attenuation, insular ribbon sign and increased attenuation within a vessel.

### Perfusion CT scans:

The axial images from perfusion CT studies were evaluated by consensus of two neuroradiologists using CTP software (VITREA, Minnetonka, MN). MTT, TTP, Delay, CBF and CBV were calculated in areas of infarction and (via an "automirror" function) in the contralateral, unaffected hemisphere. The region of interest was drawn in the area affected on CT or DWI.

### Statistical analysis:

Means were obtained for each parameter. A paired student t-test was applied to compare CTP values between the affected areas and the homologous areas in the contralateral hemisphere. P values of <0.05 were considered statistically significant.

Pt No.	Age	Sex	CBFA	CBFB	Mean/Delay	CBVA	CBVB	Mean	MTTA	MTTB	Mean	TTPA	TTPB	Mean	Delay A	Delay B	Mean
1	82	F	45.4	63.0	-27.9	3.9	3.4	73.3	8.0	3.1	131.0	19.9	15.6	25.6	4.6	0.9	411.0
2	51	M	41.4	47.3	-12.4	2.8	2.4	18.0	3.9	2.9	34.3	28.3	24.7	1.5	4.0	3.7	24.3
3	71	F	27.7	23.8	3.4	2.1	1.8	42.1	6.8	4.9	38.7	30.7	29.2	5.1	2.8	2.2	27.2
4	49	M	31.7	46.3	-11.6	4.4	3.4	33.3	5.8	4.8	28.2	20.7	17.0	2.7	4.5	3.8	18.4
5	72	M	18.0	23.8	-24.2	2.4	2.1	33.0	9.7	6.2	36.4	28.0	24.1	17.0	5.8	3.9	48.7
6	68	F	60.8	45.8	14.4	3.7	3.8	30.0	5.8	4.9	14.3	13.4	15.1	1.9	4.6	3.8	17.9
7	74	F	33.0	43.9	-11.8	4.4	3.1	39.8	3.3	4.1	19.7	20.4	20.1	14.4	0.8	2.2	19.1
8	55	M	44.5	46.8	-4.9	2.2	1.7	29.4	3.1	2.2	40.1	23.1	21.4	7.9	0.7	0.6	16.6
9	38	M	27.5	27.5	0.0	2.1	1.9	10.5	4.5	4.1	9.7	19.3	18.6	3.7	3.9	3.4	14.7
10	33	F	36.8	86.0	-109.9	4.2	3.9	7.7	3.7	2.9	27.6	14.1	13.5	4.4	0.8	0.5	60.0
Mean	58.7		48.8	47.7		3.9	3.2	28.8	5.7	4.3	38.1	22.0	20.0	10.0	3.3	2.3	38.0

Table 1. Values of CBV, CBF and MTT in a (affected vascular territories) and u (unaffected contralateral vascular territories)

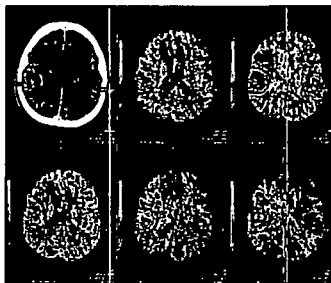


Figure 1. CT perfusion maps reveal a focal area of increased MTT in the right periorbital lobe. An ROI was drawn over this affected area as well as the contralateral hemisphere using an "automirror function". Note the increased CBF, increased CBF, elevated TTP and increased "Delay" in the affected area.

## RESULTS

Eight patients were evaluated in the subacute phase of infarct (range 3-10 days) and two presented in the acute phase (range 18-24 hrs). Patients included 5 males and 5 females, with a mean age of 58.7 years (range 23-82).

The results of CBV, CBF, MTT, TTP, and delay measurements from affected and contralateral unaffected areas are expressed in Table 1. Mean MTT and TTP values in the affected site were higher than in the contralateral site.

The difference between the means of TTP, MTT, and CBV on the affected hemisphere versus contralaterally was statistically significant at the 95% interval ( $p=0.005, 0.027, 0.03$  respectively). 90% of patients had a CBV, MTT and TTP greater on the affected side. Only one patient had a decreased MTT (-20%), with CBV and CBF nearly normal.

Although the Delay was higher in the affected site in 90% of patients (mean 3.3 seconds), the difference in the mean Delay was probably significant ( $p=0.077$ ), but not at the 95% confidence interval.

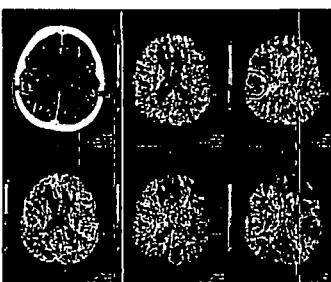


Figure 1. CT perfusion maps reveal a focal area of increased MTT in the right periorbital lobe. An ROI was drawn over this affected area as well as the contralateral hemisphere using an "automirror function". Note the increased CBV, increased CBF, elevated TTP and increased "Delay" in the affected area.

Regarding the CBF, only 50% of patients demonstrated a lower CBF on the affected side; the difference between the mean values of CBF from side-to-side was not statistically significant ( $p=0.76$ ). Hence, the CBF could not reliably detect infarction.

## CONCLUSIONS

Following acute ischemic stroke, the return of CBF in excess of metabolic requirement has been termed "luxury perfusion" by Lassen et al (11). This may be demonstrated as a combination of hyperemia (increased CBV) and hyperperfusion (increased CBF) rather than oligemia in a territory of ischemic stroke after the hyperacute phase. This misleading appearance could lead to incorrect interpretation of the CBV and CBF being preserved and "viable" tissue being present. While this typically occurs in the subacute phase, it may occasionally occur acutely (age < 3 days), presumably related flow-metabolism uncoupling, together with postischemic "vasoplegia" (12). This can also be seen in the acute or hyperacute stage after reperfusion of infarcted tissue following thrombolysis (8).

In patients with irreversible cerebral infarction who demonstrate normal CBF and mildly elevated CBV on CTP, a combination of the MTT, and Delay maps may aid in detecting the uncommon state of "luxury perfusion." Although the MTT appears to be the most sensitive for detecting this state, other etiologies can cause elevations in MTT, such as chronic oligemia/ischemia, Moya-moya, and in cerebral parenchyma supplied by critical stenoses more proximally. Hence, comparing the CTP MTT and delay images to routine non-contrast CT (hypodense) or DWI MRI (bright signal and restricted) helps confirm this diagnosis.

Recognition of the appearance of luxury perfusion using various parameters on CTP studies may prevent false negative misinterpretation of truly infarcted tissue as "viable," "normal" or simply "oligemic" in the setting of suspected acute ischemic stroke. Furthermore, the use and measurements yielded by CTP in the state of luxury perfusion may eventually contribute to our understanding the mechanisms of hemodynamic compensation in the evolution of cerebral ischemia/infarction.

## REFERENCES

- Eastwood JD et al. Correlation of early dynamic CT perfusion imaging with whole-brain MR diffusion and perfusion imaging in acute hemispheric stroke. *AJNR*. Am J Neuroradiol 2003 Oct; 24(9):1869-75.
- Wintermark M et al. Comparison of CT perfusion and magnetic resonance imaging in selecting stroke patients for acute treatment. *Neurology*. 2007 Feb 27; 68(9):994-7.
- Kilosa S et al. Perfusion CT in acute stroke: prediction of vessel recanalization and clinical outcome in intravenous thrombolytic therapy. *Eur Radiol*. 2007 Oct; 17(10):2491-8.
- Lee JY et al. Prediction of clinical outcome with baseline and 24-hour perfusion CT in acute middle cerebral artery territory ischemic stroke treated with intravenous recombinant tissue plasminogen activator. *Neuroradiology*. 2008 Jan 10.
- Murphy JD et al. Identification of penumbra and infarct in acute ischemic stroke using computed tomography perfusion-derived blood flow and blood volume measurements. *Stroke*. 2006; 37:1771-1777.
- Srinivasan A et al. State-of-art imaging of acute stroke. *RadioGraphics*. 2006; 26:73-95.
- Schaefer PW et al. First-pass quantitative CT perfusion identifies thrombolysis for non-eligible patients in acute stroke patients treated with intravenous thrombolysis. *AJNR*. Am J Neuroradiol. 2006 Jan; 27(1):30-5.
- Nagy ZS et al. Hyperperfusion on perfusion computed tomography following revascularization for acute stroke. *Acta Radiologica*. 2005; 46:610-615.
- Morimoto T et al. "Luxury perfusion" with 99mTc-ASMP and 133I-LAD-SPECT imaging during the subacute phase of stroke. *Eur J Nucl Med*. 1990; 16(1):17-22.
- Wintermark M et al. Acute dynamic perfusion CT with deconvolution in detecting acute hemispheric stroke. *Am J Neuroradiol*. 2005; 26:104-112.
- Lassen NA. The luxury-perfusion syndrome and its possible relation to acute metabolic acidosis localized within the brain. *Lancet*. 1966; 2:1113-1115.
- Marcil G et al. Early postischemic hyperperfusion: pathophysiological insights from positron emission tomography. *J Cereb Blood Flow Metab*. 1999 May; 19(5):667-82.

**Paper-10:**

**Nagar VA., McKinney AM, Karagulle AT, Truwit CL: Reperfusion phenomenon masking acute and sub acute infarcts at dynamic perfusion CT: confirmation by fusion of CT and diffusion-weighted MR images. *AJR* 2009; 193:1629–1638**

# Reperfusion Phenomenon Masking Acute and Subacute Infarcts at Dynamic Perfusion CT: Confirmation by Fusion of CT and Diffusion-Weighted MR Images

Veena A. Nagar<sup>1</sup>  
Alexander M. McKinney  
Ayse T. Karagulle  
Charles L. Truwit

**OBJECTIVE.** The purpose of this study was to evaluate cerebral blood flow, cerebral blood volume, mean transit time, time to peak, and delay in a selected sample of patients with visually normal or increased cerebral blood volume to facilitate detection of a posts ischemic CT perfusion hyperperfusion–reperfusion phenomenon that may mask subacute and acute infarcts.

**MATERIALS AND METHODS.** Ten patients were included who had visually normal or elevated cerebral blood volume in infarcts larger than 1.5 cm confirmed on diffusion-weighted MR images within 48 hours of perfusion CT. The cases were selected from 371 perfusion CT studies of stroke patients (99 associated with positive diffusion-weighted imaging findings) reviewed over 2.5 years on a 64-MDCT scanner. The perfusion CT images were fused to the diffusion-weighted images for measurement of cerebral blood volume, cerebral blood flow, mean transit time, time to peak, and delay in each infarct versus the contralateral hemisphere. Two neuroradiologists reviewed the images in consensus.

**RESULTS.** The mean time between symptom onset and perfusion CT was 3.9 days. Infarcts were in the middle cerebral artery ( $n = 7$ ) and posterior cerebral artery ( $n = 3$ ) distributions. Significant differences versus the contralateral finding were found in cerebral blood volume ( $p = 0.016$ ; mean increase, 30.0%), mean transit time ( $p = 0.007$ ; mean increase, 38.1%), time to peak ( $p = 0.005$ ; mean increase, 17.7%), and delay ( $p = 0.030$ ; mean increase, 124.9%). The difference in cerebral blood flow ( $p = 0.785$ ; mean increase, 1.8%) was not statistically significant. Infarcts became enhanced on the dynamic perfusion CT images of eight of 10 patients and on the contrast-enhanced T1-weighted MR images of six of nine patients.

**CONCLUSION.** Visual inspection of cerebral blood volume and cerebral blood flow maps alone is insufficient in the evaluation of infarcts. Mean transit time, time to peak, and delay maps also should be reviewed with dynamic source images to prevent misinterpretation of findings as false-negative. This phenomenon is unlikely to occur hyperacutely (< 8 hours after onset).

**Keywords:** cerebral infarction, CT perfusion, diffusion-weighted imaging, fusion, infarct, stroke

DOI:10.2214/AJR.09.2664

Received March 1, 2009; accepted after revision May 22, 2009.

A. M. McKinney and C. L. Truwit serve on the medical advisory board of Vital Images.

<sup>1</sup>All authors: Department of Radiology, University of Minnesota and Hennepin County Medical Center, 701 Park Ave., Minneapolis MN, 55415. Address correspondence to A. M. McKinney.

AJR 2009; 193:1629–1638

0361–803X/09/1936–1629

© American Roentgen Ray Society

**D**ynamic scanning with perfusion CT is a relatively rapid and widely available imaging method that can be used in the hyperacute (traditionally < 6–8 hours) or acute phase of cerebral infarction to accurately differentiate the penumbra of ischemic tissue and infarcted tissue [1–7]. The sensitivity and specificity of perfusion CT markers in the hyperacute stage of infarction have been found to be greater than 90%, cerebral blood volume (CBV) abnormalities at perfusion CT have been found to correlate with final infarct volume at diffusion-weighted MRI (DWI), and findings at perfusion CT usually lead to the same treatment decisions as those based on DWI findings [1–7]. The use of perfusion CT to identify tissue at risk has been found to al-

ter decision making regarding intravascular thrombolysis and to affect outcome [3, 4]. In acutely ischemic, but not yet frankly infarcted cerebrum, perfusion CT typically shows decreased cerebral blood flow (CBF) (10–20 mL/100 g/min), normal or increased CBV, elevated mean transit time (MTT), and elevated time to peak (TTP). In acute infarction, perfusion CT typically shows markedly reduced CBF (< 10–13 mL/100 g/min), increased MTT and TTP with moderately reduced CBV, and delayed or no arrival of contrast material on enhanced dynamic images [3–7].

After acute ischemic infarction, the return of CBF to normal or even to levels in excess of metabolic requirement by reperfusion or hyperperfusion has been termed luxury

## Nagar et al.

perfusion [8–15], which may relate to dysfunctional autoregulation. The phenomenon was initially described at catheter angiography, but subsequent radionuclide studies confirmed that such areas of infarction may have relative hyperperfusion and normal or elevated CBV and CBF in entirely infarcted or partially viable, mostly infarcted regions [8–15]. Although this phenomenon has typically been described as occurring in the subacute phase (72 hours or more after the onset of symptoms), hyperperfusion also has been found as early as within the first 24 hours, which many authors [8–16] have postulated results either from revascularization with development of collateral flow or from endothelial injury. This phenomenon on perfusion CT has been sparsely discussed except for a small number of reports without criteria for recognizing this imaging appearance [10, 11, 16]. Recognition of the pattern is important because falsely normal or mildly elevated CBV and CBF findings can lead to misinterpretation as false-negative evidence of infarction [16].

Because reperfusion or hyperperfusion can mask late acute or early subacute infarcts on CBV and CBF maps, the need exists to describe markers of infarction other than CBV on perfusion CT images. Some authors have suggested that MTT or TTP can aid in confirmation of the presence of infarcts if abnormalities are suspected on unenhanced CT or dynamic source perfusion CT images [16]. Over a 2.5-year period, after noticing several patients with visual evidence of no decrease in CBV but clear findings of an infarct larger than 1.5 cm at DWI, we set out to further evaluate this phenomenon with perfusion CT correlated with DWI. The purpose of this study was to determine criteria for identifying such a state of reperfusion–hyperperfusion with various perfusion CT parameters by confirming involvement using fusion of CT to DW images. Our hypothesis was that if CBV was not visually decreased, assessment of MTT, TTP, and delay in combination with review of the dynamic source perfusion CT and unenhanced CT images might be useful for detecting the reperfusion–hyperperfusion phenomenon.

## Materials and Methods

### Patient Selection

Institutional review board approval was obtained. The images from 371 perfusion CT examinations performed over a 2.5-year period with a 64-MDCT scanner as part of a hospital protocol

to rule out stroke were collected from the PACS database. Each set of images was retrospectively reviewed for the appearance of visually normal or elevated CBV in the presence of the reference standard for infarction, which was the presence of reduced diffusion at MRI. MRI also excluded other potential causes of the unenhanced CT and perfusion CT abnormalities. At our institution, a level I trauma and stroke referral center, if acute stroke is suspected (even if time of onset is uncertain), perfusion CT has been the initial technique of choice after and in combination with unenhanced CT and CT angiography.

Inclusion in the study required that all three of the following criteria be met: visually nonreduced CBV at perfusion CT, low attenuation on unenhanced CT images (obtained immediately before perfusion CT) or on dynamic enhanced source perfusion CT images, and clear depiction of an infarct larger than 1.5 cm in greatest axial diameter on DW images obtained within 48 hours of unenhanced CT and in the same general location of the abnormality on unenhanced CT or dynamic source images. Ultimately, 10 such patients (of the 99 with positive DWI findings) had this appearance confirmed with DWI. Four of the 10 had already undergone MRI (perfusion CT was performed afterward for these four patients because of acute worsening of symptoms and to evaluate for a larger area of ischemia).

Because involved regions with a CBV less than approximately 0.6 times (60% of) the unaffected hemisphere have been found to typically progress to infarction, patients with a visually low CBV relative to the opposite side were not included [7, 17]. During this period, the other 89 patients with available DW images with positive findings who also underwent perfusion CT were not included for perfusion CT parameter measurements either because an infarct larger than 1.5 cm was present (but CBV was visibly reduced) or because the infarct visualized on DW images was lacunar (traditionally defined as size < 1.5 cm) [18]. Notably, the perfusion CT images of six other patients (outside the 99) who underwent both perfusion CT and DWI were not submitted for review because either the region of interest (ROI) (positive findings on DW images) was not covered by perfusion CT or patient motion rendered the perfusion CT or DW images uninterpretable. Patients with hemorrhagic infarcts (> 1 cm), brainstem-only infarcts (due to the inherent difficulty of characterizing this area with perfusion CT), traumatic injury, aneurysmal hemorrhage, or cerebral inflammation or neoplasms also were excluded. Table 1 shows the ages and symptoms of the patients, the timing of the perfusion CT and MRI examinations, and any therapy administered between perfusion CT and MRI.

### Review of Clinical Records

The clinical records were reviewed to confirm infarction in the 10 included patients and to confirm the time of symptom onset. We recorded any therapy or invasive procedure ( $n = 2$ ) performed in the interim between symptom onset and perfusion CT or in the interim between perfusion CT and DWI, such as IV or intraarterial administration of thrombolytic medication, stenting, surgery, or catheter angiography (Table 1). Long-term clinical follow-up findings were not accessible and thus not recorded.

### Technique

Before dynamic perfusion CT, while the patient was in the CT scanner, the unenhanced CT images were reviewed by a radiology resident or neuroradiology fellow to exclude the presence of hemorrhage and to confirm the level of interest before dynamic perfusion CT acquisition. According to hospital protocol, perfusion CT was not performed if a visible definite area of hemorrhage was visualized on unenhanced CT images. Any questionable cases were shown to a staff neuroradiologist before perfusion CT. The perfusion CT examinations were conducted as part of a stroke protocol (unenhanced CT followed by CT angiography, followed 5 minutes later by perfusion CT) with a 64-MDCT scanner. Imaging consisted of two first-pass acquisitions of sequential 55- to 60-second dynamic scans (1 image/s) with no delay between the two. Each of the two acquisitions yielded 40 mm of coverage in four 10-mm-thick contiguous slices ( $32 \times 1.25$  mm collimation, 120 kV, 175 mAs). For each acquisition, 36–40 mL of nonionic contrast medium (iohexol, Omnipaque 350 mg/mL, GE Healthcare) was administered through an 18-gauge or wider needle in the antecubital vein for a total of 72–80 mL of IV contrast material. Regarding the two separate levels scanned for each perfusion CT examination, one level typically centered on the basal ganglia, and the other was at the top of the lateral ventricles, unless another area had been examined at unenhanced CT.

### Review of Unenhanced CT Scans and MR Images

Two staff neuroradiologists with more than 5 years of experience in perfusion CT interpretation reviewed the unenhanced CT, perfusion CT, and MR images. Axial DWI ( $b = 1,000$ ), FLAIR, unenhanced T1-weighted and T2\*-weighted gradient-echo sequences were standard in examinations of the 10 patients who underwent MRI. A gadolinium-enhanced T1-weighted sequence was available in nine patients. The date of the CT or MRI examination with the longest follow-up interval was recorded. The presence of atrophy was confirmed if the follow-up period was longer than



AJR:193, December 2009

**TABLE 1: Patient Details**

Patient No.	Age (y)	Sex	Clinical History	Time After Symptom Onset (d)	Infarct Territory <sup>a</sup>	Patency	Imaging Technique	Time From Perfusion CT to MRI, Follow-Up MRI	T1-Weighted MRI Enhancement	Dynamic Perfusion CT Enhancement	Follow-Up CT or MRI <sup>b</sup>	Therapy or Recanalization <sup>c</sup>
1	82	F	Left-sided weakness	4	RMCA	M1 > 70% stenosis	CTA, MRA	1 d before, DWI positive; 14 d, DWI negative	Minimal	Mild	CT 35 d, mild atrophy	None
2	51	M	Right facial droop and numbness, aphasia	3	LMCA	M2 occlusion	CTA, MRA	1 d before, DWI positive; 13 d, DWI negative	Moderate	Mild	MRI 13 d, avid cortical enhancement	None
3	77	F	Dizziness, left hand weakness	4	RMCA	M2 occlusion	CTA, MRA	5 h before, DWI positive	Avid	Avid	MRI 363 d, moderate focal atrophy	None
4	72	M	Aphasia, right hemiparesis	5	LMCA	M1 > 70% stenosis	CTA, MRA	1 d, DWI positive; 40 d, DWI negative	None	Moderate	MRI 40 d, mild atrophy	None
5	66	F	Dizziness, right hemiparesis	0.38 (9 h)	Right PCA	Basilar and right PICA occlusion	CTA, DSA	1 h, DWI positive	NA	Mild	CT 3 d, no change; no long-term follow-up	None
6	77	F	Right facial droop	3	LMCA	M1 > 70% stenosis	CTA, MRA	2 d, DWI positive	None	Minimal	None, no long-term follow-up	None
7	66	M	SAH, no aneurysm at later DSA, no therapy	5	RPCA	P1 occlusion	CTA, MRA	2 d, DWI positive; 9 d, DWI negative	Avid	Mild	MRI 9 d, no change; no long-term follow-up	Catheter DSA immediately after perfusion CT
8	59	M	Acute right hemiparesis; increased weakness over days	2 h, but weak for 10–12 d	LMCA	Widely patent	CTA, MRA	2 h, DWI positive; 31 d: DWI negative	Mild	None	MRI and CT 31 d, focal early atrophy	IV tPA before CTA and perfusion CT
9	54	M	Visual field cut, ataxia	3	Left PCA	P2 > 70% stenosis	CTA, MRA	6 h, DWI positive	None	None	CT 3 d, no change; no long-term follow-up	None
10	81	F	Dizziness, fall, left-sided weakness	8	RMCA	Widely patent	CTA, MRA	1 d before, DWI positive	Avid	Avid	CT 1 d, no change; no long-term follow-up	None

CT and MRI of Cerebral Infarcts

Note—RMCA = right middle cerebral artery, CTA = CT angiography, MRA = MR angiography, DWI = diffusion-weighted MRI, LMCA = left middle cerebral artery, PCA = posterior cerebral artery, PICA = posterior-inferior cerebellar artery, DSA = digital subtraction angiography, NA = not available, SAH = subarachnoid hemorrhage, tPA = tissue plasminogen activator.

<sup>a</sup>At perfusion CT.

<sup>b</sup>If available.

<sup>c</sup>Between symptom onset and perfusion CT.

## Nagar et al.

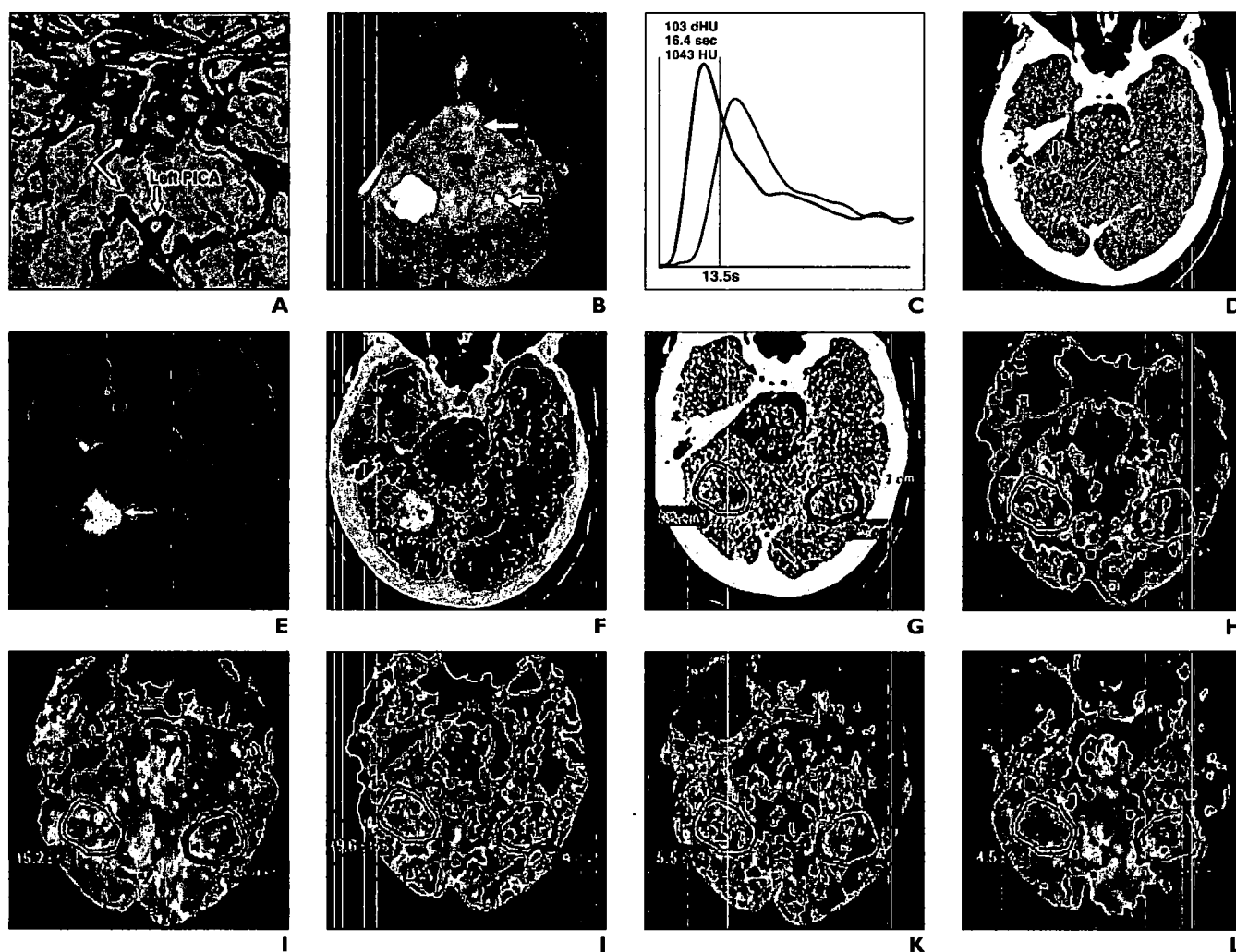
30 days ( $n = 4$ ). The affected vascular territory was recorded (Table 1). The neuroradiologists also scrolled through the dynamic perfusion CT source images to visualize whether there was either loss of the expected dynamic contrast enhancement in the affected region compared with the dynamic enhancement that occurs temporally on the normal side (graded none) or for the presence and degree of contrast enhancement greater than that in the contralateral hemisphere (graded minimal, mild, moderate, or avid). Thus, a lack of enhancement at dy-

dynamic perfusion CT was graded none, and the grades minimal, mild, moderate, and avid were applied to increasing and greater degrees of dynamic parenchymal enhancement relative to control parenchyma. A similar review was performed for the presence of enhancement, although not dynamic, on contrast-enhanced T1-weighted MR images.

## Perfusion CT Postprocessing and Review

The resultant perfusion CT maps were evaluated by consensus of the two neuroradiologists using

commercially available postprocessing software (Vitrea, Vital Images). The software uses a deconvolution model through singular value decomposition based on the central volume principle to estimate the perfusion CT parameters. The technique has been validated and is considered a relatively accurate estimation method at low injection rates for generating CBV with the calculated area under time-density curves [19]. To generate the perfusion CT maps, an arterial input function was selected from a large artery (typically the anterior or middle



**Fig. 1**—66-year-old woman (patient 5) with cerebral infarction.

**A**, CT angiogram obtained 9 hours after symptom onset shows occluded basilar and right posterior-inferior cerebellar arteries (*arrows*). PICA = posterior-inferior cerebellar artery.

**B**, Diffusion-weighted MR image obtained 1 hour after **A** shows multiple infarcts (*arrows*). Larger infarct in right cerebrum was evaluated by CT perfusion measurement.

**C**, Graph shows arterial and venous curves are appropriate after selection of internal carotid artery and torcular region.

**D**, Dynamic enhanced source perfusion CT image obtained 40 seconds after contrast administration shows area of low attenuation in right posterior cerebral artery distribution and mild peripheral enhancement (*arrows*).

**E** and **F**, Coregistration of diffusion-weighted MR image (**E**) to plane and thickness of perfusion CT image results in fused image (**F**). Arrow (**E**) indicates area of reduced diffusion.

**G**, Perfusion CT image shows selected internal carotid artery (*red dot*, **G**) and torcular region (*blue dot*, **G**). Outlines indicate affected (*yellow*) and contralateral (*purple*) regions.

**H**–**L**, Perfusion CT images of affected (*yellow*) and contralateral (*purple*) regions show mild increases in each parameter: regional cerebral blood volume (**H**), time to peak (**I**), regional cerebral blood flow (**J**), mean transit time (**K**), and delay (**L**). Area of low attenuation was unchanged on unenhanced CT images 3 days later (not shown).

### CT and MRI of Cerebral Infarcts

cerebral or less commonly the internal carotid or basilar) that was patent at CT angiography and not within the affected vascular distribution. Thereafter, a venous input (typically the superior sagittal sinus on upper-level images or the transverse sinus or the torcular region on lower images) was selected. The arterial curve was visually confirmed to precede the venous one, and on dynamic images, the arteries and veins were confirmed to become enhanced as temporally expected before generation of perfusion CT maps (Fig. 1).

ROIs corresponding to the infarct were drawn manually on the perfusion CT images on the basis of the most representative axial image with the largest DWI abnormality. An attempt was made to encircle the full extent of the infarct that had homogeneously high signal intensity on DW images. To determine the exact region to measure on the perfusion CT maps, automated rigid coregistration (fusion) was performed on the DW images with commercially available software (Fusion 7D, Mirada Solutions). A staff neuroradiologist visually confirmed adequate fusion. The fused images could be

manipulated further for confirmation of adequate fusion on the basis of anatomic landmarks (ventricles, brainstem, central sulcus). Because we typically obtain DW images in an axial oblique orientation to minimize artifact from the sphenoid sinus, fusion of the DW images was performed to the same orientation (true axial) and thickness (10 mm) as the perfusion CT images. Thereafter, an ROI was drawn on the perfusion CT maps on both sides on the basis of the site of DWI abnormality. An automirror was used for contralateral measurement and its placement was visually confirmed. Thereafter, the software generated CBV, CBF, MTT, TTP, and delay maps. Because it is a vendor-specific parameter, the delay parameter is briefly described in Appendix 1.

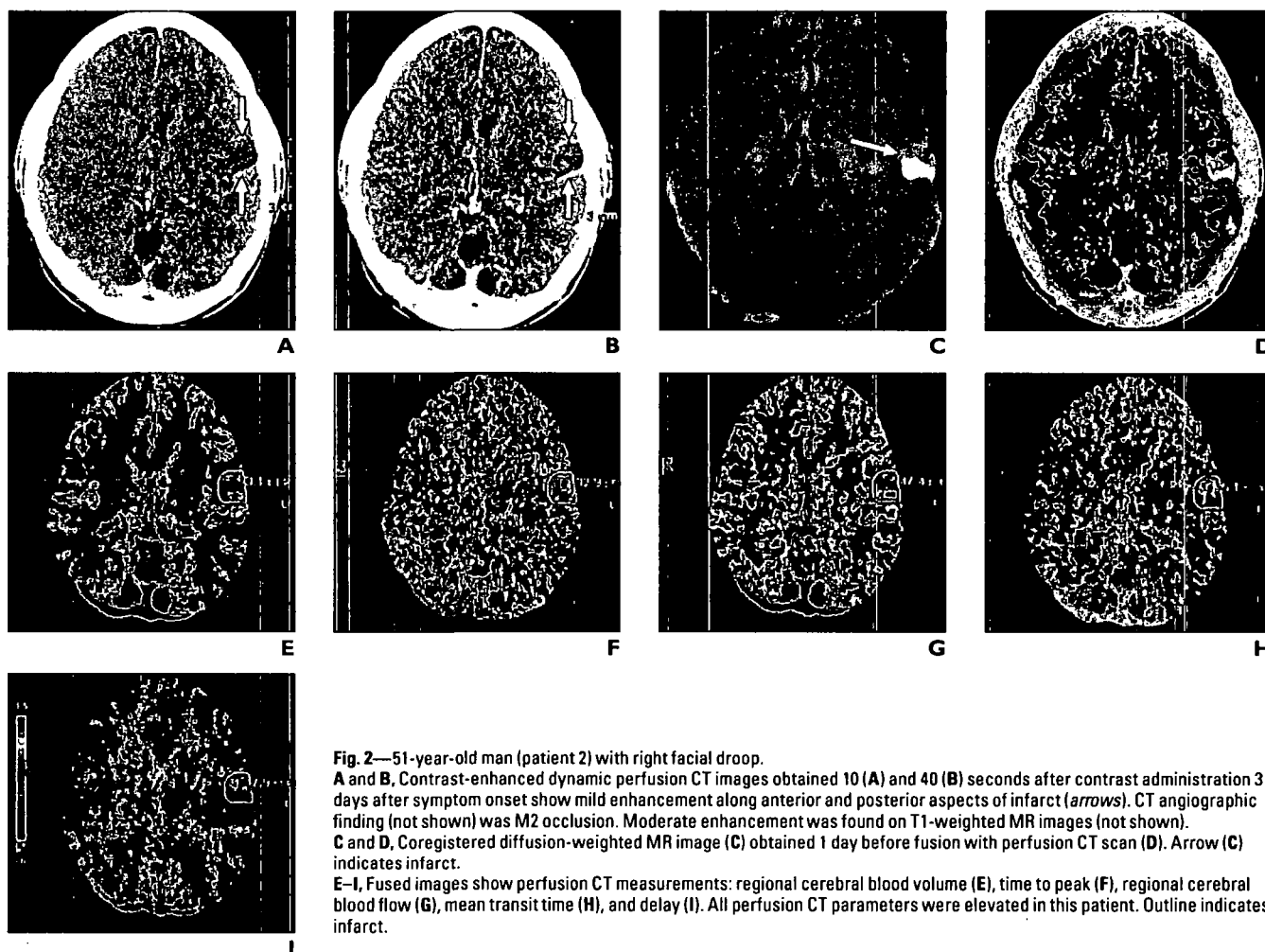
#### Statistical Analysis

Means were obtained for each parameter, and percentage increase or decrease was compared with the normal, contralateral hemisphere. A paired Student's *t* test was used to compare perfusion CT values between affected and contralateral areas. A value of  $p < 0.05$  was considered statistically significant.

### Results

Five men and five women (mean age, 68.5 years; range, 51–82 years) were included in the study. All but two were evaluated in the subacute phase of infarction (mean time in subacute infarcts from symptom onset to perfusion CT, 3.9 days; range, 3–8 days) (Table 1). However, one of the two patients (patient 8) who was evaluated in the acute phase had hyperacute worsening over 2 hours superimposed on 10–12 days of weakness, which likely represented a larger subacute infarct. In the cases of the 89 other patients with positive DWI findings who were eventually excluded from perfusion CT fusion and measurements, the clinician believed the time from symptom onset to perfusion CT was less than 8 hours.

Examples of patients evaluated in the acute and subacute stages are shown in Figures 1–4. The reasons for the late arrival for evaluation included the patient's inability to relate an adequate history owing to impaired mental status ( $n = 5$ ), the patient's living in



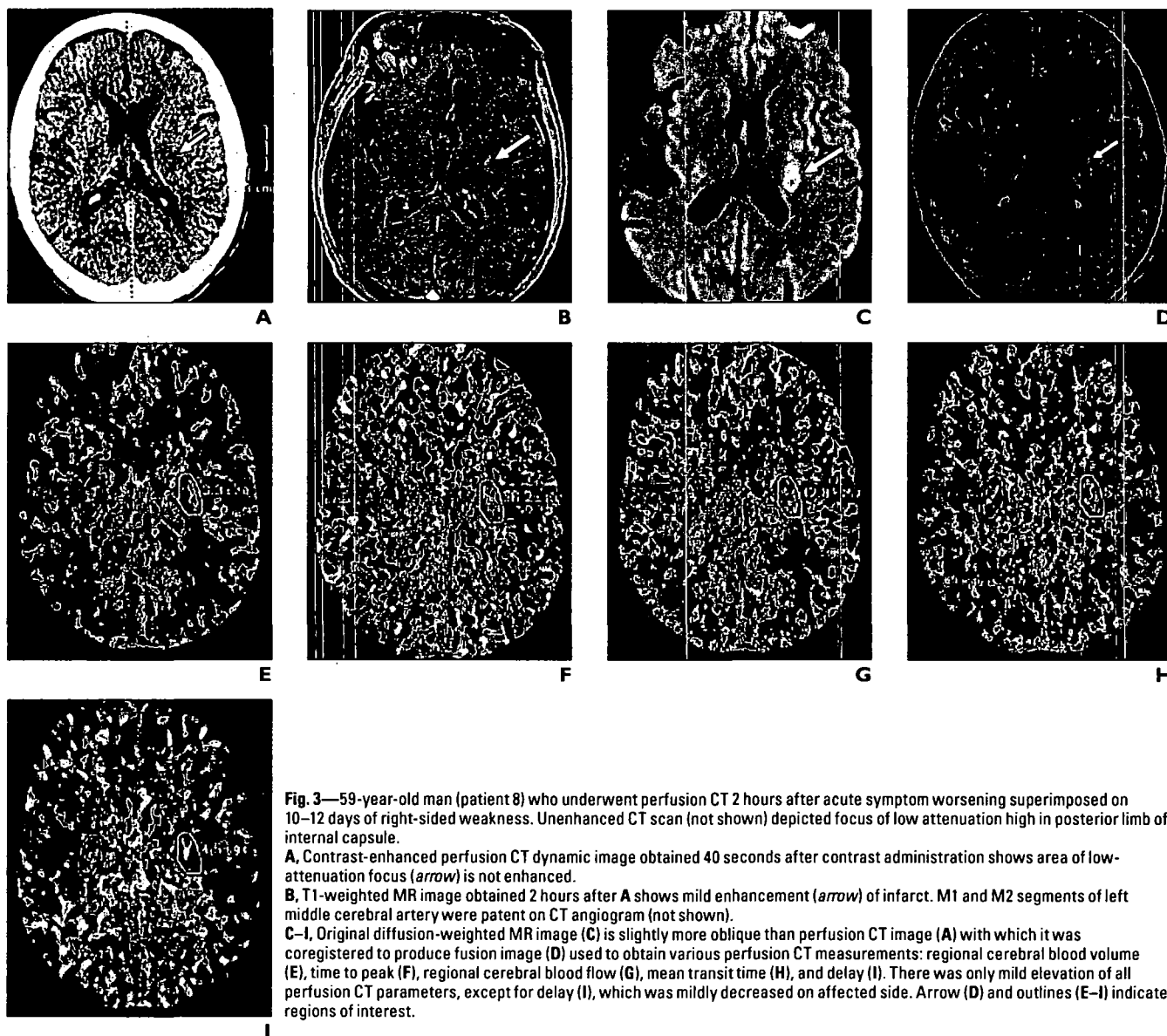
**Fig. 2—**51-year-old man (patient 2) with right facial droop.

**A and B,** Contrast-enhanced dynamic perfusion CT images obtained 10 (**A**) and 40 (**B**) seconds after contrast administration 3 days after symptom onset show mild enhancement along anterior and posterior aspects of infarct (*arrows*). CT angiographic finding (not shown) was M2 occlusion. Moderate enhancement was found on T1-weighted MR images (not shown).

**C and D,** Coregistered diffusion-weighted MR image (**C**) obtained 1 day before fusion with perfusion CT scan (**D**). Arrow (**C**) indicates infarct.

**E–I,** Fused images show perfusion CT measurements: regional cerebral blood volume (**E**), time to peak (**F**), regional cerebral blood flow (**G**), mean transit time (**H**), and delay (**I**). All perfusion CT parameters were elevated in this patient. Outline indicates infarct.

Nagar et al.



**Fig. 3**—59-year-old man (patient 8) who underwent perfusion CT 2 hours after acute symptom worsening superimposed on 10–12 days of right-sided weakness. Unenhanced CT scan (not shown) depicted focus of low attenuation high in posterior limb of internal capsule.

**A**, Contrast-enhanced perfusion CT dynamic image obtained 40 seconds after contrast administration shows area of low-attenuation focus (*arrow*) is not enhanced.

**B**, T1-weighted MR image obtained 2 hours after **A** shows mild enhancement (*arrow*) of infarct. M1 and M2 segments of left middle cerebral artery were patent on CT angiogram (not shown).

**C–I**, Original diffusion-weighted MR image (**C**) is slightly more oblique than perfusion CT image (**A**) with which it was coregistered to produce fusion image (**D**) used to obtain various perfusion CT measurements: regional cerebral blood volume (**E**), time to peak (**F**), regional cerebral blood flow (**G**), mean transit time (**H**), and delay (**I**). There was only mild elevation of all perfusion CT parameters, except for delay (**I**), which was mildly decreased on affected side. Arrow (**D**) and outlines (**E–I**) indicate regions of interest.

a remote location ( $n = 1$ ), and evaluation to rule out progression of infarction or ischemia with worsening symptoms after a diagnosis with DWI ( $n = 4$ ).

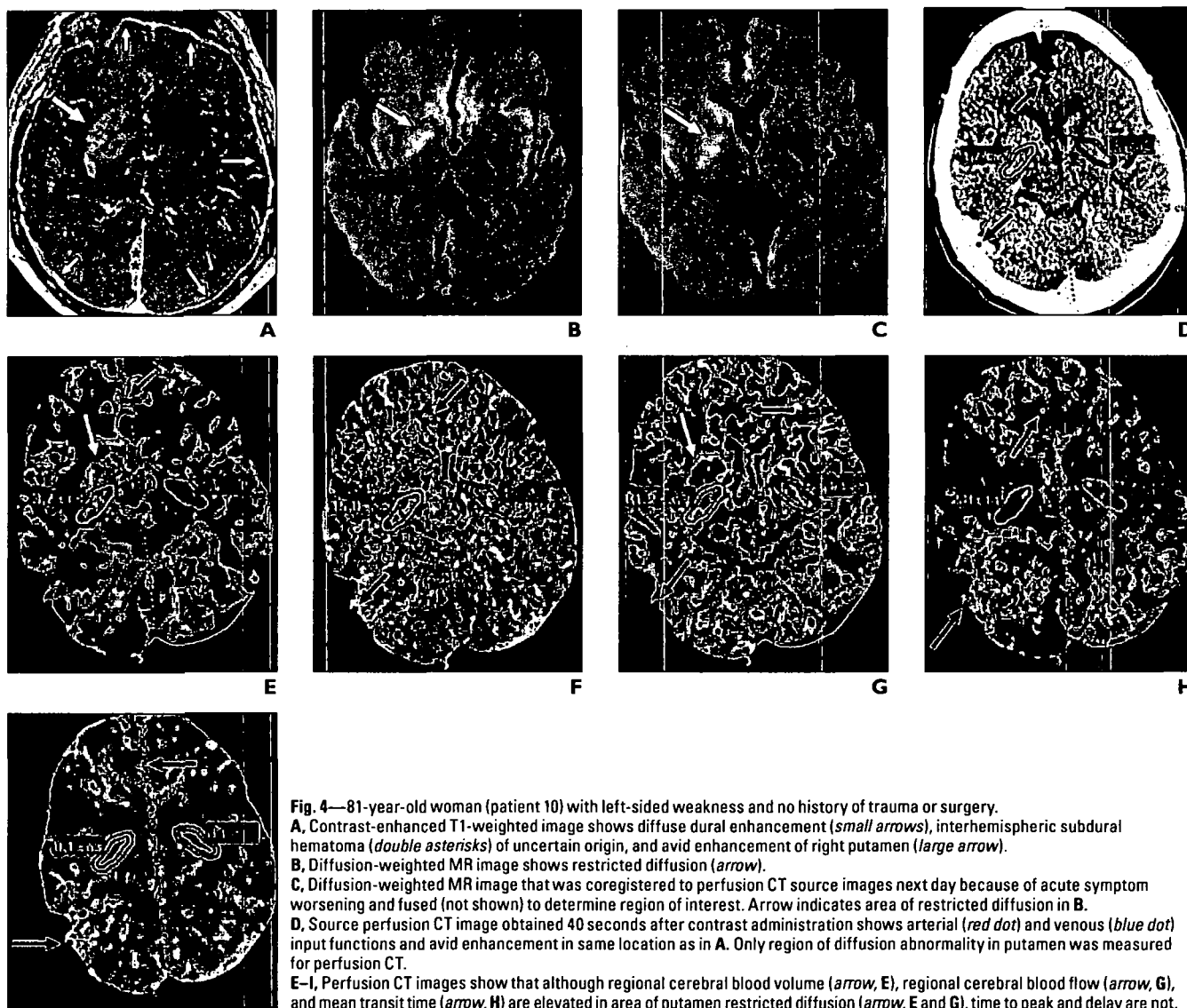
The CBV, CBF, MTT, TTP, and delay measurements are shown in Table 2. There were significant differences regarding CBV, MTT, TTP, and delay in the affected versus contralateral hemispheres ( $p = 0.016$ ,  $0.007$ ,  $0.005$ , and  $0.030$ , respectively) with no significant difference in CBF ( $p = 0.785$ ). CBV and MTT were elevated in all 10 patients, and CBF was variable. Both TTP and delay on the affected side were equal to or greater than those on the normal side in eight of the 10 patients.

At unenhanced CT performed with perfusion CT, all 10 infarcts were either low attenuation or of similar attenuation in relation to normal parenchyma (loss of gray–white matter differentiation) to varying degrees, which was augmented on dynamic perfusion CT images in eight patients by visualization of abnormal dynamic enhancement. When present, dynamic enhancement was not temporal as expected compared with unaffected regions. Among the nine patients with available contrast-enhanced T1-weighted images, the infarcts in six became enhanced to varying degrees (Table 1). At MRI, each affected region also had high signal intensity on FLAIR images.

## Discussion

The results of this study suggest that elevations of CBV and MTT, and possibly of TTP and delay, are important identifiers of a potentially misleading phenomenon that occurred during at least 2.7% of our perfusion CT examinations for stroke. This phenomenon has been called luxury perfusion, which can occur in both treated and untreated infarcts, and is traditionally defined as a state of nonnutritional reperfusion or hyperperfusion. We cannot state unequivocally, however, that all 10 patients had nonbeneficial reperfusion because there remains controversy about whether some degree of hyperperfusion of tissue in the late acute or early subacute phas-

## CT and MRI of Cerebral Infarcts



**Fig. 4**—81-year-old woman (patient 10) with left-sided weakness and no history of trauma or surgery. **A**, Contrast-enhanced T1-weighted image shows diffuse dural enhancement (*small arrows*), interhemispheric subdural hematoma (*double asterisks*) of uncertain origin, and avid enhancement of right putamen (*large arrow*). **B**, Diffusion-weighted MR image shows restricted diffusion (*arrow*). **C**, Diffusion-weighted MR image that was coregistered to perfusion CT source images next day because of acute symptom worsening and fused (not shown) to determine region of interest. Arrow indicates area of restricted diffusion in **B**. **D**, Source perfusion CT image obtained 40 seconds after contrast administration shows arterial (*red dot*) and venous (*blue dot*) input functions and avid enhancement in same location as in **A**. Only region of diffusion abnormality in putamen was measured for perfusion CT. **E–I**, Perfusion CT images show that although regional cerebral blood volume (*arrow, E*), regional cerebral blood flow (*arrow, G*), and mean transit time (*arrow, H*) are elevated in area of putamen restricted diffusion (*arrow, E and G*), time to peak and delay are not.

es of stroke is beneficial. However, most regions of reperfusion or hyperperfusion with elevated CBV and CBF on radionuclide studies have been found [9, 20, 21] to eventually progress to infarction, as confirmed with DWI in this study. Typically, as in our study, the clinician and radiologist would already suspect infarction clinically and with the finding of low attenuation on unenhanced CT images or by scrolling through dynamic perfusion CT images. However, a pitfall at perfusion CT would be finding visually normal or elevated CBV in a patient with mental impairment, whose history interview and physical examination can be difficult to perform. This surreptitious appearance could lead to misinterpretation of tissue as normal

or simply oligemic. Hence, comparing the unenhanced CT and dynamic source data and visualization of elevated CBV and MTT can confirm the diagnosis.

Our goal was to evaluate which perfusion CT parameters can be used to detect the small subset of patients with infarction who are undergoing evaluation to rule out acute stroke but who have misleadingly normal or increased CBV. Overall, the reported thresholds of less than approximately 0.6 (60% of the normal side) for CBV and less than 0.3–0.35 (30–35% of the normal side) for CBF compared with the normal side are generally valid indicators of acute cerebral infarction [7, 16]. However, on the basis of our findings in this study, CBV and CBF may not be

reliable in a small minority of patients, particularly those who arrive for evaluation outside of the hyperacute phase (< 6–8 hours after symptom onset), that is, those who have late acute or early subacute infarcts. Findings on MTT, TTP, and delay maps were the most visually discernible indicators in detection of abnormality. Elevation of MTT was found in all 10 included patients, and elevated TTP and delay in eight and seven of the 10. This phenomenon (normal or elevated CBV) did not occur in the 89 other stroke patients who had positive DWI findings and underwent perfusion CT within what was believed to be the 8 hours after symptom onset. The results of this study therefore suggest that MTT, TTP, and delay maps can aid in the detection of reper-

Nagar et al.

**TABLE 2: Measurements of CT Perfusion Parameters in Regions of Infarction and Contralateral Hemisphere**

Patient No.	Age (y)	Cerebral Blood Flow (mL/100 g/min)			Cerebral Blood Volume (mL/100 g)			Mean Transit Time (s)			Time to Peak (s)			Delay (s)		
		Affected Side	Unaffected Side	Percentage Increase	Affected Side	Unaffected Side	Percentage Increase	Affected Side	Unaffected Side	Percentage Increase	Affected Side	Unaffected Side	Percentage Increase	Affected Side	Unaffected Side	Percentage Increase
1	82	47.0	66.8	-29.6	6.2	3.7	67.6	8.1	3.5	131.4	20.5	15.2	34.9	6.7	0.7	857.1
2	51	47.4	42.0	12.9	3.1	2.3	34.8	5.1	3.6	41.7	32.9	25.3	30.0	7.9	4.5	75.6
3	77	17.9	16.6	7.8	1.9	1.6	18.8	7.0	5.8	20.7	34.8	32.5	7.1	5.1	3.7	37.8
4	72	16.1	23.4	-31.2	2.5	2.2	13.6	10.2	6.2	64.5	29.0	23.9	21.3	5.9	3.5	68.6
5	66	49.6	43.9	13.0	4.6	3.5	31.4	5.5	4.7	17.0	15.2	15.0	1.3	4.5	3.5	28.6
6	77	52.1	48.1	8.3	4.9	4.7	4.3	6.4	5.5	16.4	15.4	15.6	-1.3	2.0	2.5	-20.0
7	66	48.0	48.1	-0.2	3.7	3.2	15.6	4.9	4.2	16.7	31.4	27.9	12.5	11.0	7.8	41.0
8	59	42.8	33.9	26.3	3.3	2.7	22.2	5.3	5.1	3.9	36.2	32.2	12.4	4.5	5.5	-18.2
9	54	14.0	19.6	-28.6	2.2	1.9	15.8	9.0	5.9	52.5	24.9	15.3	62.7	13.9	5.0	178.0
10	81	81.2	58.1	39.8	3.7	2.1	76.2	2.8	2.4	16.7	15.0	15.7	-4.5	0.1	0.1	0.0
Mean	68.5	41.6	40.1	1.8	3.6	2.8	30.0	6.4	4.7	38.1	25.5	21.9	17.7	6.2	3.7	124.9

Note—Differences between affected and unaffected sides were as follows: cerebral blood flow,  $p = 0.785$ ; cerebral blood volume,  $p = 0.016$ ; mean transit time,  $p = 0.007$ ; time to peak,  $p = 0.005$ ; and delay  $p = 0.030$ .

fused and hyperperfused infarcts outside the hyperacute phase. Our results have been corroborated in studies [16, 22–24] showing that MTT and TTP may be sensitive (but not necessarily specific) in the detection of ischemia and infarction. Although delay maps have not been prospectively evaluated, delay should follow a similar pattern, on the basis of the preliminary results of our study.

It is important to note that chronic ischemia also can elevate MTT and TTP, typically with diminished CBF and variably normal or increased CBV. This finding can be differentiated with careful examination of unenhanced CT and dynamic source perfusion CT data [25]. Other than chronic ischemia, the differential diagnosis of increased CBV includes the ictal state of seizures and high-grade primary brain tumors [26–29]. However, MTT typically is reduced in such cases, although MTT occasionally is elevated at perfusion CT of high-grade tumors [28, 29].

After acute ischemic stroke, the return of CBF in excess of metabolic requirement has been termed luxury perfusion on the basis of findings at catheter angiography and subsequent radionuclide studies. It has been postulated [12–15] that such perfusion represents increased blood flow from reperfusion after endothelial damage. Two earlier studies [11, 16] showed hyperperfusion on perfusion CT images of a smaller number of patients (two and four). Wintermark et al. [16] found a decrease in MTT in two patients with false-negative findings but elevated CBF and CBV. Nguyen et al. [11], however, described either elevated or decreased MTT in four treated patients. We found elevated MTT in all of our patients. The reason for this discrepancy is not entirely clear and may be related to the time of symptom onset to perfusion CT among our patients (one study included only patients with an interval of < 12 hours) [16], to our system of ROI measurement on the perfusion CT maps after coregistration and fusion (which should be more accurate), or to the postprocessing algorithm used [11, 16]. We therefore invoke the term luxury perfusion to refer to a false-negative and perfused (although delayed perfusion) infarct at perfusion CT, during which CBV and CBF can mistakenly appear nearly normal or elevated but can be discerned on MTT, TTP, and delay maps and on dynamic enhanced images.

The mechanism of the false-negative perfusion CT appearance of CBV and CBF in reperfused or hyperperfused infarcts is not certain. This phenomenon typically has been found in the subacute phase during radionuclide imaging and digital subtraction angiography, although a similar-appearing acute hyperperfusion phenomenon at perfusion CT, radionuclide, and digital subtraction angiographic examinations also can occur [8–15]. After acute infarction, restoration of CBF and CBV is thought related to impaired vessel autoregulation, in which, in this state of postischemic hyperperfusion, powerful molecules with vasodilative properties, such as nitric oxide, adenosine, and oxygen radicals, can cause a high metabolic rate of oxygen utilization but a low oxygen extraction fraction [11, 20, 21, 23, 24, 30]. Such flow hemodynamics can be seen in reperfusion of infarcted tissue after thrombolysis in the acute or hyperacute stage; the findings are similar in the subacute stage after thrombolysis [8–15]. Another proposed mechanism of normal or elevated CBV in the acute stage is recanalization or revascularization after IV or intraarterial therapy or occurring spontaneously [11, 20, 21, 23, 24, 30]. For example, Olsen and Lassen [30] found that revascularization can occur spontaneously within 1–4 days of stroke onset. Other investigators [20, 21, 31] have found reperfusion and hyperperfusion as early as 5 hours after symptom onset in patients with a spontaneously revascularized middle cerebral artery, which has been found on digital subtraction angiographic images in as many as 30% of patients within 24 hours and in 70% of patients within 1 week of symptom onset. Because eight of our 10 patients underwent perfusion CT in the subacute phase, it is plausible that revascularization with vasodilation of injured tissue might have caused the elevated CBV in the pres-

## CT and MRI of Cerebral Infarcts

ence of nearly normal CBF. Notably, eight of the 10 patients had some degree of larger-segment (M1 or P1) patency.

Early revascularization through leptomeningeal collateral vessels also can cause hyperperfusion [32, 33]. We theorize that blood-brain barrier injury can contribute through contrast leakage, which leads to infarct enhancement and lack of reduction of CBV and CBF. Accordingly, some investigators [34, 35] have deduced from radionuclide studies that hyperfixation of the radiotracer to subacute infarcts is related to vasodilation, disruption of the blood-brain barrier, and revascularization. Breakdown of the blood-brain barrier leading to leakage of contrast material into the extravascular space, with potential overstimulation of CBV, has been described [36, 37]. We opine that the elevated CBV may be akin to the enhancement visualized on dynamic perfusion CT images that was found in most of our patients. Therefore, the results of this study corroborate earlier findings [20, 21] that suggest hyperperfusion in infarcts is related to varying degrees of revascularization (possibly spontaneous) combined with varying degrees of endothelial (blood-brain barrier) injury and collateral flow.

There were limitations to our study. First, the inclusion criteria were the presence of visually normal or nonreduced CBV in regions abnormal on DW images, so we cannot prove that postinfarction hyperperfusion found on perfusion CT images did not occur more frequently than in 2.7% among the 371 perfusion CT examinations of patients who did not undergo DWI. In addition, although we used 64-MDCT, which can cover more than one half of the cerebrum even without table toggling, another limitation was that infarcts smaller than 1.5 cm (traditionally defined as lacunar) were not included and that the entire brain was not covered. These are previously described limitations of perfusion CT [1, 16, 18, 22]. Finally, DWI was not performed immediately before or after perfusion CT; therefore, we cannot entirely exclude progression of infarcts, for example, in the interim between the two examinations. We note, however, that autofusion of perfusion CT and DW images with manual confirmation and the findings at dynamic CT and unenhanced CT confirmed that the size of the abnormalities did not change greatly in the short interim between the two examinations. These preliminary results should be validated in a larger, prospective study with long-term follow-up CT or MRI.

This preliminary study was conducted specifically to evaluate the cases of patients in which a false-negative interpretation regarding infarction might have been made if the CBV map alone had been evaluated. Therefore, use of only the CBV or CBF maps generated at perfusion CT may not be sufficient for recognition of late acute and early subacute infarcts that have a hyperperfused or reperfused appearance (luxury perfusion). Recognition of elevated CBV, MTT, TTP, and delay and review of the unenhanced CT and dynamic source perfusion CT images may prevent false-negative misinterpretation of truly infarcted tissue as viable, normal, or oligemic in the setting of thromboembolic stroke. This phenomenon was not found at perfusion CT of hyperacute infarcts (< 6–8 hours after symptom onset). Further prospective studies of this phenomenon are warranted because perfusion CT measurements in such a state may increase understanding of the compensatory hemodynamic mechanisms of evolving cerebral infarction.

### Acknowledgment

We thank Stefan Atev, Vital Images, for aiding with explanation and illustration of the perfusion CT postprocessing algorithms.

### References

1. Eastwood JD, Lev MH, Wintermark M, et al. Correlation of early dynamic CT perfusion imaging with whole-brain MR diffusion and perfusion imaging in acute hemispheric stroke. *Am J Neuroradiol* 2003; 24:1869–1875
2. Wintermark M, Meuli R, Browaeys P, et al. Comparison of CT perfusion and angiography and MRI in selecting stroke patients for acute treatment. *Neurology* 2007; 68:694–697
3. Kloska SP, Dittich R, Fischer T, et al. Perfusion CT in acute stroke: prediction of vessel recanalization and clinical outcome in intravenous thrombolytic therapy. *Eur Radiol* 2007; 17:2491–2498
4. Lee JY, Kim SH, Lee MS, et al. Prediction of clinical outcome with baseline and 24-hour perfusion CT in acute middle cerebral artery territory ischemic stroke treated with intravenous recanalization therapy. *Neuroradiology* 2008; 50:391–396
5. Murphy BD, Fox AJ, Lee DH, et al. Identification of penumbra and infarct in acute ischemic stroke using computed tomography perfusion-derived blood flow and blood volume measurements. *Stroke* 2006; 37:1771–1777
6. Srinivasan A, Goyal M, Al-Azri F, et al. State-of-art imaging of acute stroke. *RadioGraphics* 2006; 26:S75–S95
7. Schaefer PW, Roccatagliata L, Ledezma C, et al. First-pass quantitative CT perfusion identifies thresholds for salvageable penumbra in acute stroke patients treated with intra-arterial therapy. *Am J Neuroradiol* 2006; 27:20–25
8. Weir CJ, Bolster AA, Tytler S, et al. Prognostic value of single-photon emission tomography in acute ischaemic stroke. *Eur J Nucl Med* 1997; 24:21–26
9. Infeld B, Davis SM, Donnan GA, et al. Streptokinase increases luxury perfusion after stroke. *Stroke* 1996; 27:1524–1529
10. Stringer WA, Hasso AN, Thompson JR, et al. Hyperventilation-induced cerebral ischemia in patients with acute brain lesions: demonstration by xenon-enhanced CT. *Am J Neuroradiol* 1993; 14:475–484
11. Nguyen TB, Lum C, Eastwood JD, et al. Hyperperfusion on perfusion computed tomography following revascularization for acute stroke. *Acta Radiol* 2005; 46:610–615
12. Taveras JM, Gilson JM, Davis DO, et al. Angiography in cerebral infarction. *Radiology* 1969; 93:549–558
13. Moretti JL, Defer G, Cinnotti L, et al. "Luxury perfusion" with <sup>99m</sup>Tc-HMPAO and <sup>123</sup>I-IMP SPECT imaging during the subacute phase of stroke. *Eur J Nucl Med* 1990; 16:17–22
14. Lassen NA. The luxury-perfusion syndrome and its possible relation to acute metabolic acidosis localized within the brain. *Lancet* 1966; 2:1113–1115
15. Snow RM, Keyes JW Jr. The "luxury-perfusion syndrome" following a cerebrovascular accident demonstrated by radionuclide angiography. *J Nucl Med* 1974; 15:907–909
16. Wintermark M, Fischbein NJ, Smith WS, et al. Accuracy of dynamic perfusion CT with deconvolution in detecting acute hemispheric stroke. *Am J Neuroradiol* 2005; 26:104–112
17. Murphy BD, Fox AJ, Lee DH, et al. White matter thresholds for ischemic penumbra and infarct core in patients with acute stroke: CT perfusion study. *Radiology* 2008; 247:818–825
18. Fisher CM. Lacunes: small, deep cerebral infarcts. *Neurology* 1965; 15:774–784
19. Wintermark M, Maeder P, Thiran JP, et al. Quantitative assessment of regional cerebral blood flows by perfusion CT studies at low injection rates: a critical review of the underlying theoretical models. *Eur Radiol* 2001; 11:1220–1230
20. Marchal G, Furlan M, Beaudouin V, et al. Early spontaneous hyperperfusion after stroke: a marker of favourable tissue outcome? *Brain* 1996; 119:409–419
21. Marchal G, Young AR, Baron JC. Early post-ischemic hyperperfusion: pathophysiologic insights from positron emission tomography. *J Cereb Blood Flow Metab* 1999; 19:467–482
22. Reichenbach JR, Röther J, Jonetz-Mentzel L, et al. Acute stroke evaluated by time-to-peak mapping

## Nagar et al.

- during initial and early follow-up perfusion CT studies. *Am J Neuroradiol* 1999; 20:1842-1850
23. Sparacia G, Iaia A, Assadi B, Lagalla R. Perfusion CT in acute stroke: predictive value of perfusion parameters in assessing tissue viability versus infarction. *Radiol Med* 2007; 112:113-122
  24. Silvennoinen HM, Hamberg LM, Lindsberg PJ, et al. CT perfusion identifies increased salvage of tissue in patients receiving intravenous recombinant tissue plasminogen activator within 3 hours of stroke onset. *Am J Neuroradiol* 2008; 29:1118-1123
  25. Furukawa M, Kashiwagi S, Matsunaga N, et al. Evaluation of cerebral perfusion parameters measured by perfusion CT in chronic cerebral ischemia: comparison with xenon CT. *J Comput Assist Tomogr* 2002; 26:272-278
  26. Royter V, Paletz L, Waters MF. Stroke vs. status epilepticus: a case report utilizing CT perfusion. *J Neurol Sci* 2008; 266:174-176
  27. Wiest R, von Bredow F, Schindler K, et al. Detection of regional blood perfusion changes in epileptic seizures with dynamic brain perfusion CT: a pilot study. *Epilepsy Res* 2006; 72:102-110
  28. Ellika SK, Jain R, Patel SC, et al. Role of perfusion CT in glioma grading and comparison with conventional MR imaging features. *Am J Neuroradiol* 2007; 28:1981-1987
  29. Jain R, Ellika SK, Scarpace L, et al. Quantitative estimation of permeability surface-area product in astroglial brain tumors using perfusion CT and correlation with histopathologic grade. *Am J Neuroradiol* 2008; 29:694-700
  30. Olsen TS, Lassen NA. A dynamic concept of middle cerebral artery occlusion and cerebral infarction in the acute state based on interpreting severe hyperemia as a sign of embolic migration. *Stroke* 1984; 15:458-468
  31. Fieschi C, Argentino C, Lenzi GL, et al. Clinical and instrumental evaluation of patients with ischemic stroke within the first six hours. *J Neurol Sci* 1989; 91:311-321
  32. Lee KH, Cho SJ, Byun HS, et al. Triphasic perfusion computed tomography in acute middle cerebral artery stroke: a correlation with angiographic findings. *Arch Neurol* 2000; 57:990-999
  33. Yamauchi H, Kudoh T, Sugimoto K, et al. Pattern of collaterals, type of infarcts, and haemodynamic impairment in carotid artery occlusion. *J Neurol Neurosurg Psychiatry* 2004; 75:1697-1701
  34. Cho I, Hayashida K, Imakita S, et al. Hemodynamic and metabolic state of hyperfixation with  $^{99m}\text{Tc}$ -HMPAO brain SPECT in subacute stroke. *Ann Nucl Med* 2000; 14:159-163
  35. Sperling B, Lassen NA. Hyperfixation of HMPAO in subacute ischemic stroke leading to spuriously high estimates of cerebral blood flow by SPECT. *Stroke* 1993; 24:193-194
  36. Roberts HC, Roberts TP, Brasch RC, et al. Quantitative measurement of microvascular permeability in human brain tumors achieved using dynamic contrast-enhanced MR imaging: correlation with histologic grade. *Am J Neuroradiol* 2000; 21:891-899
  37. Konstas AA, Goldmakher GV, Lee TY, Lev MH. Theoretic basis and technical implementation of CT perfusion in acute ischemic stroke. Part I. *Am J Neuroradiol* 2009; 30:662-668

## APPENDIX I: Delay

According to the vendor, delay is computed from the scaled impulse residue function. If  $a(t)$  is the arterial input function and  $c(t)$  is the tissue signal, then the goal of deconvolution is to recover  $F r(t)$ , the scaled impulse residue function based on the following relationship:

$$c(t) = \int_{-\infty}^{+\infty} F \cdot a(\tau) \cdot r(t - \tau) d\tau$$

$F$  is the flow, which can be recovered because the residue function  $r$  is by definition zero until the tissue responds to its input (the

artery), when it attains a value of 1 before decreasing gradually to zero. Therefore, the maximum of the scaled residue ( $F \cdot r$ ) is  $F$ , and the time at which  $F r(t)$  achieves its maximum value is the delay time  $D$ . In Figure 5, a diagram of ( $F \cdot r$ ) illustrates the definition of delay.

In Figure 5, the red curve is an ideal scaled residue function, and the blue curve is the output of the singular value decomposition-based method. Notably,  $D$  calculated here is not the same as the difference of peak time between tissue and artery ( $TTP_{\text{tissue}} - TTP_{\text{artery}}$ ), which

is sometimes used as an indirect estimate of a delay value but is only valid under certain conditions with specific assumptions about the shape of the residue function  $r$ . In summary,  $D$  equals the time of the maximum value of the residue function and represents the contrast arrival time in tissue relative to the arrival time in the arterial input function.  $D$  is typically positive, but in theory it can be zero if the tissue selected is adjacent to a diseased vessel chosen as the arterial input function.

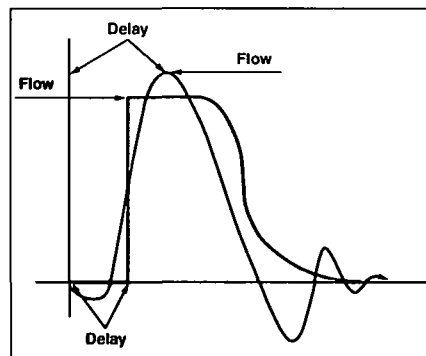


Fig. 5—Graph shows calculation of delay.



-----  
**Paper-11:**

**Natarajan SK, Snyder KV, Siddiqui AH, Ionita CC  
et al. : Safety and Effectiveness of Endovascular  
Therapy After 8 Hours of Acute Ischemic Stroke.  
Onset and Wake-Up Strokes. Stroke.  
2009;40:3269-3274.**

# Stroke

JOURNAL OF THE AMERICAN HEART ASSOCIATION



American Heart Association | American Stroke Association

## Safety and Effectiveness of Endovascular Therapy After 8 Hours of Acute Ischemic Stroke Onset and Wake-Up Strokes

Sabareesh K. Natarajan, Kenneth V. Snyder, Adnan H. Siddiqui, Catalina C. Ionita, L. Nelson Hopkins and Elad I. Levy

*Stroke*. 2009;40:3269-3274; originally published online July 23, 2009;

doi: 10.1161/STROKEAHA.109.555102

*Stroke* is published by the American Heart Association, 7272 Greenville Avenue, Dallas, TX 75231

Copyright © 2009 American Heart Association, Inc. All rights reserved.

Print ISSN: 0039-2499. Online ISSN: 1524-4628

The online version of this article, along with updated information and services, is located on the World Wide Web at:

<http://stroke.ahajournals.org/content/40/10/3269>

**Permissions:** Requests for permissions to reproduce figures, tables, or portions of articles originally published in *Stroke* can be obtained via RightsLink, a service of the Copyright Clearance Center, not the Editorial Office. Once the online version of the published article for which permission is being requested is located, click Request Permissions in the middle column of the Web page under Services. Further information about this process is available in the Permissions and Rights Question and Answer document.

**Reprints:** Information about reprints can be found online at:  
<http://www.lww.com/reprints>

**Subscriptions:** Information about subscribing to *Stroke* is online at:  
<http://stroke.ahajournals.org//subscriptions/>

# Safety and Effectiveness of Endovascular Therapy After 8 Hours of Acute Ischemic Stroke Onset and Wake-Up Strokes

Sabareesh K. Natarajan, MD, MS; Kenneth V. Snyder, MD, PhD; Adnan H. Siddiqui, MD, PhD; Catalina C. Ionita, MD; L. Nelson Hopkins, MD; Elad I. Levy, MD

**Background and Purpose**—This is a retrospective review of patients who underwent endovascular recanalization  $\geq 8$  hours after acute ischemic stroke symptom onset, including wake-up strokes, between June 2005 and June 2008.

**Methods**—Thirty patients with a pre-morbid modified Rankin score  $\leq 1$  and NIHSS between 5 and 22 were included. All had admission CT, CTA, and CT perfusion scans to evaluate for salvageable brain tissue. Recanalization effectiveness was assessed by angiograms obtained within 30 hours after intervention. Patient, treatment characteristics, and immediate and 3-month outcomes were analyzed.

**Results**—Mean NIHSS at presentation was 13 (median=12). Mean interval between time last-seen well and angiogram was 12.75 hours (median=10). Twenty-six patients (86.7%) presented with complete-to-near-complete vessel occlusion (thrombolysis in myocardial infarction [TIMI] 0/1); 4 had partial vessel occlusion (TIMI 2). Interventions included intra-arterial pharmacological thrombolysis (n=10), mechanical thrombectomy (n=21; Merci, 16; intracranial stent, 9; extracranial stent, 3), angioplasty (n=14; intracranial, 11; extracranial, 3). Nine patients received GPIIb/IIIa inhibitors (eptifibatide); all received heparin. Partial-to-complete recanalization (TIMI 2/3) was achieved in 20 patients (66.7%). Procedure-related complications included vascular perforations (n=3) and femoral access site complication (n=1). One patient had an embolic anterior cerebral artery infarct during intervention; another had progression of brain stem infarct. Symptomatic intracerebral hemorrhage occurred in 3 patients (10%), with 2 being primarily subarachnoid in location. Total in-hospital mortality including procedural mortality, disease progression, or other comorbidities was 23.3% (n=7). Mean discharge NIHSS was 9.5, representing an overall NIHSS 3.5-point improvement. Overall, mean modified Rankin score at death or last follow-up (mean=10.6 months) was 4.2. At 3 months, total mortality was 33.3% (n=10), 20% had modified Rankin score  $\leq 2$ , and 33% had modified Rankin score  $\leq 3$ . Among survivors, mean modified Rankin score at 3-month follow-up was 3.

**Conclusion**—Our data show that delayed endovascular revascularization of carefully selected patients is safe, effective, and improves clinical outcome. (*Stroke*. 2009;40:3269-3274.)

**Key Words:** acute ischemic stroke ■ endovascular therapy ■ outcomes ■ recanalization  
■ revascularization time window ■ wake-up strokes

Approximately 795 000 strokes occur in the US annually, of which  $\approx 85\%$  are ischemic.<sup>1</sup> The only US FDA-approved medical therapy for acute stroke to date is intravenous tissue plasminogen activator (t-PA) administered within 3 hours of symptom onset.<sup>2</sup> However,  $<5\%$  of patients with acute ischemic stroke in the US receive t-PA, primarily because of a delay in hospital presentation.<sup>3</sup> To increase the proportion of acute stroke patients who receive treatment, efforts are ongoing to try to expand the time window for reperfusion therapy beyond 3 hours. These efforts include the development of novel thrombolytic agents,<sup>4</sup> mechanical thrombectomy,<sup>5</sup> self-expanding stents,<sup>6</sup> and use of advanced imaging techniques.<sup>7,8</sup> There is increasing evidence that

identification of potentially salvageable brain tissue with advanced MR and CT imaging may allow the selection of patients who can be effectively and safely treated with intravenous thrombolysis for up to 9 hours after ictus.<sup>9-16</sup>

Approximately 16% to 28% of ischemic stroke patients awaken with their deficits.<sup>17,18</sup> In these wake-up strokes (WUS), the onset of symptoms is defined as the “time last-seen well” (TLSW). Because this is the time the patient went to sleep, unfortunately, these patients are usually placed outside the window for thrombolysis or ineligible for entry into reperfusion clinical trials. Barreto et al<sup>19</sup> reported that patients with WUS have better outcomes when they are treated. There was no significant difference between WUS

Received April 8, 2009; final revision received June 1, 2009; accepted June 24, 2009.

From Departments of Neurosurgery (S.K.N., K.V.S., A.H.S., C.C.I., L.N.H., E.I.L.) and Radiology (A.H.S., L.N.H., E.I.L.), School of Medicine and Biomedical Sciences, University at Buffalo, State University New York, Buffalo, NY; Department of Neurosurgery (S.K.N., K.V.S., A.H.S., C.C.I., L.N.H., E.I.L.), Millard Fillmore Gates Hospital, Kaleida Health, Buffalo NY.

Correspondence to Elad I. Levy, MD, University at Buffalo Neurosurgery, Millard Fillmore Gates Hospital, Kaleida Health, 3 Gates Circle, Buffalo, NY 14209.

© 2009 American Heart Association, Inc.

*Stroke* is available at <http://stroke.ahajournals.org>

DOI: 10.1161/STROKEAHA.109.555102

patients and patients treated within 3 hours by intravenous thrombolysis when time of stroke onset was known.

Reestablishment of flow to perfuse salvageable brain tissues has been shown to significantly reduce the morbidity and mortality of ischemic stroke.<sup>11,20</sup> Endovascular techniques to recanalize occluded vessels have overcome some of the limitations of systemic intravenous thrombolysis, such as narrow therapeutic window, poor recanalization rates, high hemorrhage rates, and inability to visualize treatment effectiveness immediately.<sup>4,21</sup> In this report, we describe our center's experience using various endovascular therapies to treat ischemic stroke at least 8 hours after stroke symptom onset and including WUS.

### Materials and Methods

A retrospective review was conducted of a prospectively collected registry of acute ischemic stroke patients undergoing endovascular treatment at a single high-volume stroke center (Millard Fillmore Gates Hospital) between June 2005 and June 2008. Data for the consecutive series of patients who had an angiogram with intent-to-treat at least 8 hours after the time when they were last known to be normal (TLSW) were collected and analyzed. Our Institutional Review Board approved this study.

### Patient Selection

All patients who had witnessed or nonwitnessed (including WUS) strokes with TLSW between 7 and 23 hours (treatment initiation between 8 and 24 hours) and had a premorbid modified Rankin score (mRS) score of 0 to 1 and NIHSS between 5 and 22 were included in this study. All patients had cranial CT, CTA, and CT perfusion scans on admission. After the diagnosis of ischemic stroke caused by vessel occlusion had been made and the presence of an intracranial hemorrhage had been excluded by noncontrast CT imaging, CT perfusion scans were analyzed to evaluate for salvageable brain tissue. Endovascular therapy was only implemented on those patients in whom CT perfusion volume maps demonstrated the presence of clinically significant salvageable brain tissue as compared with established core infarct (less than one-third of the middle cerebral artery territory) that was at high risk for hemorrhagic conversion (ASPECTS  $\geq 7$ )<sup>22</sup> as demonstrated by CT perfusion cerebral blood volume maps. Cause of ischemic stroke was determined by a complete neurological-neuroimaging evaluation, including diagnostic angiography, noninvasive imaging, telemetry, and 2-dimensional echocardiography.

### CT Perfusion Protocol

Our CT perfusion protocol starts with an axial noncontrast cranial CT scan. If hemorrhage was present, the protocol was aborted and these patients were not included in this review. Most perfusion scans were performed on the Toshiba Aquilion 64-slice CT scanner (Toshiba American Medical Systems, Inc). Maps obtained by the Aquilion 64 were generated using both Gaussian Fit and single value deconvolution methods using Vitrea software (Vital Images), yielding the following perfusion parameters: time to peak, mean transit time, cerebral blood flow, and cerebral blood volume. Patients with significant salvageable brain tissue were identified and chosen for intervention on the basis of preserved cerebral blood volume, using the criteria of  $>30\%$  relative cerebral blood volume values, compared with the unaffected hemisphere. If this criterion was satisfied using both analysis methods, the patient was selected for intervention. The few perfusion maps obtained from the Toshiba Aquilion One (320-slice CT scanner that creates whole-brain perfusion maps) were also analyzed by Gaussian fit and single value deconvolution, as well as the newest single value deconvolution plus algorithm, using Vitrea software, yielding the additional perfusion parameters of mean time to peak and a delay map. Patients were chosen for treatment using the same criteria as that for the Aquilion 64 with the

additional requirement for preserved volume on the single value deconvolution plus maps. This helped in identifying patients with decreased cerebral blood flow in the same hemisphere if there was a coexisting ipsilateral carotid stenosis.

### Treatment Protocol

Endovascular therapy was commonly performed under conscious sedation with a rigid easily detachable headholder, thereby allowing safe road mapping, adequate imaging, and continuous monitoring of the patient's neurological examination. General anesthesia was used only in cases of large dominant hemisphere strokes or for uncooperative patients. Antiplatelet therapy was instituted or continued on all patients within the first 24 hours. All patients receiving stents were given a loading dose of clopidogrel on the angiogram table via a nasogastric feeding tube. Mechanical revascularization methods were the primary choice in these patients because the use of thrombolytics at a delayed time window increases the risk of hemorrhage. Intra-arterial (IA) pharmacological thrombolysis (t-PA) was used only when the clot was not accessible with available devices or as an adjunct to mechanical strategies. An IA GP IIb/IIIa inhibitor (eptifibatid) was used if thrombus formation was noticed after recanalization. All patients were monitored in a neurosurgical intensive care unit for at least the first 24 hours after intervention. All patients received a postintervention noncontrast cranial CT scan and CT perfusion imaging and CTA on the day after the intervention.

### Data Collected

Data collected were patient characteristics (age, sex, comorbid conditions, antithrombotic agent intake, presentation NIHSS score, TLSW); treatment characteristics (angiography-catheterization time, occlusion site, occlusion grade [TIMI grading], recanalization time [time interval between catheterization and revascularization], type of intervention, adjunctive heparinization, procedural complications, extent of recanalization [TIMI]); immediate posttreatment outcome (symptomatic intracerebral hemorrhage, presence of parenchymal hemorrhage [ECASS II grading],<sup>23</sup> subarachnoid hemorrhage, discharge NIHSS score, discharge destination, hospital stay, morbidity, and mortality); and 3-month follow-up data (mRS, mortality [evaluated by the interventionist and NIHSS-certified members of his team]).

## Results

### Patient Characteristics

Thirty patients who presented with acute ischemic stroke at least 8 hours after the TLSW (including WUS) were selected for endovascular revascularization after clinical assessment and imaging. There were 17 men and 13 women, with a mean age of 72 years (range, 24–91 years), who presented with a mean NIHSS of 13 (median, 12; range, 5–22). Twenty-seven patients had anterior-circulation ischemia and 3 had posterior-circulation ischemia. Stroke risk factors included hypertension in 21 patients (70%), smoking in 11 (36.6%), hyperlipidemia in 10 (33.3%), atrial fibrillation in 13 (43.3%), diabetes mellitus in 10 (33.3%), previous stroke in 2 (6.6%; 1 ipsilateral), transient ischemic attacks in 2 (6.6%; both ipsilateral), myocardial infarction in 3 (10%), and hypercoagulable state in 3 (10%). Nine patients (30%) had concomitant coronary artery disease, 2 (6.6%) had cardiomyopathy, and 7 (23.3%) had cardiac valvulopathy. At presentation, 11 patients (36.6%) were using aspirin, 4 were using clopidogrel (13.3%), 7 (23.3%) each were using warfarin and a statin, and 1 was using aspirin/extended-release dipyridamole. Overall, 19 (63.3%) patients were receiving some form of antiplatelet or anticoagulant therapy at presentation. The etiology for ischemic stroke was determined to be arterioem-

bolic in 7 patients (23.3%), cardioembolic in 13 (43.3%), left-to-right cardiac shunt in 1, and unknown in 9 (30%). Occlusion sites were cervical ICA in 2 patients, petrous ICA in 2, intracranial ICA in 4, proximal M1 in 7, distal M1 in 13, M2 in 7, vertebrobasilar junction to superior cerebellar artery in 2, superior cerebellar artery to basilar artery bifurcation in 2, A1 in 1, and A2 in 1. Eight patients had multiple intracranial occlusions (ICA terminus, A1, and M1-3; M1 and M2-5), and 1 patient had tandem cervical ICA and intracranial M1 occlusions. Twenty-six of 30 patients (86.7%) presented with complete to near-complete vessel occlusion (TIMI 0/1); 4 patients presented with partial vessel occlusion (TIMI 2).

### Treatment Characteristics

Mean interval between TLSW and angiography-catheterization time was 12.75 hours (median, 10 hours; range, 8–27.5 hours). Mean time from emergency department door to angiography-catheterization time was 3.5 hours (median, 3 hours; range, 0.25–8.0 hours). Interventions included IA pharmacological thrombolysis in 10 patients (8 alone; 2 in combination with mechanical measures), mechanical thrombectomy in 21 patients (Merci [Concentric Medical], 16; intracranial stent, 9; extracranial stent, 3), and balloon angioplasty in 14 (intracranial, 11; extracranial, 3). A total of 9 patients received IA (8 patients) or intravenous (6 patients) eptifibatid in combination with endovascular therapy. Heparin was used in all patients to an activated coagulation time measured at 250 seconds.

Partial-to-complete recanalization (TIMI grade 2/3) was achieved in 20 of 30 patients (66.7%). The mean time to recanalization from angiography-catheterization time was 87 minutes (median, 83 minutes; range, 30 minutes to 4 hours). Procedure-related complications included vascular perforations in 3 patients and a femoral access site complication in 1. One patient required a craniotomy because of inability to open the initial middle cerebral artery M1 occlusion (with subsequent hemispheric infarct, edema, and impending herniation from mass effect); 1 patient had an anterior cerebral artery (ACA) infarct attributable to embolus during intervention, despite attempting IA thrombolytics and IA eptifibatid for the embolus; and another had progression of brain stem infarct and underwent percutaneous endoscopic gastrostomy placement.

### Immediate Posttreatment Outcomes

Postprocedure hemorrhage (subarachnoid hemorrhage or ICH) was radiologically detected in 9 patients (33.3%). Eight (26.7%) patients had subarachnoid hemorrhages and 8 had parenchymal hemorrhages (HI 1-3, HI 2-1, PH 1-3, PH 2-1 [ECASS II<sup>23</sup> grades]). Symptomatic intracerebral hemorrhage was present in 3 patients (10%), with 2 of these being primarily subarachnoid in location (and 1 being a PH2). Of these, all 3 had Merci clot retrieval, stents placed, and IA t-PA; 1 had additional balloon angioplasty; and 1 had intravenous bolus eptifibatid. Four patients (13.3%) were discharged home, 15 (50%) were discharged to rehabilitation (acute and subacute), and 4 (13.3%) were sent to chronic care facilities. The total in-hospital mortality rate including pro-

cedural mortality, progression of disease, or other comorbidities was 23.3% (7 patients). Mean discharge NIHSS was 9.5, representing an overall NIHSS improvement of 3.5 points.

### Three-Month Outcomes

At 3 months, total mortality rate was 33.3% (10 patients). Overall, mean mRS at death or last follow up (mean, 10.6 months) was 4.2. Twenty-percent (6 patients) had good outcomes (mRS  $\leq$ 2) and 33% (10 patients) had acceptable outcomes (mRS  $\leq$ 3). Among survivors, mean mRS at the time of the 3-month follow up was 3.

### Discussion

Until the recent publication of ECASS III,<sup>15</sup> there had been no level 1 evidence in the form of a randomized controlled trial with primary clinical outcome measures for intravenous t-PA (or, indeed, clot retrieval) beyond 3 hours. The results of this trial have extended the time window to 4.5 hours for intravenous t-PA.<sup>15</sup> Furthermore, there is strong evidence for IA thrombolysis in middle cerebral artery occlusion up to 6 hours, based on the PROACT II results.<sup>24</sup> The pooled analysis by Hacke et al<sup>25</sup> demonstrates a treatment effect up to 4.5 hours, and the meta-analysis by Wardlaw et al<sup>26</sup> demonstrates a treatment effect up to 6 hours, thus formally providing level 1 evidence (meta-analysis of randomized controlled trials), even in patients selected by “only” noncontrast CT. There is increasing evidence that identification of potentially salvageable brain tissue with advanced MR and CT imaging may allow selection of patients who can be effectively and safely treated with intravenous thrombolysis for up to 9 hours after ictus.<sup>9–16</sup> Although MR imaging-based perfusion imaging is a useful imaging modality for determining salvageable tissue, CT perfusion has been shown to be comparable<sup>27,28</sup> and is widely available. In this study, we used CT perfusion images to define the core and penumbra in acute ischemic stroke.

The Table compares our study to the NINDS Recombinant t-PA Stroke Study,<sup>2</sup> prominent studies of endovascular treatments for acute ischemic stroke,<sup>5,24,29</sup> and the recently published DIAS-2 study because the time window in this study was up to 9 hours and the investigators used MR imaging to assess salvageable brain tissue for treatment selection.<sup>16</sup> Our recanalization rate of 66.7% was comparable to previous series using endovascular interventions for opening up acutely occluded vessels. The use of GP IIb/IIIa inhibitors changes the prothrombotic–antithrombotic balance in the intracranial vessels, thus probably facilitating and maintaining recanalization.<sup>30,31</sup> The rates of complications, symptomatic intracerebral hemorrhage, and mortality at 3 months are comparable to previous studies in which patients were treated within a shorter duration after stroke onset.

All 3 patients with posterior circulation ischemia had basilar artery occlusions and were selected for intervention based on CT perfusion imaging. They presented with NIHSS scores of 18, 5, and 18 with TLSW–angiography-catheterization time of 19.5, 19, and 9.5 hours, respectively. Merci device was used in the first patient, but we were not able to reopen the vessel and there was a perforation with subarachnoid hemorrhage. The second patient had TIMI 3 flow after Merci, IA t-PA, and IA eptifibatid. The third patient had

**Table. Comparison of Our Study With Previous Acute Ischemic Stroke Studies**

	NINDS <sup>2</sup>	DIAS-2 <sup>16</sup>	PROACT I <sup>29</sup>	PROACT II <sup>24</sup>	Multi MERCI <sup>5</sup>	Our Study
Revascularization strategy	IV t-PA vs placebo	IV desmoteplase	IA r-proUK vs placebo	IA r-proUK+heparin vs heparin	Recent Merci+IA t-PA	IA t-PA, Angioplasty, Merci, Stents+Heparin±GP IIb/IIIa
Time window	3 hours	3–9 hours MR perfusion	6 hours	6 hours	8 hours	8–27.5 hours (including WUS)
Primary end points	Part 1: 4-point NIHSS improvement or resolution of deficit within 24 hours; Part 2: BI, mRS, GOS, NIHSS at 3 mon	NIHSS, BI, mRS at 90 days, infarct volume	Recanalization at 2 hours. NIHSS, mRS, BI at 7, 30, and 90 days; SICH	mRS <2 at 90 days	Recanalization rate, complications	NIHSS at discharge, recanalization rate, complications, SICH
Secondary end points	Not mentioned	Not mentioned	Not mentioned	MCA recanalization, SICH, mortality	mRS and mortality at 90 days	mRS at 3 mon and mortality
Placebo arm	Yes	Yes	Yes	Yes	No	No
Recanalization rate	NA	NA	57.7%	66%	70%	66.7%
SICH	6.4%	4.5%	15.4%	10%	9.8%	10%
NIHSS improvement	14 to 8	9 to not reported	17 to not reported	19 to not reported	19 to not reported	13 to 9.5
mRS <2 or <1* at 3 mon	39%*	40%	30.8%*	40%	36.7%	20%
Mortality at 3 mon	17%	21%	26.9%	26%	26%	33.3%

BI indicates Barthel Index; DIAS-2, Desmoteplase in Acute Ischemic Stroke-2; GOS, Glasgow Outcome Scale; GP, glycoprotein; IA, intraarterial; IV, intravenous; MCA, middle cerebral artery; MERCI, Mechanical Embolus Removal in Cerebral Ischemia; MR, magnetic resonance; NA, not available; NIHSS, National Institutes of Health Stroke Scale; NINDS, National Institute of Neurological Disorders and Stroke Recombinant Tissue Plasminogen Activator Stroke Study; PROACT, Prolyse in Acute Cerebral Thromboembolism; SICH, symptomatic intracranial hemorrhage; UK, urokinase.

TIMI 2 flow after Wingspan stent (Boston Scientific) placement. The first 2 patients did not recover from their original insult and died within 30 days. The third patient had a brain stem infarct, underwent percutaneous endoscopic gastrostomy placement for swallowing difficulty, was sent for inpatient rehabilitation, and had an mRS of 4 at 3 months.

Of the 3 patients who had perforations, 2 had a perforation during attempted stent placement—1 after angioplasty before balloon-mounted stent placement and another after attempted self-expanding stent placement. Both these patients underwent intubation and were managed conservatively in the intensive care unit but did not survive for >1 month after the intervention. The third patient did not have an obvious perforation during angiography after Merci retrieval, but the postprocedure CT scan showed a subarachnoid hemorrhage that was suggestive of a perforation. The patient was managed conservatively and had mRS of 2 at the 3-month follow-up evaluation.

Only 20% and 33% of patients in our series had favorable and acceptable outcomes, respectively, at 3 months. These rates are lower than those in previous studies (Table). Differences can be explained by the decrease in the ability to salvage brain tissue as the time window from insult to treatment increases. Nevertheless, in our series, there was an improvement of 3.5 points in NIHSS overall attributable to treatment, and 33% of patients had an acceptable outcome with comparable morbidity and mortality. The addition of neuroprotectants may further improve the outcomes in this group of patients, and this needs to be studied in the future.<sup>32–35</sup>

Janjua et al<sup>36</sup> used clinical diffusion mismatch criteria (patients with NIHSS >8 with limited abnormality on DWI imaging) to evaluate the benefit of endovascular interventions in 11 patients with large vessel occlusion presenting >8 hours after stroke symptom onset. At 1 week after treatment, 72% of the total and 100% of successfully revascularized patients in their study had a decrease of >4 points in NIHSS score. The DAWN trial<sup>37</sup> is an ongoing multicenter trial designed to study safety and efficacy of endovascular treatment in MR or CT perfusion-selected patients with acute ischemic stroke attributable to a proximal large-vessel anterior circulation occlusion (eg, ICA and/or middle cerebral artery M1 segment) who present “beyond the typical therapeutic window” >8 hours (including “wake-up”) events. The main hypothesis of this trial is that MR or CT perfusion-based endovascular treatment in wake-up and late-presenting stroke patients is at least as safe and effective as standard endovascular treatment performed within 8 hours of symptoms onset and leads to improved outcomes when compared to best medical treatment. The results of this trial may provide more evidence of the benefits of treatment in this group of patients.

### Conclusions

Our study sheds light on the safety, effectiveness, and feasibility of endovascular therapy for patients presenting after 8 hours of stroke symptom onset and WUS. The recanalization rate with endovascular therapy is superior to that reported using intravenous t-PA, whereas the rate of symptomatic intracerebral hemorrhage is low. There is a moderate improvement in outcome at 3 months in these

patients when they are carefully selected with perfusion imaging, without an increase in morbidity or mortality. Prospective randomized controlled trials are needed to assess the role of endovascular intervention after 8 hours of stroke symptom onset and WUS.

### Acknowledgments

The authors thank Debi Zimmer, AAS CMA-A, for editorial assistance. All authors conceived and designed the research. Natarajan and Snyder acquired data. Natarajan analyzed and interpreted the data. Natarajan performed statistical analysis. Levy, Siddiqui, and Hopkins handled funding and supervision. Natarajan drafted the manuscript. All authors made critical revision of the manuscript for important intellectual content.

### Disclosures

Dr Hopkins has an ownership interest in AccessClosure, Boston Scientific, Micrus, and Square One, Inc. (<\$10 000 each); and serves as a consultant to/member of the advisory board for Abbott, AccessClosure, Bard, Boston Scientific, Cordis, and Micrus (<\$10 000 each). Dr Levy receives research grant support, other research support (devices), and honoraria from Boston Scientific (>\$10 000) and research support from Micrus Endovascular (>\$10 000) and ev3 (<\$10 000); has ownership interests in Intratech Medical Ltd. (<\$10 000) and Mynx/AccessClosure (>\$10 000); serves as a consultant on the board of Scientific Advisors to Cordis Neurovascular, and as a consultant receiving fees on a per-project per-hour basis only for Micrus Endovascular, ev3, and TheraSyn Sensors, Inc; and receives fees for carotid stent training from Abbott Vascular and ev3 (>\$10 000). Dr Siddiqui has received a research grant from the University at Buffalo (<\$10 000); is a consultant to Codman/Cordis, Concentric Medical, ev3, Micrus Endovascular, and Neocure (<\$10 000 each); serves on the speakers' bureaus for Cordis and Genentech (<\$10 000 each); and has received honoraria from Genentech, Neocure, an American Association of Neurological Surgeons' course, an Emergency Medicine Conference, and from Cordis for training other neurointerventionists (<\$10 000 each). Dr Ionita, Dr Natarajan, and Dr Snyder have nothing to disclose.

### References

- Lloyd-Jones D, Adams R, Carnethon M, De Simone G, Ferguson TB, Flegal K, Ford E, Furie K, Go A, Greenland K, Haase N, Hailpern S, Ho M, Howard V, Kissela B, Kittner S, Lackland D, Lisabeth L, Marelli A, McDermott M, Meigs J, Mozaffarian D, Nichol G, O'Donnell C, Roger V, Rosamond W, Sacco R, Sorlie P, Stafford R, Steinberger J, Thom T, Wasserthiel-Smolter S, Wong N, Wylie-Rosett J, Hong Y. Heart disease and stroke statistics—2009 update: a report from the American Heart Association Statistics Committee and Stroke Statistics Subcommittee. *Circulation*. 2009;119:480–486.
- Tissue plasminogen activator for acute ischemic stroke. The National Institute of Neurological Disorders and Stroke rt-PA Stroke Study Group. *N Engl J Med*. 1995;333:1581–1587.
- Barber PA, Zhang J, Demchuk AM, Hill MD, Buchan AM. Why are stroke patients excluded from tPA therapy? An analysis of patient eligibility. *Neurology*. 2001;56:1015–1020.
- Nogueira RG, Schwamm LH, Hirsch JA. Endovascular Approaches to Acute Stroke. Part 1: Drugs, Devices, and Data. *AJNR Am J Neuroradiol*. 2009.
- Smith WS, Sung G, Saver J, Budzik R, Duckwiler G, Liebeskind DS, Lutsep HL, Rymer MM, Higashida RT, Starkman S, Gobin YP, Frei D, Grobelny T, Hellinger F, Huddle D, Kidwell C, Koroshetz W, Marks M, Nesbit G, Silverman IE. Mechanical thrombectomy for acute ischemic stroke: final results of the Multi MERCI trial. *Stroke*. 2008;39:1205–1212.
- Chiam PT, Samuelson RM, Mocco J, Hanel RA, Siddiqui AH, Hopkins LN, Levy EI. Navigability trumps all: stenting of acute middle cerebral artery occlusions with a new self-expandable stent. *AJNR Am J Neuroradiol*. 2008;29:1956–1958.
- Wintermark M, Flanders AE, Velthuis B, Meuli R, van Leeuwen M, Goldsher D, Pineda C, Serena J, van der Schaaf I, Waaijer A, Anderson J, Nesbit G, Gabriely I, Medina V, Quiles A, Pohlman S, Quist M, Schnyder P, Bogousslavsky J, Dillon WP, Pedraza S. Perfusion-CT assessment of infarct core and penumbra: receiver operating characteristic curve analysis in 130 patients suspected of acute hemispheric stroke. *Stroke*. 2006;37:979–985.
- Ostergaard L, Jonsdottir KY, Mouridsen K. Predicting tissue outcome in stroke: new approaches. *Curr Opin Neurol*. 2009;22:54–59.
- Hacke W, Albers G, Al-Rawi Y, Bogousslavsky J, Davalos A, Eliasziw M, Fischer M, Furlan A, Kaste M, Lees KR, Soehngen M, Warach S. The Desmoteplase in Acute Ischemic Stroke Trial (DIAS): a phase II MRI-based 9-hour window acute stroke thrombolysis trial with intravenous desmoteplase. *Stroke*. 2005;36:66–73.
- Furlan AJ, Eydling D, Albers GW, Al-Rawi Y, Lees KR, Rowley HA, Sachara C, Soehngen M, Warach S, Hacke W. Dose Escalation of Desmoteplase for Acute Ischemic Stroke (DEDAS): evidence of safety and efficacy 3 to 9 hours after stroke onset. *Stroke*. 2006;37:1227–1231.
- Albers GW, Thijs VN, Wechsler L, Kemp S, Schlaug G, Skalabrini E, Bammer R, Kakuda W, Lansberg MG, Shuaib A, Coplin W, Hamilton S, Moseley M, Marks MP. Magnetic resonance imaging profiles predict clinical response to early reperfusion: the diffusion and perfusion imaging evaluation for understanding stroke evolution (DEFUSE) study. *Ann Neurol*. 2006;60:508–517.
- Thomalla G, Schwark C, Sobesky J, Bluhmki E, Fiebich JB, Fiehler J, Zaro Weber O, Kucinski T, Juettler E, Ringleb PA, Zeumer H, Weiller C, Hacke W, Schellinger PD, Rother J. Outcome and symptomatic bleeding complications of intravenous thrombolysis within 6 hours in MRI-selected stroke patients: comparison of a German multicenter study with the pooled data of ATLANTIS, ECASS, and NINDS tPA trials. *Stroke*. 2006;37:852–858.
- Kohrmann M, Juttler E, Fiebich JB, Huttner HB, Siebert S, Schwark C, Ringleb PA, Schellinger PD, Hacke W. MRI versus CT-based thrombolysis treatment within and beyond the 3 h time window after stroke onset: a cohort study. *Lancet Neurol*. 2006;5:661–667.
- Davis SM, Donnan GA, Parsons MW, Levi C, Butcher KS, Peeters A, Barber PA, Bladin C, De Silva DA, Byrnes G, Chalk JB, Fink JN, Kimber TE, Schultz D, Hand PJ, Frayne J, Hankey G, Muir K, Gerraty R, Tress BM, Desmond PM. Effects of alteplase beyond 3 h after stroke in the Echoplanar Imaging Thrombolytic Evaluation Trial (EPITHET): a placebo-controlled randomised trial. *Lancet Neurol*. 2008;7:299–309.
- Hacke W, Kaste M, Bluhmki E, Brozman M, Davalos A, Guidetti D, Larrue V, Lees KR, Medeghri Z, Machnig T, Schneider D, von Kummer R, Wahlgren N, Toni D. Thrombolysis with alteplase 3 to 4.5 hours after acute ischemic stroke. *N Engl J Med*. 2008;359:1317–1329.
- Hacke W, Furlan AJ, Al-Rawi Y, Davalos A, Fiebich JB, Gruber F, Kaste M, Lipka LJ, Pedraza S, Ringleb PA, Rowley HA, Schneider D, Schwamm LH, Leal JS, Soehngen M, Teal PA, Wilhelm-Ogunbiyi K, Wintermark M, Warach S. Intravenous desmoteplase in patients with acute ischaemic stroke selected by MRI perfusion-diffusion weighted imaging or perfusion CT (DIAS-2): a prospective, randomised, double-blind, placebo-controlled study. *Lancet Neurol*. 2009;8:141–150.
- Fink JN, Kumar S, Horkan C, Linfante I, Selim MH, Caplan LR, Schlaug G. The stroke patient who woke up: clinical and radiological features, including diffusion and perfusion MRI. *Stroke*. 2002;33:988–993.
- Serena J, Davalos A, Segura T, Mostacero E, Castillo J. Stroke on awakening: looking for a more rational management. *Cerebrovasc Dis*. 2003;16:128–133.
- Barreto AD, Martin-Schild S, Halleivi H, Morales MM, Abraham AT, Gonzales NR, Illoh K, Grotta JC, Savitz SI. Thrombolytic therapy for patients who wake-up with stroke. *Stroke*. 2009;40:827–832.
- Rha JH, Saver JL. The impact of recanalization on ischemic stroke outcome: a meta-analysis. *Stroke*. 2007;38:967–973.
- Broderick JP. Endovascular therapy for acute ischemic stroke. *Stroke*. 2009;40:S103–S106.
- Tsivgoulis G, Saqqur M, Sharma VK, Lao AY, Hoover SL, Alexandrov AV. Association of pretreatment ASPECTS scores with tPA-induced arterial recanalization in acute middle cerebral artery occlusion. *J Neuroimaging*. 2008;18:56–61.
- Larrue V, von Kummer RR, Muller A, Bluhmki E. Risk factors for severe hemorrhagic transformation in ischemic stroke patients treated with recombinant tissue plasminogen activator: a secondary analysis of the European-Australasian Acute Stroke Study (ECASS II). *Stroke*. 2001;32:438–441.
- Furlan A, Higashida R, Wechsler L, Gent M, Rowley H, Kase C, Pessin M, Ahuja A, Callahan F, Clark WM, Silver F, Rivera F. Intra-arterial prourokinase for acute ischemic stroke. The PROACT II study: a ran-

- domized controlled trial. Prolyse in Acute Cerebral Thromboembolism. *JAMA*. 1999;282:2003-2011.
25. Hacke W, Donnan G, Fieschi C, Kaste M, von Kummer R, Broderick JP, Brott T, Frankel M, Grotta JC, Haley EC Jr, Kwiatkowski T, Levine SR, Lewandowski C, Lu M, Lyden P, Marler JR, Patel S, Tilley BC, Albers G, Bluhmki E, Wilhelm M, Hamilton S. Association of outcome with early stroke treatment: pooled analysis of ATLANTIS, ECASS, and NINDS rt-PA stroke trials. *Lancet*. 2004;363:768-774.
  26. Wardlaw JM, Sandercock PA, Berge E. Thrombolytic therapy with recombinant tissue plasminogen activator for acute ischemic stroke: where do we go from here? A cumulative meta-analysis. *Stroke*. 2003;34:1437-1442.
  27. Schaefer PW, Barak ER, Kamalian S, Gharai LR, Schwamm L, Gonzalez RG, Lev MH. Quantitative assessment of core/penumbra mismatch in acute stroke: CT and MR perfusion imaging are strongly correlated when sufficient brain volume is imaged. *Stroke*. 2008;39:2986-2992.
  28. Wintermark M, Meuli R, Browaeys P, Reichhart M, Bogousslavsky J, Schnyder P, Michel P. Comparison of CT perfusion and angiography and MRI in selecting stroke patients for acute treatment. *Neurology*. 2007;68:694-697.
  29. del Zoppo GJ, Higashida RT, Furlan AJ, Pessin MS, Rowley HA, Gent M. PROACT: a phase II randomized trial of recombinant pro-urokinase by direct arterial delivery in acute middle cerebral artery stroke. PROACT Investigators. Prolyse in Acute Cerebral Thromboembolism. *Stroke*. 1998;29:4-11.
  30. Deshmukh VR, Fiorella DJ, Albuquerque FC, Frey J, Flaster M, Wallace RC, Spetzler RF, McDougall CG. Intra-arterial thrombolysis for acute ischemic stroke: preliminary experience with platelet glycoprotein IIb/IIIa inhibitors as adjunctive therapy. *Neurosurgery*. 2005;56:46-54. discussion 54-45.
  31. Mangiafico S, Cellerini M, Nencini P, Gensini G, Inzitari D. Intravenous glycoprotein IIb/IIIa inhibitor (tirofiban) followed by intra-arterial urokinase and mechanical thrombolysis in stroke. *AJNR Am J Neuroradiol*. 2005;26:2595-2601.
  32. Lapchak PA, Araujo DM. Advances in ischemic stroke treatment: neuroprotective and combination therapies. *Expert Opin Emerg Drugs*. 2007;12:97-112.
  33. Okubo S, Igarashi H, Kanamatsu T, Hasegawa D, Orima H, Katayama Y. FK-506 extended the therapeutic time window for thrombolysis without increasing the risk of hemorrhagic transformation in an embolic rat stroke model. *Brain Res*. 2007;1143:221-227.
  34. Gutierrez M, Diez Tejedor E, Alonso de Lecinana M, Fuentes B, Carceller F, Roda JM. Thrombolysis and neuroprotection in cerebral ischemia. *Cerebrovasc Dis*. 2006;21(Suppl 2):118-126.
  35. Murata Y, Rosell A, Scannevin RH, Rhodes KJ, Wang X, Lo EH. Extension of the thrombolytic time window with minocycline in experimental stroke. *Stroke*. 2008;39:3372-3377.
  36. Janjua N, El-Gengaihy A, Pile-Spellman J, Qureshi AI. Late endovascular revascularization in acute ischemic stroke based on clinical-diffusion mismatch. *AJNR Am J Neuroradiol*. 2009;30:1024-1027.
  37. Nogueira RG, Liebeskind DS, Gupta R, Levy EI, Rai AT, Baxter B, Yoo A, Gonzalez RG, Schaefer PW, Lev MH, Jovin TG. DWI/PWI and CTP Assessment in the Triage of Wake-Up and Late Presenting Strokes Undergoing Neurointervention: The DAWN Trial. Presented at the International Stroke Conference, San Diego, CA; February 2009;17-20.



**Paper-12:**

**W.W. Orrison, K.V. Snyder, L.N. Hopkins, C.J. Roach, et al.: Whole-brain dynamic CT angiography and perfusion imaging. *Clinical Radiology*, 66 (6) 2011. Pages 566-574**




ELSEVIER

Contents lists available at ScienceDirect

Clinical Radiology

journal homepage: [www.elsevierhealth.com/journals/crad](http://www.elsevierhealth.com/journals/crad)



Pictorial Review

# Whole-brain dynamic CT angiography and perfusion imaging

W.W. Orrison Jr.<sup>a,b,c,d</sup>, K.V. Snyder<sup>e</sup>, L.N. Hopkins<sup>e</sup>, C.J. Roach<sup>f,g</sup>, E.N. Ringdahl<sup>h</sup>, R. Nazir<sup>i</sup>, E.H. Hanson<sup>b,c,g,\*</sup>

<sup>a</sup> CHW Nevada Imaging Company, Nevada Imaging Centers, Spring Valley, Las Vegas, NV, USA

<sup>b</sup> College of Osteopathic Medicine, Touro University Nevada, Henderson, NV, USA

<sup>c</sup> Department of Health Physics and Diagnostic Sciences, University of Nevada Las Vegas, Las Vegas, NV, USA

<sup>d</sup> Department of Medical Education, University of Nevada School of Medicine, Reno, NV, USA

<sup>e</sup> Department of Neurosurgery, Millard Fillmore Gates Circle Hospital, Buffalo, NY, USA

<sup>f</sup> School of Life Sciences, University of Nevada Las Vegas, Las Vegas, NV, USA

<sup>g</sup> Advanced Medical Imaging and Genetics (Amigenics), Las Vegas, NV, USA

<sup>h</sup> Department of Psychology, University of Nevada Las Vegas, Las Vegas, NV, USA

<sup>i</sup> Shifa International Hospital, Islamabad, Pakistan

## ARTICLE INFORMATION

### Article history:

Received 20 October 2010

Received in revised form

21 December 2010

Accepted 29 December 2010

The availability of whole brain computed tomography (CT) perfusion has expanded the opportunities for analysing the haemodynamic parameters associated with varied neurological conditions. Examples demonstrating the clinical utility of whole-brain CT perfusion imaging in selected acute and chronic ischaemic arterial neurovascular conditions are presented. Whole-brain CT perfusion enables the detection and focused haemodynamic analyses of acute and chronic arterial conditions in the central nervous system without the limitation of partial anatomical coverage of the brain.

© 2011 The Royal College of Radiologists. Published by Elsevier Ltd. All rights reserved.

## Introduction

Over the last two decades there have been significant advances in computed tomography (CT) technology beginning with multisection/spiral scanning followed by expansion of multidetector CT (four to 64 detector-rows) allowing three-dimensional (3D) CT angiography (CTA) and cerebral perfusion studies. Until recently, these CT systems remained limited in whole-brain coverage (z-axis). One approach to overcoming this limitation is the table toggling technique.<sup>1</sup>

Unfortunately, the results achieved with table toggling techniques have been limited by difficulty in standardizing calibration of the toggling technology and this technique cannot facilitate whole-brain perfusion imaging in a rapid scan time. The availability of 320-detector row CT with 160 mm of z-axis coverage has allowed for whole-brain evaluation with a single gantry rotation. Temporal uniformity is possible with imaging of the entire brain during each volume acquisition following contrast medium administration. This new methodology provides for extremely rapid access to four important aspects of neurovascular disease assessment: (1) unenhanced whole-brain CT, (2) contrast-enhanced whole-brain CT, (3) real-time 3D dynamic CTA, and (4) whole-brain CT perfusion (CTP).

Unenhanced CT is well established as the benchmark examination for the acute assessment of intracranial

\* Guarantor and correspondent: E.H. Hanson, Amigenics, 5495 South Rainbow Boulevard, Suite 201, Las Vegas, NV 89118, USA. Tel.: +1 (702) 343 2659; fax: +1 (702) 735 9075.

E-mail address: [eric.hanson@amigenics.com](mailto:eric.hanson@amigenics.com) (E.H. Hanson).

haemorrhage. Haemorrhage represents a contraindication to thrombolytic therapy.<sup>2</sup> In addition, the size and location of the haemorrhage may dictate acute changes in management such as intracranial pressure monitoring or surgical intervention. The availability of contrast-enhanced CT images can also provide important information improving visualization of more remote regions of ischaemia (e.g., superior cerebral hemispheres or cerebellar hemispheres) or identifying contrast-enhancing lesions that may affect management decisions.

CT digital subtraction angiography (CT DSA), time-resolved CTA (4D CTA) and time-resolved quantitative CTP measurements of various perfusion parameters, cerebral blood flow (CBF), cerebral blood volume (CBV), mean time transit (MTT), time to peak (TTP), and delay, represent more recent developments in CT technology. Combined use of unenhanced CT, whole-brain 4D CTA, and CTP (4D CTA-CTP) has been used for numerous neurological conditions including arterial steno-occlusive disease [e.g., acute ischaemic stroke (AIS),<sup>3,4</sup> internal carotid artery (ICA) stenosis,<sup>3</sup> transient ischaemic attacks (TIAs)<sup>3</sup>], arteriovenous shunting lesions [e.g., dural arteriovenous fistula,<sup>5</sup> arteriovenous malformation (AVM),<sup>3,5</sup> cortical venous reflux,<sup>5</sup> developmental venous anomalies<sup>6</sup>], intracerebral haemorrhage,<sup>3</sup> vasculitis,<sup>7</sup> and venous occlusive disease (e.g., cortical venous thrombosis with haemorrhagic infarction<sup>3</sup>). CTA-CTP has also been utilized to assess cerebrovascular reserve (CVR) in patients with chronic forms of ischaemia<sup>8,9</sup> and complex steno-occlusive disease (e.g., moyamoya disease).<sup>3</sup>

Time-resolved CTP calculations utilize the central volume principle that relates CBF, CBV and MTT in the equation  $CBF = CBV/MTT$ . CBF is the volume of blood flow per unit of brain tissue per minute (ml/100 g/min), CBV is the volume of blood per unit of brain tissue (ml/100 g), and MTT is measured in seconds. TTP and delay are also measured in seconds. MTT is the capillary transit time and is the mean time required for blood to travel from the arterial input to the venous outflow point while TTP is the amount of time required for the intensity of a particular voxel or region of interest (ROI) to be at its maximum from the time the contrast medium was injected. ROI CTP values can be evaluated following the tracer-kinetic model that assumes an intact blood–brain barrier and an increase in radiodensity (HU) during the first intravascular contrast passage<sup>10</sup> based on a direct linear relationship between contrast medium concentration and radiodensity. CTP parameter maps are then generated most commonly through the application of variations of singular value decomposition (SVD) algorithms.

The information presented here includes acute and chronic arterial neurovascular disease processes as examples of the potential indications for whole-brain CTA-CTP using 320-row CT. Crossed cerebellar diaschisis (CCD), a previously undetected or infrequently detected haemodynamic condition, demonstrates how brain autoregulatory effects can be assessed using whole-brain CTP. Acetazolamide challenge for the assessment of CVR is presented as another example of the importance of whole-brain perfusion. The need to limit radiation exposure during CTP is of

utmost concern.<sup>11</sup> Therefore, suggestions for protocol settings that affect radiation dose are also presented including a summary from the available literature on radiation dose for this newer-generation CT system.

## CTP protocol

A Health Insurance Portability and Accountability Act (HIPAA) compliant, retrospective anonymized study of clinical images was performed with Institutional Review Board exemption approval. Identifying information was not disclosed to study investigators and was not used in analysis or interpretation. A 320 × 0.5 mm detector row CT system (Aquilion ONE, Toshiba Medical Systems, Nasu, Japan) was used. Contrast medium infusion of 50–70 ml (Optiray™350, Mallinckrodt, Missouri, USA) at 4–6 ml/s was completed by automated antecubital venous injection. Detector array size or z-axis coverage was matched with patient head size up to a 160 mm. CTP used 1 s single rotation intermittent dataset scans acquired at 80 kVp. The first volume is used for the mask in the DSA and is acquired at 300 mA. Beginning 5–7 s after contrast medium injection, 13 intermittent volume scans at 100 mA are acquired every other second for 30 s during the contrast medium arrival, arterial phase [collectively creating the arterial tissue-density curve (TDC)] and capillary perfusion of brain tissue phase (collectively creating the brain tissue TDC). Five venous datasets (collectively creating the venous TDC) were then acquired every 5 s for 20 s to complete a 19 volume dataset. The TDCs are created from radiodensity enhancements versus time for the purpose of creating the various perfusion values.<sup>12,13</sup> The two acute ischaemic stroke cases used a tube current boost during the peak arterial enhancement sequence consisting of an initial 300 mA mask followed by 150 mA series for four acquisitions, 300 mA boost for five acquisitions, and 150 mA for four acquisitions (all arterial volume datasets are collected every other second). The final five acquisitions during the venous portion of the TDC were collected at 150 mA and 5 s apart to complete the 19-volume acquisition. DICOM data was reconstructed utilizing Vitrea fX software version 2.0.2 (Vital Images, Minnetonka, MN, USA). A tracer delay invariant single value decomposition plus (SVD+) deconvolution algorithm (Vital Images and Toshiba Medical Systems) was used for dataset analyses. Pixel-based colour parametric map conventions are presented in a spectrum from the lowest values depicted in cold colours or blue to the highest values represented in hot colours up to red. Effective radiation dose in millisieverts for NCCT and 4D CTA-CTP was estimated from console DLP readings and converted to millisieverts using the conversion factor for CT of the head (DLP × 0.0023) according to the European Guidelines for multisection CT.<sup>14</sup>

### *AIS and crossed cerebellar diaschisis*

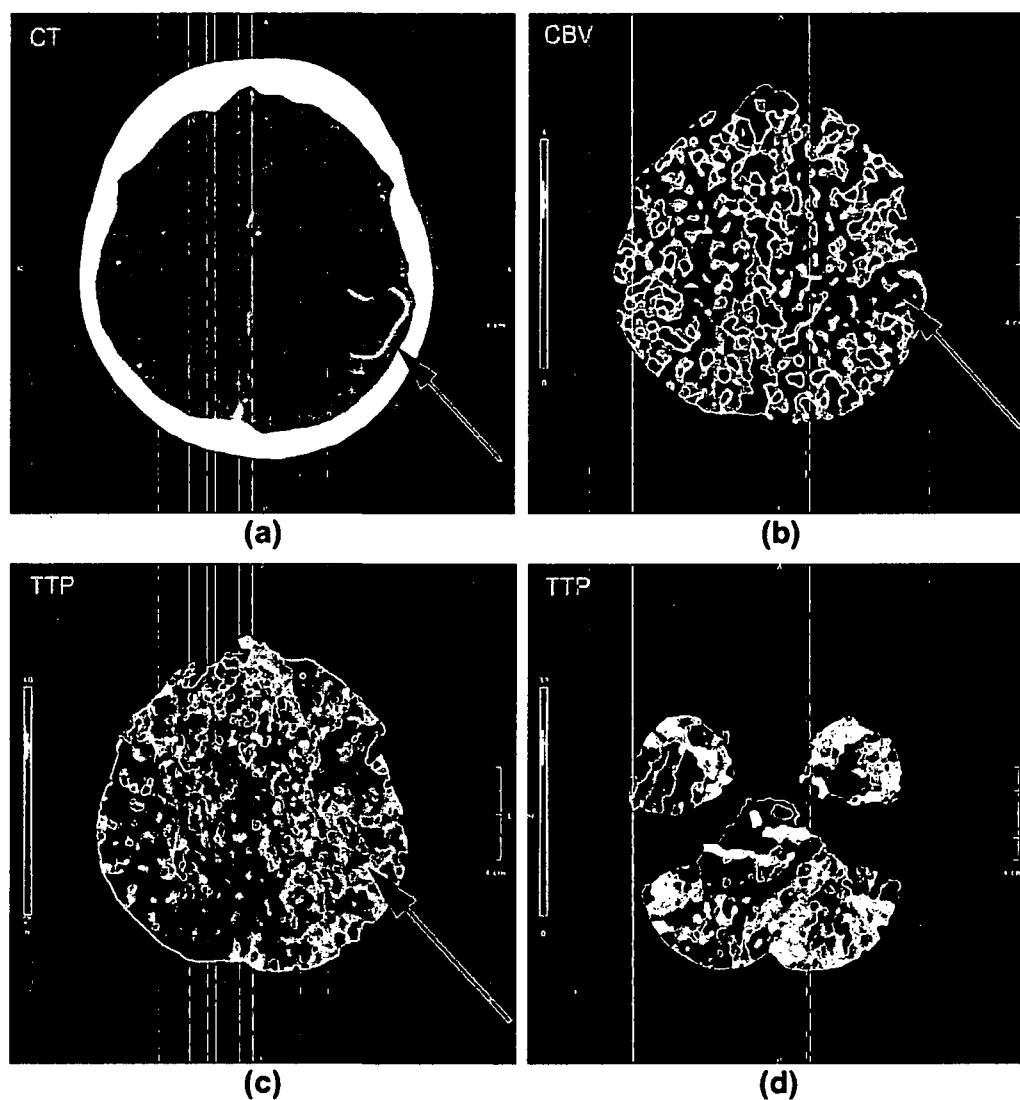
Stroke is the third most common cause of death and the most common cause of permanent disability accounting for 2–4% of worldwide healthcare costs.<sup>15</sup> In 2009, indirect and

direct US costs related to stroke were estimated to be \$68.9 billion (\$49.5B€ for a 2009 yearly average conversion rate of 1 US\$ = €0.719).<sup>16,17</sup> Left parietal AIS and associated crossed cerebellar diaschisis (CCD) are depicted in Fig 1. Diaschisis has been defined as decreased blood flow and metabolism in regions of the brain unaffected by a lesion or structurally separated from an area of damage to the brain.<sup>18</sup> Decreased CBV and CBF with a corresponding prolonged TTP, as well as a prominent collateral leptomeningeal artery, were indicative of acute ischaemia (Fig 1). A prolonged right cerebellar hemisphere TTP indicated delayed perfusion indicative of CCD (Fig 1d). CCD is defined as hypometabolism and decreased blood flow in a cerebellar hemisphere contralateral to a cerebral hemispheric lesion.<sup>19</sup> CCD is hypothesized to be caused by the interruption of afferent corticopontocerebellar fibres due to a contralateral cerebral

lesion. In rats, experimentally induced cerebral ischaemia and fibre disruption lead to a decrease in contralateral cerebellar Purkinje cell spiking activity and blood flow via microelectrode physiological recording.<sup>18</sup> CCD was originally observed using positron-emission tomography (PET) and single photon-emission computed tomography (SPECT) and has also recently been identified using dynamic susceptibility contrast magnetic resonance (MR) perfusion imaging.<sup>20</sup> The availability of whole-brain CTP makes it possible to evaluate patients for this and other potential autoregulatory effects.

#### *AIS and volumetric surface perfusion changes*

Most strokes (87%) are ischaemic.<sup>21</sup> However, less than 2% of AIS patients receive thrombolytic therapy due to the



**Figure 1** A 77-year-old man with left parietal AIS. (a) Note the dilated leptomeningeal artery, located 7.5 mm inferior to the CBV and TTP perfusion maps, indicating collateral autoregulatory response at the lateral aspect of the acute infarction in the contrast CT image (red arrow). (b) Decreased CBV and (c) prolonged TTP in the ischaemic tissue (red arrows). (d) Prolonged TTP in the contralateral cerebellar hemisphere related to the acute cerebral infarction and indicative of crossed cerebellar diaschisis.

limited time-based therapeutic window and contraindications to thrombolysis.<sup>22</sup> Whole-brain CTP can provide rapid delineation of the infarcted core and the ischaemic penumbra facilitating intervention selection.<sup>23</sup> Fig 2 depicts a right middle cerebral artery (MCA) AIS. CBF, TTP, and MTT were reduced centrally in the area of infarction with a peripheral increase in the penumbral tissue at risk secondary to collateral flow. The presence of hypervolaemia is also indicative of viable, salvageable tissue.

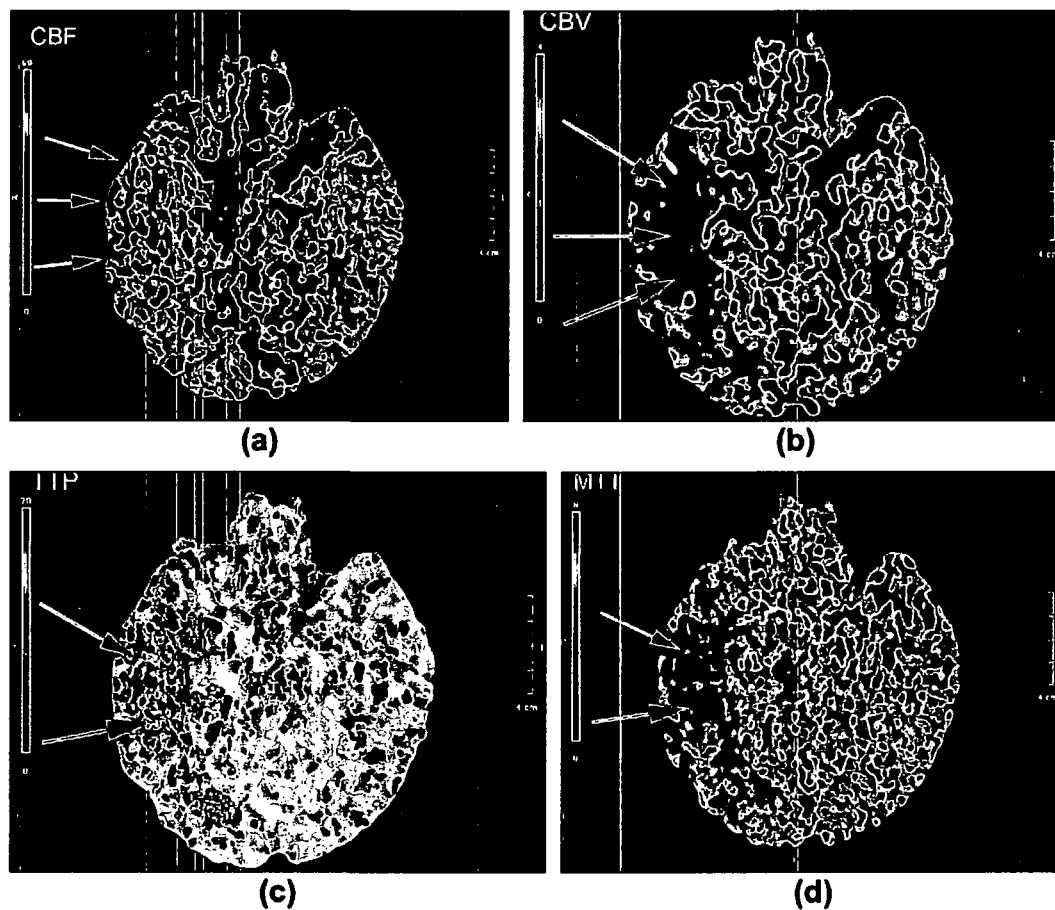
#### *Chronic ICA occlusion with perfusion deficits*

Carotid endarterectomy is the most commonly performed surgical procedure to prevent stroke. Approximately 99,000 procedures were performed in 2006.<sup>17</sup> Carotid stenosis of >50% is identified in 10–15% of patients presenting with TIA or AIS.<sup>21</sup> An example of left common carotid artery occlusion, anterior cerebral artery (ACA) collateral blood flow and cross-flow through the circle of Willis to the left MCA is presented in Fig 3 that was insufficient to provide the same CTP values present in the right MCA territory; CBV and CBF are decreased with an increase in TTP in the left distal MCA territory. There is evidence of collateral flow through the

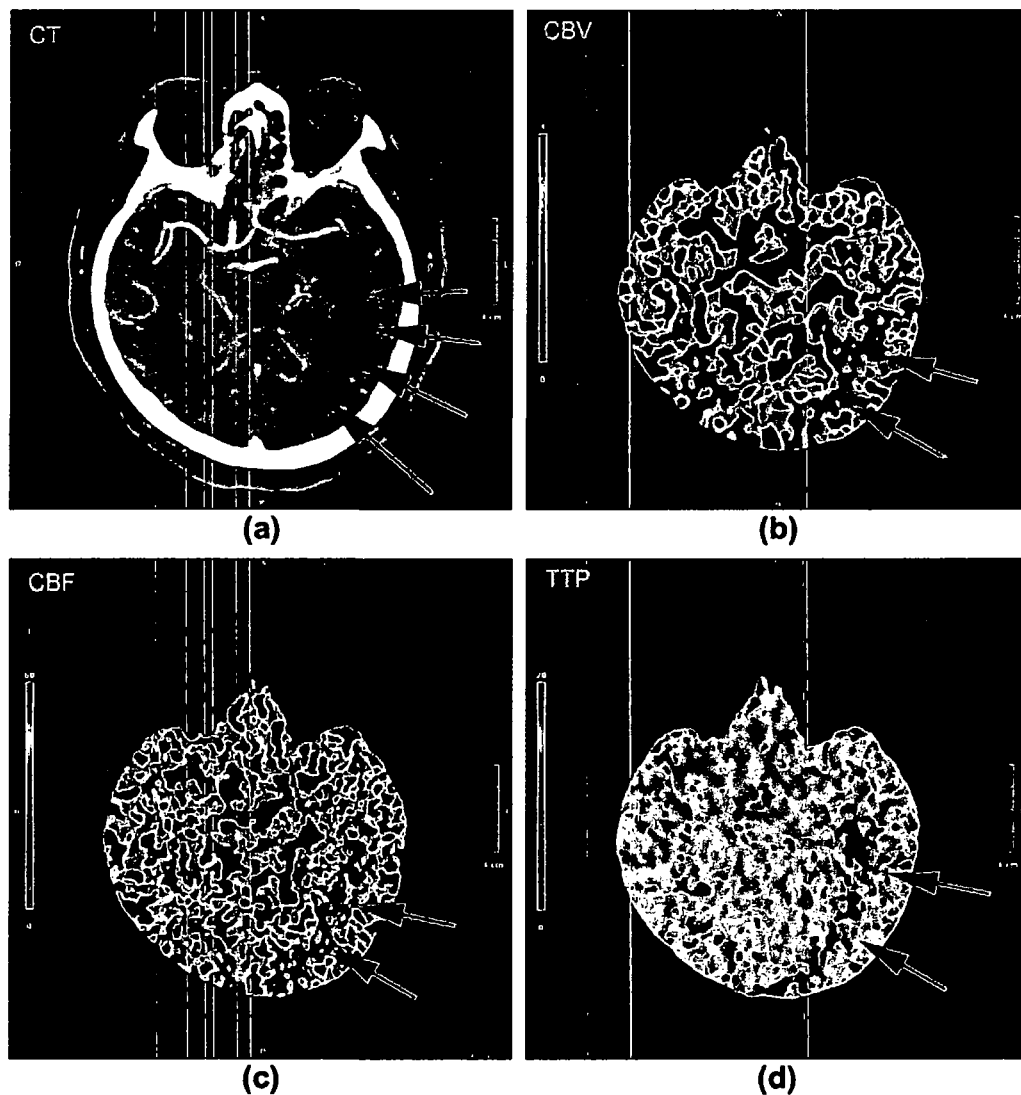
posterior communicating arteries with a decrease in CBV and CBF in the posterior cerebral artery (PCA) distributions bilaterally as well as an associated prolongation of TTP.

#### *Acetazolamide challenge for assessment of reserve capacity*

Acetazolamide is a carbonic anhydrase inhibitor that is a vasodilating drug frequently used with MR imaging, PET, SPECT, Doppler ultrasound, and xenon-CT<sup>24</sup> systems to study CVR in patients with chronic vascular disorders. Changes in CBF values before and after acetazolamide administration have primarily been used to estimate disease severity, stroke risk, and as a presurgical assessment approach. A 20–40% increase in CBF in the tissue of the affected hemisphere relative to the pre-challenge CBF value has been considered as normal and indicative of sufficient CVR.<sup>10</sup> It is increasingly suggested that changes in MTT may be more closely related to the degree of impairment in CVR in at risk territories.<sup>8,25</sup> Using CTP, Smith et al.<sup>25</sup> found that CBF decreased in at-risk brain tissue post-acetazolamide and was not discriminative based on the severity of patients' clinical symptoms. However, increases in MTT were proportional to the severity



**Figure 2** A 58-year-old man with a right MCA AIS on axial section at the level of the basal ganglia. (a) CBF is reduced centrally in the area of probable infarction with a peripheral increase secondary to collateral flow (CBF red arrows). (b) CBV is severely decreased in the MCA acute stroke territory (CBV red arrows). (c) The central reductions in TTP and (d) MTT are secondary to absent flow (not increased flow) also indicative of cerebral infarction (TTP and MTT red arrows).



**Figure 3** A 57-year-old man with chronic left ICA occlusion and hemispheric CTP deficits. (a) Decreased attenuation in the left hemisphere on the contrast-enhanced CT corresponds to the (b) area of decreased CBV, (c) decreased CBF, and (d) prolonged TTP. There are similar patterns of decreased CBV and CBF in the distal bilateral PCA regions. Prolonged TTP is present in the areas of chronic ischaemia.

of symptoms. Pre- and post-acetazolamide challenge CTP maps in a 58-year-old man with complete occlusion of the left ICA are presented in Fig 4. There was a generalized increase in cerebral perfusion present in the post-acetazolamide scan. Post-acetazolamide CBF values increased 17%, CBV increased 13%, and MTT decreased 41% on average for at-risk brain tissue. Given the increase in CBF and decreased MTT this patient had delayed, but sufficient CVR.

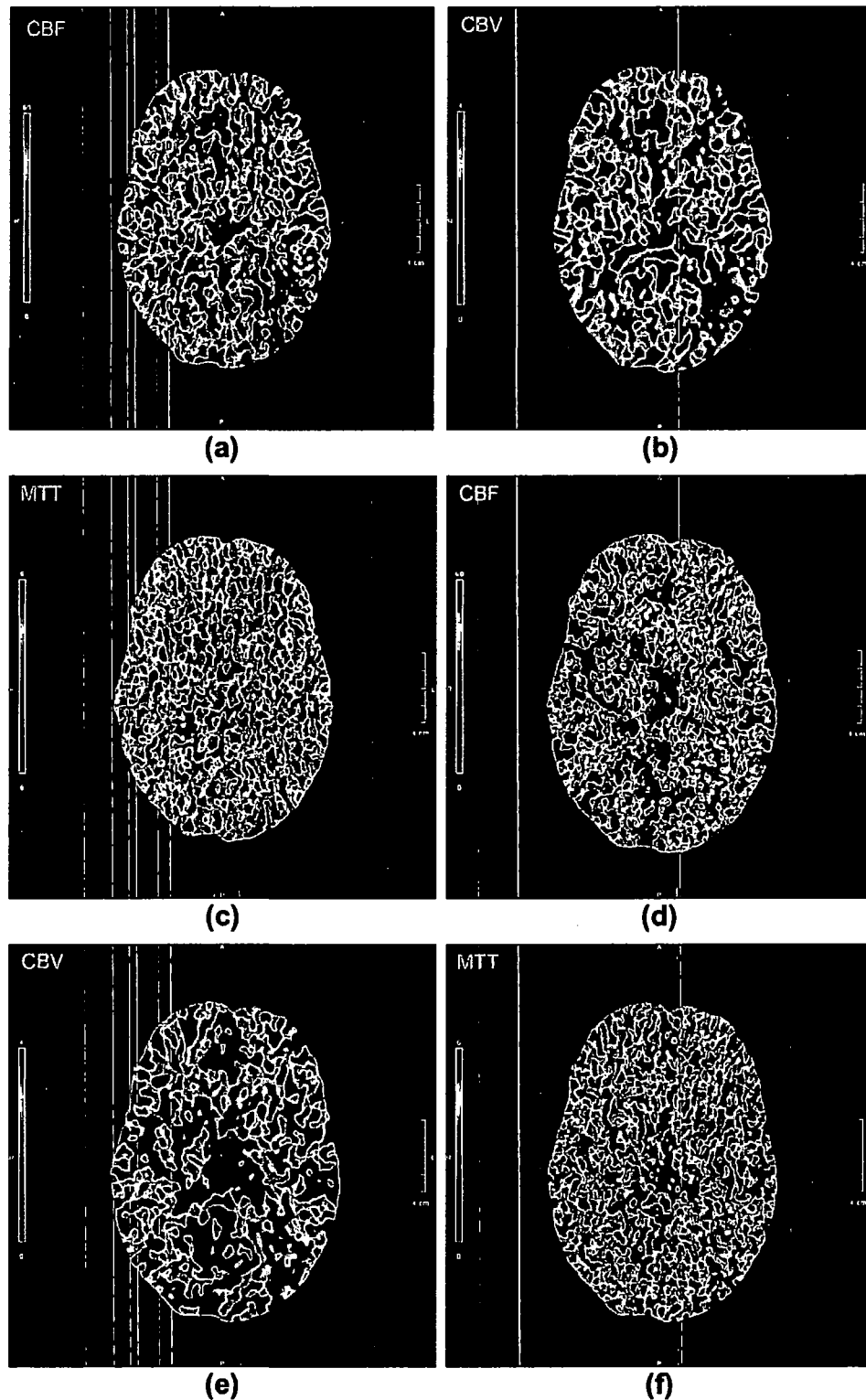
#### *Chronic left MCA occlusion*

Recurrent stroke accounts for 185,000 of the 795,000 strokes that occur annually in the US.<sup>17</sup> Fig 5 illustrates a case of a 78-year-old woman who experienced slow progressive right-sided paresis and unilateral right-sided numbness. 3D CT DSA demonstrated a left MCA occlusion with remarkable superficial collateralization. CBF and CBV

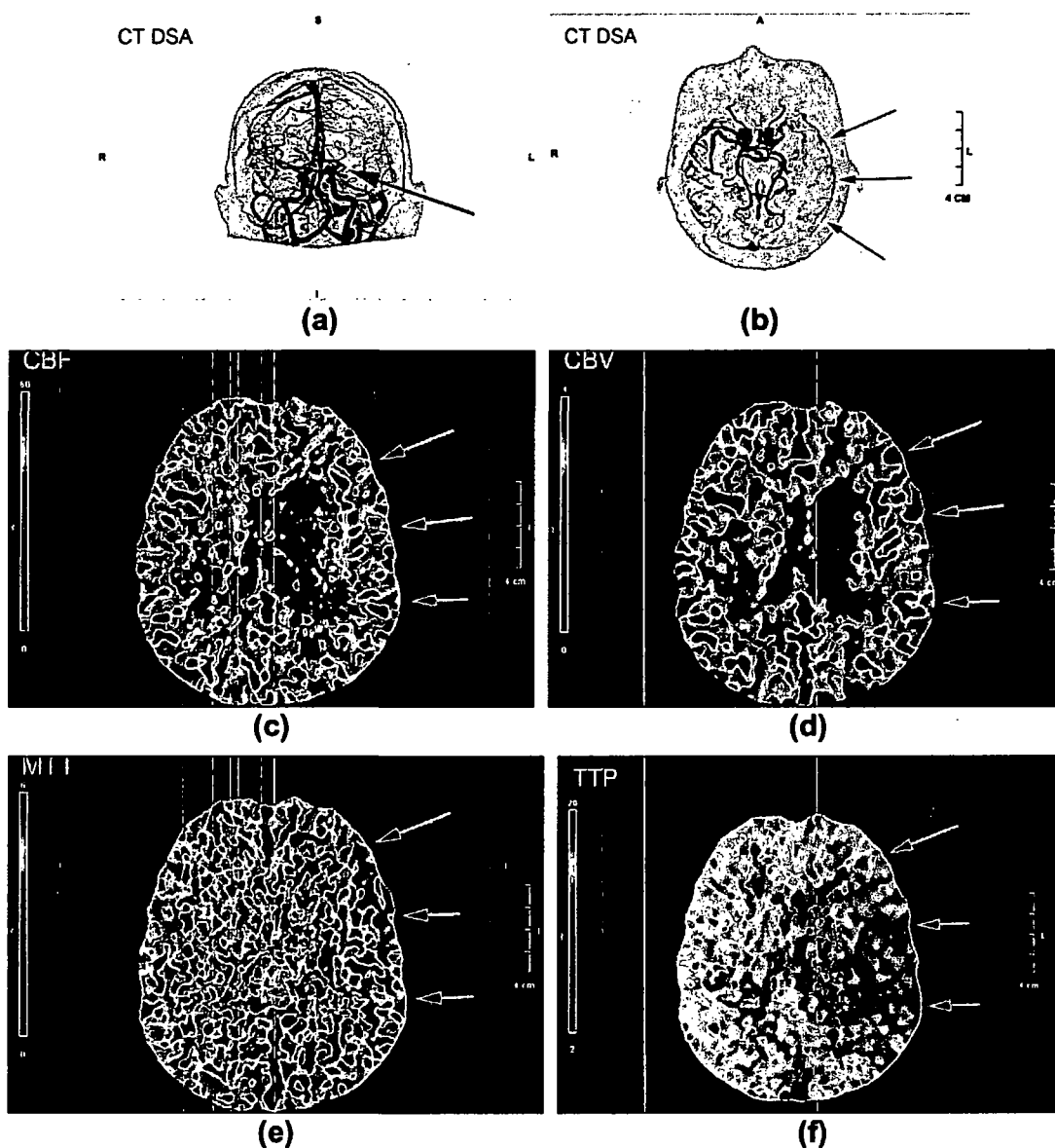
were proportionally decreased centrally with a peripheral increase. Prolongation of TTP and MTT corresponded with the established leptomeningeal collateral pathways in the lateral MCA territory (Fig 5) and reflected increased time required for contrast medium to reach the recovered tissue (Fig 5). This presentation appeared to represent a form of MCA “auto-bypass” with superficial collateralization.

#### *Patient radiation exposure*

The patient radiation doses that have been reported in the literature for CTP vary significantly.<sup>3,4,7,11,26,27</sup> Effective doses in the present study were 4.3 mSv for 19 intermittent volume datasets (80 kVp, 300 mA mask and then 100 mA), 4.4 mSv for an earlier protocol that collected 21 intermittent volume datasets (80 kVp, 300 mA mask and then 100 mA), and 5.9 mSv for 19 intermittent volume datasets with arterial



**Figure 4** Acetazolamide challenge in a 58-year-old man with complete occlusion of the left ICA and decrease in CBF/CBV in the distal MCA distribution. Pre- (a) CBF, (b) CBV, (c) MTT and post-acetazolamide challenge (d) CBF, (e) CBV, (f) MTT axial CTP maps demonstrate sufficient CVR. There is a generalized increase in CBF post-acetazolamide. Improvement in post-acetazolamide CBF and CBV is predominately in the peripheral areas of tissues at-risk. MTT is also decreased in the tissue at-risk posttreatment. Average region of interest values in the tissue a-risk increased CBF by 17%, increased CBV by 13%, and decreased MTT by 41% indicating a delayed, but sufficient vascular reserve.



**Figure 5** A 78-year-old woman with (a) chronic left MCA occlusion (red arrow). (b) There is a dramatic increase in superficial collateral blood flow established during the prolonged MCA ischaemia (red arrows). Note the decreased central and increased peripheral (c) CBF and (d) CBV. Peripherally, a prolonged (e) MTT and dramatic prolongation in (f) TTP demonstrates extensive but delayed collateral superficial blood flow.

enhancement (80 kVp, 310 mA mask, 150 mA series for four acquisitions, increase to 300 mA for five acquisitions increase during the peak arterial phase, and then returned to 150 mA for the remaining five venous phase volume acquisition datasets). These doses compare favourably to prior CTP examinations reported in the literature with doses of approximately 4.6 mSv;<sup>7</sup> 5 mSv;<sup>28</sup> 5.1 mSv;<sup>5</sup> 5.1–5.6 mSv;<sup>29</sup> 6.7 mSv;<sup>30</sup> 6.7–7.5 mSv;<sup>3</sup> and 11.2 mSv<sup>27</sup> for similar types of whole-brain CTP examinations. Two studies that combined a 64-section helical craniocervical or neck CTA study and an incremental unenhanced CT study with the whole-brain 4D CTA-CTP sequences reported combined effective doses of 10.6 mSv.<sup>31</sup> Doses for 64-section head CTP have been reported as 7.5–11.4 mSv<sup>26</sup> and 9.6 mSv<sup>4</sup> for a combined NCCT, CTA-CTP by 64-section evaluation. These effective doses for

CTP studies are generally lower than conventional angiography (10.6 mSv) and below acceptable limits required by the Food and Drug Administration, USA.<sup>11</sup> However, these variations in effective doses indicate the amount of radiation reduction that can be achieved through adjustments in protocol settings. In the cases presented here, diagnostic studies were achieved with doses as low as 4.3 mSv by lowering the tube voltage and tube current settings.

### Protocol settings and indications for acute and chronic neurovascular conditions

Settings of 80 kVp with a single 300 mA mask followed by 100 mA intermittent volume sets for a 19-volume acquisition



results in good-quality images for clinical interpretation and a significant reduction in radiation dose compared to prior reports.<sup>7</sup> Use of 80 kVp has been clinically assessed to provide adequate contrast enhancement and significant reductions in radiation dose compared to higher tube voltages.<sup>32</sup> This protocol can be used for clinical conditions that do not require increased vascular spatial resolution (e.g., epilepsy;<sup>33,34</sup> gliomas or meningiomas;<sup>35</sup> headache or cephalgia of unknown aetiology, cognitive impairment or dementia of unclear aetiology;<sup>36</sup> neurosurgical follow-ups; and acute, subacute or chronic follow up of traumatic brain injury and contusions;<sup>37</sup> arterial steno-occlusive disorders;<sup>3</sup> atherosclerotic disease or cerebrovascular disease;<sup>38</sup> cerebral vascular autoregulation assessments such as Diamox or acetazolamide challenges;<sup>17,25,39</sup> hypoperfusion from asymptomatic extracranial stenoses;<sup>29</sup> ICA stenotic disease and ICA endarterectomy follow-up).<sup>3,21</sup> Changes in protocol settings, such as a tube current boost during the peak arterial phase (80 kVp, 300 mA mask, increase to 300 mA during the peak arterial phase, and then return to 100 mA for the remaining volume datasets) increases the spatial resolution of the cerebral vasculature with a potential modest increase in radiation dose (provided the increased radiation is not excessive).<sup>11</sup> Indications for use of the peak arterial enhancement tube current boost protocol include: AIS,<sup>3</sup> subarachnoid haemorrhage with vasospasm,<sup>40</sup> aneurysm clipping postoperative assessment;<sup>4</sup> complex steno-occlusive disorders (e.g., extracranial to intracranial arterial bypass;<sup>29</sup> moyamoya;<sup>3,39</sup> vasculitis<sup>7</sup>); shunting vascular disorders (e.g., AVM and pial and dural arteriovenous fistulas;<sup>29</sup> pre- and post-treatment assessment of AVM lesions;<sup>29</sup> capillary telangiectasias; and cavernous malformations). Additional indications for improved vascular definition may be required based on the individual's clinical presentation. It is also possible that reductions in radiation dose by limiting the field of view or further decreasing the tube voltage and tube current will be appropriate in paediatric applications or conditions requiring repeated follow-up studies. Careful consideration of dose is required and good imaging results have been achieved for vascular conditions, such as large vessel vasculitis,<sup>7</sup> by using the lower dose 4D CTA-CTP protocol without the tube current boost during peak arterial enhancement.

Contrast medium infusion of 50 ml<sup>1</sup> at 4 ml/s followed by 50 ml normal saline was adequate for the CTP images presented here. Contrast infusion at 4 ml/s has been shown to be adequate for CTA and CTP deconvolution algorithms in a previous study.<sup>32</sup> These reduced contrast medium rate and volume requirements also reduce risk for the patient.

## Conclusion

The availability of whole-brain, real-time, dynamic CTA with perfusion enables accurate and rapid assessment of neurovascular disease. A major advantage of performing CTP using 320-row CT is the simultaneous imaging of the whole brain and entire intracranial circulation (4D-CTA-CTP). 4D CTA-CTP provides additional diagnostic information that

would not be possible using partial-brain CTP limited by axial acquisition at the level of the basal ganglia (in order to include the ACA, MCA, and PCA) followed by sequential slab acquisitions.<sup>10,41</sup> The cases presented here demonstrate that whole-brain unenhanced CT, 4D CTA-CTP, and acetazolamide challenge can be accomplished in less time, with less contrast medium, and lower radiation exposures and less clinical risk compared with earlier-generation CT and conventional cerebral angiography.

## Acknowledgements

A portion of the article developmental costs were provided through an unrestricted medical grant by Toshiba America Medical Systems to E.H.H. E.H.H. has received unrestricted medical grants for education and research from Toshiba America Medical Systems and Philips Healthcare. W.O. is currently a member of the speaker's bureau for Toshiba America Medical Systems, Inc., and has been a consultant for Worldwide Innovations & Technologies, Inc., on unrelated radiation shielding devices.

## References

1. Wintermark M, Smith WS, Ko NU, et al. Dynamic perfusion CT: optimizing the temporal resolution and contrast volume for calculation of perfusion CT parameters in stroke patients. *AJNR Am J Neuroradiol* 2004; **25**:720–9.
2. Rael JR, Orrison Jr WW, Baldwin N, et al. Direct thrombolysis of superior sagittal sinus thrombosis with coexisting intracranial hemorrhage. *AJNR Am J Neuroradiol* 1997; **18**:1238–42.
3. Siebert E, Bohner G, Masuhr F, et al. Neuroimaging by 320-row CT: is there a diagnostic benefit or is it just another scanner? A retrospective evaluation of 60 consecutive acute neurological patients. *Neurol Sci* 2010; DOI 10.1007/s10072-010-0292-7.
4. Page M, Nandurkar D, Crossett MP, et al. Comparison of 4 cm z-axis and 16 cm z-axis multidetector CT perfusion. *Eur Radiol* 2010; **20**:1508–14.
5. Brouwer PA, Bosman T, van Walderveen MA, et al. Dynamic 320-section CT angiography in cranial arteriovenous shunting lesions. *AJNR Am J Neuroradiol* 2010; **31**:767–70.
6. Hanson EH, Roach CJ, Ringdahl EN, et al. Developmental venous anomalies: appearance on whole-brain CT digital subtraction angiography and CT perfusion. *Neuroradiology* 2010; DOI 10.1007/s00234-010-0739-9.
7. Yahyavi-Firouz-Abadi N, Wynn BL, Rybicki FJ, et al. Steroid-responsive large vessel vasculitis: application of whole-brain 320-detector row dynamic volume CT angiography and perfusion. *AJNR Am J Neuroradiol* 2009; **30**:1409–11.
8. Chen A, Shyr MH, Chen TY, et al. Dynamic CT perfusion imaging with acetazolamide challenge for evaluation of patients with unilateral cerebrovascular steno-occlusive disease. *AJNR Am J Neuroradiol* 2006; **27**:1876–81.
9. Eastwood JD, Alexander MJ, Petrella JR, et al. Dynamic CT perfusion imaging with acetazolamide challenge for the preprocedural evaluation of a patient with symptomatic middle cerebral artery occlusive disease. *AJNR Am J Neuroradiol* 2002; **23**:285–7.
10. Cianfoni A, Colosimo C, Basile M, et al. Brain perfusion CT: principles, technique and clinical applications. *Radiol Med* 2007; **112**:1225–43.
11. *Safety investigation of CT brain perfusion scans: initial notification*. US Food and Drug Administration (FDA) Center for Devices and Radiologic Health, <http://www.fda.gov/MedicalDevices/Safety/AlertsandNotices/ucm185898.htm>; 2009 [accessed 21 10 2009].
12. Konstas AA, Goldmakher GV, Lee TY, et al. Theoretic basis and technical implementations of CT perfusion in acute ischemic stroke, part 1: theoretic basis. *AJNR Am J Neuroradiol* 2009; **30**:662–8.
13. Ostergaard L. Principles of cerebral perfusion imaging by bolus tracking. *J Magn Reson Imaging* 2005; **22**:710–7.

14. European guidelines for multislice computed tomography. *European commission*, [http://w3.tue.nl/fileadmin/sbd/Documenten/Leergang/BSM/European\\_Guidelines\\_Quality\\_Criteria\\_Computed\\_Tomography\\_Eur\\_16252.pdf](http://w3.tue.nl/fileadmin/sbd/Documenten/Leergang/BSM/European_Guidelines_Quality_Criteria_Computed_Tomography_Eur_16252.pdf); 2004 [accessed 09 04 2010].
15. Donnan GA, Fisher M, Macleod M, et al. Stroke. *Lancet* 2008;**371**:1612–23.
16. Lloyd-Jones D, Adams R, Carnethon M, et al. Heart disease and stroke statistics—2009 update: a report from the American Heart Association Statistics Committee and Stroke Statistics Subcommittee. *Circulation* 2009;**119**:e21–181.
17. Wintermark M, Chioloro R, Van Melle G, et al. Cerebral vascular autoregulation assessed by perfusion-CT in severe head trauma patients. *J Neuroradiol* 2006;**33**:27–37.
18. Gold L, Lauritzen M. Neuronal deactivation explains decreased cerebellar blood flow in response to focal cerebral ischemia or suppressed neocortical function. *Proc Natl Acad Sci USA* 2002;**99**:7699–704.
19. Takasawa M, Watanabe M, Yamamoto S, et al. Prognostic value of subacute crossed cerebellar diaschisis: single-photon emission CT study in patients with middle cerebral artery territory infarct. *AJNR Am J Neuroradiol* 2002;**23**:189–93.
20. Lin DD, Kleinman JT, Wityk RJ, et al. Crossed cerebellar diaschisis in acute stroke detected by dynamic susceptibility contrast MR perfusion imaging. *AJNR Am J Neuroradiol* 2009;**30**:710–5.
21. Vehmas T, Markkola AT. Gd-DTPA as an alternative contrast agent in conventional and interventional radiology. *Acta Radiol* 1998;**39**:223–6.
22. Schellinger PD, Fiebich JB, Mohr A, et al. Thrombolytic therapy for ischemic stroke—a review. Part I—intravenous thrombolysis. *Crit Care Med* 2001;**29**(9):1812–8.
23. Schaefer PW, Barak ER, Kamalian S, et al. Quantitative assessment of core/penumbra mismatch in acute stroke: CT and MR perfusion imaging are strongly correlated when sufficient brain volume is imaged. *Stroke* 2008;**39**:2986–92.
24. Webster MW, Makaroun MS, Steed DL, et al. Compromised cerebral blood flow reactivity is a predictor of stroke in patients with symptomatic carotid artery occlusive disease. *J Vasc Surg* 1995;**21**:338–44. discussion 344–45.
25. Smith LM, Elkins JS, Dillon WP, et al. Perfusion-CT assessment of the cerebrovascular reserve: a revisit to the acetazolamide challenges. *J Neuroradiol* 2008;**35**:157–64.
26. Cohnen M, Wittsack HJ, Assadi S, et al. Radiation exposure of patients in comprehensive computed tomography of the head in acute stroke. *AJNR Am J Neuroradiol* 2006;**27**:1741–5.
27. San Millan Ruiz D, Murphy K, Gailloud P. 320-multidetector row whole-head dynamic subtracted CT angiography and whole-brain CT perfusion before and after carotid artery stenting: technical note. *Eur J Radiol* 2010;**74**:413–9.
28. Klingebiel R, Siebert E, Diekmann S, et al. 4-D imaging in cerebrovascular disorders by using 320-slice CT: feasibility and preliminary clinical experience. *Acad Radiol* 2009;**16**:123–9.
29. Salomon EJ, Barfett J, Willems PW, et al. Dynamic CT angiography and CT perfusion employing a 320-detector row CT: protocol and current clinical applications. *Clin Neuroradiol* 2009;**19**:187–96.
30. Siebert E, Bohner G, Dewey M, et al. 320-slice CT neuroimaging: initial clinical experience and image quality evaluation. *Br J Radiol* 2009;**82**:561–70. DOI 10.1259/bjr/27721218.
31. Diekmann S, Siebert E, Juran R, et al. Dose exposure of patients undergoing comprehensive stroke imaging by multidetector-row CT: comparison of 320-detector row and 64-detector row CT scanners. *AJNR Am J Neuroradiol*; 2010. DOI 10.3174/ajnr.A1971.
32. Wintermark M, Maeder P, Thiran JP, et al. Quantitative assessment of regional cerebral blood flows by perfusion CT studies at low injection rates: a critical review of the underlying theoretical models. *Eur Radiol* 2001;**11**:1220–30.
33. Royter V, Paletz L, Waters MF. Stroke vs. status epilepticus. A case report utilizing CT perfusion. *J Neurol Sci* 2008;**266**:174–6.
34. Wiest R, von Bredow F, Schindler K, et al. Detection of regional blood perfusion changes in epileptic seizures with dynamic brain perfusion CT—a pilot study. *Epilepsy Res* 2006;**72**:102–10.
35. Ding B, Ling HW, Chen KM, et al. Comparison of cerebral blood volume and permeability in preoperative grading of intracranial glioma using CT perfusion imaging. *Neuroradiology* 2006;**48**:773–81.
36. Zimny A, Leszek J, Kiejna A, et al. Analysis of correlation between the degree of cognitive impairment and the results of perfusion CT in patients with dementia. *Med Sci Monit* 2007;**13**(Suppl. 1):23–30.
37. Soustiel JF, Mahamid E, Goldsher D, et al. Perfusion-CT for early assessment of traumatic cerebral contusions. *Neuroradiology* 2008;**50**:189–96.
38. Murayama K, Katada K, Nakane M, et al. Whole-brain perfusion CT performed with a prototype 256-detector row CT system: initial experience. *Radiology* 2009;**250**:202–11.
39. Kang KH, Kim HS, Kim SY. Quantitative cerebrovascular reserve measured by acetazolamide-challenged dynamic CT perfusion in ischemic adult Moyamoya disease: initial experience with angiographic correlation. *AJNR Am J Neuroradiol* 2008;**29**:1487–93.
40. Pham M, Johnson A, Bartsch AJ, et al. CT perfusion predicts secondary cerebral infarction after aneurysmal subarachnoid hemorrhage. *Neurology* 2007;**69**:762–5.
41. Wintermark M. Brain perfusion-CT in acute stroke patients. *European Radiology* 2005;**15**(Suppl. 4). D28-31.

U.S. Food & Drug Administration  
Center for Devices and Radiological Health  
10155  
10155  
10155

**Paper-13:**

**Rai A T, Raghuram K, Domico Jet al.: Pre-intervention triage incorporating perfusion imaging improves outcomes in patients undergoing endovascular stroke therapy: a comparison with the device trials. *J NeuroIntervent Surg* (2012).**

ORIGINAL RESEARCH

# Pre-intervention triage incorporating perfusion imaging improves outcomes in patients undergoing endovascular stroke therapy: a comparison with the device trials

Ansaar T Rai, Karthikram Raghuram, Jennifer Domico, Gerald Hobbs, Jeffrey Carpenter

Interventional Neuroradiology,  
West Virginia University  
Hospital, Morgantown, West  
Virginia, USA

**Correspondence to**

Ansaar T Rai, Department of  
Radiology/Neuroradiology, West  
Virginia University Hospital,  
2002 Ices Ferry Drive,  
Morgantown, WV 26508, USA;  
ansaar.ra@gmail.com

Received 9 November 2011  
Revised 16 January 2012  
Accepted 18 January 2012

**ABSTRACT**

**Objectives** Endovascular therapy of acute ischemic stroke is evolving towards thrombectomy devices for vessel recanalization. High rates of revascularization have been reported in stroke device trials. However, the discrepancy between recanalization and outcomes raises the question whether patients with irreversible ischemic injury are being exposed to these interventions. This study evaluated a triage methodology that incorporates perfusion imaging against previous device trials that treated all patients within a certain time frame.

**Methods** 99 consecutive patients were identified with anterior circulation strokes who had undergone endovascular therapy. All patients had a baseline NIHSS score  $\geq 8$  and had undergone pre-intervention CT perfusion. Rates of recanalization and functional outcomes were compared with the MERCI, Multi-MERCI and Penumbra trials.

**Results** This study's recanalization rate of 55.6% is not significantly different from the 46% for MERCI ( $p=0.15$ ) and 68% for Multi-MERCI ( $p=0.08$ ) but was significantly lower than the 82% for the Penumbra trial ( $p<0.0001$ ). Successfully recanalized patients had a significantly higher good outcome of 67% in this cohort versus 46% in MERCI, 49% in Multi-MERCI and 29% in Penumbra. The rate of futile recanalization was 33% compared with 54% for MERCI, 51% for Multi-MERCI and 71% for Penumbra. A small cerebral blood volume (CBV) abnormality ( $p<0.0001$ ) and large mean transit time—CBV mismatch ( $p<0.0001$ ) were strong predictors of a good outcome.

**Conclusion** Despite similar or lower recanalization rates, there was a significantly higher rate of good outcomes in the recanalized population and thus a significantly lower rate of futile recanalization in this study versus the device trials, suggesting a role for pre-intervention perfusion imaging for patient selection.

The current trend in endovascular stroke therapy towards newer thrombectomy devices is predicated on the US Food and Drug Administration approval of previous clot retrievers. The primary endpoint for success in these and ongoing device trials is vessel recanalization, a predictor of good outcome.<sup>1–3</sup> However, high rates of recanalization have not been matched by proportionally high rates of good functional outcome.

In order to test the hypothesis that a patient selection methodology including the assessment of

preprocedure cerebral perfusion leads to better outcomes, especially in recanalized patients, we compared data from our center that relied on pre-intervention perfusion imaging with the mechanical thrombectomy device trials that treated all comers.

**METHODS**

This is a retrospective review of patients with acute ischemic stroke in the anterior circulation that underwent endovascular therapy. The study was performed after approval by the institutional review board. The data from our center were compared with the device trials for acute ischemic stroke as discussed below.

**Patient selection**

At our institution patient selection for endovascular therapy of stroke incorporates preprocedure perfusion imaging analysis, with the benefit of any doubt always given to the patient. Patients are primarily excluded from an intervention if the non-contrast head CT (NCCT) shows signs of early ischemia affecting at least one third of the occluded vascular territory. Secondary exclusion can be based on the perfusion imaging showing a large cerebral blood volume (CBV) abnormality, for example, 50–75% of the affected vascular territory. The rationale is that an irreversible ischemic injury could be identified using CBV before it becomes abnormal on NCCT. Endovascular therapy in patients with minimal or no NCCT abnormality but with large CBV abnormality may not only be futile but expose the patient to unnecessary risks of the procedure. As mentioned initially, in cases of any doubt we favor treating the patient over no treatment. For example, patients presenting within 3 h but ineligible for intravenous thrombolytics are generally treated unless there is a large NCCT abnormality.

We do not have a cut-off time limit for no treatment. Patients presenting beyond 8 h or with wake-up strokes were treated if they had favorable imaging profiles.

In this stroke treatment triage setting, we applied the following inclusion criteria to all consecutive patients who underwent endovascular stroke therapy over an 8-year period:

**Ischemic stroke**

1. Anterior circulation symptoms at presentation with a baseline National Institutes of Health stroke scale (NIHSS) score of 8 or greater.
2. Intracerebral vascular occlusion on admission CT angiography correlating with the neurological deficit.

The endovascular procedures were performed through a transfemoral approach in all patients. General endotracheal anesthesia was used in 62 (62.6%) patients while conscious sedation was used in 37 (37.4%) patients. The type of endovascular therapy involved intra-arterial thrombolytics in only 33 (33.3%) patients, mechanical device in only 24 (24.2%) patients and both thrombolytics and mechanical thrombectomy in 42 (42.4%) patients. All patients went to the medical intensive care unit after the procedure.

**Image analysis**

In order to ensure consistency of the imaging analysis the source dicom data utilized for the original perfusion study was processed utilizing Vitrea-4 perfusion software by vital images. The software uses a deconvolution method based on singular value decomposition. The image acquisition time is 60 s to ensure inclusion of the complete tissue time-density curve. A neuroradiologist blinded to the procedure or the clinical outcome identified two levels predicting the largest perfusion abnormality on cerebral blood flow, CBV and meant transit time (MTT). Our CT perfusion coverage for the anterior circulation is 40 mm. We believe this is sufficient to cover the internal carotid artery (ICA) or the middle cerebral artery (MCA) territories, which were the vessels that were analyzed. It is possible to miss smaller lesions that are outside the coverage but these will typically involve third order branches, have a low baseline NIHSS and overall carry a favorable prognosis. While it is possible to have part of the lesion outside the field of coverage, we believe for proximal vessel occlusions, such as in this study, enough relevant 'clinical' information can be obtained on which to base a treatment decision. A region of interest (ROI) was manually drawn around the perceived perfusion abnormality yielding an area in square millimeters for each level and an average of the two levels showing the largest abnormality was obtained. A mirror image ROI was automatically generated in the contralateral unaffected hemisphere. In addition, the relative perfusion value in the abnormal ROI was measured as a percentage of the normal ROI. The MTT-CBV mismatch was defined as  $(1 - CBV/MTT) \times 100$ .

Successful recanalization was defined as a post-intervention thrombolysis in myocardial ischemia score of 2 or 3. An independent observer blinded to the outcomes graded the post-procedure recanalization status. A good outcome was defined as a 90-day modified Rankin score of 2 or less.

**Comparison**

We compared our procedural and clinical outcomes with the MERCI (Mechanical Embolus Removal in Cerebral Ischemia), Multi-MERCI and the Penumbra Pivotal trials.<sup>2-4</sup> We only compared the anterior circulation strokes. This was done because we did not have reliable perfusion imaging data on the posterior circulation, a smaller number of posterior circulation strokes were treated in the device trials as well as our own cohort and basilar artery occlusions carry a very high mortality despite intervention.

**Statistical analysis**

The significance of simple bivariate associations was assessed using  $\chi^2$  tests or logistic regression as appropriate. Multiple logistic regression was used when several factors were assessed simultaneously. We used the t-test to compare our sample means against the device trials. All data analysis was performed using JMP statistical software.

**RESULTS**

A total of 99 patients satisfied the inclusion criteria. A good outcome was seen in 41 patients (41.4%) while successful recanalization was achieved in 55 patients (55.6%). Twenty-five per cent of ICA, 41% of M1 and 69% of M2 occlusion patients had a good outcome ( $p=0.02$ ). The mortality was 62% in patients with an ICA occlusion, 29% in patients with an M1 occlusion and 12% in those with an M2 occlusion ( $p=0.001$ ). The baseline characteristics of the patients in comparison with the device trial are listed in table 1. The significant clinical and imaging predictors of outcome and mortality are shown in table 2. Younger age and lower NIHSS score significantly correlated with a good outcome while older age and a higher baseline NIHSS score predicted mortality. Patients with successful recanalization had significantly higher odds of a good outcome and lower mortality than those with no recanalization. Among the 41 patients with a good outcome, successful recanalization was achieved in 37 patients or 90.2%. In contrast, in the 58 patients with a poor outcome, successful recanalization was seen in only 18 patients or 31% ( $p<0.0001$ ). Likewise, in the 55 successfully recanalized patients, a good outcome was seen in 37 patients or 67.3%, whereas only four (9.1%) of the 44 non-recanalized patients achieved a good outcome ( $p<0.0001$ ).

Analysis of the perfusion parameters showed that a small area of CBV abnormality and large MTT-CBV mismatch were significant predictors of a good outcome and lower mortality (table 2). We defined futile or ineffective recanalization as patients ending with a poor outcome despite successful recanalization. Among the patients who were successfully recanalized ( $n=55$ ), 18 (33%) had a poor outcome or futile recanalization.

**Table 1** Baseline characteristics compared with the device trials

	Current N=99	Versus MERCI N (total) 141 N (anterior circulation) 127	p Value	Versus Multi-MERCI N (total) 164 N (anterior circulation) 150	p Value	Versus Penumbra N (total) 125 N (anterior circulation) 110	p Value
Age, years	69±17	67±15.5	0.35	68.1±16	0.67	63.5±13.5	0.008
Women %	51	46	0.4	57	0.4	49	0.7
ICA %	24.2	37	0.04	34.7	0.08	20.9	0.6
MCA %	75.8	63	0.04	65.3	0.08	79.1	0.6
NIHSS overall	17±7	20.1±6.6	0.0005	19.1±6.2	0.013	17.6±5.2	0.47
NIHSS ICA	21±7.5	19±4	0.01	20.4±5.9	0.5	NA	—
NIHSS MCA	17±6	20±6	0.0002	18.2±5.5	0.11	NA	—
Time to procedure	6±3.2	4.3±1.7	<0.0001	4.4±1.8	<0.0001	4.3±1.5	<0.0001

ICA, internal carotid artery; MCA, middle cerebral artery; NIHSS, National Institutes of Health stroke scale.

**Table 2 Predictors of outcome and mortality**

	Outcome		p Value
	Good, (n=41)	Poor, (n=58)	
Age, years, mean±SD (95% CI)	62±19 (56 to 68)	74±13 (70 to 77)	0.0004
NIHSS, mean±SD (95% CI)	15±6 (13 to 16)	19±7 (17 to 21)	0.003
Successful recanalization, %, (95% CI)	90.2	9.1	<0.0001, OR 0.05 (0.01 to 0.16)
MTT-CBV mismatch, %, mean±SD (95% CI)	91±11 (88 to 94)	71±32 (63 to 80)	0.0003
CBV, mm <sup>2</sup> , mean±SD (95% CI)	249±298 (154 to 343)	1001±1179 (691 to 1311)	0.0001

	Mortality		p Value
	No (n=65)	Yes (n=34)	
Age, years, mean±SD (95% CI)	65±19 (61 to 70)	75±11 (71 to 79)	0.008
NIHSS, mean±SD (95% CI)	15±6 (14 to 17)	20±7 (18 to 22)	0.001
Recanalization % (95% CI)	80	20	<0.0001, OR 0.05 (0.01 to 0.16)
MTT-CBV mismatch, %, mean±SD (95% CI)	90±13 (87 to 93)	60±35 (48 to 72)	<0.0001
CBV, mm <sup>2</sup> , mean±SD (95% CI)	296±408 (194 to 397)	1443±1307 (224 to 987)	<0.0001

CBV, cerebral blood volume; MTT, mean transit time; NIHSS, National Institutes of Health stroke scale.

**Comparison with the device trials**

**The MERCI trial**

The MERCI trial was a prospective, single-arm, multicenter trial to test whether the device could safely achieve recanalization at a rate greater than a prespecified rate of spontaneous recanalization. The rate of spontaneous recanalization used was that reported in PROACT-II.<sup>5</sup> Of the 151 patients enrolled, angiography results were available in 141 patients, and of these 90-day follow-up was available in 138 patients. Of these, 47 patients had an ICA (37%) and 80 patients (63%) had an MCA occlusion, these 127 anterior circulation strokes formed the cohort for comparison. The mean age and gender distribution was similar to our study (table 1). A comparison of recanalization rates, good outcomes and mortality is shown in table 3A. Our recanalization rate was not significantly different from the MERCI trial, and while the percentage of good outcomes in our series was higher, the most notable difference was the significantly increased odds of achieving a good outcome in recanalized patients in our series as opposed to the MERCI trial. To account for the lower baseline NIHSS score in our study compared with the MERCI trial (table 1) we used the trial's mean baseline NIHSS score of 20, which predicts a good outcome of 57% for recanalized patients. This is still significantly higher than the 46% good outcome in recanalized patients in the MERCI trial (p=0.008). Our time to treatment from symptom onset was significantly higher than the MERCI trial (table 1), which could potentially have an adverse effect on the outcomes (table 3).

The mortality in recanalized patients was lower in the current study compared with the MERCI trial; however, there was no difference in outcomes or mortality in the non-recanalized patients and no difference in overall outcomes or mortality based on site of occlusion.

The rate of futile anterior circulation recanalization in the MERCI trial was 54%, which is significantly higher than the 33% rate in the current series (OR 2.3, 95% CI 1.3 to 4.2; p=0.002).

**The Multi-MERCI trial**

The Multi-MERCI trial was similar in design to the MERCI trial, but tested a newer version of the thrombectomy device. The mean age and gender distribution and composition of the

occlusion site was similar to our study (table 1). While the overall baseline NIHSS score was slightly lower in our study, the baseline NIHSS score for patients with ICA and MCA occlusions was not significantly different (table 1). As shown in table 3B, the overall recanalization rate was higher in the Multi-MERCI trial. The overall percentage of good outcomes and mortality was not different; however, the percentage of good outcomes in recanalized patients was significantly higher in our series. Using the mean baseline NIHSS score of 19 (similar to the Multi-MERCI trial) predicts a good outcome of 60% in our recanalized cohort compared with the 49% good outcome in recanalized patients in the Multi-MERCI trial (p=0.007). Again, our time to procedure from symptom onset was significantly higher and should theoretically offset at least partly the effect of a lower NIHSS score. The percentage of futile recanalizations in the Multi-MERCI trial of 51% was significantly higher than the 33% in the present series (OR 2.1, 95% CI 1.2 to 3.7; p=0.009).

**The Penumbra Pivotal trial**

The Penumbra Pivotal study enrolled a total of 125 patients in a prospective, single-arm, multicenter trial. The baseline sample characteristics compared with our study do not show a difference between the mean age, baseline NIHSS score or distribution of the occlusion site. The mean time to procedure initiation was 4.3 h (±1.5) was, however, significantly lower than the present study. As shown in table 3C, the rate of recanalization in the Pivotal trial was significantly higher than the current series; in fact it was the highest reported recanalization rate of any of the device trials. However, the rate of good outcomes was not only significantly lower than the current series but was also lower when compared with the MERCI trials. In addition, the patients who were recanalized did not have significantly better outcomes than the overall cohort. Most importantly, however, the percentage of patients with successful recanalization who achieved a good outcome was significantly lower when compared with the current series. By contrast, the rate of ineffective recanalization of 71% was the highest of any of the device trials and was significantly higher than the 33% observed in our series (OR 4.97, 95% CI 2.7 to 9.1; p<0.0001). The overall mortality and the mortality in the recanalized and the non-recanalized groups was not different when compared with the current series. The Penumbra trial also allowed comparison of

**Ischemic stroke**

**Table 3** A comparison with the device trials

	Current	MERCI	p Value, OR (95% CI)
<b>A. Current versus MERCI</b>			
Recanalization	55.6	46	0.15, 0.66 (0.28 to 1.1)
ICA recanalization	33	53	0.004, 2.2 (1.3 to 4.1)
MCA recanalization	63	45	0.01, 0.5 (0.27 to 0.84)
Good outcome	41	27.7	0.05, 0.55 (0.3 to 1)
Good outcome in RC patients	67	46	0.002, 0.4 (0.23 to 0.74)
Good outcome in NR patients	9	10.4	0.8, 1.1 (0.4 to 2.9)
ICA good outcome	25	24	0.86
MCA good outcome	41	29	0.07
Mortality	34	44	0.1, 1.5 (0.86 to 2.7)
Mortality in RC patients	20	32	0.05, 1.9 (0.99 to 3.6)
Mortality in NR patients	52	54	0.77
ICA mortality	62	51	0.1
MCA mortality	29	39	0.1
	Current	Multi-MERCI	p Value, OR (95% CI)
<b>B. Current versus Multi-MERCI</b>			
Recanalization	55.6	68	0.08, 1.7 (0.93 to 2.97)
ICA recanalization	33	65	<0.0001, 3.8 (2.1 to 6.8)
M1 recanalization	61	61	1, 1 (0.57 to 1.77)
M2 recanalization	69	91	<0.0001, 4.5 (2.03 to 10.1)
Good outcome	41	36	0.4, 0.8 (0.46 to 1.43)
Good outcome in RC patients	67	49	0.009, 0.47 (0.27 to 0.83)
Good outcome in NR patients	9	10	0.8, 1.12 (0.44 to 2.9)
ICA good outcome	25	33	0.2, 1.5 (0.8 to 2.7)
M1 good outcome	41	36	0.4, 0.8 (0.46 to 1.43)
M2 good outcome	69	50	0.006, 0.4 (0.25 to 0.8)
Mortality	34	34	1, 1 (0.56 to 1.8)
Mortality in RC patients	20	25	0.39, 1.33 (0.68 to 2.6)
Mortality in NR patients	52	52	1, 1 (0.57 to 1.74)
ICA mortality	62	45	0.01, 0.5 (0.28 to 0.88)
M1 mortality	29	29	1, 1 (0.54 to 1.84)
M2 mortality	12	15	0.5, 1.3 (0.57 to 2.92)
	Current	Penumbra Pivotal	p Value, OR (95%CI)
<b>C. Current versus Penumbra Pivotal</b>			
Recanalization	55.6	81.6	<0.0001, 3.6 (1.87 to 6.82)
Good outcome	41	25	0.01, 0.47 (0.26 to 0.88)
Good outcome in RC patients	67	29	<0.0001, 0.2 (0.11 to 0.37)
Good outcome in NR patients	9	9	1, 1 (0.37 to 2.63)
Mortality	34	33	0.88, 0.95 (0.53 to 1.72)
Mortality in RC patients	20	29	0.13, 1.63 (0.85 to 3.13)
Mortality in NR patients	52	48	0.57, 0.85 (0.49 to 1.48)

The rates represent percentages.  
 ICA, internal carotid artery; MCA, middle cerebral artery; NR, non-recanalized; RC, recanalized.

the outcome and mortality rates among the recanalized and non-recanalized cohorts by the site of vascular occlusion, as shown in table 4. Again, the percentage of patients achieving a favorable outcome with successful recanalization was significantly higher in the present series than the Penumbra trial for both the ICA and MCA occlusions. The Penumbra trial had a very high rate of futile recanalization for both the ICA and MCA occlusions. For ICA occlusions, the odds of ineffective recanalization in the Penumbra trial were more than eight times higher than the current series, a rate of 74% in the Penumbra trial versus 25% in the current study (OR 8.5, 95% CI 4.5 to 16.1;  $p < 0.0001$ ). Likewise, for an MCA occlusion, the odds of futile recanalization in the Penumbra trial was four times higher, a rate of 68% futile recanalization compared with 33% observed in the current series (OR 4.1, 95% CI 2.28 to 7.43;  $p < 0.0001$ ).

A significantly lower mortality was observed in our series for patients with ICA occlusions than the Penumbra trial; however, no such difference was elicited for patients with MCA occlu-

sions. Similarly, no difference in outcome or mortality was observed in patients who were not recanalized. A graphic representation highlighting the differences in futile recanalization and the rates of good outcomes in recanalized and non-recanalized patients is shown in figure 1.

**DISCUSSION**

The ultimate goal of an endovascular stroke intervention is neurological recovery or improvement. Recanalization of an arterial occlusion is central to achieving this goal; however, higher recanalization rates are not being paralleled by equally higher rates of favorable outcomes in recanalized patients. Patient selection thus remains crucial in achieving not only recanalization in the right patient but also in accomplishing a favorable neurological outcome. The extent of irreversible ischemic injury is related to the site of vascular occlusion<sup>4,6</sup> and the duration of such occlusion. The NIHSS score and the time

**Table 4** Comparison of outcome and mortality with the Penumbra Pivotal trial based on recanalization and site of occlusion

	Overall			Recanalized			Non-recanalized		
	Current	Penumbra	p Value, OR	Current	Penumbra	p Value, OR	Current	Penumbra	p Value, OR
<b>Good outcome</b>									
ICA	25	22	0.6	75	26	<0.0001, 0.11 (0.06 to 0.22)	0	0	NA
MCA	47	27	0.03, 0.5 (0.29 to 0.96)	66	32	<0.0001, 0.24 (0.13 to 0.43)	14	7	0.1
<b>Mortality</b>									
ICA	62	57	0.4	25	53	<0.0001, 3.38 (1.85 to 6.15)	81	75	0.3
MCA	25	29	1	19	25	0.3	36	47	0.1

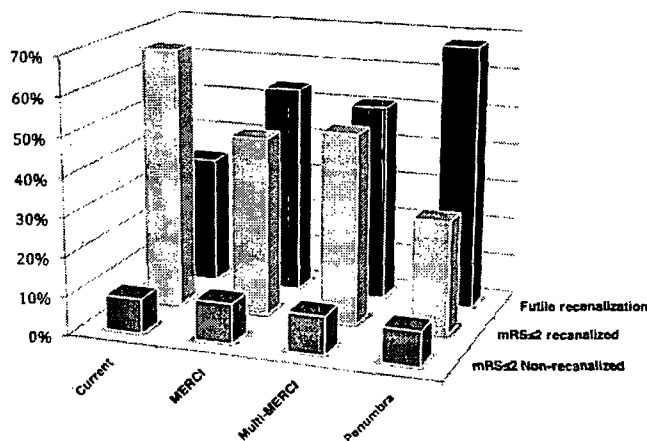
ICA, internal carotid artery; MCA, middle cerebral artery.

from symptom onset serve as surrogate markers for the severity and duration of ischemia, respectively. As endovascular stroke therapy is initiated after expiration of the intravenous time window or for cases refractory to intravenous thrombolytics, it is by default selecting patients with ischemia of longer duration and strokes of worse severity. The mean time to initiation of intra-arterial therapy was almost 6 h in our study and is typically reported to be 4 h or longer in previous endovascular stroke trials,<sup>1 3 5</sup> as opposed to 90 min in the NINDS trial.<sup>7</sup> In terms of severity, patients with proximal vessel occlusion such as the MCA or intracranial ICA are less responsive to intravenous thrombolytics<sup>8</sup> and are increasingly becoming the target population for stroke interventions. The current arbitrary recommendations for endovascular therapy based on a time window of up to 8 h rely on using time as a surrogate for cell death. A problem with this approach of treating all comers within a certain time frame is that endovascular procedures are not benign and carry a fairly significant morbidity and mortality. Subjecting a patient with minimal or no chance of recovery makes the procedure not only futile but also dangerous. By the same token restricting treatment to a time frame may deprive a patient of a procedure that could help regain function. Patients waking up with a stroke are prime examples of the latter and patient selection beyond 8 h based on imaging has shown promising initial results.<sup>9 10</sup>

The preprocedure imaging methodology at our institution evolved towards CT perfusion due to its round-the-clock availability and immediate proximity to the emergency department; a setting that is not unique to our hospital. For stroke imaging and intervention to disseminate beyond large metropolitan centers, such logistic concerns can be important. Furthermore,

the utility of CT in determining viable ischemic tissue versus core infarct correlates well with MRI.<sup>11-13</sup> Our patient selection based on utilizing MTT and CBV has valid precedence in the literature.<sup>14</sup> Similar mismatch can be constructed by using cerebral blood flow and CBV.<sup>15</sup> In addition, a visual evaluation of the perfusion maps has been shown to correlate with final infarct volumes,<sup>16 17</sup> a fact that is important in timely assessment of the perfusion maps, and mitigates the vendor software variability that primarily affects absolute values in quantitative perfusion maps.<sup>18</sup> Visual assessment may overestimate the size of the MTT abnormality in some patients by including non-threatened tissue;<sup>19</sup> however, overestimating the MTT abnormality will favor treatment as it will overestimate the size of the mismatch or penumbra. An overestimation of MTT is a serious issue if it would result in excluding patients who would otherwise be eligible for therapy, but this is not the case with visual assessment, and so we feel in a real-world scenario when time is of the essence a visual subjective analysis yields enough useful information on which to base a treatment decision. The infarct core determination based on cerebral blood lesion volume is strongly supported by the literature,<sup>13 20</sup> and CBV predicting clinical outcomes in patients undergoing both intravenous and intra-arterial stroke therapies is also documented.<sup>13 21-24</sup> We realize that CBV may not exactly match the diffusion-weighted imaging abnormality and that it may even slightly underestimate the infarct compared with diffusion-weighted imaging,<sup>12</sup> however, again, underestimation of the CBV size favors endovascular therapy and will result in the patient being treated. Our strategy for triaging patients even though based on imaging hinges on the philosophy that in case of any doubt the benefit is given to the patient and we err on the side of treatment. Another confounding variable is a true characterization and definition of infarct core on imaging, which may be different from its pathological description. The basis of incorporating perfusion imaging in stroke triage is to use this methodology in furnishing a functional and clinical concept of infarct core, ie, the identification of ischemic tissue that is resistant to revascularization. Our data suggest that the CBV lesion size is a surrogate for irreversible ischemic injury and thus is an appropriate parameter to aid in triaging stroke patients. Extensive discussion on appropriate perfusion imaging techniques, factors impacting vendor variation and standardization of imaging methodology is beyond the scope of the current paper and has been discussed in the literature. There is in summary sufficient evidence to support CT perfusion as a safe,<sup>25</sup> rapid,<sup>26</sup> and reliable imaging methodology.

Two US Food and Drug Administration-approved devices<sup>1-3</sup> are currently being utilized for endovascular stroke therapy, with several others undergoing clinical trials and yet more in the development stage. Most if not all are non-inferiority trials designed to show a primary endpoint of similar or better acute



**Figure 1** A comparison of effective and futile recanalization between the current study and the device trials. mRS, modified Rankin score.



## Ischemic stroke

vascular recanalization compared with a previously approved device. Recanalization as a predictor of good outcome is well supported by the literature.<sup>5 6 9 27 28</sup> In the MERCI and the Multi-MERCI trials,<sup>1 2</sup> recanalized patients had better outcomes; however, the majority of patients in the recanalized cohort, more than half, did not achieve a favorable outcome. The Penumbra Pivotal trial had the highest rates of recanalization but the lowest percentage of good outcomes, and recanalization was not even associated with a clear improvement in outcome.<sup>3</sup> This mismatch between recanalization and favorable outcomes is termed 'futile recanalization'.<sup>29 30</sup> As shown in figure 1, our rate of futile recanalization is the lowest of all the device trials while the rate of effective recanalization is the highest. One hypothesis to explain futile recanalization could be that subjecting all patients within a certain time window to endovascular therapy disregards their individual physiology thus limiting the impact of revascularization. The fact that such response can differ among patients based on collateral circulation, comorbid conditions and preprocedure physiology is well studied and documented. Our finding of a pre-intervention imaging profile defined by a small CBV abnormality predicting a favorable outcome supports this hypothesis. This is in keeping with multiple previous studies that have determined CBV to be a determinant of functional outcome.<sup>15 31 32</sup> We did not find any difference in mortality or outcomes in non-recanalized patients (table 3) indicating that restoration of blood flow remains vital to a good outcome. However, this restoration is more significant in terms of its impact in patients who still have viable brain tissue.

The intent of pre-intervention imaging is to identify patients who will respond to therapy. Such information, while not the sole determinant for triage, can nonetheless add a layer of knowledge to the clinical analysis and decision process. The reasons why this stated intent has not been fully realized are manifold. First, in contrast to preprocedure variables such as NIHSS score and age, which have been shown to predict outcome in large studies, no comparable, clear or consistent information exists when it comes to parametric perfusion studies. Second, imaging represents a snap shot in time in a complicated and rapidly evolving process. Due to the logistics involved in endovascular therapy an intervention may not be performed for an hour or more after the imaging study and revascularization may not be achieved until even later. The further out the intervention from the imaging, the less relevant the information obtained from it, as given time, most if not all ischemic tissue will succumb to infarction. With the introduction of the next generation of thrombectomy and retrieval devices for stroke, it is important that in order to maximize the effect of these devices, revascularization is linked to neurological recovery. These devices will have a greater impact when used on the right patient and a rapid physiological assessment of cerebral perfusion can support pre-intervention triage in selecting these patients.

### Limitations

A major limitation of our study is the comparison of a retrospective cohort with controlled, prospective device trials. While our data are very similar to these trials in terms of baseline characteristics, and even allowing for a higher initial NIHSS score we demonstrate significantly better outcomes, this limitation cannot be ignored. However, given the scarcity of literature showing a role of imaging in improving outcomes we hope that our data offer evidence supporting perfusion imaging as a possible tool in stroke triage.

### CONCLUSION

The most significant difference between our study and the device trials was a higher rate of good outcomes in patients who were successfully recanalized and thus a much lower rate of futile recanalization. This was despite a longer time to intervention, a similar or lower recanalization rate and accounting for the difference in NIHSS scores. The endpoint of any stroke intervention is not just re-establishing blood flow but to achieve better functional outcomes as a consequence of restoring blood flow. Therefore, adding cerebral perfusion information to other clinical predictors of outcome may increase the confidence with which an intervention is decided upon.

**Contributors** All authors contributed toward the study concept, design, literature review, data collection, statistical analysis and manuscript preparation.

**Competing interests** None.

**Ethics approval** Ethics approval was provided by the local institutional review board.

**Provenance and peer review** Not commissioned; externally peer reviewed.

### REFERENCES

1. **Smith WS**, Sung G, Saver J, *et al*. Mechanical thrombectomy for acute ischemic stroke: final results of the Multi MERCI trial. *Stroke* 2008;**39**:1205–12.
2. **Smith WS**, Sung G, Starkman S, *et al*. Safety and efficacy of mechanical embolectomy in acute ischemic stroke: results of the MERCI trial. *Stroke* 2005;**36**:1432–8.
3. **Penumbra Pivotal Stroke Trial Investigators**. The Penumbra Pivotal Stroke trial: safety and effectiveness of a new generation of mechanical devices for clot removal in intracranial large vessel occlusive disease. *Stroke* 2009;**40**:2761–8.
4. **Smith WS**. Safety of mechanical thrombectomy and intravenous tissue plasminogen activator in acute ischemic stroke. Results of the multi Mechanical Embolus Removal in Cerebral Ischemia (MERCI) trial, part I. *AJNR Am J Neuroradiol* 2006;**27**:1177–82.
5. **Furlan A**, Higashida R, Wechsler L, *et al*. Intra-arterial prourokinase for acute ischemic stroke. The PROACT II study: a randomized controlled trial. Prolase in Acute Cerebral Thromboembolism. *JAMA* 1999;**282**:2003–11.
6. **Flint AC**, Duckwiler GR, Budzik RF, *et al*. Mechanical thrombectomy of intracranial internal carotid occlusion: pooled results of the MERCI and Multi-MERCI Part I trials. *Stroke* 2007;**38**:1274–80.
7. **Anon**. Tissue plasminogen activator for acute ischemic stroke. The National Institute of Neurological Disorders and Stroke rt-PA Stroke Study Group. *N Engl J Med* 1995;**333**:1581–7.
8. **Demchuk AM**, Christou I, Wein TH, *et al*. Specific transcranial Doppler flow findings related to the presence and site of arterial occlusion. *Stroke* 2000;**31**:140–6.
9. **Natarajan SK**, Snyder KV, Siddiqui AH, *et al*. Safety and effectiveness of endovascular therapy after 8 hours of acute ischemic stroke onset and wake-up strokes. *Stroke* 2009;**40**:3269–74.
10. **Jovin TG**, Liebeskind DS, Gupta R, *et al*. Imaging-based endovascular therapy for acute ischemic stroke due to proximal intracranial anterior circulation occlusion treated beyond 8 hours from time last seen well: retrospective multicenter analysis of 237 consecutive patients. *Stroke* 2011;**42**:2206–11.
11. **Wintermark M**, Meuli R, Browaeys P, *et al*. Comparison of CT perfusion and angiography and MRI in selecting stroke patients for acute treatment. *Neurology* 2007;**68**:694–7.
12. **Schaefer PW**, Barak ER, Kamalian S, *et al*. Quantitative assessment of core/penumbra mismatch in acute stroke: CT and MR perfusion imaging are strongly correlated when sufficient brain volume is imaged. *Stroke* 2008;**39**:2986–92.
13. **Aviv RI**, Mandelcorn J, Chakraborty S, *et al*. Alberta Stroke Program Early CT Scoring of CT perfusion in early stroke visualization and assessment. *AJNR Am J Neuroradiol* 2007;**28**:1975–80.
14. **Wintermark M**, Flanders AE, Velthuis B, *et al*. Perfusion-CT assessment of infarct core and penumbra: receiver operating characteristic curve analysis in 130 patients suspected of acute hemispheric stroke. *Stroke* 2006;**37**:979–85.
15. **Murphy BD**, Fox AJ, Lee DH, *et al*. Identification of penumbra and infarct in acute ischemic stroke using computed tomography perfusion-derived blood flow and blood volume measurements. *Stroke* 2006;**37**:1771–7.
16. **Muir KW**, Halbert HM, Baird TA, *et al*. Visual evaluation of perfusion computed tomography in acute stroke accurately estimates infarct volume and tissue viability. *J Neurol Neurosurg Psychiatry* 2006;**77**:334–9.
17. **Preim B**, Oeltze S, Mlejnek M, *et al*. Survey of the visual exploration and analysis of perfusion data. *IEEE Trans Vis Comput Graph* 2009;**15**:205–20.
18. **Zussman BM**, Boghosian G, Goniak RJ, *et al*. The relative effect of vendor variability in CT perfusion results: a method comparison study. *AJR Am J Roentgenol* 2011;**197**:468–73.
19. **Furlan AJ**, Eyding D, Albers GW, *et al*. Dose Escalation of Desmoteplase for Acute Ischemic Stroke (DEDAS): evidence of safety and efficacy 3 to 9 hours after stroke onset. *Stroke* 2006;**37**:1227–31.

20. **Gasparotti R**, Grassi M, Mardighian D, *et al*. Perfusion CT in patients with acute ischemic stroke treated with intra-arterial thrombolysis: predictive value of infarct core size on clinical outcome. *AJNR Am J Neuroradiol* 2009;**30**:722-7.
21. **Furtado AD**, Smith WS, Koroshetz W, *et al*. Perfusion CT imaging follows clinical severity in left hemispheric strokes. *Eur Neurol* 2008;**60**:244-52.
22. **Kloska SP**, Dittrich R, Fischer T, *et al*. Perfusion CT in acute stroke: prediction of vessel recanalization and clinical outcome in intravenous thrombolytic therapy. *Eur Radiol* 2007;**17**:2491-8.
23. **Kim JT**, Yoon W, Park MS, *et al*. Early outcome of combined thrombolysis based on the mismatch on perfusion CT. *Cerebrovasc Dis* 2009;**28**:259-65.
24. **Arkuszewski M**, Swiat M, Opala G. Perfusion computed tomography in prediction of functional outcome in patients with acute ischaemic stroke. *Nucl Med Rev Cent East Eur* 2009;**12**:89-94.
25. **Dittrich R**, Akdeniz S, Kloska SP, *et al*. Low rate of contrast-induced nephropathy after CT perfusion and CT angiography in acute stroke patients. *J Neurol* 2007;**254**:1491-7.
26. **Rai AT**, Carpenter JS, Peykanu JA, *et al*. The role of CT perfusion imaging in acute stroke diagnosis: a large single-center experience. *J Emerg Med* 2008;**35**:287-92.
27. **Lee JY**, Kim SH, Lee MS, *et al*. Prediction of clinical outcome with baseline and 24-hour perfusion CT in acute middle cerebral artery territory ischemic stroke treated with intravenous recanalization therapy. *Neuroradiology* 2008;**50**:391-6.
28. **Nogueira RG**, Liebeskind DS, Sung G, *et al*. Predictors of good clinical outcomes, mortality, and successful revascularization in patients with acute ischemic stroke undergoing thrombectomy: pooled analysis of the Mechanical Embolus Removal in Cerebral Ischemia (MERCI) and Multi MERCI Trials. *Stroke* 2009;**40**:3777-83.
29. **Molina CA**. Futile recanalization in mechanical embolectomy trials: a call to improve selection of patients for revascularization. *Stroke* 2010;**41**:842-3.
30. **Hussein HM**, Georgiadis AL, Vazquez G, *et al*. Occurrence and predictors of futile recanalization following endovascular treatment among patients with acute ischemic stroke: a multicenter study. *AJNR Am J Neuroradiol* 2010;**31**:454-8.
31. **Kim JT**, Park MS, Choi KH, *et al*. The CBV-ASPECT Score as a predictor of fatal stroke in a hyperacute state. *Eur Neurol* 2010;**63**:357-63.
32. **Wang XC**, Gao PY, Xue J, *et al*. Identification of infarct core and penumbra in acute stroke using CT perfusion source images. *AJNR Am J Neuroradiol* 2010;**31**:34-9.



## Pre-intervention triage incorporating perfusion imaging improves outcomes in patients undergoing endovascular stroke therapy: a comparison with the device trials

Ansaar T Rai, Karthikram Raghuram, Jennifer Domico, et al.

*J NeuroIntervent Surg* published online February 18, 2012  
doi: 10.1136/neurintsurg-2011-010189

---

Updated information and services can be found at:  
<http://jnis.bmj.com/content/early/2012/02/17/neurintsurg-2011-010189.full.html>

---

*These include:*

- |                               |   |
|-------------------------------|---|
| <b>References</b>             | This article cites 32 articles, 20 of which can be accessed free at:<br><a href="http://jnis.bmj.com/content/early/2012/02/17/neurintsurg-2011-010189.full.html#ref-list-1">http://jnis.bmj.com/content/early/2012/02/17/neurintsurg-2011-010189.full.html#ref-list-1</a> |
| <b>P&lt;P</b>                 | Published online February 18, 2012 in advance of the print journal.   |
| <b>Email alerting service</b> | Receive free email alerts when new articles cite this article. Sign up in the box at the top right corner of the online article.  |
- 

- |                          |  |
|--------------------------|--|
| <b>Topic Collections</b> | Articles on similar topics can be found in the following collections<br>Ischemic stroke (105 articles) |
|--------------------------|--|
- 

### Notes

---

Advance online articles have been peer reviewed, accepted for publication, edited and typeset, but have not yet appeared in the paper journal. Advance online articles are citable and establish publication priority; they are indexed by PubMed from initial publication. Citations to Advance online articles must include the digital object identifier (DOIs) and date of initial publication.

---

To request permissions go to:  
<http://group.bmj.com/group/rights-licensing/permissions>

To order reprints go to:  
<http://journals.bmj.com/cgi/reprintform>

To subscribe to BMJ go to:  
<http://group.bmj.com/subscribe/>

**Paper-14:**

**Shankar and J Lum C: Crossed cerebellar diaschisis: assessment with dynamic contrast imaging on whole brain perfusion on 320 slice CT scanner. SNIS Annual Meeting poster abstracts (25). J NeuroIntervent Surg 2009 1: 97-98**

**022 ABO BLOOD GROUP ANALYSIS IN CEREBRAL DURAL ARTERIOVENOUS FISTULAE**

E Murphy, J Pryor. *Neurointerventional Radiology, Massachusetts General Hospital, Boston, Massachusetts, USA*

**Introduction and Purpose:** Thrombosis of dural arteriovenous fistulae (dAVF) is a well documented but rare phenomenon. Research suggests a connection between non-O blood grouping and thrombus formation in various organ systems; however, we report the first association of ABO blood type with spontaneous thrombosis in dAVF. **Material and Methods:** Between February 2000 and July 2007, a total of 55 dAVFs were evaluated by our service for endovascular treatment. Data collected included patient age, sex, presenting symptoms, blood group and outcome.

**Results:** Blood type data were obtained for 46 patients. ABO blood group distribution was: 15 (32.6%) type O, 20 (43.5%) type A, nine (19.6%) type B and two (4.3%) with AB. Spontaneous thrombosis was noted in four of 46 (8.7%) identified dAVF cases, all with blood type A. Each of the four dAVF patients demonstrating spontaneous thrombosis received distinctive clinical management. One case underwent cerebral angiogram demonstrating complete spontaneous thrombosis following transfer from another institution. Embolization was attempted in one case but was unsuccessful due to anatomical challenges. Angiogram of the subsequent day showed complete thrombosis of the dAVF. Another case received coil embolization with residual dAVF on the final run and at 6 months. One year follow-up angiography demonstrated complete spontaneous thrombosis of the dAVF. The final case underwent glue embolization followed by surgical resection with persistent residual dAVF documented on post-operative and 1-month follow-up examination. Angiography at 6 weeks demonstrated spontaneous thrombosis of the residual dAVF and his dural sinuses. Of the 55 cases identified, 43 received embolization treatment. Angiographic obliteration of the dAVF was documented in 20 (46.5%) cases. ABO blood group analysis showed five patients (33%) were type O, seven (35%) type A, one (11%) type B and two (100%) type AB. Blood type data were unavailable in five cases.

**Conclusion:** Given the distribution of ABO blood type prevalence in the USA, ABO blood type A expression appears to be a strong predictor of spontaneous thrombosis in patients with dAVFs, in this series of patients approaching statistical significance.

**Competing interests:** JP, Micrus Endovascular, ev3.

**023 VERTBROPLASTY FOR OSTEOPOROTIC VERTEBRAL FRACTURE**

M Kawanishi, Y Itoh, H Tanaka, K Yokoyama, M Yamada. *Neurosurgery, Takeda General Hospital, Kyoto, Japan*

**Background:** Percutaneous vertebroplasty is a less invasive method for the treatment of vertebral corpora with compression fracture by injection of bone cement. However, several studies have reported the occurrence of severe complications caused by leakage of the injected materials after percutaneous vertebroplasty.

**Objectives:** We examined safe and accurate procedures of percutaneous vertebroplasty, and evaluated short term results. We also evaluated methods for the prevention of complications.

**Subjects and Methods:** The subjects were 184 patients (268 vertebral corpora), consisting of 72 men and 112 women with a mean age of 76 years. Mean surgery time and complications were examined. Changes in pain and walking conditions after surgery were evaluated. The period required for the start of walking after surgery was examined in patients who could not walk by themselves before surgery.

**Results:** Mean surgery time was 15 min. Neurological or systemic complications, such as pulmonary embolism, were not observed. Postoperatively, no aggravation of pain was observed, pain was alleviated in 132 patients and pain remained unchanged in 52 patients. The mean visual analog scale (VAS) was 7.8 points before surgery and

1.8 points after surgery. Preoperatively, 106 patients could walk by themselves, 54 patients could walk with a little help and 24 patients could not walk, while postoperatively, 169 patients could walk by themselves.

**Conclusions:** Percutaneous vertebroplasty for the treatment of compression fractures removed pain in more than 90% of patients, indicating good short term results. To obtain good results without complications by this method requires accurate determination of the vertebral corpora to be treated, body position and needling under the guidance of fluoroscopy.

**Competing interests:** None.

**024 DOMINANCE OF ANTERIOR CEREBRAL ARTERY: A CT ANGIOGRAPHIC STUDY**

J Kalia, T Wolfe, S Hussain, K Mohammad, O Zaidat. *Medical College of Wisconsin, Milwaukee, Wisconsin, USA*

**Objective:** Dominance of arteries has been studied in different tissues/organs of body. Diagnostic, therapeutic and prognostic implications are hypothesized to be related to symmetry or asymmetry of circulation. One major implication in the case of the brain is the hypotheses that asymmetry exists due to differences in vascular requirements of the brain tissue. We studied the dominance of anterior cerebral artery on CT angiography.

**Methods:** This retrospective analysis included only ischemic stroke patients that were admitted to Froedtert Medical Luther Hospital (FMLH) between September 2007 and May 2008. The CT angiographic image was read by blinded readers. All were given printed forms on which they marked: dominance, small, hypoplastic or co-dominant for each side. The data were then gathered and analyzed. Dominance was defined on the basis of comparative luminal diameter and degree of flow.

**Results:** Of 53 patients assessed, we found that anterior cerebral artery origin is co-dominant in 30.2% (n = 16) of patients. The right side was dominant in 24.5% (n = 13); small in 3.8% (n = 2); and hypoplastic in 9.4% (n = 5). The left side was dominant 18.9% (n = 10); small in 3.8% (n = 2); and hypoplastic in 9.4% (n = 5).

**Conclusion:** Co-dominance is the most common form of dominance in anterior cerebral artery, and right anterior cerebral artery is the second most common form of dominance pattern.

**Competing interests:** None.

**025 CROSSED CEREBELLAR DIASCHISIS: ASSESSMENT WITH DYNAMIC CONTRAST IMAGING ON WHOLE BRAIN PERFUSION ON 320 SLICE CT SCANNER**

J Shankar, C Lum. *Diagnostic Imaging, The Ottawa Hospital, Ottawa, Ontario, Canada*

**Purpose:** Crossed cerebellar diaschisis refers to metabolic depression in the cerebellum contralateral to supratentorial lesions. It was first described in the positron emission tomography (PET) literature. Crossed cerebellar diaschisis is interpreted as functional deactivation, presumably caused by a loss of excitatory or inhibitory afferent inputs, on the corticopontocerebellar or other pathways. This phenomenon has been repeatedly described in studies examining oxygen consumption, cerebellar blood flow and glucose metabolism, using radioisotopes and MR perfusion. However, the literature describing crossed cerebellar diaschisis by CT perfusion is limited. The purpose of our study was to investigate the feasibility of the whole brain perfusion using a 320-slice CT scanner to depict crossed cerebellar diaschisis.

**Materials and Methods:** We studied 11 patients after unilateral supratentorial stroke with or without unilateral ICA occlusion. CT perfusion was performed using 50 ml of contrast at the rate of 4 ml/s. 20 volumes of the brain were acquired at the rate of 1 volume

**SNIS Annual Meeting poster abstracts**

every 2 s for 24 s followed by 1 volume every 5 s for another 20 s with an acquisition delay of 7 s. The acquisition parameters were 80 KV and 100 mA with a rotation time of 1 s. The post-processing of all perfusion studies was on a Vitrea fx V.1.0 workstation (Vital Images Inc, Minnesota, Wisconsin, USA) using singular value decomposition plus deconvolution method. Cerebral blood flow, cerebral blood volume and mean transit time were calculated in the two cerebellar hemispheres and were compared using paired t test. A p value of less than 0.005 was taken as significant.

**Results:** In all 11 patients, the relative regional cerebellar blood volume ( $p < 0.0001$ ) and flow ( $p = 0.0005$ ) values of the non-affected cerebellar hemisphere were significantly larger than those of the affected side.

**Conclusion:** The relative regional cerebellar blood volume map obtained with whole brain perfusion on 320-slice CT scanner depicted findings compatible with crossed cerebellar diaschisis in patients with supratentorial stroke. Its clinical feasibility may be further confirmed by direct comparison with PET or single photon emission computed tomography in a larger population.

**Competing interests:** None.

#### 026 PREVALENCE OF CO-DOMINANCE IN VERTEBRAL ARTERIES: A CT ANGIOGRAPHIC ASSESSMENT

J Kalia, S Hussain, T Wolfe, K Mohammad, O Zaidat. *Neurosciences, Medical College of Wisconsin, Milwaukee, Wisconsin, USA*

**Objective:** Dominance of arteries has been studied in different tissues/organs of body. Diagnostic, therapeutic and prognostic im-

plications are hypothesized to be related to symmetry or asymmetry of circulation. One major implication in the case of the brain is the hypotheses that asymmetry exists due to differences in vascular requirements of the brain tissue. Vertebral artery origin and its dominance have not been properly studied, especially on CT angiography. Since neurovascular intervention is increasingly becoming common, this information will be helpful in determining suitable access to basilar artery. Decreased bending of the basilar artery has also been reported to be related to dominance of the vertebral artery.

**Methods:** This retrospective analysis included only ischemic stroke patients that were admitted at Froedtert Medical Luther Hospital (FMLH) between September 2007 and May 2008. The CT angiographic image was read by blinded readers. All were given printed forms on which they marked: dominance, small, hypoplastic or co-dominant for each side. The data were then gathered and analyzed. Dominance was defined on the basis of comparative luminal diameter and degree of flow.

**Results:** Of 134 patients assessed, we found that vertebral artery origin is co-dominant in 31.8% ( $n = 27$ ) of patients. The right side was dominant in 21.6% ( $n = 29$ ); small in 11.9% ( $n = 16$ ); and hypoplastic in 1.5% ( $n = 2$ ). The left side was dominant in 37.3% ( $n = 50$ ); small in 6.75% ( $n = 9$ ); and hypoplastic in 0.7% ( $n = 1$ ). Although intracranially the ratio is different and the left side is still more dominant (24.7%) than the right side (18.8%), co-dominance was much less (4.7%).

**Conclusion:** Left side is most commonly found to be dominant in vertebral artery origin and co-dominance is the second most common form of dominance in vertebral arteries.

**Competing interests:** None.



**025 Crossed cerebellar diaschisis:  
assessment with dynamic contrast imaging  
on whole brain perfusion on 320 slice CT  
scanner**

J Shankar and C Lum

*J NeuroIntervent Surg* 2009 1: 97-98  
doi: 10.1136/jnis.2009.000869y

---

Updated information and services can be found at:  
<http://jnis.bmj.com/content/1/1/97.4.full.html>

---

**Email alerting  
service**

*These include:*

Receive free email alerts when new articles cite this article. Sign up in the box at the top right corner of the online article.

---

**Notes**

---

To request permissions go to:  
<http://group.bmj.com/group/rights-licensing/permissions>

To order reprints go to:  
<http://journals.bmj.com/cgi/reprintform>

To subscribe to BMJ go to:  
<http://group.bmj.com/subscribe/>

**Paper-15:**

**Shiva Shankar J J, Lum C, Sharma M: Whole-Brain Perfusion Imaging with 320-MDCT Scanner: reducing Radiation Dose by increasing sampling interval. AJR 2010; 195:1183-1186**



# Whole-Brain Perfusion Imaging With 320-MDCT Scanner: Reducing Radiation Dose by Increasing Sampling Interval

Jai Jai Shiva Shankar<sup>1</sup>  
Cheemun Lum<sup>2</sup>  
Mukul Sharma<sup>3</sup>

**OBJECTIVE.** The purpose of this study was to investigate whether perfusion CT values obtained with a reduced-dose imaging protocol on a 320-MDCT scanner are similar to those obtained with a standard protocol.

**CONCLUSION.** Similar perfusion values at one-half the radiation dose can be obtained with the alternative algorithm used in this study.

**P**erfusion CT of the brain generates hemodynamic information about different diseases but poses radiation risk. The chief limitation of perfusion CT has been limited brain coverage, but the introduction of 320-MDCT scanners has made it possible to perform perfusion CT of the whole brain. CT is the main source of nonbackground radiation [1]. Judicious use of CT according to the as low as reasonably achievable principle is necessary to prevent the detrimental effects of medical radiation. Several algorithms have been proposed to limit radiation in the imaging of stroke [2, 3], including limited-slice perfusion CT [4]. An imaging technique that generates hemodynamic information about the whole brain with a reasonable radiation dose profile is desirable. We describe an alternative acquisition protocol that yields whole-brain perfusion CT information at a reduced radiation dose compared with that of the existing scanning technique.

## Materials and Methods

The study was approved by the institutional ethics committee. We retrospectively reviewed images from 20 perfusion studies of 19 patients (10 men, nine women; age range, 34–78 years) performed with a 320-MDCT scanner (Aquilion One, Toshiba) for various clinical indications (Table 1). One of the patients with vasospasm underwent two perfusion CT studies.

## Imaging Protocol

For each patient, 19 volumes of whole brain were acquired, and a total of 40 mL of nonionic iodinated contrast medium (iohexol, Omnipaque 300 mg/mL I, GE Healthcare) was injected at a rate of

4 mL/s. Each volume consisted of 320 images of 0.5-mm thickness with z-axis coverage of 16 cm. An acquisition delay of 7 seconds allowed acquisition of a baseline volume (80 kVp; 300 mAs; rotation time, 1 second) without contrast enhancement. This acquisition was used as a bone subtraction mask for subsequent CT angiography. The next 13 volumes of the brain (80 kVp; 100 mAs; rotation time, 1 second) were acquired 11 seconds after the start of contrast injection at a sampling interval of 2 seconds during the arterial and the capillary phases. Another five volumes were acquired at a sampling interval of 5 seconds. The total acquisition time was 60 seconds.

## Data Processing

All perfusion CT studies were postprocessed on an independent workstation (Vitrea fx version 1.0, Vital Images) with the delay insensitive singular value decomposition plus nonparametric deconvolution method. To avoid volume averaging, the reference arterial input function selected was the supraclinoid segment of the internal carotid artery; the venous output function was the posterior portion of the superior sagittal sinus.

The same data sets were postprocessed in a two-step manner: first with the standard algorithm of selecting all acquired volumes and then with alternate volumes, which increased the sampling interval twofold in our acquisition protocol (Fig. 1). Color parametric maps were obtained with each algorithm.

## Data Analysis

Identical slice locations were selected at the level of the basal ganglia in all perfusion studies performed with both the standard and alternative algorithms. Five identical regions of interest, each measuring more than 5 mm<sup>2</sup>, were placed in the

**Keywords:** 320-MDCT, perfusion CT, radiation dose, whole-brain perfusion CT

DOI:10.2214/AJR.10.4230

Received January 5, 2010; accepted after revision April 12, 2010.

Data presented at the 2009 annual meeting of the American Society of Neuroradiology, Vancouver, BC, Canada.

<sup>1</sup>Neuroradiology Section, Department of Medical Imaging, QE II Hospital, 1807, 5770 Spring Garden Road, Halifax, NS, Canada B3H4J8. Address correspondence to J. J. S. Shankar (shivajai1@gmail.com).

<sup>2</sup>Department of Diagnostic Imaging, The Ottawa Hospital, Ottawa, ON, Canada.

<sup>3</sup>Department of Neurology, The Ottawa Hospital, Ottawa, ON, Canada.

AJR 2010; 195:1183–1186

0361–803X/10/1955–1183

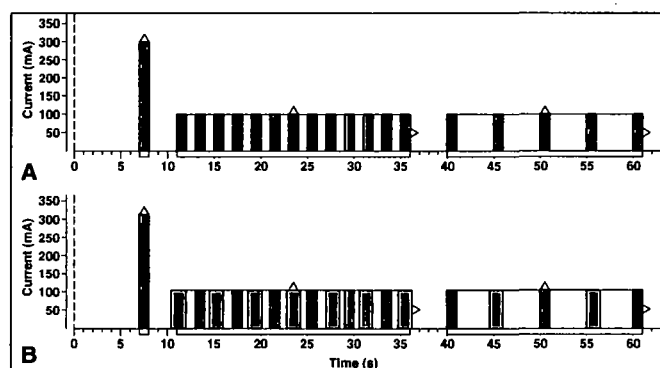
© American Roentgen Ray Society

Shankar et al.

**TABLE 1: Clinical Indications for Whole-Head Perfusion CT**

Indication	No. of Patients
Acute stroke	3
Vasospasm	3
Bilateral severe stenosis of ICA	2
Occlusion of right ICA	4
Stenosis of right ICA	2
Occlusion of left ICA	1
Stenosis of left ICA	2
Tumor (meningioma)	1
Frontal arteriovenous malformation	1

Note—ICA = internal carotid artery.



**Fig. 1—Acquisition protocols.** A and B, diagrams show standard (A) and alternative (B) acquisition protocols for whole-brain perfusion CT.

bilateral frontal gray and white matter, putamen, and temporal gray and white matter. The perfusion parameters cerebral blood flow, cerebral blood volume, and mean transit time were calculated. The expected radiation dose in dose-length product for the alternative postprocessing algorithm was calculated on the CT workstation.

**Statistical Analysis**

Pearson’s correlation coefficient was used to correlate the perfusion parameters of the two algorithms. A value of  $p < 0.05$  was considered significant.

**Results**

Tables 2–4 show the perfusion values obtained with the two algorithms in the five regions of interest. Pearson’s correlation coefficient for the values obtained with the two acquisition algorithms was  $0.84 \pm 0.086$ , suggesting excellent correlation ( $p < 0.0001$ ). The perfusion values obtained with the two algorithms exhibited linear correlation (Fig. 2). The color parametric maps obtained with the two algorithms did not differ significantly (Fig. 3). The radiation dose with the standard algorithm was a dose-length product of 1,920 and with the alternative algorithm was a dose-length product of approximately 1,000.

**Discussion**

Since 1980, the number of CT examinations performed has increased almost 20-fold, mainly owing to advances in neuroradiologic CT technology [2, 3]. The limited coverage of perfusion CT and the radiation exposure, particularly when repeated examinations are needed, are the major concerns in the care of patients with acute stroke [3]. The

development of 320-MDCT scanners addresses the issue of whole-brain coverage in perfusion CT [5]. Radiation exposure continues to be a concern, however, and alternative methods of limiting the radiation dose are desirable. Multiple factors, including tube voltage [6, 7], tube current [7], scanning duration [8], pitch factor, and temporal resolution [9–11], can be altered to reduce the radiation dose of CT. The principal strategy for reducing the radiation dose in perfusion CT has been reduction of the tube voltage from 120 to 80 kVp [6].

A wide range of sampling intervals from 0.5 to 4 seconds have been proposed [10, 11]. Wintermark et al. [9] found that a sampling interval greater than 1 second can be used without altering the quantitative accuracy of perfusion CT. Those authors, however, also stated that with a 40-mL contrast bolus, the highest temporal resolution that should be used is 3 seconds. Our results suggest that we may be able to use temporal resolution of up to 4 seconds with a contrast bolus of 40 mL. Our results also suggest excellent correlation between absolute perfusion values obtained with a sampling interval of 4 and those obtained with an interval of 2 seconds. This increased sampling interval allows conventional CT, time-resolved CT angiography of the whole head, and whole-brain perfusion CT in one acquisition with a 320-MDCT scanner. The radiation dose in our alternative algorithm (dose-length product, ~ 1,000) is comparable to the radiation dose for conventional CT of the head.

Although contrast volume has been found insignificant in the acute setting [12], an upper limit of approximately 150 mL of contrast

**TABLE 2: Correlation Between Standard and Alternative Perfusion CT Algorithms With Respect to Mean Cerebral Blood Flow (mL/100 g/min)**

Region of Interest	Algorithm		r
	Standard	Alternative	
Right frontal gray matter	30.53	29.46	0.863
Right frontal white matter	24.76	23.00	0.973
Right putamen	31.77	31.85	0.844
Right temporal gray matter	27.31	24.01	0.809
Right temporal white matter	20.46	21.68	0.874
Left frontal gray matter	33.51	32.84	0.92
Left frontal white matter	23.76	25.29	0.986
Left putamen	33.43	33.19	0.932
Left temporal gray matter	30.09	29.61	0.949
Left temporal white matter	22.75	21.39	0.569

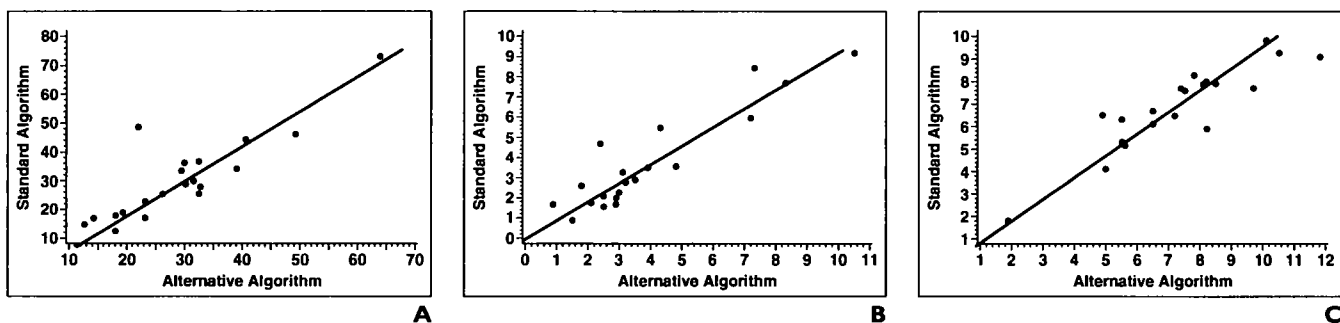
**Reducing Radiation Dose in Whole-Brain Perfusion CT**

**TABLE 3: Correlation Between Standard and Alternative Perfusion CT Algorithms With Respect to Mean Cerebral Blood Volume (mL/100 g)**

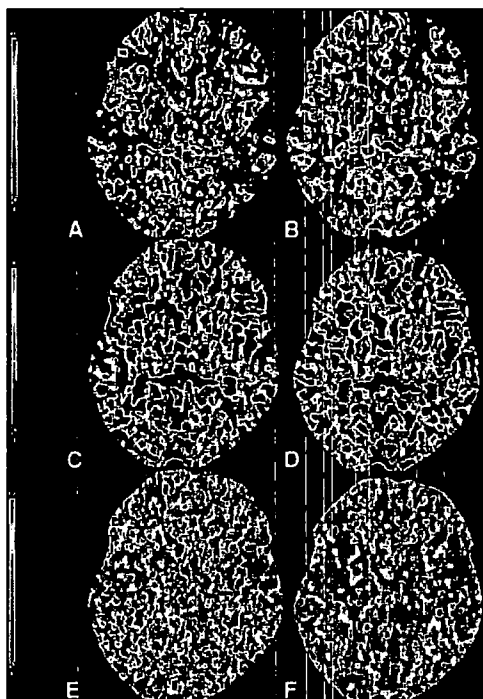
Region of Interest	Algorithm		r
	Standard	Alternative	
Right frontal gray matter	3.89	4.21	0.929
Right frontal white matter	3.28	3.53	0.94
Right putamen	5.04	5.78	0.959
Right temporal gray matter	3.72	3.93	0.92
Right temporal white matter	3.29	3.97	0.954
Left frontal gray matter	3.68	4.42	0.75
Left frontal white matter	3.16	4.07	0.895
Left putamen	4.39	5.56	0.798
Left temporal gray matter	3.79	5.13	0.805
Left temporal white matter	3.47	4.14	0.858

**TABLE 4: Correlation Between Standard and Alternative Perfusion CT Algorithms With Respect to Mean Transit Time (seconds)**

Region of Interest	Algorithm		r
	Standard	Alternative	
Right frontal gray matter	6.89	7.32	0.896
Right frontal white matter	6.64	6.69	0.809
Right putamen	6.68	6.85	0.784
Right temporal gray matter	6.35	6.64	0.87
Right temporal white matter	6.25	6.42	0.702
Left frontal gray matter	6.74	7.02	0.808
Left frontal white matter	6.5	6.86	0.712
Left putamen	6.76	6.99	0.721
Left temporal gray matter	5.91	6.41	0.575
Left temporal white matter	6.19	6.28	0.819



**Fig. 2—**Scatter diagrams of values obtained in all regions of interest. A–C, Diagrams show linear correlation between alternative and standard algorithms with respect to cerebral blood flow (mL/100 g/min) (A), cerebral blood volume (mL/100 g) (B), and mean transit time (seconds) (C).



**Fig. 3—**44-year-old woman with chronic right internal carotid occlusion. A–F, Color parametric maps of cerebral blood flow obtained with standard (A) and alternative (B) algorithms, of cerebral blood volume (C and D), and of mean transit time (E and F) show no significant difference in findings with two algorithms.

agent should be used to avoid renal dysfunction. The CT angiography and perfusion CT for our stroke protocol with other helical CT scanners require contrast volumes of 70 and 50 mL. With a 320-MDCT scanner, the total dose of contrast material with our algorithm for time-resolved CT angiography and perfusion CT is 40 mL, an approximately threefold reduction compared with the standard algorithm. The alternative algorithm may be useful in cases of acute stroke and as a screening tool in the care of unconscious patients to detect unlocalized infarcts that might be managed in a manner similar to that for vasospasm in postaneurysmal subarachnoid hemorrhage.

Our study was limited by the lack of a defined study population. To further validate our hypothesis, it would be ideal to evaluate patients who have experienced acute stroke. Despite the limitations, our proposed acquisition protocol for whole-brain perfusion CT yields perfusion values comparable to those obtained with the standard algorithm at a radiation dose reduced by a dose-length product of 900, approximately one-half the usual dose.

**Shankar et al.**

**References**

1. Brenner DJ, Hall EJ. Computed tomography: an increasing source of radiation exposure. *N Engl J Med* 2007; 357:2277–2284
2. Smith AB, Dillon WP, Gould R, et al. Radiation dose-reduction strategies for neuroradiology CT protocols. *AJNR* 2007; 28:1628–1632
3. Cohnen M, Wittsack HJ, Assadi S, et al. Radiation exposure of patients in comprehensive computed tomography of the head in acute stroke. *AJNR* 2006; 27:1741–1745
4. Wiesmann M, Berg S, Bohner G, et al. Dose reduction in dynamic perfusion CT of the brain: effects of the scan frequency on measurements of cerebral blood flow, cerebral blood volume, and mean transit time. *Eur Radiol* 2008; 18:2967–2974
5. Siebert E, Bohner G, Dewey M, et al. 320-slice CT neuroimaging: initial clinical experience and image quality evaluation. *Br J Radiol* 2009; 82: 561–570
6. Wintermark M, Maeder P, Verdun FR, et al. Using 80 kVp versus 120 kVp in perfusion CT measurement of regional cerebral blood flows. *AJNR* 2000; 21:1881–1884
7. Hirata M, Sugawara Y, Fukutomi Y, et al. Measurement of radiation dose in cerebral CT perfusion study. *Radiat Med* 2005; 23:97–103
8. Hirata M, Sugawara Y, Murase K, et al. Evaluation of optimal scan duration and end time in cerebral CT perfusion study. *Radiat Med* 2005; 23: 351–363
9. Wintermark M, Smith WS, Ko NU, et al. Dynamic perfusion CT: optimizing the temporal resolution and contrast volume for calculation of perfusion CT parameters in stroke patients. *AJNR* 2004; 25:720–729
10. Kämena A, Streitparth F, Grieser C, et al. Dynamic perfusion CT: optimizing the temporal resolution for the calculation of perfusion CT parameters in stroke patients. *Eur J Radiol* 2007; 64:111–118
11. Lee SH, Kim JH, Kim KG, Park SJ, Im JG. Application of time sampling in brain CT perfusion imaging for dose reduction. In: Hsieh J, Flynn MJ, eds. *Medical imaging 2007: physics of medical imaging—proceedings of SPIE*, vol. 6510. Bellingham, WA: SPIE, 2007:65102P
12. Hopyan JJ, Gladstone DJ, Mallia G, et al. Renal safety of CT angiography and perfusion imaging in the emergency evaluation of acute stroke. *AJNR* 2008; 29:1826–1830

**FOR YOUR INFORMATION**

The American Roentgen Ray Society now provides instant Web exclusive access to its annual meeting abstracts. The abstracts, featured as a supplement to the *American Journal of Roentgenology*, summarize the latest comprehensive and clinically important information presented at ARRS's annual meetings. The abstracts can be viewed online by visiting [www.ajronline.org](http://www.ajronline.org).

1  
2  
3  
4  
5  
6  
7  
8  
9  
10  
11  
12  
13  
14  
15  
16  
17  
18  
19  
20  
21  
22  
23  
24  
25  
26  
27  
28  
29  
30  
31  
32  
33  
34  
35  
36  
37  
38  
39  
40  
41  
42  
43  
44  
45  
46  
47  
48  
49  
50  
51  
52  
53  
54  
55  
56  
57  
58  
59  
60  
61  
62  
63  
64  
65  
66  
67  
68  
69  
70  
71  
72  
73  
74  
75  
76  
77  
78  
79  
80  
81  
82  
83  
84  
85  
86  
87  
88  
89  
90  
91  
92  
93  
94  
95  
96  
97  
98  
99  
100

**Paper-16:**  
**Shankar. Whole brain CT perfusion on a 320-**  
**slice CT scanner. Indian J Radiol Imaging. 2011**  
**Jul-Sep; 21(3): 209-214**



JOURNAL | AHEAD OF PRINT | CURRENT ISSUE | PAST ISSUES | INSTRUCTIONS | SUBMISSION | SUBSCRIBE | ADVERTISE

Log in | 595 online | 458

Home | About | Contact Us

Click here to download free Android Application for this and other journals

### Home Ultrasound Unit

Relieve Pain, Speed Healing At Home 100% Guaranteed & Dr Recommended  
[UltrasoundCure.com](http://UltrasoundCure.com) AdChoices

◀ Previous Article | TOC | Next Article ▶

## NEURORADIOLOGY

Year : 2011 | Volume : 21 | Issue : 3 | Page : 209-214

Whole brain CT perfusion on a 320-slice CT scanner

Jai Jai Shiva Shankar<sup>1</sup>, Cheemun Lum<sup>2</sup>

<sup>1</sup> Department of Diagnostic Imaging, QE II Hospital, Halifax, Canada

<sup>2</sup> Department of Diagnostic Imaging, The Ottawa Hospital, Canada

Click [here](#) for correspondence address and email

Date of Web Publication: 24-Sep-2011

- Download Article (pdf)
- Email Article
- Print Article
- Read / Write a Comment
- Citation Manager

### Abstract

Computed tomography perfusion (CTP) has been criticized for limited brain coverage. This may result in inadequate coverage of the lesion, inadequate arterial input function, or omission of the lesion within the target perfusion volume. The availability of 320-slice CT scanners offers whole brain coverage. This minimizes the chances of misregistration of lesions regardless of location, and makes the selection of the arterial input function easy. We present different clinical scenarios in which whole brain CTP is especially useful.

**Keywords:** 320-slice CT scanner; whole brain CT perfusion; CT scan

### How to cite this article:

Shiva Shankar JJ, Lum C. Whole brain CT perfusion on a 320-slice CT scanner. Indian J Radiol Imaging 2011;21:209-14

### How to cite this URL:

Shiva Shankar JJ, Lum C. Whole brain CT perfusion on a 320-slice CT scanner. Indian J Radiol Imaging [serial online] 2011 [cited 2012 Oct 1];21:209-14. Available from: <http://www.ijri.org/text.asp?2011/21/3/209/85370>

### Introduction

The major limitation of computed tomography perfusion (CTP) has been its limited brain coverage. This may result in inadequate coverage of the lesion, inadequate arterial input function, or omission of the lesion within the target perfusion volume. This is important

### Search

GO

Similar in PUBMED  
Search Pubmed for

- [Shiva Shankar JJ](#)
- [Lum C](#)

Search in Google Scholar for

- [Shiva Shankar JJ](#)
- [Lum C](#)

### Related articles

- [320-slice CT scanner: whole brain CT perfusion: CT scan](#)

### Email Alert \*

Add to My List \*

\* Registration required (free)

### Abstract

[Introduction](#)

[Principle and Method](#)

[Results](#)

[Discussion](#)

[Conclusion](#)

### References

[Article Figures](#)

[Article Tables](#)

### Article Access Statistics

Viewed	1559
Printed	81
Emailed	3
PDF Downloaded	171
Comments	<a href="#">[Add]</a>

Total downloads in last 2 months

Oct 2012	4
Sep 2012	80

especially in diffuse and multifocal diseases such as vasculitis or vasospasm, arteriovenous malformation (AVM), and chronic ischemia.

The other available options for evaluating brain perfusion are nuclear medicine studies such as positron emission tomography (PET) and single photon emission computed tomography (SPECT). However, accessibility and spatial resolution are a major limitation. In addition, the resolution of these imaging studies may be a limiting factor. MRI perfusion (MRP) is a promising technology, offering the ability to image the whole brain. The major disadvantage of MRP is that the perfusion parameters are relative rather than absolute, unlike those in CTP.

Imaging of the whole brain can be done with 320-slice CT scanners. The other major advantage is the possibility of getting time-resolved CT angiographic information from the same data set, without additional contrast or radiation.<sup>11</sup> The purpose of this article is to review the clinical situations in which whole brain CTP is useful.

## Principle and Method

We retrospectively reviewed patients who underwent whole brain CTP for various clinical indications between May 2008 and March 2009 at a single institution. The study was approved by our institutional ethics committee. All studies were performed on a 320-slice CT scanner (Toshiba Medical System, Nasu, Japan).

## Imaging protocol

CT perfusion was performed using 40 mL of nonionic iodinated contrast media (Omnipaque, 300 mg/mL of iodine; Amersham Heath, Princeton, NJ, USA), injected intravenously at the rate of 4 mL/s. A total of 19 volumes covering the whole brain were acquired, with each volume consisting of 320 images of 0.5 mm thickness covering a total of 16 cm of the head in the z direction. The first volume was acquired with an acquisition delay of 7 s after the injection of contrast media. The time delay allowed the acquisition of baseline images without contrast enhancement, which were used as a mask for obtaining bone subtraction for subsequent computed tomographic angiogram (CTA). The acquisition parameters for the first volume were 80 kVp and 300 mA. Next, 13 volumes of the brain were acquired starting at 11 s after the injection of contrast media at a sampling interval of one volume every 2 s. These volumes were acquired during the arterial and the capillary phase. Then, five volumes were acquired at a sampling interval of one volume every 5 s. The acquisition parameters for all volumes after the first volume were 80 kVp and 100 mA. The total duration of the acquisition was 60 s.

## Data processing

Postprocessing was performed on a Vitrea fx, version 1.0, workstation (Vital Images Inc., MN, USA) using the delay-insensitive singular-value decomposition (SVD) plus nonparametric deconvolution method. The supraclinoid segment of the internal cerebral artery was chosen to measure the reference arterial input function to avoid any volume averaging. The posterior portion of the superior sagittal sinus was selected for the same reason, to evaluate the venous output function.

Color maps of the hemodynamic parameters such as blood flow (BF), blood volume (BV), mean transit time (MTT), and time to peak (TTP) were calculated using the SVD plus deconvolution method. The specific hemodynamic information of the diseased portion of the brain was obtained by drawing various regions of interest (ROIs) in the area and then comparing them with the ROIs of the normal brain.

In most cases, CTP was requested by the referring doctors for clinical indications. In other cases, CTP data was acquired from the time-resolved CT angiograms of the brain performed for other clinical indications.

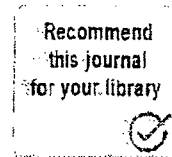
## Results

Ads by Google

Treatment of Brain Tumor

Brain Surgery

Coronary CT Scan



Google Translate

Select Language

Google, Gooqle powered by Google

A total of 81 patients (35 males and 46 females) with a mean age of 56.5 years (range, 31-85 years) underwent whole brain CTP in our institute for various clinical indications as shown in [Table 1].

## Cases

Since the patients with brain tumors were studied with limited-slice CTP on another CT scanner as part of another ongoing study, most of the patients in our study had one or the other form of ischemia.

### Acute stroke

In cases of acute stroke, whole brain CTP demonstrates the whole extent of the infarct. These can be either territorial infarcts [Figure 1] or multiple embolic infarcts. In cases of multiple emboli, whole brain perfusion helps in the localization of infarcts and in determining their age [Figure 2]. This is particularly helpful in cases where infarcts are located at the extreme ends of the brain, i.e., near the vertex or posterior fossa. Using conventional CTP with limited brain coverage, it is often difficult to obtain an adequate arterial input curve in these areas.



Figure 1: A 95-year-old woman presented with left hemiplegia. CT scan of the brain (A) shows a positive "dense MCA sign" (arrow) with the rest of the brain (B) showing relatively preserved gray-white matter differentiation. Time-resolved CTA (C) shows lack of flow in the right internal carotid artery (arrow) and the right middle cerebral artery (MCA) territory with delayed filling of the right distal internal carotid artery (ICA; arrow in D). Whole brain perfusion shows an almost complete right MCA territory-matched defect (arrows) on cerebral blood flow (CBF; E) and cerebral blood volume (CBV; F) maps. The whole extent of the right MCA territory infarct is better seen on the 3D reconstruction of CBF (G), CBV (H), mean transit time (I), and time to peak (J) maps

[Click here to view](#)

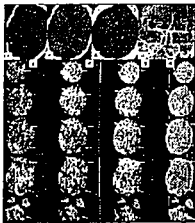


Figure 2: A 65-year-old woman collapsed immediately after bronchoscopy. CT scan of the brain (A-C) shows multiple foci of air (arrows) throughout the brain, suggestive of air embolism. CTA (D) shows no obvious abnormality. Multiple axial images of whole brain CT perfusion show the overall decrease in cerebral blood flow (arrows in E), multiple foci of decreased cerebral blood volume (arrows in F), increased mean transit time (arrows in G), and increased time to peak (arrows in H) throughout the brain

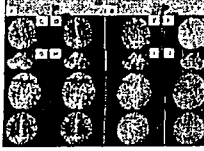
[Click here to view](#)

CT perfusion is helpful in evaluating patients with an impaired level of consciousness, for whom clinical examination has limited scope. Whole brain CTP is important in localizing unsuspected infarcts in this group of patients. This may be seen in patients with intracranial hemorrhage, in whom the infarcts occur secondary to mass effect or from vasospasm after aneurysmal subarachnoid hemorrhage [Figure 3]. These ischemic lesions may be reversible with timely intervention, especially in cases of vasospasm [Figure 3].



Figure 3: A 51-year-old woman with a ruptured left posterior communicating artery aneurysm developed a decreased level of consciousness and right hemiplegia, postclipping. Digital subtraction angiography (A) shows vasospasm (arrows), which improved (arrows)





in B), after treatment with intra-arterial thrombolysis.

Whole brain CT perfusion shows a large area of decreased CBF (arrow in C), normal CBV (D), and increased MTT (arrow in E) and TTP (arrow in F) in the left hemisphere. Post-treatment CTP (G-J) was normal with no residual clinical deficits

[Click here to view](#)

### Chronic ischemia

In patients with chronic ischemia of the brain, a wide spectrum of findings such as multiple, patchy ischemic lesions or lesions quite remote from the actual site of ischemia can be seen. In crossed cerebellar diaschisis (CCD), there is metabolic depression in the cerebellum contralateral to supratentorial lesions.<sup>[2]</sup> This entity has been described on PET and MRI perfusion studies.<sup>[3],[4]</sup> However, to the best of our knowledge, it has not been described on conventional CTP due to reasons of limited coverage. With the whole brain CTP, we have seen evidence of CCD in patients with supratentorial lesions<sup>[5]</sup> [Figure 4].




Figure 4: An 83-year-old woman with clinical evidence of right hemispheric ischemia shows no obvious infarct or chronic ischemic changes in the right cerebral hemisphere and in the cerebellum on plain CT scan of the head (A-C). Chronic right internal carotid artery occlusion (arrows) is seen on a CT angiogram image (D). Whole brain CT perfusion (E-H) shows matched decrease in CBF (arrows in E) and CBV (arrows in F) in the right middle cerebral artery distribution. There is also decreased CBF (arrows in G) and CBV (arrows in H) in the contralateral cerebellar hemisphere (arrows), suggestive of crossed cerebellar diaschisis

[Click here to view](#)

In the case of the chronic occlusion of a major artery with chronic hemispheric ischemic symptoms, surgical revascularization is an option. The assessment of the cerebrovascular reserve is critical to determine whether patients will benefit from bypass surgery.<sup>[6]</sup> Whole brain CTP can provide information regarding global cerebral hemodynamics, which are of critical importance in this clinical scenario [Figure 5].



Figure 5: A 59-year-old man with a history of chronic right hemispheric ischemia. Time-resolved CTA (A) shows right internal carotid artery occlusion (arrows). Before external carotid artery (ECA)-internal carotid artery (ICA) bypass surgery, the acetazolamide test done with whole brain CT (B-E) perfusion shows an increase in CBF (arrows in D) and no change in CBV before (B and C) and after (D and E) injection of acetazolamide. This is much more pronounced in the right cerebral hemisphere (arrows in D), suggestive of a good cerebral vascular reserve. His symptoms improved following bypass surgery

[Click here to view](#)

After the external-to-internal carotid artery bypass surgery for chronic ischemia, the hemodynamics of the brain change immediately after surgery and evolve further over time as the brain adapts to its new blood supply. We have found that in the immediate postoperative period, there is an increase in the cerebral blood flow (CBF), cerebral blood volume (CBV), and MTT compared to the decreased CBF and increased CBV

and MTT in the setting of chronic ischemia [Figure 6]. The increase in the CBF may be explained by the increase in the blood flow through the bypass. However, as the bypass channel matures over time, both CBF and CBV normalize. The MTT continues to increase, possibly reflecting the low perfusion pressure through the alternate bypass channel.

Figure 6: Patient with a right ICA occlusion underwent right superficial temporal artery-middle cerebral artery (STA-MCA) bypass surgery for right hemispheric ischemic symptoms. Time-resolved CTA (A) done after the surgery shows the patent bypass channel (A). Whole brain CTP (B and C) done before (B) and after (C) the surgery shows a marked increase in CBF



(arrow) and CBV (arrow) and a relative decrease in MTT (arrow) and TTP (arrow) in the right middle cerebral artery distribution. However, the MTT and TTP continued to be elevated (arrows in C)

[Click here to view](#)

### Arteriovenous malformation

Although focal, AVMs can affect the global hemodynamics of the brain. This is dependent on the size and presence of high-flow channels. [12] We have observed similar findings on whole brain CTP. [13] The CBF and CBV are markedly elevated within the AVM nidus, reflecting high vascularity [Figure 7]. However, the perinidal areas demonstrated low CBF and CBV, suggestive of perinidal ischemia. In two of our patients with supratentorial AVMs, we found low CBF and CBV in the contralateral cerebellar hemisphere, consistent with crossed cerebellar diaschisis [Figure 7]. Similar findings have also been described in the nuclear medicine literature. [14]

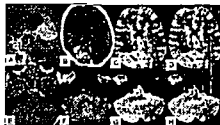

Figure 7: A 50-year-old woman presented with recently worsening headache. Time-resolved (A) and axial (B) CT angiograms show a high-flow right occipital AVM (arrows). Whole brain CT perfusion (C and D) shows high CBF (black arrows in C) and CBV (black arrows in D) in the nidus and low CBF (white arrows in C) and CBV (white arrows in D) in the perinidal area, suggestive of perinidal ischemia. There is no evidence of cerebellar ischemia on the FLAIR (E) and diffusion (F) images. CBF (arrows in G) and CBV (arrows in H) are low in the contralateral cerebellar hemisphere, suggesting crossed cerebellar diaschisis

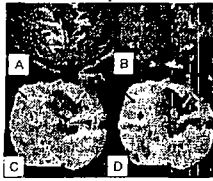
[Click here to view](#)

### Brain tumors

Most brain tumors can be assessed with limited-slice CTP as localization of the lesion is usually not an issue. The major limitation is the selection of the arterial input function in tumors located at the extreme ends of the brain, i.e., either near the vertex or in the posterior fossa [Figure 8]. The limited coverage of a large tumor on limited-slice CTP may also be inadequate in depicting tumor heterogeneity, which is an important characteristic for the grading of brain tumors on imaging.

Figure 8: A 49-year-old man with a parasagittal meningioma underwent surgical resection and radiation therapy. Axial FLAIR (A) and diffusion-weighted (B) images show similar changes (arrows) in both frontoparietal regions. Whole brain CT perfusion (C





and D) done to differentiate tumor recurrence from radiation necrosis shows very high CBF (black arrows in C) and CBV (black arrows in D) in the right frontoparietal lesion, most likely suggestive of tumor recurrence, compared to the left frontoparietal lesion, which shows low CBF (white arrows in C) and CBV (white arrows in D), suggestive of either postoperative changes or radiation necrosis

[Click here to view](#)

### Intracerebral hematoma

Intracerebral lobar hematomas are known to demonstrate perilesional ischemia.<sup>[9]</sup> The presence of the positive "spot sign" has been described to be an indicator of the future growth of the hematoma.<sup>[10]</sup> In one of our patients with lobar hematoma who demonstrated an evolving "spot sign," there was decreased CBF and CBV in the perilesional brain parenchyma [Figure 9]. The increase in the size of the hematoma on the follow-up CT scan appeared to be in the area of perilesional ischemia. Whether this perilesional area of decreased perfusion is at risk of hematoma growth needs to be studied with a larger number of patients.

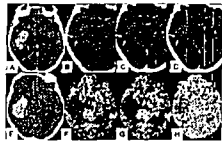


Figure 9: An 86-year-old woman presented with a large right temporal lobar hematoma, which is seen on the axial CT scan (arrows in A). On the raw data of time-resolved CT angiography (B-D), an increasing "spot sign" is seen (arrows) over the multiple volumes acquired during the late venous phase. This sign may be predictive of an increase in the hematoma volume over time, seen on the subsequent CT of the head (E) done 6 h later. The whole brain CTP (F-H) obtained from the CTA data shows evidence of perilesional ischemia with low CBF (arrows in F), low CBV (arrows in G), and high MTT (arrows in H)

[Click here to view](#)

### Discussion

Cerebral perfusion provides information about blood flow at the tissue (capillary) level.<sup>[11],[12]</sup> In the setting of cerebral ischemic disease, CTP can be used to assess the reversibility of an ischemic lesion. In the setting of acute ischemic stroke, CBV lesions represent the core of the infarct tissue whereas the CBF, MTT, and TTP lesions represent the area of ischemia. In a setting of a mismatch between the CBF, MTT or TTP lesions, and CBV lesions, the difference represents the area of the penumbra, which is ischemic but potentially salvageable tissue. This area of penumbra is the target for treatment in the setting of acute ischemic stroke. If the lesions on CBF, MTT or TTP maps, and CBV maps match, it implies that the whole area is already infarcted and there is no role of thrombolysis in the treatment of acute ischemic stroke. Many of the diseases of the cerebral vasculature have global effects rather than focal effects. So it is important to have an imaging modality that can assess the cerebral vasculature globally.

Nuclear studies, including PET and SPECT and MRI perfusion, are ideal choices for these clinical situations. The disadvantage of nuclear studies is variable local experiences and availability. A major disadvantage of MRP is lack of proper validation, which however has improved with recent advances in MRP. In certain cases, MRP may not be possible due to various contraindications for MRI.

CTP is relatively new but has been better validated compared to MRP and is a more widely available modality.<sup>[11],[12]</sup> The major limitation of CTP has been its limited brain coverage. Recent studies have demonstrated the value of improved coverage, which

results in the demonstration of more lesions. <sup>[13]</sup>

Complete brain coverage is useful in cases of lesions located at the margins of the brain, for example, the vertex and posterior fossa. The selection of an appropriate arterial input function has been an issue, which can be resolved with the use of whole brain CTP.

Another advantage of the whole brain CTP is the simultaneous acquisition of the time-resolved CTA information. <sup>[14]</sup> This reduces the radiation dose, contrast volume, and the time for acquisition compared to standard CTA and CTP protocols. This is valuable in the setting of suspected cerebral vasospasm after subarachnoid hemorrhage (SAH), where the vessel diameter and whole brain perfusion need to be assessed simultaneously.

A higher radiation dose has been one of the major concerns in whole brain CTP. <sup>[14]</sup> However, this has to be seen in the light of the fact that both CTA and CTP information can be obtained from the same whole brain CTP study. Moreover, the first volume of whole brain CTP, although not as good as a standard CT scan of the head, can be used as a plain head CT scan study. The poor quality can be compensated by the accompanying CTP information, which is very useful, especially in the case of ischemia. However, using different protocols for whole brain CTP, further reduction of the radiation dose is possible in these clinical situations. <sup>[15]</sup> The average dose for whole brain CTP on a 320-slice scanner is 4.002 mSv. With a modified algorithm, it can be further reduced up to 2.1 mSv. <sup>[15]</sup>

Shading or streak artifacts also known as Feldkamp artifacts may be observed at the edge of the scan region but usually do not affect image interpretation. <sup>[16]</sup> There is a potential pitfall related to the delay between the appearance of the contrast in the lowermost slice as compared to the topmost slice of acquisition. This can potentially cause errors in the calculation of CBV. However, this is usually compensated by the use of delay-insensitive SVD plus nonparametric deconvolution methods.

#### Conclusion

We have highlighted the advantages and new implications of whole brain CTP compared to the limited-slice CT perfusion. Other avenues to harness the potential of whole brain CTP will open up with further experiences in this field. Using different protocols, the radiation dose can also be reduced for whole brain CTP.

#### References

1. Siebert E, Bohner G, Dewey M, Masuhr F, Hoffmann KT, Mews J, *et al*. 320-slice CT neuroimaging: Initial clinical experience and image quality evaluation. *Br J Radiol* 2009;82:561-70. †  
[PUBMED] [FULLTEXT]
2. Pantano P, Baron JC, Samson Y, Bousser MG, Derouesne C, Comar D. Crossed cerebellar diaschisis: Further studies. *Brain* 1986;109:677-94. †  
[PUBMED] [FULLTEXT]
3. Baron JC, Bousser MG, Comar D, Castaigne P. Crossed cerebellar diaschisis in human supratentorial brain infarction. *Trans Am Neurol Assoc* 1980;105:459-61. †
4. Yamada H, Koshimoto Y, Sadato N, Kawashima Y, Tanaka M, Tsuchida C, *et al*. Crossed cerebellar diaschisis: Assessment with dynamic susceptibility contrast MR imaging. *Radiology* 1999;210:558-62. †  
[PUBMED] [FULLTEXT]
5. Shankar JJ, Lum C. Crossed cerebellar diaschisis: Assessment with dynamic contrast imaging on whole brain perfusion on 320 slice CT scanner. *NeuroIntervent Surg* 2009;1:97-8. †
6. Kang KH, Kim HS, Kim SY. Quantitative cerebrovascular reserve measured by acetazolamide-challenged dynamic CT perfusion in ischemic adult moyamoya disease: Initial experience with angiographic correlation. *AJNR Am J Neuroradiol* 2008;29:1487-93. †

7. Takeuchi S, Kikuchi H, Karasawa J, Naruo Y, Hashimoto K, Nishimura T, *et al.* Cerebral hemodynamics in arteriovenous malformations: Evaluation by single-photon emission CT. *AJNR Am J Neuroradiol* 1987;8:2193-7. †
  
8. Shankar JJ, Lum C. Whole brain CT Perfusion in cerebral Arterio-venous malformation- presented in annual meeting of the World Federation of Therapeutic and Interventional Neuroradiology 2009, Montreal, Canada. †
  
9. Mayer SA, Lignelli A, Fink ME, Kessler DB, Thomas CE, Swarup R, *et al.* Perilesional blood flow and edema formation in acute intracerebral hemorrhage a SPECT study. *Stroke* 1998;29:1791-8. †  
[\[PUBMED\]](#) [\[FULLTEXT\]](#)
  
10. Wada R, Aviv RI, Fox AJ, Sahlas DJ, Gladstone DJ, Tomlinson G, *et al.* CT angiography "Spot Sign" predicts hematoma expansion in acute intracerebral hemorrhage. *Stroke* 2007;38:1257-62. †
  
11. Konostas AA, Goldmakher GV, Lee TY, Lev MH. Theoretic basis and technical implementations of CT perfusion in acute ischemic stroke, Part 1: Theoretic basis. *AJNR Am J Neuroradiol* 2009;30:662-8. †  
[\[PUBMED\]](#) [\[FULLTEXT\]](#)
  
12. Konostas AA, Goldmakher GV, Lee TY, Lev MH. Theoretic basis and technical implementations of CT perfusion in acute ischemic stroke, Part 2: Technical implementations. *AJNR Am J Neuroradiol* 2009;30:885-92. †  
[\[PUBMED\]](#) [\[FULLTEXT\]](#)
  
13. Youn SW, Kim JH, Weon YC, Kim SH, Han MK, Bae HJ. Perfusion CT of the brain using 40-mm-wide detector and toggling table technique for initial imaging of acute stroke. *AJR Am J Roentgenol* 2008;191:W120-6. †  
[\[PUBMED\]](#) [\[FULLTEXT\]](#)
  
14. Diekmann S, Siebert E, Juran R, Roll M, Deeg W, Bauknecht HC, *et al.* Dose exposure of patients undergoing comprehensive stroke imaging by multidetector-row CT: Comparison of 320-detector row and 64-detector row CT scanners. *AJNR Am J Neuroradiol* 2010;31:1003-9. †  
[\[PUBMED\]](#)
  
15. Shankar JJ, Lum C, Sharma M. Reduction of radiation dose on whole brain perfusion study by increasing the sampling interval on 320 slice CT scanner. *AJR Am J Roentgenol* 2010;195:1183-6. †  
[\[PUBMED\]](#) [\[FULLTEXT\]](#)
  
16. Mori S, Endo M, Nishizawa K, Murase K, Fujiwara H, Tanada S. Comparison of patient doses in 256-slice CT and 16-slice CT scanners. *Br J Radiol* 2006;79:56-61. †  
[\[PUBMED\]](#) [\[FULLTEXT\]](#)

---

**Correspondence Address:**

Jai Jai Shiva Shankar  
 Department of Diagnostic Imaging, QE II Hospital, Halifax  
 Canada

 Login to access the email ID

DOI: 10.4103/0971-3026.85370

PMID: 22013297



**Figures**


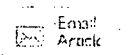

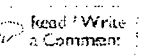

[\[Figure 1\]](#), [\[Figure 2\]](#), [\[Figure 3\]](#), [\[Figure 4\]](#), [\[Figure 5\]](#), [\[Figure 6\]](#), [\[Figure 7\]](#), [\[Figure 8\]](#), [\[Figure 9\]](#)

Tables

[Table 1]

**Take Survey. Win \$50**

OT working with stroke patients? Answer 10 Q's and enter to win gift  
[survey.qualtrics.com/](http://survey.qualtrics.com/) AdChoices ▶

 Download Article (pdf)
  Email Article
  Print Article
  Read & Write a Comment
  Citation Manager

◀ Previous Article  
Next Article ▶

[Contact us](#) | [Sitemap](#) | [Advertise](#) | [What's New](#) | [Feedback](#) | [Copyright and Disclaimer](#)

© 2007 - 2012 Indian Journal of Radiology and Imaging | Published by [Medknow](#)

Online since 10<sup>th</sup> January, 2007

  Open Access  No Fee  RoMEO  W3C HTML 4  W3C CSS  ACAP ENABLED  View mobile site

ISSN: Print -0971-3026, Online - 1998-3808

**Paper-17:**

**Siebert E, Bohner G, Dewey M, Mashur F,  
Hoffmann K T et al: 320-slice CT  
neuroimaging: initial clinical experience and  
image quality evaluation. The British Journal  
of Radiology, 82 (2009), 561-570.**

## 320-slice CT neuroimaging: initial clinical experience and image quality evaluation

<sup>1</sup>E SIEBERT, MD, <sup>1</sup>G BOHNER, MD, <sup>2</sup>M DEWEY, MD, <sup>3</sup>F MASUHR, MD, <sup>1</sup>K T HOFFMANN, MD, <sup>4</sup>J MEWS, <sup>2</sup>F ENGELKEN, MD, <sup>2</sup>H C BAUKNECHT, MD, <sup>1</sup>S DIEKMANN, MD and <sup>1</sup>R KLINGEBIEL, MD

Departments of <sup>1</sup>Neuroradiology, <sup>2</sup>Radiology and, <sup>3</sup>Neurology, Charité University Medicine, Berlin, Germany, and <sup>4</sup>Toshiba Medical Systems, Neuss, Germany

**ABSTRACT.** The aim of this study was to report initial clinical experience with a 320-slice CT scanner and to perform an image quality evaluation. 26 patients with presumptive cerebrovascular pathology underwent 320-slice CT. Single-rotation CT of the head, incremental CT angiography (three-dimensional (3D) CTA) as well as four-dimensional whole-brain CTA (4D CTA) and whole-brain CT perfusion (CTP) were performed and the resulting images were assessed for quality and compared with those obtained with 64-slice CT protocols. 320-slice CT neuroimaging could be performed in all cases. The image quality of 320-slice CT of the head and 3D CTA was inferior to that of the 64-slice protocols. The image quality of 4D 320-slice CTA was rated as inferior to both 320- and 64-slice 3D CTA. 4D CTA-CTP imaging added information with pivotal clinical implications. 320-slice CT neuroimaging is feasible technique that permits whole-brain 4D imaging and has the potential to identify pathologies with altered haemodynamics. However, image quality is a limitation of this technique at present.

Received 8 June 2008  
Accepted 25 September  
2008

DOI: 10.1259/bjr/27721218

© 2009 The British Institute of  
Radiology

Evaluation of cerebrovascular pathology is commonly performed by CT because this modality is widely available and can be carried out rapidly. Since the introduction of multislice CT (MSCT), rapid and comprehensive assessment of the cervicocranial vasculature has become available [1, 2]. Its usefulness in stroke patients has been shown in many studies [1, 3–7]. However, with conventional scanners, acquisition of perfusion data and time-resolved haemodynamic information for the whole brain is limited by the detector width, which is around 2–4 cm in most cases. In CT perfusion (CTP) even elaborate regimens such as the toggling-table technique cannot entirely address this restriction [8]. Recently, 320-slice, cone beam CT, which features a detector width of 16 cm, has been introduced into clinical practice [9]. This new CT technology opens up a whole new arsenal of protocol options that have not yet been described in a clinical setting and that range from a single-rotation whole-brain scan and a cervicocranial three-dimensional CT angiography (3D CTA) using an incremental approach to a four-dimensional (4D), time-resolved whole-brain CTA and perfusion imaging that can be acquired simultaneously.

Here we present a technical and image quality analysis of our preliminary clinical experience.

## Methods and materials

### Patients

26 patients (11 male, 15 female, average age 63 years, range 46–91 years) with clinically suspected cerebrovascular pathology underwent neuroimaging using a 320-slice CT scanner (Aquilion ONE, Toshiba Medical Systems, Nasu, Japan) over a period of 3 months. Written consent was obtained from all patients after the nature and purpose of the procedure had been fully explained. Patients' assignment to the various scanners of our institution (16-, 64- and 320-slice scanners) depended on scanner availability at the time of clinical assessment. The institutional review board provided a waiver for the retrospective analysis of the data.

All patients were referred from the departments of neurology, vascular surgery or emergency medicine for the following symptoms and presumptive diagnoses: acute stroke, early subacute stroke, fluctuating neurological deficits in the setting of chronic internal carotid artery (ICA) occlusion, subacute stroke in the setting of chronic contralateral ICA occlusion, differentiation between potential ICA occlusion and pseudo-occlusion, status of collateral flow and perfusion in the setting of chronic ICA occlusion, aetiological classification of intracranial haemorrhage and exclusion of dissection in patients with cephalgia.

### Scanner

All investigations were performed using a 320-slice CT scanner (Aquilion ONE). It features a detector width of 16 cm with 320 detector rows. The total cone angle is

Address correspondence to: Eberhard Siebert, Department of Neuroradiology, Charité University Medicine Berlin, Charitéplatz 1, 10117 Berlin, Germany. E-mail: eberhard.siebert@charite.de



15.2° for the complete coverage of the detector width. Image reconstruction is performed by using a filtered back-projection (FBP)-type cone beam reconstruction algorithm (ConeXact, Toshiba Medical Systems). This algorithm allows for gantry angulation of 22°. Minimum gantry rotation time is 350 ms. Reconstruction time for a whole data set of 320 rows  $\times$  0.5 mm = 16 cm volume amounts to 10 s.

### Imaging protocols

#### Non-contrast single-rotation CT of the head

Parameters for this protocol are listed in Table 1. Axial scanning took place during one single rotation, resulting in a total scan time of 1.0 s. When the complete detector width was used, a primary DICOM (Digital Imaging and Communications in Medicine) volume of 640 axial slices of 0.5 mm section thickness and 0.25 mm slice increment resulted. Radiation exposure as stated by the software of the console amounted to 39.9 mGy (dose-length product (DLP) 558.7 mGy cm) (these values and the values given below are valid for a scan length of 16 cm).

#### 4D CT angiography

Parameters for this protocol are listed in Table 1. The protocol consisted of two sets of scans: (1) a set of three non-contrast intermittent scans for acquisition of a bone subtraction mask during a total scan time of 3 s (11.2 mGy; DLP 179.3 mGy cm) and (2) a continuous axial scan of 16 s total scan time (59.8 mGy; DLP 956.1 mGy cm) during which the arrival and outflow of a bolus of contrast medium occurred as calculated beforehand by a test bolus protocol at the level of the circle of Willis (parameters: 2 mm slice thickness, 80 kV, 100 mA, rotation time 1.0 s, 20 ml of iodinated contrast medium at 5 ml s<sup>-1</sup> intravenously, chased by 30 ml of saline). For 4D CTA, 40 ml of contrast medium was injected at 5 ml s<sup>-1</sup> chased by 30 ml of saline. A half-scan reconstruction was performed, resulting in an image reconstruction window length of 0.5 s, equivalent to a temporal resolution of 1 s.

#### Combined 4D CTA-CTP

Parameters for this protocol are listed in Table 1. The protocol consisted of three sets of scans: (1) a set of three intermittent scans for acquisition of a bone subtraction mask during a total scan time of 3 s (11.2 mGy; DLP 179.3 mGy cm); (2) a continuous scan with a total scan time of 15 s (56.0 mGy; DLP 896.3 mGy cm) during which arrival of a bolus of contrast medium occurred as

calculated beforehand by a test bolus protocol at the level of the circle of Willis (see 4D CTA); and (3) five intermittent scans, rotation time 0.5 s each, performed every 5 s (18.7 mGy; DLP 298.8 mGy cm). For the 4D CTA-CTP, 40 ml of contrast agent was injected at 5 ml s<sup>-1</sup> chased by 30 ml of saline. Image reconstruction window length and temporal resolution were the same as for 4D CTA.

#### Cervicocranial incremental 3D CTA

Parameters for this protocol are listed in Table 1. The protocol consisted of three steps of axial scans with two steps in between ("step and shoot"). The first scan reached from the aortic arch to the lower neck, the second from the lower neck to the base of skull and the third from the base of skull to the vertex covering the entire brain. Scan time for each axial scan amounted to 0.5 s. The transition time between one axial scan and the next was 1.4 s, resulting in a total scan time of 4.3 s. The scans were started as calculated beforehand by a test bolus protocol at the level of the circle of Willis (see description of 4D CTA) or, alternatively, manually, in which case bolus arrival was noted in a dynamic low-dose scan at the level of the fourth cervical vertebral body. For the 3D CTA, 80 ml of contrast medium was injected at 4 ml s<sup>-1</sup> chased by 30 ml of saline.

#### Conventional CT protocols

In order to perform image quality comparison of head CT and 3D CTA with conventional CT scans, results were compared with those obtained previously on a 64-slice scanner (Aquilion 64, Toshiba Medical Systems). The parameters of the protocols used are listed in Table 2. Contrast administration for 64-slice cervicocranial 3D CTA did not differ from 320-slice cervicocranial 3D CTA.

#### Data transfer and image reconstruction

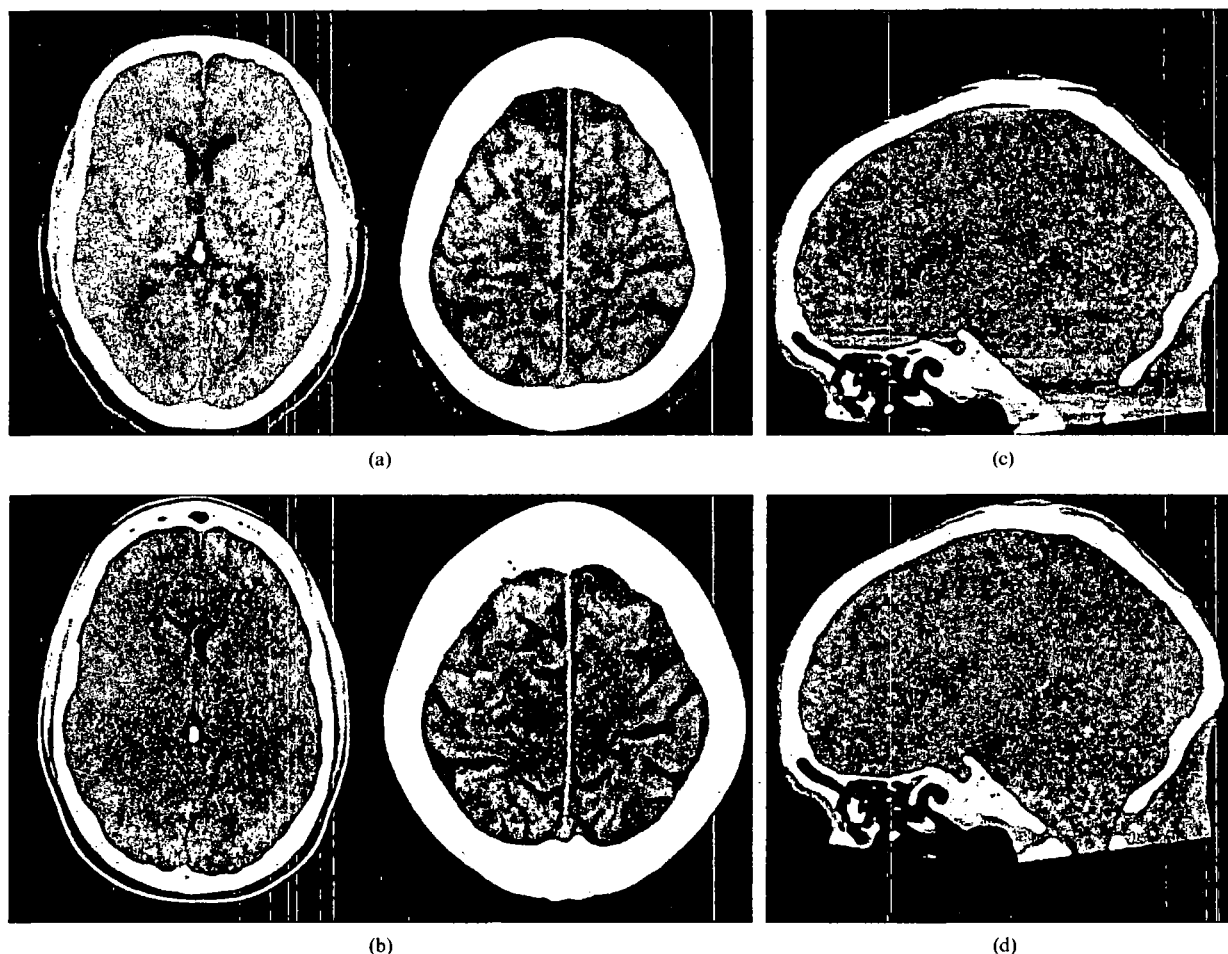
Primary data were reconstructed on the console or on a modified Vitrea workstation upgraded for cone beam CT (Vitrea fx, Version 1.0, Vital Images, Minnetonka, MN). Currently, a limited number of only 8000 images per investigation (corresponding to 25 time points, each 160 MB of image data, when employing a scan length of 16 cm) can be loaded into the software of the console. The time needed for bone subtraction for 4D CTA and 4D CTA-CTP combinations was 4 min  $\pm$  45 s when 25 time points were studied. Generation of perfusion maps using a delay-invariant single-value decomposition algorithm (SVD+, Vital Images, and Toshiba Medical Systems) took approximately 6  $\pm$  1.5 min. These maps were of the

**Table 1.** 320-slice CT protocol parameters

Parameter	Head CT	4D CTA	4D CTA-CTP	3D CTA
Tube voltage (kV)	120	80	80	120
Tube current (mA)	320	100	100	300
Rotation time (s)	1.0	1.0	1.0	0.5
Axial section thickness (mm)	0.5	0.5	0.5	0.5
Reconstruction interval (mm)	0.25	0.5	0.5	0.4

3D, three-dimensional; 4D, four-dimensional; CTA, computed tomography angiography; CTA-CTP, combined 4D CTA computed tomography perfusion.

Neuroimaging by 320-slice CT



**Figure 1.** Comparison of unenhanced CT scans of the head (8 mm axial sections) at the level of the basal ganglia and the high semioval centre. (a) Single rotation 320-slice CT. (b) Incremental 64-slice CT. The image quality of the 64-slice CT concerning the differentiation of grey and white matter is seen to be superior. (c, d) Sagittally reformatted 0.5 mm section of single-rotation 320-slice CT (c) without and (d) with cone beam artefact correction algorithm. Note the substantially reduced artefacts in the posterior fossa.

enhanced DICOM format, which is as yet incompatible with many currently available picture archiving and communication systems (PACS); thus, they can only be viewed on the console or exported separately as snapshots or as standard DICOM images (which cannot be re-used for time-resolved post-processing). Perfusion maps for the parameters mean transit time (MTT), time to peak (TTP), cerebral blood flow (CBF), cerebral blood volume (CBV) and a delay map were generated by the

perfusion software. Each of these parametric maps consisted of 320 images with a section thickness of 0.5 mm (for a scan length of 16 cm). This allowed for various post-processing options, such as volume rendering, maximal intensity projection and multiplanar reformation of the parametric maps. The 4D CTA information could be post-processed to multiplanar reformatted images, maximum intensity projections and volume-rendered images. Here, time-resolved sequences of these post-processed images could be saved as DICOM series, exported and archived.

**Table 2.** 64-slice CT protocol parameters

Parameter	Head CT	3D CTA <sup>ver</sup>
Tube voltage (kV)	120	120
Tube current (mA)	250	300
Rotation time (s)	1.0	0.5
Pitch	Incremental	0.61
Axial section thickness (mm)	4 and 8	0.5
Reconstruction interval (mm)	4 and 8	0.4

**Qualitative image evaluation**

Qualitative image evaluation was performed by two experienced neuroradiologists in consensus. The readers were blinded to patient and technical information as far as possible. A five-point (1–5) visual analogue scale was employed, with 5 being the best and 1 being the worst image quality.

A total of 38 non-contrast CT scans of the head from 38 different patients (19 investigations each for 320-slice CT

and 64-slice CT) were evaluated. Image quality assessment was performed on 8 mm slices for both groups. Scrolling through the whole scan was mandatory. The readers were asked to concentrate on the following image quality factors: image noise, artefacts, grey matter–white matter conspicuity, subarachnoid space sharpness, ventricular margins and distinctness of the posterior fossa contents. Furthermore, the ability of the cone beam artefact correction algorithm (CLAC) to reduce artefacts in the 320-slice head CT scans was evaluated by comparing sagittal images before and after submitting the data sets to the CLAC algorithm on a visual five-point analogue scale for artefacts ranging from 1 (non-diagnostic owing to severe artefacts) to 5 (no artefacts).

A total of 20 cervicocranial 3D CTA scans from 20 different patients (10 investigations each for 320-slice CT and 64-slice CT) were evaluated. Image quality was assessed with a particular focus on the delineation of the arterial vessels and the presence of artefacts on a five-point visual analogue scale (with 5 being the best and 1 being the worst image quality). The following arterial vessel categories were analysed and evaluated: cervical (vertebral and carotid arteries), large intracranial (M1—middle cerebral artery (MCA), basilar artery (BA)); P1—posterior cerebral artery (PCA); and A1—anterior cerebral artery (ACA)), medium intracranial (M2, A2/3, P2/3) and small intracranial (M3–4, A4–5 and P4, ophthalmic artery).

15 intracranial 4D CTA scans from 15 different patients were evaluated in the same way as the intracranial parts of 3D CTA scans. The time point of the arterial contrast peak was chosen as the time point for the evaluation. Furthermore, the quality of bone subtraction was evaluated on a visual five-point analogue scale, with 1 being inadequate and 5 being excellent bone subtraction.

Window and level settings were standardised for the initial reviews, but individual adjustment was allowed. The reading was performed by using soft-copy images on a PACS workstation.

### Quantitative image evaluation

For analysis of the non-contrast CTs of the head, three small (1–5 mm<sup>2</sup>) representative regions of interest (ROIs) were chosen in identical neuroanatomical locations, *i.e.* the caudate nucleus for subcortical GM, the hand area of the motor cortex for cortical GM and central WM inferior to the motor cortex, similar to that described by Mullins and colleagues [10]. Careful attention was paid to avoid volume-averaging effects from blood vessels, sulci and cisterns, as well as between GM and WM. ROI values

were measured in Hounsfield units (HU)  $\pm$  standard deviation (SD). Contrast-to-noise ratio:

$$\frac{[(ROI\ GM - ROI\ WM)]}{[(SD\ ROI\ WM)^2 + (SD\ ROI\ GM)^2]} \quad (1)$$

was defined as described previously [10]. On all scans only regions not affected by pathological findings were included into the qualitative and quantitative image evaluation.

### Statistical evaluation

Comparisons of qualitative image evaluation were performed by using a Mann–Whitney rank-sum test. Comparisons of quantitative image evaluation criteria were performed by using a *t*-test. A significance level of  $p < 0.05$  was considered significant. Values are expressed as mean  $\pm$  SD.

## Results

### Feasibility and time requirements

All investigations using the 320-slice CT could be performed successfully. Although some patients were only moderately compliant, no significant motion artefacts were encountered on non-contrast single-rotation CT scans of the head. Procedural times required for the incremental and single-rotation techniques were significantly shorter than for conventional CT studies: data acquisition for cranial CT took 2 s for 320-slice CT compared with 30 s for conventional CT, and data acquisition for cervicocranial CTA took 5 s for 3D 320-slice CTA compared with 12 s for conventional CT. Preparation times due to patient positioning, protocol adjustment, scanogram and circulation time measurement were identical. However, for the dynamic protocols (4D CTA and 4D CTA-CTP combination) post-processing times reached up to 10 min using 320-slice data.

### Image quality of CT of the head

When employing the milliamperes product of the 64-slice head CT (250 mA) for the 320-slice head CT, the consensus was that images were of non-diagnostic quality (data not shown). Thus, the milliamperes product was increased by increasing the tube current to 320 mA (rotation time 1 s) until quantitative image quality criteria, such as density values for grey and white matter, CNR and GM conspicuity, no longer differed

**Table 3.** Quantitative image quality criteria for non-enhanced CT of the head

SD GM		SD WM		CNR	
320	64	320	64	320	64
2.13 $\pm$ 0.61	2.40 $\pm$ 0.99	2.17 $\pm$ 0.71	1.83 $\pm$ 0.67	4.02 $\pm$ 1.06	3.91 $\pm$ 1.92
$p = 0.511$		$p = 0.17$		$p = 0.35$	

Results are expressed as the mean  $\pm$  SD.

CNR, contrast-to-noise ratio; GM, grey matter; ROIs, regions of interest; SD GM, standard deviation of Hounsfield units in grey matter ROIs; SD WM, standard deviation of Hounsfield units in white matter.

### Neuroimaging by 320-slice CT

significantly between the two modalities (Table 3). Nevertheless, the image quality of the non-contrast single-rotation 320-slice CT scan was judged in consensus readings to be inferior to that of the non-contrast 64-slice incremental CT scans:  $3.0 \pm 0.8$  compared with  $4.0 \pm 0.4$  ( $p < 0.001$ ) (Figure 1 a, b).

Artefacts, most likely due to beam hardening, were frequently observed at the junction of the calvaria and brain. Often, this reduced differentiation between grey and white matter. These artefacts were particularly pronounced at the skull base and were judged to impede image evaluation at least as much as artefacts at the skull base and posterior fossa on conventional CT images. However, these skull base artefacts could be significantly reduced by applying an additional CLAC (Toshiba Medical Systems). On a visual analogue scale for artefact, application of CLAC resulted in a score of  $3.9 \pm 0.3$ ; by comparison, studies without CLAC scored  $1.8 \pm 0.5$  ( $p < 0.001$ ) (Figure 1c,d). However, even with the CLAC algorithm, ring artefacts were noted in the majority of cases. Furthermore, regional differences in image contrast were frequently found to lead to a reduction in image quality in these areas. 320-slice CT was reconstructed primarily as axial 0.5-mm sections. As signal-to-noise ratio (SNR) was poor, we could not recommend these images for primary study, except to rule out partial volume effects.

### Image quality of the cervicocranial 3D CTA

Table 4 summarises the image quality findings for the cervicocranial 3D CTA scans. For all vessel categories (i.e. cervical and large, medium and small intracranial arteries) image quality of 64-slice CTA was judged to be significantly superior to that of 320-slice CTA ( $p < 0.04$  to  $p < 0.001$ ) (Figure 2). In particular, the small arteries were significantly ( $p < 0.001$ ) better visualised by 64-slice 3D CTA.

Static structures, such as bone, at the borders of prospectively acquired shots of the 320-slice 3D CTA nearly always showed a slight shift of up to 2 mm secondary to geometric distortion (Figure 3a,b). Pulsatile structures at the borders of prospectively acquired shots, such as arterial vessels, sometimes showed a more pronounced shift than the accompanying static structures, which is probably due to pulsation artefacts (Figure 3c). In particular, the lowest shot at the level of the aortic arch was usually affected by serious artefacts from the shoulders being more pronounced than with 64-slice CT (Figure 3a). In addition, regional differences in image contrast were frequently seen on the 320-slice 3D CTA scans, especially at the level of the skull base, which resulted in reduced vessel visibility at this level.

### Image quality of the 4D CTP-CTA protocols

Image quality findings for the 320-slice intracranial 4D CTA with respect to the different vessel categories are summarised in Table 5. The image quality of the intracranial 4D 320-slice CTA images for all arterial vessel size categories (large, medium and small) was rated as significantly inferior to that of images of

intracranial compartments obtained by 3D 320-slice CTA as well as by 64-slice CTA. The quality of bone subtraction was judged to amount to  $3.1 \pm 1.5$  on a five-point visual analogue scale. Results ranged from 1 to 5 and were strongly dependent on patient co-operation. Incomplete bone subtraction occurred, particularly at the skull base and the vertex. This did not reduce the diagnostic yield of the primary images but substantially reduced the quality of the whole-brain maximum intensity projections (MIPs).

As a result of the isotropic voxel acquisition, whole-brain perfusion maps could be displayed either as multiplanar reformatted images (MPRs; Figure 4a) or as 3D surface-rendered whole-brain views (Figure 4b). Time-resolved CTA proved to be especially beneficial for elucidating cerebrovascular haemodynamics, such as in patients with ICA occlusion or cerebrovascular malformation (Figure 5).

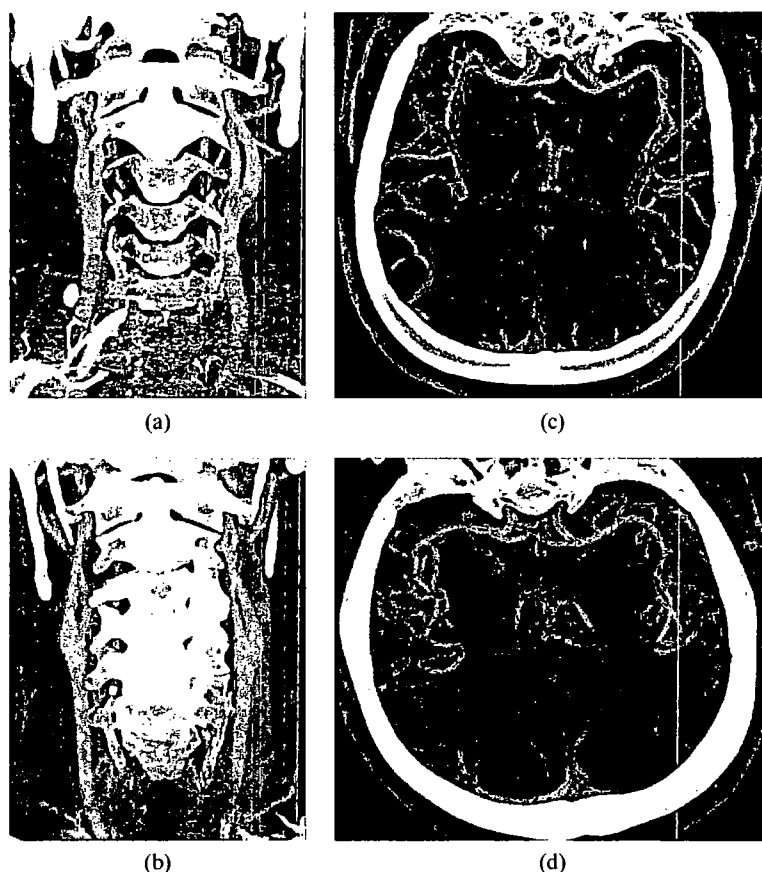
### Patients

Final diagnoses as stated in the discharge letters were acute hypertensive putaminal haemorrhage, acute subcortical haemorrhage due to a previously asymptomatic, superficially draining, arteriovenous malformation (AVM), AVM with deep venous drainage, acute temporal haemorrhage secondary to warfarin treatment (international normalised ratio (INR) 3.5), chronic occlusions of the ICA with statement concerning sufficient and insufficient collateralisation and hemispheric perfusion, exclusion of lacunar stroke, acute stroke in the territory of the MCA and basilar tip occlusion.

### Discussion

From a technical point of view, all investigations were carried out successfully, indicating that 320-slice CT is a feasible and robust neuroimaging method for the comprehensive assessment of cerebrovascular pathology. However, we observed a noticeable degradation of image quality when using conventional multislice scanning techniques, such as non-contrast CT of the head and cervicocranial 3D CTA. This is most likely a result of an increase in scattered radiation, which causes greater density value deviations (i.e. higher noise levels) and reduction in SNR [11–13]. Non-contrast CT images of the head were not of diagnostic quality when the tube current was identical to that used for 64-slice non-contrast CT of the head. Thus, we increased the tube current until objective image quality criteria, such as CNR, did not show any significant differences when compared with 64-slice investigations. With cervicocranial 3D CTA, reduced image quality of the 320-slice CT scans resulted in a significantly inferior depiction of all arteries (i.e. cervical arteries and large, medium and small intracranial arteries) compared with 64-slice studies.

Our findings are in contrast to the results of Mori and colleagues [12], who reported good image quality using a prototype 256-slice scanner. However, they did not compare image quality with that achieved using a conventional state-of-the-art 64-slice CT scanner.



**Figure 2.** Comparison of cervicocranial three-dimensional CT angiography (3D CTA) image quality. (a,b) Paracoronal thick-slab maximum intensity projections (MIPs) of the carotid arteries. (c,d) Para-axial thick-slab MIPs of the middle cerebral arteries (MCAs). (a,c) 320-slice step-and-shoot incremental 3D CTA. (b,d) Spiral 64-slice 3D CTA. An inferior image quality of the cervicothoracic region is seen on 320-slice CTA, as well as an inferior delineation of the small intracranial MCA-branches in particular.

Furthermore, they used a 256-detector-row scanner, whereas we used a 320-slice scanner with an even larger detector collimation of 16 cm. This requires a broader cone angle, which is likely to increase scattered radiation and to cause image degradation [11–13]. Another important observation is that we encountered pronounced artefacts at the convexity of the skull, which limited the assessability of the adjacent grey matter. However, skull base artefacts could be substantially reduced by an additional CLAC. In the near future, this algorithm will run automatically during image reconstruction. Further research to improve the not yet perfect image reconstruction algorithms is under way, and is likely to result in a further improvement in 320-slice CT

image quality. Furthermore, the scanner will soon be equipped with a spiral mode that allows for collimation, e.g. 64 detector rows. Spiral mode scanning reduces the cone angle and thus scattered radiation. Spiral scanning with 256-slice CT is reported to suppress Feldkamp artefacts while the complete data required for exact reconstruction of a volume are collected [11, 13]. This should lead to an improvement in the image quality of investigations that can be performed in a spiral mode, such as 3D CTA.

In the cervicocranial incremental 3D CTA, three shots had to be applied to cover the distance from the aortic arch to the vertex. This resulted in three data sets that were automatically fused after reconstruction. At the borders of these images, we have regularly noticed a slight spatial shift of 1–2 mm, which is most likely attributable to geometric distortion. In arterial structures shifts secondary to pulsation could be encountered. This may lead to diagnostic insecurity and prompt further investigations, e.g. when dissections have to be excluded. Furthermore, with the current 320-slice system it is impossible to apply different parameter settings to different shots without a time delay of less than 5 s, rendering it impossible for the lowest scan step at the shoulder girdle level to apply more milliamperes for image quality improvement.

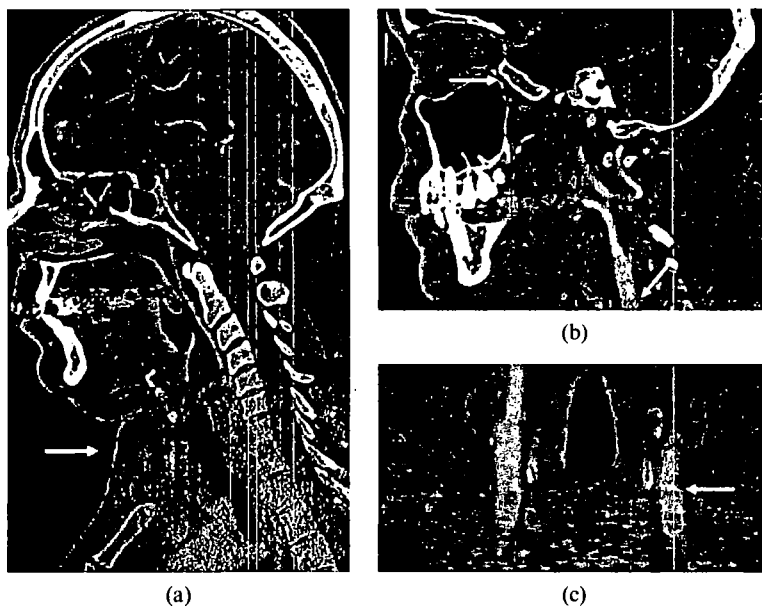
To reduce radiation exposure in whole-brain 4D CTA and perfusion continuous scanning, a tube voltage of only 80 kV is applied (with higher iodine efficiency) in combination with a tube current of 100 mA. This leads to

**Table 4.** Image quality scores (mean  $\pm$  SD) and results of statistical evaluation for cervicocranial 320-slice and 64-slice 3D CTA

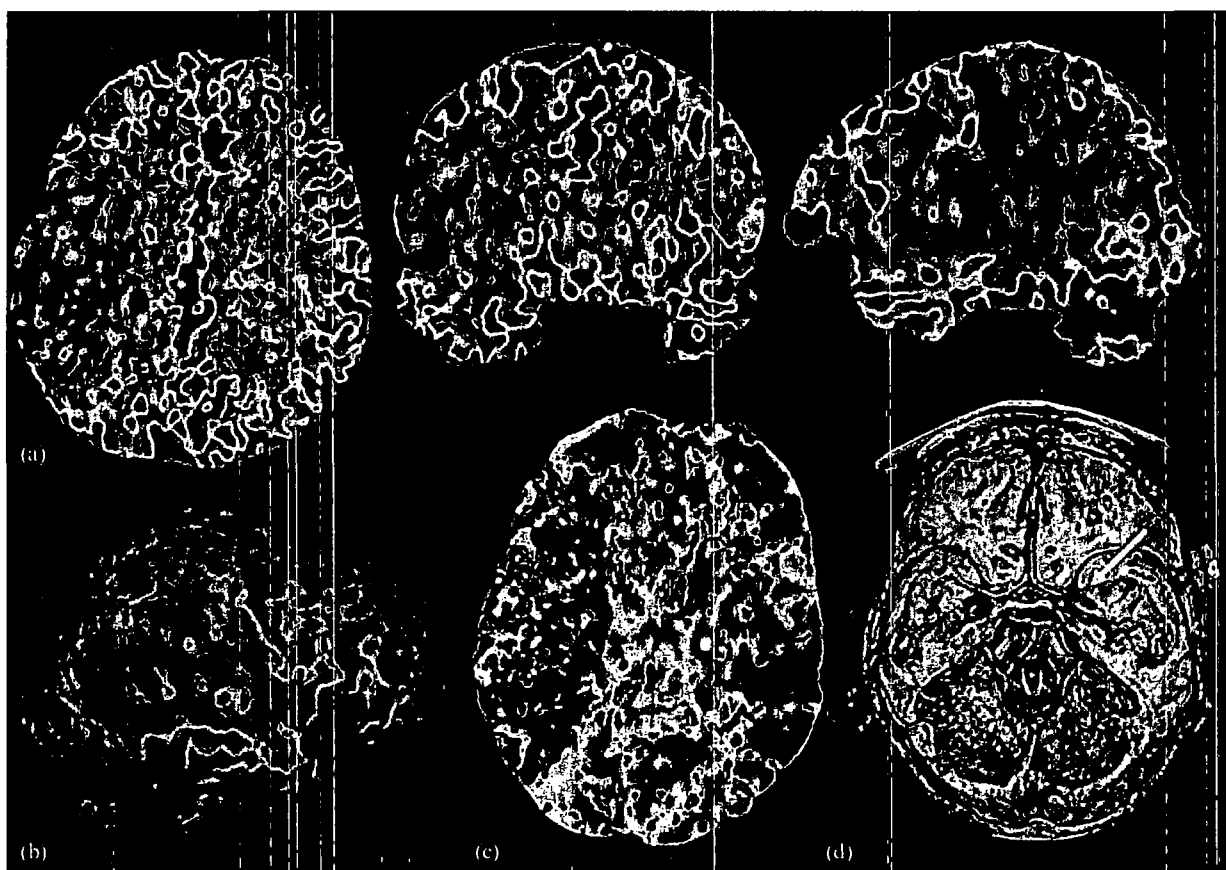
Category	3D 320 CTA	3D 64 CTA	Test result
Cervical artery	3.3 $\pm$ 0.8	4.2 $\pm$ 0.5	$p = 0.03$
Intracranial artery			
Large	4.4 $\pm$ 0.6	4.8 $\pm$ 0.4	$p = 0.04$
Medium	4.2 $\pm$ 0.6	4.7 $\pm$ 0.6	$p = 0.01$
Small	3.0 $\pm$ 0.5	3.9 $\pm$ 0.3	$p < 0.001$

3D 320 CTA, three-dimensional 320-slice CT angiography; 3D 64 CTA, three-dimensional 64-slice CT angiography; SD, standard deviation.

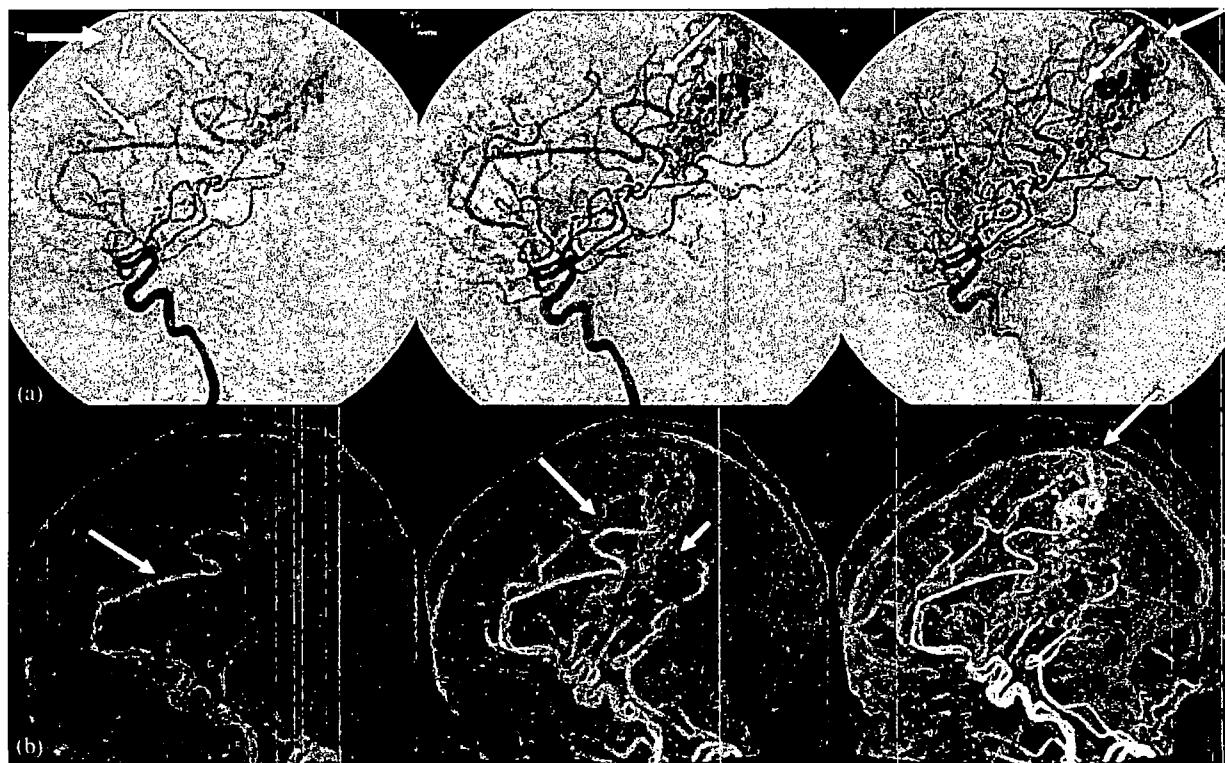
Neuroimaging by 320-slice CT



**Figure 3.** Frequently encountered artefacts in 320-slice cervicocranial 3D CTA. (a) Decreased image quality of the lowest shot at the shoulder girdle level (arrow). (b) Shift of structures at the end of scans due to geometric distortion (arrows). (c) In arterial structures, this can be clearly pronounced, probably as a result of pulsation (arrow).



**Figure 4.** (a) Regional cerebral blood volume (rCBV) parameter maps in axial, coronal and sagittal orientation and (b) a lateral view of a volume-rendered CBV parameter map. Both illustrations show the area of irreversible ischaemia as revealed by CBV reduction. (c) Axial mean transit time parameter map indicating no significant penumbra when compared with the CBV information. (d) 3D CT angiography surface-rendered image showing distal internal carotid occlusion and no significant leptomeningeal collateralisation.



**Figure 5.** Sagittal whole-brain maximum intensity projection 4D CTA series (b) compared with a sagittal digital subtraction angiography projection (a) in a patient with acute intracerebral haemorrhage. An abnormally strong right pericallosal and callosomarginal artery are depicted feeding an aneurysmal nidus of a superficially draining arteriovenous malformation (arrows). On the second arterial image, a faint cortical venous contrast can be seen that becomes more pronounced at later time points (upper arrows in right column). As a consequence of the shunt, the draining cortical vein, as well as the superior sagittal sinus, are arterialised. The short arrow indicates smaller feeding branches of the right posterior cerebral artery. The thick arrow indicates the temporal axis.

a significantly reduction in image quality of the 4D CTA compared with the 3D CTA studies (120 kV, 300 mA) with both scanner types (320-slice and 64-slice). Thus, evaluation of medium-size and small intracranial arteries, in particular, is limited.

In the setting of acute stroke, but also in the setting of chronic steno-occlusive disease, a major drawback of conventional CT scanning is the inability to perform image perfusion of the whole brain. Even with special protocols, such as the toggling-table technique, this limitation cannot be overcome entirely, as the best it is possible to achieve is a doubling of the investigated volume [8]. Furthermore, such a regimen is achieved at

the expense of temporal resolution, which is as low as one image every 3–5 s [8]. Other approaches consist of consecutive scanning of distinct sections, leading to prolongation of the investigation and an increase in the amount of contrast medium required due to repeated runs [3]. This limitation has now been overcome by volumetric, time-resolved whole-brain imaging using 320-slice CT. Until now, there has been only one report of an experimental whole-brain perfusion study, using 256-slice CT in pigs [14]. Although the clinical usefulness of whole-brain perfusion is still to be evaluated, it is likely that the sensitivity of CTP will increase, especially with respect to ischaemic lesions in the upper brain regions,

**Table 5.** Image quality scores (mean  $\pm$  SD) and results of statistical evaluation for 320-slice 4D CTA in comparison with the 320-slice 3D CTA and 64-slice 3D CTA

Category	4D 320 CTA	3D 320 CTA	3D 64 CTA	Test result
Large	3.0 $\pm$ 0.7	4.4 $\pm$ 0.6	4.8 $\pm$ 0.4	$p < 0.001$ ; $p < 0.001$
Medium	2.3 $\pm$ 0.7	4.2 $\pm$ 0.6	4.7 $\pm$ 0.6	$p < 0.001$ ; $p < 0.001$
Small	1.3 $\pm$ 0.6	3.0 $\pm$ 0.5	3.9 $\pm$ 0.3	$p < 0.001$ ; $p < 0.001$

The first  $p$ -value refers to the comparison of 320-slice 4D CTA with 320-slice 3D CTA and the second  $p$ -value refers to the comparison of the 320-slice 4D CTA with the 64-slice 3D CTA.

3D 320 CTA, three-dimensional 320-slice computed tomography angiography; 3D 64 CTA, three-dimensional 64-slice computed tomography angiography; 4D 320 CTA, four-dimensional 320-slice computed tomography angiography.

*Neuroimaging by 320-slice CT*

for example the juxtacortical semioval centre and the frontoparietal cortex, which are usually not included in the perfusion scan at the basal ganglia level determined by one detector width. The same considerations also apply to infratentorial ischaemic lesions, which are regularly hard to track with CTP. However, further and, in particular, larger clinical trials are necessary to address this important question in detail.

As illustrated here, volumetric whole-brain perfusion imaging provides superior spatial resolution to conventional parametric maps, being as high as 0.5 mm along the z-axis. This permits the application of various post-processing algorithms such as multiplanar reformatting, maximal intensity projections and 3D volume rendering of source and parameter data [11, 14]. Higher spatial resolution will probably enable detection of smaller lesions. Whether lacunar ischaemic lesions will become detectable has to be determined in further studies, ideally by comparing CT images with diffusion-weighted MRI sequences from the same individual [15]. All we can say here is that we were able to apply perfusion imaging for the evaluation of collateral supply in the setting of steno-occlusive disease. Furthermore, we were able to perform perfusion imaging successfully in patients with territorial stroke.

To date only CTP has been used for visualisation and quantification of processes involving haemodynamic alterations or collateral flow. Cervicocranial 3D CTA using 64-Detector-row scanners has been found to be able to distinguish the arterial from venous phase according to the bolus timing only approximately; other signs were indirect, such as vessel calibre and vessel density in comparison with other vessels or the contralateral side [16, 17]. One study investigated ECG-triggered reconstruction of phase-resolved CTA and the usefulness of this in visualising the pulsation of aneurysms, enabling rupture sites to be determined as the spot of pronounced wall thinning and pulsation [18]. At present, CT cannot provide whole-brain dynamic angiographic information, making it difficult to assess reduction in circulation times caused by shunting vascular disorders, venous arteria- lisation or prolongation of venous outflow in the setting of venous occlusions, especially cortical vein thromboses. It may now be possible to address all of these issues, directly and dynamically, using whole-brain 4D CTA. In the assessment of the haemodynamic relevance of steno-occlusive disease, this technique allows the delay of the dependent territory, as well as direction and velocity of collateral flow, to be determined. This provides information that was previously obtainable only by invasive digital subtraction angiography (DSA), which is well known to be associated with procedural risks such as silent and symptomatic ischaemia with persistent neurological deficits [19–21]. Further potential applications include non-invasive monitoring of vasospasms after subarachnoid haemorrhage and brain tumour perfusion.

When applying dynamic whole-brain imaging, further issues need to be discussed. The temporal resolution depends on the rotation time of the system and the reconstruction technique. The temporal resolution chosen by us was 1 s per image, applying a rotation time of 1 s and half-scan reconstructions (image reconstruction window length 0.5 s). SNR could be improved by performing full-scan reconstructions, but at the expense

of a reduced temporal resolution. On the other hand, rotation time could be increased to a maximum of 0.35 s at the expense of tripling the patient's radiation exposure. Thus, theoretically, a temporal resolution of nearly three images per second could be achieved, which would be sufficient for most angiographic applications. However, the number of data sets would increase proportionally, exceeding the post-processing capabilities of the available workstations. Another limitation is the absence of vascular selectivity due to peripheral intravenous contrast medium injection.

Radiation exposure when comparing investigations using identical tube currents, voltage and rotation times was found to be lower in cone beam CT than in 16-slice CT [12]. This finding can be explained by the fact that a large cone angle leads to a smaller contribution of overbeaming to the total dose and the fact that no over-ranging for helical acquisitions is encountered [12].

According to the manufacturer's phantom measurements, radiation exposure during the dynamic whole-brain 4D CTA-CTP combined protocol amounts to 5–6 mSv. The calculated effective dose, the product of DLP and the ICRP factor for the head ( $2355.4 \text{ mGy cm}$ ,  $k = 0.0023 \text{ mSv mGy}^{-1} \text{ cm}^{-1}$ ), is 5.4 mSv, which is in line with the exposure of conventional CTP published in the literature [22]. However, whole-brain coverage and 4D CTA are likely to deliver additional information that may justify increased radiation exposure.

This new-generation CT scanner also requires greater infrastructure. Parametric maps have enhanced DICOM format, a fact that may present problems to a conventional PACS. Image reconstruction requires high-end computers to process the extremely large amounts of information associated with a comprehensive neuroimaging procedure. A protocol combining CT of the head, cervicocranial 3D CTA and 4D CTA-CTP produces approximately 10 000 DICOM images (equal to 5 GB). This explains the relatively long reconstruction times for 4D CTA and perfusion maps of 10 min, which is close to the upper limit of being clinically useful in the acute stroke setting. Finally, a substantial number of images need to be archived or transferred via network connections to workstations.

## Conclusions

Comprehensive neuroimaging of cerebrovascular pathology using 320-slice CT is a feasible and robust method. For the first time dynamic whole-brain imaging can be performed by CT, increasing the potential to delineate pathologies that alter cerebral haemodynamics. However, further (at best, controlled) studies are necessary to assess the clinical impact of this promising new method. A drawback is the inferior image quality of single-rotation and incremental protocols compared with conventional 64-slice protocols. This is likely to improve as this novel tool is being further perfected. In order to overcome the limitations of single-rotation CT and incremental cervicocranial 3D CTA, the scanner will be equipped with a spiral mode and a 64 row  $\times$  0.5 mm collimation to overcome the limitation of the single-rotation CT and incremental cervicocranial 3D CTA.



The improved infrastructure that is required to cope with the large amount of data and relatively long reconstruction times at present are further issues to be considered.

## References

1. Klingebiel R, Busch M, Bohner G, Zimmer C, Hoffmann O, Masuhr F. Multi-slice CT angiography in the evaluation of patients with acute cerebrovascular disease—a promising new diagnostic tool. *J Neurol* 2002;249:43–9.
2. Wintermark M. Brain perfusion-CT in acute stroke patients. *Eur Radiol* 2005;15 Suppl 4:D28–31.
3. Mayer TE, Hamann GF, Baranczyk J, Rosengarten B, Klotz E, Wiesmann M, et al. Dynamic CT perfusion imaging of acute stroke. *AJNR Am J Neuroradiol* 2000;21:1441–9.
4. Schramm P, Schellinger PD, Fiebach JB, Heiland S, Jansen O, Knauth M, et al. Comparison of CT and CT angiography source images with diffusion-weighted imaging in patients with acute stroke within 6 hours after onset. *Stroke* 2002;33:2426–32.
5. Schellinger PD, Fiebach JB. Value of modern CT-techniques in the diagnosis of acute stroke. *Radiologe* 2004;44:380–8.
6. Elijovich L, Kazmi K, Gauvrit JY, Law M. The emerging role of multidetector row CT angiography in the diagnosis of cervical arterial dissection: preliminary study. *Neuroradiology* 2006;48:606–12.
7. Tan JC, Dillon WP, Liu S, Adler F, Smith WS, Wintermark M. Systematic comparison of perfusion-CT and CT-angiography in acute stroke patients. *Ann Neurol* 2007;61:533–43.
8. Roberts HC, Roberts TP, Smith WS, Lee TJ, Fischbein NJ, Dillon WP. Multisection dynamic CT perfusion for acute cerebral ischemia: the “toggling-table” technique. *AJNR Am J Neuroradiol* 2001;22:1077–80.
9. Dewey M, Zimmermann E, Laule M, Rutsch W, Hamm B. Three-vessel coronary artery disease examined with 320-slice computed tomography coronary angiography. *Eur Heart J* 2008;29:1669.
10. Mullins ME, Lev MH, Bove P, O’Reilly CE, Saini S, Rhea JT, et al. Comparison of image quality between conventional and low-dose nonenhanced head CT. *AJNR Am J Neuroradiol* 2004;25:533–8.
11. Mori S, Endo M, Obata T, Murase K, Fujiwara H, Susumu K, et al. Clinical potentials of the prototype 256-detector row CT-scanner. *Acad Radiol* 2005;12:148–54.
12. Mori S, Endo M, Nishizawa K, Murase K, Fujiwara H, Tanada S. Comparison of patient doses in 256-slice CT and 16-slice CT scanners. *Br J Radiol* 2006;79:56–61.
13. Mori S, Endo M, Obata T, Tsunoo T, Susumu K, Tanada S. Properties of the prototype 256-row (cone beam) CT scanner. *Eur Radiol* 2006;16:2100–8.
14. Mori S, Obata T, Nakajima N, Ichihara N, Endo M. Volumetric perfusion CT using prototype 256-detector row CT scanner: preliminary study with healthy porcine model. *AJNR Am J Neuroradiol* 2005;26:2536–41.
15. Ahlhelm F, Schneider G, Backens M, Reith W, Hagen T. Time course of the apparent diffusion coefficient after cerebral infarction. *Eur Radiol* 2002;12:2322–9.
16. Tanebe S, Uede T, Nonaka T, Ohtaki M, Hashi K. Diagnosis of cerebral arteriovenous malformations with three-dimensional CT angiography. *J Clin Neurosci* 1998;5(Suppl):33–8.
17. Osborn A. *Diagnostic Imaging: Brain*. 1st edition. Salt Lake City, UT: Amirsys: I.5.4.
18. Hayakawa M, Katada K, Anno H, Imizu S, Hayashi J, Irie K, et al. CT angiography with electrocardiographically gated reconstruction for visualizing pulsation of intracranial aneurysms: identification of aneurysmal protuberance presumably associated with wall thinning. *AJNR Am J Neuroradiol* 2005;26:1366–9.
19. Bendszus M, Koltzenburg M, Burger R, Warmuth-Metz M, Hofmann E, Solymosi L. Silent embolism in diagnostic cerebral angiography and neurointerventional procedures: a prospective study. *Lancet* 1999;354:1594–7.
20. Dawkins AA, Evans AL, Wattam J, Romanowski CA, Connolly DJ, Hodgson TJ, et al. Complications of cerebral angiography: a prospective analysis of 2,924 consecutive procedures. *Neuroradiology* 2007;49:753–9.
21. Kaufmann TJ, Huston J 3rd, Mandrekar JN, Schleck CD, Thielen KR, Kallmes DF. Complications of diagnostic cerebral angiography: evaluation of 19,826 consecutive patients. *Radiology* 2007;243:812–19.
22. Cohnen M, Wittsack HJ, Assadi S, Muskalla K, Ringelstein A, Poll LW, et al. Radiation exposure of patients in comprehensive computed tomography of the head in acute stroke. *AJNR Am J Neuroradiol* 2006;27:1741–5.

3/10/2015 10:11 AM

**Paper-18:**

**Tekşam M, Çakır B, Coşkun M: CT perfusion  
imaging in the early diagnosis of acute stroke.  
Diagn. Interv. Radiol 2005; 11:202-205**

# CT perfusion imaging in the early diagnosis of acute stroke

Mehmet Tekşam, Banu Çakır, Mehmet Coşkun

## ABSTRACT

Early diagnosis of acute cerebral infarction is critical due to the time limit of thrombolytic treatment. Cerebral computed tomography (CT) perfusion imaging is a new technique, which appears to provide early diagnosis of major vessel occlusions in the brain. CT perfusion imaging also provides valuable information about the hemodynamic status of ischemic brain tissue. In this report, we present the CT perfusion findings in comparison to the non-contrast CT and diffusion-weighted (DW) magnetic resonance (MR) imaging findings in two cases of acute cerebral infarction. Non-contrast CT findings were non-specific in the first case and there was minimal hypoattenuation in the superior aspect of the lentiform nucleus in the second case. CT perfusion imaging demonstrated significant perfusion defects in the middle cerebral artery territory in both cases. DW-MR imaging confirmed acute infarctions, which were smaller than the perfusion defect areas in the CT perfusion imaging in both cases.

**Key words:** • cerebral infarction • tomography, X-ray computed • perfusion • diffusion magnetic resonance imaging

Stroke is the third most frequent cause of deaths after cardiovascular diseases and cancers (1, 2). However, prognosis can be good if thrombolytic therapy is administered to patients within the first three hours (3, 4). Computed tomography (CT) is generally performed before starting the therapy in order to exclude the presence of bleeding and tumors. With cerebral perfusion imaging, it is possible to diagnose ischemia early, as well as gather information about the extension and severity of the ischemia. In this article, we will discuss the perfusion brain CT findings in two cases of acute ischemic stroke in which non-contrast brain CT findings were not specific in the early period.

## Case reports

### Case 1

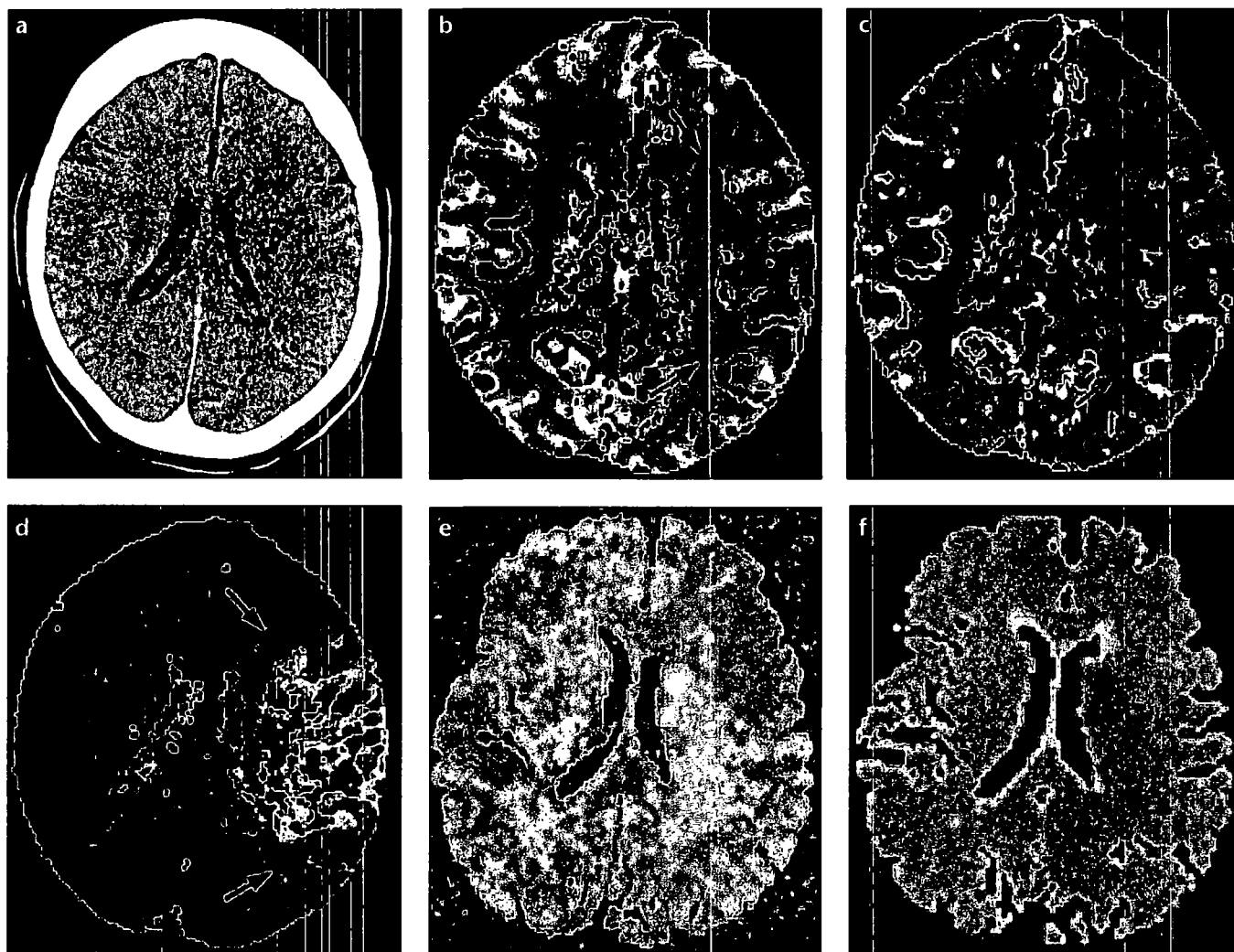
A 71-year-old female presented to the emergency service of our hospital with complaints of loss of strength in the right side of her body and inability to speak, which had started 3.5 hours earlier. Right hemiparesis was found in neurological examination. In the non-contrast brain CT performed with the pre-diagnosis of cerebrovascular incident, no marked pathology was observed except for diffuse cerebral and cerebellar atrophy (Figure 1a). Following the non-contrast brain CT, a perfusion brain CT examination was performed. Brain perfusion examination was performed using a CT device (Somatom Sensation 16, Siemens Medical Systems, Erlangen, Germany) with 16 detectors and an automatic injector, giving a total of 40 ml of non-ionic iodinated contrast material with a speed of 8 ml/sec. Sections 10 mm thick from two neighbouring sections (60 sections from basal ganglia level and 60 sections from corona radiata level) were obtained. The source images were then sent to a separate computer system for postprocessing (Leonardo, Siemens Medical Systems, Erlangen, Germany). Relative cerebral blood flow, relative cerebral blood volume, and perfusion images of time to peak were obtained with a semi-automatic procedure. Wide perfusion defects were found in the feeding region of the left middle cerebral artery (Figure 1b-d). In the diffusion-weighted magnetic resonance (MR) examination performed about 24 hours later, using echo-planar imaging technique with  $b=0$  s/mm<sup>2</sup> and  $b=1000$  s/mm<sup>2</sup> (TR/TE, 10,000/135 msec), a restricted diffusion image consistent with acute infarction was observed in the corona radiata localization on the left (Figure 1e and f).

### Case 2

A 30-year-old female presented to the emergency room of our hospital with complaints of weakness at left upper and lower extremities that started 6 hours earlier. Left hemiparesis was found in neurological examination. In the non-contrast brain CT performed with the pre-diagnosis of cerebrovascular incident, minimal edematous appearance was

From the Department of Radiology (M.T. ✉ mehmett@baskent-ank.edu.tr), Başkent University School of Medicine, Ankara, Turkey.

Received 1 April 2004; revision requested 17 July 2004; revision received 24 July 2004; accepted 26 July 2004.



**Figure 1. a-f.** A 71 year-old female with right hemiparesis. No marked edema appearance consistent with acute infarct can be noted in the non-contrast axial brain CT image (a) through the lateral ventricles 3.5 hours after the onset of acute symptoms. Relative cerebral blood volume (b), relative cerebral blood flow (c) and time to peak (d) CT perfusion maps show large perfusion defect observed in the feeding area of the middle cerebral artery (arrows). Despite the wide perfusion defect observed on CT images, it was noted that tissue progressing to infarct has been arrested in the left corona radiata on a diffusion weighted MR image (e), and the corresponding apparent diffusion coefficient (ADC) map (f).

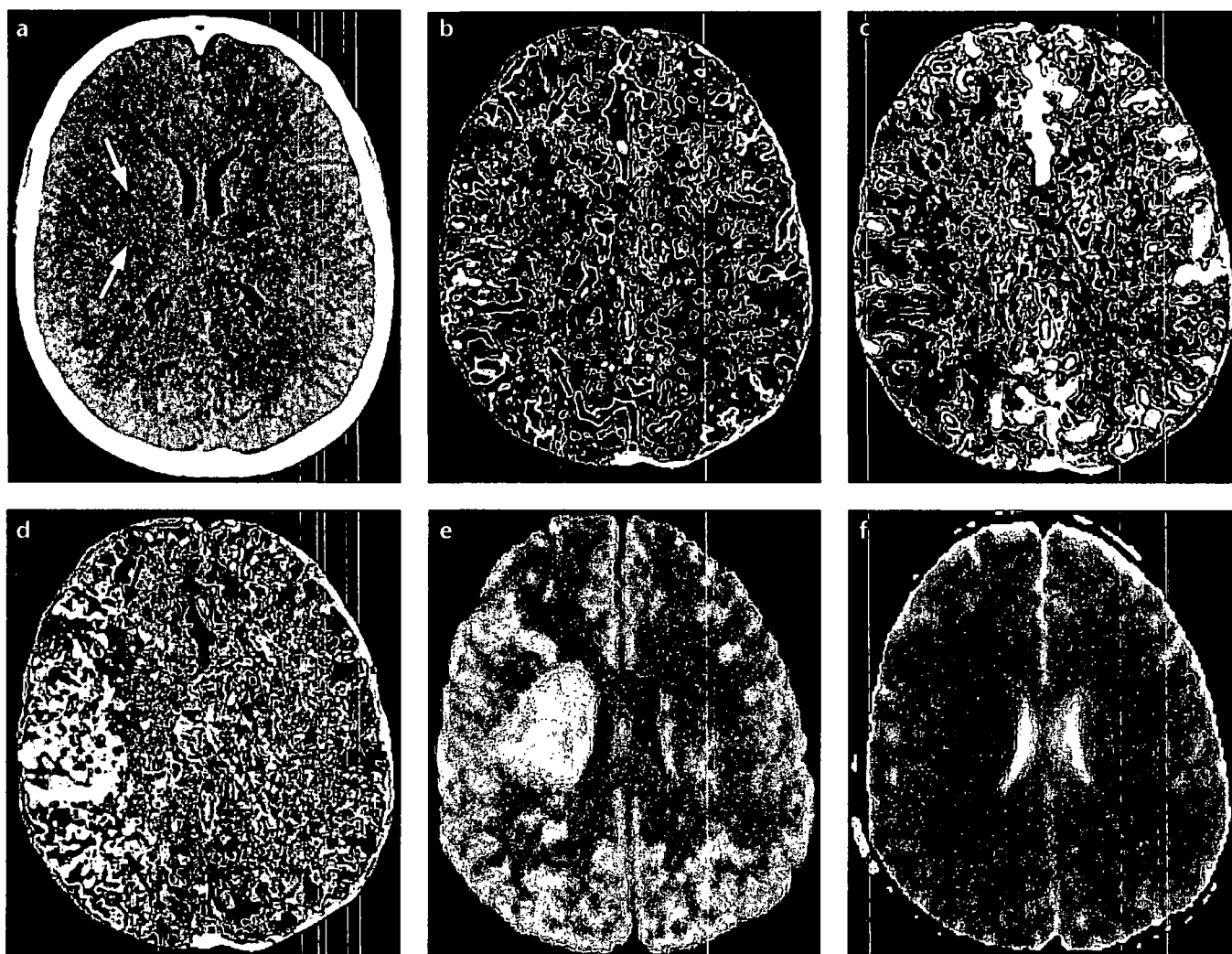
noted in the right lentiform nucleus (Figure 2a). Following the non-contrast brain CT, brain perfusion CT was performed with a protocol similar to that of the first case previously described. Source images were then sent to a separate computer system for postprocessing (Vitrea 2 Workstation, Vital Images Inc., Plymouth, MN, USA). Relative cerebral blood flow, relative cerebral blood volume, and mean transit time images were obtained with a semi-automatic procedure. Wide perfusion defects were found in the left middle cerebral artery territory (Figure 2b-d). On DW images performed about 16 hours after the onset of the patient's symptoms, using a similar technique with that of the first case, a restricted diffusion con-

sistent with acute infarction was observed in the corona radiata (Figure 2e and f). Contrast-enhanced MR carotid angiograms taken in the same session showed the embolism that caused infarct in the patient, originating from a dissection, was observed in the distal part of the common carotid artery.

#### Discussion

Thromboembolic stroke can be seen at any age; however, morbidity and mortality rates are high in middle aged and elderly patients (6). Diagnosis is made only with neurological examination. However, while the symptoms are sensitive in cerebral ischemia, they are not specific (7). Therefore, imaging methods are used for the purpose of

supporting the clinical diagnosis. Non-contrast brain CT examination is frequently used since it is a method that can be employed in emergency conditions and is available in almost every hospital. Brain CT examination is used for detecting tumors, vascular malformations, or subdural hematomas that can clinically imitate stroke and also for excluding bleeding that is a contraindication for thrombolytic treatment (8). CT is typically positive 6-18 hours after ischemia. However, sometimes the early findings of ischemia can be observed on CT images in the first 6 hours. Hyperdense middle cerebral artery sign, hypoattenuation in lentiform nucleus, edema in insular cortex (insular ribbon sign), disappear-



**Figure 2. a-e.** A 30-year-old female with left hemiparesis. Minimal hypoattenuation is observed on non-contrast axial brain CT image at the level of the right lentiform superior nucleus (a) (arrows) 6 hours after the onset of acute symptoms. Relative cerebral blood volume (b), relative cerebral blood flow (c) and mean transit time (d) CT perfusion maps show large perfusion defect observed in the feeding area of the right middle cerebral artery (arrows). Despite the wide perfusion defect observed on CT images, it was noted that tissue progressing to infarct has been arrested in the right corona radiata on diffusion weighted MR image (e), and apparent diffusion coefficient (ADC) map (f).

ance of gray-white matter discrimination, obliteration of sulci, and shifting due to edema can be observed (9, 10). In Case 1, while the CT findings of the early period could not be observed, minimal hypoattenuation at the lentiform nucleus was seen.

Perfusion and diffusion-weighted MR examinations are more sensitive imaging methods in the diagnosis of acute ischemia as compared to routine brain CT. Ischemic areas can be determined within minutes or hours. Both imaging methods can provide rather useful information for determining the tissue under risk that is progressing to infarct, particularly when used together (11). Ischemia with perfusion defect in perfusion MR, which does

not progress to infarct in diffusion MR imaging (ischemic penumbra, diffusion-perfusion mismatch), can be reversible with efficient early treatment. However, diffusion and perfusion examination with MR, although one of the most efficient imaging methods in acute stroke, are not used as the first-step imaging method, especially during the initial hours following the onset of symptoms. Other methods used for determining the perfusion deficit are positron emission tomography, xenon CT, and single photon emission computed tomography (12-14). Use of these methods has been restricted since they are not available in every hospital and are difficult to employ under emergency conditions.

Perfusion brain CT, on the other hand, is a new imaging method capable of providing information about the extension and hemodynamic status of ischemic brain tissue, which can be used in emergency conditions (15, 16). In this examination, the quantity of contrast material passing through the brain tissue is measured, and asymmetrical changes in cerebral perfusion are determined. Perfusion examination of the entire brain is not possible yet. Since only a few neighbouring sections can be imaged, the anatomical region that is clinically involved can be examined with the cooperation of the clinician; otherwise, the basal ganglia level can be selected, including the feeding areas of the anterior, middle, and pos-

terior cerebral arteries. A total of 40 ml of non-ionic iodine contrast material is given using an automatic injector with a delay of 6 seconds and a speed of 8 ml/sec, and then images are taken from two neighbouring sections (16). Parameters such as relative cerebral blood flow, relative cerebral blood volume, and time elapsed for reaching the peak are determined after a semi-automatic procedure to differentiate reversible and irreversible ischemic tissue (15). This differentiation is important particularly in planning the therapy. In both our cases, it was noted that while there were wide perfusion defects in perfusion CT examinations, the brain tissue with progressing infarct was limited to the central region of the perfusion defect. The most important factor here is the efficient planning of therapy in the early period.

Tomandl et al. divided the perfusion of brain tissue in perfusion brain CT examinations into 5 groups according to the values of cerebral blood flow, relative cerebral blood volume, and time elapsed for reaching the peak (16). Brain tissue has been classified as normal, compensating arterial stenosis or occlusion, possibly restorable oligemic tissue, risky tissue, and irreversibly damaged tissue, and a protocol of treatment according to this classification was created (16). In both of our cases, early diagnosis was possible during the time when the brain tissue suffering from acute infarct was in oligemic or risky tissue, and treatment was started in the early phase. When early treatment begins in patients with a diagnosis of acute infarct, the more

risky tissue can be spared. In our cases, it was possible to cure the more risky tissues with the help of early diagnosis with perfusion brain CT examination.

The most significant drawbacks of perfusion brain CT examination are the limitations of multi-detector CT technology presently available and the inability of obtaining sufficient information about the perfusion of the entire brain, since it is possible to take images of only a few sections of the brain. It is recommended that the examination be performed on the basal ganglia level in order to minimize this restriction. It is thus possible to get information about the feeding areas of the anterior, middle, and posterior cerebral arteries.

In conclusion, we believe that using diffusion MR imaging and perfusion CT together provide rather useful information for diagnosing ischemia in the early phase, showing the extension of ischemia, and planning the appropriate therapy.

#### References

1. National Institute of Neurological Disorders and Stroke rtPA Stroke Study Group. Tissue plasminogen activator for acute ischaemic stroke. *N Engl J Med* 1995; 33:1581-1587.
2. American Heart Association. Stroke Facts. Dallas, Tex: American Heart Association; 1999.
3. Wardlaw JM. Overview of Cochrane thrombolysis meta-analysis. *Neurology* 2001; 57:69-76.
4. Prokop M. Multislice CT angiography. *Eur J Radiol* 2000; 36:86-96.
5. Karonen JO, Liu Y, Vanninen RL, et al. Combined perfusion and diffusion-weighted MR imaging in acute ischemic stroke during the 1st week: a longitudinal study. *Radiology* 2000; 217:886-894.
6. Brott T, Bogousslovsky J. Treatment of acute ischemic stroke. *N Engl J Med* 2000; 343:710-722.
7. Mayer TE, Hamann GF, Baranczyk J, et al. Dynamic CT perfusion imaging of acute stroke. *AJNR Am J Neuroradiol* 2000; 21:1441-1449.
8. Grunwald I, Reith W. Non-traumatic neurological emergencies: imaging of cerebral ischemia. *Eur Radiol* 2002; 12:1632-1647.
9. Von Kummer V, Meyding-Lamade U, Forsting M, et al. Sensitivity and prognostic value of early CT in occlusion of middle cerebral artery trunk. *AJNR Am J Neuroradiol* 1994; 15:9-15.
10. Moulin T, Cattin F, Crepin-Leblond T, et al. Early CT signs in acute middle cerebral artery infarction: predictive value for subsequent infarct locations and outcome. *Neurology* 1996; 47:366-375.
11. Eastwood JD, Lev MH, Provenzale JM. Perfusion CT with iodinated contrast material. *AJR Am J Roentgenol* 2003; 180:3-12.
12. Powers WJ, Grubb RIJ, Darriet D, Raichle ME. Cerebral blood flow and cerebral metabolic rate of oxygen requirements for cerebral function and viability in humans. *J Cereb Blood Flow Metab* 1985; 5:600-608.
13. Weir CJ, Bolster AA, Tytler S, et al. Prognostic value of single-photon emission tomography in acute ischaemic stroke. *Eur J Nucl Med* 1997; 24:21-26.
14. Yonas H, Gur D, Claassen D, Wolfson SK, Moosy J. Stable xenon enhanced computed tomography in the study of clinical and pathologic correlates of focal ischemia in baboons. *Stroke* 1988; 19:228-239.
15. Koenig M, Kraus M, Theek C, Klotz E, Gehlen W, Heuser L. Quantitative assessment of the ischemic brain by means of perfusion related parameters derived from perfusion CT. *Stroke* 2001; 32:431-437.
16. Tomandl BF, Klotz E, Handschu R, et al. Comprehensive imaging of ischemic stroke with multislice CT. *Radiographics* 2003; 23:565-592.

**Paper-19:**

**Zussman BM, Boghosian G, Gorniak RJ,  
Olszewski ME et al.: The Relative Effect of  
Vendor Variability in CT Perfusion Results: A  
Method Comparison Study. AJR 2011; 197:468-  
473**

# The Relative Effect of Vendor Variability in CT Perfusion Results: A Method Comparison Study

Benjamin M. Zussman<sup>1</sup>  
Garen Boghosian<sup>1</sup>  
Richard J. Gorniak<sup>1</sup>  
Mark E. Olszewski<sup>2</sup>  
Katrina M. Read<sup>2</sup>  
Khan M. Siddiqui<sup>3</sup>  
Adam E. Flanders<sup>1</sup>

**OBJECTIVE.** There are known interoperator, intraoperator, and intervender software differences that can influence the reproducibility of quantitative CT perfusion values. The purpose of this study was to determine the relative impact of operator and software differences in CT perfusion variability.

**MATERIALS AND METHODS.** CT perfusion imaging data were selected for 11 patients evaluated for suspected ischemic stroke. Three radiologists each independently postprocessed the source data twice, using four different vendor software applications: Results for cerebral blood volume (CBV), cerebral blood flow (CBF), and mean transit time (MTT) were recorded for the lentiform nuclei in both hemispheres. Repeated variables multivariate analysis of variance was used to assess differences in the means of CBV, CBF, and MTT. Bland-Altman analysis was used to assess agreement between pairs of vendors, readers, and read times.

**RESULTS.** Choice of vendor software, but not interoperator or intraoperator disagreement, was associated with significant variability ( $p < 0.001$ ) in CBV, CBF, and MTT. The mean difference in CT perfusion values was greater for pairs of vendors than for pairs of operators.

**CONCLUSION.** Different vendor software applications do not generate quantitative perfusion results equivalently. Intervendor difference is, by far, the largest cause of variability in perfusion results relative to interoperator and intraoperator difference. Caution should be exercised when interpreting quantitative CT perfusion results because these values may vary considerably depending on the postprocessing software.

**Keywords:** brain imaging, CT perfusion, reproducibility, stroke, variability

DOI:10.2214/AJR.10.6058

Received October 30, 2010; accepted after revision December 23, 2010.

<sup>1</sup>Department of Radiology, Thomas Jefferson University Hospital, Ste 1080B, Main Bldg, 132 S Tenth St, Philadelphia, PA 19107-5244. Address correspondence to A. E. Flanders (adam.flanders@jefferson.edu).

<sup>2</sup>Philips Healthcare, Cleveland, OH.

<sup>3</sup>University of Maryland, Baltimore, MD.

AJR 2011; 197:468–473

0361–803X/11/1972–468

© American Roentgen Ray Society

**S**troke is the third leading cause of mortality and a primary cause of disability among adults in the United States. Because stroke damages cerebral tissue rapidly, effective stroke treatment depends on quick and accurate diagnosis. Although unenhanced CT remains the initial diagnostic study of choice in the setting of acute stroke, CT perfusion is an increasingly attractive adjunct because it can be performed rapidly, is relatively safe, and provides valuable qualitative and quantitative information about cerebral blood flow kinetics [1, 2]. Imaging protocols that include CT perfusion improve diagnostic accuracy in stroke detection [3].

CT perfusion calculates perfusion parameters from the first-pass kinetics of an administered IV contrast agent. These parameters are used to distinguish between the potentially reversible penumbra, or cerebral tissue that is at risk for infarction, and the irreversibly damaged infarct core [4]. This information is potentially useful when determining

the risk-benefit ratio for therapeutic intervention with thrombolytic therapy, which is not without significant risk because these drugs can cause life-threatening intracranial hemorrhage [5]. Because CT perfusion results may influence clinical decisions, it is critical that they be reproducible and accurate.

Human operators direct CT perfusion data processing by performing several tasks: They select the image slice to be processed and manually define the ROIs for arterial input and venous output. Interoperator (between operator) differences in performing these tasks have been shown to reduce the reproducibility (increase the variability) of CT perfusion results [6–9]. Repeated CT perfusion processing of identical source data by the same operator has also been associated with variability (intraoperator differences) in CT perfusion results [8].

In addition to human operators, vendor software applications play a central role in generating CT perfusion results. These software applications are fed imaging source



## Vendor Variability in CT Perfusion

data and, with varying degrees of operator interaction, calculate perfusion results using mathematic algorithms. Because these commercial applications are proprietary, it is not known to the end user to what extent they differ from one another. A recent study showed that significantly different CT perfusion values are generated by different vendor postprocessing software applications [10].

Although the effects of human operator differences and software differences on CT perfusion reproducibility have been studied independently, the relative impacts of these factors have not been jointly assessed. The purpose of this study was to assess the reproducibility of quantitative CT perfusion results in a broad contextual manner by comparing the effects of human operator differences with those of software differences.

### Materials and Methods

#### Subjects

The institutional review board approved a waiver for this study because no personal health information was used. CT perfusion imaging data for 11 patients were randomly and retrospectively selected from our institution's database of patients evaluated for carotid insufficiency and possible anterior circulation infarction over a 6-month period. Four inclusion criteria were applied to imaging data: correct patient positioning, absence of motion degradation, adequacy of the contrast bolus, and complete and consistent capture of the arterial input or venous outflow functions. The 11 CT perfusion studies were randomized and deidentified. Patient characteristics, treatments, and outcomes were not recorded in this study.

#### CT Protocol

CT perfusion studies were acquired using one of two methods. In method 1, a 40-channel CT scanner (Brilliance CT 40-Channel, Philips Healthcare) was used to obtain images every 0.5 second with the following acquisition parameters: tube voltage, 80 kVp; tube current, 150 mA; and collimation,  $32 \times 1.25$  mm. Four contiguous 10-mm-thick slices were obtained. In method 2, a 16-channel CT scanner (LightSpeed Pro 16, GE Healthcare) was used to obtain images every 0.5 second for 45 seconds with the following acquisition parameters: tube voltage, 80 kVp; tube current, 200 mA; and collimation,  $4 \times 5$  mm. The four 5-mm-thick slices were reconstructed into two 10-mm-thick slabs. For all CT perfusion studies, 40 mL of 320 mg I/mL of isoosmolar iodinated contrast material was injected IV using a power injector at a rate of 4 mL/s and was followed by 20–40 mL of saline flush. Scanning

was initiated 5 seconds after the start of contrast injection to ensure unenhanced baseline sampling. For all scans, slice orientation was parallel to the hard palate, with the lowest prescribed slice at the level of the anterior commissure.

#### Postprocessing of CT Perfusion Imaging Data

Source CT perfusion data for the 11 subjects were transferred to freestanding workstations with four vendor software applications for postprocessing: Brain Perfusion, Extended Brilliance Workspace, version 3.5, Philips Healthcare; CT Perfusion, version 4.3, GE Healthcare; Vitrea, version 2, Vital Images; and Aquarius Workstation, version 3.5, TeraRecon.

Before postprocessing, the single image slice with the best representation of the lentiform nuclei was preselected by operator consensus for subsequent postprocessing. Lentiform nuclei are well defined and uncomplicated to trace in comparison with irregularly shaped areas, such as frontal white matter, insular cortex, or middle cerebral artery territory, and were selected to minimize variations due to manual placement or drawing of ROIs. In addition, the readers collectively reviewed the correct operation of each software application before performing analyses and practiced performing pilot analyses on each workstation to ensure optimal software usage.

Three neuroradiologists each independently postprocessed all of the source data. Each vendor's semiautomated method was used to calculate the arterial input and venous outflow functions. Freehand ROIs were drawn that circumscribed the right and left lentiform nuclei on the preselected slices. The operators recorded the calculated quantitative perfusion parameters for each ROI, including cerebral blood volume (CBV) measured in mL/100 g, cerebral blood flow (CBF) measured in mL/100 g/min, and mean transit time (MTT) measured in seconds. Postprocessing of the source data was performed on the four different software applications and then repeated, yielding a repeat measure for each operator on each application. In total, 528 discrete sets of values (CBV, CBF, and MTT) and 1584 total values were recorded.

#### Statistical Analysis

Results were transferred to a spreadsheet (Microsoft Excel) that was subsequently imported into the statistical software. Statistical analysis was performed using R (version 2.6.0, The R Foundation for Statistical Computing, <http://www.r-project.org>). A repeated measures multivariate analysis of variance test using Pillai trace was performed to assess differences in the means of CBV, CBF, and MTT. An alpha value of 0.05 was used for the omnibus test. Post hoc

univariate F tests using Bonferroni correction were performed when the omnibus F test indicated a significant difference. An alpha value of 0.01 was used for all post hoc tests.

Bland-Altman analysis was performed to assess agreement between pairs of vendors, operators, and read times. Mean difference, 95% limits of agreement, and 95% CIs were recorded. For data presentation in Tables 1 and 2, the absolute values of the mean difference for pairs of vendors, operators, and read times were averaged. A two-sided Student *t* test was used to compare the average mean differences between pairs of vendors, operators, and read times.

### Results

#### Analysis of Variance

There were no statistically significant differences between the means of CBV, CBF, and MTT related to operator or read time. There were statistically significant differences between the means of CBV, CBF, and MTT with respect to the vendor application used to postprocess the data (Fig. 1). Specifically, CBV, CBF, and MTT were all significantly different between vendors 1 and 2 ( $p < 0.001$ ), 1 and 3 ( $p < 0.001$ ), 1 and 4 ( $p < 0.001$ ), and 2 and 4 ( $p < 0.001$ ). For vendors 3 and 4, CBV, CBF, and MTT were all significantly different, with  $p < 0.001$  for CBF and MTT and  $p = 0.001$  for CBV. Only MTT was significantly different ( $p < 0.001$ ) between vendors 2 and 3.

#### Method Comparison Analysis

In general, the mean difference between values obtained by pairs of vendors was greater in magnitude than the mean difference obtained by pairs of operators or read times (Tables 1 and 2). The data for the method comparison of vendor pairs are listed in Table 3. Method comparison analysis of operator pairs yielded absolute values for interoperator mean differences ranging from 0.0 to 0.3 mL/100 g for CBV, 0.2 to 14.6 mL/100 g/min for CBF, and 0.0 to 0.6 seconds for MTT. For intraoperator mean differences, the ranges were from 0.0 to 0.2 mL/100 g for CBV, 0.1 to 2.6 mL/100 g/min for CBF, and 0.0 to 0.7 seconds for MTT. Figure 2 shows two of the Bland-Altman plots, but plots of the remaining analyses are not shown.

### Discussion

Operator differences have been reported to cause an unacceptably high amount of variability in CT perfusion results. Fiorella et al. [6] studied the effect of operator differences on CT perfusion results by having

Zussman et al.

**TABLE 1: Average Mean Difference in the Values**

Parameter	Average Mean Difference		
	CBV (mL/100 g)	CBF (mL/100 g/min)	MTT (s)
Vendor pairs	1.91 (1.74)	26.23(16.3)	1.65 (0.89)
Operator pairs	0.13 (0.07)	5.23(4.23)	0.24 (0.17)
Time pairs	0.05 (0.07)	1.16(0.9)	0.2 (0.2)

Note—Values in parentheses are SD. CVB = cerebral blood volume, CBF = cerebral blood flow, MTT = mean transit time.

**TABLE 2: Comparison of Average Mean Differences**

Parameter	Two-Sided Student t Test Comparison of Average Mean Differences		
	CBV (p)	CBF (p)	MTT (p)
Vendor vs operator pairs	0.05	0.02	0.01
Vendor vs time pairs	0.05	0.01	0.01
Operator vs time pairs	0.01	0.01	0.29

Note—CVB = cerebral blood volume, CBF = cerebral blood flow, MTT = mean transit time.

three experienced operators process identical source data for 20 stroke patients seven times each. Although they found high interoperator correlation coefficients for CT perfusion results ( $r = 0.73$  for CBV,  $0.87$  for CBF, and  $0.89$  for MTT), the coefficients of variation

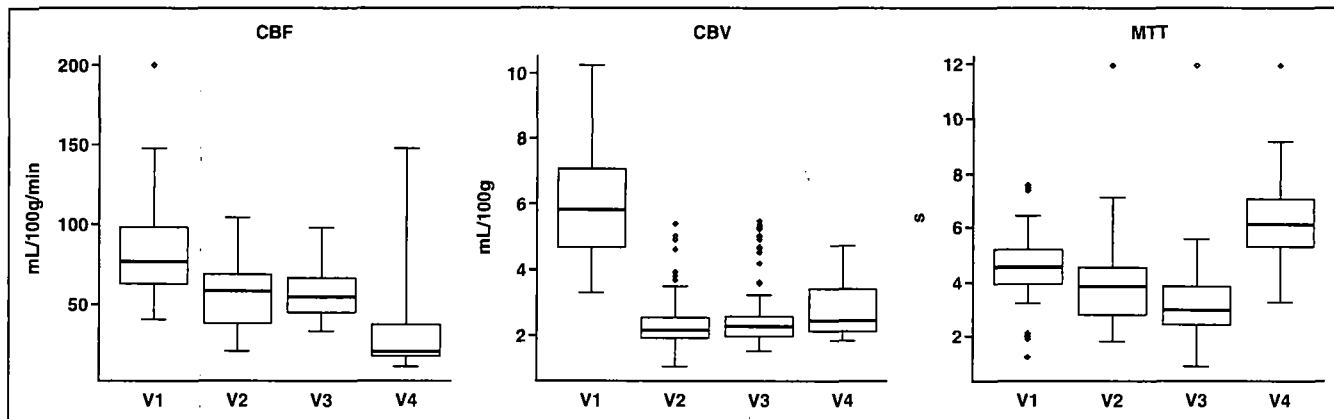
for CT perfusion results were 31% for CBV, 30% for CBF, and 14% for MTT and the authors concluded that these differences were clinically significant and that operator differences limit the usefulness of quantitative CT perfusion results in clinical decision making.

Specifically, differences in operator-defined inputs during data processing may cause this variability. Sanelli et al. [7] systematically varied several input parameters while processing identical source data for three stroke patients and found that major variations of arterial ROI or ROI size had no significant effect on results, whereas even minor variations in the placement of venous ROI or in enhancement cutoff values did significantly

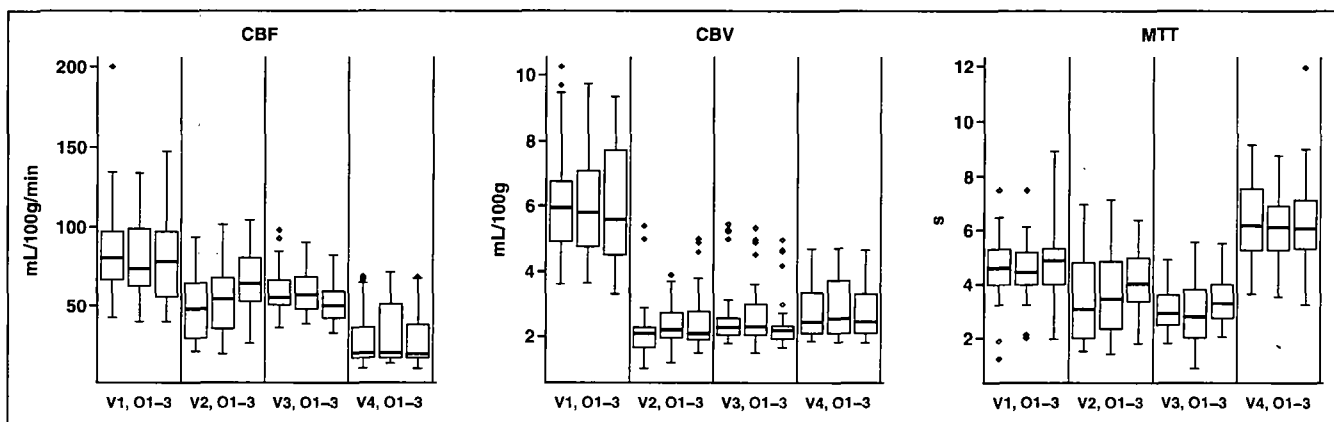
**Fig. 1—Variation in CT perfusion values.** Box-and-whisker plots graphically depict data; bottom and top of each box represent lower and upper quartiles, respectively, and band near middle of box is median. Ends of whiskers represent one SD above and below mean of data, and outliers are plotted as small dots. CBF = cerebral blood flow reported in mL/100 g/min, CBV = cerebral blood volume reported in mL/100 g, MTT = mean transit time reported in seconds, V = vendor, O = observer.

**A,** Box-and-whisker plots show values obtained by vendor. **B,** Box-and-whisker plots show values obtained by vendor and observer (i.e., first 3 boxes show values obtained by vendor 1 and observers 1–3). This row allows visual comparison of interobserver variability with respect to vendor variability.

(Fig. 1 continues on next page)

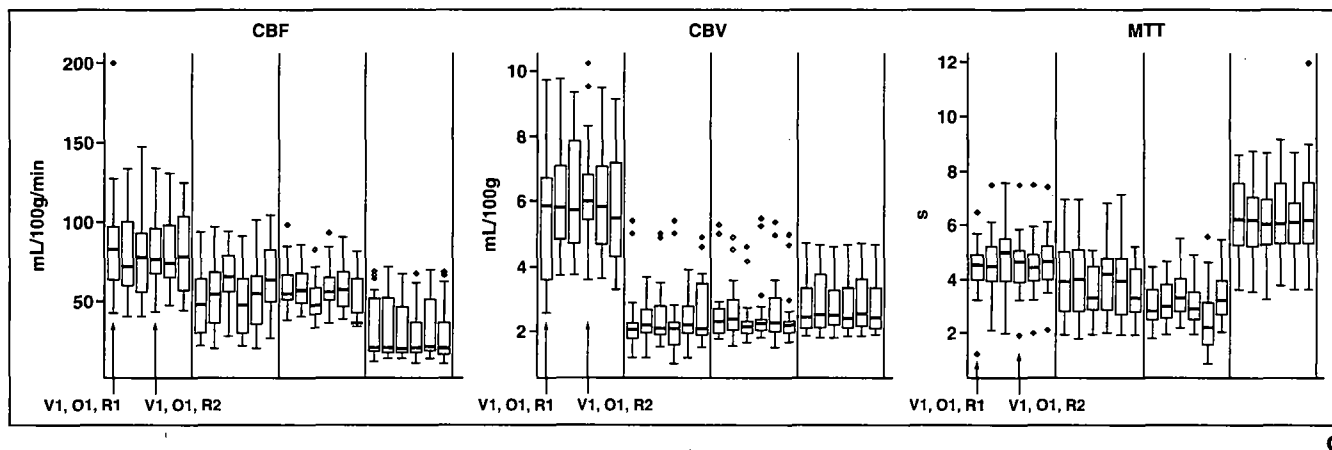


**A**



**B**

**Vendor Variability in CT Perfusion**



**Fig. 1 (continued)**—Variation in CT perfusion values. Box-and-whisker plots graphically depict data; bottom and top of each box represent lower and upper quartiles, respectively, and band near middle of box is median. Ends of whiskers represent one SD above and below mean of data, and outliers are plotted as small dots. CBF = cerebral blood flow reported in mL/100 g/min, CBV = cerebral blood volume reported in mL/100 g, MTT = mean transit time reported in seconds, V = vendor, O = observer. **C**, Box-and-whisker plots show values obtained by vendor, observer, and read time (i.e., first 3 boxes show values obtained by vendor 1 and readers 1–3 at read time 1. Similarly, second 3 boxes show values obtained by vendor 1 and readers 1–3 at read time 2.) This row allows visual comparison of interobserver and intraobserver variability with respect to vendor variability.

alter CT perfusion results. They concluded that minor variations of operator-defined inputs can significantly influence quantitative CT perfusion results.

A standard operator protocol, however, may reduce the effect of operator differences on CT perfusion reproducibility. In another study, Sanelli et al. [8] examined the effect

of observer skill and experience on CT perfusion results by having five observers with different levels of training process identical source data for 20 stroke and vasospasm patients. They found a high correlation ( $r = 0.87-0.99$ ) among all possible pairings of observers and low variability (2.5–9.5%) in CT perfusion results. They concluded that CT perfusion results are reproducible when processed by operators with varying skill levels and emphasized that uniformity of the data-processing process is essential for maintaining good reproducibility.

Strategies to improve the reproducibility of CT perfusion have also been developed. Waaijer et al. [9] studied the effect of operator differences on CT perfusion results by having two operators process identical source data for 20 patients with unilateral symptomatic carotid artery stenosis and one operator process the data twice. They reported interobserver and intraobserver variability for CT perfusion results of less than 11–18% for CBV, 15–19% for CBF, and less than 10% for MTT and found that ratios of CT perfusion results between the symptomatic and asymptomatic cerebral hemispheres were somewhat less variable than standard CT perfusion results (11–16% vs 16–17% for CBV and 10–13% vs 18% for CBF). The authors suggested that to reduce variability, CT perfusion ratios should be reported instead of absolute CT perfusion values.

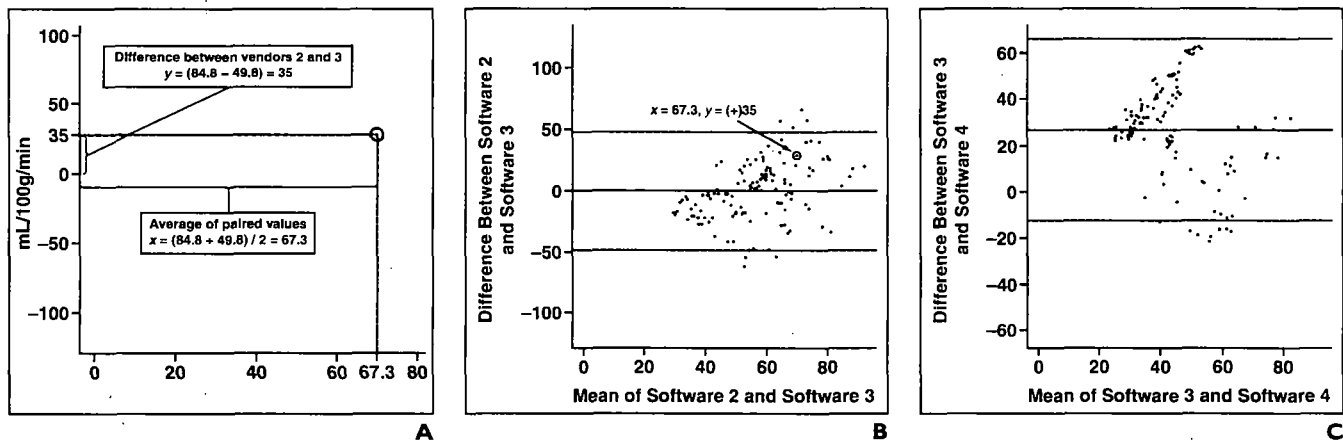
With regard to software differences, there are conflicting reports about the role of software automation. Turk et al. [11] studied the ef-

**TABLE 3: Mean Difference and Limits of Agreement for Values Obtained by Pairs of Vendors**

Vendor Pair	Mean Difference	LLA	ULA
<b>CBV (mL/100 g)</b>			
1 vs 2	3.7 (3.5, 4.0)	0.8 (0.4, 1.3)	6.6 (6.1, 7.0)
1 vs 3	3.6 (3.3, 3.8)	1.1 (0.7, 1.4)	6.1 (5.7, 6.4)
1 vs 4	3.2 (3.0, 3.4)	0.4 (0.0, 0.8)	6.0 (5.6, 6.4)
2 vs 3	-0.2 (-0.2, -0.1)	-1.2 (-1.4, -1.1)	0.9 (0.8, 1.1)
2 vs 4	-0.5 (-0.7, -0.4)	-2.2 (-2.5, -2.0)	1.2 (0.9, 1.5)
3 vs 4	-0.4 (-0.5, -0.2)	-1.9 (-2.2, -1.7)	1.2 (1.0, 1.4)
<b>CBF (mL/100 g/min)</b>			
1 vs 2	26.1 (21.2, 31.1)	-30.7 (-39.4, -22.1)	83.1 (74.4, 91.7)
1 vs 3	25.4 (21.4, 29.5)	-20.7 (-27.7, -13.7)	71.6 (64.6, 78.6)
1 vs 4	52.2 (47.9, 56.6)	2.4 (-5.2, 10.0)	102.1 (94.5, 109.6)
2 vs 3	-0.7 (-4.9, 3.5)	-48.8 (-56.1, -41.5)	47.4 (40.1, 54.7)
2 vs 4	26.1 (22.1, 30.0)	-18.9 (-25.8, -12.1)	71.1 (64.3, 78.0)
3 vs 4	26.8 (23.3, 30.2)	-12.3 (-18.3, -6.4)	65.9 (60.0, 71.8)
<b>MTT (s)</b>			
1 vs 2	0.8 (0.6, 1.0)	-1.4 (-1.7, -1.1)	3.0 (0.6, 1.0)
1 vs 3	1.5 (1.3, 1.7)	-0.7 (-1.1, -0.4)	3.7 (3.4, 4.1)
1 vs 4	-1.5 (-1.7, -1.3)	-4.0 (-4.3, -3.6)	0.9 (0.5, 1.2)
2 vs 3	0.7 (0.5, 0.9)	-1.5 (-1.8, -1.2)	2.9 (2.6, 3.3)
2 vs 4	-2.3 (-2.5, -2.1)	-5.0 (-5.4, -4.6)	0.3 (-0.1, 0.7)
3 vs 4	-3.0 (-3.3, -2.8)	-6.0 (-6.4, -5.5)	-0.1 (-0.6, 0.3)

Note—Values in parentheses are 95% confidence limits. LLA = lower limit of agreement, ULA = upper limit of agreement, CBV = cerebral blood volume, CBF = cerebral blood flow, MTT = mean transit time.

Zussman et al.



**Fig. 2**—Bland-Altman plots. CBF = cerebral blood flow in units of mL/100 g/min.

**A**, Bland-Altman plot graphically compares two methods of measurement in context of values measured. For example, vendor 2 generated CBF value of 49.8 mL/100 g/min and vendor 3 generated CBF value of 84.8 mL/100 g/min for patient 1, observer 1, read time 1, and same cerebral hemisphere. Thus, plot shows that there is bias of 35 (circle) between vendors 2 and 3 at average CBF value of 67.3.

**B**, Actual Bland-Altman plot compares vendors 2 and 3 for CBF. Graphic point generated in **A** is circled. Note that data points hover around y-axis, with average bias, or mean difference of  $-0.7$  (see Table 3 for more details). Mean difference is marked with solid line and dashed lines represent upper and lower limits of agreement.

**C**, Unlike comparison between vendors 2 and 3, plot comparing vendors 3 and 4 for CBF shows significant and larger mean difference of 26.8 (see Table 3 for more details).

fect of software automation on CT perfusion results by using both manual and automated software settings to process identical source data for 33 patients with carotid stenosis before and after treatment by stenting. They found that manual processing resulted in variability coefficients of 19% for CBV, 25% for CBF, and 18% for MTT, which were less variable than the results generated by automated processing. In contrast, Soares et al. [12] studied the effect of software automation on CT perfusion results by having two operators use both manual and automated software settings to process identical source data for 30 patients with suspected acute stroke twice. They found that the automated settings yielded lower coefficients of variation than the manual settings (16% vs 31% for infarct core volume, 6% vs 12% for total perfusion defect volume, 11% vs 24% for CBV, 10% vs 33% for CBF, and 10% vs 17% for MTT).

Choice of postprocessing software has recently been reported to cause significant variability in CT perfusion results. Kudo et al. [10] used five different commercial software applications and one open-source software application to process identical source data for 10 stroke patients three times. They found that ratios of CBF and MTT were significantly different among all software packages and also that the commercial software applications, when gauged against the open-source software application, could be sorted into two groups on the basis of the results they produced. They concluded that commercial software applications do not process CT perfusion results

equivalently and that differences in software tracer delay sensitivity may have caused the bimodal grouping of software applications.

The results of this study differed from the general findings of Fiorella et al. [6], Waaijer et al. [9], and Turk et al. [11], which suggested that human operator differences caused substantial variability in CT perfusion results. Rather, interoperator and intraoperator differences in this study were not associated with any significant variability in CT perfusion results, which more closely matches the results of Sanelli et al. [8]. Those authors did note that the uniformity of operator protocol during data processing is critical for the reproducibility of results. The meticulous review of the operator's manual for each software package and the group pilot analyses that were performed by the operators in this study in preparation for data acquisition may have contributed to this finding. It is difficult to explain the wide range of operator variation reported in the literature, but as long as CT perfusion data processing requires subjective operator inputs, operator disagreement will remain inevitable. The results of this study show that it is possible to limit the magnitude of this variability on several software applications.

The results of this study confirm the conclusion of Kudo et al. [10] that different commercial software applications do not produce quantitative CT perfusion results equivalently. These findings have several noteworthy implications: First, CT perfusion results generated by one vendor may not be generalizable to CT perfusion results generated

by a different vendor. Stated differently, it is likely that a clinician who processes identical source data for one stroke patient on multiple different software applications in the same institution will obtain CBV, CBF, and MTT values that are significantly different. This may especially occur in practice because CT perfusion workflows often include the generation of initial results (using one software application on the CT console) and then repeated secondary results (using a different application on the radiology workstation). Second, software version updates, by definition, modify the properties of that software. It is therefore possible that different versions of the same vendor application will not produce equivalent CT perfusion results (although this finding has not been directly reported). Third, the inability to generalize CT perfusion results between different vendors raises the question of whether quantitative metrics of cerebral perfusion can be relied on for setting best practice standards or treatment recommendations. Indeed, thresholds valid for one application cannot necessarily be applied to a different application.

The results of this study show that software differences constitute the primary cause of variability in CT perfusion results relative to human operator differences. This contextual information may prove valuable for prioritizing efforts to improve CT perfusion reproducibility.

Public knowledge of the mathematic algorithms that are used by software applications to calculate results has generally been restricted

### Vendor Variability in CT Perfusion

by the proprietary nature of commercial post-processing software platforms. Still, a variety of mathematic models have been reported. A 2001 review by Wintermark et al. [13] described two techniques for CT perfusion calculations—a nondeconvolution maximal slope model and a deconvolution model—and a 2009 review by Konstas et al. [4] described at least two methods for calculating CBV and eight models for calculating CBF. More recently, elegant analyses performed with open-source perfusion software showed that complex differences exist between the algorithms used by different vendors [14]. These studies suggest that vendor software applications probably use permutations of the various known mathematic models, but it is possible that other independent techniques are in use. Such differences in the mathematic algorithms used by software applications are the most likely cause of interapplication variability in CT perfusion results.

This study had several limitations. Due to the limited sample size, this study did not determine whether the variation in CT perfusion values was constant throughout the physiologic range of perfusion values. Variation in the normal physiologic range, however, is of lesser clinical importance than variation at the critical perfusion value boundaries between normal and ischemic tissue. Although this study examined the effect of vendor differences on CT perfusion results, it did not analyze the specific software characteristics that led to variability in CT perfusion results due to the proprietary nature of the vendor software applications. Finally, this study did not analyze the clinically acceptable limits of variability in CT perfusion results, which was deemed beyond the scope of this article.

The solution to the software problem may hinge on the development of an industry standard that all CT perfusion postprocessing software applications can be calibrated against. An accepted CT perfusion stan-

dard would provide vendors with the means to conduct their own calibration studies and would eliminate the need to examine proprietary software or clashes with intellectual property boundaries. Vendor performance against this standard could also be used as an independent basis of comparison for potential customers. Industrywide use of a CT perfusion standard would likely be a potent driver of increased reproducibility among different vendors and thereby establish a greater capacity to rely on quantitative perfusion metrics for clinical decision making. At least one team is already working on developing a virtual standard called a “digital phantom” for this purpose [14] and more attention to this opportunity is warranted.

In conclusion, different vendor software applications do not generate quantitative perfusion results equivalently. Software differences constitute the primary cause of variability in perfusion results relative to interoperator and intraoperator differences. Caution should be exercised when interpreting quantitative CT perfusion data because these results may vary considerably depending on the postprocessing software. Further studies are needed to determine the limits of clinically acceptable variability and error in CT perfusion results.

#### References

1. Wintermark M, Albers GW, Alexandrov AV, et al. Acute stroke imaging research roadmap. *AJNR* 2008; 29:e23–e30
2. Hoeffner EG, Case I, Jain R, et al. Cerebral perfusion CT: technique and clinical applications. *Radiology* 2004; 231:632–644
3. Hopyan J, Ciarallo A, Dowlatshahi D, et al. Certainty of stroke diagnosis: incremental benefit with CT perfusion over noncontrast CT and CT angiography. *Radiology* 2010; 255:142–153
4. Konstas AA, Goldmakher GV, Lee TY, Lev MH. Theoretic basis and technical implementations of CT perfusion in acute ischemic stroke. Part 1. Theoretic basis. *AJNR* 2009; 30:662–668
5. Latchaw RE, Yonas H, Hunter GJ, et al. Guidelines and recommendations for perfusion imaging in cerebral ischemia: a scientific statement for healthcare professionals by the writing group on perfusion imaging from the Council on Cardiovascular Radiology of the American Heart Association. *Stroke* 2003; 34:1084–1104
6. Fiorella D, Heiserman J, Prenger E, Partovi S. Assessment of the reproducibility of postprocessing dynamic CT perfusion data. *AJNR* 2004; 25:97–107
7. Sanelli PC, Lev MH, Eastwood JD, Gonzalez RG, Lee TY. The effect of varying user-selected input parameters on quantitative values in CT perfusion maps. *Acad Radiol* 2004; 11:1085–1092
8. Sanelli PC, Nicola G, Tsiouris AJ, et al. Reproducibility of postprocessing of quantitative CT perfusion maps. *AJR* 2007; 188:213–218
9. Waaijer A, van der Schaaf IC, Velthuis BK, et al. Reproducibility of quantitative CT brain perfusion measurements in patients with symptomatic unilateral carotid artery stenosis. *AJNR* 2007; 28:927–932
10. Kudo K, Sasaki M, Yamada K, et al. Differences in CT perfusion maps generated by different commercial software: quantitative analysis by using identical source data of acute stroke patients. *Radiology* 2010; 254:200–209
11. Turk AS, Grayev A, Rowley HA, et al. Variability of clinical CT perfusion measurements in patients with carotid stenosis. *Neuroradiology* 2007; 49:955–961
12. Soares BP, Dankbaar JW, Bredno J, et al. Automated versus manual post-processing of perfusion-CT data in patients with acute cerebral ischemia: influence on interobserver variability. *Neuroradiology* 2009; 51:445–451
13. Wintermark M, Maeder P, Thiran JP, Schnyder P, Meuli R. Quantitative assessment of regional cerebral blood flows by perfusion CT studies at low injection rates: a critical review of the underlying theoretical models. *Eur Radiol* 2001; 11:1220–1230
14. Kudo K, Christensen S, Sasaki M, Ostergaard L. STIR-1 Digital Phantom Project. (abstr) *Proceedings of the International Stroke Conference of the Stroke Imaging Repository (STIR)*. San Antonio, TX: Stroke Imaging Repository Consortium, 2010



































